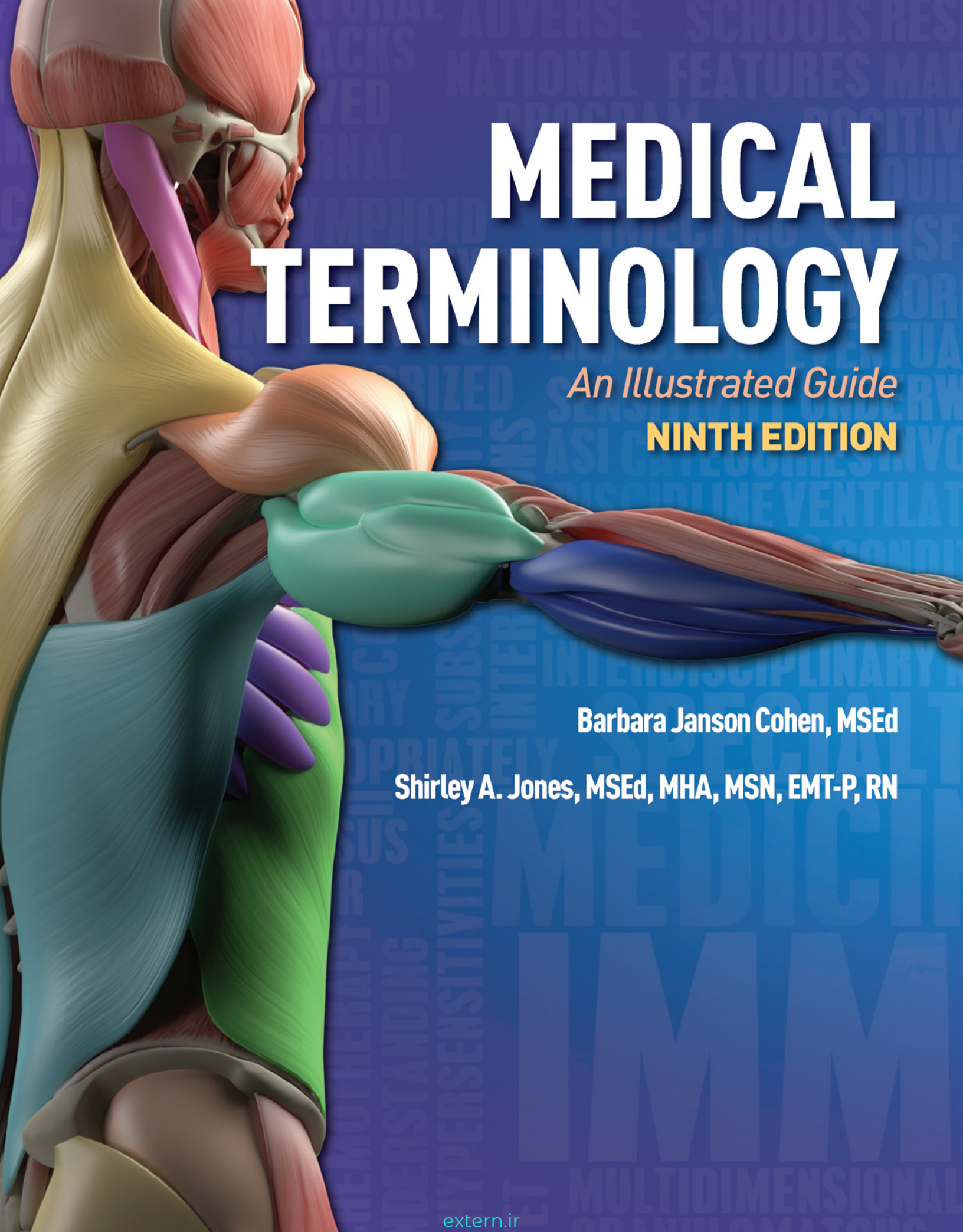

MEDICAL TERMINOLOGY

An Illustrated Guide

NINTH EDITION

Barbara Janson Cohen, MSEd

Shirley A. Jones, MSEd, MHA, MSN, EMT-P, RN

extern.ir

MEDICAL TERMINOLOGY

An Illustrated Guide

NINTH EDITION

Barbara Janson Cohen, MSEd

Shirley A. Jones, MSEd, MHA, MSN, EMT-P, RN

JONES & BARTLETT
LEARNING

extern.ir

World Headquarters
Jones & Bartlett Learning
5 Wall Street
Burlington, MA 01803
978-443-5000
info@jblearning.com
www.jblearning.com

Jones & Bartlett Learning books and products are available through most bookstores and online booksellers. To contact Jones & Bartlett Learning directly, call 800-832-0034, fax 978-443-8000, or visit our website, www.jblearning.com.

Substantial discounts on bulk quantities of Jones & Bartlett Learning publications are available to corporations, professional associations, and other qualified organizations. For details and specific discount information, contact the special sales department at Jones & Bartlett Learning via the above contact information or send an email to specialsales@jblearning.com.

Copyright © 2021 by Jones & Bartlett Learning, LLC, an Ascend Learning Company

All rights reserved. No part of the material protected by this copyright may be reproduced or utilized in any form, electronic or mechanical, including photocopying, recording, or by any information storage and retrieval system, without written permission from the copyright owner.

The content, statements, views, and opinions herein are the sole expression of the respective authors and not that of Jones & Bartlett Learning, LLC. Reference herein to any specific commercial product, process, or service by trade name, trademark, manufacturer, or otherwise does not constitute or imply its endorsement or recommendation by Jones & Bartlett Learning, LLC and such reference shall not be used for advertising or product endorsement purposes. All trademarks displayed are the trademarks of the parties noted herein. *Medical Terminology: An Illustrated Guide, Ninth Edition* is an independent publication and has not been authorized, sponsored, or otherwise approved by the owners of the trademarks or service marks referenced in this product.

There may be images in this book that feature models; these models do not necessarily endorse, represent, or participate in the activities represented in the images. Any screenshots in this product are for educational and instructive purposes only. Any individuals and scenarios featured in the case studies throughout this product may be real or fictitious, but are used for instructional purposes only.

The authors, editor, and publisher have made every effort to provide accurate information. However, they are not responsible for errors, omissions, or for any outcomes related to the use of the contents of this book and take no responsibility for the use of the products and procedures described. Treatments and side effects described in this book may not be applicable to all people; likewise, some people may require a dose or experience a side effect that is not described herein. Drugs and medical devices are discussed that may have limited availability controlled by the Food and Drug Administration (FDA) for use only in a research study or clinical trial. Research, clinical practice, and government regulations often change the accepted standard in this field. When consideration is being given to use of any drug in the clinical setting, the health care provider or reader is responsible for determining FDA status of the drug, reading the package insert, and reviewing prescribing information for the most up-to-date recommendations on dose, precautions, and contraindications, and determining the appropriate usage for the product. This is especially important in the case of drugs that are new or seldom used.

21683-7

Production Credits

VP, Product Management: Amanda Martin
Director of Product Management: Cathy L. Esperti
Product Coordinator: Elena Sorrentino
Senior Project Specialist: Vanessa Richards
Digital Project Specialist: Angela Dooley
Director of Marketing: Andrea DeFronzo
Marketing Manager: Suzy Balk
VP, Manufacturing and Inventory Control: Therese Connell
Composition & Project Management: Aptara Inc.
Cover Design: Kristin E. Parker
Senior Media Development Editor: Troy Liston
Rights Specialist: Rebecca Damon
Cover Image (Title Page, Part Opener, Chapter Opener): © Anatomy Insider/Shutterstock and © kentoh/Shutterstock
Printing and Binding: LSC Communications
Cover Printing: LSC Communications

Library of Congress Cataloging-in-Publication Data
Library of Congress Cataloging-in-Publication Data unavailable at time of printing.

Library of Congress Control Number: 2019916641

6048

Printed in the United States of America
24 23 22 21 20 10 9 8 7 6 5 4 3 2 1

extern.ir

For their ongoing, wholehearted love and support, I dedicate this ninth edition of *Medical Terminology: An Illustrated Guide* to my children, Jocelyn Hooven and Saul Janson.

—Barbara Janson Cohen

I dedicate this book to my parents Vivian and George Jones, to my sister Virginia E. Kelleher, and to Francis, who are all heroes in my life.

—Shirley A. Jones

extern
www.extern.ir
مرجع دانلود رایگان کتب پزشکی، پیراپزشکی، علوم پایه، دندان پزشکی و داروسازی
فیلم ها و تصاویر آموزشی پزشکی برای دانشجویان، اکسترن ها، اینترن ها و رزیدنت ها
مرجع مقالات پزشکی و سلامتی بر اساس رفرنس های معتبر

Brief Contents

Preface x
Acknowledgments xi
Reviewers xii
User's Guide xiii

PART I Introduction to Medical Terminology 1

1 Concepts, Suffixes, and Prefixes of Medical Terminology 2
2 Body Structure 38
3 Disease and Treatment 74

PART II Body Systems 123

4 Integumentary System 124
5 Skeletal System 150
6 Muscular System 188
7 Nervous System and Mental Health 216
8 Special Senses: Ear and Eye 258
9 Endocrine System 292
10 Cardiovascular and Lymphatic Systems 314
11 Blood and Immunity 356
12 Respiratory System 390
13 Digestive System 424
14 Urinary System 460
15 Male Reproductive System 488
16 Female Reproductive System; Pregnancy and Birth 510

Appendices:

1 Commonly Used Symbols 554
2 Abbreviations and Their Meanings 555
3 Word Parts and Their Meanings 564
4 Meanings and Their Corresponding Word Parts 571
5 Word Roots 579
6 Suffixes 584
7 Prefixes 586
8 Metric Measurements 588
9 Stedman's Medical Dictionary at a Glance 589
10 Drugs 590
11 Answer Key 595

Glossary 622
Figure Credits 648
Index of Boxes 654
Index 655

extern.ir

Contents

Preface x
Acknowledgments xi
Reviewers xii
User's Guide xiii

PART I Introduction to Medical Terminology 1

1 Concepts, Suffixes, and Prefixes of Medical Terminology 2

Introduction 4

Concepts of Medical Terminology 4

Word Parts 4
Combining Forms 5

Word Derivations 6
Words Ending in *x* 6
Suffixes Beginning With *rh* 6

Pronunciation 6
Soft and Hard *c* and *g* 7
Silent Letters and Unusual Pronunciations 7

Abbreviations 8
Phrase Abbreviations 8
Symbols 8

Medical Dictionaries 8

Suffixes 9
Noun Suffixes 9
Adjective Suffixes 12

Forming Plurals 15
Some Exceptions to the Rules 18

Prefixes 18

2 Body Structure 38

Introduction 40

The Cell 40

Tissues 43
Membranes 45

Organs and Organ Systems 45

Word Parts Pertaining to Cells, Tissues, and Organs 47

The Body as a Whole 51
Directional Terms 52
Body Cavities 54
Abdominal Regions 54
Positions 55

Word Parts Pertaining to Body Structure 57

3 Disease and Treatment 74

Introduction 76

Types of Diseases 76

Infectious Diseases 76
Bacteria 78

Responses to Disease 79
Inflammation 79
Phagocytosis 79
Immunity 79

Neoplasia 80

Word Parts Pertaining to Disease 82

Diagnosis 89
Imaging Techniques 91

Treatment 93
Surgery 93

Alternative and Complementary Medicine 95

Cancer 95

Word Parts Pertaining to Diagnosis and Treatment 98

Drugs 106
Adverse Drug Effects 106
Drug Names 106
Drug Information 106

Herbal Medicines 106

Drug Administration 107

Word Parts Pertaining to Drugs 112

extern.ir

PART II Body Systems 123

4 Integumentary System 124

Introduction 126

Anatomy of the Skin 126

Associated Skin Structures 126

Roots Pertaining to the Integumentary System 129

Clinical Aspects of the Skin 130
- Wounds 131
- Dermatitis 133
- Psoriasis 133
- Autoimmune Disorders 134
- Skin Cancer 134

5 Skeletal System 150

Introduction 152

Divisions of the Skeleton 152

Bone Formation 155

Structure of a Long Bone 155

Joints 156

Roots Pertaining to the Skeletal System 158

Clinical Aspects of the Skeleton 160
- Infection 162
- Fractures 162
- Metabolic Bone Diseases 162
- Neoplasms 164
- Joint Disorders 164
- Disorders of the Spine 166

6 Muscular System 188

Introduction 190

Types of Muscles 190

Skeletal Muscle 190
- Muscle Structure 190
- Muscle Action 190
- Naming of Muscles 194

Roots Pertaining to Muscles 197

Clinical Aspects of the Muscular System 198
- Muscular Dystrophy 198
- Multiple-System Disorders Involving Muscles 198
- Stress Injuries 199

7 Nervous System and Mental Health 216

Introduction 218

Organization of the Nervous System 218
- The Neuron 218
- Nerves 219

The Brain 219
- Protecting the Brain 220

The Spinal Cord 222
- The Spinal Nerves 222
- Reflexes 222

The Autonomic Nervous System 224

Word Parts Pertaining to the Nervous System 227

Clinical Aspects of the Nervous System 231
- Vascular Disorders 231
- Head Injury 231
- Confusion and Coma 232
- Infection 232
- Neoplasms 233
- Degenerative Diseases 233
- Epilepsy 234
- Sleep Disturbances 234
- Others 235

Behavioral Disorders 235
- Anxiety Disorders 235
- Mood Disorders 236
- Psychosis 236
- Attention Deficit Hyperactivity Disorder 236
- Autism Spectrum Disorder 237
- Drugs Used in Treatment 237

8 Special Senses: Ear and Eye 258

Introduction 260

The Senses 260

The Ear 262

Clinical Aspects of Hearing 266
- Hearing Loss 266
- Otitis 266
- Otosclerosis 266
- Ménière Disease 266
- Acoustic Neuroma 266

The Eye and Vision 269

Word Parts Pertaining to the Eye and Vision 273

Clinical Aspects of Vision 276

extern.ir

Errors of Refraction 276
Infection 276
Disorders of the Retina 276
Cataract 278
Glaucoma 278

9 Endocrine System 292

Introduction 294

Hormones 294

The Endocrine Glands 294
Pituitary 296
Thyroid and Parathyroids 296
Adrenals 297
Pancreas 297

Other Endocrine Tissues 297

Roots Pertaining to the Endocrine System 299

Clinical Aspects of the Endocrine System 300
Pituitary 300
Thyroid 301
Parathyroids 301
Adrenals 301
The Pancreas and Diabetes 302

10 Cardiovascular and Lymphatic Systems 314

Introduction 316

The Heart 317
Blood Flow Through the Heart 317
Blood Supply to the Myocardium 318
The Heartbeat 318
Electrocardiography 319

The Vascular System 321
Blood Pressure 321

Roots Pertaining to the Cardiovascular System 326

Clinical Aspects of the Cardiovascular System 328
Atherosclerosis 328
Thrombosis and Embolism 328
Aneurysm 329
Hypertension 329
Heart Disease 330
Disorders of the Veins 333

The Lymphatic System 337

Roots Pertaining to the Lymphatic System 340

Clinical Aspects of the Lymphatic System 341

11 Blood and Immunity 356

Introduction 358

Blood 358
Blood Plasma 358
Blood Cells 358
Blood Types 362

Immunity 364
Innate Immunity 364
Adaptive Immunity 364
Types of Adaptive Immunity 365

Word Parts Pertaining to Blood and Immunity 367

Clinical Aspects of Blood 370
Anemia 370
Coagulation Disorders 373
Neoplasms 373

Clinical Aspects of Immunity 374
Hypersensitivity 374
Immunodeficiency 374
Autoimmune Diseases 375

12 Respiratory System 390

Introduction 392

Upper Respiratory Passageways 392
The Nose 392
The Pharynx 393

Lower Respiratory Passageways and Lungs 394
The Larynx 394
The Trachea 394
The Bronchial System 395
The Lungs 395

Breathing 395
Inspiration 396
Expiration 396

Gas Transport 396

Word Parts Pertaining to the Respiratory System 398

Clinical Aspects of the Respiratory System 401
Infections 401
Emphysema 404
Asthma 405
Pneumoconiosis 405
Lung Cancer 405
Respiratory Distress Syndrome 405
Cystic Fibrosis 405
Sudden Infant Death Syndrome 405
Pleural Disorders 405
Diagnosis of Respiratory Disorders 406

extern.ir

13 Digestive System 424

Introduction 426

Digestion 426

The Digestive Tract 426
The Mouth to the Stomach 427
The Small Intestine 428
The Large Intestine 429

The Accessory Organs 429

Roots Pertaining to the Digestive System 432

Clinical Aspects of the Digestive System 436
Digestive Tract 436
Accessory Organs 440

14 Urinary System 460

Introduction 462

The Kidneys 462
Kidney Location and Structure 462
The Nephrons 463
Blood Supply to the Kidney 463

Urine Formation 463
Transport and Removal of Urine 464

Roots Pertaining to the Urinary System 466

Clinical Aspects of the Urinary System 469
Infections 469
Glomerulonephritis 469
Nephrotic Syndrome 470
Renal Failure 470
Urinary Stones 472
Cancer 472
Urinalysis 473

15 Male Reproductive System 488

Introduction 490

The Testes 490

Transport of Spermatozoa 492

The Penis 492

Formation of Semen 492

Word Parts Pertaining to the Male Reproductive System 494

Clinical Aspects of the Male Reproductive System 496
Infection 496
Benign Prostatic Hyperplasia 497
Cancer 497
Cryptorchidism 498
Infertility 498

Erectile Dysfunction 498
Inguinal Hernia 498

16 Female Reproductive System; Pregnancy and Birth 510

Introduction 512

The Female Reproductive System 512
The Ovaries 512
The Uterine Tubes, Uterus, and Vagina 512
The External Genital Organs 512

The Mammary Glands 512

The Menstrual Cycle 514
Menopause 515

Contraception 515

Roots Pertaining to the Female Reproductive System 518

Clinical Aspects of Female Reproduction 521
Infection 521
Fibroids 522
Endometriosis 522
Dysfunctional Uterine Bleeding 523
Premenstrual Syndrome 523
Polycystic Ovarian Syndrome 523
Cancer of the Female Reproductive Tract 523
Breast Cancer 523

Pregnancy and Birth 528
Fertilization and Early Development 528
The Placenta 528
Fetal Circulation 530
Childbirth 531
Lactation 532

Roots Pertaining to Pregnancy and Birth 534

Clinical Aspects of Pregnancy and Birth 535
Infertility 535
Ectopic Pregnancy 535
Preeclampsia 536
Abortion 536
Rh Incompatibility 536
Placental Abnormalities 536
Mastitis 536

Congenital Disorders 537
Diagnosis of Congenital Disorders 539

extern.ir

Appendices:

1 Commonly Used Symbols 554

2 Abbreviations and Their Meanings 555

3 Word Parts and Their Meanings 564

4 Meanings and Their Corresponding Word Parts 571

5 Word Roots 579

6 Suffixes 584

7 Prefixes 586

8 Metric Measurements 588

9 Stedman's Medical Dictionary at a Glance 589

10 Drugs 590

11 Answer Key 595

Glossary 622

Figure Credits 648

Index of Boxes 654

Index 655

extern.ir

Preface

Knowledge of medical terminology is fundamental to a wide variety of healthcare fields. This text is designed to satisfy the basic learning requirements needed to practice in any health career setting. In the course of your training and future careers, you will need to learn thousands of new terms. The job might be overwhelming if not for learning the skills of dividing the words into their component parts. These roots, suffixes, and prefixes appear over and over in different terms but retain the same meanings. Knowing these meanings will help you define and remember a host of words. This process is like using a set of building blocks to assemble different structures. Using a more scientific example, it is like using the four bases in DNA to code for all the amino acids needed to make proteins.

The text opens with a general introduction to word parts and the human body as a whole, followed by an overview of diseases and treatments. Each subsequent chapter on the individual body systems begins with an illustrated overview of the system with definitions of key terms relevant to that system. Tables of word parts and exercises on using them follow. Turning to the abnormal, a section on diseases and treatments is included, followed by definitions of related key terms. The section of enrichment terms includes words and phrases that are "good to know" if time allows or if someone is particularly interested in that specialty. The sequence of the systems chapters follows the same order as that found in traditional anatomy and physiology books. Thus this text easily can be used simultaneously with study of A & P. We have tried to make this text easy to use and full of reinforcing drills. We have also included many phonetic pronunciations so you can recognize technical terms when they are spoken and can comfortably use them yourself. Each chapter is enlivened with a short opening case study. These may have some words and abbreviations that are unfamiliar to you, especially at the start of the text. They are included to spark your interest in the chapter material, and give you a sense of medical situations and language. Don't be concerned if you don't understand them completely. Return to them after you study the chapter, or even later chapters, and see if they are more understandable.

You are probably at the beginning of a long journey to gain accomplishment in your chosen field. We hope that this text will aid you in that endeavor and provide a basis on which to build your career.

—Barbara Janson Cohen
and Shirley A. Jones

extern.ir

Acknowledgments

In our constant quest to improve the quality of *Medical Terminology: An Illustrated Guide*, we rely on the advice and talents of many people. First, we want to acknowledge the observant instructors and students who take the time to suggest improvements in the text. Also we thank the reviewers, who make many valuable suggestions for revisions. As always, we are grateful to the dedicated publishing staff; especially for this edition, Jonathan Joyce, Michael Kerns, Julie Vitale, Jeremiah Kiely, Cody Adams, Leo Gray, and Jennifer Clements.

—*Barbara Janson Cohen*
and Shirley A. Jones

extern.ir

Reviewers

Cynthia Bowers, MS
Adjunct Instructor
Department of Allied Health
City College of Montana State University-Billings
Billings, Montana

Gerard Cronin, MS
Associate Professor
Department of Health Sciences
Salem Community College
Salem County, New Jersey

Dr. Abbey Dondanville, EdD, LAT
Associate Dean
Department of Health Sciences
Piedmont College
Demorest, Georgia

Robin Gardenhire, MSEd
Clinical Instructor
Department of Respiratory Therapy
Georgia State University
Atlanta, Georgia

Dr. David Good, PhD
School of Allied Health
Australian Catholic University
Sydney, Australia

Carolyn Hart, PhD, RN, CNE
Chair
Department of Nursing
Barry University
Miami, Florida

Chris Haynes, BS, MS
Department of Natural Sciences
Shelton State College
Tuscaloosa, Alabama

Timothy Jones
University of Oklahoma
Center for Distance Learning
Norman, Oklahoma

Karma Peters, PT, DPT, GCS
Clinical Assistant Professor of Physical Therapy
Carroll University
Waukesha, Wisconsin

Melissa C. Poua, BSCLS, MT (ASCP)
Instructor
Department of Medical Laboratory Sciences
Andrews University
Berrien Springs, Michigan

Melissa Reed, PhD
Associate Professor
Assistant Chair
Exercise Science Division
West Chester University
West Chester, Pennsylvania

Tasha Simpson
Assistant Professor
Department of Medical Laboratory Sciences
Andrews University
Berrien Springs, Michigan

Dr. Chanadra Young Whiting, EdD, MPH/HSA
Clinical Assistant Professor
Health Services Administration
Florida International University
Miami, Florida

extern.ir

User's Guide

Medical Terminology: An Illustrated Guide, Ninth Edition was created and developed to help you master the language of medicine. The tools and features in the text will help you work through the material presented. Please take a few moments to look through this User's Guide, which will introduce you to the features that will enhance your learning experience.

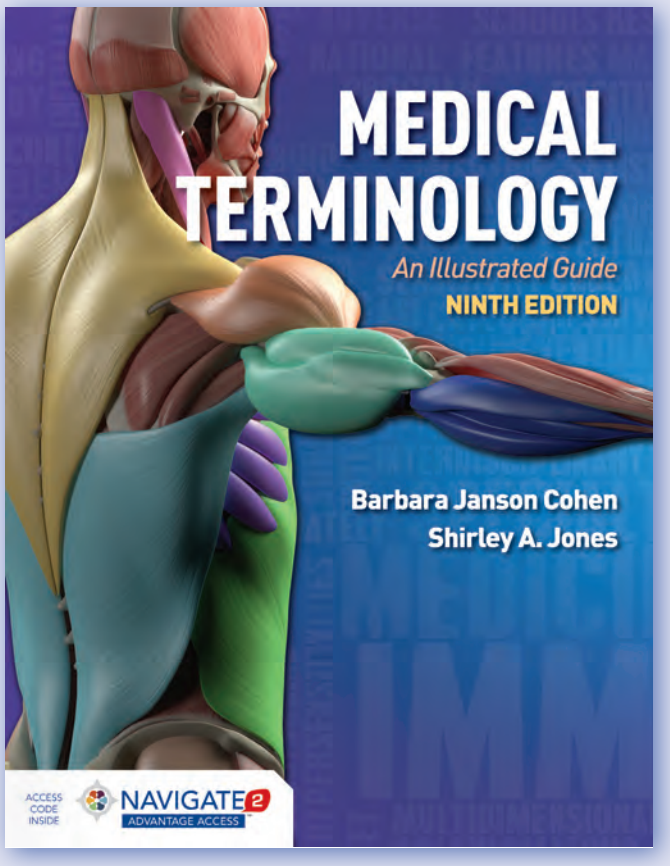

Learning Objectives

After careful study of this chapter, you should be able to:

1. Compare the location and function of smooth, cardiac, and skeletal muscles. ***P190***
2. Describe the typical structure of a skeletal muscle. ***P190***
3. Briefly describe the mechanism of muscle contraction. ***P190***
4. Explain how muscles work together to produce movement. ***P191***
5. Describe the main types of movements produced by muscles. ***P192***
6. List some of the criteria for naming muscles, and give examples of each. ***P192***
7. Identify and use the roots pertaining to the muscular system. ***P197***
8. Describe at least seven disorders that affect muscles. ***P198***
9. Interpret abbreviations pertaining to muscles. ***P204***
10. Analyze several case studies involving muscles. ***PP189, 212***

Case Study: Thomas s Brachial Plexus Injury

Chief Complaint
Thomas, a 16 y/o high school student, had a severe lacrosse accident that resulted in a flail arm. He had sustained right brachial plexus injury and had no recovery. He has continued to take medication for neurologic pain. He was scheduled to see his orthopedic surgeon for a possible brachial plexus exploration.

Examination
The orthopedic surgeon examined Thomas and noted that there had not been any change in his condition since the previous visit. Thomas still had no feeling or motion in his right shoulder or arm. He had atrophy over the supraspinatus and infraspinatus muscles and also subluxation of his shoulder and deltoid atrophy. He had no active motion of the right upper extremity and no sensation. The rest of his orthopedic exam showed full ROM of his hips, knees, and ankles with intact sensation and palpable distal pulses as well as normal motor function. He was diagnosed with a possible middle trunk brachial plexus injury from C7.

Clinical Course
Thomas and his parents had previous discussions with the surgeon and were aware of the prognosis and treatment plan. With middle trunk brachial plexus injury, damage to the subscapular nerve will interrupt conduction to the subscapularis and teres major muscles. Damage to the long thoracic nerve prevents conduction to the serratus anterior muscles. Injury to the pectoral nerves affects the pectoralis major and minor muscles.

Thomas was scheduled for an EMG, nerve conduction studies, and somatosensory evoked potentials (SSEPs). His diaphragm was examined under fluo oscopy to R/O phrenic nerve injury. The results of the diagnostic studies indicated that Thomas had most likely sustained a middle trunk brachial plexus injury. Thomas was scheduled for a brachial plexus exploration with possible bilateral sural (calf) nerve graft, nerve transfer, or gracilis muscle graft from his right thigh.

Case Study Revisited: Once you complete this chapter, please review the case follow-up on p. 205.

Ancillaries *At-A-Glance*

Visit the web resource to access the following resources.

Learning Resources

- eBook
- A&P Module with Heart & Lung Sounds
- Image bank
- TestPrep
- Animations
- Audio Pronunciation Glossary

Chapter 6 ■ Muscular System **189**

Chapter Contents, Objectives, and Pretests
Chapter Opening Case Studies and Objectives help you identify learning goals and familiarize yourself with the materials covered in the chapter. Chapter Pretests quiz students on previous knowledge at the beginning of each chapter. Students should take each Chapter Pretest before starting the chapter and again after completing the chapter in order to measure progress.

extern.ir

Detailed Illustrations

Detailed, full-color drawings and photographs illuminate the chapters. These include clinical photographs and tissue micrographs. The many figures amplify and clarify the text and are particularly helpful for visual learners.

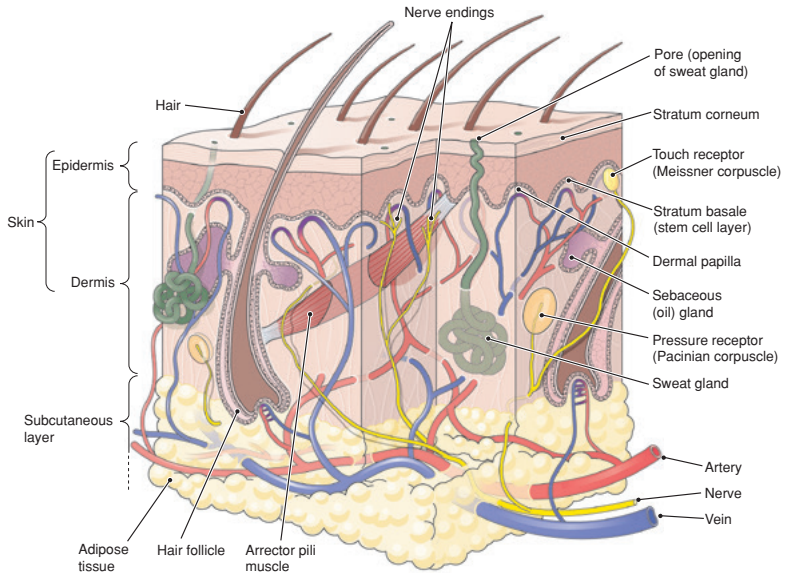

FIGURE 4-1 Cross-section of the skin. The skin layers and associated structures are shown.

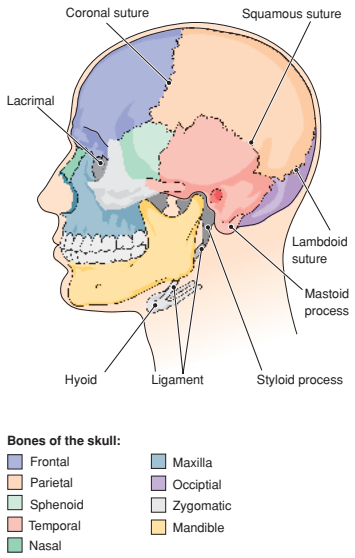

FIGURE 5-2 The skull from the left. An additional cranial bone, the ethmoid (*ETH-moyd*), is visible mainly from the interior of the skull. The hyoid is considered part of the axial skeleton but is not attached to any other bones. The tongue and other muscles are attached to the hyoid.

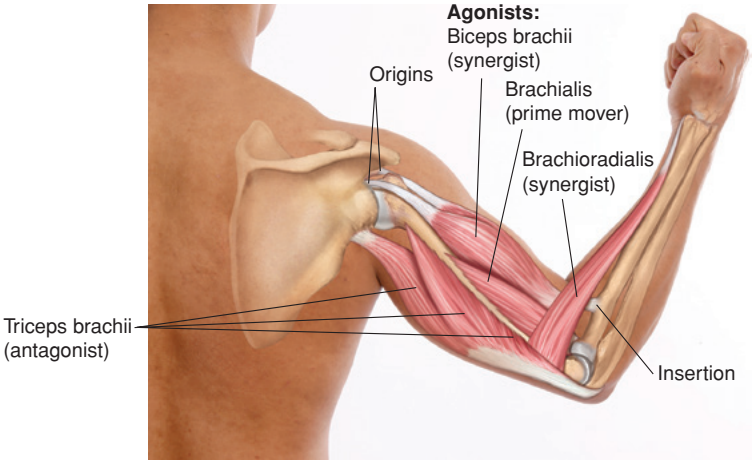

FIGURE 6-4 Muscles work together. When the brachialis, the agonistic prime mover, flexes the arm, the triceps brachii, the antagonist, must relax. Synergists, the biceps brachii and the brachioradialis, assist in this action. When the arm is extended, these muscle actions are reversed. This figure also shows three attachments of the biceps brachii, two origins and one insertion.

Focus on Words boxes

provide historical or other interesting information on select terms within a chapter.

FOCUS ON WORDS
Meaningful Suffixes

BOX 1-3

Suffixes sometimes take on a color of their own as they are added to different words. The suffix *-thon* is taken from the name of the Greek town Marathon, from which news of a battle victory was carried by a long-distance runner. It has been attached to various words to mean a contest of great endurance. We have bike-a-thons, dance-a-thons, telethons, and even major charity fundraisers called thon-a-thons.

The adjective ending *-ish* is used, as in *boyish* or *childish*, to suggest traces of certain characteristics. People tack it onto words to indicate that they are estimates, not right on target, as in *forty-ish* or *blue-ish*. A vague time for a lunch appointment could be *noon-ish*.

In science and medicine, the ending *-tech* is used to imply high technology, as in the company name Genentech, and *-pure* may be added to inspire confidence, as in the naming of the Multi-Pure water filter. The ending *-mate* suggests helping, as in *helpmate*, defined in the dictionary as a helpful companion, more specifically, a wife, or sometimes, a husband. The medical device HeartMate is a pump used to assist a damaged heart. In current terminology, the ending *-ome* refers to the objects in a comprehensive topic of study such as microbiome (total microbiologic population associated with an individual), genome (study of all the genes in an individual), and proteome (the entire protein makeup of an individual).

extern.ir

CLINICAL PERSPECTIVES

BOX 4-1

Medication Patches: No Bitter Pill to Swallow

For most people, pills are a convenient way to take medication, but for some, they have drawbacks. Pills must be taken at regular intervals to ensure consistent dosing, and they must be digested and absorbed into the bloodstream before they can begin to work. For those who have difficulty swallowing or digesting pills, transdermal (TD) patches offer an effective alternative to oral medications.

TD patches deliver a consistent dose of medication that diffuses at a constant rate through the skin into the bloodstream. There is no daily schedule to follow, nothing to swallow, and no stomach upset. TD patches can also deliver medication to unconscious patients, who would otherwise require intravenous drug delivery. TD patches are used in hormone replacement therapy, to treat heart disease, to manage pain, and to suppress motion sickness. Nicotine patches are also used as part of programs to quit smoking.

TD patches must be used carefully. Drug diffusion through the skin takes time, so it is important to know how long the patch must be in place before it is effective. It is also important to know when the medication's effects disappear after the patch is removed. Because the body continues to absorb what has already diffused into the skin, removing the patch does not entirely remove the medicine. There is also a danger that patches may become unsafe when heated, as by exercise, high fever, or a hot environment, such as a hot tub, heating pad, or sauna. When heat dilates the capillaries in the skin, a dangerous increase in dosage may result as more medication enters the blood.

A recent advance in TD drug delivery is iontophoresis. Based on the principle that like charges repel each other, this method uses a mild electrical current to move ionic drugs through the skin. A small electrical device attached to the patch uses positive current to "push" positively charged drug molecules through the skin and a negative current to push negatively charged ones. Even though very low levels of electricity are used, people with pacemakers should not use iontophoretic patches. Another disadvantage of these patches is that they can move only ionic drugs through the skin.

Clinical Perspectives boxes focus on body processing, as well as techniques used in clinical settings.

Health Professions boxes focus on a variety of health careers, showing how the knowledge of medical terminology is applied in future careers.

HEALTH PROFESSIONS

BOX 13-2

Dental Hygienist

Dental hygienists focus primarily on dental health maintenance and preventive dental care. They examine patients' dentition and periodontium (supporting structures of the teeth); take radiographic images; and perform oral prophylaxis using hand and ultrasonic instruments to remove deposits, such as calculus, stains, and plaque. They may also apply fluorides to prevent caries. They work independently or along with a dentist to administer local anesthesia and nitrous oxide sedation and to do oral screenings, polish restorations, remove sutures, apply dental sealants, and perform periodontal procedures. Dental hygienists must be knowledgeable about safety concerning x-ray equipment, anesthesia, and infectious diseases. They wear safety glasses, surgical masks, and gloves to protect themselves and their patients. A major component of the dental hygienist's work is patient education for maintenance of good oral health. They may give instruction on nutrition and proper oral care, such as brushing, flossing, and the use of antimicrobial rinses.

Most dental hygiene programs award an associate degree; some offer bachelor's or master's degrees. The higher degrees are required for research, teaching, or practice in public or school health facilities. The professional program requires 1 year of college-level prerequisite courses. The curriculum includes courses in radiography, dental anatomy, pharmacology, head and neck anatomy, and other health- and dental-related sciences. Additional material on the legal and ethical aspects of dental hygiene practice and extensive clinical training are included in the program. After graduation, dental hygienists must be licensed in their states by passing clinical and written examinations administered by the American Dental Association's (ADA) Joint Commission on National Dental Examinations.

Almost all hygienists work in dental offices. One advantage of this field is scheduling flexibility and the opportunity for part-time work. Job prospects are good; dental hygiene is among the fastest growing occupations. Benefits vary with place of employment. For additional information, contact the American Dental Hygienists' Association at adha.org.

FOR YOUR REFERENCE

BOX 1-2

Silent Letters and Unusual Pronunciations

Letter(s)	Pronunciation	Example	Definition of Example
ch	k	chemical *KEM-ih-kal*	pertaining to the elements and their interactions (root *chem/o* means "chemical")
dys	dis	dysfunction *dis-FUNK-shun*	difficult or abnormal (dys-) function
eu	u	euphoria *u-FOR-e-ah*	exaggerated feeling of well-being (*eu-* means "true" or "good")
gn	n	gnathic *NATH-ik*	pertaining to the jaw (gnath/o)
ph	f	phantom *FAN-tom*	illusion or imaginary image
pn	n	pneumonia *nu-MO-ne-ah*	inflammation of the lungs (pneumon/o)
ps	s	pseudonym *SU-do-nim*	false name (-nym)
pt	t	ptosis *TO-sis*	dropping, downward displacement
rh	r	rhinoplasty *RI-no-plas-te*	plastic repair of the nose (rhin/o)
x	z	xiphoid *ZI-foyd*	pertaining to cartilage attached to the sternum (from Greek *xiphos*, meaning "sword")

For Your Reference boxes provide supplemental information for terms within a chapter.

extern.ir

Table 2-1 Roots for Cells and Tissues

Root	Meaning	Example	Definition of Example
morph/o	form	polymorphous *pol-e-MOR-fus*	having many forms
cyt/o, -cyte	cell	cytologist *si-TOL-o-jist*	one who studies cells
nucle/o	nucleus	nuclear *NU-kle-ar*	pertaining to a nucleus
kary/o	nucleus	karyotype *KAR-e-o-tipe*	picture of a cell's chromosomes organized according to size (FIG. 2-10)
hist/o, histi/o	tissue	histocompatibility *his-to-kom-pat-ih-BIL-ib-te*	tissue similarity that permits transplantation
fibr/o	fiber	fibrosis *fi-BRO-sis*	abnormal formation of fibrous tissue
reticul/o	network	reticulum *reh-TIK-u-lum*	a network
aden/o	gland	adenoma *ad-eh-NO-mah*	tumor (-oma) of a gland
papill/o	nipple	papilla *pah-PIL-ah*	projection that resembles a nipple
myx/o	mucus	myxadenitis *miks-ad-eh-NI-tis*	inflammation (-itis) of a mucus-secreting gland
muc/o	mucus, mucous membrane	mucorrhea *mu-ko-RE-ah*	increased flow (-rhea) of mucus
somat/o, -some	body, small body	chromosome *KRO-mo-some*	small body that takes up color (dye) (chrom/o)

Word Part Tables present roots, prefixes, and suffixes covered in each chapter in an easy-to-reference format (with examples of their use in medical terminology). Word Part Knowledge aids in the learning and understanding of common terminology.

Exercise 13-3

Complete the exercise. To check your answers go to Appendix 11.

Use the suffix *-ic* to write a word for the following definitions.

1. pertaining to the liver _____
2. pertaining to the gallbladder _____
3. pertaining to the pancreas _____

Use the suffix *-graphy* to write a word for the following definitions.

4. radiographic study of the liver _____
5. radiographic study of the gallbladder _____
6. radiographic study of the bile ducts _____
7. radiographic study of the pancreas _____

Use the suffix *-lithiasis* to write a word for the following definitions.

8. condition of having a stone in the common bile duct _____
9. condition of having a stone in the pancreas _____

Fill in the blanks.

10. Inflammation of the liver is called _____ .
11. The word biligenesis (*bil-ih-JEN-eh-sis*) means the formation of _____ .
12. A cholelith (*KO-le-lith*) is a(n) _____ .
13. Choledochotomy (*ko-led-o-KOT-o-me*) is incision of the _____ .
14. Cholecystectomy (*ko-le-sis-TEK-to-me*) is removal of the _____ .
15. Hepatomegaly (*hep-ah-to-MEG-ah-le*) is enlargement of the _____ .
16. Cholangitis (*ko-lan-JI-tis*) is inflammation of a(n) _____ .
17. Pancreatolysis (*pan-kre-ah-TOL-ih-sis*) is dissolving of the _____ .

Exercises are designed to test your knowledge before you move to the next learning topic that follows each table.

Terminology *Key Terms*

The terms listed below are emphasized in this chapter. Knowing them will help you organize and prioritize your learning. These boldface terms are also found, collectively, with all chapter key terms in the Glossary.

Disease

acute *ah-KUTE*	Sudden, severe; having a short course
benign *be-NINE*	Not recurrent or malignant, favorable for recovery, describing a tumor that does not spread (metastasize) to other tissues
carcinoma *kar-sih-NO-mah*	A malignant neoplasm composed of epithelial cells (from Greek root carcino, meaning "crab") (adjective: carcinomatous)
chronic *KRON-ik*	Of long duration, progressing slowly
cyst *sist*	An abnormal filled sac or pouch; used as a root meaning a normal bladder or sac, such as the urinary bladder or gallbladder (root: cyst/o)
edema *eh-DE-mah*	Accumulation of fluid in the tissues, swelling; adjective: edematous (eh-DE-mah-tus) (see FIG. 3-2)
etiology *e-te-OL-o-je*	The cause of a disease
Gram stain	A laboratory staining procedure that divides bacteria into two groups: gram positive, which stains purple, and gram negative, which stains red
hernia *HER-ne-ah*	Protrusion of an organ through an abnormal opening; commonly called a rupture (FIG. 3-4)
immunity *ih-MU-nih-te*	All our defenses against infectious disease
inflammation *in-flah-MA-shun*	A localized response to tissue injury characterized by heat, pain, redness, and swelling
lesion *LE-zhun*	A distinct area of damaged tissue, an injury or wound

Terminology Tables-Key Terms outline the key terms emphasized in the chapter and can be used as a learning and study tool.

extern.ir

Terminology — *Enrichment Terms*

The terms listed below expand on the key terms to increase your knowledge of this chapter topic.

amino acids *ah-ME-no*	The nitrogen-containing compounds that make up proteins
anabolism *ah-NAB-o-lizm*	The type of metabolism in which body substances are made; the building phase of metabolism
catabolism *kah-TAB-o-lizm*	The type of metabolism in which substances are broken down for energy and simple compounds
collagen *KOL-ah-jen*	A fibrous protein found in connective tissue
cortex *KOR-tex*	The outer region of an organ
glycogen *GLI-ko-jen*	A complex sugar compound stored in liver and muscles and broken down into glucose when needed for energy
interstitial *in-ter-STISH-al*	Between parts, such as the spaces between cells in a tissue
medulla *meh-DUL-lah*	The inner region of an organ, marrow (root: medull/o)
parenchyma *par-EN-kih-mah*	The functional tissue of an organ
parietal *pah-RI-eh-tal*	Pertaining to a wall, describes a membrane that lines a body cavity
soma *SO-mah*	The body
stem cell	An immature cell that has the capacity to develop into any of a variety of different cell types, a precursor cell

Terminology Tables-Enrichment Terms provide you with more challenging terms to expand your knowledge.

Terminology — *Abbreviations*

The abbreviations listed below are emphasized in this chapter. These are also found, collectively, with all chapter abbreviations in Appendix 2.

ACE	Angiotensin-converting enzyme	**GFR**	Glomerular filtration rate
ADH	Antidiuretic hormone	**GU**	Genitourinary
ARF	Acute renal failure	**IVP**	Intravenous pyelography
ATN	Acute tubular necrosis	**IVU**	Intravenous urography
BUN	Blood urea nitrogen	**K**	Potassium
CAPD	Continuous ambulatory peritoneal dialysis	**KUB**	Kidney–ureter–bladder (radiography)
CCPD	Continuous cyclic peritoneal dialysis	**Na**	Sodium
CMG	Cystometrography; cystometrogram	**PEP**	Protein electrophoresis
CRF	Chronic renal failure	**SG**	Specific gravity
EPO	Erythropoietin	**Tm**	Maximal transport capacity
ESRD	End-stage renal disease	**UA**	Urinalysis
ESWL	Extracorporeal shock-wave lithotripsy	**UTI**	Urinary tract infection

Terminology Tables-Abbreviations are listed for common terms.

SKULL FROM THE LEFT

Write the name of each numbered part on the corresponding line.

Frontal
Hyoid
Lacrimal
Mandible
Maxilla
Nasal
Occipital
Parietal
Sphenoid
Temporal
Zygomatic

1. _____
2. _____
3. _____
4. _____
5. _____
6. _____
7. _____
8. _____
9. _____
10. _____
11. _____

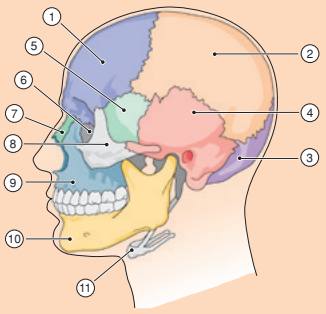

VERTEBRAL COLUMN

Write the name of each numbered part on the corresponding line.

Body of vertebra
Cervical vertebrae
Coccyx
Intervertebral disk
Lumbar vertebrae
Sacrum
Thoracic vertebrae

1. _____
2. _____
3. _____
4. _____
5. _____
6. _____
7. _____

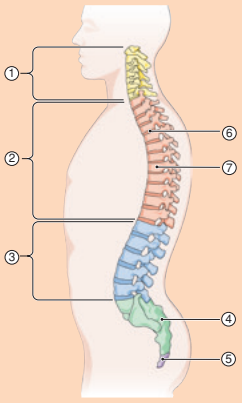

Chapter Review Exercises are designed to test your knowledge of the chapter material and appear at the end of each chapter.

extern.ir

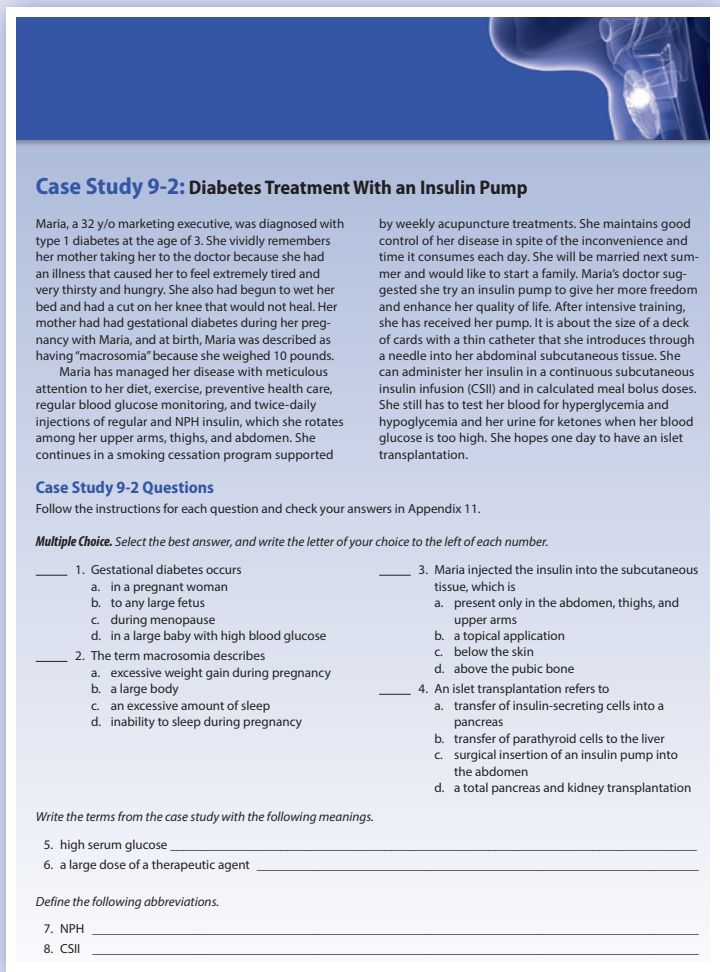

Case Study 9-2: Diabetes Treatment With an Insulin Pump

Maria, a 32 y/o marketing executive, was diagnosed with type 1 diabetes at the age of 3. She vividly remembers her mother taking her to the doctor because she had an illness that caused her to feel extremely tired and very thirsty and hungry. She also had begun to wet her bed and had a cut on her knee that would not heal. Her mother had had gestational diabetes during her pregnancy with Maria, and at birth, Maria was described as having "macrosomia" because she weighed 10 pounds.

Maria has managed her disease with meticulous attention to her diet, exercise, preventive health care, regular blood glucose monitoring, and twice-daily injections of regular and NPH insulin, which she rotates among her upper arms, thighs, and abdomen. She continues in a smoking cessation program supported by weekly acupuncture treatments. She maintains good control of her disease in spite of the inconvenience and time it consumes each day. She will be married next summer and would like to start a family. Maria's doctor suggested she try an insulin pump to give her more freedom and enhance her quality of life. After intensive training, she has received her pump. It is about the size of a deck of cards with a thin catheter that she introduces through a needle into her abdominal subcutaneous tissue. She can administer her insulin in a continuous subcutaneous insulin infusion (CSII) and in calculated meal bolus doses. She still has to test her blood for hyperglycemia and hypoglycemia and her urine for ketones when her blood glucose is too high. She hopes one day to have an islet transplantation.

Case Study 9-2 Questions

Follow the instructions for each question and check your answers in Appendix 11.

Multiple Choice. *Select the best answer, and write the letter of your choice to the left of each number.*

_____ 1. Gestational diabetes occurs
a. in a pregnant woman
b. to any large fetus
c. during menopause
d. in a large baby with high blood glucose

_____ 2. The term macrosomia describes
a. excessive weight gain during pregnancy
b. a large body
c. an excessive amount of sleep
d. inability to sleep during pregnancy

_____ 3. Maria injected the insulin into the subcutaneous tissue, which is
a. present only in the abdomen, thighs, and upper arms
b. a topical application
c. below the skin
d. above the pubic bone

_____ 4. An islet transplantation refers to
a. transfer of insulin-secreting cells into a pancreas
b. transfer of parathyroid cells to the liver
c. surgical insertion of an insulin pump into the abdomen
d. a total pancreas and kidney transplantation

Write the terms from the case study with the following meanings.

5. high serum glucose _____
6. a large dose of a therapeutic agent _____

Define the following abbreviations.

7. NPH _____
8. CSII _____

Case Studies and Case Study Questions at the end of every chapter present terminology in the context of a medical report. These are an excellent review tool because they test your cumulative knowledge of medical terminology and put terminology into a real-world context.

Instructor, Student and Learning Resources

For the Instructor

Qualified instructors will receive a full suite of instructor resources, including the following:

- Slides in PowerPoint format
- Testbank in LMS compatible format
- Lesson Plans

For the Student

- eBook
- Anatomy & Physiology Review Module with Heart & Lung Sounds
- Animations
- TestPrep

Learning Resources

- eBook
- A&P Module with Heart & Lung Sounds
- Image Bank
- TestPrep
- Animations
- Audio Pronunciation Glossary

extern.ir

PART I

Introduction to Medical Terminology

Chapter 1 Concepts, Suffixes, and Prefixes of Medical Terminology

Chapter 2 Body Structure

Chapter 3 Disease and Treatment

extern.ir

CHAPTER 1

Concepts, Suffixes, and Prefixes of Medical Terminology

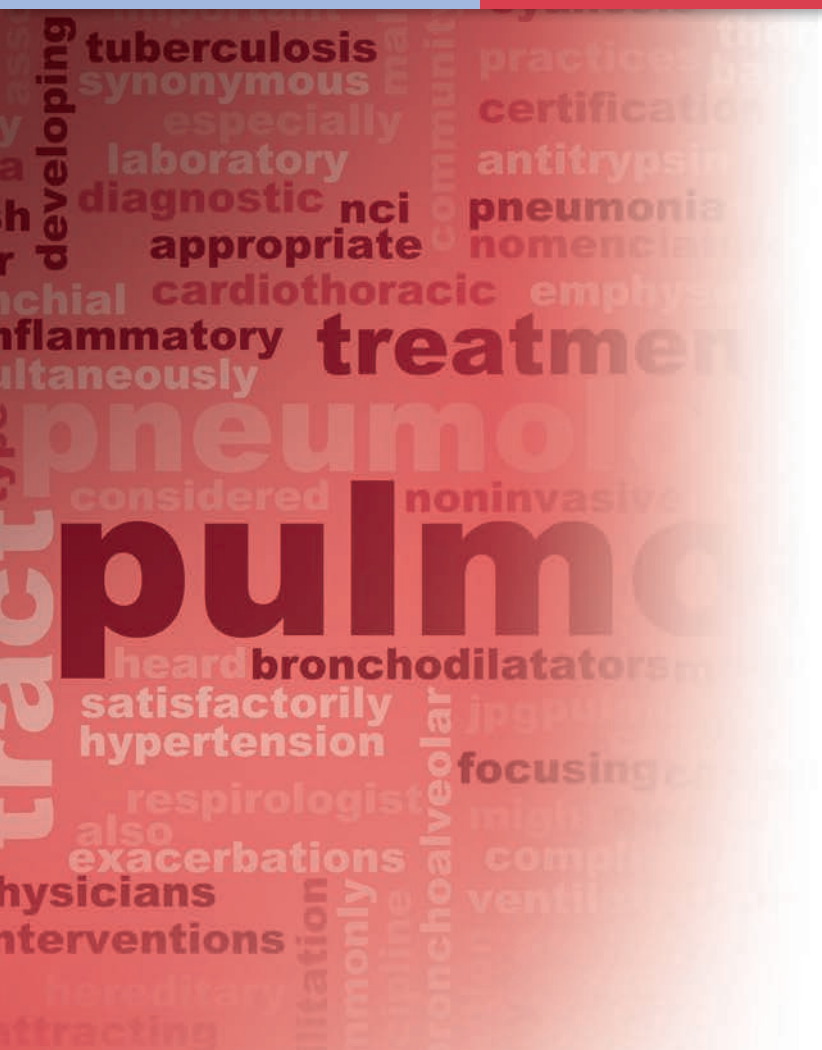

Pretest

Multiple Choice. **Select the best answer, and write the letter of your choice to the left of each number. To check your answers go to Appendix 11.**

_____ 1. The main part of a word is called the
a. origin
b. prefix
c. root
d. extension

_____ 2. A word part at the end of a word is the
a. prefix
b. adjective
c. insertion
d. suffix

_____ 3. The *ch* in the word *chemical* is pronounced like the letter
a. s
b. h
c. k
d. f

_____ 4. The word below that has a hard *g* is
a. grip
b. page
c. gem
d. judge

_____ 5. The suffixes *-ic, -ous, -al*, and *-oid* are found in
a. adjectives
b. nouns
c. verbs
d. roots

_____ 6. The singular of *ova* (eggs) is
a. ovi
b. ovae
c. ovum
d. ovas

_____ 7. The prefix in the word *microscopic* is
a. mic-
b. scop-
c. micro-
d. pic-

_____ 8. The opposite of hypoglycemia (low blood sugar) is
a. hypoglucemia
b. hyperglycemia
c. hypocalcemia
d. hypoglycemic

extern.ir

Learning Objectives

After careful study of this chapter, you should be able to:

1. Explain the purpose of medical terminology. ***P4***
2. Name the languages from which most medical word parts are derived. ***P4***
3. Define the terms *root, suffix*, and *prefix*. ***P4***
4. Explain what combining forms are and why they are used. ***P5***
5. List three features of medical dictionaries. ***P8***
6. Recognize and apply some general noun, adjective, and plural suffixes used in medical terminology. ***P9***
7. Recognize and define prefixes used in medical terminology. ***P18***
8. Analyze the suffixes and prefixes used in chapter case studies. ***PP3, 34***

Case Study: David's Digestive Problems

Chief Complaint

David, a 22 y/o college student, visited the university health clinic and stated he had a 4-month history of a burning pain in the middle of his chest (heartburn). He notices it more at night and has difficulty sleeping because of the pain. He said he is under stress due to the intensity of his college courses and has gained 20 pounds over the last 6 months. He also said that the pain seems to occur more frequently following late-night college gatherings where pizza, spicy chicken wings, and beer are served.

Examination

A well-nourished 22 y/o male complaining of (c/o) epigastric (upper abdominal) pain no longer relieved by antacids; orthopnea—currently sleeping with three pillows to aid in breathing; occasional swallowing problems, or dysphagia; ETOH (alcohol) consumption is six to eight beers per week; nonsmoker; no neurologic, musculoskeletal, genitourinary, or respiratory deficits. David was referred to a gastroenterologist for ↑ acid production and possible gastroesophageal reflux disease (GERD).

Clinical Course

The gastroenterologist saw David and ordered a special x-ray procedure, a barium swallow radiograph, to rule out any structural problems with the esophagus. The barium provides contrast to enable the radiologist to take x-rays of the esophagus. Since the results of this test proved to be inconclusive for GERD, David was scheduled for an esophageal gastroduodenoscopy (EGD). An EGD allows the gastroenterologist to visually examine the upper GI tract, showing the esophagus, stomach, and duodenum (the upper part of the small intestine). Results of the EGD showed no evidence of bleeding, ulcerations, or strictures. Since David still complained of mild heartburn he was sent home with a prescription of Prevacid and given educational material on GERD, including dietary, exercise, and stress reduction recommendations. He was told he needed to be reevaluated in 3 months.

Case Study Revisited: Once you complete this chapter, please review the case follow-up on p. 27.

Ancillaries *At-A-Glance*

Visit the web resource to access the following resources.

Learning Resources

- eBook
- A&P Module with Heart & Lung Sounds
- Image Bank
- TestPrep
- Animations
- Audio Pronunciation Glossary

extern.ir

Introduction

Medical terminology is a special vocabulary used by healthcare professionals for effective and accurate communication. Every health-related field requires an understanding of medical terminology, and this book highlights selected healthcare occupations in special boxes (**BOX 1-1**). While studying this chapter, you will learn about the general concepts of medical terminology and explore the specific role of suffixes and prefixes in words.

Concepts of Medical Terminology

Because it is based mainly on Greek and Latin words, medical terminology is consistent and uniform throughout the world. It is also efficient; although some of the terms are long, they often reduce an entire phrase to a single word. The one word *gastroduodenostomy*, for example, means "a communication between the stomach and the first part of the small intestine" **(FIG. 1-1)**. The part *gastr* means stomach; *duoden* represents the duodenum, the first part of the small intestine; and *ostomy* means a communication.

The medical vocabulary is vast, and learning it may seem like learning the entire vocabulary of a foreign language. Moreover, like the jargon that arises in all changing fields, it is always expanding. Think of the terms that have been added to our vocabulary in relation to computers, such as *software*, *search engine*, *flash drive*, *app*, and *blog*. The task may seem overwhelming, but there are methods to aid in learning and remembering words and even to help make informed guesses about unfamiliar words. Most medical terms can be divided into component parts—roots, prefixes, and suffixes—that maintain the same meaning whenever they appear. By learning these meanings, you can analyze and remember many words.

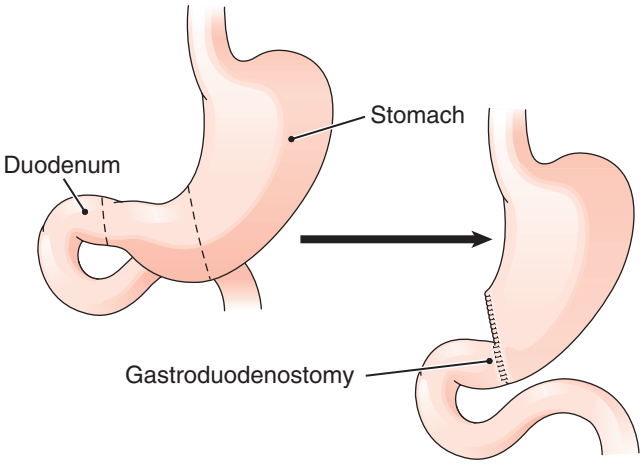

FIGURE 1-1 Gastroduodenostomy. A communication (-stomy) between the stomach (gastr) and the first part of the small intestine, or duodenum (duoden).

Word Parts

Word components fall into three categories:

1. The **root** is the fundamental unit of each medical word. It establishes the basic meaning of the word and is the part to which modifying word parts are added.
2. A **suffix** is a short word part or series of parts added at the end of a root to modify its meaning. This book indicates suffixes by a dash before the suffix, such as *-itis* (inflammation).

HEALTH PROFESSIONS
Health Information Technicians

BOX 1-1

Patient medical records are used as the basis for all medical care delivered. Every time a patient receives medical treatment, information is added to the patient's medical record, which includes the medical history, data about symptoms, test results, diagnoses, treatments, and follow-up care. Health information technicians (HITs) organize and manage these records and work closely with physicians, nurses, and other health professionals to ensure that they provide a complete and accurate basis for quality patient care.

Accurate medical records are essential for administrative purposes, third-party payers, and researchers. HITs assign a code to each diagnosis and procedure a patient receives, and this information is used for accurate patient billing. In addition, HITs analyze medical records to reveal trends in health and disease. This research can be used to improve patient care, manage costs, and help establish new medical treatments.

To read and interpret medical records, HITs need a thorough background in medical terminology. Students planning to pursue this career may obtain a certificate in health information technology or complete an associate's degree in health information technology at a community college. Those wanting to move into an administrative role may complete advanced studies and a bachelor's degree in health informatics at a university. A certification examination is required to become certified as a registered health information technician (RHIT). Many institutions prefer to hire individuals who are professionally certified.

Most HITs work in hospitals and long-term care facilities. Others may work in medical clinics, government agencies, insurance companies, and consulting firms. Because of the growing need for medical care, health information technology is projected to be one of the fastest growing careers in the United States.

For more information about this profession, contact the American Health Information Management Association at ahima.org.

extern.ir

3. A **prefix** is a short word part added before a root to modify its meaning. This book indicates prefixes by a dash after the prefix, such as *pre-* (before).

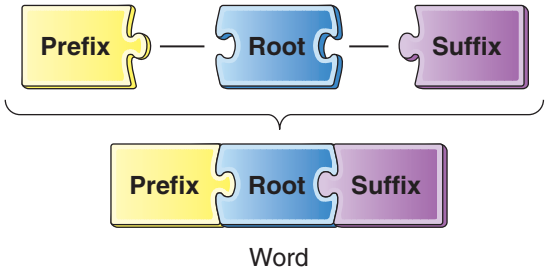

Words are formed from roots, suffixes, and prefixes.

The simple word *learn* can be used as a root to illustrate. If we add the suffix *-er* to form *learner*, we have "one who learns." If we add the prefix *re-* to form *relearn*, we have "to learn again."

Not all roots are complete words. In fact, most medical roots are derived from other languages and are meant to be used in combinations. The Greek word *kardia*, for example, meaning "heart," gives us the root *cardi*. The Latin word *pulmo*, meaning "lung," gives us the root *pulm*. In a few instances, both the Greek and Latin roots are used for the same structure. We find both the Greek root *nephr* and the Latin root *ren* used in words pertaining to the kidney **(FIG. 1-2)**.

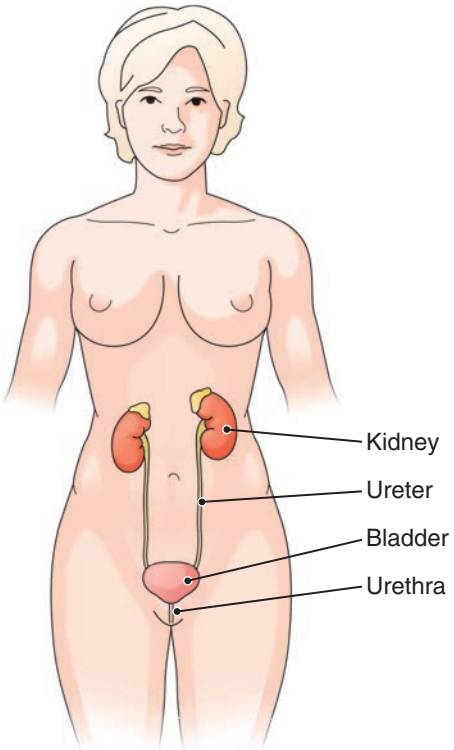

FIGURE 1-2 Structures named with more than one word root. Medical terminology uses both the Greek root *nephr* and the Latin root *ren* for the kidney, an organ of the urinary system.

Note that the same root may have different meanings in different fields of study, just as the words *web, spam, cloud, cookie,* and *tweet* have different meanings in common vocabulary than they do in "computerese." The root *myel* means "marrow" and may apply to either the bone marrow or the spinal cord. The root *scler* means "hard" but may also apply to the white of the eye. *Cyst* means "a filled sac or pouch" but also refers specifically to the urinary bladder. You will sometimes have to consider the context of a word before assigning its meaning.

A **compound word** contains more than one root. The words *eyeball*, *bedpan*, *frostbite*, and *wheelchair* are examples. Some examples of compound medical words are *cardiovascular* (pertaining to the heart and blood vessels), *urogenital* (pertaining to the urinary and reproductive systems), and *lymphocyte* (a white blood cell found in the lymphatic system).

COMBINING FORMS

When a suffix or another root beginning with a consonant is added to a root, a vowel is inserted between the root and the next word part to aid in pronunciation. This combining vowel is usually an *o*, as seen in the previous example of gastroduodenostomy, but may occasionally be *a*, *e*, or *i*.

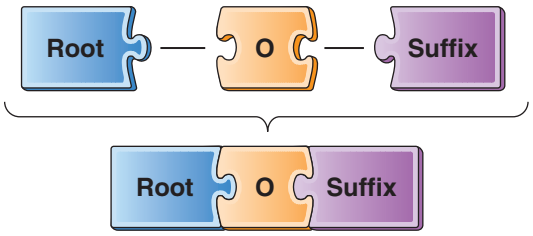

A combining vowel may be added between a root and a word part that follows.

Thus, when the suffix *-logy*, meaning "study of," is added to the root *neur*, meaning "nerve or nervous system," a combining vowel is added:

neur + o + logy = neurology (study of the nervous system)

Roots shown with a combining vowel are called **combining forms.**

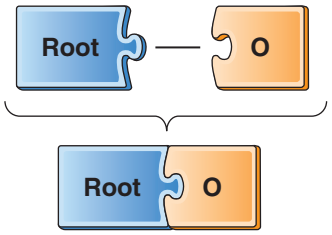

A root with a combining vowel is called a combining form.

This text gives roots with their most common combining vowels added after a slash and refers to them simply as roots, as in *neur/o*. A combining vowel is usually not used if

extern.ir

the ending begins with a vowel. For example, the root *neur* is combined with the suffix *-itis*, meaning "inflammation of," in this way:

neur + itis = neuritis (inflammation of a nerve)

This rule has some exceptions, particularly when they affect pronunciation or meaning, and you will observe these as you work.

Word Derivations

As mentioned, most medical word parts come from Greek (G.) and Latin (L.). The original words and their meanings are included in this text only occasionally. However, they are interesting and may aid in learning. For example, *muscle* comes from a Latin word that means "mouse" because the movement of a muscle under the skin was thought to resemble the scampering of a mouse. The coccyx, the tail end of the spine, is named for the cuckoo because it was thought to resemble the cuckoo's bill **(FIG. 1-3)**. For those interested in the derivations of medical words, a good medical dictionary will provide this information.

WORDS ENDING IN *x*

When you add a suffix to a word ending in *x*, the *x* is changed to a *g* or a *c*. If there is a consonant before the *x*, such as *yx* or *nx*, the *x* is changed to a *g*. For example, *pharynx* (throat) becomes *pharyngeal* (*fah-RIN-je-al*), to mean "pertaining to the throat"; *coccyx* (terminal portion of the spine) becomes *coccygeal* (*kok-SIJ-e-al*), to mean "pertaining to the coccyx."

If a vowel comes before the *x*, such as *ax* or *ix*, you change the *x* to a *c*. Thus, *thorax* (chest) becomes *thoracic* (*tho-RAS-ik*), to mean "pertaining to the chest"; and *cervix* (neck) becomes *cervical* (*SER-vih-kal*), to mean "pertaining to a neck."

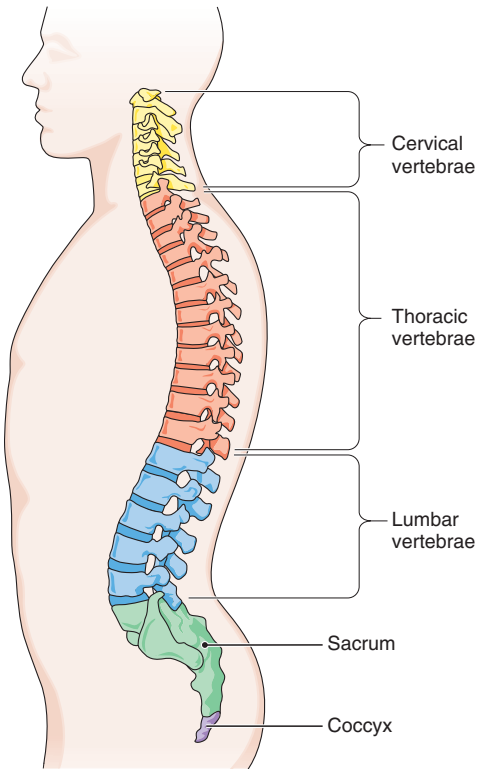

FIGURE 1-3 Word derivations. The coccyx of the spine is named by its resemblance to a cuckoo's bill.

SUFFIXES BEGINNING WITH *rh*

When you add a suffix beginning with *rh* to a root, the *r* is doubled. For example:

hem/o (blood) + **r**hage (bursting forth) = hemo**rr**hage (a bursting forth of blood)

men/o (menses) + **r**hea (flow, discharge) = meno**rr**hea (menstrual flow)

Pronunciation

This text provides phonetic pronunciations at every opportunity, even in the answer keys. The web resource has a large audio pronunciation dictionary. Take advantage of these aids. Repeat each word aloud as you learn to recognize it in print or hear it on the web resource.

The following definitions apply to pronunciation:

Vowel: There are five English vowels; a, e, i, o, u. Each has a specific sound when pronounced.

Syllable: A unit of pronunciation having one vowel sound, forming the whole or part of a word. The number of times you hear a vowel (a, e, i, o, u) in a word is equal to the number of syllables contained in the word.

No special marks are needed to follow the pronunciation if you keep a few simple rules in mind.

Rule 1

Any vowel that appears alone or at the end of a syllable gets a long pronunciation. The alphabet sounds (when the vowel "says its name") are called long vowels. They are called "long" because we hold them longer than the short sounds.

Vowel	Long Pronunciation
a	as in s*a*y, *a*te, t*a*pe
e	as in t*e*a, *e*at, s*e*at
i	as in l*i*e, m*i*te, m*i*ght
o	as in h*o*se, *o*at, m*o*at
u	as in s*u*e, m*u*te, c*u*be

Rule 2

Any vowel that appears within a syllable gets a short pronunciation:

Vowel	Short Pronunciation
a	as in h*a*t, p*a*n, m*a*t
e	as in m*e*t, p*e*n, b*e*d
i	as in b*i*n, p*i*n, m*i*tt
o	as in n*o*t, c*o*t, r*o*t
u	as in r*u*n, m*u*tt, h*u*g

extern.ir

Rule 3
If a vowel is at the end of a syllable but needs a short pronunciation, an *h* is added, as in *vah-nil-ah* for vanilla.

Rule 4
If a vowel within a syllable needs a long pronunciation, an *e* is added, as in *re-pete* for repeat.

Rule 5
The accented syllable in each word is shown with capital letters, as in *AK-sent*.

Be aware that word parts may change in pronunciation when they are combined in different ways. Note also that accepted pronunciations may vary from place to place. Only one pronunciation for each word is given here, but be prepared for differences.

SOFT AND HARD *c* AND *g*

- A soft *c*, as in *racer*, will be written in pronunciations as *s* (*RA-ser*).
- A hard *c*, as in *candy*, will be written as *k* (*KAN-de*).
- A soft *g*, as in *page*, will be written as *j* (*paje*).
- A hard *g*, as in *grow*, will be written as *g* (*gro*).

SILENT LETTERS AND UNUSUAL PRONUNCIATIONS

A silent letter or an unusual pronunciation can be a problem, especially if it appears at the start of a word that you are trying to look up in the dictionary. See **BOX 1-2** for some examples.

The combinations in **BOX 1-2** may be pronounced differently when they appear within a word, as in dia**gn**osis (*di-ag-NO-sis*), meaning determination of the cause of disease, in which the *g* is pronounced; a**pn**ea (*AP-ne-ah*), meaning cessation of breathing, in which the *p* is pronounced; nephro**pt**osis (*nef-rop-TO-sis*), meaning dropping of the kidney, in which the *p* is pronounced.

FOR YOUR REFERENCE
Silent Letters and Unusual Pronunciations — BOX 1-2

Letter(s)	Pronunciation	Example	Definition of Example
ch	k	chemical *KEM-ih-kal*	pertaining to the elements and their interactions (root *chem/o* means "chemical")
dys	dis	dysfunction *dis-FUNK-shun*	difficult or abnormal (dys-) function
eu	u	euphoria *u-FOR-e-ah*	exaggerated feeling of well-being (*eu-* means "true" or "good")
gn	n	gnathic *NATH-ik*	pertaining to the jaw (gnath/o)
ph	f	phantom *FAN-tom*	illusion or imaginary image
pn	n	pneumonia *nu-MO-ne-ah*	inflammation of the lungs (pneumon/o)
ps	s	pseudonym *SU-do-nim*	false name (-nym)
pt	t	ptosis *TO-sis*	dropping, downward displacement
rh	r	rhinoplasty *RI-no-plas-te*	plastic repair of the nose (rhin/o)
x	z	xiphoid *ZI-foyd*	pertaining to cartilage attached to the sternum (from Greek *xiphos*, meaning "sword")

extern.ir

Abbreviations

Shortened words or initials can save time in writing medical reports and case histories. We commonly use TV for television, Jr. for junior, F for Fahrenheit temperature readings, UV for ultraviolet, and Dr. for doctor. A few of the many medical abbreviations are mL for the metric measurement milliliter; dB for decibels, units of sound intensity; CA for cancer; hgb for hemoglobin; and ECG for electrocardiogram.

PHRASE ABBREVIATIONS

An **acronym** is an abbreviation formed from the first letter of each word in a phrase. Some everyday acronyms are ASAP (as soon as possible), ATM (automated teller machine), and a computer's RAM (random access memory). Acronyms have become popular for saving time and space in naming objects, organizations, and procedures. They abound in the names of government agencies: FDA (Food and Drug Administration), USDA (United States Department of Agriculture), and NIH (National Institutes of Health). Some medical acronyms are BP for blood pressure, MRI for magnetic resonance imaging, AIDS for acquired immunodeficiency syndrome, CNS for the central nervous system, and RN for registered nurse. Acronyms and abbreviations that appear in a chapter are listed and defined at the end of that chapter. Appendix 2 is a more complete list of commonly used abbreviations and acronyms with their meanings. An abbreviation dictionary is also helpful.

SYMBOLS

Symbols are commonly used as shorthand in case histories. Some examples are Ⓛ and Ⓡ for left and right and ↑ and ↓ for increase and decrease. A list of common symbols appears in Chapter 3 and in Appendix 1.

Symbols and abbreviations can save time, but they can also cause confusion if they are not universally understood. Usage varies in different institutions, and the same abbreviation may have different meanings in different fields. For example, the acronym CRF can mean chronic renal failure or case report form, and MS can represent mitral stenosis or multiple sclerosis. Again, as with roots having multiple meanings, if the acronym is not defined, its interpretation depends on its context.

Some abbreviations and symbols are subject to error and should never be used. These appear in "Do Not Use" lists published by organizations that promote patient safety, such as the Joint Commission on Accreditation of Healthcare Organizations (JCAHO) and the Institute for Safe Medical Practices (ISMP). Most institutions have a policy manual that details the accepted abbreviations for that facility. Only the most commonly used symbols and abbreviations are given here.

Medical Dictionaries

With few exceptions, you can do all the exercises in this book without the aid of a dictionary, but medical dictionaries are valuable references for everyone in health-related

Terminology *Key Terms*

The terms listed below are emphasized in this chapter. Knowing them will help you organize and prioritize your learning. These boldface terms are also found, collectively, with all chapter key terms in the Glossary.

acronym *AK-ro-nim*	An abbreviation formed from the first letter of each word in a phrase
combining forms *kom-BI-ning*	A word root combined with a vowel that links the root with another word part, such as a suffix or another root; combining forms are shown with a slash between the root and the vowel, as in *neur/o*
compound word *KOM-pownd*	A word that contains more than one root
prefix *PRE-fix*	A word part added before a root to modify its meaning
root *rute*	The fundamental unit of a word
suffix *SUH-fix*	A word part added to the end of a root to modify its meaning

extern.ir

fields. These include not only complete, unabridged versions, but also easy-to-carry short versions and dictionaries of medical acronyms and abbreviations. Many of these dictionaries are also available on the internet, and as applications for smartphones and tablets. Dictionaries give information on meanings, synonyms, derivations, and related terms. Those dictionaries intended for nursing and allied health professions include more complete clinical information, with notes on patient care.

Dictionaries vary in organization; in some, almost all terms are entered as nouns, such as disease, syndrome, procedure, or test. Those with a more clinical approach enter some terms according to their first word, which may be an adjective or proper name, for example, biomedical engineering, Cushing disease, and wind chill factor. This format makes it easier to look up some terms. All dictionaries have directions on how to use the book and interpret the entries, as shown in Appendix 9, taken from *Stedman's Medical Dictionary*, 28th ed.

In addition to information on individual terms and phrases, medical dictionaries have useful appendices on measurements, clinical tests, drugs, diagnosis, body structure, information resources, and other topics.

Suffixes

A suffix is a word ending that modifies a root. A suffix may indicate that the word is a noun or an adjective and often determines how the definition of the word will begin (**BOX 1-3**). For example, using the root *myel/o*, meaning "bone marrow," the adjective ending *-oid* forms the word *myeloid*, which means "like or pertaining to bone marrow." The ending *-oma* forms *myeloma*, which is a tumor of the bone marrow. Adding another root, *gen*, which represents genesis or origin, and the adjective ending *-ous* forms the word *myelogenous*, meaning "originating in bone marrow."

The suffixes given in this chapter are general ones that are used throughout medical terminology. They include endings that form:

- Nouns: a person, place, or thing
- Adjectives: words that modify nouns
- Plurals: endings that convert single nouns to multiples

Additional suffixes will be presented in later chapters as they pertain to disease states, medical treatments, or specific body systems.

NOUN SUFFIXES

The following general suffixes convert roots into nouns. **TABLE 1-1** lists suffixes that represent different conditions. Note that the ending *-sis* may appear with different combining vowels as *-osis*, *-iasis*, *-esis*, or *-asis*. The first two of these denote an abnormal condition.

TABLE 1-2 lists endings that convert roots into medical specialties or specialists. The suffix *-logy* applies to many fields other than medicine. It contains the root *log/o* taken from the Greek word *logos*, which means "word," and generally means a field of study. Some examples are biology, archeology, terminology, and technology. Terms with this ending are also used to identify an institutional department or a specialty, as in cardiology, dermatology, radiology, and others. The two endings *-iatrics* and *-iatry* contain the root *-iatr/o*, based on a Greek word for healing and meaning "physician" or "medical treatment."

FOCUS ON WORDS BOX 1-3

Meaningful Suffixes

Suffixes sometimes take on a color of their own as they are added to different words. The suffix *-thon* is taken from the name of the Greek town Marathon, from which news of a battle victory was carried by a long-distance runner. It has been attached to various words to mean a contest of great endurance. We have bike-a-thons, dance-a-thons, telethons, and even major charity fundraisers called thon-a-thons.

The adjective ending *-ish* is used, as in *boyish* or *childish*, to suggest traces of certain characteristics. People tack it onto words to indicate that they are estimates, not right on target, as in *forty-ish* or *blue-ish*. A vague time for a lunch appointment could be *noon-ish*.

In science and medicine, the ending *-tech* is used to imply high technology, as in the company name Genentech, and *-pure* may be added to inspire confidence, as in the naming of the Multi-Pure water filter. The ending *-mate* suggests helping, as in *helpmate*, defined in the dictionary as a helpful companion, more specifically, a wife, or sometimes, a husband. The medical device HeartMate is a pump used to assist a damaged heart. In current terminology, the ending *-ome* refers to the objects in a comprehensive topic of study such as microbiome (total microbiologic population associated with an individual), genome (study of all the genes in an individual), and proteome (the entire protein makeup of an individual).

extern.ir

Table 1-1 Suffixes That Mean "Condition of"

Suffix	Example	Definition of Example
-ia	dementia *de-MEN-she-ah*	loss of (de-) intellectual function (from L. *mentis*: mind)
-ism	racism *RA-sizm*	discrimination based on race
-sis	thrombosis *throm-BO-sis*	having a blood clot (thrombus) in a vessel **(FIG. 1-4)**
-y	atony *AT-o-ne*	lack (a-) of muscle tone

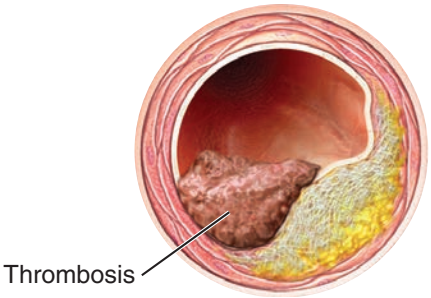

FIGURE 1-4 Thrombosis. This term refers to having a blood clot (thrombus) in a vessel. The word *thrombosis* has the noun suffix *-sis*, meaning "condition of."

Exercise 1-1

Complete the exercise. To check your answers go to Appendix 11.

Write the suffix that means "condition of" in the following words. Remember to use the phonetics to pronounce each word as you work through the exercises.

1. phobia (unfounded fear; from G. *phobos*: fear) *FO-be-ah* ia
2. psoriasis (skin disease) *so-RI-ah-sis* _____
3. egotism (exaggerated self-importance; from *ego*: self) *E-go-tizm* _____
4. dystrophy (changes due to lack of nourishment; root: troph/o) *DIS-tro-fe* _____
5. anesthesia (loss of sensation; root: esthesi/o) **(FIG. 1-5)** *an-es-THE-ze-ah* _____
6. parasitism (infection with parasites or behaving as a parasite) *PAR-ah-sit-izm* _____
7. stenosis (narrowing of a canal) *steh-NO-sis* _____
8. tetany (sustained muscle contraction) *TET-ah-ne* _____
9. diuresis (increased urination; root: ur/o) *di-u-RE-sis* _____

extern.ir

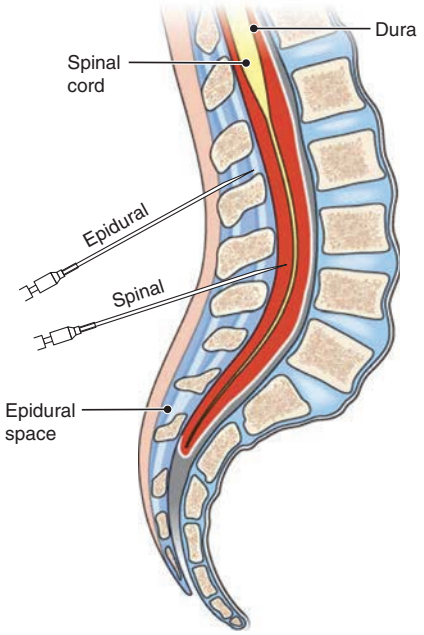

FIGURE 1-5 Injection sites for anesthesia. The word *anesthesia* uses the noun suffix *-ia*, meaning "condition of." The dura is a layer of the meninges, the membranes that cover the brain and spinal cord. One who administers anesthesia is an anesthetist or anesthesiologist.

FIGURE 1-6 Pediatrics is the care and treatment of children. The ending *-ics* indicates a medical specialty. In this photo, a pediatrician, one who practices pediatrics, is testing an infant's reflexes. The root *ped/o* means "child."

Table 1-2 Suffixes for Medical Specialties

Suffix	Meaning	Example	Definition of Example
-ian	specialist in a field of study	physician *fih-ZISH-un*	practitioner of medicine (from root *physi/o*, meaning "nature")
-iatrics	medical specialty	pediatrics *pe-de-AT-riks*	care and treatment of children (ped/o) **(FIG. 1-6)**
-iatry	medical specialty	psychiatry *si-KI-ah-tre*	study and treatment of mental (psych/o) disorders
-ics	medical specialty	orthopedics *or-tho-PE-diks*	study and treatment of the skeleton and joints (from root *ped/o*, meaning "child," and prefix *ortho*, meaning "straight")
-ist	specialist in a field of study	podiatrist *po-DI-ah-trist*	one who studies and treats the foot (pod/o)
-logy	study of	physiology *fiz-e-OL-o-je*	study of function in a living organism (from root *physi/o*, meaning "nature")

Exercise 1-2

Complete the exercise. To check your answers go to Appendix 11.

Write the suffix in the following words that means "study of," "medical specialty," or "specialist in a field of study."

1. cardiologist (specialist in the study and treatment of the heart; root: cardi/o) ist
   kar-de-OL-o-jist
2. neurology (the study of the nervous system; root: neur/o) _____
   nu-ROL-o-je

(continued)

extern.ir

Exercise 1-2 *(Continued)*

3. geriatrics (study and treatment of the aged; root: ger/e) **(FIG. 1-7)** _____
   jer-e-AT-riks
4. dermatology (study and treatment of the skin, or derma) _____
   der-mah-TOL-o-je
5. optician (one who makes and fits corrective lenses for the eyes; root: opt/o) _____
   op-TISH-an
6. anesthetist (one who administers anesthesia) (see **FIG. 1-5**) _____
   ah-NES-theh-tist

Write a word for a specialist in the following fields.

7. anatomy (study of body structure) anatomist
   ah-NAT-o-me
8. pediatrics (care and treatment of children; root: ped/o) (see **FIG. 1-6**) _____
   pe-de-AT-riks
9. radiology (use of radiation in diagnosis and treatment) _____
   ra-de-OL-o-je
10. psychology (study of the mind; root: psych/o) _____
    si-KOL-o-je
11. technology (practical application of science) _____
    tek-NOL-o-je
12. obstetrics (medical specialty concerning pregnancy and birth) _____
    ob-STET-riks



FIGURE 1-7 Geriatrics is the care and treatment of the aged.
A specialist in this field, a geriatrician, is shown.

ADJECTIVE SUFFIXES

The suffixes below are all adjective endings that mean "pertaining to," "like," or "resembling" **(TABLE 1-3)**. There are no rules for which ending to use for a given noun. Familiarity comes with practice. When necessary, tips on proper usage are given in the text.

Note that for words ending with the suffix *-sis*, the first *s* is changed to a *t* before adding *-ic* to form the adjective, as in genetic, pertaining to genesis (origin); psychotic, pertaining to psychosis (a mental disorder); or diuretic, pertaining to diuresis (increased urination).

extern.ir

Table 1-3 Suffixes That Mean "Pertaining to," "Like," or "Resembling"

Suffix	Example	Definition of Example
-ac	cardiac *KAR-de-ak*	pertaining to the heart
-al	vocal *VO-kal*	pertaining to the voice
-ar	nuclear *NU-kle-ar*	pertaining to a nucleus
-ary	salivary *SAL-ih-var-e*	pertaining to saliva
-form	muciform *MU-sih-form*	like or resembling mucus
-ic	anatomic *an-ah-TOM-ik*	pertaining to anatomy **(FIG. 1-8)**
-ical (ic + al)	electrical *e-LEK-trih-kal*	pertaining to electricity
-ile	virile *VIR-il*	pertaining to the male, masculine
-oid	lymphoid *LIM-foyd*	pertaining to the lymphatic system
-ory	circulatory *SIR-ku-lah-tor-e*	pertaining to circulation
-ous	cutaneous *ku-TA-ne-us*	pertaining to the skin (from L. *cutis*: skin)

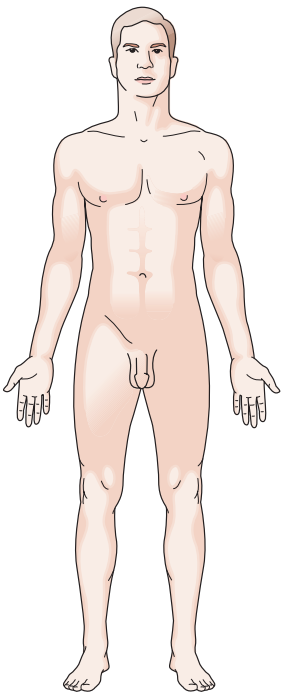

FIGURE 1-8 The anatomic position. This posture is standard in the study of anatomy. A person in this position is facing forward with arms at the side and palms forward (anterior). The adjective suffix *-ic* means "pertaining to."

extern.ir

Exercise 1-3

Complete the exercise. To check your answers go to Appendix 11.

Identify the suffix meaning "pertaining to," "like," or "resembling" in the following words. Remember to use the phonetics to pronounce each word as you work through the exercises.

1. dietary (pertaining to the diet) ary
   DI-eh-tar-e
2. neuronal (pertaining to a nerve cell, or neuron) **(FIG. 1-9)** _____
   NU-ro-nal
3. metric (pertaining to a meter or measurement; root metr/o means "measure") _____
   MEH-trik
4. venous (pertaining to a vein; root: ven/o) _____
   VE-nus
5. epileptiform (like or resembling epilepsy) _____
   ep-ih-LEP-tih-form
6. toxoid (like or resembling a toxin, or poison) _____
   TOK-soyd
7. topical (pertaining to a surface) _____
   TOP-ih-kal
8. febrile (pertaining to fever) _____
   FEB-rile
9. neurotic (pertaining to neurosis, a mental disorder) _____
   nu-ROT-ik
10. surgical (pertaining to surgery) _____
    SUR-jih-kal
11. muscular (pertaining to a muscle) _____
    MUS-ku-lar
12. urinary (pertaining to urine; root: ur/o) _____
    U-rih-nar-e
13. respiratory (pertaining to respiration) _____
    RES-pih-rah-tor-e
14. pelvic (pertaining to the pelvis) **(FIG. 1-10)** _____
    PEL-vik
15. saccular (pouch-like, resembling a small sac) _____
    SAK-u-lar

extern.ir

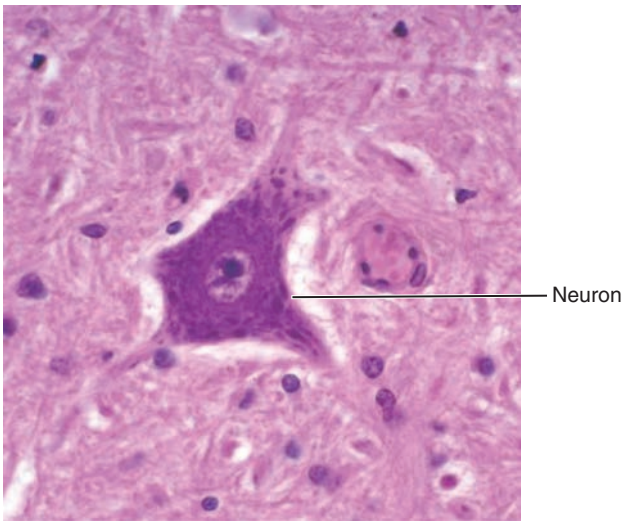

FIGURE 1-9 A neuron is a nerve cell. The adjective form of *neuron* is *neuronal*.

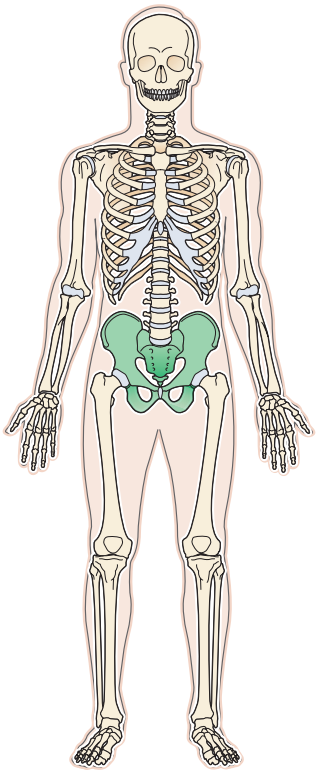

FIGURE 1-10 The pelvis is the bony hip girdle. The adjective form of pelvis is *pelvic*.

Forming Plurals

Many medical words have special plural forms based on the ending of the word. **TABLE 1-4** gives some general rules for the formation of plurals along with examples. The plural endings listed in the second column are substituted for the word endings in the first column. Note that both singular endings *-on* and *-um* change to *-a* for the plural. You have to learn which singular ending to use for specific words when converting a plural word ending in *-a* to the singular.

Table 1-4 Plural Endings

Word Ending	Plural Ending	Singular Example	Plural Example
a	ae	vertebra (bone of the spine) *VER-teh-brah*	vertebrae **(FIG. 1-11)** *VER-teh-bre*
en	ina	lumen (central opening) *LU-men*	lumina **(FIG. 1-12)** *LU-min-ah*
ex, ix, yx	ices	matrix (background substance; mold) *MA-triks*	matrices *MA-trih-seze*
is	es	diagnosis (determination of a disease or defect) *di-ag-NO-sis*	diagnoses *di-ag-NO-seze*
ma	mata	stigma (mark or scar) *STIG-mah*	stigmata *stig-MAT-ah*
nx (anx, inx, ynx)	nges	phalanx (bone of finger or toe) *fah-LANKS*	phalanges **(FIG. 1-13)** *fah-LAN-jeze*
on	a	ganglion (mass of nervous tissue) *GANG-le-on*	ganglia *GANG-le-ah*
um	a	serum (thin fluid) *SE-rum*	sera *SE-rah*
us	i	thrombus (see **FIG. 1-4**) *THROM-bus*	thrombi *THROM-bi*

extern.ir

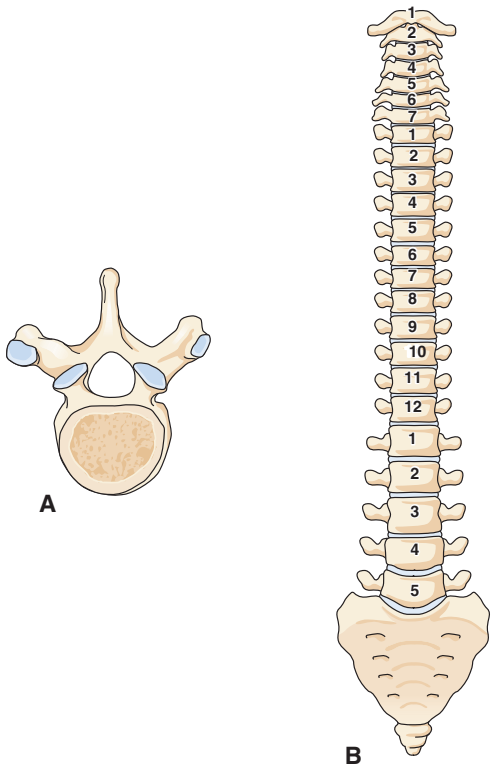

FIGURE 1-11 Bones of the spine. A. Each bone of the spine is a vertebra. **B.** The spinal column is made of 26 vertebrae.

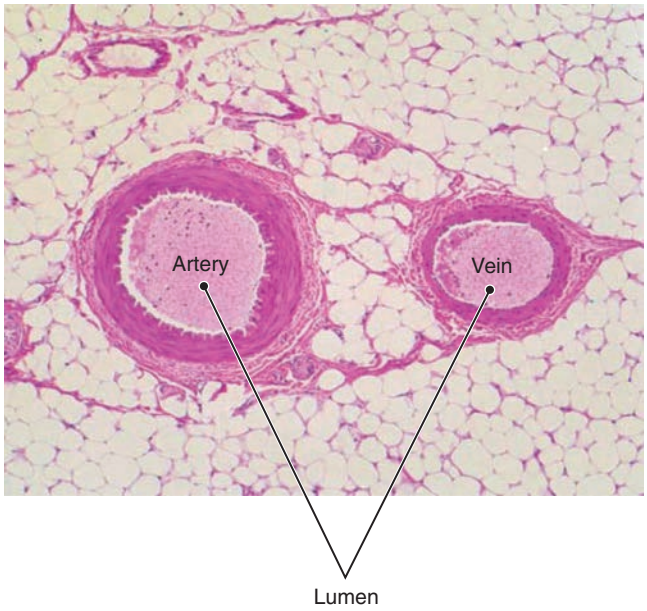

FIGURE 1-12 A lumen is the central opening of an organ or vessel. Two blood vessels are shown, an artery and a vein. The plural of lumen is *lumina*.

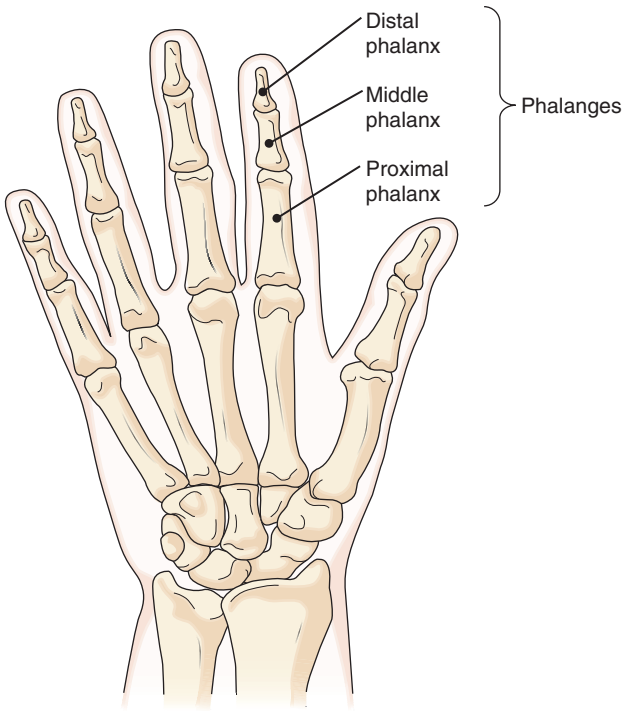

FIGURE 1-13 Bones of the right hand (anterior view). Each bone of a finger or toe is a phalanx. Each hand has 15 phalanges.

extern.ir

Exercise 1-4

Complete the exercise. To check your answers go to Appendix 11.

Write the plural form of the following words. The word ending is underlined in each. Remember to use the phonetics to pronounce each word as you work through the exercises.

1. patella (kneecap) *pah-TEL-ah* — patellae
2. phenomenon (occurrence or perception) *feh-NOM-eh-non* — _____
3. omentum (abdominal membrane) *o-MEN-tum* — _____
4. prognosis (prediction of disease outcome) *prog-NO-sis* — _____
5. apex (tip or peak) *A-peks* — _____
6. ovum (female reproductive cell; egg) *O-vum* — _____
7. spermatozoon (male reproductive cell; sperm cell) *sper-mah-to-ZO-on* — _____
8. meninx (membrane around the brain and spinal cord) *MEH-ninks* — _____
9. embolus (blockage in a vessel) *EM-bo-lus* — _____

Write the singular form of the following words. The word ending is underlined in each.

10. protozoa (single-celled animals) *pro-to-ZO-ah* — protozoon
11. appendices (things added) *ah-PEN-dih-seze* — _____
12. adenomata (tumors of glands) *ad-eh-NO-mah-tah* — _____
13. fungi (simple, nongreen plants) *FUN-ji* — _____
14. pelves (cup-shaped cavities) *PEL-veze* — _____
15. foramina (openings, passageways) *fo-RAM-ih-na* — _____
16. curricula (series of courses) *kur-RIK-u-lah* — _____
17. indices (directories, lists) *IN-dih-seze* — _____
18. alveoli (small sacs) *al-VE-o-li* — _____

extern.ir

SOME EXCEPTIONS TO THE RULES

There are exceptions to the rules given for forming plurals, some of which will appear in later chapters. For example, the plural of *sinus* (space) is *sinuses*, the plural of *virus* is *viruses*, and *serums* (thin fluids) is sometimes used instead of *sera*. An *-es* ending may be added to words ending in *-ex* or *-ix* to form a plural, as in *appendixes*, *apexes*, and *indexes*.

Some incorrect plural forms are in common usage, for example, *stigmas* instead of *stigmata*, *referendums* instead of *referenda*, *stadiums* instead of *stadia*. Often people use *phalange* instead of *phalanx* as the singular of *phalanges*. Words ending in *-oma*, meaning "tumor," should be changed to *-omata*, but most people just add an *s* to form the plural. For example, the plural of *carcinoma* (a type of cancer) should be *carcinomata*, but *carcinomas* is commonly used.

Prefixes

A prefix is a short word part added before a word or word root to modify its meaning. For example, the word *lateral* means "side." Adding the prefix *uni-*, meaning "one," forms *unilateral*, which means "affecting or involving one side." Adding the prefix *contra-*, meaning "against or opposite," forms *contralateral*, which refers to an opposite side. The term *equilateral* means "having equal sides." Prefixes in this book are followed by dashes to show that word parts are added to the prefix to form a word.

Most of the prefixes used in medical terminology are shown in **TABLES 1-5** to **1-12**. Although the list is long, almost all of the prefixes you will need to work through this book are presented here. Some additional prefixes, including those related to disease, are given in several later chapters. The meanings of many of the prefixes in this chapter are familiar to you from words that are already in your vocabulary. You may not know all the words in the exercises, but make your best guess. The words in the tables are given as examples of usage. Almost all of them reappear in other chapters. If you forget a prefix as you work, you may refer to this chapter or to the alphabetical lists of word parts and their meanings in Appendices 3 and 4. Appendix 7 lists prefixes only.

Table 1-5 Prefixes for Numbers[a]

Prefix	Meaning	Example	Definition of Example
prim/i-	first	primary *PRI-mar-e*	first
mon/o-	one	monocular *mon-OK-u-lar*	having one eyepiece or affecting one eye
uni-	one	unite *u-NITE*	form into one part
hemi-	half, one side	hemisphere *HEM-ih-sfere*	one-half of a rounded structure **(FIG. 1-14)**
semi-	half, partial	semipermeable *sem-e-PER-me-ah-bl*	partially permeable (capable of being penetrated)
bi-	two, twice	binary *BI-nar-e*	made up of two parts
di-	two, twice	diatomic *di-ah-TOM-ik*	having two atoms
dipl/o-	double	diplococci *dip-lo-KOK-si*	round bacteria (cocci) that grow in groups of two
tri-	three	tricuspid *tri-KUS-pid*	having three points or cusps **(FIG. 1-15)**
quadr/i-	four	quadruplet *kwah-DRUPE-let*	one of four babies born together
tetra-	four	tetralogy *tet-RAL-o-je*	a group of four
multi-	many	multicellular *mul-ti-SEL-u-lar*	consisting of many cells **(FIG. 1-16)**
poly-	many, much	polymorphous *pol-e-MOR-fus*	having many forms (morph/o)

[a]Prefixes pertaining to the metric system are in Appendix 8-2.

extern.ir

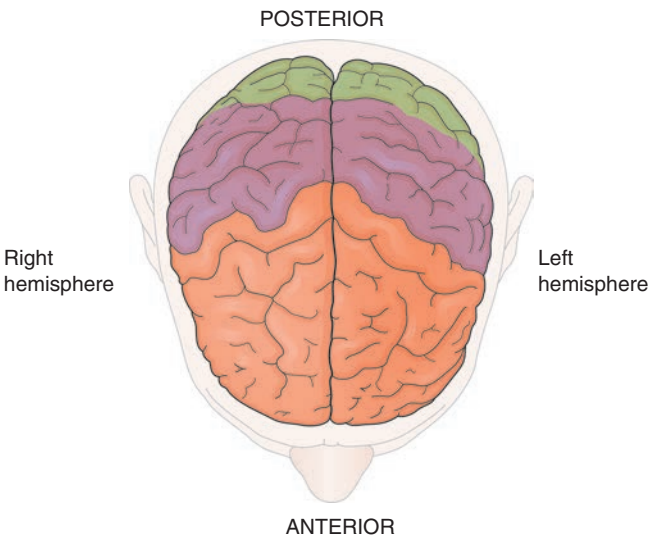

FIGURE 1-14 Brain hemispheres. Each half of the brain is a hemisphere. The prefix *hemi-* means half or one side.

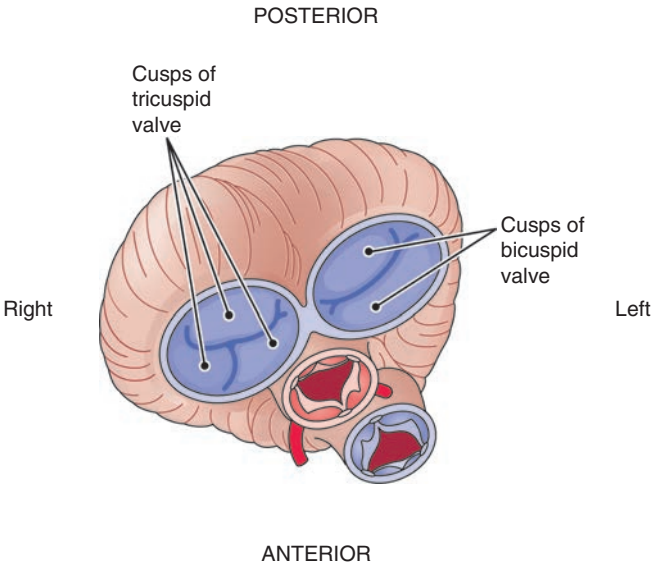

FIGURE 1-15 Heart valves. The valve on the heart's right side, the tricuspid, has three cusps (flaps); the valve on the heart's left side, the bicuspid, has two cusps. The prefixes *bi-* and *tri-* indicate number.

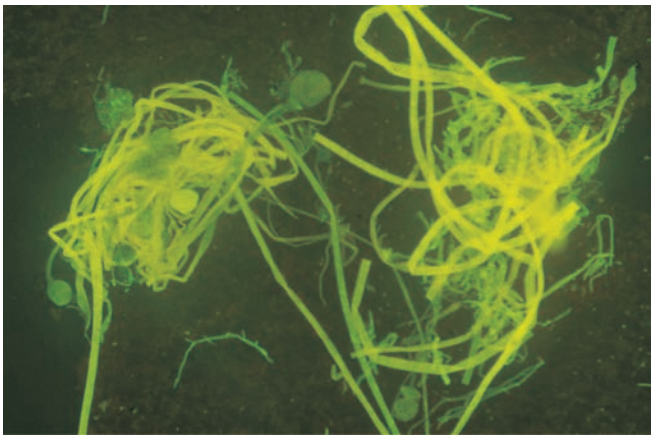

FIGURE 1-16 A multicellular organism. This fungus has more than one cell. It is a simple multicellular organism.

Exercise 1-5

Complete the exercise. To check your answers go to Appendix 11.

Fill in the blanks. Use the phonetics to pronounce each word as you work through the exercises.

1. Place the following prefixes in order of increasing numbers: tri, uni-, tetra-, bi- _____
2. A binocular (*bi-NOK-u-lar*) microscope has _____ eyepieces.
3. A quadruped (*KWAD-ru-ped*) animal walks on _____ feet (ped/o).
4. The term unilateral (*u-nih-LAT-eh-ral*) refers to _____ side (later/o).
5. The term semilunar (*sem-e-LU-nar*) means shaped like a _____ moon.
6. A diploid (*DIP-loyd*) organism has _____ sets of chromosomes (-ploid).

(continued)

extern.ir

Exercise 1-5 *(Continued)*

7. A tetrad (*TET-rad*) has _____ components.
8. A tripod (*TRI-pod*) has _____ legs.
9. Monophonic (*mon-o-FON-ik*) sound has _____ channel.

Give a prefix that is similar in meaning to each of the following.

10. di- _____
11. poly- _____
12. hemi- _____
13. mon/o- _____

Table 1-6 Prefixes for Colors

Prefix	Meaning	Example	Definition of Example
cyan/o-	blue	cyanosis *si-ah-NO-sis*	bluish discoloration of the skin due to lack of oxygen **(FIG. 1-17)**
erythr/o-	red	erythrocyte *eh-RITH-ro-site*	red blood cell (-cyte)
leuk/o-	white, colorless	leukemia *lu-KE-me-ah*	cancer of white blood cells
melan/o-	black, dark	melanin *MEL-ah-nin*	the dark pigment that colors the hair and skin
xanth/o-	yellow	xanthoma *zan-THO-mah*	yellow growth (-oma) on the skin

FIGURE 1-17 Cyanosis, a bluish discoloration. This abnormal coloration is seen in the toenails and toes, as compared to the normal coloration of the fingertips. The prefix *cyan/o-* means "blue."

extern.ir

Exercise 1-6

Complete the exercise. To check your answers go to Appendix 11.

Match the following terms, and write the appropriate letter to the left of each number.

____ 1. melanocyte (*MEL-ah-no-site*)
____ 2. xanthoderma (*zan-tho-DER-mah*)
____ 3. cyanotic (*si-ah-NOT-ik*)
____ 4. erythema (*eh-RIH-the-mah*)
____ 5. leukocyte (*LU-ko-site*)

a. pertaining to bluish discoloration
b. redness of the skin
c. yellow coloration of the skin
d. cell that produces dark pigment
e. white blood cell

Table 1-7 Negative Prefixes

Prefix	Meaning	Example	Definition of Example
a-, an-	not, without, lack of, absence	anhydrous *an-HI-drus*	lacking water (hydr/o)
anti-	against	antiseptic *an-tih-SEP-tik*	agent used to prevent infection (sepsis)
contra-	against, opposite, opposed	contraindicated *kon-trah-IN-dih-ka-ted*	against recommendations, not advisable
de-	down, without, removal, loss	decalcify *de-KAL-sih-fi*	remove calcium (calc/i) from
dis-	absence, removal, separation	dissect *dih-SEKT*	to separate tissues for anatomic study
in-[a], im- (used before b, m, p)	not	incontinent *in-KON-tih-nent*	not able to contain or control discharge of excretions
non-	not	noncontributory *non-kon-TRIB-u-tor-e*	not significant, not adding information to a medical diagnosis
un-	not	uncoordinated *un-ko-OR-dih-na-ted*	not working together, not coordinated

[a]May also mean "in" or "into" as in inject, inhale.

Exercise 1-7

Complete the exercise. To check your answers go to Appendix 11.

Identify and define the prefix in the following words.

	Prefix	Meaning of Prefix
1. aseptic	a	not, without, lack of, absence
2. antidote		
3. amnesia		
4. disintegrate		
5. contraception		
6. inadequate		

(continued)

extern.ir

Exercise 1-7 *(Continued)*

7. depilatory _____ _____
8. nonconductor _____ _____

Add a prefix to form the negative of the following words.

9. conscious
10. significant _____ unconscious _____
11. infect _____
12. usual _____
13. specific _____
14. congestant _____
15. compatible _____

Table 1-8 Prefixes for Direction

Prefix	Meaning	Example	Definition of Example
ab-	away from	abduct *ab-DUKT*	to move away from the midline **(FIG. 1-18)**
ad-	toward, near	adduct *ad-DUKT*	to move toward the midline (see **FIG. 1-18**)
dia-	through	diarrhea *di-ah-RE-ah*	frequent discharge of fluid fecal matter
per-	through	percutaneous *per-ku-TA-ne-us*	through the skin
trans-	through	transected *tran-SEKT-ed*	cut (sectioned) through or across

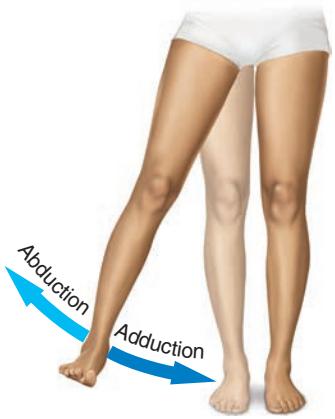

FIGURE 1-18 Abduction and adduction. The prefix *ab-* means "away from"; the leg is moved away from the body in abduction. The prefix *ad-* means "toward"; the leg is moved toward the body in adduction.

extern.ir

Exercise 1-8

Complete the exercise. To check your answers go to Appendix 11.

Identify and define the prefix in the following words.

	Prefix	Meaning of Prefix
1. dialysis	dia	through
2. percolate	_____	_____
3. adjacent	_____	_____
4. absent	_____	_____
5. diameter	_____	_____
6. transport	_____	_____

Table 1-9 Prefixes for Degree

Prefix	Meaning	Example	Definition of Example
hyper-	over, excess, abnormally high, increased	hyperthermia *hi-per-THER-me-ah*	high body temperature
hypo-[a]	under, below, abnormally low, decreased	hyposecretion *hi-po-se-KRE-shun*	underproduction of a substance
olig/o-	few, scanty	oligospermia *ol-ih-go-SPER-me-ah*	abnormally low number of sperm cells in semen
pan-	all	pandemic *pan-DEM-ik*	disease affecting an entire population
super-[a]	above, excess	supernumerary *su-per-NU-mer-ar-e*	in excess number

[a]May also indicate position, as in hypodermic, superficial.

Exercise 1-9

Complete the exercise. To check your answers go to Appendix 11.

Match the following terms, and write the appropriate letter to the left of each number.

____ 1. hypotensive (*hi-po-TEN-siv*)
____ 2. oligodontia (*ol-ih-go-DON-she-ah*)
____ 3. panplegia (*pan-PLE-je-ah*)
____ 4. superscript (*SU-per-skript*)
____ 5. hyperventilation (*hi-per-ven-tih-LA-shun*)

a. excess breathing
b. something written above
c. having low blood pressure
d. total paralysis
e. less than the normal number of teeth

extern.ir

Table 1-10 Prefixes for Size and Comparison

Prefix	Meaning	Example	Definition of Example
equi-	equal, same	equilibrium *e-kwih-LIB-re-um*	a state of balance, state in which conditions remain the same
eu-	true, good, easy, normal	euthanasia *u-thah-NA-ze-ah*	easy or painless death (thanat/o)
hetero-	other, different, unequal	heterogeneous *het-er-o-JE-ne-us*	composed of different materials, not uniform
homo-, homeo-	same, unchanging	homograft *HO-mo-graft*	tissue transplanted to another of the same species
iso-	equal, same	isocellular *i-so-SEL-u-lar*	composed of similar cells
macro-	large, abnormally large	macroscopic *mak-ro-SKOP-ik*	large enough to be seen without a microscope
mega-[a], megal/o	large, abnormally large	megacolon *meg-ah-KO-lon*	enlargement of the colon
micro-[a]	small	microcyte *MI-kro-site*	very small cell (-cyte)
neo-	new	neonate *NE-o-nate*	a newborn infant **(FIG. 1-19)**
normo-	normal	normovolemia *nor-mo-vol-E-me-ah*	normal blood volume
ortho-	straight, correct, upright	orthodontics *or-tho-DON-tiks*	branch of dentistry concerned with correction and straightening of the teeth (odont/o)
poikilo-	varied, irregular	poikilothermic *poy-kih-lo-THER-mik*	having variable body temperature (therm/o)
pseudo-	false	pseudoplegia *su-do-PLE-je-ah*	false paralysis (-plegia)
re-	again, back	reflux *RE-flux*	backward flow

[a]Mega- also means 1 million, as in megahertz. Micro- also means 1 millionth, as in microsecond.

FIGURE 1-19 A neonate or newborn. The prefix *neo-* means "new."

extern.ir

Exercise 1-10

Complete the exercise. To check your answers go to Appendix 11.

Match the following terms, and write the appropriate letter to the left of each number.

____ 1. isograft (*I-so-graft*)
____ 2. orthotic (or-*THOT-ik*)
____ 3. pseudoreaction (*su-do-re-AK-shun*)
____ 4. poikiloderma (*poy-kil-o-DER-mah*)
____ 5. homothermic (*ho-mo-THER-mik*)

a. having a constant body temperature
b. irregular, mottled condition of the skin
c. false response
d. tissue transplanted between identical individuals
e. straightening or correcting deformity

Identify and define the prefix in the following words.

	Prefix	Meaning of Prefix
6. homeostasis	homeo	same, unchanging
7. equivalent	_____	_____
8. orthopedics	_____	_____
9. rehabilitation	_____	_____
10. euthyroidism	_____	_____
11. neocortex	_____	_____
12. megabladder	_____	_____
13. isometric	_____	_____
14. normothermic	_____	_____

Write the opposite of the following words.

15. homogeneous (of uniform composition) *ho-mo-JE-ne-us* _____
16. macroscopic (large enough to see with the naked eye) *mah-kro-SKOP-ik* _____

Table 1-11 Prefixes for Time and/or Position

Prefix	Meaning	Example	Definition of Example
ante-	before	antenatal *an-te-NA-tal*	before birth (nat/i)
pre-	before, in front of	premature *pre-mah-CHUR*	occurring before the proper time
pro-	before, in front of	prodrome *PRO-drome*	symptom that precedes a disease
post-	after, behind	postnasal *post-NA-sal*	behind the nose (nas/o)

extern.ir

Exercise 1-11

Complete the exercise. To check your answers go to Appendix 11.

Match the following terms, and write the appropriate letter to the left of each number.

____ 1. postmortem (*post-MOR-tem*)
____ 2. antedate (*AN-te-date*)
____ 3. progenitor (*pro-JEN-ih-tor*)
____ 4. prepartum (*pre-PAR-tum*)
____ 5. projectile (*pro-JEK-tile*)

a. to occur before another event
b. ancestor, one who comes before
c. before birth (parturition)
d. throwing or extending forward
e. occurring after death

Identify and define the prefix in the following words.

	Prefix	Meaning of Prefix
6. prediction (*pre-DIK-shun*)	pre	before, in front of
7. postmenopausal (*post-men-o-PAW-zal*)		
8. procedure (*pro-SE-jur*)		
9. predisposing (*pre-dis-PO-zing*)		
10. antepartum (*an-te-PAR-tum*)		

Table 1-12 Prefixes for Position

Prefix	Meaning	Example	Definition of Example
dextr/o-	right	dextrogastria *deks-tro-GAS-tre-ah*	displacement of the stomach (gastr/o) to the right
sinistr/o-	left	sinistromanual *sin-is-tro-MAN-u-al*	left-handed
ec-, ecto-	out, outside	ectopic *ek-TOP-ik*	out of normal position
ex/o-	away from, outside	excise *ek-SIZE*	to cut out
end/o-	in, within	endoderm *EN-do-derm*	inner layer of a developing embryo
mes/o-	middle	mesencephalon *mes-en-SEF-ah-lon*	middle portion of the brain (encephalon), midbrain
syn-, sym- (used before b, m, p)	together	synapse *SIN-aps*	a junction between two nerve cells (**FIG. 1-20**)
tel/e-, tel/o-	end, far, at a distance	teletherapy *tel-eh-THER-ah-pe*	radiation therapy delivered at a distance from the body

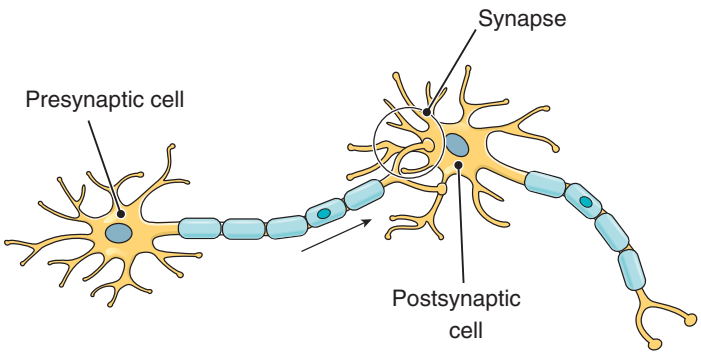

FIGURE 1-20 A synapse. Nerve cells come together at a synapse, as shown by the prefix *syn-*. The presynaptic cell is located before (prefix *pre-*) the synapse; the postsynaptic cell is located after (prefix *post-*) the synapse.

extern.ir

Exercise 1-12

Complete the exercise. To check your answers go to Appendix 11.

Match the following terms, and write the appropriate letter to the left of each number.

____ 1. mesoderm (*MES-o-derm*)	a. displacement of the heart to the left
____ 2. symbiosis (*sim-bi-O-sis*)	b. device for viewing the inside of a structure
____ 3. sinistrocardia (*sin-is-tro-KAR-de-ah*)	c. two organisms living together
____ 4. endoscope (*EN-do-skope*)	d. last stage of cell division (mitosis)
____ 5. telephase (*TEL-eh-faze*)	e. middle layer of a developing embryo

Identify and define the prefix in the following words.

	Prefix	Meaning of Prefix
6. sympathetic (*sim-pah-THET-ik*)	sym	together
7. extract (*EKS-tract*)	_____	_____
8. ectoparasite (*ek-to-PAR-ah-site*)	_____	_____
9. syndrome (*SIN-drome*)	_____	_____
10. endotoxin (*en-do-TOX-in*)	_____	_____

Write the opposite of the following words.

11. exogenous (outside the organism) *eks-OJ-eh-nus*	_____	_____
12. dextromanual (right-handed) *deks-tro-MAN-u-al*	_____	_____
13. ectoderm (outermost layer of the embryo) *EK-to-derm*	_____	_____

Case Study Revisited

David's Follow-up

David took the recommendations and instructions from the gastroenterologist seriously. He was aware of the consequences of GERD since his father had undergone a surgical procedure for it 2 years ago. David's father had allowed his symptoms to go untreated which caused damage to his esophagus requiring surgery. Even after surgery, David's father continues to have ongoing issues due to his noncompliance with meds and obesity. David saw first-hand what he could be facing if he did not take care of his health.

David knew he had a lot to accomplish prior to his 3-month follow-up with his physician. He followed the dosage instructions on his Prevacid and made sure he stopped by the student health center to have his monthly prescriptions filled. David also joined the local health club where he received a student discount. The club allowed free sessions with a personal trainer who helped David develop an exercise routine along with some diet tips. Soon David developed friendships with others at the club and began playing racquetball.

At his 3-month follow-up appointment, David reported no repeat episodes of epigastric pain. He completed his prescription of Prevacid, lost 10 pounds, changed his diet, and with the advice of his educational counselor cut back on some of his classes for the new semester. The gastroenterologist concluded that David's initial experience with epigastric pain was most likely due to gastroesophageal reflux (GER) and had been relieved by Prevacid and through David's lifestyle changes.

extern.ir

CHAPTER 1

Review

This review tests your understanding of the content introduced in this chapter. Follow the instructions for each exercise and check your answers in Appendix 11.

MULTIPLE CHOICE

Select the best answer and write the letter of your choice to the left of each number.

_____ 1. *Epi-* in the term *epigastric* is a
a. word root
b. prefix
c. suffix
d. combining form

_____ 2. The *-oid* in the term *xiphoid* is a
a. root
b. prefix
c. derivation
d. suffix

_____ 3. The term *musculoskeletal* is a(n)
a. abbreviation
b. word root
c. combining form
d. compound word

_____ 4. The adjective for *larynx* is
a. larynxic
b. laryngeal
c. larynal
d. largeal

_____ 5. The combining form for *thorax* (chest) is
a. thorax/o
b. thor/o
c. thorac/o
d. thori/o

_____ 6. In David's case study, the term GERD represents a(n)
a. combining form
b. acronym
c. prefix
d. suffix

_____ 7. In David's case study, the *ph* in dysphagia is pronounced as
a. f
b. p
c. h
d. s

extern.ir

FILL IN THE BLANKS

Complete the sentence with the correct term(s).

8. A root with a vowel added to aid in pronunciation is called a(n) _____.
9. Combine the word parts *dia-*, meaning "through," and *-rhea*, meaning "flow," to form a word meaning "passage of fluid stool" _____.
10. The abbreviation ETOH means (refer to Appendix 2) _____.
11. Use Appendix 3 to find that the suffix in *gastroduodenoscopy*, seen in David's opening case study, means _____.
12. Combine the root *cardi*, meaning "heart," with the suffix *-logy*, meaning "study of," to form a word meaning "study of the heart" _____.
13. The suffix *-al*, as in *esophageal*, seen in David's case study follow-up means _____.
14. Appendix 1 shows that the symbol ↑ means _____.
15. A monocle has _____ lens(es).
16. A triplet is one of _____ babies born together.
17. Sinistrad means toward the _____.
18. A disaccharide is a sugar composed of _____ subunits.
19. A contralateral structure is located on the side _____ to a given point.
20. A tetralogy is composed of _____ part(s).

Identify the suffix that means "condition of" in the following words. Remember to use the phonetics in the following exercises to pronounce each word as you work.

21. alcoholism (*AL-ko-hol-izm*) (alcohol dependence) _____
22. insomnia (*in-SOM-ne-ah*) (inability to sleep; root: somn/o) _____
23. acidosis (*as-ih-DO-sis*) (acid body condition) _____
24. dysentery (*DIS-en-ter-e*) (intestinal disorder; root: enter/o) _____
25. psychosis (*si-KO-sis*) (disorder of the mind) _____
26. anemia (*ah-NE-me-ah*) (lack of blood or hemoglobin; root: hem/o) _____

Give the suffix in the following words that means "specialty" or "specialist."

27. psychiatry (*si-KI-ah-tre*) _____
28. orthopedics (*or-tho-PE-diks*) _____
29. anesthesiologist (*an-es-the-ze-OL-o-jist*) _____
30. technician (*tek-NISH-un*) _____
31. obstetrician (*ob-steh-TRISH-un*) _____

Give the name of a specialist in the following fields.

32. dermatology (*der-mah-TOL-o-je*) _____
33. pediatrics (*pe-de-AH-triks*) _____
34. physiology (*fiz-e-OL-o-je*) _____
35. gynecology (*gi-neh-KOL-o-je*) _____

extern.ir

Identify the adjective suffix in the following words that means "pertaining to," "like," or "resembling."

36. anxious (*ANG-shus*) _____
37. fibroid (*FI-broyd*) _____
38. arterial (*ar-TE-re-al*) _____
39. pelvic (*PEL-vik*) _____
40. binary (*BI-nar-e*) _____
41. skeletal (*SKEL-eh-tal*) _____
42. rheumatoid (*RU-mah-toyd*) _____
43. febrile (*FEB-rile*) _____
44. vascular (*VAS-ku-lar*) _____
45. exploratory (*ek-SPLOR-ah-tor-e*) _____

PLURALS

Write the plural for the following words. Each word ending is underlined.

46. gingiva (*JIN-jih-vah*) (gum) _____
47. testis (*TEST-is*) (male reproductive organ) _____
48. criterion (*kri-TIR-e-on*) (standard) _____
49. lumen (*LU-men*) (central opening) _____
50. locus (*LO-kus*) (place) _____
51. ganglion (*GANG-le-on*) (mass of nervous tissue) _____
52. larynx (*LAR-inks*) (voice box) _____
53. nucleus (*NU-kle-us*) (center; core) _____

SINGULARS

Write the singular form for the following words. Each word ending is underlined.

54. thrombi (*THROM-bi*) (blood clots) _____
55. vertebrae (*VER-teh-bre*) (bones of the spine) _____
56. bacteria (*bak-TE-re-ah*) (type of microorganism) _____
57. alveoli (*al-VE-oli*) (air sacs) _____
58. apices (*A-pih-seze*) (high points, tips) _____
59. foramina (*fo-RAM-ih-nah*) (openings) _____
60. diagnoses (*di-ag-NO-seze*) (identifications of disease) _____
61. carcinomata (*kar-sih-NO-mah-tah*) (cancers) _____

DEFINITIONS

Identify and define the prefix in the following words.

	Prefix	Meaning of Prefix
62. hyperactive	_____	_____
63. transfer	_____	_____
64. posttraumatic	_____	_____
65. regurgitate	_____	_____
66. extend	_____	_____

extern.ir

67. adhere _____ _____
68. unusual _____ _____
69. detoxify _____ _____
70. semisolid _____ _____
71. premenstrual _____ _____
72. perforate _____ _____
73. dialysis (*di-AL-ih-sis*) _____ _____
74. antibody _____ _____
75. microsurgery _____ _____
76. disease _____ _____
77. endoparasite _____ _____
78. symbiotic (*sim-bi-OT-ik*) _____ _____
79. prognosis (*prog-NO-sis*) _____ _____
80. insignificant _____ _____

OPPOSITES

Write a word that means the opposite of each of the following.

81. humidify _____
82. permeable _____
83. heterogeneous _____
84. exotoxin _____
85. microscopic _____
86. hyperventilation _____
87. postsynaptic _____
88. septic _____

SYNONYMS

Write a synonym (a word having the same or nearly the same meaning as another word) in each of the following blanks.

89. supersensitivity _____
90. megalocyte (extremely large red blood cell) _____
91. antenatal _____
92. isolateral (having equal sides) _____

TRUE–FALSE

Examine the following statements. If the statement is true, write T in the first blank. If the statement is false, write F in the first blank, and correct the statement by replacing the underlined word in the second blank.

	True or False	Correct Answer
93. Immune cells are primed by their <u>first</u> exposure to a disease organism.	T	
94. Unicellular organisms are composed of <u>10 cells</u>.	F	one cell
95. To bisect is to cut into <u>two</u> parts.		
96. A tetrad has <u>five</u> parts		

extern.ir

97. In Latin, the oculus dexter is the left eye. _____ _____

98. A triceps muscle has six parts. _____ _____

99. A polygraph measures many physiologic responses. _____ _____

PRONUNCIATION

Pronounce the following words.

100. dyslexia

101. rheumatism

102. pneumatic

103. chemist

104. pharmacy

Pronounce the following phonetic forms and write the words they represent.

105. *KAR-de-ak* _____

106. *HI-dro-jen* _____

107. *OK-u-lar* _____

108. *ru-MAT-ik* _____

MATCHING

Match the following terms, and write the appropriate letter to the left of each number.

_____ 109.	primitive	a. one-half or one side of the chest
_____ 110.	biceps	b. having two forms
_____ 111.	unify	c. combine into one part
_____ 112.	dimorphous	d. a muscle with two parts
_____ 113.	hemithorax	e. occurring first in time

_____ 114.	erythematous	a. cell with yellow color
_____ 115.	melanoma	b. having a bluish discoloration
_____ 116.	xanthocyte	c. darkly pigmented tumor
_____ 117.	cyanotic	d. red in color
_____ 118.	leukocyte	e. white blood cell

Match each of the following prefixes with its meaning.

_____ 119.	poikilo-	a. good, true, easy
_____ 120.	eu-	b. straight, correct
_____ 121.	ortho-	c. false
_____ 122.	pseudo-	d. few, scanty
_____ 123.	oligo-	e. varied, irregular

WORD BUILDING

Write words for the following definitions using the word parts provided. A combining vowel is included. Each word part can be used more than once.

-itis	-logy	-ptosis	nephr	-o	gastr	cardi	neur-

124. Inflammation of the stomach _____ gastritis _____

125. Study of the nervous system _____

extern.ir

126. Dropping of the kidney _____

127. Study of the kidney _____

128. Inflammation of a nerve _____

129. Downward displacement of the heart _____

Write words for the following definitions using the word parts provided. Each word part may be used more than once.

mon/o	-al	dextr/o	end/o	macro	cardi	cyt	-ic	ecto	micro	-ia

130. Pertaining to a very small cell _____

131. A condition in which the heart is outside its normal position _____

132. Pertaining to a cell with a single nucleus _____

133. Condition in which the heart is displaced to the right _____

134. Pertaining to the innermost layer of the heart _____

135. Pertaining to a very large cell _____

136. Condition in which the heart is extremely small _____

WORD ANALYSIS

Define each of the following words, and give the meaning of the word parts in each. Use a dictionary if necessary. Remember to use the phonetics to pronounce each word as you work through the exercise.

137. renogastric (*re-no-GAS-trik*)

a. ren/o _____

b. gastr/o _____

c. -ic _____

138. geriatrician (*jer-e-ah-TRIH-shun*)

a. ger/e _____

b. iatr/o _____

c. -ic _____

d. -ian _____

139. isometric (*i-so-MET-rik*)

a. iso- _____

b. metr/o _____

c. -ic _____

140. symbiosis (*sim-be-O-sis*)

a. sym- _____

b. bio _____

c. -sis _____

extern.ir

Additional Case Studies

Case Study 1-1: Greg's Arthritic Knees

Chief Complaint

Greg, a 68 y/o male, presents to his family doctor c/o bilateral knee discomfort that worsens prior to a heavy rainstorm. He states that his "arthritis" is not getting any better. He has been taking NSAIDs but is not obtaining relief at this point. His family physician referred him to an orthopedic surgeon for further evaluation.

Past Medical History

Greg was active in sports in high school and college. He tore his ACL while playing soccer during his junior year in college, at which time he retired from intercollegiate athletics. His only other physical complaint involves stiffness in his right shoulder, which he attributes to pitching while playing baseball in high school.

Current Medications

NSAIDs prn for arthritic pain; Lipitor 10 mg for mild hyperlipidemia.

X-Rays

Bilateral knee x-rays revealed moderate degenerative changes with joint space narrowing in the left knee; severe degenerative changes and joint space narrowing in the right knee.

Case Study 1-1 Questions

Multiple Choice. *Select the best answer, and write the letter of your choice to the left of each number. To check your answers go to Appendix 11.*

_____ 1. The *bi-* in the word *bilateral* is a
   a. suffix
   b. root
   c. prefix
   d. combining form

_____ 2. The *-itis* in the word *arthritis* is a
   a. root
   b. prefix
   c. derivation
   d. suffix

_____ 3. *Arthr/o* is a(n)
   a. combining form
   b. acronym
   c. prefix
   d. suffix

_____ 4. The AI in the abbreviation NSAID means (see Appendix 2)
   a. antacid
   b. anti-inflammatory
   c. anti-infectious
   d. after incident

Fill in the blank with the correct answer.

5. Use Appendix 2 to find what the abbreviation *ACL* means.

   _____

6. Use Appendix 2 to find what the abbreviation *c/o* means.

   _____

7. Use Appendix 7 to find what the prefix *hyper-* means.

   _____

8. Use Appendix 2 to find what the abbreviation *prn* means.

   _____

9. Use Appendices 5, 6, and 7 to find what the word parts in *hyperlipidemia* mean.

   a. hyper- _____
   b. lip/o _____
   c. -emia _____

extern.ir

10. Use Appendix 3 to find what the word parts in *orthopedic* mean.

    a. orth/o _____

    b. ped/o _____

11. Use Appendix 7 to find what the prefix *inter-* means.

    _____

Case Study 1-2: Sally's Job-Related Breathing Problems

Chief Complaint

Sally, a 54 y/o woman, has been having difficulty breathing (dyspnea) that was originally attributed to a left upper lobe (LUL) pneumonia. She was treated with an antibiotic, and after no improvement was noted in her breathing, Sally had a follow-up chest x-ray that revealed a small LUL pneumothorax. She was referred to the respiratory clinic and saw Dr. Williams, a pulmonologist.

Past Medical History

Sally has a history of smoking a pack of cigarettes a day for 30 years but stopped smoking 2 years ago. She noticed an improvement in her breathing and tired less easily after she quit. About 1 month ago, she complained of general malaise, dyspnea, and a productive cough; she was expectorating pus-containing (purulent) sputum and was febrile. The chest radiograph and sputum cultures indicate that her symptoms had progressed into a bronchopneumonia with pulmonary edema complicated by a small pneumothorax in the LUL. A pea-size mass was identified in the left lobe. Also noted, Sally is a hairstylist as well as a manicurist and recently went back to work in a beauty salon. She has complained that the fumes from the hair chemicals and nail products affect her breathing.

Clinical Course

Dr. Williams performed a bronchoscopic examination. During the examination, she took a biopsy of the mass, and the results were negative. Sputum cultures were also taken to determine the spectrum of action of an appropriate antibiotic. A respiratory therapist measured Sally's respiratory volumes and recorded any changes. Sally was told to drink plenty of liquids, get proper rest, and refrain from working for 1 week. She was told to wear a mask when she returned to work, avoid unventilated areas in the salon, and avoid the chemical fumes as much as possible. She was given an appointment to return to the clinic in 1 month for follow-up.

Case Study 1-2 Questions

Multiple Choice. *Select the best answer, and write the letter of your choice to the left of each number. To check your answers go to Appendix 11.*

_____ 1. The *gh* in the terms cough and radiograph is pronounced as
   a. g
   b. h
   c. f
   d. s

_____ 2. The *pn* in the term bronchopneumonia is pronounced as
   a. p
   b. n
   c. f
   d. s

extern.ir

_____ 3. Which of the following is a compound word?
a. pulmonary
b. pneumothorax
c. respiratory
d. antibiotic

_____ 4. The suffix that means "condition of" in *pneumonia* is
a. -nia
b. -monia
c. -ia
d. -onia

_____ 5. The plural of *spectrum* is
a. spectra
b. spectria
c. spectrina
d. spectrums

Fill in the blank with the correct answer.

6. Find four words in the case study with a suffix that means "specialist in a field."
1. _____
2. _____
3. _____
4. _____

7. Find five words in the case study with suffixes that mean "pertaining to, like, or resembling," and write both the suffix and the word that contains it.

	Suffix	Word
1.	_____	_____
2.	_____	_____
3.	_____	_____
4.	_____	_____
5.	_____	_____

Case Study 1-3: Displaced Fracture of the Femoral Neck

While walking home from the train station, Esther, a 72 y/o woman with pre-existing osteoporosis, tripped over a raised curb and fell. In the emergency department, she was assessed for severe pain, and swelling and bruising of her right thigh. A radiograph (x-ray) showed a fracture at the neck of the right femur (thigh bone) (FIG. 1-21). Esther was prepared for surgery and given a preoperative injection of an analgesic to relieve her pain. During surgery, she was given spinal anesthesia and positioned on an operating room table, with her right hip elevated on a small pillow. Intravenous antibiotics were given before the incision was made. Her right hip was repaired with a bipolar hemiarthroplasty (joint reconstruction). Postoperative care included maintaining the right hip in abduction, fluid replacement, physical therapy, and attention to signs of tissue degeneration and possible dislocation.



Anterior view

FIGURE 1-21 The right femur (thigh bone). The femoral neck is the fracture site in Case Study 1-3.

extern.ir

Case Study 1-3 Questions

Identify and define the prefixes in the following words. To check your answers go to Appendix 11.

	Prefix	Meaning of Prefix
1. pre-existing	_____	_____
2. analgesic, anesthesia	_____	_____
3. dislocation	_____	_____
4. replacement	_____	_____
5. bipolar	_____	_____
6. hemiarthroplasty	_____	_____
7. degeneration	_____	_____

Fill in the blanks.

8. The suffixes in the words osteoporosis and anesthesia mean _____.
9. The suffixes in the words intravenous, femoral, and analgesic mean _____.

Find a word in the case study that describes the following.

10. The time period before surgery _____
11. The time period after surgery _____
12. A position away from the midline of the body _____

extern.ir

CHAPTER 2

Body Structure

Pretest

Multiple Choice. **Select the best answer, and write the letter of your choice to the left of each number. To check your answers go to Appendix 11.**

_____ 1. The root that means "cell" is
a. spher
b. aden
c. cyt
d. gen

_____ 2. The process of body cell division is called
a. separation
b. segregation
c. mitosis
d. gestation

_____ 3. A compound that speeds up the rate of a metabolic reaction is a(n)
a. vitamin
b. enzyme
c. salt
d. lipid

_____ 4. The substance that makes up the cell's genetic material is
a. DNA
b. mineral
c. base
d. neurons

_____ 5. Chemicals: cells: tissues: _____: systems: organism. What belongs in the blank?
a. genes
b. enzymes
c. nuclei
d. organs

_____ 6. In humans, dorsal is another term for
a. lateral
b. central
c. anterior
d. posterior

_____ 7. The root *brachi/o* refers to the
a. head
b. spinal cord
c. leg
d. arm

_____ 8. The prefix *supra-* means
a. above
b. near
c. behind
d. below

extern.ir

Learning Objectives

After careful study of this chapter, you should be able to:

1. List the simplest to the most complex levels of a living organism. ***P40***
2. Describe and locate the main parts of a cell. ***P40***
3. Name and give the functions of the four basic types of tissues in the body. ***P43***
4. Define basic terms pertaining to the structure and function of body tissues. ***P44***
5. Define the main directional terms used in anatomy. ***P52***
6. Describe division of the body along three different planes. ***P53***
7. Locate the dorsal and ventral body cavities. ***P54***
8. Locate and name the nine divisions and four quadrants of the abdomen. ***P54***
9. Describe the main body positions used in medical practice. ***P55***
10. Define basic terms describing body structure. ***P57***
11. Use word parts pertaining to body organization and structure. ***P57***
12. Identify and analyze medical terms and abbreviations in chapter case studies. ***PP39, 70***

Case Study: Zachary's Self-Diagnosis

Chief Complaint

Zachary is a second-year medical student who, until recently, has done well in school. Lately, he finds that he is always tired and unable to focus in class. He decides to self-diagnose and begins with a review of systems (ROS). He notes that he is not having any cardiovascular, lymphatic, or respiratory system symptoms, such as tissue swelling, coughing, or shortness of breath. He also has not noticed any changes in urinary system functions. He realizes that he has gained some weight recently and has also been a little constipated but has no other problems with his digestive system. He rules out anything concerning his musculoskeletal system because he has no muscle cramps, joint pain, or weakness. He thinks his skin is drier than usual. He worries that this is an integumentary system sign of hypothyroidism and becomes concerned about his endocrine system function. Unable to perform any imaging studies or laboratory tests on his own, he makes an appointment to see a campus health services physician.

Examination

Zachary tells the physician he feels he has a metabolic disorder. He thinks he might have an adenoma, a glandular tumor that is disrupting homeostasis, his normal metabolic state. The physician takes a complete history and orders various blood tests to assist with the diagnosis. He completes a physical examination that reveals no abnormalities.

Clinical Course

The blood glucose levels, complete blood count (CBC), and thyroid function tests are all normal. Nothing in the tests indicates anything physically wrong with the Zachary. There is no indication that any further cytologic or histologic tests are necessary. The physician tells Zachary that he is sleep deprived from all his studying and that his weight gain can be explained by his poor food choices in the university cafeteria. In addition, the physician advises Zachary to schedule some exercise into his daily routine. Lastly, he reminds Zachary that although he is studying to be a physician, self-diagnosis at this point in his career could be inaccurate and cause undue anxiety.

Case Study Revisited: Once you complete this chapter, please review the case follow-up on p. 61.

Ancillaries *At-A-Glance*

Visit the web resource to access the following resources.

extern.ir

Learning Resources

- eBook
- A&P Module with Heart & Lung Sounds
- Image Bank
- TestPrep
- Animations
- Audio Pronunciation Glossary

Introduction

All organisms are built from simple to more complex levels (FIG. 2-1). Chemicals form the materials that make up cells, which are the body's basic structural and functional units. Groups of cells working together make up **tissues**, which in turn make up the **organs**, which have specialized functions. Organs become components of the various systems, which together comprise the whole organism. This chapter discusses the terminology related to basic body structure, leading to the study of all the individual organ systems in Part II.

The Cell

The **cell** is the basic unit of living organisms (FIG. 2-2). Cells accomplish all the activities and produce all the components of the body. They carry out **metabolism**, the sum of all the body's physical and chemical activities. They provide the energy for metabolic reactions in the form of the chemical **adenosine triphosphate** (ATP), commonly described as the energy compound of the cell. The main categories of organic compounds contained in cells are:

- **Proteins**, which include the **enzymes**, some hormones, and structural materials.
- **Carbohydrates**, which include sugars and starches. The main carbohydrate is the sugar **glucose**, which circulates in the blood to provide energy for the cells.
- **Lipids**, which include fats. Some hormones are derived from lipids, and adipose (fat) tissue is designed to store lipids.

Within the **cytoplasm** that fills the cell are subunits called **organelles**, each with a specific function (see FIG. 2-2). The main cell structures are named and described in BOX 2-1. Diseases may affect specific parts of cells. Cystic fibrosis and diabetes, for example, involve the plasma membrane. Other disorders originate with mitochondria, the endoplasmic reticulum (ER), lysosomes, or peroxisomes.

The **nucleus** is the control region of the cell. It contains the **chromosomes**, which carry genetic information (FIG. 2-3). Each human cell, aside from the reproductive (sex) cells, contains 46 chromosomes. These thread-like structures compose a complex organic substance, **deoxyribonucleic acid** (DNA), which is organized into separate units called **genes**. Genes control the formation of proteins, most particularly enzymes, the catalysts needed to speed the rate of metabolic reactions. To help manufacture proteins, the cells use a compound called **ribonucleic acid** (RNA), which is chemically related to DNA. Changes (mutations) in the

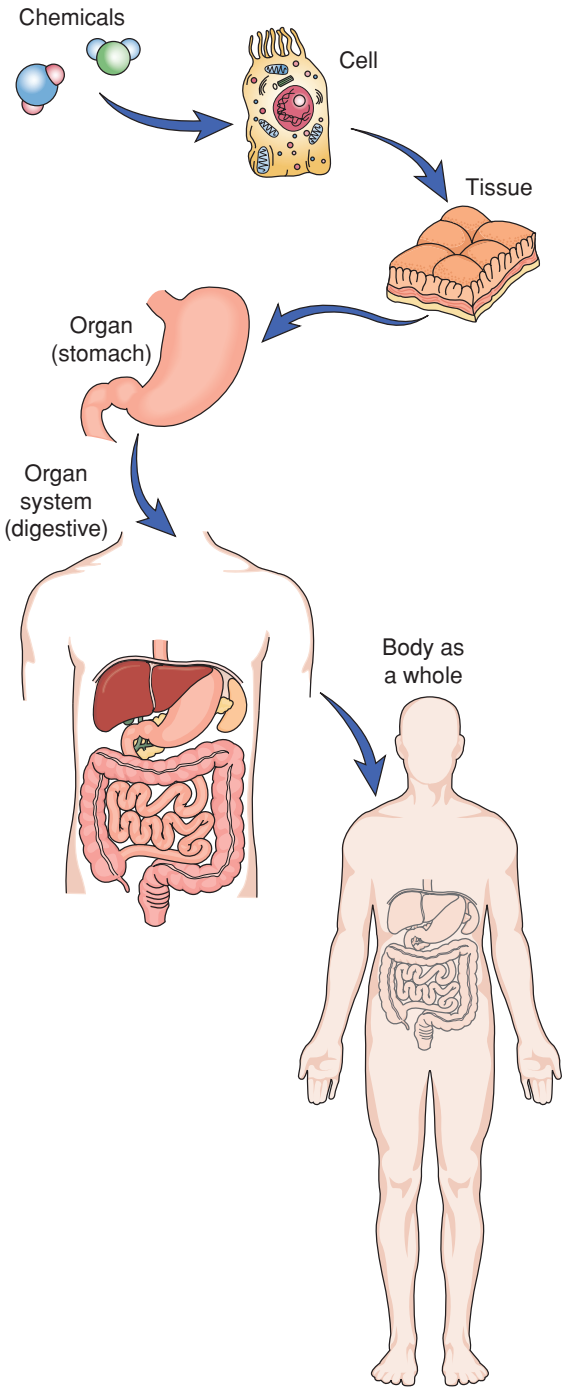

FIGURE 2-1 Levels of organization. The body is organized from the simple level of chemicals to the most complex level of the whole organism. The organ shown is the stomach, which is part of the digestive system.

extern.ir

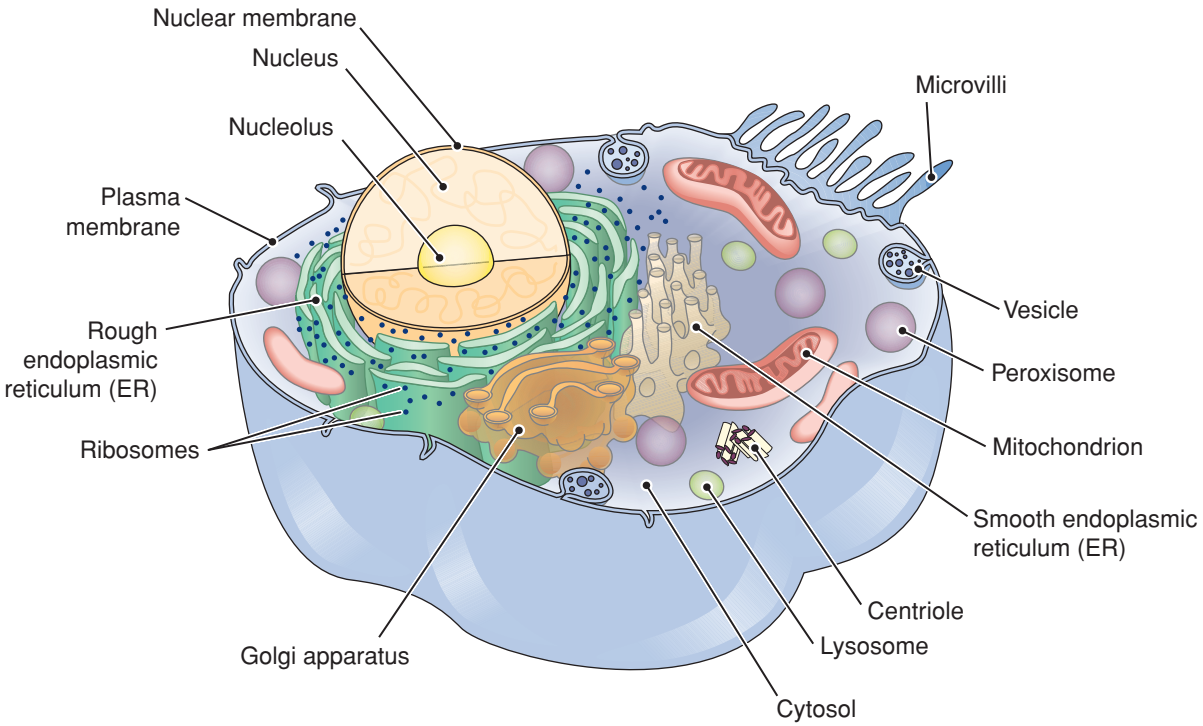

FIGURE 2-2 Generalized animal cell (sectional view). The main organelles are shown.

FOR YOUR REFERENCE

BOX 2-1

Cell Structures

Name	Description	Function
plasma membrane (*PLAZ-mah*)	outer layer of the cell, composed mainly of lipids and proteins	encloses the cell contents; regulates what enters and leaves the cell; participates in many activities, such as growth, reproduction, and interactions between cells
microvilli (*mi-kro-VIL-i*)	short extensions of the cell membrane	absorb materials into the cell
nucleus (*NU-kle-us*)	large, membrane-bound, dark-staining organelle near the center of the cell	contains the chromosomes, the hereditary units that direct all cellular activities
nucleolus (*nu-KLE-o-lus*)	small body in the nucleus	makes ribosomes
cytoplasm (*SI-to-plazm*)	colloidal suspension that fills the cell from the nuclear membrane to the plasma membrane	site of many cellular activities; consists of cytosol and organelles
cytosol (*SI-to-sol*)	fluid portion of the cytoplasm	surrounds the organelles
endoplasmic reticulum (ER) (*en-do-PLAZ-mik re-TIK-u-lum*)	network of membranes within the cytoplasm; rough ER has ribosomes attached to it; smooth ER does not	rough ER modifies, folds, and sorts proteins; smooth ER participates in lipid synthesis
ribosomes (*RI-bo-somz*)	small bodies free in the cytoplasm or attached to the ER, composed of RNA and protein	manufacture proteins

(continued)

extern.ir

FOR YOUR REFERENCE *(Continued)*

BOX 2-1

Cell Structures

Name	Description	Function
Golgi apparatus (*GOL-je*)	layers of membranes	modifies proteins; sorts and prepares proteins for transport to other parts of the cell or out of the cell
mitochondria (*mi-to-KON-dre-ah*)	large organelles with internal folded membranes	convert energy from nutrients into ATP
lysosomes (*LI-so-somz*)	small sacs of digestive enzymes	digest substances within the cell
peroxisomes (*per-OKS-ih-somz*)	membrane-enclosed organelles containing enzymes	break down harmful substances
vesicles (*VES-ih-klz*)	small membrane-bound sacs in the cytoplasm	store materials and move materials into or out of the cell in bulk
centrioles (*SEN-tre-olz*)	rod-shaped bodies (usually two) near the nucleus	help separate the chromosomes during cell division
surface projections	structures that extend from the cell	move the cell or the fluids around the cell
cilia (*SIL-e-ah*)	short, hair-like projections from the cell	move the fluids around the cell
flagellum (*flah-JEL-um*)	long, whip-like extension from the cell	moves the cell

FIGURE 2-3 Human chromosomes. There are 46 chromosomes in each human cell, except the sex cells (egg and sperm).

extern.ir

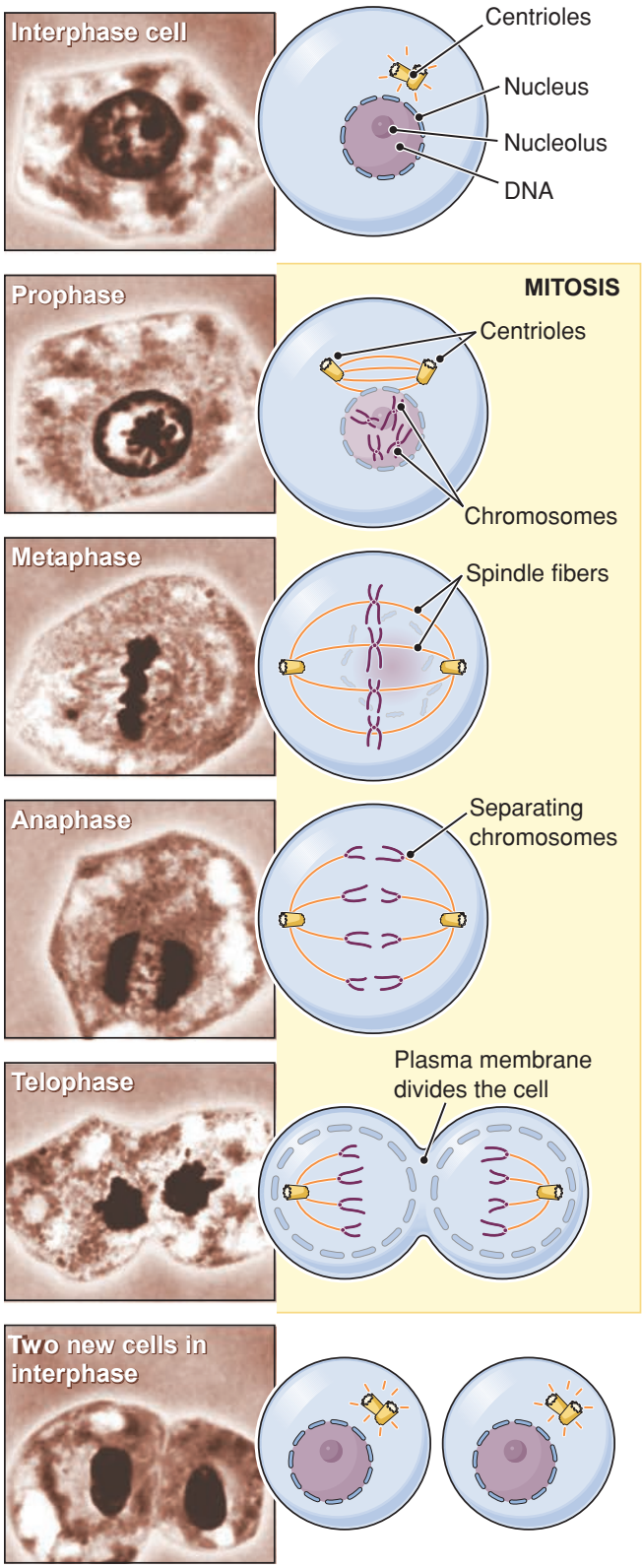

FIGURE 2-4 The stages in cell division (mitosis). When it is not undergoing mitosis, the cell is in interphase. The cell shown is for illustration only. It is not a human cell, which has 46 chromosomes.

genes or chromosomes are the source of hereditary diseases, as described in Chapter 16.

When a body cell divides by the process of **mitosis**, the chromosomes are doubled and then equally distributed to the two daughter cells. The stages in mitosis are shown in **FIGURE 2-4**. When a cell is not dividing, it remains in a stage called *interphase*. In cancer, cells multiply without control causing cellular overgrowth and tumors. Reproductive cells (eggs and sperm) divide by a related process, meiosis, that halves the chromosomes in preparation for fertilization. The role of meiosis in reproduction is further explained in Chapter 15.

Tissues

Cells are organized into four basic types of tissues that perform specific functions:

- Epithelial (*ep-ih-THE-le-al*) tissue, as shown in **FIGURE 2-5**, covers and protects body structures and lines organs, vessels, and cavities. Simple epithelium, composed of cells in a single layer, functions to absorb substances from one system to another, as in the respiratory and digestive tracts. Stratified epithelium, with cells in multiple layers, protects deeper tissues, as in the mouth and vagina. Most

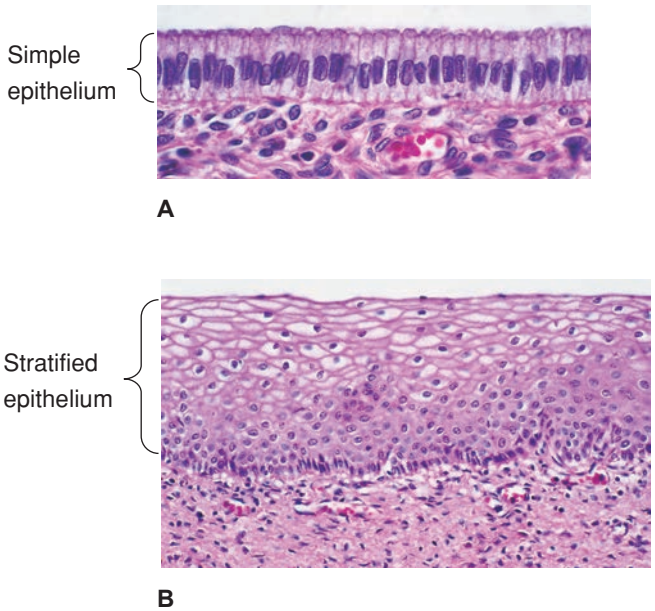

FIGURE 2-5 Epithelial tissue. The cells in simple epithelium (**A**) are in a single layer and absorb materials from one system to another. The cells in stratified epithelium (**B**) are in multiple layers and protect deeper tissues.

extern.ir

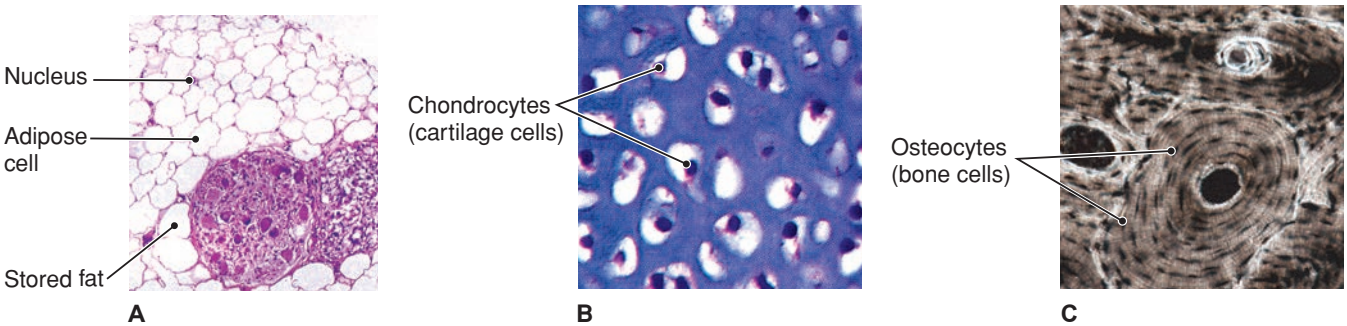

FIGURE 2-6 Connective tissue. Examples of connective tissue are adipose tissue (**A**), which stores fat; cartilage (**B**), which is used for protection and reinforcement; and bone (**C**), which makes up the skeleton.

of the active cells in glands are epithelial cells. Glands are described in more detail in Chapter 9.

- Connective tissue supports and binds body structures **(FIG. 2-6)**. It contains fibers and other nonliving material between the cells. Included in this category are blood (Chapter 10), adipose (fat) tissue, cartilage, and bone (Chapter 5).
- Muscle tissue (root: my/o) contracts to produce movement **(FIG. 2-7)**. There are three types of muscle tissues:
  - Skeletal muscle moves the skeleton. It has visible cross-bands, or striations, that are involved in contraction. Because it is under conscious control, it is also called voluntary muscle. Skeletal muscle is discussed in greater detail in Chapter 6.
  - Cardiac muscle forms the heart. It functions without conscious control and is described as involuntary. Chapter 10 describes the heart and its actions.
  - Smooth or visceral muscle forms the walls of the abdominal organs; it is also involuntary. Many organs described in later chapters on the systems have walls made of smooth muscle. The walls of ducts and blood vessels also are composed mainly of smooth muscle.
- Nervous tissue (root: neur/o) makes up the brain, spinal cord, and nerves **(FIG. 2-8)**. It coordinates and controls

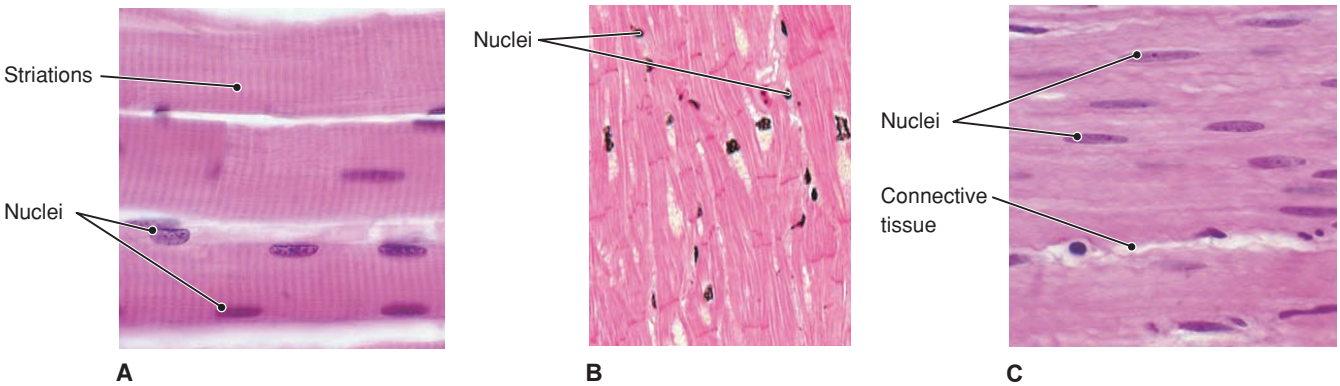

FIGURE 2-7 Muscle tissue. Skeletal muscle (**A**) moves the skeleton. It has visible bands (striations) that produce contraction. Cardiac muscle (**B**) makes up the wall of the heart. Smooth muscle (**C**) makes up the walls of hollow organs, ducts, and vessels.

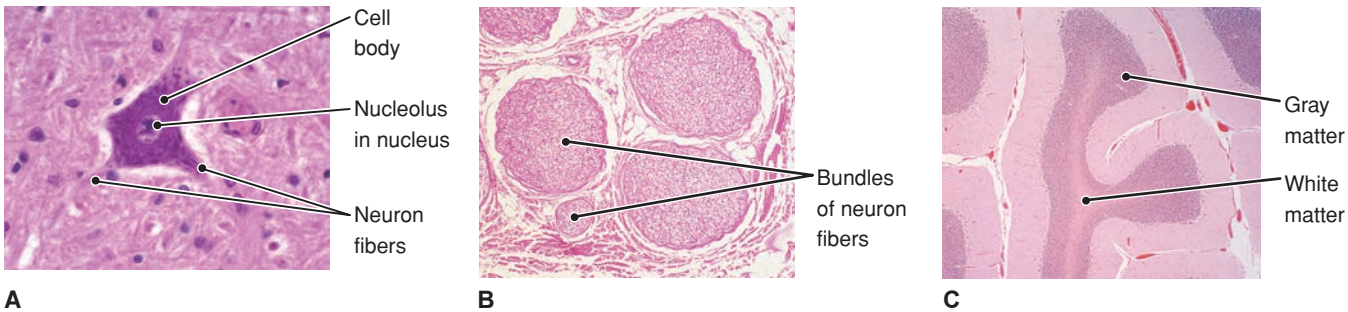

FIGURE 2-8 Nervous tissue. The functional cell of the nervous system is the neuron (**A**). Neuron fibers join to form nerves (**B**). Nervous tissue also makes up the spinal cord and brain (**C**), where it is divided into gray matter and white matter.

extern.ir

CLINICAL PERSPECTIVES
Laboratory Study of Tissues

BOX 2-2

Biopsy is the removal and examination of living tissue to determine a diagnosis. The term is also applied to the specimen itself. *Biopsy* comes from the Greek word *bios*, meaning "life," plus *opsis*, meaning "vision." Together they mean the visualization of living tissue.

Some other terms that apply to cells and tissues come from Latin. *In vivo* means "in the living body," as contrasted with *in vitro*, which literally means "in glass," and refers to procedures and experiments done in the laboratory, as compared to studies done in living organisms. *In situ* means "in its original place" and is used to refer to tumors that have not spread.

In toto means "whole" or "completely," as in referring to a structure or organ removed totally from the body. *Postmortem* literally means "after death," as in referring to an autopsy performed to determine the cause of death.

body responses by the transmission of electrical impulses. The basic cell in nervous tissue is the neuron, or nerve cell. The nervous system and senses are discussed in Chapters 7 and 8.

MEMBRANES

A **membrane** (*MEM-brane*) is a simple, very thin, and pliable sheet of tissue. Membranes may cover an organ, line a cavity, or separate one structure from another. Some secrete special substances. Mucous membranes secrete **mucus**, a thick fluid that lubricates surfaces and protects the underlying tissue, as in the lining of the digestive tract and respiratory passages. Serous membranes, which secrete a thin, watery fluid, line body cavities and cover organs. These include the membranes around the heart and lungs. Fibrous membranes cover and support organs, as found around the bones, brain, and spinal cord.

The study of tissues is **histology** (*his-TOL-o-je*), based on the root *hist/o*, meaning "tissue." BOX 2-2 describes some terms used in histology.

Organs and Organ Systems

Tissues are arranged into organs, which serve specific functions, and organs, in turn, are grouped into individual systems. FIGURE 2-9 shows the organs of the digestive system as an example. Although all body systems are interrelated, they are listed and described separately here as they appear in this text.

- Integumentary system, which includes the skin and its associated structures, such as hair, sweat glands, and oil glands. This system functions in protection and also helps to regulate body temperature.
- Skeletal system, which includes the bones and joints.
- Muscular system, which moves the skeleton and makes up the walls of internal organs. The muscular system and skeleton protect vital body parts.
- Nervous system, consisting of the brain, spinal cord, and nerves, and including the sensory system and special senses, with emphasis on the ear and the eye. This system receives and processes stimuli and directs responses.
- Endocrine system, consisting of individual glands that produce hormones.
- Cardiovascular system, consisting of the blood, heart, and blood vessels.
- Lymphatic system, organs, and vessels that aid circulation and help protect the body from foreign materials.

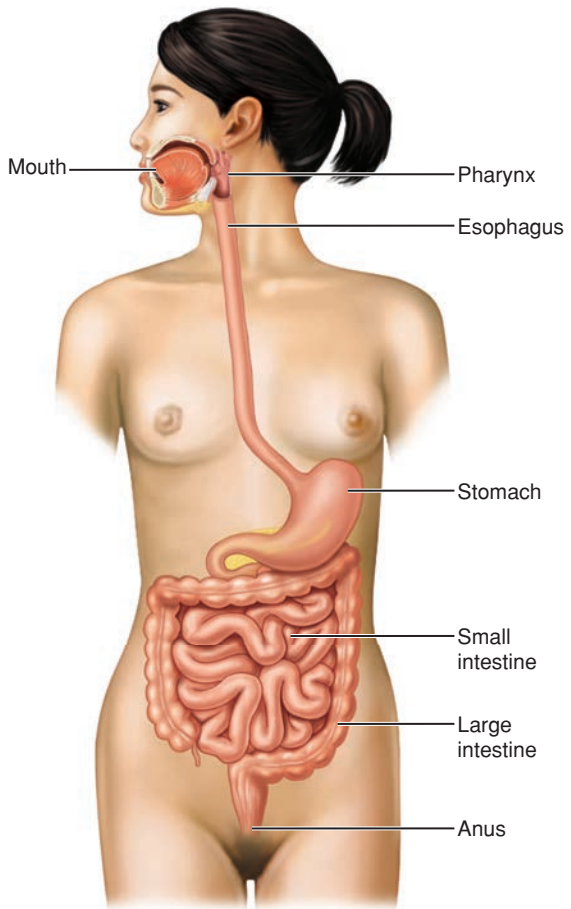

FIGURE 2-9 Organs of the digestive tract. Other organs and glands contribute to digestion, as described in Chapter 13.

extern.ir

- Respiratory system, which obtains the oxygen needed for metabolism and eliminates carbon dioxide, a byproduct of metabolism.
- Digestive system, which takes in, breaks down, and absorbs nutrients and eliminates undigested waste.
- Urinary system, which eliminates soluble waste and balances the volume and composition of body fluids
- The male and female reproductive systems concerned with production of offspring

Each of the body systems is discussed in Part II. However, bear in mind that the body functions as a whole; no system is independent of the others. They work together to maintain the body's state of internal stability, termed **homeostasis** (*ho-**me**-o-STA-sis*).

Terminology *Key Terms*

The terms listed below are emphasized in this chapter. Knowing them will help you organize and prioritize your learning. These boldface terms are also found, collectively, with all chapter key terms in the Glossary.

Cells to Organ Systems

adenosine triphosphate (ATP) *ah-DEN-o-sene tri-FOS-fate*	The energy compound of the cell that stores energy needed for cell activities
carbohydrates *kar-bo-HI-drates*	The category of organic compounds that includes sugars and starches
cell *sel*	The basic structural and functional unit of the living organism, a microscopic unit that combines with other cells to form tissues (root: cyt/o)
chromosome *KRO-mo-some*	A thread-like body in a cell's nucleus that contains genetic information
cytology *si-TOL-o-je*	Study of cells
cytoplasm *SI-to-plazm*	The fluid that fills a cell and holds the organelles
deoxyribonucleic acid (DNA) *de-ok-se-ri-bo-nu-KLE-ik*	The genetic compound of the cell, makes up the genes
enzyme *EN-zime*	An organic substance that speeds the rate of a metabolic reaction
gene *jene*	A hereditary unit composed of DNA and combined with other genes to form the chromosomes
glucose *GLU-kose*	A simple sugar that circulates in the blood, the main energy source for metabolism (roots: gluc/o, glyc/o)
histology *his-TOL-o-je*	Study of tissues
homeostasis *ho-me-o-STA-sis*	A steady state, a condition of internal stability and constancy
lipid *LIP-id*	A category of organic compounds that includes fats (root: lip/o)
membrane *MEM-brane*	A simple, very thin, and pliable sheet of tissue that might cover an organ, line a cavity, or separate structures
metabolism *meh-TAB-o-lizm*	The sum of all the physical and chemical reactions that occur within an organism
mitosis *mi-TO-sis*	Cell division
mucus *MU-kus*	A thick fluid secreted by cells in membranes and glands that lubricates and protects tissues (roots: muc/o, myx/o); the adjective is *mucous*

extern.ir

Terminology Key Terms (Continued)

nucleus *NU-kle-us*	The cell's control center; directs all cellular activities based on the information contained in its chromosomes (roots: nucle/o, kary/o)
organ *OR-gan*	A part of the body with a specific function, a component of a body system
organelle *OR-gah-nel*	A specialized structure in the cytoplasm of a cell
protein *PRO-tene*	A category of organic compounds that includes structural materials, enzymes, and some hormones
ribonucleic acid (RNA) *ri-bo-nu-KLE-ik*	An organic compound involved in the manufacture of proteins within cells
tissue *TISH-u*	A group of cells that acts together for a specific purpose (roots: hist/o, histi/o); types include epithelial tissue, connective tissue, muscle tissue, and nervous tissue

Word Parts Pertaining to Cells, Tissues, and Organs

See **TABLES 2-1** to **2-3**.

Table 2-1 Roots for Cells and Tissues

Root	Meaning	Example	Definition of Example
morph/o	form	polymorphous *pol-e-MOR-fus*	having many forms
cyt/o, -cyte	cell	cytologist *si-TOL-o-jist*	one who studies cells
nucle/o	nucleus	nuclear *NU-kle-ar*	pertaining to a nucleus
kary/o	nucleus	karyotype *KAR-e-o-tipe*	picture of a cell's chromosomes organized according to size **(FIG. 2-10)**
hist/o, histi/o	tissue	histocompatibility *his-to-kom-pat-ih-BIL-ih-te*	tissue similarity that permits transplantation
fibr/o	fiber	fibrosis *fi-BRO-sis*	abnormal formation of fibrous tissue
reticul/o	network	reticulum *reh-TIK-u-lum*	a network
aden/o	gland	adenoma *ad-eh-NO-mah*	tumor (-oma) of a gland
papill/o	nipple	papilla *pah-PIL-ah*	projection that resembles a nipple
myx/o	mucus	myxadenitis *miks-ad-eh-NI-tis*	inflammation (-itis) of a mucus-secreting gland
muc/o	mucus, mucous membrane	mucorrhea *mu-ko-RE-ah*	increased flow (-rhea) of mucus
somat/o, -some	body, small body	chromosome *KRO-mo-some*	small body that takes up color (dye) (chrom/o)

extern.ir

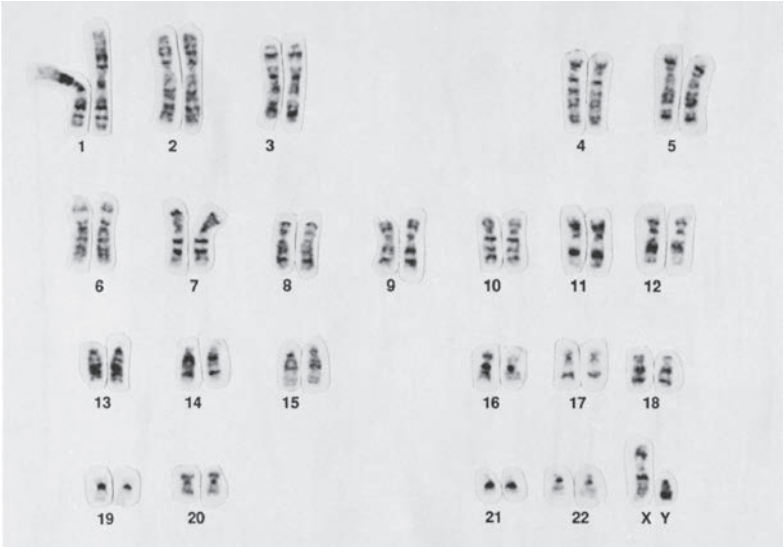

FIGURE 2-10 Human karyotype. The 46 chromosomes are in 23 pairs arranged according to size. The XY sex chromosomes, the 23rd pair at the lower right, indicate that the cell is from a male; a female cell has XX sex chromosomes.

Exercise 2-1

Complete the exercise. To check your answers go to Appendix 11.

Fill in the blanks. Use the phonetics to pronounce the words in the exercises.

1. Cytogenesis (*si-to-JEN-eh-sis*) is the formation (genesis) of cells .
2. A fibril (*FI-bril*) is a small _____ .
3. A histologist (*his-TOL-o-jist*) studies _____ .
4. A dimorphic (*di-MOR-fik*) organism has two _____ .
5. Karyomegaly (*kar-e-o-MEG-ah-le*) is enlargement (-megaly) of the _____ .
6. Nucleoplasm (*NU-kle-o-plazm*) is the substance that fills the _____ .
7. Adenitis (*ad-eh-NI-tis*) is inflammation (-itis) of a(n) _____ .
8. A papillary (*PAP-ih-lar-e*) structure resembles a(n) _____ .
9. A myxoma (*mik-SO-mah*) is a tumor of tissue that secretes _____ .
10. A reticulocyte (*reh-TIK-u-lo-site*) is a cell that contains a(n) _____ .
11. The term *mucosa* (*mu-KO-sah*) is used to describe a membrane that secretes _____ .
12. Somatotropin (*so-mah-to-TRO-pin*), also called growth hormone, has a general stimulating effect on the _____ .

Use the suffix -logy to build a word with each of the following meanings.

13. The study of form _____
14. The study of cells _____
15. The study of tissues _____

extern.ir

Table 2-2 Roots for Cell Activity

Root	Meaning	Example	Definition of Example
blast/o, -blast	immature cell, productive cell, embryonic cell	histioblast *HIS-te-o-blast*	a tissue-forming cell
gen	origin, formation	karyogenesis *kar-e-o-JEN-eh-sis*	formation of a nucleus
phag/o	eat, ingest	autophagy *aw-TOF-ah-je*	self (auto)-destruction of a cell's organelles
phil	attract, absorb	basophilic *ba-so-FIL-ik*	attracting basic stain
plas	formation, molding, development	hyperplasia *hi-per-PLA-ze-ah*	overdevelopment of an organ or tissue
trop	act on, affect	chronotropic *kron-o-TROP-ik*	affecting rate or timing (chron/o)
troph/o	feeding, growth, nourishment	atrophy *AT-ro-fe*	tissue wasting

The roots in **TABLE 2-2** are often combined with a simple noun suffix (*-in*, *-y*, or *-ia*) or an adjective suffix (*-ic*) and used as word endings. Such combined forms that routinely appear as word endings are simply described and used as suffixes in this book. Examples from the above list are: *-phagy*, *-philic*, *-plasia*, *-tropic*, and *-trophy*.

Exercise 2-2

Complete the exercise. To check your answers go to Appendix 11.

Match the following terms in the following sets, and write the appropriate letter to the left of each number.

____ 1. phagocyte (*FAG-o-site*)	a. overdevelopment of tissue
____ 2. histogenesis (*his-to-JEN-eh-sis*)	b. study of heredity
____ 3. leukoblast (*LU-ko-blast*)	c. formation of tissue
____ 4. genetics (*jeh-NET-iks*)	d. cell that ingests waste
____ 5. hypertrophy (*hi-PER-tro-fe*)	e. immature white blood cell

____ 6. neoplasia (*ne-o-PLA-ze-ah*)	a. attracting color
____ 7. gonadotropin (*gon-ah-do-TRO-pin*)	b. pertaining to the body
____ 8. aplasia (*ah-PLA-ze-ah*)	c. substance that acts on the sex glands
____ 9. somatic (*so-MAT-ik*)	d. new formation of tissue
____ 10. chromophilic (*kro-mo-FIL-ik*)	e. lack of development

Identify and define the root in the following words.

	Root	Meaning of Root
11. genesis (*JEN-eh-sis*)	gen	origin, formation
12. esophagus (*eh-SOF-ah-gus*)	_____	_____
13. normoblast (*NOR-mo-blast*)	_____	_____
14. aplastic (*ah-PLAS-tik*)	_____	_____
15. dystrophy (*DIS-tro-fe*)	_____	_____

extern.ir

Table 2-3 Suffixes and Roots for Body Chemistry

Word Part	Meaning	Example	Definition of Example
Suffixes			
-ase	enzyme	lipase *LI-pase*	enzyme that digests fat (lipid)
-ose	sugar	lactose *LAK-tose*	milk sugar
Roots			
hydr/o	water, fluid	hydration *hi-DRA-shun*	addition of water, relative amount of water present
gluc/o	glucose	glucogenesis *glu-ko-JEN-eh-sis*	production of glucose
glyc/o	sugar, glucose	normoglycemia *nor-mo-gli-SE-me-ah*	normal blood sugar level
sacchar/o	sugar	polysaccharide *pol-e-SAK-ah-ride*	compound containing many simple sugars
amyl/o	starch	amyloid *AM-ih-loyd*	resembling starch
lip/o	lipid, fat	lipophilic *lip-o-FIL-ik*	attracting or absorbing lipids
adip/o	fat	adiposuria *ad-ih-po-SUR-e-ah*	presence of fat in the urine (ur/o)
steat/o	fatty	steatorrhea *ste-ah-to-RE-ah*	discharge (-rhea) of fatty stools
prote/o	protein	protease *PRO-te-ase*	enzyme that digests protein

Exercise 2-3

Complete the exercise. To check your answers go to Appendix 11.

Fill in the blanks.

1. A disaccharide (*di-SAK-ah-ride*) is a compound that contains two sugars.
2. The ending *-ose* indicates that fructose is a(n) _____.
3. Hydrophobia (*hi-dro-FO-be-ah*) is an aversion (-phobia) to _____.
4. Amylase (*AM-ih-lase*) is an enzyme that digests _____.
5. Liposuction (*LIP-o-suk-shun*) is the surgical removal of _____.
6. A glucocorticoid (*glu-ko-KOR-tih-koyd*) is a hormone that controls the metabolism of _____.
7. An adipocyte (*AD-ih-po-site*) is a cell that stores _____.

Identify and define the root in the following words.

	Root	Meaning of Root
8. asteatosis (*as-te-ah-TO-sis*)	_____	_____
9. lipoma (*li-PO-mah*)	_____	_____
10. hyperglycemia (*hi-per-gli-SE-me-ah*)	_____	_____
11. glucolytic (*glu-ko-LIT-ik*)	_____	_____

extern.ir

Terminology *Enrichment Terms*

The terms listed below expand on the key terms to increase your knowledge of this chapter topic.

amino acids *ah-ME-no*	The nitrogen-containing compounds that make up proteins
anabolism *ah-NAB-o-lizm*	The type of metabolism in which body substances are made; the building phase of metabolism
catabolism *kah-TAB-o-lizm*	The type of metabolism in which substances are broken down for energy and simple compounds
collagen *KOL-ah-jen*	A fibrous protein found in connective tissue
cortex *KOR-tex*	The outer region of an organ
glycogen *GLI-ko-jen*	A complex sugar compound stored in liver and muscles and broken down into glucose when needed for energy
interstitial *in-ter-STISH-al*	Between parts, such as the spaces between cells in a tissue
medulla *meh-DUL-lah*	The inner region of an organ, marrow (root: medull/o)
parenchyma *par-EN-kih-mah*	The functional tissue of an organ
parietal *pah-RI-eh-tal*	Pertaining to a wall, describes a membrane that lines a body cavity
soma *SO-mah*	The body
stem cell	An immature cell that has the capacity to develop into any of a variety of different cell types, a precursor cell
visceral *VIS-er-al*	Pertaining to the internal organs; describes a membrane on the surface of an organ

The Body as a Whole

All healthcare professionals must be thoroughly familiar with the terms used to describe body locations and positions. Radiologic technologists, for example, must be able to position a person and direct x-rays to obtain suitable images for diagnosis, as noted in **BOX 2-3**.

HEALTH PROFESSIONS — BOX 2-3
Radiologic Technologist

Radiologic technologists help in the diagnosis of medical disorders by taking x-ray images (radiographs) of the body. They also use CT scans and other imaging technology to perform examinations on patients to aid in diagnosis. Following institutional safety patient mobilization procedures; they must prepare patients for radiologic examinations, place patients in appropriate positions; and then adjust equipment to the correct angles, heights, and settings for taking the x-ray or other diagnostic image. They must position the image receptors correctly and, after exposure, remove and process the images. They are also required to keep patient records and maintain equipment. Radiologic technologists must minimize radiation hazards by using protective equipment for themselves and patients and by delivering the minimum possible amount of radiation. They wear badges to monitor radiation levels and keep records of their exposure.

Radiologic technologists may specialize in a specific imaging technique such as bone densitometry, cardiovascular-interventional radiography, computed tomography, mammography, magnetic resonance imaging, nuclear medicine,

(continued)

extern.ir

HEALTH PROFESSIONS *(Continued)*
Radiologic Technologist

BOX 2-3

and quality management. Some of these will be described in later chapters.

The majority of radiologic technologists work in hospitals, but they may also be employed in physicians' offices, diagnostic imaging centers (e.g., doing mammograms), and outpatient care centers. Radiologic technologists must possess a minimum of an associate's degree to qualify for professional certification. A higher degree is necessary for a supervisory or teaching position. The Joint Review Committee on Education in Radiologic Technology accredits most of the education programs. The American Registry of Radiologic Technologists (ARRT) offers a national certification examination in radiography as well as in other imaging technologies (CT, MRI, nuclear medicine, etc.). ARRT certification is required for employment as a radiologic technologist in most U.S. states. Job opportunities in this field are currently good. The American Society of Radiologic Technologists has information on this career at asrt.org.

DIRECTIONAL TERMS

In describing the location or direction of a given point in the body, it is always assumed that the subject is in the **anatomic position**, that is, upright, with face front, arms at the sides with palms forward, and feet parallel. In this stance, the terms illustrated in FIGURE 2-11 and listed in BOX 2-4 are used to designate relative position.

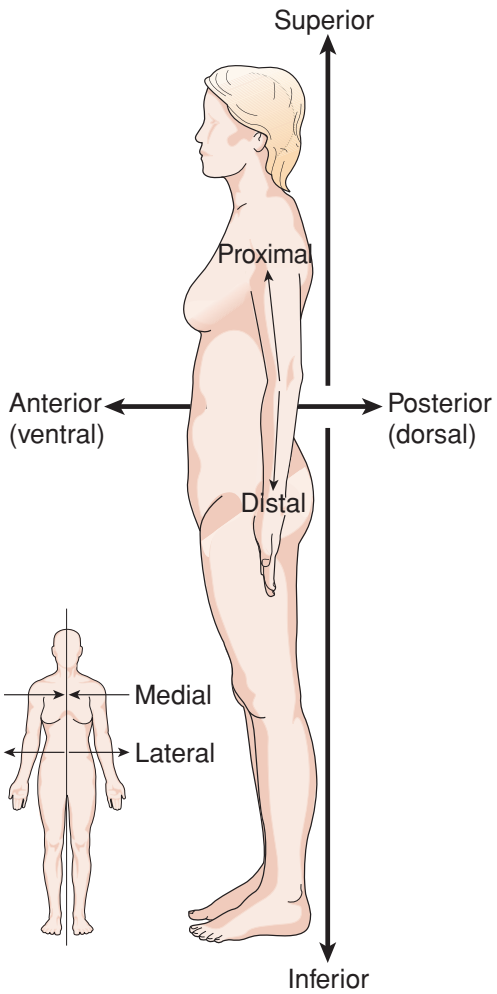

FIGURE 2-11 Directional terms.

extern.ir

FOR YOUR REFERENCE
Anatomic Directions

BOX 2-4

Term	Definition
anterior (ventral)	toward or at the front (belly) of the body
posterior (dorsal)	toward or at the back (dorsum) of the body
medial	toward the midline of the body
lateral	toward the side of the body
proximal	nearer to the point of attachment or to a given reference point
distal	farther from the point of attachment or from a given reference point
superior	above, in a higher position
inferior	below, in a lower position
cranial (cephalad)	toward the head
caudal	toward the lower end of the spine (Latin *cauda* means "tail"); in humans, in an inferior direction
superficial (external)	closer to the surface of the body
deep (internal)	closer to the center of the body

FIGURE 2-12 illustrates planes of section, that is, directions in which the body can be cut. A **frontal plane**, also called a coronal plane, is made at right angles to the midline and divides the body into anterior and posterior parts. A **sagittal** (*SAJ-ih-tal*) **plane** passes from front to back and divides the body into right and left portions. If the plane passes through the midline, it is a mid-sagittal or medial plane. A **transverse (horizontal) plane** passes horizontally, dividing the body into superior and inferior parts.

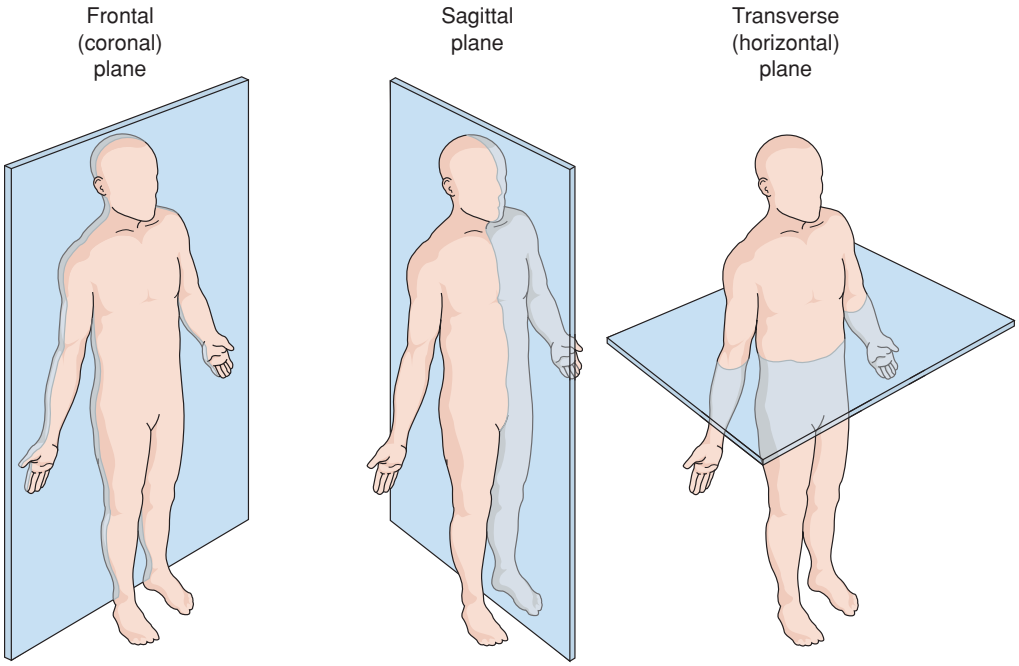

FIGURE 2-12 Planes of division.

extern.ir

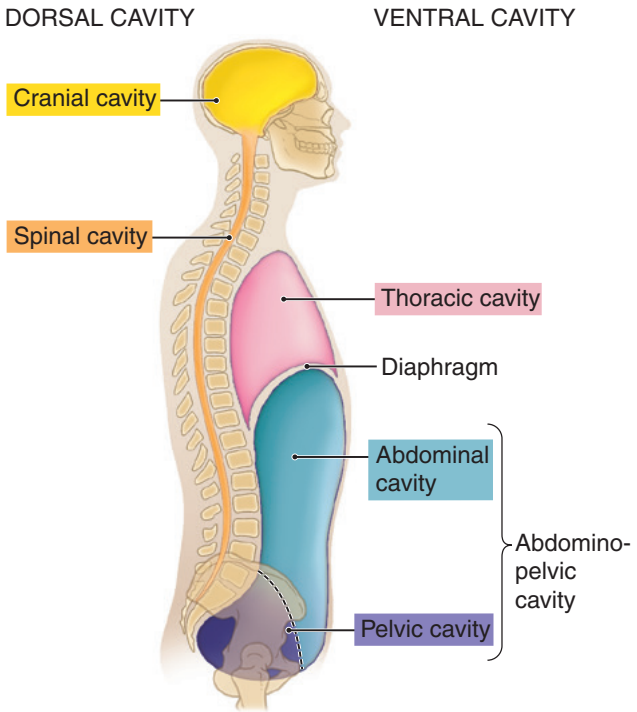

FIGURE 2-13 Body cavities, lateral view. Shown are the dorsal and ventral cavities with their subdivisions.

BODY CAVITIES

Internal organs are located within dorsal and ventral cavities (FIG. 2-13). The dorsal cavity contains the brain in the **cranial cavity** and the spinal cord in the **spinal cavity** (**canal**). The uppermost ventral space, the **thoracic cavity**, is separated from the **abdominal cavity** by the **diaphragm**, a muscle used in breathing. There is no anatomic separation between the abdominal cavity and the **pelvic cavity**, which together make up the **abdominopelvic cavity**. The large membrane that lines the abdominopelvic cavity and covers the organs within it is the **peritoneum** (*per-ih-to-NE-um*).

ABDOMINAL REGIONS

For orientation, the abdomen can be divided by imaginary lines into nine regions—three medial regions and six lateral regions (FIG. 2-14). The sections down the midline are the:

- epigastric (*ep-ih-GAS-trik*) region, located above the stomach
- umbilical (*um-BIL-ih-kal*) region, named for the umbilicus, or navel
- hypogastric (*hi-po-GAS-trik*) region, located below the stomach

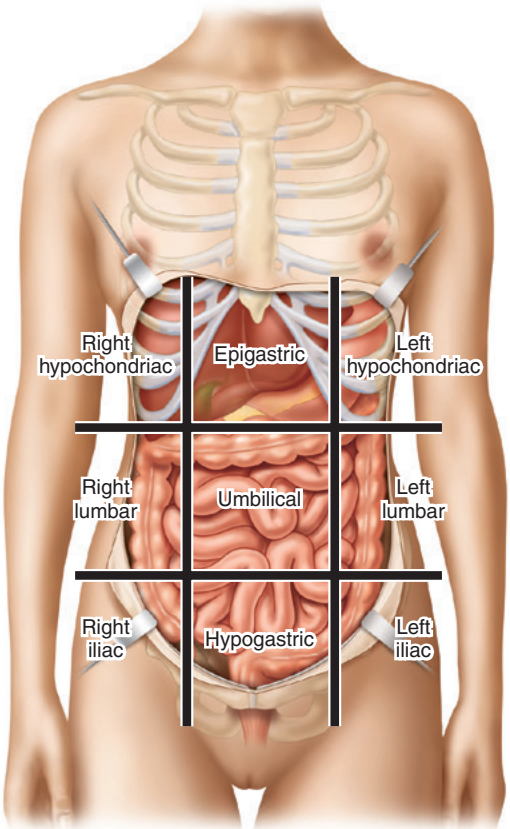

FIGURE 2-14 The nine regions of the abdomen.

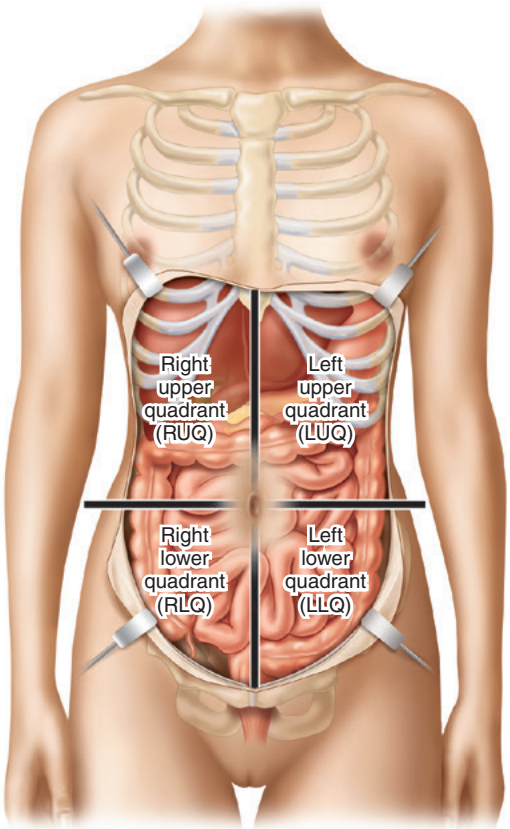

FIGURE 2-15 Quadrants of the abdomen. Some organs within the quadrants are indicated.

extern.ir

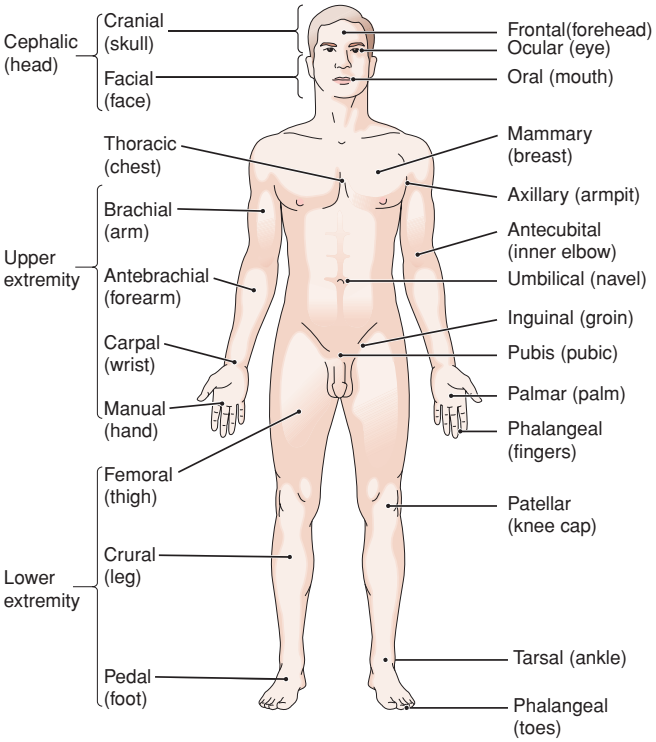

FIGURE 2-16 Common terms for body regions, anterior view. Anatomic adjectives for regions are in parentheses.

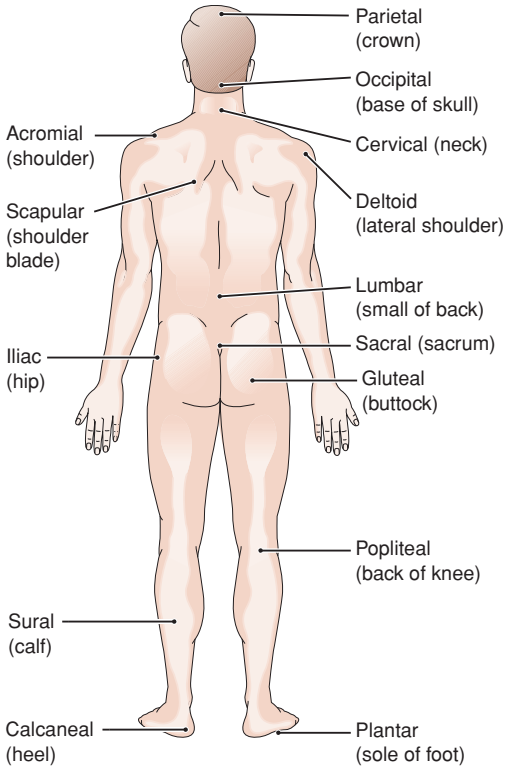

FIGURE 2-17 Common terms for body regions, posterior view. Anatomic adjectives for regions are in parentheses.

The lateral regions have the same name on the left and right sides. They are the:

- hypochondriac (*hi-po-KON-dre-ak*) regions, right and left, named for their positions near the ribs, specifically near the cartilages (root: chondr/o) of the ribs
- lumbar (*LUM-bar*) regions, right and left, which are located near the small of the back (lumbar region of the spine)
- iliac (*IL-e-ak*) regions, right and left, named for the upper bone of the hip, the ilium; also called the inguinal (*ING-gwih-nal*) regions, with reference to the groin

More simply, but less precisely, the abdomen can be divided into four sections by a single vertical line and a single horizontal line that intersect at the umbilicus (navel) **(FIG. 2-15)**. The sections are the right upper quadrant (RUQ), left upper quadrant (LUQ), right lower quadrant (RLQ), and left lower quadrant (LLQ).

Additional terms for body regions are shown in **FIGURES 2-16** and **2-17**. You may need to refer to these illustrations as you work through the book.

POSITIONS

In addition to the anatomic position, there are other standard positions in which the body is placed for special purposes, such as examination, tests, surgery, or fluid drainage. The most common of these positions and some of their uses are described in **BOX 2-5**.

FOR YOUR REFERENCE

BOX 2-5

Body Positions

Position	Description
anatomic position *an-ah-TOM-ik*	standing erect, facing forward, arms at sides, palms forward, legs parallel, toes pointed forward; used for descriptions and studies of the body
decubitus position *de-KU-bih-tus*	lying down, specifically according to the part of the body resting on a flat surface, as in left or right lateral decubitus, or dorsal or ventral decubitus
dorsal recumbent position *re-KUM-bent*	on back, with legs bent and separated, feet flat; used for obstetrics and gynecology

(continued)

extern.ir

FOR YOUR REFERENCE *(Continued)*

BOX 2-5

Body Positions

Position	Description
Fowler position	on back, head of bed raised about 18 inches, knees elevated; used to ease breathing and for drainage
jackknife position *JAK-nife*	on back with shoulders elevated, legs flexed and thighs at right angles to the abdomen; used to introduce a tube into the urethra
knee–chest position	on knees, head and upper chest on table, arms crossed above head; used in gynecology and obstetrics and for flushing the intestine
lateral recumbent position	on the side with one leg flexed, arm position may vary
lithotomy position *lih-THOT-o-me*	on back, legs flexed on abdomen, thighs apart; used for gynecologic and urologic surgery
prone	lying face down
prone jackknife position *JAK-nife*	on abdomen with bed bent so that the body is in a V with the head and feet below the hips. Used for anorectal surgery
Sims position	on left side, right leg drawn up high and forward, left arm along back, chest forward resting on bed; used for kidney and uterine surgery, colon examination, and enemas
supine[a] *SU-pine*	lying face up
Trendelenburg position *tren-DEL-en-berg*	on back with head lowered by tilting bed back at 45-degree angle; used for pelvic and abdominal surgery, treatment of shock

[a]To remember the difference between prone and supine, look for the word *up* in supine.

Terminology *Key Terms*

The terms listed below are emphasized in this chapter. Knowing them will help you organize and prioritize your learning. These boldface terms are also found, collectively, with all chapter key terms in the Glossary.

The Body as a Whole

abdominal cavity *ab-DOM-ih-nal*	The large ventral cavity below the diaphragm and above the pelvic cavity
abdominopelvic cavity *ab-dom-ih-no-PEL-vik*	The large ventral cavity between the diaphragm and pelvis that includes the abdominal and pelvic cavities
anatomic position *an-ah-TOM-ik*	Standard position for anatomic studies, in which the body is erect and facing forward, the arms are at the sides with palms forward, and the feet are parallel
cranial cavity *KRA-ne-al*	The dorsal cavity that contains the brain

extern.ir

Terminology Key Terms (Continued)

diaphragm *DI-ah-fram*	The muscle that separates the thoracic from the abdominal cavity
frontal (coronal) plane *FRUHN-tal*	Plane of section that separates the body into anterior (front) and posterior (back) portions
pelvic cavity *PEL-vik*	The ventral cavity that is below the abdominal cavity
peritoneum *per-ih-to-NE-um*	The large serous membrane that lines the abdominopelvic cavity and covers the organs within it
sagittal plane *SAJ-ih-tal*	Plane that divides the body into right and left portions
spinal cavity (canal) *SPI-nal*	Dorsal cavity that contains the spinal cord
thoracic cavity *tho-RAS-ik*	The ventral cavity above the diaphragm, the chest cavity
transverse (horizontal) plane *trans-VERS*	Plane that divides the body into superior (upper) and inferior (lower) portions

Word Parts Pertaining to Body Structure

TABLES 2-4 to **2-6** provide word roots and prefixes pertaining to body structure.

Table 2-4 Roots for Regions of the Head and Trunk

Root	Meaning	Example	Definition of Example
cephal/o	head	megacephaly *meg-ah-SEF-a-le*	abnormal largeness of the head
cervic/o	neck	cervicofacial *ser-vih-ko-FA-shal*	pertaining to the neck and face
thorac/o	chest, thorax	thoracotomy *tho-rah-KOT-o-me*	incision (-tomy) into the chest
abdomin/o	abdomen	intra-abdominal *in-trah-ab-DOM-ih-nal*	within the abdomen
celi/o	abdomen	celiocentesis *se-le-o-sen-TE-sis*	surgical puncture (centesis) of the abdomen
lapar/o	abdominal wall	laparoscope *LAP-ah-ro-skope*	instrument (-scope) for viewing the peritoneal cavity through the abdominal wall
lumb/o	lumbar region, lower back	thoracolumbar *tho-rak-o-LUM-bar*	pertaining to the chest and lumbar region
periton, peritone/o	peritoneum	peritoneal *per-ih-to-NE-al*	pertaining to the peritoneum

extern.ir

Exercise 2-4

Complete the exercise. To check your answers go to Appendix 11.

Write the adjective for each of the following definitions. The correct suffix is given in parentheses.

1. Pertaining to (-ic) the chest thoracic
2. Pertaining to (-ic) the head _____
3. Pertaining to (-al) the neck _____
4. Pertaining to (-al) the abdomen _____
5. Pertaining to (-ar) the lower back _____

Fill in the Blanks

6. Peritonitis (*per-ih-to-NI-tis*) is inflammation (-itis) of the _____ .
7. The adjective celiac (*SE-le-ak*) pertains to the _____ .
8. A laparotomy (*lap-ah-ROT-o-me*) is an incision through the _____ .

Table 2-5 Roots for the Extremities

Root	Meaning	Example	Definition of Example
acro	extremity, end	acrocyanosis *ak-ro-si-ah-NO-sis*	bluish discoloration of the extremities
brachi/o	arm	antebrachium *an-te-BRA-ke-um*	forearm
dactyl/o	finger, toe	polydactyly *pol-e-DAK-til-e*	having more than the normal number of fingers or toes
ped/o	foot	pedometer *pe-DOM-eh-ter*	instrument that measures footsteps
pod/o	foot	podiatric *po-de-AT-rik*	pertaining to study and treatment of the foot

Exercise 2-5

Complete the exercise. To check your answers go to Appendix 11.

Fill in the blanks.

1. Acrokinesia (*ak-ro-ki-NE-se-ah*) is excess motion (-kinesia) of the _____ .
2. Animals that brachiate (*BRA-ke-ate*), such as monkeys, swing from place to place using their _____ .
3. A dactylospasm (*DAK-til-o-spazm*) is a spasm (cramp) of a(n) _____ .
4. The term brachiocephalic (*bra-ke-o-seh-FAL-ik*) refers to the _____ .
5. Sinistropedal (*sih-nis-tro-PE-dal*) refers to the use of the left _____ .

extern.ir

Table 2-6 Prefixes for Position and Direction

Prefix	Meaning	Example	Definition of Example
circum-	around	circumoral *ser-kum-OR-al*	around the mouth
peri-	around	periorbital *per-e-OR-bit-al*	around the orbit (eye socket)
intra-	in, within	intravascular *in-trah-VAS-ku-lar*	within a vessel (vascul/o)
epi-	on, over	epithelial *ep-ih-THE-le-al*	referring to epithelium, tissue that covers surfaces
extra-	outside	extrathoracic *eks-trah-tho-RAS-ik*	outside the thorax
infra-[a]	below	infrascapular *in-frah-SKAP-u-lar*	below the scapula (shoulder blade)
sub-[a]	below, under	sublingual *sub-LING-gwal*	under the tongue (lingu/o)
inter-	between	intercostal *in-ter-KOS-tal*	between the ribs (cost/o)
juxta-	near, beside	juxtaposition *juks-tah-po-ZIH-shun*	a location near or beside another structure
para-	near, beside	parasagittal *par-ah-SAJ-ih-tal*	near or beside a sagittal plane
retro-	behind, backward	retrouterine *reh-tro-U-ter-in*	behind the uterus
supra-	above	suprapatellar *su-prah-pah-TEL-ar*	above the patella (kneecap)

[a]Also indicates degree.

Exercise 2-6

Complete the exercise. To check your answers go to Appendix 11.

Synonyms

Write a word that means the same as each of the following.

1. perioral circumoral
2. infrascapular _____
3. perivascular _____
4. subcostal _____
5. circumorbital _____

Opposites

Write a word that means the opposite of each of the following.

6. suprapatellar infrapatellar
7. extracellular _____
8. subscapular _____
9. intrathoracic _____

(continued)

extern.ir

Exercise 2-6 *(Continued)*

Define the following words.

10. paranasal (*par-ah-NA-zal*) _____
11. retroperitoneal (*reh-tro-per-ih-to-NE-al*) _____
12. supraabdominal (*su-prah-ab-DOM-ih-nal*) _____
13. intrauterine (*in-trah-U-ter-in*) _____

Refer to FIGURES 2-16 and 2-17 to define the following terms.

14. periumbilical (*per-e-um-BIL-ih-kal*) _____
15. intergluteal (*in-ter-GLU-te-al*) _____
16. epitarsal (*ep-ih-TAR-sal*) _____
17. intraocular (*in-trah-OK-u-lar*) _____
18. parasacral (*par-ah-SA-kral*) _____

Terminology *Enrichment Terms*

The terms listed below expand on the key terms to increase your knowledge of this chapter topic.

The Body as a Whole

digit *DIJ-it*	A finger or toe (adjective: digital)
epigastrium *ep-ih-GAS-tre-um*	The epigastric region
fundus *FUN-dus*	The base or body of a hollow organ, the area of an organ farthest from its opening
hypochondrium *hi-po-KON-dre-um*	The hypochondriac region (left or right)
lumen *LU-men*	The central opening within a tube or hollow organ
meatus *me-A-tus*	A passage or opening
orifice *OR-ih-fis*	The opening of a cavity
os	Mouth, any body opening
septum *SEP-tum*	A wall dividing two cavities
sinus *SI-nus*	A cavity, as within a bone
sphincter *SFINK-ter*	A circular muscle that regulates an opening

extern.ir

Terminology *Abbreviations*

The abbreviations listed below are emphasized in this chapter. These are also found, collectively, with all chapter abbreviations in Appendix 2.

LLQ	Left lower quadrant	**RLQ**	Right lower quadrant
LUQ	Left upper quadrant	**RUQ**	Right upper quadrant

Case Study Revisited

Zachary's Return to Class Schedule
Following his appointment, Zachary decided to accept his physician's advice. He started preparing at least two meals a day at home and often boxed a lunch to eat during the day on campus. The more nutritious meals provided him greater energy; he no longer felt sluggish. He visited the university gym to work out at least two to three times a week for 20 minutes and hoped to increase that time when his schedule permitted. He realized how important exercise is to feeling energized, upbeat, and more confident in his everyday activities. By providing himself with healthy meals and routine exercise, Zachary was able to sleep better. He also made sure he had at least 8 hours of sleep each night. Finally, he recognized that a little knowledge is a dangerous thing and that it is not smart to try and diagnose oneself.

extern.ir

CHAPTER 2

Review

This review tests your understanding of the content introduced in this chapter. Follow the instructions for each exercise and check your answers in Appendix 11.

LABELING EXERCISE

DIRECTIONAL TERMS

Write the name of each numbered part on the corresponding line of the answer sheet.

Anterior (ventral)	Medial
Distal	Posterior (dorsal)
Inferior (caudal)	Proximal
Lateral	Superior (cranial)

1. _____
2. _____
3. _____
4. _____
5. _____
6. _____
7. _____
8. _____

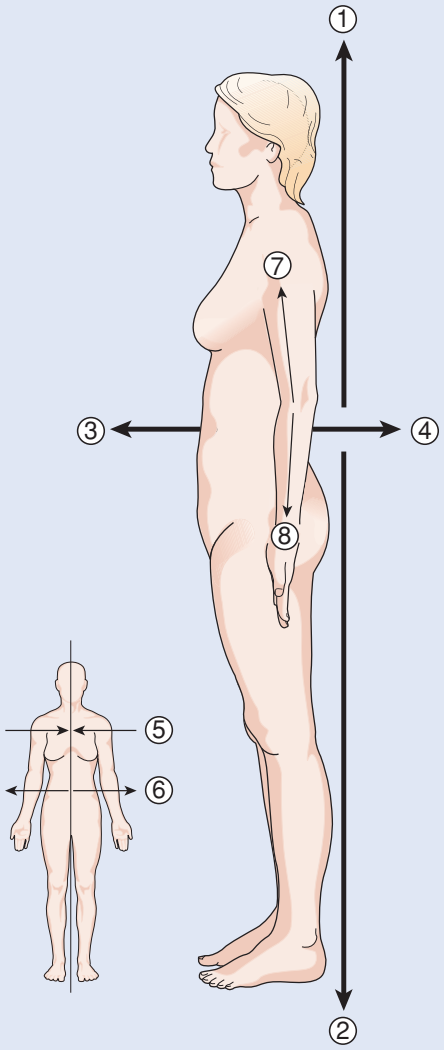

extern.ir

PLANES OF DIVISION

Write the name of each numbered part on the corresponding line of the answer sheet.

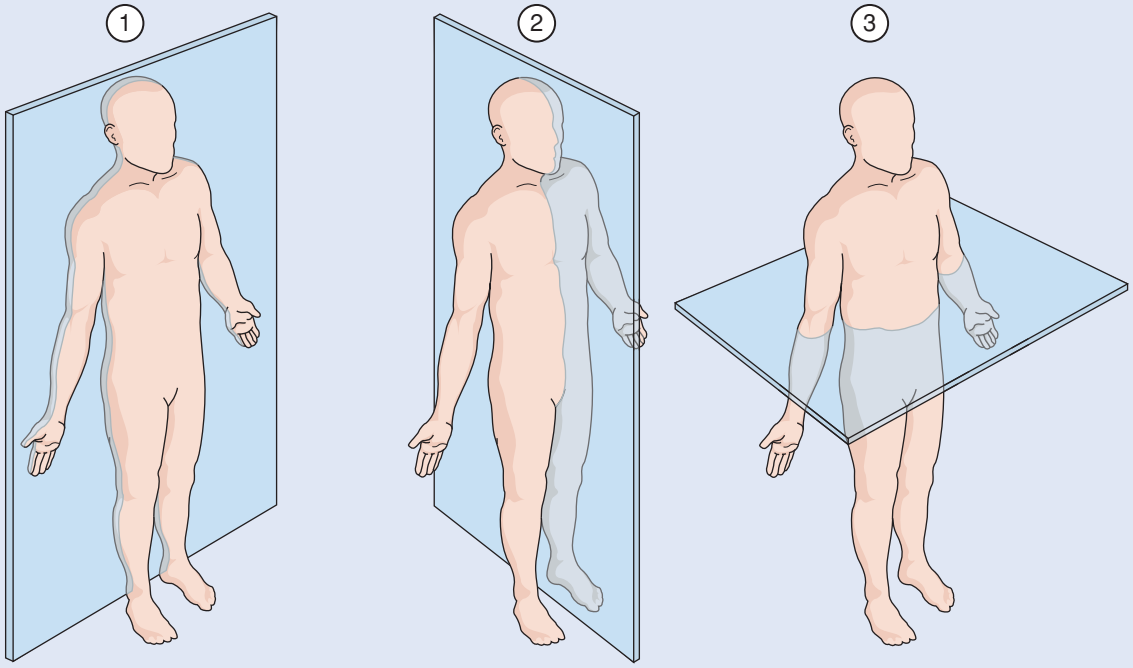

Frontal (coronal) plane
Sagittal plane
Transverse (horizontal) plane

1. _____
2. _____
3. _____

BODY CAVITIES, LATERAL VIEW

Write the name of each numbered part on the corresponding line of the answer sheet.

Abdominal cavity
Abdominopelvic cavity
Cranial cavity
Diaphragm
Dorsal cavity
Pelvic cavity
Spinal cavity (canal)
Thoracic cavity
Ventral cavity

1. _____
2. _____
3. _____
4. _____
5. _____
6. _____
7. _____
8. _____
9. _____

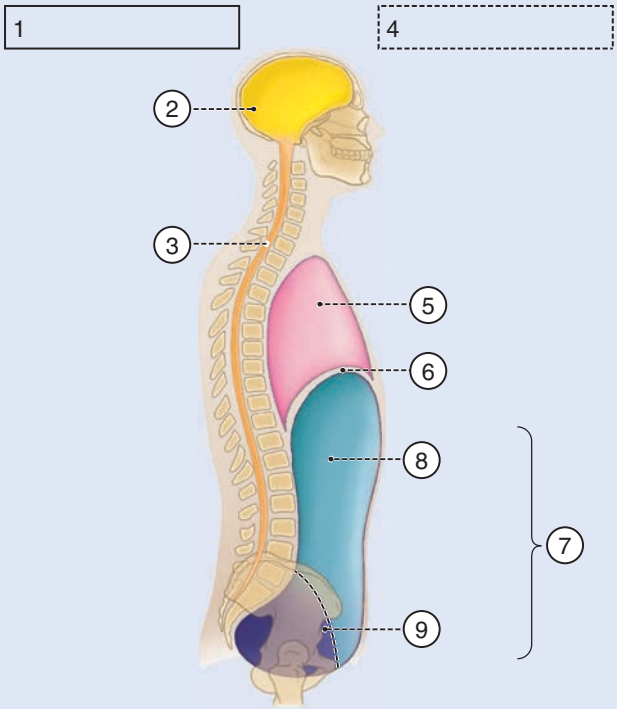

extern.ir

THE NINE REGIONS OF THE ABDOMEN

Write the name of each numbered part on the corresponding line of the answer sheet.

Epigastric region
Hypogastric region
Left hypochondriac region
Left iliac (inguinal) region
Left lumbar region
Right hypochondriac region
Right iliac (inguinal) region
Right lumbar region
Umbilical region

1. _____
2. _____
3. _____
4. _____
5. _____
6. _____
7. _____
8. _____
9. _____

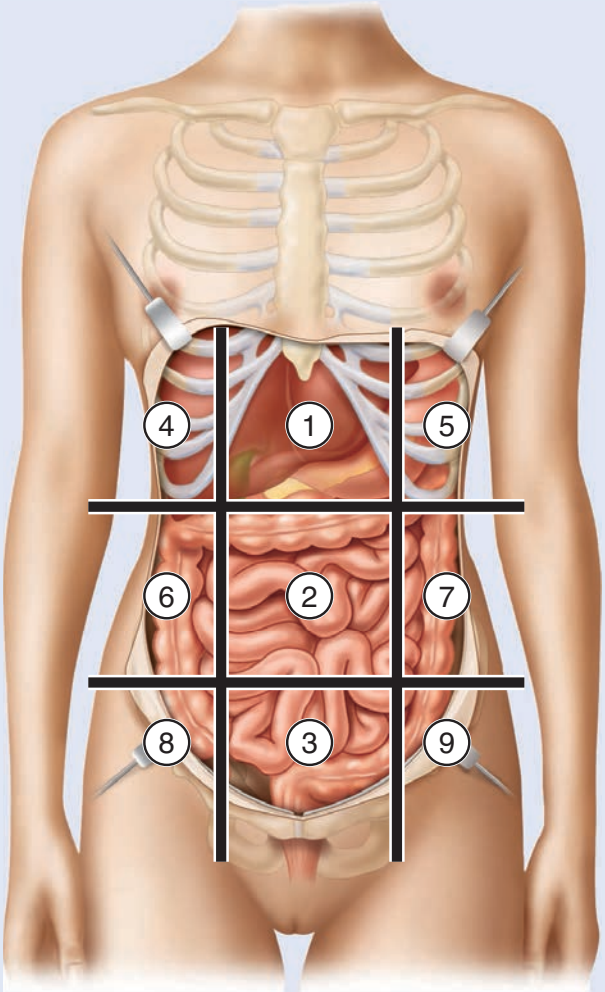

extern.ir

TERMINOLOGY

MATCHING

Match the following terms, and write the appropriate letter to the left of each number.

____ 1. ATP	a. control region of the cell
____ 2. DNA	b. material that holds the cellular organelles
____ 3. nucleoplasm	c. energy compound of the cells
____ 4. nucleus	d. genetic material
____ 5. cytoplasm	e. material that fills the nucleus
____ 6. blastocyte	a. immature cell
____ 7. ribosomes	b. organelles that produce ATP
____ 8. mitochondria	c. organelles that contain RNA
____ 9. mitosis	d. small cellular body containing digestive enzymes
____ 10. lysosome	e. cell division
____ 11. reticular	a. resembling a gland
____ 12. adenoid	b. fibrous tumor
____ 13. fibroma	c. cell with a very large nucleus
____ 14. megakaryocyte	d. pertaining to a network
____ 15. chromosome	e. structure that contains genes
____ 16. autotroph	a. resembling a nipple
____ 17. papilliform	b. having no specific form
____ 18. amorphous	c. wasting of tissue
____ 19. atrophy	d. pertaining to the body
____ 20. somatic	e. organism that can manufacture its own food
____ 21. adiposuria	a. presence of fat in the urine
____ 22. proteolytic	b. presence of glucose in the urine
____ 23. glucosuria	c. treatment using water
____ 24. polysaccharide	d. compound composed of many simple sugars
____ 25. hydrotherapy	e. destroying or dissolving protein
____ 26. macropodia	a. circular cut
____ 27. subdermal	b. excessive size of the feet
____ 28. macrocephaly	c. beneath the skin
____ 29. celiotomy	d. abnormal largeness of the head
____ 30. circumcision	e. incision of the abdomen

Enrichment Terms

____ 31. amino acid	a. pertaining to the internal organs
____ 32. collagen	b. breakdown phase of metabolism
____ 33. visceral	c. fibrous protein in connective tissue
____ 34. cortex	d. outer region of an organ
____ 35. catabolism	e. building block of protein

extern.ir

____ 36. fundus	a. passage or opening
____ 37. meatus	b. circular muscle that regulates an opening
____ 38. lumen	c. central opening of a tube
____ 39. sphincter	d. base of a hollow organ
____ 40. septum	e. dividing wall

FILL IN THE BLANKS

Complete the sentence with the correct term(s).

41. The study of tissues is called _____.
42. The four basic tissue types are _____.
43. All the activities of a cell make up its _____.
44. The systems involved in circulation are the cardiovascular system and the _____.
45. The simple sugar that is the main energy source for metabolism is _____.
46. A thick cellular secretion that lubricates and protects tissues is called _____.
47. An organic compound that speeds the rate of metabolic reactions is a(n) _____.
48. The term dehydration refers to a loss or deficiency of _____.
49. The study of form and structure is called _____.

ADJECTIVES

Name the body part referred to in the following adjectives.

50. celiac (*SE-le-ak*)_____
51. phalangeal (*fa-LAN-ge-al*)_____
52. occipital (*ok-SIP-ih-tal*) _____
53. carpal (*KAR-pal*) _____
54. cervical (*SER-vih-kal*) _____
55. brachial (*BRA-ke-al*) _____

DEFINITIONS

Write words for the following definitions.

56. laparoscope (*LAP-ah-ro-skope*) _____
57. suprapubic (*su-prah-PU-bic*) _____
58. infraumbilical (*in-fra-um-BIL-ih-kal*)_____
59. sublingual (*sub-LING-wal*) _____
60. retroperitoneal (*ret-ro-per-ih-to-NE-al*) _____
61. bipedal (*BIP-eh-dal*) _____

SYNONYMS

Write a word that means the same as each of the following.

62. posterior_____
63. circumocular _____
64. submammary_____
65. ventral _____

extern.ir

OPPOSITES

Write a word that means the opposite of each of the following.

66. microcephaly _____
67. deep _____
68. proximal _____
69. subscapular _____
70. extracellular _____
71. superior _____

ELIMINATIONS

In each of the sets below, underline the word that does not fit in with the rest and explain the reason for your choice.

72. umbilical region — hypochondriac region — epigastric region — cervical region — iliac region

_____

73. jackknife — supine — transverse— decubitus — prone

_____

74. thoracic cavity — spinal cavity — pelvic cavity — abdominal cavity — abdominopelvic cavity

_____

TRUE–FALSE

Examine the following statements. If the statement is true, write T in the first blank If the statement is false, write F in the first blank and correct the statement by replacing the underlined word in the second blank.

	True or False	Correct Answer
75. A megakaryocyte is a cell with a large <u>nucleus</u>.	T	
76. An adipocyte is a cell that stores <u>glucose</u>.	F	fat
77. A whip-like extension of a cell is a <u>flagellum</u>.		
78. The cranial and spinal cavities are the <u>ventral</u> body cavities.		
79. A <u>midsagittal plane</u> divides the body into equal right and left parts.		
80. The wrist is <u>proximal</u> to the elbow.		
81. A <u>transverse plane</u> divides the body into anterior and posterior parts.		
82. The hypogastric region is <u>inferior</u> to the umbilical region.		
83. The right hypochondriac region is in the <u>RUQ</u>.		

extern.ir

WORD BUILDING

Write a word for each of the following definitions using the word parts provided. Each word part can be used more than once.

-oid	amyl/o	muc/o	aden/o	-ase	lip/o	leuk/o	histi/o	blast

84. Like or resembling a gland adenoid
85. Immature white blood cell _____
86. Enzyme that digests fat _____
87. Resembling mucus _____
88. Cell that gives rise to tissue _____
89. Enzyme that digests starch _____
90. Resembling starch _____

Write a word for each of the following definitions using the word parts provided. Each word part can be used more than once.

spasm	cephal	-o-	dactyl	extra-	-ic	infra-	syn-	thorac	a-	intra-	-y	poly-

91. cramp of a finger or toe _____
92. below the chest _____
93. inside the chest _____
94. condition of having extra fingers or toes _____
95. fusion of the fingers or toes _____
96. pertaining to the head and chest _____
97. absence of a finger or toe _____
98. within the head _____
99. absence of a head _____

extern.ir

WORD ANALYSIS

Define each of the following words, and give the meaning of the word parts in each. Use a dictionary if necessary.

100. homeostasis (*ho-me-o-STA-sis*)
    a. homeo _____
    b. stat (from Greek *states*) _____
    c. -sis _____
101. autophagy (*aw-TOF-ah-je*)
    a. auto _____
    b. phag/o _____
    c. -y _____
102. acrocyanosis (*ak-ro-si-ah-NO-sis*)
    a. acro _____
    b. cyan/o _____
    c. -sis _____
103. antebrachial (*an-te-BRA-ke-al*)
    a. ante- _____
    b. brachi/o _____
    c. -al _____

extern.ir

Additional Case Studies

Case Study 2-1: Needle Aspiration of Thyroid Tumor

Chief Complaint

Mathew, a 65 y/o male, noticed a lump on the side of his neck and went to see his physician. He has a history of prostate cancer and had a prostatectomy 4 years ago. Bilateral lymph node dissection revealed no metastasis. His physician referred him to a surgeon for evaluation of a nodule on the thyroid gland.

Examination

Dr. Thompson, a general surgeon, examined Mathew and recommended a needle aspiration of the thyroid gland.

The ultrasound-guided fine needle aspiration revealed atypical cells with abundant cytoplasm and prominent nuclei but no metastasis. However, the nuclei showed some morphologic changes. Histologic slides of the left thyroid showed clusters of epithelial cells associated with lymphocytes suggestive of lymphocytic thyroiditis.

Clinical Course

Mathew underwent a total thyroidectomy and is healing well. A follow-up CT scan of the neck and chest showed no additional nodules or indications of metastatic disease.

Case Study 2-1 Questions

Follow the instructions for each question and check your answers against Appendix 11.

Multiple Choice. *Select the best answer and write the letter of your choice to the left of each number.*

_____ 1. The suffix in *prostatectomy* and *thyroidectomy* means
   a. removal or excision
   b. incision into
   c. inflammation
   d. resembling

_____ 2. The singular form of *nuclei* is
   a. nucleolus
   b. nucleoli
   c. nucleum
   d. nucleus

Identify and give the meaning of the prefixes in the following words.

	Prefix	Meaning of Prefix
3. atypical	_____	_____
4. bilateral	_____	_____
5. metastasis (see Appendix 7)	_____	_____

Find words in the case study for the following.

6. A word with a root that means form _____
7. A word with a root that means tissue _____
8. Three words that contain a root that means cell _____

extern.ir

Case Study 2-2: Emergency Care

During a triathlon, paramedics responded to a scene with multiple patients involved in a serious bicycle accident. Patti, a 20 y/o woman, lost control of her bike while descending a hill at approximately 40 mph. As she fell, two other cyclists collided with her, sending all three crashing to the ground.

At the scene, Patti reported pain in her head, back, chest, and leg. She also had numbness and tingling in her legs and feet. Other injuries included a cut on her face and on her right arm and an obvious deformity to both her shoulder and knee. She had slight difficulty breathing.

The paramedic did a rapid cephalocaudal assessment and immobilized Patti's neck in a cervical collar. She was secured on a backboard and given oxygen. After her bleeding was controlled and her injured extremities were immobilized, she was transported to the nearest emergency department.

During transport, the paramedic in charge radioed ahead to provide a prehospital report to the charge nurse. Her report included the following information: occipital and frontal head pain; laceration to right temple, superior and anterior to right ear; lumbar pain; bilateral thoracic pain on inspiration at midclavicular line on the right and midaxillary line on the left; dull aching pain of the posterior proximal right thigh; bilateral paresthesia (numbness and tingling) of distal lower legs circumferentially; varus (knock-knee) adduction deformity of left knee; and posterior displacement deformity of left shoulder.

At the hospital, the emergency department physician ordered radiographs for Patti. Before the procedure, the radiology technologist positioned a lead gonadal shield centered on the midsagittal line above Patti's symphysis pubis to protect her ovaries from unnecessary irradiation by the primary beam. The technologist knew that gonadal shielding is important for female patients undergoing imaging of the lumbar spine, sacroiliac joints, acetabula, pelvis, and kidneys. Shields should not be used for any examination in which an acute abdominal condition is suspected.

extern.ir

Case Study 2-2 Questions

Follow the instructions for each question and check your answers against Appendix 11.

Multiple Choice. *Select the best answer and write the letter of your choice to the left of each number.*

_____ 1. The term for the timespan between injury and admission to the emergency department is
a. preoperative
b. prehospital
c. pretrauma
d. intrainjury

_____ 2. A cephalocaudal assessment goes from
a. front to back
b. head to toe
c. side to side
d. skin to bone

_____ 3. The victim's injured extremities were immobilized before transport. Immobilized means
a. abducted as far as possible
b. internally rotated and flexed
c. adducted so that the limbs are crossed
d. held in place to prevent movement

_____ 4. A cervical collar was placed on the victim to stabilize and immobilize the
a. uterus
b. shoulders
c. neck
d. pelvis

_____ 5. The singular form of acetabula is
a. acetabulum
b. acetabia
c. acetab
d. acetabulae

extern.ir

Draw or shade the appropriate area(s) on one or both diagrams for each question pertaining to the case study.

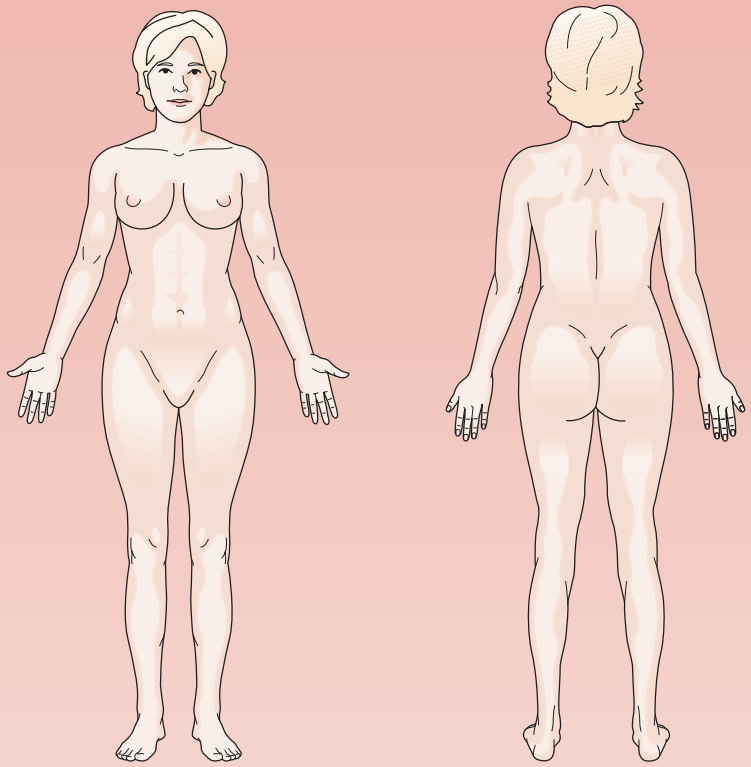

6. Draw dots over the areas of the victim's occipital and frontal head pain.
7. Draw a dash (—) over the area of the right temporal laceration—superior and anterior to the right ear.
8. Crosshatch the area of lumbar pain.
9. Place an X over the area of thoracic pain at the anterior left midaxillary line.
10. Draw a star at the area of the pain on the right proximal posterior thigh.
11. Shade the area of the bilateral paresthesia of the distal lower legs, circumferentially.
12. Draw an arrow to show the direction of the varus adduction of the left knee.
13. Draw an arrow to show the direction of the posterior displacement of the left shoulder.
14. Draw a fig leaf to show the gonadal shield on the midsagittal line above the symphysis pubis.
15. Draw a circle around the area of the sacroiliac joints.

extern.ir

CHAPTER 3

Disease and Treatment

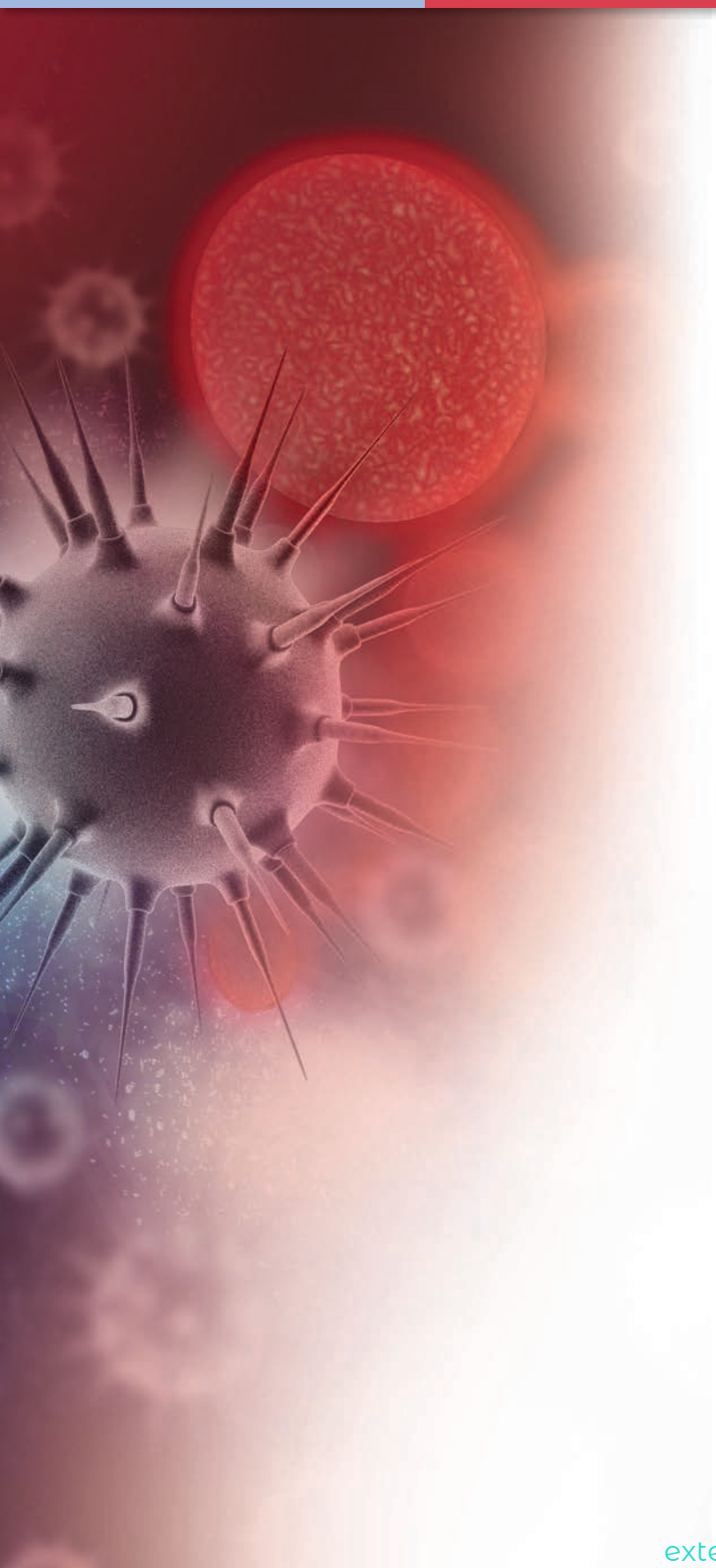

Pretest

Multiple Choice. **Select the best answer, and write the letter of your choice to the left of each number. To check your answers go to Appendix 11.**

_____ 1. A disease that has a sudden and severe onset is described as
a. chronic
b. mild
c. acute
d. infectious

_____ 2. Abnormal and uncontrolled growth of tissue is termed
a. anemia
b. neoplasia
c. parasitism
d. toxicity

_____ 3. White blood cells engulf foreign organisms by the process of
a. phagocytosis
b. egestion
c. ejection
d. dysphagia

_____ 4. The sum of all body defenses against infectious disease is termed
a. pyosis
b. complementation
c. secretion
d. immunity

_____ 5. Determination of a disease's nature and cause is called
a. admission
b. diagnosis
c. titration
d. prognosis

_____ 6. A simple device for listening to sounds within the body is a
a. cystoscope
b. stethoscope
c. barometer
d. speculum

_____ 7. A reason for not using a specific drug is a
a. prescription
b. counter-purpose
c. contraindication
d. prognosis

_____ 8. The solvent in an aqueous solution is
a. acid
b. salt
c. base
d. water

extern.ir

Learning Objectives

After careful study of this chapter, you should be able to:

1. List the major categories of diseases. ***P76***
2. Compare the common types of infectious organisms and list some diseases caused by each. ***P76***
3. Describe the common responses to disease. ***P79***
4. Describe the main methods used in patient examination. ***P91***
5. Name and describe nine imaging techniques. ***P92***
6. Name possible forms of treatment. ***P93***
7. Describe theories of alternative and complementary medicine and some healing practices used in these fields. ***P95***
8. Explain the difference between over-the-counter and prescription drugs and the difference between generic and brand name drugs. ***P106***
9. List three potential adverse side effects of drugs and two ways in which drugs can interact. ***P106***
10. List three sources of drug information. ***P106***
11. Describe five safety issues related to the use of herbal medicines. ***P106***
12. List standard forms for drug preparation and administration. ***P107***
13. Define basic terms related to disease and treatment. ***P96***
14. Identify and use word parts pertaining to disease and treatment. ***PP82, 98***
15. Identify and analyze medical terms and abbreviations in chapter case studies. ***PP75, 120***

Case Study: Mary's Rollerblading Injury

Chief Complaint

Mary, an active 59 y/o woman, was rollerblading early one morning. When attempting to avoid some loose gravel, she fell, injuring her right wrist and knee. She immediately experienced pain in her wrist and knee and noticed that her knee was swelling. She was able to use her cell phone and call her husband who came and took her to a nearby emergency department.

Examination

The physician assistant (PA) in the emergency department obtained the following history (Hx) of the incident:

Mary was rollerblading on a path early that morning and skated into some loose gravel, causing her to fall forward. She attempted to break the fall with her arms and ended up landing with her right hand and knee bearing the impact of the fall. She was able to take off the rollerblades and, favoring her right leg, make her way over to a nearby bench, where she used her cell phone to contact her husband for help. Mary was not wearing a helmet or any protective pads on her knees, elbows, or wrists.

The PA inspected the wrist, which had no open wounds, was slightly deformed, and edematous. She palpated the wrist area and documented that Mary complained of pain with limited range of motion (ROM) of the wrist. The fingers were warm and dry with good sensation. Next, the PA examined the knee that had some superficial abrasions, was swollen and painful, limiting full weight bearing on the right leg. The PA explained the prognosis to Mary and her husband, then proceeded to order diagnostic tests. Mary's knee was cleansed with a mild antiseptic wash and covered with a dry dressing. Her right arm was placed in a sling that was evaluated above her heart with ice packs placed on the wrist and knee.

Clinical Course

Mary was taken to the radiology department, where an x-ray of the right wrist revealed a distal radius or "Colles" fracture. An MRI was ordered for the knee and showed no fractures or ligament tears. The PA explained to Mary that she might

extern.ir

need to have an arthrocentesis, a tap to remove fluid in the knee joint, which would relieve some of the pain. She also explained that an endoscopic examination of the joint, an arthroscopy, might be required, but that the orthopedic surgeon who had already been consulted would determine whether or not this procedure was necessary.

Case Study Revisited: Once you complete this chapter, please review the case follow-up on p. 114.

Ancillaries *At-A-Glance*

Visit the web resource to access the following resources.

Learning Resources

- eBook
- A&P Module with Heart & Lung Sounds
- Image Bank
- TestPrep
- Animations
- Audio Pronunciation Glossary

Introduction

Medical care begins with assessing a disorder using information gathered from the patient and a variety of testing and examination methods. Based on these results, a course of treatment is recommended that may include drugs and surgery.

Types of Diseases

A disease is any disorder of normal body function. Diseases can be grouped into a number of different but often overlapping categories.

- Infectious diseases are caused by certain harmful **microorganisms** and other **parasites** that live at the expense of another organism. Any disease-causing agent is described as a **pathogen.**
- Degenerative diseases result from wear and tear, aging, or **trauma** (injury) that can lead to a **lesion** (wound) and perhaps **necrosis** (death of tissue). Common examples include arthritis, cardiovascular problems, and certain respiratory disorders such as emphysema. Structural malformations such as congenital malformations, **prolapse** (dropping), or **hernia** (rupture) may also result in degenerative changes.
- **Neoplasia** is the abnormal and uncontrolled growth of tissue.
- Immune disorders include failures of the immune system, allergies, and autoimmune diseases, in which the body makes antibodies to its own tissues. (Immune disorders receive more detailed discussion in Chapter 11.)
- Metabolic disorders result from lack of enzymes or other factors needed for cellular functions. Many hereditary disorders fall into this category. Malnutrition caused by inadequate intake of nutrients or inability of the body to absorb and use nutrients also upsets metabolism. (Metabolic disorders are discussed in more detail in Chapter 13, and hereditary disorders are discussed in Chapter 16.)
- Hormonal disorders are caused by underproduction or overproduction of hormones or by an inability of the hormones to function properly. One common example is diabetes mellitus. (Chapter 9 has more detail on hormonal disorders.)
- Mental and emotional disorders affect the mind and adaptation of an individual to his or her environment. (Chapter 7 has further discussion on behavioral disorders.)

Some methods for naming diseases are described in **BOX 3-1**.

The cause of a disease is its **etiology** (*e-te-OL-o-je*), although many diseases have multiple interacting causes. An **acute** disease is sudden, severe, and of short duration. A **chronic** disease is of long duration and progresses slowly. One health profession that deals with the immediate effects of acute disease is the emergency medical technician (EMT) (**BOX 3-2**).

Infectious Diseases

Infectious diseases are caused by viruses, bacteria, fungi (yeasts and molds), protozoa (single-celled animals), and worms (helminths) (**BOX 3-3**). Infecting organisms can enter

extern.ir

FOCUS ON WORDS
Name That Disease

BOX 3-1

Diseases get their names in a variety of ways. Some are named for the places where they were first found, such as Lyme disease for Lyme, Connecticut; West Nile disease, Rift Valley fever, and Ebola for places in Africa; and hantavirus fever for a river in Korea. Others are named for the people who first described them, such as Cooley anemia; Crohn disease, an inflammatory bowel disease; and Hodgkin disease of the lymphatic system. Note, however, that the World Health Organization (WHO) is discouraging the use of people, places, and animals in naming diseases, because these names can be offensive or negative and are often inaccurate.

Many diseases are named on the basis of the symptoms they cause. Tuberculosis causes small lesions known as tubercles in the lungs and other tissues. Skin anthrax produces lesions that turn black, and its name comes from the same root as anthracite coal. In sickle cell anemia, red blood cells become distorted into a crescent shape when they give up oxygen. Having lost their smooth, round form, the cells jumble together, blocking small blood vessels and depriving tissues of oxygen.

Bubonic plague causes painful and enlarged lymph nodes called buboes. Lupus erythematosus, a systemic autoimmune disorder, is named for the Latin term for wolf, because the red rash that may form on the faces of people with this disease gives them a wolf-like appearance. Yellow fever, scarlet fever, and rubella (German measles) are named for colors associated with the pathology of these diseases.

HEALTH PROFESSIONS
Emergency Medical Technicians

BOX 3-2

Emergency medical technicians (EMTs) are the first healthcare professionals to arrive at the scene of a motor vehicle accident, heart attack, or other emergency situation. EMTs must assess and respond rapidly to a medical crisis, taking a medical history, performing a physical examination, stabilizing the patient, and, if necessary, transporting the patient to the nearest medical facility.

To perform their lifesaving duties, EMTs need extensive training, including a thorough understanding of anatomy and physiology. EMTs must know how to use specialized equipment, such as backboards to immobilize injuries, and automated external defibrillators (AEDs) to treat cardiac arrest. At medical facilities, EMTs work closely with physicians and nurses, reporting on histories, physical examinations, and measures taken to stabilize the patient. Most EMTs receive their training from college or technical schools and must be certified in the state where they are employed.

As the American population ages and becomes concentrated in urban centers, the rate of accidents and other emergencies is expected to rise. Thus, the need for EMTs remains high. For more information about this career, contact the National Association of Emergency Medical Technicians at **naemt.org.**

FOR YOUR REFERENCE
Common Infectious Organisms

BOX 3-3

Type of Organism	Description	Examples of Diseases Caused
bacteria *bak-TE-re-ah*	simple microscopic organisms that are widespread throughout the world, some can produce disease; singular: bacterium (*bak-TE-re-um*)	
cocci *KOK-si*	round bacteria; may be in clusters (staphylococci), chains (streptococci), and other formations; singular: coccus (*KOK-us*)	pneumonia, rheumatic fever, food poisoning, septicemia, urinary tract infections, gonorrhea
bacilli *bah-SIL-i*	rod-shaped bacteria; singular: bacillus (*ba-SIL-us*)	typhoid, dysentery, salmonellosis, tuberculosis, botulism, tetanus
vibrios *VIB-re-oze*	short curved rods	cholera, gastroenteritis
spirochetes *SPI-ro-ketze*	corkscrew-shaped bacteria that move with a twisting motion	Lyme disease, syphilis, Vincent disease

(continued)

extern.ir

FOR YOUR REFERENCE *(Continued)*

BOX 3-3

Common Infectious Organisms

Type of Organism	Description	Examples of Diseases Caused
chlamydia *klah-MID-e-ah*	extremely small bacteria with complex life cycles that grow in living cells but, unlike viruses, are susceptible to antibiotics	conjunctivitis, trachoma, pelvic inflammatory disease (PID), and other sexually transmitted infections (STIs)
rickettsia *rih-KET-se-ah*	extremely small bacteria that grow in living cells but are susceptible to antibiotics	typhus, Rocky Mountain spotted fever
viruses *VI-rus-es*	submicroscopic infectious agents that can live and reproduce only within living cells	colds, herpes, hepatitis, measles, varicella (chickenpox), influenza, AIDS
fungi *FUN-ji*	simple, nongreen plants, some of which are parasitic; includes yeasts and molds; singular: fungus (*FUN-gus*)	candidiasis, skin infections (tinea, ringworm), valley fever
protozoa *pro-to-ZO-ah*	single-celled animals; singular: protozoon (*pro-to-ZO-on*)	dysentery, *Trichomonas* infection, malaria
helminths *HEL-minths*	worms	trichinosis; infestations with roundworms, pinworms, hookworms

the body through several routes, or portals of entry, including damaged skin, respiratory tract, digestive system, and urinary and reproductive tracts. An infected person's bodily discharges may contain organisms that spread infection through the air, food, water, or direct contact. Microorganisms often produce disease by means of the **toxins** (poisons) they release. The presence of harmful microorganisms or their toxins in the body is termed **sepsis.**

BACTERIA

Bacteria occur in the following shapes, as shown in **FIGURE 3-1**:

- Round, or cocci
- Rod-shaped, or bacilli
- Curved, including vibrios and spirochetes

Bacteria may be named according to their shape and also by the arrangements they form (see **FIG. 3-1**). They are also described according to the dyes they take up when stained in the laboratory. Chlamydia and rickettsia are two bacterial groups that are smaller than typical bacteria and can grow only within living host cells (see **BOX 3-3**).

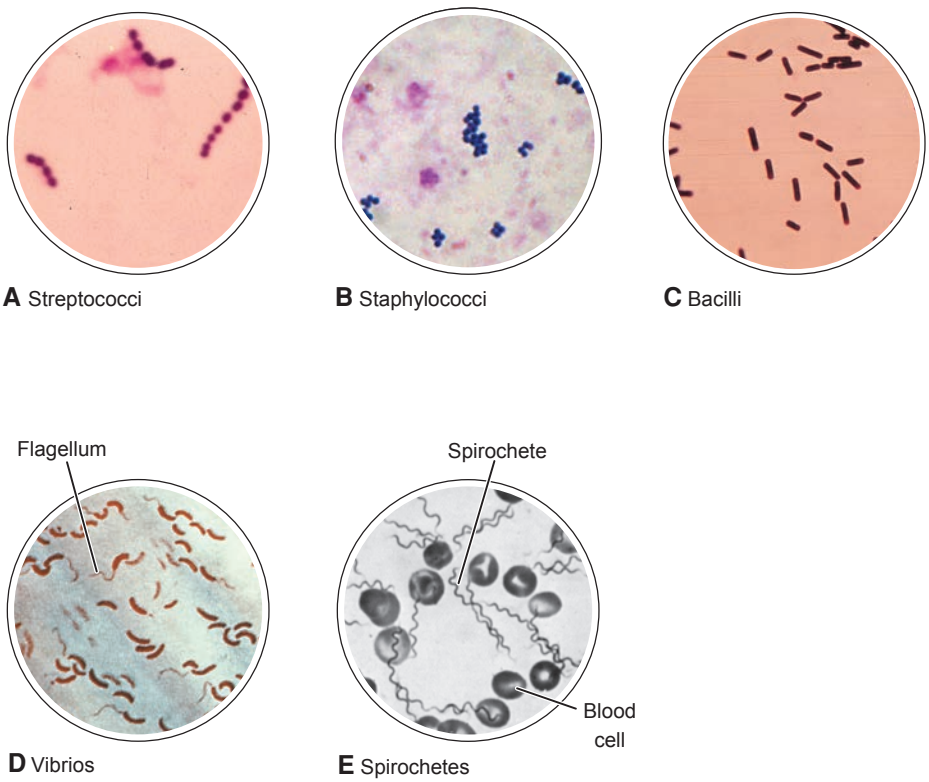

FIGURE 3-1 Bacteria. A. Streptococci, round bacteria in chains. **B.** Staphylococci, round bacteria in clusters. **C.** Bacilli, rod-shaped bacteria. **D.** Vibrios, short curved rods. **E.** Spirochetes, spiral-shaped bacteria.

extern.ir

Responses to Disease

INFLAMMATION

A common response to infection and to other forms of disease is **inflammation.** When cells are injured, they release chemicals that allow blood cells and fluids to move into the tissues. This inflow of blood results in the four signs of inflammation:

- Heat
- Pain
- Redness
- Swelling

The suffix *-itis* indicates inflammation, as in appendicitis (inflammation of the appendix) and tonsillitis (inflammation of the tonsils).

Inflammation is one possible cause of **edema**, a swelling or accumulation of fluid in the tissues (FIG. 3-2). Other causes of edema include fluid blockage, heart failure, and imbalance in body fluid composition, as described in later chapters.

A B

FIGURE 3-2 Edema. A. A normal foot showing veins, tendons, and bones. **B.** Edema (swelling) obscures surface features.

PHAGOCYTOSIS

The body uses **phagocytosis** to get rid of invading microorganisms, damaged cells, and other types of harmful debris. Certain white blood cells are capable of engulfing these materials and destroying them internally (FIG. 3-3). Phagocytic cells are found circulating in the blood, in the tissues, and in the lymphatic system (see Chapters 10 and 11). The remains of phagocytosis consist of fluid and white blood cells, a mixture called **pus**.

IMMUNITY

Immunity refers to all our defenses against infectious disease. Inflammation and phagocytosis are examples of inborn or innate protective mechanisms, which are based on a person's genetic makeup and do not require any previous exposure to a disease organism. Other defenses that fall into this category are mechanical barriers, such as intact skin and mucous membranes, as well as body secretions, such as stomach acid and enzymes in saliva and tears.

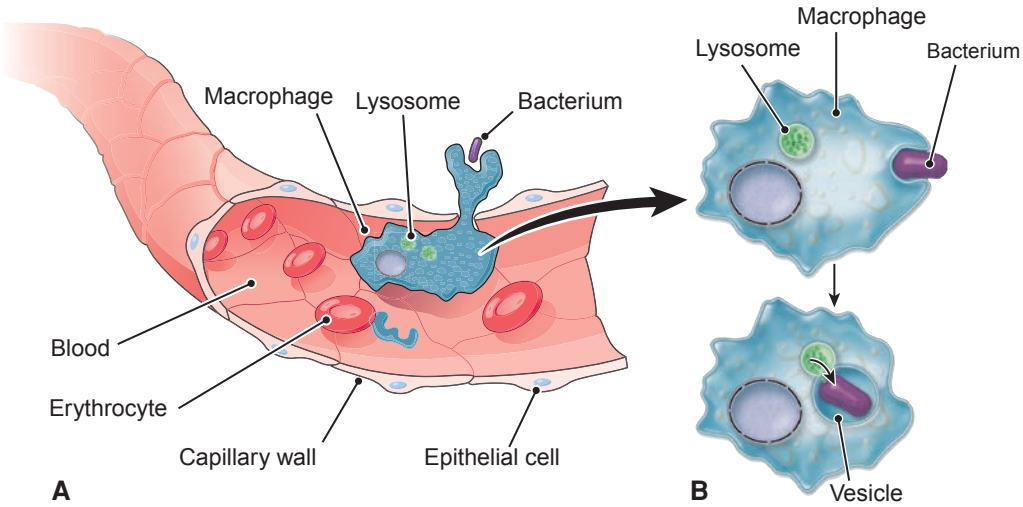

FIGURE 3-3 Phagocytosis. A. A phagocytic white blood cell squeezes through a capillary wall to engulf a bacterium. **B.** The bacterium is enclosed in a vesicle and destroyed by lysosomal enzymes.

extern.ir

Immunity that we develop during life from exposure to disease organisms is termed *adaptive immunity*, or acquired immunity. This type of immunity is specific for particular diseases encountered by natural exposure or by the administration of vaccines (see Chapter 11). The system responsible for adaptive immunity consists of cells in the blood, lymphatic system, and other tissues. These cells recognize different foreign invaders and get rid of them by direct attack and by producing circulating antibodies that immobilize and help destroy them. The immune system also monitors the body continuously for abnormal and malfunctioning cells, such as cancer cells. The immune system may overreact to produce allergies and may react to one's own tissues to cause autoimmune diseases.

Neoplasia

As noted earlier, a **neoplasm** is an abnormal and uncontrolled growth of tissue—a tumor or growth. A **benign** neoplasm does not spread, that is, undergo **metastasis** to other tissues, although it may cause damage at the site where it grows. An invasive neoplasm that can metastasize to other tissues is termed **malignant** and is commonly called *cancer*. A malignant tumor that involves epithelial tissue is a **carcinoma**. If the tumor arises in glandular epithelium, it is an adenocarcinoma (the root *aden/o* means "gland"); a cancer of pigmented epithelial cells (melanocytes) is a melanoma. A neoplasm that involves connective tissue or muscle is a **sarcoma**. Cancers of the blood, lymphatic system, and nervous system are classified according to the cell types involved and other clinical features. Further descriptions of these cancers appear in Chapters 11 and 7.

Often mistaken for a malignancy is a **cyst**, a sac or pouch filled with fluid or semisolid material that is abnormal but not cancerous. Common sites for cyst formation are the breasts, the skin's sebaceous glands, and the ovaries. Causes of cyst formation include infection or blockage of a duct.

Terminology *Key Terms*

The terms listed below are emphasized in this chapter. Knowing them will help you organize and prioritize your learning. These boldface terms are also found, collectively, with all chapter key terms in the Glossary.

Disease

acute *ah-KUTE*	Sudden, severe; having a short course
benign *be-NINE*	Not recurrent or malignant, favorable for recovery, describing a tumor that does not spread (metastasize) to other tissues
carcinoma *kar-sih-NO-mah*	A malignant neoplasm composed of epithelial cells (from Greek root carcino, meaning "crab") (adjective: carcinomatous)
chronic *KRON-ik*	Of long duration, progressing slowly
cyst *sist*	An abnormal filled sac or pouch; used as a root meaning a normal bladder or sac, such as the urinary bladder or gallbladder (root: cyst/o)
edema *eh-DE-mah*	Accumulation of fluid in the tissues, swelling; adjective: edematous (eh-DE-mah-tus) (see **FIG. 3-2**)
etiology *e-te-OL-o-je*	The cause of a disease
Gram stain	A laboratory staining procedure that divides bacteria into two groups: gram positive, which stains purple, and gram negative, which stains red
hernia *HER-ne-ah*	Protrusion of an organ through an abnormal opening; commonly called a rupture (**FIG. 3-4**)
immunity *ih-MU-nih-te*	All our defenses against infectious disease
inflammation *in-flah-MA-shun*	A localized response to tissue injury characterized by heat, pain, redness, and swelling
lesion *LE-zhun*	A distinct area of damaged tissue, an injury or wound

extern.ir

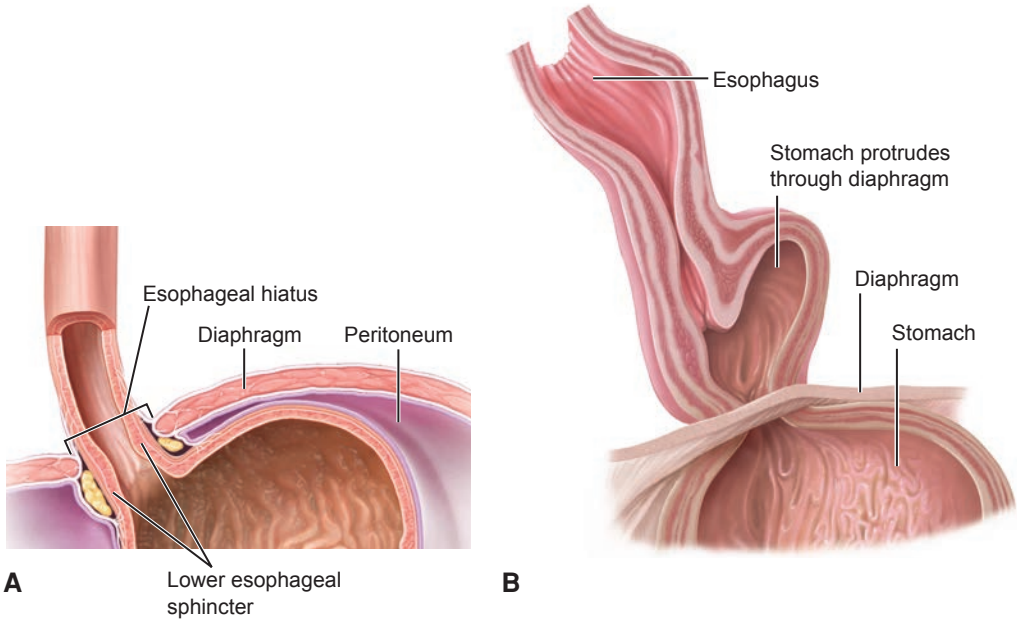

FIGURE 3-4 Hernia. A. Normal stomach. **B.** Hiatal hernia. The stomach protrudes through the diaphragm into the thoracic cavity, raising the level of the junction between the esophagus and the stomach.

Terminology — *Key Terms (Continued)*

malignant *mah-LIG-nant*	Growing worse, harmful, tending to cause death, describing an invasive tumor that can spread (metastasize) to other tissues
metastasis *meh-TAS-tah-sis*	Spread from one part of the body to another, characteristic of cancer; verb is metastasize (*meh-TAS-tah-size*), adjective: metastatic (*met-ah-STAT-ik*); from Greek met/a (beyond, change) + stasis (stand)
microorganism *mi-kro-OR-gan-izm*	An organism too small to be seen without the aid of a microscope
necrosis *neh-KRO-sis*	Death of tissue (root necr/o means "death"); adjective: necrotic (*neh-KROT-ik*)
neoplasia *ne-o-PLA-ze-ah*	An abnormal and uncontrolled growth of tissue; from prefix neo- meaning "new" and root plasm meaning "formation"
neoplasm *NE-o-plazm*	A tumor, or abnormal growth, which may be benign or malignant (root onc/o and suffix -oma refer to neoplasms)
parasite *PAR-ah-site*	An organism that grows on or in another organism (the host), causing damage to it
pathogen *PATH-o-jen*	An organism capable of causing disease (root path/o means "disease")
phagocytosis *fag-o-si-TO-sis*	The ingestion of organisms, such as invading bacteria or small particles of waste material by a cell (root phag/o means "to eat"); the phagocytic cell, or phagocyte, then destroys the ingested material (see **FIG. 3-3**)
prolapse *PRO-laps*	A dropping or downward displacement of an organ or part, ptosis
pus	A product of inflammation consisting of fluid and white blood cells (root: py/o)
sarcoma *sar-KO-mah*	A malignant neoplasm arising from connective tissue (from Greek root sarco, meaning "flesh"); adjective: sarcomatous

(continued)

extern.ir

Terminology Key Terms (Continued)

sepsis *SEP-sis*	The presence of harmful microorganisms or their toxins in the blood or other tissues; adjective: septic
toxin *TOKS-in*	A poison; adjective: toxic (roots: tox/o, toxic/o)
trauma *TRAW-mah*	A physical or psychological wound or injury

See also **BOX 3-3** on infectious organisms.

Word Parts Pertaining to Disease

See **TABLES 3-1** to **3-5**.

Table 3-1 Roots for Disease

Root	Meaning	Example	Definition of Example
alg/o, algi/o, algesi/o	pain	algesia *al-JE-ze-ah*	condition of having pain
carcin/o	cancer, carcinoma	carcinoid *KAR-sih-noyd*	resembling a carcinoma
cyst/o	filled sac or pouch, cyst, bladder	cystic *SIS-tik*	pertaining to or having cysts
lith	calculus, stone	lithiasis *lith-I-ah-sis*	stone formation
onc/o	tumor	oncogenic *on-ko-JEN-ik*	causing a tumor
path/o	disease	pathogen *PATH-o-jen*	organism that produces disease
py/o	pus	pyocyst *PI-o-sist*	cyst filled with pus
pyr/o, pyret/o	fever, fire	pyrexia *pi-REK-se-ah*	fever
scler/o	hard	sclerosis *skle-RO-sis*	hardening of tissue
tox/o, toxic/o	poison	endotoxin *en-do-TOK-sin*	toxin within bacterial cells

Exercise 3-1

Complete the exercise. To check your answers go to Appendix 11.

Identify and define the root in each of the following words.

	Root	Meaning of Root
1. toxicology (*tok-sih-KOL-o-je*)	toxic/o	poison
2. pyorrhea (*pi-o-RE-ah*)	_____	_____
3. lithotomy (*lih-THOT-o-me*)	_____	_____
4. pathologist (*pah-THOL-o-jist*)	_____	_____

extern.ir

Exercise 3-1 *(Continued)*

Fill in the blanks

5. Arteriosclerosis (*ar-te-re-o-skleh-RO-sis*) is a(n) _____ of the arteries.
6. A urolith (*U-ro-lith*) is a(n) _____ in the urinary tract (ur/o).
7. A cystotome (*SIS-to-tome*) is an instrument for incising the _____.
8. The term pathogenic (*path-o-JEN-ik*) means producing _____.
9. A carcinogen (*kar-SIN-o-jen*) is a substance that causes _____.
10. An exotoxin (*ek-so-TOK-sin*) is a(n) _____ secreted by bacterial cells.
11. Pyoderma (*pi-o-DER-mah*) is a skin disease associated with _____.
12. An algesimeter (*al-jeh-SIM-eh-ter*) is used to measure sensitivity to _____.
13. An oncogene (*ON-ko-jene*) is a gene that causes a(n) _____.
14. A pyrogenic (*pi-ro-JEN-ik*) agent induces _____.

3

Table 3-2 Prefixes for Disease

Prefix	Meaning	Example	Definition of Example
brady-	slow	bradypnea *brad-ip-NE-ah*	slow breathing (-pnea) rate
dys-	abnormal, painful, difficult	dysplasia *dis-PLA-je-ah*	abnormal development (plas) of tissue
mal-	bad, poor	malabsorption *mal-ab-SORP-shun*	poor absorption of nutrients
pachy-	thick	pachycephaly *pak-ih-SEF-ah-le*	abnormal thickness of the skull
tachy-	rapid	tachycardia *tak-ih-KAR-de-ah*	rapid heart (cardi/o) rate
xero-	dry	xeroderma *ze-ro-DER-mah*	dryness of the skin

Exercise 3-2

Complete the exercise. To check your answers go to Appendix 11.

Match the following terms, and write the appropriate letter to the left of each number.

____ 1. tachycardia (*tak-ih-KAR-de-ah*)	a. abnormal thickness of the fingers
____ 2. pachydactyly (*pak-e-DAK-til-e*)	b. abnormal nourishment of tissue
____ 3. bradypnea (*brad-IP-ne-ah*)	c. difficulty in swallowing
____ 4. dystrophy (*DIS-tro-fee*)	d. slow breathing
____ 5. dysphagia (*dis-FA-je-ah*)	e. rapid heart rate

Identify and define the prefix in each of the following words.

	Prefix	Meaning of Prefix
6. xerosis (*ze-RO-sis*)	_____	_____
7. dysentery (*DIS-en-ter-e*)	_____	_____
8. maladjustment (*mal-ad-JUST-ment*)	_____	_____

extern.ir

Table 3-3 Suffixes for Disease

Suffix	Meaning	Example	Definition of Example
-algia, -algesia	pain	neuralgia *nu-RAL-je-ah*	pain in a nerve (neur/o)
-cele	hernia, localized dilation	gastrocele *GAS-tro-sele*	hernia of the stomach (gastr/o)
-clasis, -clasia	breaking	karyoclasis *kar-e-OK-lah-sis*	breaking of a nucleus (kary/o)
-itis	inflammation	cystitis *sis-TI-tis*	inflammation of the urinary bladder (cyst/o)
-megaly	enlargement	hepatomegaly *hep-ah-to-MEG-ah-le*	enlargement of the liver (hepat/o)
-odynia	pain	urodynia *u-ro-DIN-e-ah*	pain on urination (ur/o)
-oma[a]	tumor	lipoma *li-PO-mah*	tumor of fat cells
-pathy	any disease of	nephropathy *nef-ROP-ah-the*	any disease of the kidney (nephr/o)
-rhage[b], -rhagia[b]	bursting forth, profuse flow, hemorrhage	hemorrhage *HEM-or-ij*	profuse flow of blood
-rhea[b]	flow, discharge	pyorrhea *pi-o-RE-ah*	discharge of pus
-rhexis[b]	rupture	amniorrhexis *am-ne-o-REK-sis*	rupture of the amniotic sac (bag of waters)
-schisis	fissure, splitting	retinoschisis *ret-ih-NOS-kih-sis*	splitting of the retina of the eye

[a]Plurals: *-omas*, *-omata*.
[b]Remember to double the r when adding this suffix to a root.

Exercise 3-3

Complete the exercise. To check your answers go to Appendix 11.

Match the following terms, and write the appropriate letter to the left of each number.

____ 1. adipocele (*AD-ih-po-sele*)	a. hernia containing fat
____ 2. blastoma (*blas-TO-mah*)	b. fissure of the chest
____ 3. thoracoschisis (*tho-rah-KOS-kih-sis*)	c. breaking of a bone
____ 4. melanoma (*mel-ah-NO-mah*)	d. tumor of immature cells
____ 5. osteoclasis (*os-te-OK-lah-sis*)	e. tumor of pigmented cells
____ 6. gastrodynia (*gas-tro-DIN-e-ah*)	a. local dilatation containing fluid
____ 7. menorrhagia (*men-o-RA-je-ah*)	b. pain in the stomach
____ 8. hydrocele (*HI-dro-sele*)	c. pain in the head
____ 9. cephalgia (*seh-FAL-je-ah*)	d. profuse menstrual flow
____ 10. hepatorrhexis (*hep-ah-to-REK-sis*)	e. rupture of the liver

extern.ir

Exercise 3-3 *(Continued)*

The root my/o means "muscle." Define the following terms.

11. myalgia (*mi-AL-je-ah*) _____
12. myopathy (*mi-OP-ah-the*) _____
13. myorrhexis (*mi-o-REK-sis*) _____
14. myodynia (*mi-o-DIN-e-ah*) _____
15. myoma (*mi-O-mah*) _____

Some words pertaining to disease are used as suffixes in compound words **(TABLE 3-4)**. As previously noted, the term *suffix* is used in this book to mean any word part that consistently appears at the end of words. This may be a simple suffix (such as -y, -ia, -ic), a word, or a root–suffix combination, such as -megaly, -rhagia, -pathy.

Table 3-4 Words for Disease Used as Suffixes

Word	Meaning	Example	Definition of Example
dilation[a], dilatation[a]	expansion, widening	vasodilation *vas-o-di-LA-shun*	widening of blood vessels (vas/o)
ectasia, ectasis	dilation, dilatation, distension	gastrectasia *gas-trek-TA-se-ah*	dilatation of the stomach (gastr/o)
edema	accumulation of fluid, swelling	cephaledema *sef-al-eh-DE-mah*	swelling of the head
lysis[a]	separation, loosening, dissolving, destruction	dialysis *di-AL-ih-sis*	separation of substances by passage through (dia-) a membrane
malacia	softening	craniomalacia *kra-ne-o-mah-LA-she-ah*	softening of the skull (crani/o)
necrosis	death of tissue	osteonecrosis *os-te-o-neh-KRO-sis*	death of bone (oste/o) tissue
ptosis	dropping, downward displacement, prolapse	blepharoptosis *blef-eh-rop-TO-sis*	dropping or drooping of the eyelid (blephar/o; **FIG. 3-5**)
sclerosis	hardening	phlebosclerosis *fleb-o-skleh-RO-sis*	hardening of veins (phleb/o)
spasm	sudden contraction, cramp	arteriospasm *ar-TERE-e-o-spazm*	spasm of an artery
stasis[a]	suppression, stoppage	menostasis *men-OS-tah-sis*	suppression of menstrual (men/o) flow
stenosis	narrowing, constriction	bronchostenosis *brong-ko-steh-NO-sis*	narrowing of a bronchus (air passageway)
toxin	poison	nephrotoxin *nef-ro-TOK-sin*	substance poisonous or harmful for the kidneys

[a]May also refer to treatment.

extern.ir

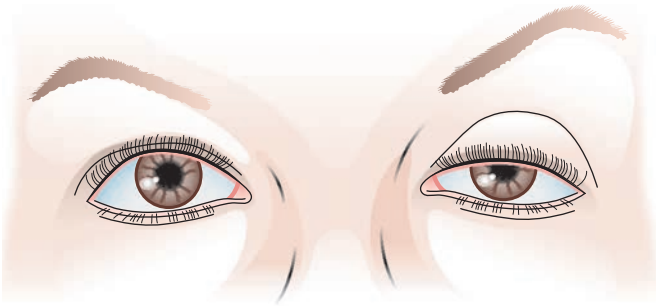

FIGURE 3-5 Blepharoptosis (dropping or drooping of the eyelid). Ptosis means a downward displacement.

Exercise 3-4

Complete the exercise. To check your answers go to Appendix 11.

Match the following terms, and write the appropriate letter to the left of each number.

____ 1. myolysis (*mi-OL-ih-sis*)
____ 2. osteomalacia (*os-te-o-mah-LA-she-ah*)
____ 3. cardionecrosis (*kar-de-o-neh-KRO-sis*)
____ 4. hemolysis (*he-MOL-ih-sis*)
____ 5. hemostasis (*he-mo-STA-sis*)

a. destruction of blood cells
b. death of heart tissue
c. stoppage of blood flow
d. softening of a bone
e. dissolving of muscle

The root splen/o means "spleen." Define the following words.

6. splenomalacia (*sple-no-mah-LA-she-ah*) _____
7. splenoptosis (*sple-nop-TO-sis*) _____
8. splenotoxin (*sple-no-TOK-sin*) _____

Table 3-5 Prefixes and Roots for Infectious Diseases

Word Part	Meaning	Example	Definition of Example
Prefixes			
staphylo-	grape-like cluster	staphylococcus *staf-ih-lo-KOK-us*	a round bacterium that forms clusters (see **FIG. 3-1B**)
strepto-	chain	streptobacillus *strep-to-bah-SIL-us*	a rod-shaped bacterium that forms chains (see **FIG. 3-1A**)
Roots			
bacill/i, bacill/o	bacillus	bacilluria *bas-ih-LU-re-ah*	bacilli in the urine (-uria)
bacteri/o	bacterium	bacteriostatic *bak-tere-e-o-STAT-ik*	stopping (stasis) the growth of bacteria
myc/o	fungus, mold	mycotic *mi-KOT-ik*	pertaining to a fungus
vir/o	virus	viremia *vi-RE-me-ah*	presence of viruses in the blood (-emia)

extern.ir

Exercise 3-5

Complete the exercise. To check your answers go to Appendix 11.

Fill in the blanks.

1. A bactericidal (*bak-tere-ih-SI-dal*) agent kills _____.
2. A mycosis (*mi-KO-sis*) is any disease caused by a(n) _____.
3. The term bacillary (*BAS-il-ah-re*) means pertaining to _____.
4. The prefix strepto- means _____.
5. The prefix staphylo- means _____.

Use the suffix -logy to write a word that means the same as each of the following.

6. Study of fungi _____
7. Study of viruses _____
8. Study of bacteria _____

Terminology *Enrichment Terms*

The terms listed below expand on the key terms to increase your knowledge of this chapter topic.

Disease

acid-fast stain	A laboratory staining procedure used mainly to identify the tuberculosis (TB) organism
communicable *ko-MUN-ih-kah-bl*	Capable of passing from one person to another, such as an infectious disease
endemic *en-DEM-ik*	Occurring at a low level but continuously in a given region, such as the common cold (from en-, meaning "in" and Greek demos, meaning "people")
epidemic *ep-ih-DEM-ik*	Affecting many people in a given region at the same time, a disease that breaks out in a large proportion of a population at a given time
exacerbation *eks-zas-er-BA-shun*	Worsening of disease, increase in severity of a disease or its symptoms
iatrogenic *i-at-ro-JEN-ik*	Caused by the effects of treatment (from Greek root iatro-, meaning "physician")
idiopathic *id-e-o-PATH-ik*	Having no known cause (root idio means "self-originating")
in situ *in SI-tu*	Localized, noninvasive (literally "in position"); said of tumors that do not spread, such as carcinoma in situ (CIS)
normal flora *FLO-rah*	The microorganisms that normally live on or in the body and are generally harmless and often beneficial but can cause disease under special circumstances, such as injury or failure of the immune system
nosocomial *nos-o-KO-me-al*	Describing an infection acquired in a hospital (root nos/o means "disease," and comial refers to a hospital), which can be a serious problem, especially if it is resistant to antibiotics, such as strains of methicillin-resistant *Staphylococcus aureus* (MRSA) and vancomycin-resistant *S. aureus* (VRSA)
opportunistic *op-por-tu-NIS-tik*	Describing an infection that occurs because of a host's poor or altered condition
pandemic *pan-DEM-ik*	Describing a disease that is prevalent throughout an entire region or the world; for example, AIDS is pandemic in certain regions of the world

(continued)

extern.ir

Terminology Enrichment Terms (Continued)

remission *re-MISH-un*	A lessening of disease symptoms, the period during which such lessening occurs
septicemia *sep-tih-SE-me-ah*	Presence of pathogenic bacteria in the blood, blood poisoning
systemic *sis-TEM-ik*	Pertaining to the whole body
Manifestations of Disease	
abscess *AB-ses*	A localized collection of pus
adhesion *ad-HE-zhun*	A uniting of two surfaces or parts that may normally be separated
anaplasia *ah-nah-PLA-ze-ah*	Lack of normal differentiation, as shown by cancer cells
ascites *a-SI-teze*	Accumulation of fluid in the peritoneal cavity
cellulitis *sel-u-LI-tis*	A spreading inflammation of tissue
effusion *eh-FU-zhun*	Escape of fluid into a cavity or other body part
exudate *EKS-u-date*	Material that escapes from blood vessels as a result of tissue injury
fissure *FISH-ur*	A groove or split
fistula *FIS-tu-lah*	An abnormal passage between two organs or from an organ to the surface of the body
gangrene *GANG-grene*	Death of tissue, usually caused by lack of blood supply; may be associated with bacterial infection and decomposition
hyperplasia *hi-per-PLA-ze-ah*	Excessive growth of normal cells in normal arrangement
hypertrophy *hi-PER-tro-fe*	An increase in the size of an organ without increase in the number of cells; may result from an increase in activity, as in muscles
induration *in-du-RA-shun*	Hardening, an abnormally hard spot or place
metaplasia *met-ah-PLA-ze-ah*	Conversion of cells to a form that is not normal for that tissue (prefix meta- means "*change*")
polyp *POL-ip*	A tumor attached by a thin stalk
purulent *PUR-u-lent*	Forming or containing pus
suppuration *sup-u-RA-shun*	Pus formation

extern.ir

Terminology Abbreviations Pertaining to Disease

The abbreviations listed below are emphasized in this chapter. These are also found, collectively, with all chapter abbreviations in Appendix 2.

AF	Acid fast	**MDR**	Multidrug resistant
CA, Ca	Cancer	**MRSA**	Methicillin-resistant *S. aureus*
CIS	Carcinoma in situ	**Staph**	*Staphylococcus*
FUO	Fever of unknown origin	**Strep**	*Streptococcus*
Gm+	Gram positive	**VRSA**	Vancomycin-resistant *S. aureus*
Gm⁻	Gram negative		

Diagnosis

Medical **diagnosis**, the determination of the nature and cause of an illness, begins with a patient history. This includes a history of the present illness with a description of **symptoms** (evidence of disease), a past medical history, and a family and a social history.

A physical examination, which includes a review of all systems and observation of any **signs** of illness, follows the history taking. Practitioners use the following techniques in performing physicals:

- **Inspection:** visual examination
- **Palpation:** touching the surface of the body with the hands or fingers **(FIG. 3-6)**
- **Percussion:** tapping the body to evaluate tissue according to the sounds produced **(FIG. 3-7)**
- **Auscultation:** listening to body sounds with a stethoscope **(FIG. 3-8)**

FIGURE 3-6 Palpation. The practitioner touches the body surface with the hands or fingers.

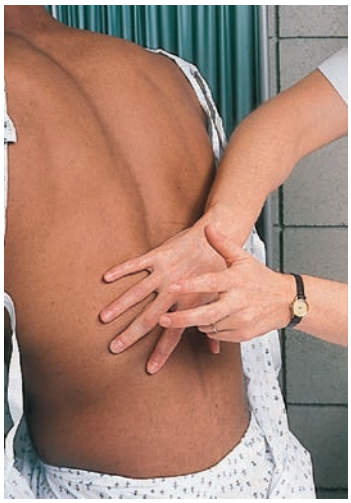

FIGURE 3-7 Percussion. The practitioner taps the body to evaluate tissues.

FIGURE 3-8 Auscultation. The practitioner uses a stethoscope to listen to body sounds.

extern.ir

FIGURE 3-9 Pulse rate. The practitioner palpates an artery to measure pulse rate in beats per minute.

Vital signs (VS) are also recorded for comparison with normal ranges. VS are measurements that reflect basic functions necessary to maintain life and include:

- Temperature (T).
- Pulse rate, measured in beats per minute (bpm) **(FIG. 3-9)**. Pulse rate normally corresponds to the heart rate (HR), the number of times the heart beats per minute.
- Respiration rate (R), measured in breaths per minute.
- Blood pressure (BP), measured in millimeters of mercury (mm Hg) and recorded when the heart is contracting (systolic pressure) and relaxing (diastolic pressure) **(FIG. 3-10)**. An examiner typically uses a **stethoscope** and a blood pressure cuff, or **sphygmomanometer** (*sfig-mo-mah-NOM-eh-ter*), to measure blood pressure. Newer devices that read blood pressure directly and give digital readings are also in use. Chapter 10 has more information on blood pressure.

FIGURE 3-10 Blood pressure. The practitioner uses a blood pressure cuff (sphygmomanometer) and a stethoscope to measure systolic and diastolic pressures.



FIGURE 3-11 Examination tools. A. Ophthalmoscope for eye examination. **B.** Otoscope for ear examination.

Additional tools used in physical examinations include the **ophthalmoscope** **(FIG. 3-11A)**, for examination of the eyes; the **otoscope** **(FIG. 3-11B)**, for examination of the ears; and hammers for testing reflexes.

The skin, hair, and nails provide easily observable indications of a person's state of health. Skin features such as color, texture, thickness, and presence of lesions (local injuries) are noted throughout the course of the physical examination. Chapter 4 contains a discussion of the skin and skin diseases.

Diagnosis is further aided by laboratory test results. These may include tests on blood, urine, and other body fluids and the identification of infectious organisms. Additional tests may include study of the electrical activity of tissues such as the brain and heart, examination of body cavities by means of an **endoscope** **(FIG. 3-12)**, and imaging

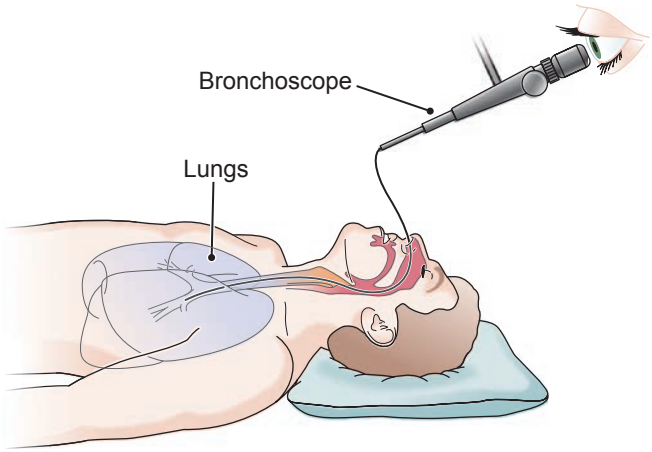

FIGURE 3-12 Endoscope. A bronchoscope is a type of endoscope used to examine the respiratory bronchi.

extern.ir

techniques. **Biopsy** is the removal of tissue for microscopic examination. Biopsy specimens can be obtained by:

- Needle withdrawal (aspiration) of fluid, as from the chest or from a cyst
- A small punch, as of the skin
- Endoscopy, as from the respiratory or digestive tract
- Surgical removal, as of a tumor or node

In some cases, cancer can be diagnosed and its treatment monitored by a *liquid biopsy*, which relies on analysis of cancerous cells or tumor DNA in circulating blood. These samples are easier to obtain, may give a more complete picture of tumor spread than isolated tissue biopsies, and may someday be used as screening tests for hard-to-diagnose types of cancer.

When new tests appear, as in all other areas of health sciences, new terminology is added to the medical vocabulary.

IMAGING TECHNIQUES

Imaging techniques employ various types of energy to produce visual images of the body. The most fundamental imaging method is **radiography** (FIG. 3-13), which uses x-rays to produce an image (radiograph) on film or to produce a digital image that can be viewed on a monitor. Radiography is the preferred method for imaging dense tissues, such as bone. Some soft-tissue structures can be demonstrated as well, but a contrast medium, such as a barium mixture, may be needed to enhance visualization. Other forms of energy used to produce diagnostic images include sound waves, radioactive isotopes, radio waves, and magnetic fields. See BOX 3-4 for a description of the most commonly used imaging methods and BOX 3-5 for a summary of these and other imaging techniques in use.

FIGURE 3-13 Radiography. The action of x-rays on sensitized film produced this image (radiograph) of a normal right hand.

CLINICAL PERSPECTIVES
Medical Imaging

BOX 3-4

Three imaging techniques that have revolutionized medicine are radiography, computed tomography (CT), and magnetic resonance imaging (MRI). With them, physicians today can "see" inside the body without making a single cut.

The oldest technique is radiography (*ra-de-OG-rah-fe*), in which a machine beams x-rays (a form of radiation) through the body onto a piece of film. The resulting image is called a radiograph. Dark areas indicate where the beam passed through the body and exposed the film, whereas light areas show where the beam did not pass through. Dense tissues (bone, teeth) absorb most of the x-rays, preventing them from exposing the film. For this reason, radiography is commonly used to visualize bone fractures and tooth decay as well as abnormally dense tissues like tumors. Radiography does not provide clear images of soft tissues because most of the beam passes through and exposes the film, but contrast media can help make structures like blood vessels and hollow organs more visible. For example, barium sulfate (which absorbs x-rays) coats the digestive tract when ingested.

During a CT scan, a machine revolves around the patient, beaming x-rays through the body onto a detector. The detector takes numerous images of the beam and a computer assembles them into transverse sections, or "slices." Unlike conventional radiography, CT produces clear images of soft structures such as the brain, liver, and lungs. It is commonly used to visualize brain injuries and tumors and even blood vessels when used with contrast media.

MRI uses a strong magnetic field and radio waves. The patient undergoing MRI lies inside a chamber within a very powerful magnet. The molecules in the patient's soft tissues align with the magnetic field inside the chamber. When radio waves hit the soft tissue, the aligned molecules emit energy that the MRI machine detects, and a computer converts these signals into an image. MRI produces even clearer images of soft tissue than does CT and can create detailed views of blood vessels without contrast media. MRI can visualize brain injuries and tumors that might be missed using CT.

extern.ir

FOR YOUR REFERENCE
Imaging Techniques

BOX 3-5

Method	Description
cineradiography *sin-eh-ra-de-OG-rah-fe*	making of a motion picture of successive images appearing on a fluoroscopic screen
computed tomography (CT, CT scan) *to-MOG-rah-fe*	use of a computer to generate an image from a large number of x-rays passed at different angles through the body; a three-dimensional image of a cross-section of the body is obtained; reveals more about soft tissues than does simple radiography (**FIG. 3-14A**)
fluoroscopy *flor-OS-ko-pe*	use of x-rays to examine deep structures; the shadows cast by x-rays passed through the body are observed on a fluorescent screen; the device used is called a fluoroscope
magnetic resonance imaging (MRI)	production of images through the use of a magnetic field and radio waves; the characteristics of soft tissue are revealed by differences in molecular properties; eliminates the need for x-rays and contrast media (see **FIG. 3-14B**)

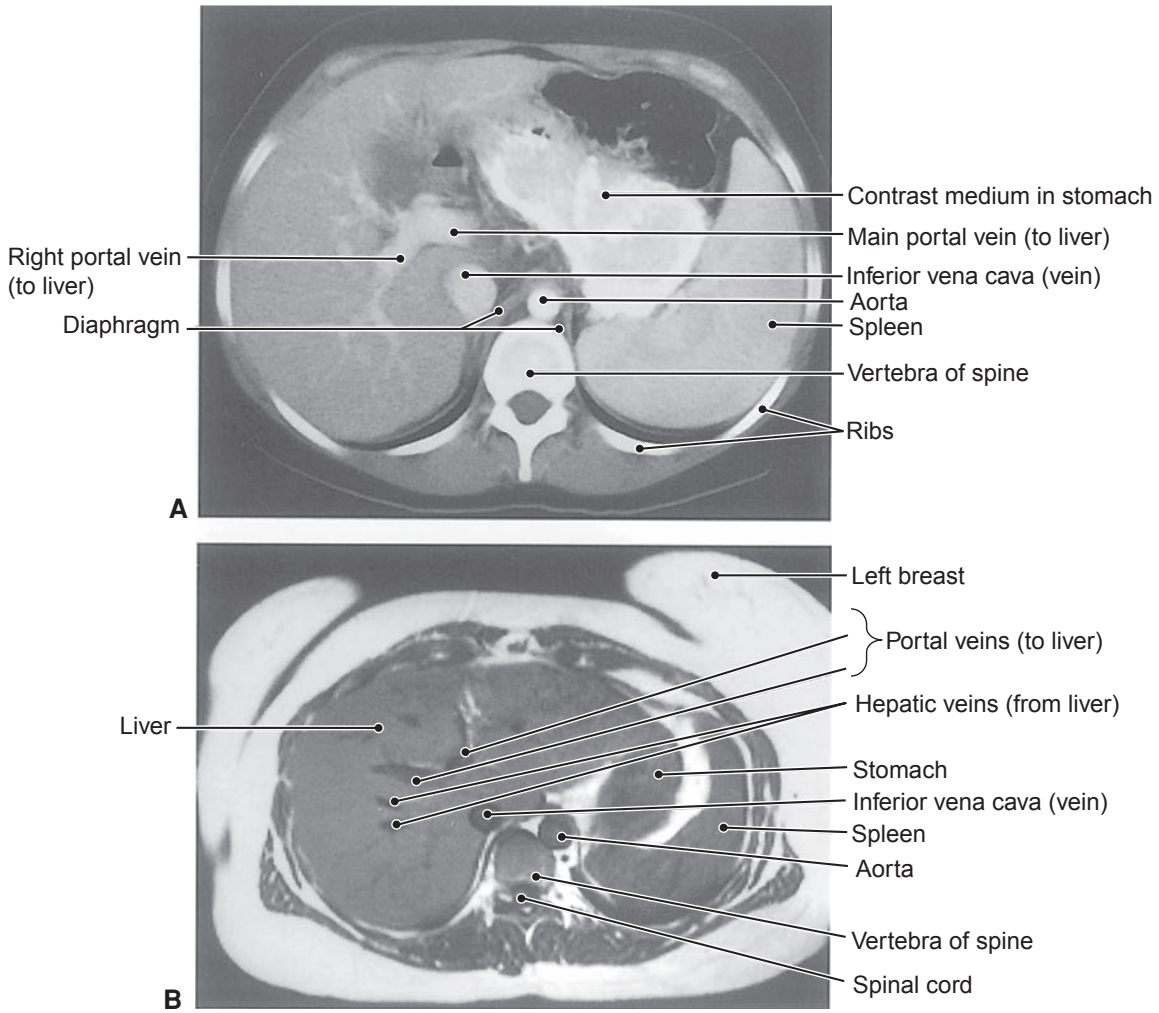

FIGURE 3-14 Imaging techniques. Shown are cross-sections through the liver and spleen. **A.** Computed tomography (CT). **B.** Magnetic resonance imaging (MRI).

extern.ir

FOR YOUR REFERENCE *(Continued)*
Imaging Techniques

BOX 3-5

Method	Description
positron emission tomography (PET)	production of sectional body images by administration of a natural substance, such as glucose, labeled with a positron-emitting isotope; the rays subsequently emitted are interpreted by a computer to show the internal distribution of the substance administered; PET has been used to follow blood flow through an organ and to measure metabolic activity within an organ, such as the brain, under different conditions
radiography *ra-de-OG-rah-fe*	use of x-rays passed through the body to make a visual record (radiograph) of internal structures either on specially sensitized film or digitally; also called roentgenography (*rent-geh-NOG-rah-fe*) after the developer of the technique
scintigraphy *sin-TIG-rah-fe*	imaging the radioactivity distribution in tissues after internal administration of a radioactive substance (radionuclide); the images are obtained with a scintillation camera; the record produced is a scintiscan (*SIN-tih-skan*) and usually specifies the part examined or the isotope used for the test, as in bone scan, gallium scan
single-photon emission computed tomography (SPECT)	scintigraphic technique that permits visualization of a radioisotope's cross-sectional distribution
ultrasonography *ul-trah-son-OG-rah-fe*	generation of a visual image from the echoes of high-frequency sound waves traveling back from different tissues; also called sonography (*so-NOG-rah-fe*) and echography (*ek-OG-rah-fe*) (FIG. 3-15)

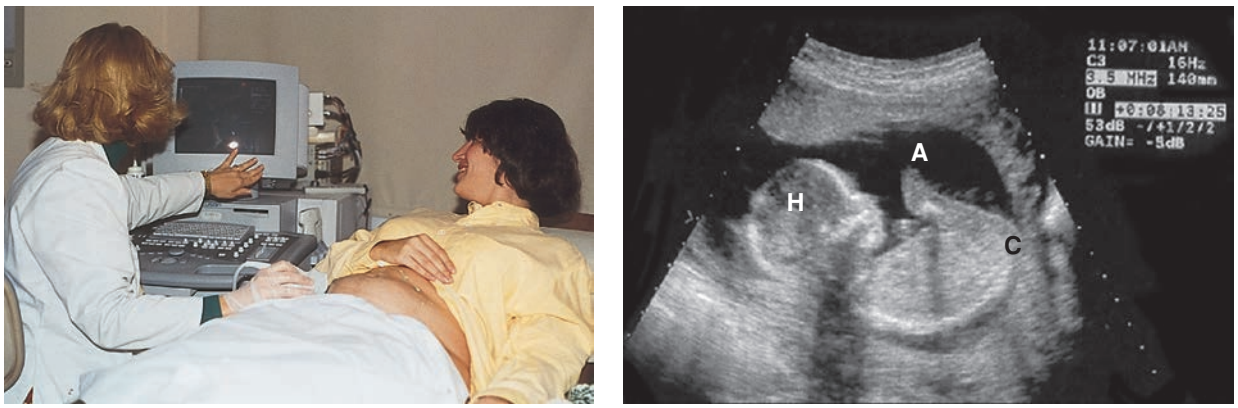

A B

FIGURE 3-15 Ultrasonography. A. The practitioner is using ultrasound to monitor pregnancy. **B.** Sonogram of a pregnant uterus at 10 to 11 weeks showing the amniotic cavity (*A*) filled with amniotic fluid. The fetus is seen in longitudinal section showing the head (*H*) and coccyx (*C*).

Treatment

If diagnosis so indicates, treatment, also termed **therapy**, is begun. This may consist of counseling, drugs, surgery, radiation, physical therapy, occupational therapy, psychiatric treatment, or some combination of these. Drugs and their actions are discussed in Appendix 10. **Palliative therapy** is treatment that provides relief but is not intended as a cure. Terminally ill patients, for example, may receive treatment that eases pain and provides comfort but is not expected to change the outcome of the disease. During diagnosis and throughout the course of treatment, a patient is evaluated to establish a **prognosis**—that is, a prediction of the disease's outcome.

SURGERY

Surgery is a method for treating disease or injury by manual operations. Surgery may be done through an existing body opening, but usually it involves cutting or puncturing tissue with a sharp instrument in the process of **incision.** BOX 3-6 for descriptions of surgical instruments and FIGURE 3-16 for pictures of surgical instruments. Surgery usually requires some form of **anesthesia** to dull or eliminate

extern.ir

FOR YOUR REFERENCE
Surgical Instruments

BOX 3-6

Instrument	Description
bougie *BOO-zhe*	slender, flexible instrument for exploring and dilating tubes
cannula *KAN-u-lah*	tube enclosing a trocar (see below) that allows escape of fluid or air after removal of the trocar
clamp	instrument used to compress tissue
curet (curette) *KU-ret*	spoon-shaped instrument for removing material from the wall of a cavity or other surface (see **FIG. 3-16**)
elevator *EL-eh-va-tor*	instrument for lifting tissue or bone
forceps *FOR-seps*	instrument for holding or extracting (see **FIG. 3-16**)
Gigli saw *JE-yle*	flexible wire saw
hemostat *HE-mo-stat*	small clamp for stopping blood flow from a vessel (see **FIG. 3-16**)
rasp	surgical file
retractor *re-TRAK-tor*	instrument used to maintain exposure by separating a wound and holding back organs or tissues (see **FIG. 3-16**)
rongeur *ron-ZHUR*	gouge forceps
scalpel *SKAL-pel*	surgical knife with a sharp blade (see **FIG. 3-16**)
scissors *SIZ-ors*	a cutting instrument with two opposing blades
sound *sownd*	instrument for exploring a cavity or canal (see **FIG. 3-16**)
trocar *TRO-kar*	sharp pointed instrument contained in a cannula used to puncture a cavity

pain. After surgery, incisions must be closed for proper healing. Traditionally, surgeons have used stitches or **sutures** to close wounds, but today they also use adhesive strips, staples, and skin glue.

Many types of operations are now performed with a **laser**, an intense beam of light. Some procedures require destruction of tissue by a harmful agent, such as by heat or a chemical, in the process of **cautery** or cauterization. Surgeons are now increasingly using computer-assisted robotic surgery for certain procedures. In this type of operation, the surgeon uses robotic instruments manipulated remotely or by a computer. These operations can be less invasive than standard surgeries and result in less bleeding. The method has been used mainly for urogenital procedures, some joint replacement, correction of certain heart abnormalities, and gallbladder removal.

Some of the purposes of surgery include:

- Treatment: For **excision** (cutting out) of diseased or abnormal tissue, such as a tumor or an inflamed appendix. Surgical methods are also used to repair wounds or injuries, as in skin grafting for burns or for realigning broken bones. Surgical methods are used to correct circulatory problems and to return structures to their normal positions, as in raising a prolapsed organ, such as the urinary bladder, in a surgical **fixation** procedure.

extern.ir

Curette Forceps Hemostat Retractor Sound Scalpel

FIGURE 3-16 Surgical instruments.

- Diagnosis: To remove tissue for laboratory study in a biopsy, as previously described. Exploratory surgery to investigate the cause of symptoms is performed less frequently now because of advances in noninvasive diagnostic and imaging techniques.
- Restoration: Surgery may compensate for lost function, as when a section of the intestine is redirected in a colostomy, a tube is inserted to allow breathing in a tracheostomy, a feeding tube is inserted, or an organ is transplanted. Surgeons may perform plastic or reconstructive surgery to accommodate a prosthesis (substitute part), to restore proper appearance, or for cosmetic reasons.
- Relief: Palliative surgery relieves pain or discomfort, as by cutting the nerve supply to an organ or reducing the size of a tumor to relieve pressure.

Surgery may be done in an emergency or urgent situation under conditions of acute danger, as in traumatic injury or severe blockage. Other procedures, such as cataract removal from the eye, may be planned when convenient. Elective or optional surgery would not cause serious consequences if delayed or not done.

Over time, surgery has extended beyond the classic operating room of a hospital to other hospital areas and to private surgical facilities where people can be treated within 1 day as outpatients. Preoperative care is given before surgery and includes examination, obtaining the patient's informed consent for the procedure, and preadmission testing. Postoperative care includes recovery from anesthesia, follow-up evaluations, and instructions for home care.

Alternative and Complementary Medicine

During the past century, the leading causes of death in industrialized countries have gradually shifted from infectious diseases to chronic diseases of the cardiovascular and respiratory systems and cancer. In addition to advancing age, life habits and the environment greatly influence these conditions. As a result, many people have begun to consider healing practices from other philosophies and cultures as alternatives and complements to conventional Western medicine. Some of these philosophies include **osteopathy**, **naturopathy**, **homeopathy**, and **chiropractic.** Techniques of **acupuncture**, **biofeedback**, **massage**, and **meditation** may also be used, as well as herbal remedies (see Chapter 8) and nutritional counseling on diet, vitamins, and minerals. Complementary and alternative therapies emphasize maintaining health rather than treating disease and allowing the body opportunity to heal itself. These ideas fit into the concept of **holistic health care**, which promotes treating an individual as a whole with emotional, social, and spiritual needs in addition to physical needs and encouraging people to be involved in their own health maintenance.

The U.S. government has established the National Center for Complementary and Alternative Medicine (NCCAM) within the National Institutes of Health (NIH) to study these therapies.

Cancer

Methods used in the diagnosis of cancer include physical examination, biopsy, imaging techniques, and laboratory tests for abnormalities, or "markers," associated with specific types of malignancies. Some cancer markers are byproducts, such as enzymes, hormones, and cellular proteins that are abnormal or are produced in abnormal amounts. Researchers have also linked specific genetic mutations to certain forms of cancer.

Oncologists (cancer specialists) use two methods, **grading** and **staging**, to classify cancers, select and evaluate therapy, and estimate disease outcome. Grading is based on histologic (tissue) changes observed in tumor cells when they are examined microscopically. Grades increase from I to IV with increasing cellular abnormality.

Staging is a procedure for establishing the clinical extent of tumor spread, both at the original site and in

extern.ir

other parts of the body (metastases). The TNM system is commonly used. These letters stand for primary tumor (T), regional lymph nodes (N), and distant metastases (M). Evaluation in these categories varies for each type of tumor. Based on TNM results, a stage ranging in severity from I to IV is assigned. Cancers of the blood, lymphatic system, and nervous system are evaluated by different standards.

The most widely used methods for treatment of cancer are surgery, radiation therapy, and **chemotherapy** (treatment with chemicals). Newer methods of **immunotherapy** use substances that stimulate the immune system as a whole or vaccines prepared specifically against a tumor. Hormone therapy may also be effective against certain types of tumors. When no active signs of the disease remain, the cancer is said to be in **remission.**

Terminology *Key Terms*

The terms listed below are emphasized in this chapter. Knowing them will help you organize and prioritize your learning. These boldface terms are also found, collectively, with all chapter key terms in the Glossary.

Diagnosis and Treatment

anesthesia *an-es-THE-ze-ah*	Loss of the ability to feel pain, as by administration of a drug
auscultation *aws-kul-TA-shun*	Listening for sounds within the body, usually within the chest or abdomen (see **FIG. 3-8**)
biopsy *BI-op-se*	Removal of a small amount of tissue for microscopic examination
cautery *KAW-ter-e*	Destruction of tissue by a damaging agent, such as a harmful chemical, heat, or electric current (electrocautery); cauterization
chemotherapy *ke-mo-THER-ah-pe*	Use of chemicals to treat disease; the term is often applied specifically to the treatment of cancer with chemicals
diagnosis *di-ag-NO-sis*	The process of determining the cause and nature of an illness
endoscope *EN-do-skope*	An instrument for examining the inside of an organ or cavity through a body opening or small incision; most endoscopes use fiber optics for viewing (see **FIG. 3-12**)
excision *ek-SIZH-un*	Removal by cutting (suffix: -ectomy)
fixation *fik-SA-shun*	Holding or fastening a structure in a firm position (suffix: -pexy)
grading *GRA-ding*	A method for evaluating a tumor based on microscopic examination of the cells
immunotherapy *im-u-no-THER-ah-pe*	Treatment that involves stimulation or suppression of the immune system, either specifically or nonspecifically
incision *in-SIZH-un*	A cut, as for surgery; also the act of cutting (suffix: -tomy)
inspection *in-SPEK-shun*	Visual examination of the body
laser *LA-zer*	A device that transforms light into a beam of intense heat and power; used for surgery and diagnosis
ophthalmoscope *of-THAL-mo-skope*	An instrument for examining the interior of the eye (see **FIG. 3-11A**)
otoscope *O-to-skope*	Instrument used to examine the ears (see **FIG. 3-11B**)
palliative therapy *PAL-e-ah-tiv*	Providing relief but not cure; a treatment that provides such relief

extern.ir

Terminology Key Terms (Continued)

palpation *pal-PA-shun*	Examining by placing the hands or fingers on the surface of the body to determine characteristics such as texture, temperature, movement, and consistency (see **FIG. 3-6**)
percussion *per-KUSH-un*	Tapping the body lightly but sharply to assess the condition of the underlying tissue by the sounds obtained (see **FIG. 3-7**)
prognosis *prog-NO-sis*	Prediction of a disease's course and outcome
radiography *ra-de-OG-rah-fe*	Use of x-rays passed through the body to make a visual record (radiograph) of internal structures either on specially sensitized film or digitally; roentgenography (*rent-geh-NOG-rah-fe*)
remission *re-MISH-un*	Lessening of disease symptoms; the period during which this decrease occurs or the period when no sign of a disease exists
sign *sine*	Objective evidence of disease that can be observed or tested; examples are fever, rash, high blood pressure, and blood or urine abnormalities; an objective symptom
sphygmomanometer *sfig-mo-mah-NOM-eh-ter*	Blood pressure apparatus or blood pressure cuff; pressure is read in millimeters of mercury (mm Hg) when the heart is contracting (systolic pressure) and when the heart is relaxing (diastolic pressure) and is reported as systolic/diastolic (see **FIG. 3-10**)
staging *STA-jing*	The process of classifying malignant tumors for diagnosis, treatment, and prognosis
stethoscope *STETH-o-skope*	An instrument used for listening to sounds produced within the body (from the Greek root steth/o, meaning "chest") (see **FIG. 3-8**)
surgery *SUR-jer-e*	A method for treating disease or injury by manual operations
suture *SU-chur*	To unite parts by stitching them together; also the thread or other material used in that process or the seam formed by surgical stitching (suffix: -rhaphy)
symptom *SIMP-tum*	Any evidence of disease; sometimes limited to subjective evidence of disease as experienced by the individual, such as pain, dizziness, and weakness
therapy *THER-ah-pe*	Treatment, intervention
vital signs *VI-tal*	Measurements that reflect basic functions necessary to maintain life
Alternative and Complementary Medicine	
acupuncture *AK-u-punk-chur*	An ancient Chinese method of inserting thin needles into the body at specific points to relieve pain, induce anesthesia, or promote healing; similar effects can be obtained by using firm finger pressure at the surface of the body in the technique of *acupressure*
biofeedback *bi-o-FEDE-bak*	A method for learning control of involuntary physiologic responses by using electronic devices to monitor bodily changes and feeding this information back to a person
chiropractic *ki-ro-PRAK-tik*	A science that stresses the condition of the nervous system in diagnosis and treatment of disease; often, the spine is manipulated to correct misalignment; most patients consult for musculoskeletal pain and headaches (from Greek *cheir*, meaning "hand")
holistic health care *ho-LIS-tik*	Practice of treating a person as a whole entity with physical, emotional, social, and spiritual needs; it stresses comprehensive care, involvement in one's own care, and the maintenance of good health rather than the treatment of disease
homeopathy *ho-me-OP-ah-the*	A philosophy of treating disease by administering drugs in highly diluted form along with promoting healthy life habits and a healthy environment (from *homeo*, meaning "same," and *path/o*, meaning "disease")

(continued)

extern.ir

Terminology Key Terms (Continued)

massage *ma-SAHJ*	Manipulation of the body or portion of the body to calm, relieve tension, increase circulation, and stimulate muscles
meditation *med-ih-TA-shun*	Process of clearing the mind by concentrating on the inner self while controlling breathing and perhaps repeating a word or phrase (mantra)
naturopathy *na-chur-OP-ah-the*	A therapeutic philosophy of helping people heal themselves by developing healthy lifestyles; naturopaths may use some of the methods of conventional medicine (from *nature* and *path/o*, meaning "disease")
osteopathy *os-te-OP-ah-the*	A system of therapy based on the theory that the body can overcome disease when it has normal structure, a favorable environment, and proper nutrition; osteopaths use standard medical practices for diagnosis and treatment but stress the identification and correction of faulty body structure (from *oste/o*, meaning "bone," and *path/o*, meaning "disease")

Word Parts Pertaining to Diagnosis and Treatment

See **TABLES 3-6** to **3-8**.

Table 3-6 Roots for Physical Forces

Root	Meaning	Example	Definition of Example
aer/o	air, gas	aerobic *air-O-bik*	pertaining to or requiring air (oxygen)
bar/o	pressure	barometer *bah-ROM-eh-ter*	instrument used to measure pressure
chrom/o, chromat/o	color, stain	chromatic *kro-MAT-ik*	having color
chron/o	time	chronologic *kron-o-LOJ-ik*	arranged according to the time of occurrence
cry/o	cold	cryoprobe *KRI-o-probe*	instrument used to apply extreme cold
electr/o	electricity	electrolysis *e-lek-TROL-ih-sis*	decomposition of a substance by means of electric current
erg/o	work	synergistic *sin-er-JIS-tik*	working together with increased effect, such as certain drugs in combination
phon/o	sound, voice	phonograph *FO-no-graf*	instrument used to reproduce sound
phot/o	light	photoreaction *fo-to-re-AK-shun*	response to light
radi/o	radiation, x-ray	radiology *ra-de-OL-o-je*	study and use of radiation
son/o	sound	sonogram *SON-o-gram*	record obtained by use of ultrasound
therm/o	heat, temperature	hypothermia *hi-po-THER-me-ah*	abnormally low body temperature

extern.ir

Exercise 3-6

Complete the exercise. To check your answers go to Appendix 11.

Match the following terms, and write the appropriate letter to the left of each number.

____ 1. hyperthermia (*hi-per-THER-me-ah*)	a. abnormally high body temperature
____ 2. hyperbaric (*hi-per-BAR-ik*)	b. any pigmented cell
____ 3. synchrony (*SIN-kro-ne*)	c. pertaining to increased pressure
____ 4. radioactive (*ra-de-o-AK-tiv*)	d. occurrence at the same time
____ 5. chromocyte (*kro-mo-site*)	e. giving off radiation

Identify and define the root in each of the following words.

	Root	Meaning of Root
6. sonographer (*so-NOG-rah-fer*)	_____	_____
7. chronic (*KRON-ik*)	_____	_____
8. homeothermic (*ho-me-o-THER-mik*)	_____	_____
9. exergonic (*eks-er-GON-ik*)	_____	_____
10. anaerobic (*an-er-O-bik*)	_____	_____
11. achromatic (*ak-ro-MAT-ik*)	_____	_____

Fill in the blanks

12. The term electroconvulsive (*e-lek-tro-con-VUL-siv*) means causing convulsions by means of _____.
13. A photograph (*FO-to-graf*) is an image produced by means of _____.
14. Cryotherapy (*kri-o-THER-ah-pe*) is treatment using _____.
15. Barotrauma (*bah-ro-TRAW-mah*) is injury caused by _____.
16. Phonetics (*fo-NET-iks*) is the study of _____.

Table 3-7 Suffixes for Diagnosis

Suffix	Meaning	Example	Definition of Example
-graph	instrument for recording data	**polygraph** *POL-e-graf*	instrument used to record many physiologic responses simultaneously; lie detector
-graphy	act of recording data[a]	**echography** *ek-OG-rah-fe*	recording data obtained by ultrasound
-gram[b]	a record of data	**electrocardiogram** *eh-lek-tro-KAR-de-o-gram*	record of the heart's electrical activity
-meter	instrument for measuring	**calorimeter** *kal-o-RIM-eh-ter*	instrument for measuring the caloric energy of food
-metry	measurement of	**audiometry** *aw-de-OM-eh-tre*	measurement of hearing (audi/o); root *metr/o* means "measure"
-scope	instrument for viewing or examining	**bronchoscope** *BRONG-ko-skope*	instrument for examining the bronchi (breathing passages) (see **FIG. 3-12**)
-scopy	examination of	**celioscopy** *se-le-OS-ko-pe*	examination of the abdominal cavity (celi/o)

[a]This ending is often used to mean not only the recording of data but also the evaluation and interpretation of the data.
[b]An image prepared simply using x-rays is called a radiograph. When special techniques are used to image an organ or region with x-rays, the ending *-gram* is used with the root for that area, as in urogram (urinary tract), angiogram (blood vessels), and mammogram (breast).

extern.ir

Exercise 3-7

Complete the exercise. To check your answers go to Appendix 11.

Match the following terms, and write the appropriate letter to the left of each number.

____ 1. microscope (*MI-kro-skope*)	a. examination of the abdomen
____ 2. ergometry (*er-GOM-eh-tre*)	b. a record of sound
____ 3. thermometer (*ther-MOM-eh-ter*)	c. measurement of work done
____ 4. laparoscopy (*lap-ah-ROS-ko-pe*)	d. instrument for measuring temperature
____ 5. sonogram (*SON-o-gram*)	e. instrument for examining very small objects
____ 6. endoscope (*EN-do-skope*)	a. a record of sound
____ 7. electroencephalograph (*e-lek-tro-en-SEF-ah-lo-graf*)	b. instrument for measuring time
____ 8. audiometer (*aw-de-OM-eh-ter*)	c. instrument for viewing the inside of a cavity or organ
____ 9. phonogram (*FO-no-gram*)	d. instrument used to measure hearing
____ 10. chronometer (*kron-OM-eh-ter*)	e. instrument used to record the brain's electrical activity

Table 3-8 Suffixes for Surgery

Suffix	Meaning	Example	Definition of Example
-centesis	puncture, tap	thoracentesis *thor-ah-sen-TE-sis*	puncture of the chest (thorac/o)
-desis	binding, fusion	pleurodesis *plu-ROD-eh-sis*	binding of the pleura (membranes around the lungs)
-ectomy	excision, surgical removal	hepatectomy *hep-ah-TEK-to-me*	excision of liver tissue (hepat/o)
-pexy	surgical fixation	hysteropexy *HIS-ter-o-pek-se*	surgical fixation of the uterus (hyster/o)
-plasty	plastic repair, plastic surgery, reconstruction	rhinoplasty *RI-no-plas-te*	plastic surgery of the nose (rhin/o)
-rhaphy	surgical repair, suture	herniorrhaphy *her-ne-OR-ah-fe*	surgical repair of a hernia (herni/o)
-stomy	surgical creation of an opening	tracheostomy *tra-ke-OS-to-me*	creation of an opening into the trachea (trache/o)
-tome	instrument for incising (cutting)	microtome *MI-kro-tome*	instrument for cutting thin sections of tissue for microscopic study
-tomy	incision, cutting	laparotomy *lap-ah-ROT-o-me*	surgical incision of the abdomen (lapar/o)
-tripsy	crushing	neurotripsy *nu-ro-TRIP-se*	crushing of a nerve (neur/o)

extern.ir

Exercise 3-8

Complete the exercise. To check your answers go to Appendix 11.

Match the following terms, and write the appropriate letter to the left of each number.

____ 1. nephropexy (*nef-ro-PEK-se*)	a. crushing of a stone
____ 2. rhinoplasty (*RI-no-plas-te*)	b. surgical fixation of the kidney
____ 3. lithotripsy (*LITH-o-trip-se*)	c. puncture of the abdomen
____ 4. adenectomy (*ad-eh-NEK-to-me*)	d. excision of a gland
____ 5. celiocentesis (*se-le-o-sen-TE-sis*)	e. plastic surgery of the nose

The root *cyst/o* means "urinary bladder." Use this root to write a word that means each of the following.

6. Incision into the bladder _____
7. Surgical fixation of the bladder _____
8. Plastic repair of the bladder _____
9. Surgical repair of the bladder _____
10. Creation of an opening into the bladder _____

The root *arthr/o* means "joint." Use this root to write a word that means each of the following.

11. Plastic repair of a joint _____
12. Instrument for incising a joint _____
13. Incision of a joint _____
14. Puncture of a joint _____
15. Fusion of a joint _____

Write a word for each of the following definitions using the roots given.

16. Incision into the trachea (trache/o) _____
17. Surgical repair of the stomach (gastr/o) _____
18. Creation of an opening into the colon (col/o) _____

Terminology *Enrichment Terms*

The terms listed below expand on the key terms to increase your knowledge of this chapter topic.

Diagnosis and Treatment

Symptoms

clubbing *KLUB-ing*	Enlargement of the ends of the fingers and toes because of soft-tissue growth of the nails; seen in a variety of diseases, especially lung and heart diseases (**FIG. 3-17**)
colic *KOL-ik*	Acute abdominal pain associated with smooth muscle spasms
cyanosis *si-ah-NO-sis*	Bluish discoloration of the skin due to lack of oxygen
diaphoresis *di-ah-fo-RE-sis*	Profuse sweating

(continued)

extern.ir

Terminology Enrichment Terms (Continued)

malaise *mah-LAZE*	A feeling of discomfort or uneasiness, often indicative of infection or other disease (from French, meaning "discomfort," using the prefix mal-, meaning "bad")
nocturnal *nok-TUR-nal*	Pertaining to or occurring at night (roots noct/i and nyct/o mean "night")
pallor *PAL-or*	Paleness, lack of color
prodrome *PRO-drome*	A symptom indicating an approaching disease
sequela *seh-KWEL-ah*	A lasting effect of a disease (plural: sequelae)
syncope *SIN-ko-pe*	A temporary loss of consciousness because of inadequate blood flow to the brain, fainting
Diagnosis	
alpha-fetoprotein (AFP) *AL-fah-fe-to-PRO-tene*	A fetal protein that appears in the blood of adults with certain types of cancer
bruit *brwe*	A sound, usually abnormal, heard in auscultation
facies *FA-she-eze*	The expression or appearance of the face
febrile *FEB-ril*	Pertaining to fever
nuclear medicine	The branch of medicine concerned with the use of radioactive substances (radionuclides) for diagnosis, therapy, and research
radiology *ra-de-OL-o-je*	The branch of medicine that uses radiation, such as x-rays, in the diagnosis and treatment of disease; a specialist in this field is a radiologist
radionuclide *ra-de-o-NU-klide*	A substance that gives off radiation; used for diagnosis and treatment; also called radioisotope or radiopharmaceutical
speculum *SPEK-u-lum*	An instrument for examining a canal (**FIG. 3-18**)
syndrome *SIN-drome*	A group of signs and symptoms that together characterize a disease condition
Treatment	
catheter *KATH-eh-ter*	A thin tube that can be passed into the body; used to remove fluids from or introduce fluids into a body cavity (**FIG. 3-19**)
clysis *KLI-sis*	The introduction of fluid into the body, other than orally, as into the rectum or abdominal cavity; also refers to the solution thus used
irrigation *ir-ih-GA-shun*	Flushing of a tube, cavity, or area with a fluid (see **FIG. 3-19**)
lavage *lah-VAJ*	The washing out of a cavity, irrigation
normal saline (NS) *SA-lene*	A salt (NaCl) solution compatible with living cells, also called physiologic saline solution (PSS)
paracentesis *par-ah-sen-TE-sis*	Puncture of a cavity for removal of fluid

extern.ir

Terminology *Enrichment Terms (Continued)*

prophylaxis *pro-fih-LAK-sis*	Prevention of disease
Surgery	
drain	Device for allowing matter to escape from a wound or cavity; common types include Penrose (cigarette), T-tube, Jackson–Pratt (J-P), and Hemovac
ligature *LIG-ah-chur*	A tie or bandage, the process of binding or tying (also called ligation)
resection *re-SEK-shun*	Partial excision of a structure
stapling *STA-pling*	In surgery, the joining of tissue by using wire staples that are pushed through the tissue and then bent
surgeon *SUR-jun*	A physician who specializes in surgery

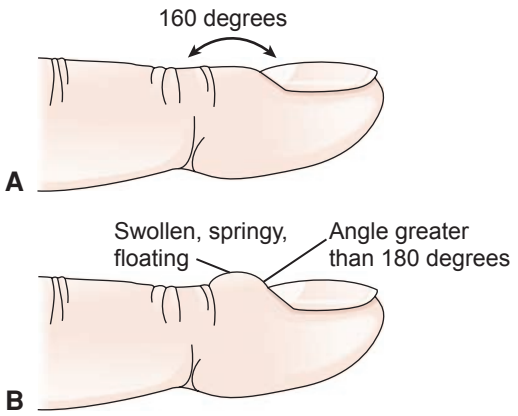

FIGURE 3-17 Clubbing. A. Normal. **B.** Clubbing; the end of the finger is enlarged because of soft-tissue growth around the nail.

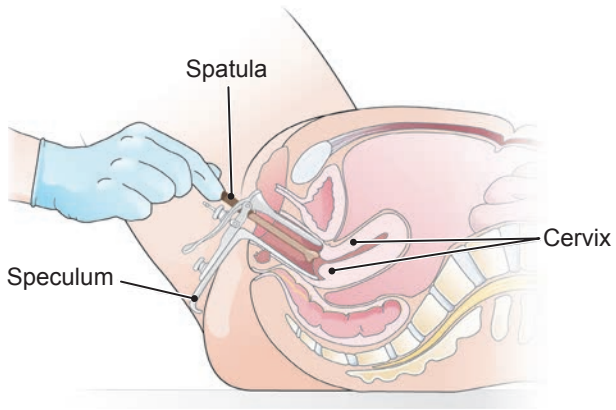

FIGURE 3-18 A vaginal speculum. This instrument is used to examine the vagina and cervix and to obtain a cervical sample for testing.

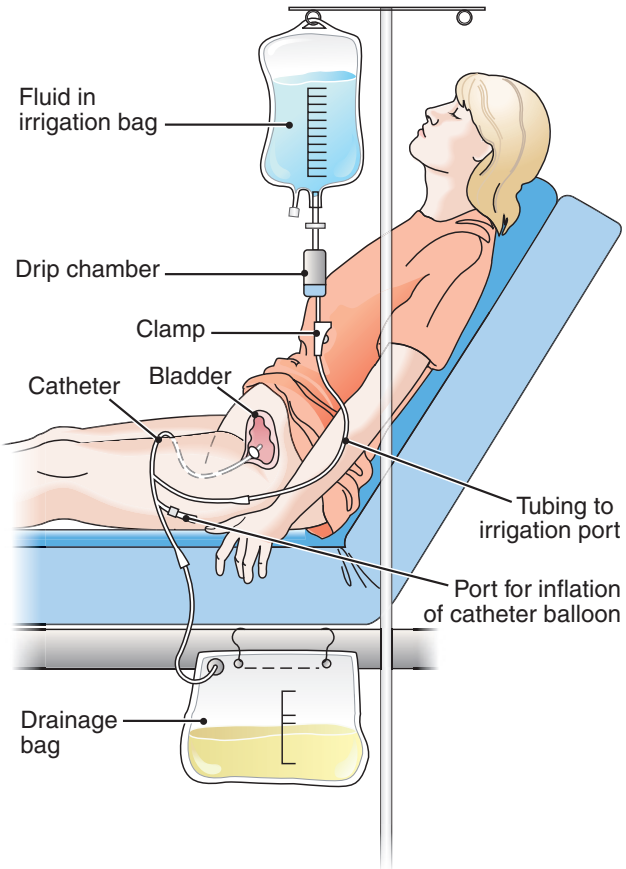

FIGURE 3-19 Continuous bladder irrigation using a catheter.

extern.ir

Terminology *Symbols*

1°	primary	°	degree
2°	secondary (to)	∧	above
Δ	change	∨	below
Ⓛ	left	=	equal to
Ⓡ	right	≠	not equal to
↑	increase(d)	±	doubtful, slight
↓	decrease(d)	~	approximately
♂	male	×	times
♀	female	#	number, pound

Terminology *Abbreviations*

The abbreviations listed below are emphasized in this chapter. These are also found, collectively, with all chapter abbreviations in Appendix 2.

History and Physical Examination

ADL	Activities of daily living
BP	Blood pressure
bpm	Beats per minute
C	Celsius (centigrade)
CC	Chief complaint
c/o, co	Complains (complaining) of
EOMI	Extraocular muscles intact
ETOH	Alcohol (ethyl alcohol)
F	Fahrenheit
HEENT	Head, eyes, ears, nose, and throat
HIPAA	Health Insurance Portability and Accountability Act
h/o	History of
H&P	History and physical
HPI	History of present illness
HR	Heart rate
Hx	History
I&O	Intake and output
IPPA	Inspection, palpation, percussion, auscultation
IVDA	Intravenous drug abuse
NAD	No apparent distress
NKDA	No known drug allergies
P	Pulse
PE	Physical examination
PE(R)RLA	Pupils equal (regular) react to light and accommodation
PMH	Past medical history
pt	Patient
R	Respiration
R/O	Rule out
ROS	Review of systems
T	Temperature
TPR	Temperature, pulse, respiration
VS	Vital signs
WD	Well developed
WNL	Within normal limits
w/o	Without
y/o, YO	Years old, year-old

extern.ir

Terminology *Abbreviations (Continued)*

Diagnosis and Treatment

ABC	Aspiration biopsy cytology
AFP	Alpha-fetoprotein
BS	Bowel sounds, breath sounds
bx	Biopsy
CAM	Complementary and alternative medicine
Ci	Curie (unit of radioactivity)
C&S	Culture and (drug) sensitivity (of bacteria)
CT	Computed tomography
D/C, dc	Discontinue
Dx	Diagnosis
EBL	Estimated blood loss
ED	Emergency department
ICU	Intensive care unit
I&D	Incision and drainage
MET	Metastasis
MRI	Magnetic resonance imaging
NCCAM	National Center for Complementary and Alternative Medicine
NS, N/S	Normal saline
OR	Operating room
PACU	Postanesthesia care unit
PCA	Patient-controlled analgesia
PET	Positron emission tomography
PICC	Peripherally inserted central catheter
postop	Postoperative
preop	Preoperative
PSS	Physiologic saline solution
RATx	Radiation therapy
Rx	Drug, prescription, therapy
SPECT	Single-photon emission computed tomography
TNM	(Primary) tumor, (regional lymph) nodes, (distant) metastases
UV	Ultraviolet

Views for Radiography

AP	Anteroposterior
LL	Left lateral
PA	Posteroanterior
RL	Right lateral

Orders

AMA	Against medical advice
AMB	Ambulatory
BRP	Bathroom privileges
CBR	Complete bed rest
DNR	Do not resuscitate
KVO	Keep vein open
NPO	Nothing by mouth (Latin, *non per os*)
OOB	Out of bed
QNS	Quantity not sufficient
QS	Quantity sufficient
STAT	Immediately
TKO	To keep open

extern.ir

Drugs

A **drug** is a substance that alters body function. Traditionally, drugs have been derived from natural plant, animal, and mineral sources. Today, most are manufactured synthetically by pharmaceutical companies. A few, such as certain hormones and enzymes, have been produced by genetic engineering.

Many drugs, described as over-the-counter (OTC) drugs, are available without a signed order, or **prescription (Rx).** Others require a healthcare provider's prescription for use.

Responsibility for the safety and **efficacy** (effectiveness) of all drugs sold in the United States lies with the Federal Food and Drug Administration (FDA), which must approve all drugs before they are sold.

ADVERSE DRUG EFFECTS

An unintended or off-target effect of a drug or any other form of treatment is a **side effect.** Most drugs have potential adverse side effects that must be evaluated before they are prescribed. In addition, there may be **contraindications**, or reasons not to use a particular drug for a specific individual based on the person's medical conditions, current medications, sensitivity, or family history. While a patient is under treatment, it is important to be alert for signs of adverse effects such as digestive upset, changes in the blood, or signs of allergy, such as hives or skin rashes. **Anaphylaxis** is an immediate and severe allergic reaction that may be caused by a drug. It can lead to life-threatening respiratory distress and circulatory collapse.

Because drugs given in combination may interact, the prescriber must know of any drugs the patient is taking before prescribing another. In some cases, a combination may result in **synergy** or **potentiation**, meaning that the drugs together have a greater effect than either of the drugs acting alone. In other cases, one drug may act as an **antagonist** of another, interfering with its action. Drugs may also react adversely with certain foods or substances used socially, such as alcohol and tobacco.

Drugs that act on the central nervous system may lead to psychological or physical **substance dependence**, in which a person has a chronic or compulsive need for a drug regardless of its bad effects. With repeated use, a drug **tolerance** may develop, whereby a constant dose has less effect, and the dose must be increased to produce the original response. Cessation of the drug then leads to symptoms of substance **withdrawal**, a state that results from a drug's removal or dose reduction. Certain symptoms are associated with withdrawal from specific drugs.

DRUG NAMES

Drugs may be cited by either their generic or **brand names.** The **generic name** is usually a simple version of the chemical name for the drug and is not capitalized. The brand name (trade name, proprietary name) is a registered trademark of the manufacturer and is written with an initial capital letter. For example, Tylenol is the brand name for the analgesic compound acetaminophen; the antidepressant Prozac is fluoxetine. A brand name is protected by a patent; only the company that holds the patent can produce and sell that drug under its brand name until the patent expires. Appendix 10 has many more examples of generic and brand names. Note that the same drug may be marketed by different companies under different brand names. Both Motrin and Advil, for example, are the generic anti-inflammatory agent ibuprofen.

DRUG INFORMATION

In the United States, the standard for drug information is the *United States Pharmacopeia* (USP). This reference is published by a national committee of pharmacologists and other scientists. It contains formulas for drugs sold in the United States; standards for testing the strength, quality, and purity of drugs; and standards for the preparation and dispensing of drugs. The American Society of Health System Pharmacists (ASHP) publishes extensive drug information, and the *Physicians' Desk Reference* (PDR), published yearly by Thomson Healthcare, contains information supplied by drug manufacturers. An enormous amount of drug information is available online through the websites for these publications and others. Another excellent source of up-to-date information on drugs is a community or hospital pharmacist.

Herbal Medicines

For hundreds of years, people have used plants to treat diseases, a practice described as herbal medicine or **phytomedicine.** Many people in industrialized countries are now turning to herbal products as alternatives or complements to conventional medicines. Although plants are the source of many conventional drugs, pharmaceutical companies usually purify, measure, and often modify or synthesize the active ingredients in these plants rather than presenting them in their natural states.

Some issues have arisen with the increased use of herbal medicines and nutritional supplements, including questions about their purity, safety, concentration, and efficacy. Another issue is drug interactions. Healthcare providers should ask about the use of herbal remedies when taking a patient's drug history, and patients should report any herbal medicines they take when under treatment. The FDA does not test or verify herbal medicines, and there are no requirements to report adverse effects. There are, however, restrictions on the health claims that can be made by the manufacturers of herbal medicines. The U.S. government has established the Office of Dietary Supplements (ODS) to support and coordinate research in this field.

extern.ir

Terminology *Key Terms*

The terms listed below are emphasized in this chapter. Knowing them will help you organize and prioritize your learning. These boldface terms are also found, collectively, with all chapter key terms in the Glossary.

Drugs

anaphylaxis *an-ah-fih-LAK-sis*	An extreme allergic reaction that can lead to respiratory distress, circulatory collapse, and death
antagonist *an-TAG-o-nist*	A substance that interferes with or opposes the action of a drug
brand name	The trade or proprietary name of a drug, a registered trademark of the manufacturer; written with an initial capital letter
contraindication *kon-trah-in-dih-KA-shun*	A factor that makes the use of a drug undesirable or dangerous
drug	A substance that alters body function
efficacy *EF-ih-kah-se*	The power to produce a specific result; effectiveness
generic name *jeh-NER-ik*	The nonproprietary name of a drug; that is, a name that is not privately owned or trademarked; usually a simplified version of the chemical name; not capitalized
phytomedicine *fi-to-MED-ih-sin*	Another name for herbal medicine (root *phyt/o* meaning "plant")
potentiation *po-ten-she-A-shun*	Increased potency created by two drugs acting together
prescription (Rx) *pre-SKRIP-shun*	Written and signed order for a drug with directions for its administration
side effect	A result of drug therapy or other therapy that is unrelated to or an extension of its intended effect; usually applies to an undesirable effect of treatment
substance dependence	A condition that may result from chronic use of a drug, in which a person has a chronic or compulsive need for a drug regardless of its adverse effects; dependence may be psychological or physical
synergy *SIN-er-je*	Combined action of two or more drugs working together to produce an effect greater than any of the drugs could produce when acting alone; also called synergism (*SIN-er-jizm*); adjective: synergistic (*sin-er-JIS-tik*)
tolerance	A condition in which chronic use of a drug results in loss of effectiveness and the dose must be increased to produce the original response
withdrawal	A condition that results from abrupt cessation or reduction of a drug that has been used regularly

Appendix 10 has a reference chart (A10-1) on common drugs and their actions, with select examples in each category according to generic and brand names. A second chart (A10-2) lists some common herbal medicines and their therapeutic uses. Drug information also appears within chapters on individual systems, but Appendix 10 is available as a general reference as you study.

Drug Administration

The next section provides reference information and illustrations on drug preparations and routes of administration. **BOX 3-7** has information on routes of administration, **BOX 3-8** describes drug preparations, and **BOX 3-9** lists terms pertaining to injectable drugs.

extern.ir

FOR YOUR REFERENCE

BOX 3-7

Routes of Drug Administration

Route	Description
BY ABSORPTION	
absorption *ab-SORP-shun*	drug taken into the circulation through the digestive tract or by transfer across another membrane
inhalation *in-hah-LA-shun*	administration through the respiratory system, as by breathing in an aerosol or nebulizer spray (**FIG. 3-20**)
instillation *in-stil-LA-shun*	liquid is dropped or poured slowly into a body cavity or on the surface of the body, such as into the ear or onto the conjunctiva of the eye (**FIG. 3-21**)
oral *OR-al*	given by mouth; per os (po)
rectal *REK-tal*	administered by rectal suppository or enema
sublingual (SL) *sub-LING-gwal*	administered under the tongue
topical *TOP-ih-kal*	applied to the surface of the skin
transdermal *trans-DER-mal*	absorbed through the skin, as from a patch placed on the surface of the skin
BY INJECTION	
injection *in-JEK-shun*	administered by a needle and syringe (**FIG. 3-22**); described as parenteral (*pah-REN-ter-al*) routes of administration
epidural *ep-ih-DUR-al*	injected into the space between the meninges (membranes around the spinal cord) and the spine
hypodermoclysis *hi-po-der-MOK-lih-sis*	administration of a solution by subcutaneous infusion; useful for fluid delivery as an alternative for intravenous infusion
intradermal (ID) *in-trah-DER-mal*	injected into the skin
intramuscular (IM) *in-trah-MUS-ku-lar*	injected into a muscle
intravenous (IV) *in-trah-VE-nus*	injected into a vein
spinal (intrathecal) *in-trah-THE-kal*	injected through the meninges into the spinal fluid
subcutaneous (SC) *sub-ku-TA-ne-us*	injected beneath the skin; hypodermic

extern.ir

FIGURE 3-20 Inhalation of a drug. The patient is using a metered-dose inhaler for drug administration.

FIGURE 3-21 Instillation of a drug. A practitioner pulls down the lower lid to administer eye drops into the lower conjunctival sac.

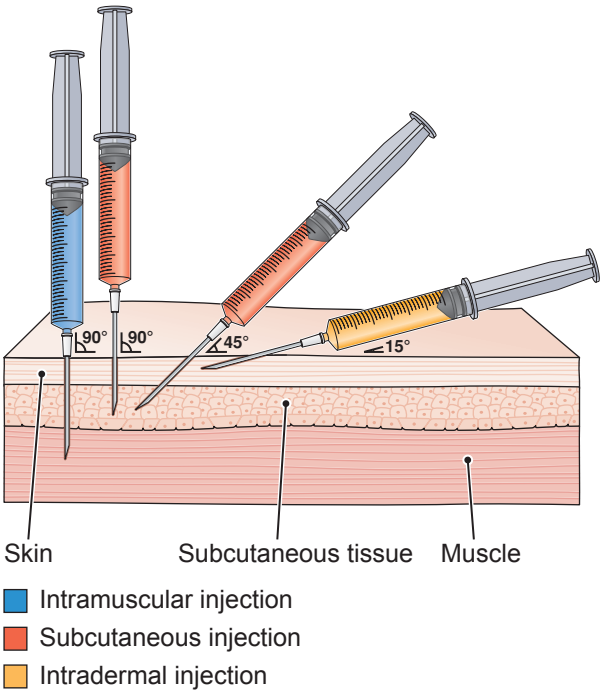

FIGURE 3-22 Injection. Comparison of the angles of insertion for intramuscular, subcutaneous, and intradermal injections.

extern.ir

FOR YOUR REFERENCE
Drug Preparations

BOX 3-8

Form	Description
LIQUID	
aerosol *AIR-o-sol*	solution dispersed as a mist to be inhaled
aqueous solution *AKE-we-us*	substance dissolved in water
elixir (elix) *e-LIK-sar*	a clear, pleasantly flavored and sweetened hydroalcoholic liquid intended for oral use
emulsion *e-MUL-shun*	a mixture in which one liquid is dispersed but not dissolved in another liquid
lotion *LO-shun*	solution prepared for topical use
suspension (susp) *sus-PEN-shun*	fine particles dispersed in a liquid, must be shaken before use
tincture (tinct) *TINK-chur*	substance dissolved in an alcoholic solution
SEMISOLID	
cream *kreme*	a semisolid emulsion used topically
ointment (ung) *OYNT-ment*	drug in a base that keeps it in contact with the skin
SOLID	
capsule (cap) *KAP-sule*	material in a gelatin container that dissolves easily in the stomach
lozenge *LOZ-enj*	a pleasant-tasting medicated tablet or disk to be dissolved in the mouth, such as a cough drop
suppository (supp) *su-POZ-ih-tor-e*	substance mixed and molded with a base that melts easily when inserted into a body opening
tablet (tab) *TAB-let*	a solid dosage form containing a drug in a pure state or mixed with a nonactive ingredient and prepared by compression or molding, also called a pill

extern.ir

FOR YOUR REFERENCE
Terms Pertaining to Injectable Drugs

BOX 3-9

Term	Meaning
ampule *AM-pule*	a small sealed glass or plastic container used for sterile intravenous solutions (**FIG. 3-23**)
bolus *BO-lus*	a concentrated amount of a diagnostic or therapeutic substance given rapidly intravenously
catheter *KATH-eh-ter*	a thin tube that can be passed into a body cavity, organ, or vessel (**FIG. 3-24**)
syringe *sir-INJ*	an instrument for injecting fluid (see **FIG. 3-23**)
vial *VI-al*	a small glass or plastic container (see **FIG. 3-23A**)

A

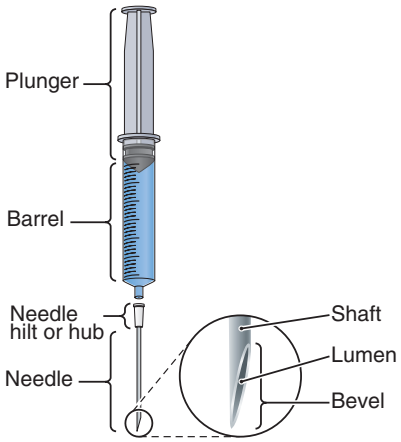

B

FIGURE 3-23 Injectable drug materials. **A.** Injectable drug containers. An ampule (*top left*), a vial (*top right*), and a syringe (*bottom*) are shown. **B.** Parts of a needle and syringe.

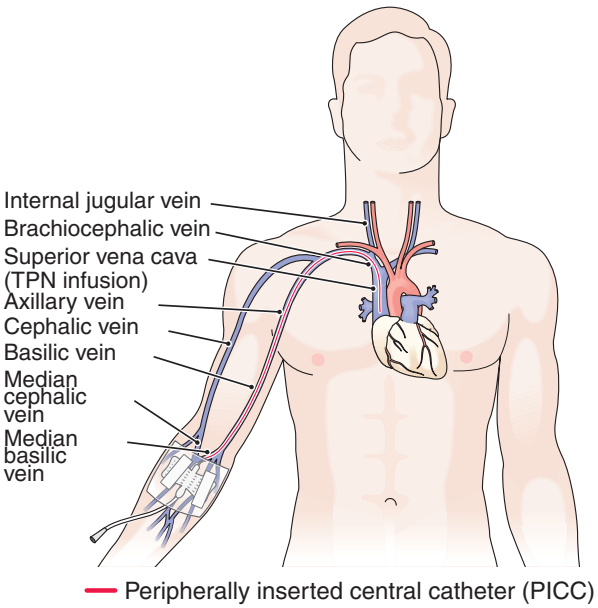

FIGURE 3-24 Catheter. Shown is placement of a peripherally inserted central catheter (PICC).

extern.ir

Word Parts Pertaining to Drugs

TABLE 3-9 lists word parts pertaining to drugs.

Table 3-9 Word Parts Pertaining to Drugs

	Meaning	Example	Definition of Example
Suffixes			
-lytic (adjective of lysis)	dissolving, reducing, loosening	thrombolytic *throm-bo-LIT-ik*	agent that dissolves a blood clot (thrombus)
-mimetic	mimicking, simulating	sympathomimetic *sim-pah-tho-mih-MET-ik*	mimicking the effects of the sympathetic nervous system
-tropic	acting on	psychotropic *si-ko-TROP-ik*	acting on the mind (psych/o)
Prefixes			
anti-	against	antiemetic *an-te-eh-MET-ik*	drug that prevents vomiting (emesis)
contra-	against, opposite, opposed	contraceptive *kon-trah-SEP-tiv*	preventing conception
counter-	against, opposed	countertransport *kown-ter-TRANS-port*	movement in an opposite direction
Roots			
alg/o, algi/o, algesi/o	pain	algesia *al-JE-ze-ah*	sense of pain
chem/o	chemical	chemotherapy *ke-mo-THER-ah-pe*	treatment with drugs
hypn/o	sleep	hypnosis *hip-NO-sis*	induced state of sleep
narc/o	stupor	narcotic *nar-KOT-ik*	agent that induces a state of stupor with decreased sensation
pharm, pharmac/o	drug, medicine	pharmacy *FAR-mah-se*	the science of preparing and dispensing drugs, or the place where these activities occur
pyr/o, pyret/o	fever	antipyretic *an-te-pi-RET-ik*	counteracting fever
tox/o, toxic/o	poison, toxin	toxicity *tok-SIS-ih-te*	state of being poisonous
vas/o	vessel	vasodilation *vas-o-di-LA-shun*	widening of a vessel

Exercise 3-9

Complete the exercise. To check your answers go to Appendix 11.

Identify and define the suffix in each of the following words.

	Suffix	Meaning of Suffix
1. hemolytic (*he-mo-LIT-ik*)	_____	_____
2. hydrotropic (*hi-dro-TROP-ik*)	_____	_____
3. parasympathomimetic (*par-ah-sim-pah-tho-mih-MET-ik*)	_____	_____

extern.ir

Exercise 3-9 *(Continued)*

Using the prefixes listed in **TABLE 3-9**, write the opposite of each of the following words.

4. bacterial _____
5. lateral _____
6. septic _____
7. act _____
8. emetic _____
9. pyretic _____

Identify and define the root in each of the following words.

	Root	Meaning of Root
10. narcosis (*nar-KO-sis*)	_____	_____
11. chemistry (*KEM-is-tre*)	_____	_____
12. analgesia (*an-al-JE-ze-ah*)	_____	_____
13. toxicology (*tok-sih-KOL-o-je*)	_____	_____
14. hypnotic (*hip-NOT-ik*)	_____	_____

Define each of the following words.

15. vasodilation (*va-so-di-LA–shun*) _____
16. pharmacology (*far-mah-KOL-o-je*) _____
17. mucolytic (*mu-ko-LIT-ik*) _____
18. gonadotropic (*go-nad-o-TROP-ik*) _____

Terminology *Abbreviations*

The abbreviations listed below are emphasized in this chapter. These are also found, collectively, with all chapter abbreviations in Appendix 2.

Drugs and Drug Formulations

APAP	Acetaminophen
ASA	Acetylsalicylic acid (aspirin)
ASHP	American Society of Health System Pharmacists
cap	Capsule
elix	Elixir
FDA	Food and Drug Administration
INH	Isoniazid (antituberculosis drug)
MED(s)	Medicine(s), medication(s)
NSAID(s)	Nonsteroidal anti-inflammatory drug(s)
ODS	Office of Dietary Supplements
OTC	Over-the-counter
PDR	*Physicians' Desk Reference*
Rx	Prescription
supp	Suppository
susp	Suspension
tab	Tablet
tinct	Tincture
ung	Ointment
USP	*United States Pharmacopeia*

Dosages and Directions

ā	Before (Latin, *ante*)

(continued)

extern.ir

Terminology *Abbreviations (Continued)*

āā	Of each (Greek, *ana*)
ac	Before meals (Latin, *ante cibum*)
ad lib	As desired (Latin, *ad libitum*)
aq	Water (Latin, *aqua*)
bid, b.i.d.	Twice a day (Latin, *bis in die*)
c̄	With (Latin, *cum*)
DAW	Dispense as written
D/C, dc	Discontinue
DS	Double strength
hs	At bedtime (Latin, *hora somni*)
ID	Intradermal(ly)
IM	Intramuscular(ly)
IU	International unit
IV	Intravenous(ly)
LA	Long-acting
mcg	Microgram
mg	Milligram
mL	Milliliter
p	After, post
pc	After meals (Latin, *post cibum*)
po, PO	By mouth (Latin, *per os*)
pp	Postprandial (after a meal)
prn	As needed (Latin, *pro re nata)*
qam	Every morning (Latin, *quaque ante meridiem*)
qh	Every hour (Latin, *quaque hora*)
q __ h	Every _____ hours
qid, q.i.d.	Four times a day (Latin, *quater in die*)
s̄	Without (Latin, *sine*)
SA	Sustained action
SC, SQ, subcut	Subcutaneous(ly)
SL	Sublingual(ly)
SR	Sustained release
s̄s̄	Half (Latin, *semis*)
tid, t.i.d.	Three times per day (Latin, *ter in die*)
U	Unit(s)
x	Times

Case Study Revisited

Mary's Injury Follow-Up

Mary was seen by the orthopedic surgeon who scheduled an OR and performed a surgical procedure by making an incision to directly access the broken bones to improve alignment (open reduction). A plate and screws were inserted to hold the bones in the proper place. Generally, the plate stays in permanently, causes no problems, and usually does not set off airport alarms. Mary was then scheduled for an arthrocentesis to remove fluid from the right knee. After an overnight stay in the hospital Mary was discharged to home. The physical therapist (PT) gave Mary educational material on how to safely be mobile at home and guided her through some exercises.

Since Mary's gait was a bit unsteady the PT sent her home with a platform walker, which is designed for those who are unable to grip the walker. A large top bracket allows the platform attachment to be placed over the right or left hand grip of the walker. In Mary's case placement was over the right-hand grip with an adjustable strap to secure the arm in place. The surgeon directed Mary to take an anti-inflammatory medication (NSAID) for the inflammation and pain. She said that postoperative fractures hurt moderately for a few days to a couple of weeks. She also instructed that using ice, elevation (holding her right arm up above her heart) in addition to the NSAID should be all that would be needed to relieve pain. The surgeon also scheduled several clinic visits with Mary to closely monitor the healing by taking regular x-rays and checking the incision site.

extern.ir

CHAPTER 3

Review

These questions test your understanding of the content introduced in this chapter. Follow the instructions for each exercise and check your answers in Appendix 11.

Match the following terms, and write the appropriate letter to the left of each number.

____ 1. cardiomegaly	a. pertaining to profuse flow of blood
____ 2. neuroma	b. fear of cancer
____ 3. carcinophobia	c. tumor of a nerve
____ 4. encephalitis	d. enlargement of the heart
____ 5. hemorrhagic	e. inflammation of the brain

____ 6. sclerotic	a. stone formation
____ 7. oncolysis	b. dry
____ 8. analgesia	c. destruction of a tumor
____ 9. xerotic	d. absence of pain
____ 10. lithiasis	e. hardened

____ 11. blepharoptosis	a. local wound or injury
____ 12. hemostasis	b. stoppage of blood flow
____ 13. toxoid	c. dropping of the eyelid
____ 14. lesion	d. like a poison
____ 15. ectasia	e. dilatation

____ 16. electrolyte	a. substance that conducts electric current
____ 17. staging	b. evidence of disease
____ 18. symptom	c. classification of malignant tumors
____ 19. syndrome	d. a group of symptoms that characterizes a disease
____ 20. suture	e. to unite parts by stitching them together

____ 21. cautery	a. a removal of tissue for microscopic study
____ 22. scintiscan	b. pain caused by cold
____ 23. cryalgesia	c. destruction of tissue with a damaging agent
____ 24. vasotripsy	d. image obtained with a radionuclide
____ 25. biopsy	e. crushing of a vessel

____ 26. hyperpyrexia	a. extreme allergic reaction
____ 27. potentiation	b. effectiveness
____ 28. chronotropic	c. affecting timing
____ 29. anaphylaxis	d. combined drug action to greater effect
____ 30. efficacy	e. abnormally high body temperature

extern.ir

Enrichment Terms

____ 31. nosocomial	a. abnormal passageway
____ 32. iatrogenic	b. escape of fluid into a cavity
____ 33. fistula	c. tumor attached by a thin stalk
____ 34. polyp	d. acquired in a hospital
____ 35. effusion	e. caused by effects of treatments

____ 36. sequelae	a. partial excision
____ 37. prophylaxis	b. prevention of disease
____ 38. clubbing	c. symptom indicating an approaching disease
____ 39. prodrome	d. lasting effects of disease
____ 40. resection	e. enlargement of the ends of the fingers and toes

____ 41. catheter	a. thin tube
____ 42. colic	b. feeling of discomfort
____ 43. diaphoresis	c. acute abdominal pain
____ 44. malaise	d. washing out of a cavity
____ 45. lavage	e. profuse sweating

FILL IN THE BLANKS

Complete the sentence with the correct term(s).

46. Heat, pain, redness, and swelling are the four major signs of _____ .
47. Any abnormal and uncontrolled growth of tissue, whether benign or malignant, is called a(n) _____ .
48. The spreading of cancer to other parts of the body is the process of _____ .
49. Protrusion of an organ through an abnormal opening is a(n) _____ .
50. Death of tissue is called _____ .
51. An oncoprotein is a protein associated with a(n) _____ .
52. The common name for a helminth is a(n) _____ .
53. The PA in Mary's case evaluated her wrist by touching it. The term for this examination technique is _____ .
54. Following her examination, the PA predicted the outcome of Mary's injuries; that is, she gave a(n) _____ .
55. In the same case study, the adjective form of edema is _____ .
56. Another word for *treatment* is _____ .
57. Photochromic eyeglass lenses change color in response to _____ .
58. Plastic repair of the stomach is called _____
59. Fusion of a joint is _____ .
60. Surgical creation of an opening in the colon is a(n) _____ .
61. A transdermal route of administration is through the _____ .
62. When a drug has lost its effect at a constant dose, the patient has developed _____ .
63. An intravenous injection is given into a(n) _____ .
64. With reference to drug interactions, another term for synergy is _____ .

extern.ir

Use Appendix 10 to answer the following six questions.

65. Any drug that promotes excretion by the kidney is a(n) _____ .
66. Any drug that relieves nausea and prevents vomiting is (a)n _____ .
67. Analgesics are used to eliminate _____ .
68. Any drug that affects the mind is described as a(n) _____ .
69. Flax is an herbal substance that is supplies _____ .
70. The part of the aloe plant that is used for treatment is the _____ .

Use the root -hepat/o, meaning "liver," to write a word for each of the following.

71. Incision of the liver _____
72. Excision of liver tissue _____
73. Surgical fixation of the liver _____
74. Surgical repair of the liver _____

Use the suffix -genesis to write words with the following meanings.

75. Formation of cancer _____
76. Origin of any disease _____
77. Formation of pus _____
78. Formation of a tumor _____

The root bronch/o pertains to a bronchus, an air passageway in the lungs. Add a suffix to this root to form words with the following meanings.

79. Excessive flow or discharge from a bronchus _____
80. Inflammation of a bronchus _____
81. Narrowing of a bronchus _____
82. Sudden contraction of a bronchus _____

Use the root oste/o, meaning "bone," to form words with the following meanings.

83. Pain in a bone _____
84. Death of bone tissue _____
85. Tumor of a bone _____
86. Breaking of a bone _____
87. Softening of a bone _____

extern.ir

TRUE–FALSE

Examine the following statements. If the statement is true, write T in the first blank. If the statement is false, write F in the first blank, and correct the statement by replacing the underlined word in the second blank.

	True or False	Correct Answer
88. A mycosis is an infection with a protozoon.	_____	_____
89. Round bacteria in chains are streptococci.	_____	_____
90. A sudden disease of short duration is chronic.	_____	_____
91. A tumor that does not metastasize is termed benign.	_____	_____
92. A slower than normal heart rate is tachycardia.	_____	_____
93. An otoscope is used to examine the eye.	_____	_____
94. An image produced by x-rays is a radiogram.	_____	_____
95. Arthroscopy is endoscopic examination of a joint.	_____	_____

ELIMINATIONS

In each of the sets below, underline the word that does not fit in with the rest, and explain the reason for your choice.

96. cocci — helminths — chlamydia — bacilli — vibrios

_____

97. septicemic — endemic — metastatic — opportunistic — epidemic

_____

98. percussion — inspection — palpation — remission — auscultation

_____

99. ophthalmoscope — sphygmomanometer — stethoscope — syncope — endoscope

_____

100. solution — elixir — tincture — emulsion — tablet

_____

WORD BUILDING

Use the word parts given to build words for the following definitions. Each word part can be used more than once.

tox	pyr	gen	o	py	-oma	-y	path	nephr	-logy	-ic

101. poisonous for the kidney _____
102. producing pus _____
103. tumor of the kidney _____
104. study of disease _____
105. producing fever _____
106. study of the kidney _____
107. producing disease _____
108. any disease of the kidney _____
109. producing kidney tissue _____

extern.ir

WORD BUILDING

Use the word parts given to build words for the following definitions. Each word part can be used more than once.

lith/o	-rhaphy	neur/o	-tripsy	-tome	r	-pexy	-scopy	cyst/o

110. Crushing of a nerve _____
111. Surgical repair of the bladder _____
112. Surgical fixation of the bladder _____
113. Surgical repair of a nerve _____
114. Crushing of a stone _____
115. Bladder stone _____
116. Endoscopic examination of the bladder _____
117. Instrument used to incise a nerve _____
118. Instrument used to incise the bladder _____

WORD ANALYSIS

Define the following words, and give the meanings of the word parts in each. Use a dictionary if necessary.

119. phagocytosis (*fag-o-si-TO-sis*)
    a. phag/o _____
    b. cyt/o _____
    c. -sis _____
120. antipyretic (*an-te-pi-RET-ik*)
    a. anti- _____
    b. pyret/o _____
    c. -ic _____
121. arteriosclerosis (*ar-te-re-o-skleh-RO-sis*)
    a. arterio/o _____
    b. scler/o _____
    c. -sis _____
122. asymmetric (*a-sim-ET-rik*)
    a. a- _____
    b. sym- _____
    c. metr/o _____
    d. -ic _____

extern.ir

Additional Case Studies

Case Study 3-1: Endocarditis

Robert, a 37 y/o man, sought treatment after experiencing several days of high fever and generalized weakness on return from his vacation. Robert's family doctor suspected cardiac involvement because of Robert's history of rheumatic fever. The doctor was concerned because Robert's brother had died of acute malignant hyperpyrexia during surgery at the age of 12. Robert was referred to a cardiologist, who scheduled an electrocardiogram (ECG) and a transesophageal echocardiogram (TEE).

Robert was admitted to the hospital with subacute bacterial endocarditis (SBE) and placed on high-dose IV antibiotics and bed rest. He had also developed a heart murmur, which was diagnosed as idiopathic hypertrophic subaortic stenosis (IHSS).

Case Study 3-1 Questions

Follow the instructions for each question and check your answers in Appendix 11.

Multiple Choice. *Select the best answer, and write the letter of your choice to the left of each number.*

_____ 1. The endocardium is the tissue lining the heart's chambers. Endocarditis refers to a(n) _____ of this lining.
   a. narrowing
   b. inflammation
   c. overgrowth
   d. thinning

_____ 2. Robert's heart murmur was caused by a stenosis, or _____ of the heart's aortic valve.
   a. narrowing
   b. inflammation
   c. overgrowth
   d. cancer

_____ 3. The term for a condition or disease of unknown etiology is
   a. iatrogenic
   b. chronic
   c. acute
   d. idiopathic

_____ 4. A term that describes increase in the size of an organ without increase in the number of cells is
   a. hyperplastic
   b. fistular
   c. hypertrophic
   d. metaplastic

Give the meaning of the following abbreviations.

5. ECG _____
6. TEE _____
7. SBE _____
8. IHSS _____

extern.ir

Case Study 3-2: Asthma

Chelsea, a 20 y/o woman with asthma, visited the preadmission testing unit 1 week before her cosmetic surgery to meet with the nurse and anesthesiologist. Her current meds included several bronchodilators, which she takes by mouth and by inhalation, and a tranquilizer that she takes when needed for nervousness. She sometimes receives inhalation treatments with Mucomyst, a mucolytic agent. On Chelsea's preoperative note, the nurse wrote:

Theo-Dur 1 cap 200 mg t.i.d.
Flovent inhaler 1 spray (50 mcg each nostril b.i.d.)
Ativan (lorazepam) 1 mg po b.i.d.
Albuterol metered-dose inhaler 2 puffs (180 mcg) p.r.n. q4–6h for bronchospasm and before exercise

Chelsea stated that she has difficulty with her asthma when she is anxious and when she exercises. She also admitted to occasional use of marijuana and ecstasy, a hallucinogen and mood-altering illegal recreational drug. The anesthesiologist wrote an order for lorazepam 4 mg IV 1 hour preop. The plastic surgeon recommended several supplements to complement her surgery and her recovery. He ordered a high-potency vitamin, 1 tab with breakfast and dinner, to support tissue health and healing. He also prescribed bromelain, an enzyme from pineapple, to decrease inflammation, one 500 mg cap po q.i.d. 3 days before surgery and postoperatively for 2 weeks. Arnica montana was prescribed to decrease discomfort, swelling, and bruising; three tabs sublingual t.i.d. the evening after surgery and for the following 10 days.

Case Study 3-2 Questions

Follow the instructions for each question and check your answers in Appendix 11.

Multiple Choice. *Select the best answer, and write the letter of your choice to the left of each number.*

_____ 1. Chelsea's Flovent inhaler is indicated as 1 spray of 50 mcg in each nostril b.i.d. How many micrograms (mcg) does she get in 1 day?
a. 100 mcg
b. 200 mcg
c. 250 mcg
d. 500 mcg

_____ 2. As noted in Appendix 10, the Ativan that E.N. takes for nervousness is a(n) _____ drug.
a. anxiolytic
b. antiemetic
c. analgesic
d. bronchodilator

_____ 3. The anesthesiologist ordered lorazepam (Ativan) to be given IV preop to decrease anxiety and to smooth Chelsea's anesthesia induction. The complementary way that lorazepam and anesthesia work together is called
a. antagonistic
b. complementary medicine
c. synergy
d. tolerance

_____ 4. Bromelain and Arnica montana are supplements that can be described as all of the following except
a. phytopharmaceutical
b. alternative
c. chronotropic
d. complementary

_____ 5. Arnica montana was prescribed three tabs SL t.i.d. How many tablets would Chelsea take in 1 day?
a. 6
b. 33
c. 12
d. 9

_____ 6. Flovent is administered as an inhalant. The form in which the drug is prepared is called a(n)
a. aerosol
b. elixir
c. unguent
d. emulsion

extern.ir

Define each of the following abbreviations.

7. po _____
8. mg _____
9. mcg _____
10. IV _____

extern.ir

PART II

Body Systems

Chapter 4 Integumentary System
Chapter 5 Skeletal System
Chapter 6 Muscular System
Chapter 7 Nervous System and Mental Health
Chapter 8 Special Senses: Ear and Eye
Chapter 9 Endocrine System
Chapter 10 Cardiovascular and Lymphatic Systems
Chapter 11 Blood and Immunity
Chapter 12 Respiratory System
Chapter 13 Digestive System
Chapter 14 Urinary System
Chapter 15 Male Reproductive System
Chapter 16 Female Reproductive System; Pregnancy and Birth

extern.ir

CHAPTER 4

Integumentary System

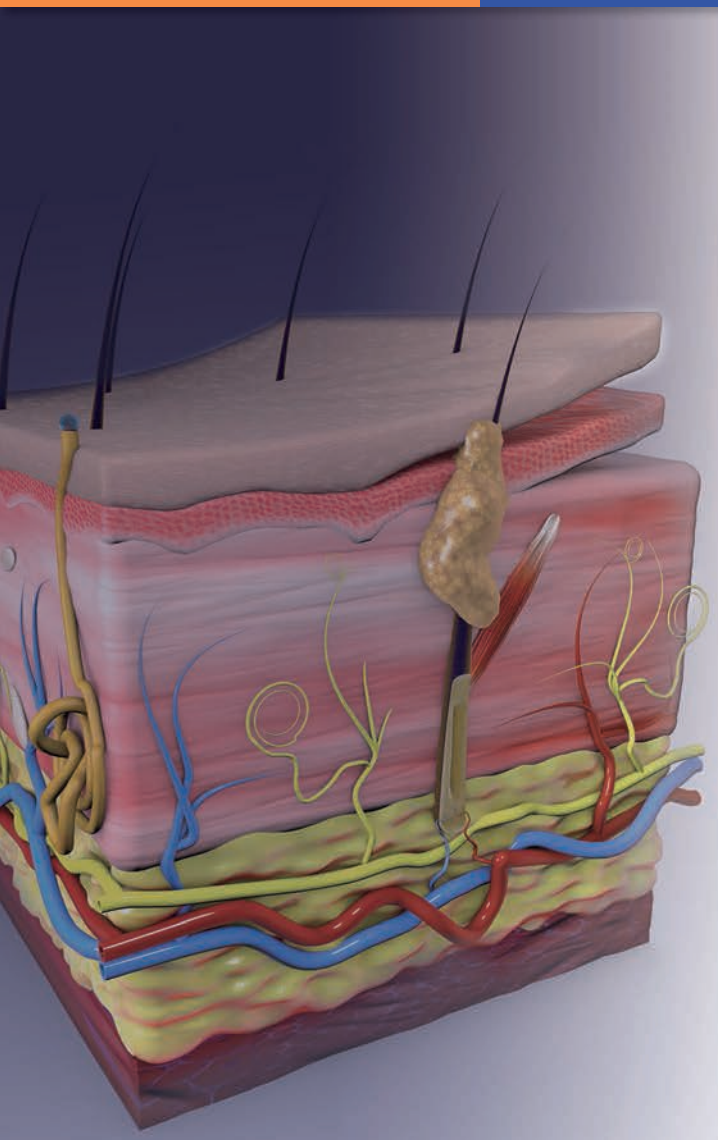

Pretest

Multiple Choice. **Select the best answer, and write the letter of your choice to the left of each number. To check your answers go to Appendix 11.**

_____ 1. The uppermost portion of the skin is called the
   a. fossa
   b. cuticle
   c. epidermis
   d. epiphysis

_____ 2. The glands that secrete an oily substance that lubricates the skin are the
   a. mammary glands
   b. sebaceous glands
   c. sweat glands
   d. ceruminous glands

_____ 3. The rule of nines is a system used to evaluate
   a. burns
   b. fever
   c. immunity
   d. inflammation

_____ 4. A pigmented skin tumor is a(n)
   a. chondrosarcoma
   b. melanoma
   c. lymphoma
   d. adenoma

_____ 5. The root *hidr/o* pertains to
   a. saliva
   b. tears
   c. mucus
   d. sweat

_____ 6. Onychomycosis is a fungal infection of a(n)
   a. eyelid
   b. hair
   c. nail
   d. bone

extern.ir

Learning Objectives

After careful study of this chapter, you should be able to:

1. Define and list the functions of the integumentary system. ***P126***
2. Compare the locations and structures of the epidermis, dermis, and subcutaneous tissues. ***P126***
3. Describe the roles of keratin and melanin in the skin. ***P126***
4. Name and describe the glands in the skin. ***P126***
5. Describe the structure of hair and nails. ***P127***
6. Identify and use roots pertaining to the integumentary system. ***P129***
7. Describe the main disorders that affect the skin. ***P130***
8. Interpret abbreviations used in the study and treatment of the skin. ***P141***
9. Identify and analyze medical terms and abbreviations in chapter case studies. ***PP125, 148***

Case Study: Kathleen's Pressure Ulcer

Chief Complaint

Kathleen, an elderly woman in failing health, had recently moved in with her daughter after her hospitalization for a stroke. The daughter reported to the home care nurse that her mother had minimal appetite and was confused and disoriented and that a blister had developed on her lower back since she had been confined to bed.

Examination

During the biweekly visit, the home care nurse spoke with the daughter and then went in to see the mother. On her initial assessment, the nurse noted that Kathleen had lost weight since her last visit and that her skin was dry, with poor skin turgor pressure. She also observed that the mother was wearing an "adult diaper," which was wet. The nurse took the mother's BP, HR, and R, which were normal. She assessed the mother's mental status and then proceeded to a skin assessment paying special attention to the bony prominences. After examining Kathleen's sacrum, the nurse noted a nickel-sized open area, 2 cm in diameter and 1 cm in depth (stage II pressure ulcer), with a 0.5-cm reddened surrounding area with no drainage. Kathleen moaned when the nurse palpated the lesion. The nurse also noted reddened areas on Kathleen's elbows and heels. The remainder of the examination saw no change from the previous visit.

Clinical Course

The nurse provided Kathleen's daughter with instructions for proper skin care, incontinence management, enhanced nutrition, and frequent repositioning to prevent pressure ischemia to the prominent body areas. However, 6 months later, Kathleen's pressure ulcer had deteriorated to class III. She was hospitalized under the care of a plastic surgeon and wound care nurse. Surgery was scheduled for debridement of the sacral wound and closure with a full-thickness skin graft (FTSG) taken from her thigh. Kathleen was discharged 8 days later to a long-term care facility with orders for an alternating pressure mattress, position change every 2 hours, supplemental nutrition, and meticulous wound care.

Case Study Revisited: Once you complete this chapter, please review the case follow-up on p. 142.

Ancillaries *At-A-Glance*

Visit the web resource to access the following resources.

extern.ir

Learning Resources

- eBook
- A&P Module with Heart & Lung Sounds
- Image Bank
- TestPrep
- Animations
- Audio Pronunciation Glossary

Introduction

The **skin** and its associated structures make up the **integumentary system**. This body-covering system protects against infection, dehydration, ultraviolet radiation, and injury. Extensive damage to the skin, such as by burns, can result in a host of dangerous complications.

The skin helps to regulate temperature by evaporation of sweat and by changes in the diameter of surface blood vessels, which control how much heat is lost to the environment. The skin also contains receptors for the sensory perceptions of touch, temperature, pressure, and pain. Medication can be delivered through the skin from patches, as explained in **BOX 4-1**.

The word **derma** (from Greek) means "skin" and is used as an ending in words pertaining to the skin, such as xeroderma (dryness of the skin) and scleroderma (hardening of the skin). The adjective **cutaneous** refers to the skin and is from the Latin word *cutis* for skin. Like the eyes, the skin is a readily visible reflection of one's health. Its color, texture, and resilience reveal much, as does the condition of the hair and nails.

Anatomy of the Skin

The skin's outermost portion is the **epidermis**, consisting of four to five layers (strata) of epithelial cells **(FIG. 4-1)**. The deepest epidermal layer, the stratum basale, or basal layer, produces new cells. As these cells gradually rise toward the surface, they die and become filled with **keratin**, a protein that thickens and toughens the skin. The outermost epidermal layer, the stratum corneum or horny layer, is composed of flat, dead, protective cells that are constantly being shed and replaced. Some of the cells in the epidermis produce **melanin**, a pigment that gives the skin color and protects against sunlight. Irregular spots of melanin form freckles.

The **dermis** is beneath the epidermis. It contains connective tissue, nerves, blood vessels, lymphatics, and sensory receptors. This layer supplies nourishment and support for the skin. The **subcutaneous layer** beneath the dermis is composed mainly of connective tissue and fat.

Associated Skin Structures

Specialized structures within the skin are part of the integumentary system:

- The **sweat** (sudoriferous) **glands** act mainly in temperature regulation by releasing a watery fluid that evaporates to cool the body.
- The **sebaceous glands** release an oily fluid, **sebum**, that lubricates the hair and skin and prevents drying.

CLINICAL PERSPECTIVES — BOX 4-1

Medication Patches: No Bitter Pill to Swallow

For most people, pills are a convenient way to take medication, but for some, they have drawbacks. Pills must be taken at regular intervals to ensure consistent dosing, and they must be digested and absorbed into the bloodstream before they can begin to work. For those who have difficulty swallowing or digesting pills, transdermal (TD) patches offer an effective alternative to oral medications.

TD patches deliver a consistent dose of medication that diffuses at a constant rate through the skin into the bloodstream. There is no daily schedule to follow, nothing to swallow, and no stomach upset. TD patches can also deliver medication to unconscious patients, who would otherwise require intravenous drug delivery. TD patches are used in hormone replacement therapy, to treat heart disease, to manage pain, and to suppress motion sickness. Nicotine patches are also used as part of programs to quit smoking.

TD patches must be used carefully. Drug diffusion through the skin takes time, so it is important to know how long the patch must be in place before it is effective. It is also important to know when the medication's effects disappear after the patch is removed. Because the body continues to absorb what has already diffused into the skin, removing the patch does not entirely remove the medicine. There is also a danger that patches may become unsafe when heated, as by exercise, high fever, or a hot environment, such as a hot tub, heating pad, or sauna. When heat dilates the capillaries in the skin, a dangerous increase in dosage may result as more medication enters the blood.

A recent advance in TD drug delivery is iontophoresis. Based on the principle that like charges repel each other, this method uses a mild electrical current to move ionic drugs through the skin. A small electrical device attached to the patch uses positive current to "push" positively charged drug molecules through the skin and a negative current to push negatively charged ones. Even though very low levels of electricity are used, people with pacemakers should not use iontophoretic patches. Another disadvantage of these patches is that they can move only ionic drugs through the skin.

extern.ir

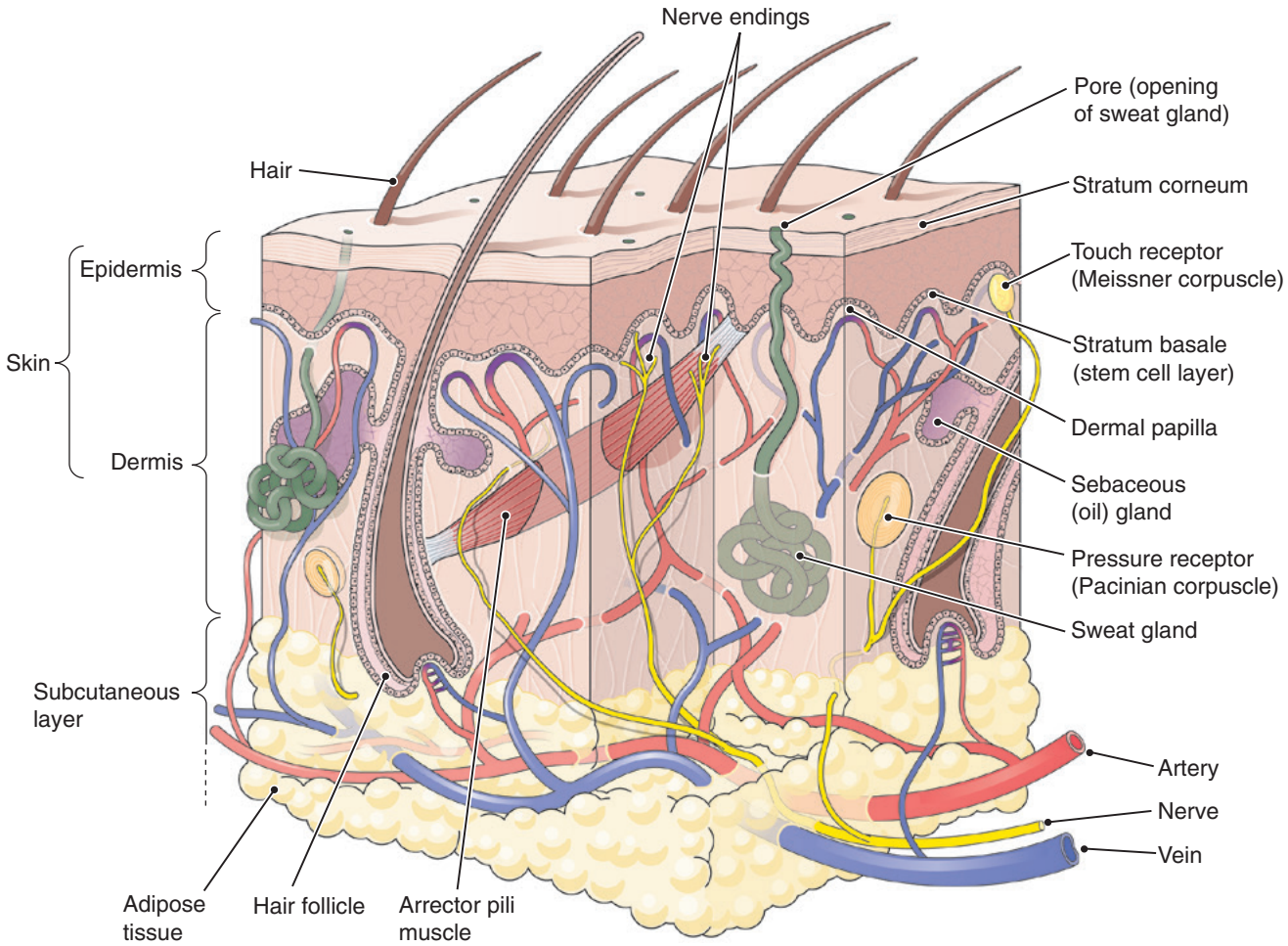

FIGURE 4-1 Cross-section of the skin. The skin layers and associated structures are shown.

- **Hair** is widely distributed over the body. Each hair develops within a sheath or **hair follicle** and grows from its base within the skin's deep layers. A small muscle (arrector pili) attached to the follicle raises the hair to produce "goosebumps" when one is frightened or cold (see **FIG. 4-1**). In animals this is a warning sign and a means of insulation.

- **Nails** develop from a growing region at the proximal end **(FIG. 4-2)**. The cuticle, technically named the eponychium (*ep-o-NIK-e-um*), is an extension of the epidermis onto the surface of the nail plate. A lighter region distal to the cuticle is called the lunula because it looks like a half moon. Here the underlying skin is thicker, and blood does not show as much through the nail.

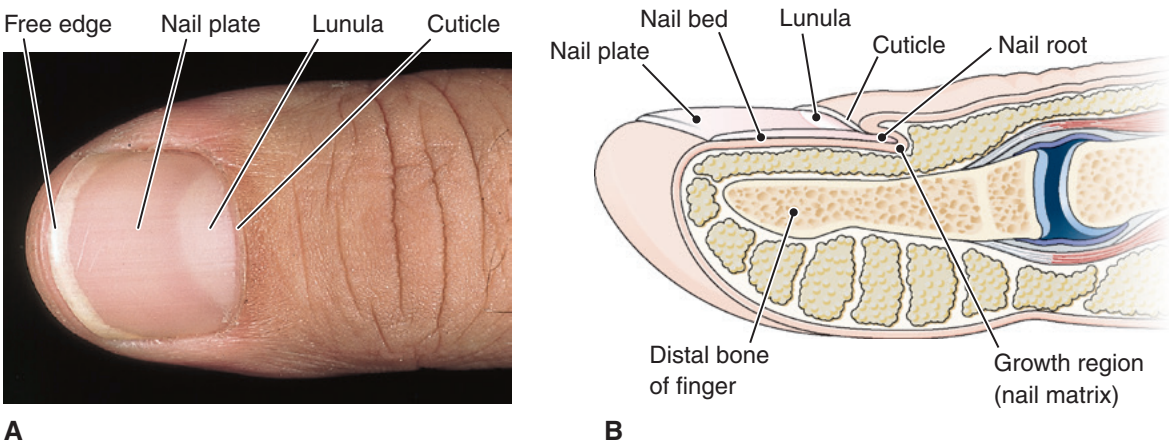

FIGURE 4-2 Nail structure. A. Photograph of a nail, superior view. **B.** Midsagittal section of a fingertip showing the growth region and tissue surrounding the nail plate.

extern.ir

Hair and nails are composed of nonliving material consisting mainly of keratin. Both function in protection.

Terminology *Key Terms*

The terms listed below are emphasized in this chapter. Knowing them will help you organize and prioritize your learning. These boldface terms are also found, collectively, with all chapter key terms in the Glossary.

Normal Structure and Function

cutaneous *ku-TA-ne-us*	Pertaining to the skin (from Latin *cutis*, meaning "skin")
derma *DER-mah*	Skin (from Greek)
dermis *DER-mis*	The layer of the skin between the epidermis and the subcutaneous tissue; the true skin or corium
epidermis *ep-ih-DER-mis*	The outermost layer of the skin (from epi-, meaning "upon or over" and derm, meaning "skin")
hair *har*	A thread-like keratinized outgrowth from the skin (root: trich/o)
hair follicle *FOL-ih-kl*	The sheath in which a hair develops
integumentary system *in-teg-u-MEN-tah-re*	The skin and its associated glands, hair, and nails
keratin *KER-ah-tin*	A protein that thickens and toughens the skin and makes up hair and nails (root: kerat/o)
melanin *MEL-ah-nin*	A dark pigment that gives color to the hair and skin and protects the skin against the sun's radiation (root: melan/o)
nail *nale*	A plate-like keratinized outgrowth of the skin that covers the dorsal surface of the terminal phalanges (root: onych/o)
sebaceous gland *se-BA-shus*	A skin gland that produces sebum; usually associated with a hair follicle (root: seb/o)
sebum *SE-bum*	A fatty secretion of the sebaceous glands that lubricates the hair and skin (root: seb/o)
skin	The tissue that covers the body; the integument (roots: derm/o, dermat/o)
subcutaneous layer *sub-ku-TA-ne-us*	The layer of tissue beneath the skin; also called the hypodermis
sweat gland *swet*	A gland that releases a watery fluid (perspiration) to the skin surface in order to cool the body. Certain sweat glands, located mainly in the armpits and groin area, release secretions with some cellular material in response to stress. A sudoriferous (*su-dor-IF-er-us*) gland. (root: hidr/o)

extern.ir

Roots Pertaining to the Integumentary System

See **TABLE 4-1**.

Table 4-1 Roots Pertaining to the Skin and Associated Structures

Root	Meaning	Example	Definition of Example
derm/o, dermat/o	skin	dermabrasion *derm-ah-BRA-zhun*	surgical procedure used to resurface the skin and remove imperfections
kerat/o	keratin, horny layer of the skin	keratinous *keh-RAT-ih-nus*	containing keratin; horny
melan/o	dark, black, melanin	melanosome *MEL-ah-no-some*	a small cellular body that produces melanin
hidr/o	sweat, perspiration	anhidrosis *an-hi-DRO-sis*	absence of sweating
seb/o	sebum, sebaceous gland	seborrhea *seb-or-E-ah*	excess flow of sebum (adjective: seborrheic)
trich/o	hair	trichomycosis *trik-o-mi-KO-sis*	fungal infection of the hair
onych/o	nail	onychia *o-NIK-e-ah*	inflammation of the nail and nail bed (Note: not an *-itis* ending)

Exercise 4-1

Complete the exercise. To check your answers go to Appendix 11.

Identify and define the roots in the following words.

	Root	Meaning of Root
1. hypodermis (*hi-po-DER-mis*)	_____	_____
2. seborrheic (*seb-o-RE-ik*)	_____	_____
3. hypermelanosis (*hi-per-mel-ah-NO-sis*)	_____	_____
4. dyskeratosis (*dis-ker-ah-TO-sis*)	_____	_____
5. hypohidrosis (*hi-po-hi-DRO-sis*)	_____	_____
6. hypertrichosis (*hi-per-trih-KO-sis*)	_____	_____
7. eponychium (*ep-o-NIK-e-um*)	_____	_____

Fill in the blanks.

8. Dermatopathology (*der-mah-to-pah-THOL-o-je*) is study of diseases of the _____.
9. Keratolysis (*ker-ah-TOL-ih-sis*) is loosening of the skin's _____.
10. A melanocyte (*MEL-ah-no-site*) is a cell that produces _____.
11. Trichoid (*TRIK-oyd*) means resembling a(n) _____.
12. Onychomycosis (*on-ih-ko-mi-KO-sis*) is a fungal infection of a(n) _____.
13. Hidradenitis (*hi-drad-eh-NI-tis*) is inflammation of a gland that produces _____.
14. A hypodermic (*hi-po-DER-mik*) injection is given under the _____.

(continued)

extern.ir

Exercise 4-1 *(Continued)*

Write words for the following definitions.

15. loosening or separation of the skin _____
16. study of the skin and skin diseases _____
17. softening of a nail _____
18. excess production of sweat _____
19. study of the hair _____
20. instrument for cutting the skin _____
21. formation (-genesis) of keratin _____
22. a tumor containing melanin _____

Use *-derma* as a suffix meaning "skin" to write words for the following. Use the word part appendices if needed.

23. hardening of the skin _____
24. presence of pus in the skin _____

Clinical Aspects of the Skin

Many diseases are manifested by changes in the quality of the skin or by specific lesions. Some types of skin lesions are described and illustrated in BOX 4-2 and appear later in photographs of specific skin disorders. The study of the skin and skin diseases is **dermatology**, but careful observation of the skin, hair, and nails should be part of every physical examination. The skin should be examined for color, unusual pigmentation, and lesions. It should be palpated to

FOR YOUR REFERENCE — BOX 4-2
Types of Skin Lesions

Lesion	Description
bulla *BUL-ah*	raised, fluid-filled lesion larger than a vesicle (plural: bullae) (see FIGS. 4-5B and 4-7)
fissure *FISH-ure*	crack or break in the skin
macule *MAK-ule*	flat, colored spot less than 1 cm in size. A larger spot is called a patch
nodule *NOD-ule*	solid, raised lesion larger than a papule; often indicative of systemic disease (see FIG. 4-9)
papule *PAP-ule*	firm, circular, raised surface lesion less than 1 cm in size, such as a pimple (see FIG. 4-8)
plaque *plak*	superficial, flat, or slightly raised differentiated patch more than 1 cm in diameter (see FIG. 4-6)
pustule *PUS-tule*	raised pus-filled lesion; often in a hair follicle or sweat pore (see FIG. 4-13)
ulcer *UL-ser*	lesion resulting from destruction of the skin and perhaps subcutaneous tissue (see FIG. 4-18)
vesicle *VES-ih-kl*	fluid-filled, raised lesion less than 5 mm in size; a blister or bleb
wheal *wele*	smooth, rounded, slightly raised area often associated with itching; seen in urticaria (hives), such as that resulting from allergy (see FIG. 4-17)

extern.ir

HEALTH PROFESSIONS
Nurse Practitioners

BOX 4-3

A nurse practitioner (NP) is a nurse with a professional degree beyond registered nurse (RN) who provides healthcare services similar to those of a physician. All NPs have a master's degree in nursing and postmaster's, or doctoral education. They can specialize in areas such as acute care, family health, neonatology, or gerontology and medical specialties such as oncology or psychiatry. Their advanced education allows them to independently diagnose and treat patients, order testing, perform minor surgeries, and often prescribe medications. Many NPs practice autonomously, with so-called "full practice authority," but most work in collaboration with physicians. They focus not only on treatment of disease but also on disease prevention, patient education, and counseling. Such early intervention and education can lower overall healthcare costs.

NPs are licensed to practice in all U.S. states and must follow the rules and regulations of the state in which they are licensed. In most states, they are able to prescribe medications without a physician's cosignature, and they may bill insurance agencies for services. Their professional organization is the American Academy of Nurse Practitioners at aanp.org.

evaluate its texture, temperature, moisture, firmness, and any tenderness. **BOX 4-3** on nurse practitioners, who, like other healthcare professionals, observe the skin when performing physical examinations.

WOUNDS

Wounds are caused by trauma, as in cases of accidents or attacks, or by surgery and other therapeutic or diagnostic procedures. Wounds may affect not only the injured area but also other body systems. Infection and hemorrhage may complicate wounds, as do **dehiscence**, disruption of the wound layers, and **evisceration**, protrusion of internal organs through the lesion.

As a wound heals, fluid and cells drain from the damaged tissue. This drainage, called **exudate**, may be clear, bloody (sanguinous), or pus-containing (purulent). Tubes may be used to remove exudate from the site of a wound.

Proper wound healing depends on cleanliness and care of the lesion and also on proper circulation, good general health, and good nutrition. The edges of a deep wound should be joined by sutures, either stitches or, for simple cuts in areas that can be kept dry and immobilized, with a tissue adhesive (glue). Healing is accompanied by scar formation or **cicatrization** (an alternative name for a scar is a cicatrix). Permanent scarring is lessened by appropriate wound care, but some people, especially those of African or Asian descent, may tend to form **keloids** because of excess collagen formation during healing **(FIG. 4-3)**. Plastic surgery can often improve keloids and other unsightly scars.

Various types of dressings are used to protect wounded areas and promote healing. Vacuum-assisted closure (VAC) uses negative pressure to close the tissues and begin the healing process. Healing may be promoted by **debridement**, the removal of dead or damaged tissue from a wound. **BOX 4-4** mentions the origin of the word debridement and gives the meaning of other medical terms taken from French. Debridement may be accomplished by cutting or scrubbing away the dead tissue or by means of enzymes. A thick, dark crust or scab (eschar) may be removed in an **escharotomy.**

FIGURE 4-3 Keloid. Marked overgrowth of scar tissue following earlobe piercing.

extern.ir

FOCUS ON WORDS
The French Connection

BOX 4-4

Many scientific and medical terms are adapted from foreign languages. Most roots come from Latin and Greek; others are derived from German or French. Sometimes a foreign word is used "as is." Debridement, removal of dead or damaged tissue from a wound, comes from French, meaning removal of a restraint, such as the bridle of a harness. Also from French, a contrecoup injury occurs when the head is thrown forward and back, as in a car accident, and the brain is injured by hitting the skull on the side opposite the blow. *Contrecoup* in French means "counterblow." Tic douloureux, a disorder causing pain along the path of the trigeminal nerve in the face, translates literally as "painful spasm." A sound heard while listening to the body with a stethoscope is a bruit, a word in French that literally means "noise." Lavage, which refers to irrigation of a cavity, is a French word meaning "washing."

Deep wounds may require skin grafting for proper healing. Grafts may be a full-thickness skin graft (FTSG), which consists of the epidermis and dermis, or a split-thickness skin graft (STSG), consisting of the epidermis only. Skin is cut for grafting with a **dermatome.**

Burns

Most burns are caused by hot objects, explosions, or scalding with hot liquids. They may also be caused by electricity, contact with harmful chemicals, or abrasion. Sunlight can also cause severe burns that may result in serious illness. Burns are assessed in terms of the depth of damage and the percentage of body surface area (BSA) involved. Depth of tissue destruction is categorized as follows:

1. *Superficial*—involves the epidermis only. The skin is red and dry; there is minimal pain. Typical causes are mild sunburn and very short heat exposure. This type of burn is also called a first-degree burn. The skin will whiten (blanch) when pressed and then turn bright red again when released.
2. *Superficial partial thickness*—involves the epidermis and a superficial portion of the dermis. The tissue reddens and blisters and is painful, as in cases of severe sunburn or scalding.
3. *Deep partial thickness*—involves the epidermis and both superficial and deeper regions of the dermis. The tissue may be blistered with a weeping surface or dry because of sweat gland damage. These burns may be less painful than superficial burns because of nerve damage. The blisters may fill with blood due to dermal capillary damage. Causes include scalding and exposure to flame or hot grease. Superficial and deep partial thickness burns are also classified as second-degree burns.
4. *Full thickness*—involves the full skin and sometimes subcutaneous tissue and underlying tissues as well. The tissue is broken, dry and pale, or charred. These injuries may require skin grafting and may result in loss of digits or limbs. Full-thickness burns are also classified as third-degree or fourth-degree burns.

The amount of BSA involved in a burn may be estimated by using the **rule of nines,** in which areas of body surface are assigned percentages in multiples of nine **(FIG. 4-4)**. The more accurate Lund and Browder method divides the body into small areas and estimates the proportion of BSA contributed by each.

Infection is a common complication of burns because a person's major defense against bacterial invasion is damaged. Respiratory complications and shock may also occur.

Treatment of burns includes respiratory care, administration of fluids, wound care, and pain control. Monitoring for cardiovascular complications, infections, and signs of posttraumatic stress is also important.

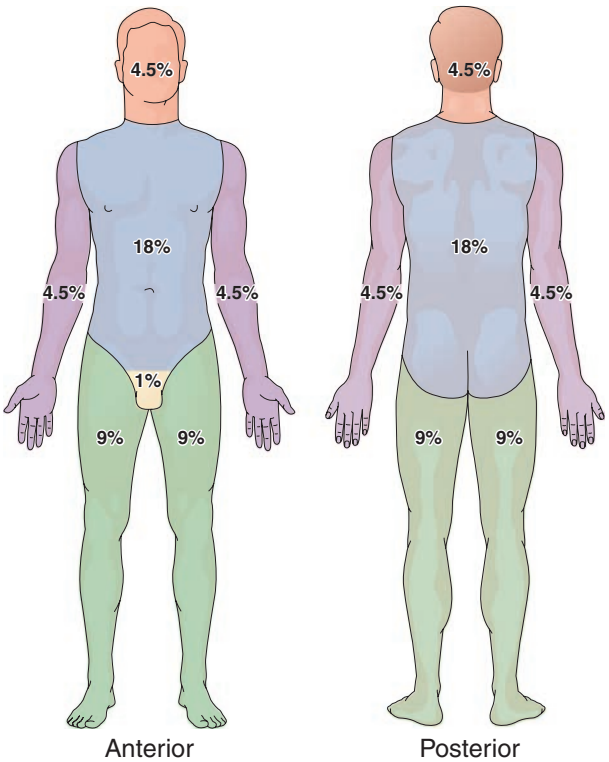

FIGURE 4-4 The rule of nines. Percentage of body surface area (BSA) in the adult is estimated by sectioning the body surface into areas with numerical values related to nine. This method is used to evaluate the extent of skin burns.

extern.ir

A B

FIGURE 4-5 Dermatitis. A. Atopic dermatitis (eczema) on an infant's wrist. **B.** Contact dermatitis from shoe material. Note several fluid-filled bullae (see **BOX 4-2**).

Pressure Ulcers

Pressure ulcers are necrotic skin lesions that appear where the body rests on skin that covers bony projections, such as the sacrum, heel, elbow, ischial bone of the pelvis, or greater trochanter of the femur (see *ulcer*, **BOX 4-2**, and Kathleen's opening case study). The pressure interrupts circulation, leading to thrombosis, ulceration, and tissue death (necrosis). Poor general health, malnutrition, age, obesity, and infection contribute to the development of pressure ulcers.

Pressure ulcer lesions first appear as redness of the skin. If ignored, they may penetrate the skin and underlying muscle, extending even to bone, and may require months to heal.

Pads or mattresses to relieve pressure, regular cleansing and drying of the skin, frequent change in position, and good nutrition help to prevent pressure ulcers. Other terms for pressure ulcers are *decubitus ulcer* and *bedsore*. Both of these terms refer to lying down in bed, although pressure ulcers may appear in anyone with limited movement, not only those who are confined to bed.

DERMATITIS

Dermatitis is a general term for inflammation of the skin, which may be acute or chronic. Mild forms show **erythema** (redness) and edema and sometimes **pruritus** (itching), but the condition may worsen to include deeper lesions and secondary bacterial infections. A chronic allergic form of this disorder that appears early in childhood is called **atopic dermatitis** or **eczema** (**FIG. 4-5**). Although its exact cause is unknown, atopic dermatitis is made worse by allergies, infection, temperature extremes, and skin irritants. Patients have tried a variety of treatments for this disorder over the years. Clinicians are currently studying biologic drugs targeting specific immune system components that are overproduced in cases of eczema and other allergic disorders.

Other forms of dermatitis include contact dermatitis, caused by allergens or chemical irritants (see **FIG. 4-5B**); seborrheic dermatitis, which involves areas with many sebaceous glands, such as the scalp and face; and stasis dermatitis, caused by poor circulation.

PSORIASIS

Psoriasis is a chronic overgrowth (hyperplasia) of the epidermis, producing large, erythematous (red) plaques with silvery scales (**FIG. 4-6**; see also *plaques*, **BOX 4-2**). The cause is unknown, but there is sometimes a hereditary pattern, and autoimmunity may be involved.

Dermatologists treat psoriasis in the following ways depending on severity:

1. Topical agents, including corticosteroids, immunosuppressants, vitamins A and D
2. Phototherapy—exposure to ultraviolet B (UVB) light; administration of the drug psoralen (P) to increase skin sensitivity to light followed by exposure to ultraviolet A (UVA) light; laser treatment
3. Systemic suppression of the immune system

FIGURE 4-6 Psoriasis. Plaques with scales seen at the front of the knee (see *plaque*, **BOX 4-2**).

extern.ir

FIGURE 4-7 Pemphigus. Blisters (bullae) are seen on the forearm (see *bulla*, **BOX 4-2**).

The discoid form (DLE) involves only the skin. It is seen as rough, raised, erythematous papules that are worsened by exposure to the ultraviolet radiation in sunlight **(FIG. 4-8)**. Lupus skin lesions are confined to the face and scalp and may form a typical butterfly-shaped rash across the nose and cheeks.

Scleroderma is a disease of unknown cause that involves thickening and tightening of the skin. There is gradual fibrosis of the dermis because of collagen overproduction. Sweat glands and hair follicles are also involved. A very early sign of scleroderma is Raynaud disease, in which blood vessels in the fingers and toes constrict in the cold, causing numbness, pain, coldness, and tingling. Skin symptoms first appear on the forearms and around the mouth. Internal organs become involved in a diffuse form of scleroderma called progressive systemic sclerosis (PSS).

AUTOIMMUNE DISORDERS

The diseases discussed below are caused, at least in part, by autoimmune reactions. They are diagnosed by biopsy of lesions and by antibody studies.

Pemphigus is characterized by the formation of bullae (blisters) in the skin and mucous membranes caused by a separation of epidermal cells from underlying layers (**FIG. 4-7**; see also *bulla*, **BOX 4-2**). Rupture of these lesions leaves deeper skin areas unprotected from infection and fluid loss, much as in cases of burns. The cause is an autoimmune reaction to epithelial cells. Pemphigus is fatal unless treated by suppressing the immune system.

Lupus erythematosus (LE) is a chronic inflammatory autoimmune disease of connective tissue. The more widespread form of the disease, systemic lupus erythematosus (SLE), involves the skin and other organs. SLE is more prevalent in women than in men and has a higher incidence among Asians and blacks than among other populations.

SKIN CANCER

Skin cancer is the most common type of human cancer. Its incidence has been increasing in recent years, mainly because of the mutation-causing effects of sunlight's ultraviolet rays. **Squamous cell carcinoma** and **basal cell carcinoma** are both cancers of epithelial cells. Both appear in areas exposed to sunlight, such as the face and hands. Basal cell carcinoma constitutes more than 75% of all skin cancers. It usually appears as a smooth, pearly papule (**FIG. 4-9**; see also *papules*, **BOX 4-2**). Because these cancers are easily seen and do not metastasize, the cure rate after excision is greater than 95%.

Squamous cell carcinoma appears as a painless, firm, red nodule or plaque that may develop surface scales, ulceration, or crusting (**FIG. 4-10**; see also **BOX 4-2**). This cancer may invade underlying tissue but tends not to metastasize. It is treated by surgical removal and sometimes with x-irradiation or chemotherapy.

FIGURE 4-8 Discoid (cutaneous) lupus erythematosus. Erythematous papules and plaques in a typical sun-exposed distribution on the chest (see *plaque,* **BOX 4-2**).

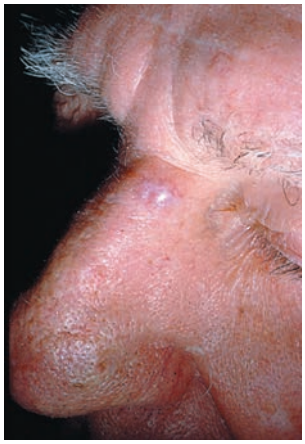

FIGURE 4-9 Basal cell carcinoma. An initial translucent nodule has spread, leaving a depressed center and a firm, elevated border (see *nodule*, **BOX 4-2**).

extern.ir

FIGURE 4-10 Squamous cell carcinoma. Lesions are shown on the face and the back of the hand, sun-exposed areas that are commonly affected.

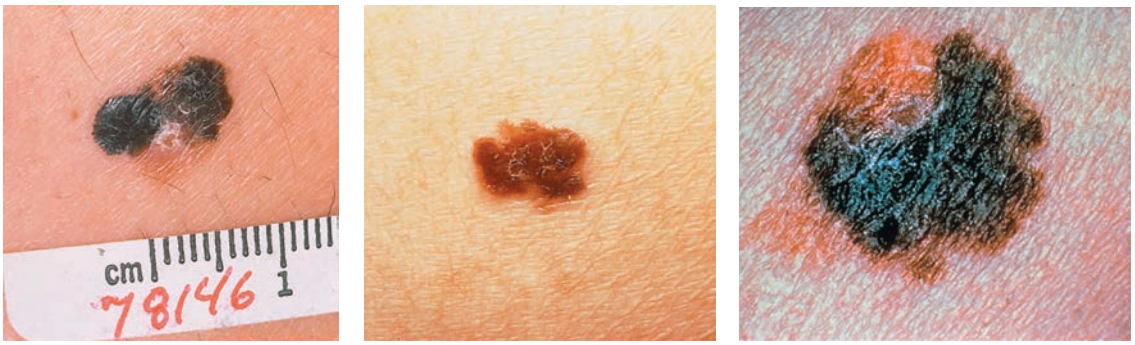

A B C

FIGURE 4-11 Melanoma. Several characteristics are shown. **A.** Asymmetry. **B.** Irregular borders. **C.** Variation in color, a diameter greater than 6 mm, and elevation.

Melanoma results from a malignant overgrowth of melanocytes, the pigment-producing cells in the epidermis. It can arise anywhere in the body where melanocytes are found and is the most dangerous form of skin cancer because of its tendency to metastasize. This cancer appears as a lesion that is variable in color with an irregular border **(FIG. 4-11)**. A melanoma shows the so-called ABCDE factors: **a**symmetry, uneven **b**orders, different **c**olors, **d**iameter of more than 6 millimeters, and **e**volution (change). The tumor may spread superficially for up to 1 or 2 years before it begins to invade the deeper skin tissues and to metastasize through blood and lymph. Predisposing factors for melanoma include severe sunburn and frequent tanning. The prognosis for cure is good if the lesion is recognized and removed surgically before it enters this invasive stage.

Kaposi sarcoma, once considered rare, is now seen frequently in association with AIDS. It usually appears as distinct brownish areas on the legs. These plaques become raised and firm as the tumor progresses. In those with weakened immune systems, such as patients with AIDS, the cancer can metastasize.

Terminology *Key Terms*

The terms listed below are emphasized in this chapter. Knowing them will help you organize and prioritize your learning. These boldface terms are also found, collectively, with all chapter key terms in the Glossary.

Clinical Aspects

atopic dermatitis *ah-TOP-ik der-mah-TI-tis*	Hereditary, allergic, chronic skin inflammation with pruritus (itching); eczema
basal cell carcinoma *BA-sal*	An epithelial tumor that rarely metastasizes and has a high cure rate with surgical removal
cicatrization *sik-ah-trih-ZA-shun*	The process of scar formation; a scar is a cicatrix (*SIK-ah-triks*)

(continued)

extern.ir

Terminology Key Terms (Continued)

debridement *da-brede-MON*	Removal of dead or damaged tissue, as from a wound
dehiscence *de-HIS-ens*	Splitting or bursting, as when the layers of a wound separate
dermatitis *der-mah-TI-tis*	Inflammation of the skin, often associated with redness and itching; may be caused by allergy, irritants (contact dermatitis), or a variety of diseases
dermatology *der-mah-TOL-o-je*	Study of the skin and diseases of the skin
dermatome *DER-mah-tome*	Instrument for cutting thin skin sections for grafting
eczema *EK-ze-mah*	A general term for skin inflammation with redness, lesions, and itching; atopic dermatitis
erythema *er-ih-THE-mah*	Diffuse redness of the skin
escharotomy *es-kar-OT-o-me*	Removal of scab tissue resulting from burns or other skin injuries; a scab or crust is an eschar (*ES-kar*)
evisceration *e-vis-er-A-shun*	Protrusion of internal organs (viscera) through an opening, as through a wound
exudate *EKS-u-date*	Material, which may include fluid, cells, pus, or blood, that escapes from damaged tissue
Kaposi sarcoma *KAP-o-se*	Cancerous lesion of the skin and other tissues seen most often in patients with AIDS
keloid *KE-loyd*	A raised, thickened scar caused by tissue overgrowth during scar formation
lupus erythematosus (LE) *LU-pus er-ih-the-mah-TO-sis*	A chronic, inflammatory, autoimmune disease of connective tissue that often involves the skin; types include the more widespread systemic lupus erythematosus (SLE) and a discoid form (DLE) that involves only the skin
melanoma *mel-ah-NO-mah*	A metastasizing pigmented skin tumor that arises from melanocytes; malignant melanoma
pemphigus *PEM-fih-gus*	An autoimmune disease of the skin characterized by sudden, intermittent formation of bullae (blisters); may be fatal if untreated
pressure ulcer	An ulcer caused by pressure to an area of the body, as from a bed or chair; decubitus (*de-KU-bih-tus*) ulcer, bedsore, pressure sore
pruritus *pru-RI-tus*	Severe itching
psoriasis *so-RI-ah-sis*	A chronic hereditary dermatitis with red lesions covered by silvery scales
rule of nines	A method for estimating the extent of body surface area involved in a burn by assigning percentages in multiples of nine to various body regions
scleroderma *sklere-o-DER-mah*	A chronic disease that is characterized by thickening and tightening of the skin and that often involves internal organs in a form called progressive systemic sclerosis (PSS)
squamous cell carcinoma *SKWA-mus*	An epidermal cancer that may invade deeper tissues but tends not to metastasize

extern.ir

Terminology *Enrichment Terms*

The terms listed below expand on the key terms to increase your knowledge of this chapter topic.

Symptoms and Conditions

acne *AK-ne*	An inflammatory disease of the sebaceous glands and hair follicles usually associated with excess sebum secretion; acne vulgaris
actinic *ak-TIN-ik*	Pertaining to the effects of radiant energy, such as sunlight, ultraviolet light, and x-rays
albinism *AL-bin-izm*	A hereditary lack of pigment in the skin, hair, and eyes
alopecia *al-o-PE-she-ah*	Absence or loss of hair; baldness
Beau lines *bo*	White lines across the fingernails; usually a sign of systemic disease or injury **(FIG. 4-12)**
bromhidrosis *brom-hi-DRO-sis*	Sweat that has a foul odor because of bacterial decomposition; also spelled bromidrosis (*bro-mih-DRO-sis*)
carbuncle *CAR-bung-kl*	A localized infection of the skin and subcutaneous tissue, usually caused by staphylococcus, and associated with pain and discharge of pus
comedo *KOM-eh-do*	A plug of sebum, often containing bacteria, in a hair follicle; a blackhead (plural: comedones)
dermatophytosis *der-mah-to-fi-TO-sis*	Fungal infection of the skin, especially between the toes; athlete's foot (root *phyt/o* means "plant")
diaphoresis *di-ah-fo-RE-sis*	Profuse sweating
dyskeratosis *dis-ker-ah-TO-sis*	Any abnormality in keratin formation in epithelial cells
ecchymosis *ek-ih-MO-sis*	A collection of blood under the skin caused by leakage from small vessels
erysipelas *er-ih-SIP-eh-las*	An acute infectious skin disease with localized redness and swelling and systemic symptoms

(continued)

FIGURE 4-12 Beau lines. These transverse depressions in the nails are associated with acute severe illness.

extern.ir

Terminology Enrichment Terms (Continued)

erythema nodosum *no-DO-sum*	Inflammation of subcutaneous tissues resulting in tender, erythematous nodules; may be an abnormal immune response to a systemic disease, an infection, or a drug
exanthema *ek-zan-THE-mah*	Any cutaneous eruption that accompanies a disease, such as measles; a rash
excoriation *eks-ko-re-A-shun*	Lesion caused by scratching or abrasion
folliculitis *fo-lik-u-LI-tis*	Inflammation of a hair follicle
furuncle *FU-rung-kl*	A painful skin nodule caused by staphylococci that enter through a hair follicle; a boil
hemangioma *he-man-je-O-mah*	A benign tumor of blood vessels; in the skin, called birthmarks or port wine stains
herpes simplex *HER-peze SIM-pleks*	A group of acute infections caused by herpes simplex virus; type I herpes simplex virus produces fluid-filled vesicles, usually on the lips, after fever, sun exposure, injury, or stress, also called cold sore or fever blister; type II infections usually involve the genital organs
hirsutism *HIR-su-tizm*	Excessive growth of hair
ichthyosis *ik-the-O-sis*	A dry, scaly condition of the skin (from the root *ichthy/o*, meaning "fish")
impetigo *im-peh-TI-go*	A bacterial skin infection with pustules that rupture and form crusts; most commonly seen in children, usually on the face (**FIG. 4-13**; see also *pustules*, **BOX 4-2**)
keratosis *ker-ah-TO-sis*	Any skin condition marked by thickened or horny growth; seborrheic keratosis is a benign tumor, yellow or light brown in color, that appears in the elderly; actinic keratosis is caused by exposure to sunlight and may lead to squamous cell carcinoma
lichenification *li-ken-ih-fih-KA-shun*	Thickened marks caused by chronic rubbing, as seen in atopic dermatitis (a lichen is a flat, branching type of plant that grows on rocks and bark) **(FIG. 4-14)**

FIGURE 4-13 Impetigo. This bacterial skin infection, seen here on the nostril, causes pustules that rupture and form crusts (see *pustule*, **BOX 4-2**).

FIGURE 4-14 Lichenification. Skin shows thickened areas from chronic rubbing, as seen in atopic dermatitis.

extern.ir

Terminology *Enrichment Terms (Continued)*

mycosis fungoides *mi-KO-sis fun-GOY-deze*	A rare malignant disease that originates in the skin and involves the internal organs and lymph nodes; there are large, painful, ulcerating tumors
nevus *NE-vus*	A defined discoloration of the skin; a congenital vascular skin tumor; a mole, birthmark
paronychia *par-o-NIK-e-ah*	Infection around a nail **(FIG. 4-15)** caused by bacteria or fungi; may affect multiple nails
pediculosis *peh-dik-u-LO-sis*	Infestation with lice
petechiae *pe-TE-ke-e*	Flat, pinpoint, purplish-red spots caused by bleeding within the skin or mucous membrane (singular: petechia)
photosensitization *fo-to-sen-sih-tih-ZA-shun*	Sensitization of the skin to light, usually from the action of drugs, plant products, or other substances
purpura *PUR-pu-rah*	A condition characterized by hemorrhages into the skin and other tissues
rosacea *ro-ZA-she-ah*	A condition of unknown cause involving redness of the skin, pustules, and overactivity of sebaceous glands, mainly on the face
scabies *SKA-beze*	A highly contagious skin disease caused by a mite
senile lentigines *len-TIJ-ih-neze*	Brown macules that appear on sun-exposed skin in adults; liver spots
shingles	An acute eruption of vesicles along the path of a nerve; herpes zoster (*HER-peze ZOS-ter*); caused by the same virus that causes chickenpox
tinea *TIN-e-ah*	A fungal skin infection; ringworm **(FIG. 4-16)**
tinea versicolor *VER-sih-kol-or*	Superficial chronic fungal infection that causes varied skin pigmentation

(continued)

FIGURE 4-15 Paronychia. Infection and inflammation of the proximal and lateral nail folds is shown.

FIGURE 4-16 Tinea corporis. Ringworm infection seen on the body.

extern.ir

Terminology *Enrichment Terms (Continued)*

urticaria *ur-tih-KAR-e-ah*	A skin reaction marked by temporary, smooth, raised areas (wheals) associated with itching; hives (**FIG. 4-17**; see also *wheals*, **BOX 4-2**)
venous stasis ulcer	Ulcer caused by venous insufficiency and stasis of venous blood; usually forms near the ankle (**FIG. 4-18**; see also *ulcer*, **BOX 4-2**)
verruca *ver-RU-kah*	A small, usually benign epidermal tumor caused by human papilloma virus (HPV); a wart
vitiligo *vit-ih-LI-go*	Patchy disappearance of pigment in the skin; leukoderma **(FIG. 4-19)**
xeroderma pigmentosum *ze-ro-DER-mah pig-men-TO-sum*	A fatal hereditary disease that begins in childhood with skin discolorations and ulcers and muscle atrophy; there is increased sensitivity to the sun and increased susceptibility to cancer

FIGURE 4-17 Urticaria (hives). Wheals associated with drug allergy are shown in an infant (see *wheal*, **BOX 4-2**).

FIGURE 4-18 Venous stasis ulcer. Lesion on the ankle caused by venous insufficiency and blood stasis (see *ulcer*, **BOX 4-2**).

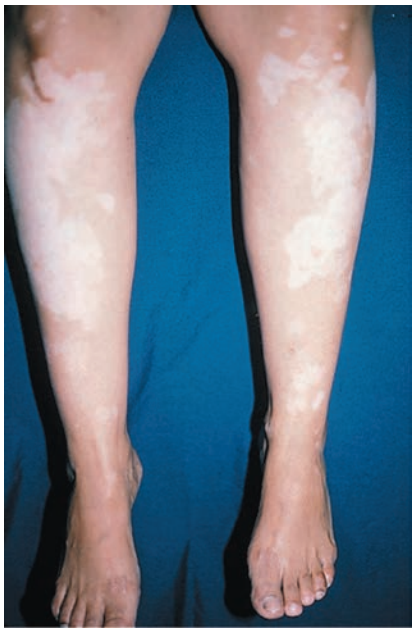

FIGURE 4-19 Vitiligo. Depigmented macules appear on the skin and may merge into large areas that lack melanin. The brown pigment seen in the illustration is the person's normal skin color; the pale areas are caused by vitiligo.

extern.ir

Terminology Enrichment Terms (Continued)

Diagnosis and Treatment	
aloe *AH-lo*	A gel from leaves of the plant *Aloe vera* that is used in treatment of burns and minor skin irritations
antipruritic *an-te-pru-RIT-ik*	Agent that prevents or relieves itching
cautery *KAW-ter-e*	Destruction of tissue by physical or chemical means; cauterization; also the instrument or chemical used for this purpose
dermabrasion *DERM-ah-bra-zhun*	A plastic surgical procedure for removing scars or birthmarks by chemical or mechanical destruction of epidermal tissue
dermatoplasty *DER-mah-to-plas-te*	Transplantation of human skin; skin grafting
diascopy *di-AS-ko-pe*	Examination of skin lesions by pressing a glass plate against the skin
fulguration *ful-gu-RA-shun*	Destruction of tissue by high-frequency electric sparks
skin turgor *TUR-gor*	Resistance of the skin to deformation; evidenced by the ability of the skin to return to position when pinched; skin turgor is a measure of the skin's elasticity and state of hydration; typically declines with age and when decreased may also be a sign of poor nutrition
Wood lamp	An ultraviolet light used to diagnose fungal infections

4

Terminology Abbreviations

The abbreviations listed below are emphasized in this chapter. These are also found, collectively, with all chapter abbreviations in Appendix 2.

ABCDE	Asymmetry, uneven borders, different colors, diameter of more than 6 millimeters, and evolution (change).
BSA	Body surface area
DLE	Discoid lupus erythematosus
FTSG	Full-thickness skin graft
LE	Lupus erythematosus
PSS	Progressive systemic sclerosis
PUVA	Psoralen ultraviolet A
SCLE	Subacute cutaneous lupus erythematosus
SLE	Systemic lupus erythematosus
SPF	Sun protection factor
STSG	Split-thickness skin graft
UV	Ultraviolet
UVA	Ultraviolet A
UVB	Ultraviolet B
VAC	Vacuum-assisted closure

extern.ir

Case Study Revisited

Kathleen's Follow-Up

Kathleen made progress while in the long-term care facility. She also worked with a physical therapist (PT) and occupational therapist (OT) and began performing simple activities of daily living (ADL). The therapists performed range of motion (ROM) activities on a regular schedule to both the stroke-affected and unaffected sides. With the increase in activity and improved nutrition, Kathleen's circulation and skin condition improved. She also showed less confusion. Kathleen's daughter visited her frequently. She was thus able to observe and assist with her mother's activities and receive instruction for her care firsthand. Goals were set to evaluate Kathleen's progress. Discharge plans were made to have her return home at an appropriate time. In expectation of her mother's return, her daughter had made arrangements for a home healthcare worker to assist in her care.

extern.ir

CHAPTER 4

Review

These questions test your understanding of the content introduced in this chapter. Follow the instructions for each exercise and check your answers in Appendix 11.

LABELING EXERCISE

CROSS-SECTION OF THE SKIN

Write the name of each numbered part on the corresponding line of the answer sheet.

Adipose tissue
Arrector pili muscle
Artery
Dermis
Epidermis
Hair
Hair follicle
Nerve
Nerve endings
Pore (opening of sweat gland)
Pressure receptor
Sebaceous (oil) gland
Skin
Stratum basale (growing layer)
Stratum corneum
Subcutaneous layer
Sweat gland
Touch receptor
Vein

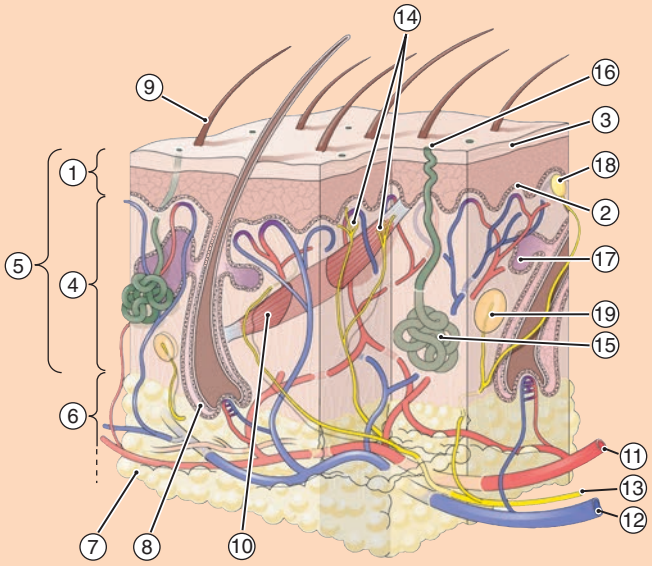

1. _____
2. _____
3. _____
4. _____
5. _____
6. _____
7. _____
8. _____
9. _____
10. _____
11. _____
12. _____
13. _____
14. _____
15. _____
16. _____
17. _____
18. _____
19. _____

extern.ir

TERMINOLOGY

MATCHING

____ 1. cicatrization	a. redness of the skin
____ 2. erythema	b. severe itching
____ 3. eczema	c. material that escapes from damaged tissue
____ 4. pruritus	d. atopic dermatitis
____ 5. exudate	e. scar formation

____ 6. stratum basale	a. oily skin secretion
____ 7. hypodermis	b. sheath that contains a hair
____ 8. sebum	c. subcutaneous layer
____ 9. stratum corneum	d. growing layer of the epidermis
____ 10. follicle	e. thickened layer of the epidermis

Enrichment Terms

____ 11. alopecia	a. profuse sweating
____ 12. excoriation	b. lesion caused by scratching or abrasion
____ 13. nevus	c. mole or birthmark
____ 14. diaphoresis	d. blackhead
____ 15. comedo	e. baldness

____ 16. rosacea	a. condition causing redness and pustules, mainly on the face
____ 17. tinea	b. fungal skin infection
____ 18. bromhidrosis	c. infection around a nail
____ 19. albinism	d. lack of skin pigmentation
____ 20. paronychia	e. sweat with a foul odor

FILL IN THE BLANKS

Complete the sentence with the correct term(s).

21. The main pigment in skin is _____ .
22. The oil-producing glands of the skin are the _____ .
23. A sudoriferous gland produces _____ .
24. The adjective *cutaneous* refers to the _____ .
25. Dermabrasion (*der-mah-BRA-zhun*) is surface scraping of the _____ .
26. The protein that thickens the skin and makes up hair and nails is _____ .
27. Schizonychia (*skiz-o-NIK-e-ah*) is splitting of a(n) _____ .

Refer to Kathleen's opening case study.

28. Two other terms for a pressure ulcer are _____ .
29. When the nurse palpated Kathleen's lesion, she used her sense of _____ .
30. Part of Kathleen's treatment was removal of dead skin from her lesion. This process is called _____ .
31. The abbreviation FTSG refers to a(n) _____ .
32. A term for lack of blood (root: hem/o) to tissue is _____ .
33. The medical specialist who treated Kathleen's deteriorating pressure ulcer was a(n) _____ .

extern.ir

DEFINITIONS

Define the following words.

34. xeroderma (*ze-ro-DER-mah*) _____
35. dyskeratosis (*dis-ker-ah-TO-sis*) _____
36. seborrhea (*seb-or-E-ah*) _____
37. pachyderma (*pak-e-DER-mah*) _____
38. onychia (*o-NIK-e-ah*) _____
39. hypermelanosis (*hi-per-mel-ah-NO-sis*) _____
40. percutaneous (*per-ku-TA-ne-us*) _____
41. keratogenic (*ker-ah-to-JEN-ik*) _____

Write words for the following definitions.

42. pertaining to discharge of sebum _____
43. excess production of keratin _____
44. instrument for cutting the skin _____
45. tumor containing melanin _____
46. cell that produces melanin _____
47. hardening of the skin _____

Use the word hidrosis (sweating) as an ending for words with the following meanings.

48. absence of sweating _____
49. excess sweating _____
50. excretion of colored (chrom/o) sweat _____

PLURALS

Give the plural form for the following key and enrichment terms.

51. bulla _____
52. ecchymosis _____
53. fungus _____
54. comedo _____
55. staphylococcus _____

extern.ir

TRUE–FALSE

Examine the following statements. If the statement is true, write T in the first blank. If the statement is false, write F in the first blank, and correct the statement by replacing the underlined word in the second blank.

	True or False	Correct Answer
56. The skin and its associated structures make up the integumentary system.	_____	_____
57. The root trich/o refers to hair.	_____	_____
58. The dermis is between the epidermis and the subcutaneous layer.	_____	_____
59. A cicatrix is a scar.	_____	_____
60. Hirsutism is excess growth of nails.	_____	_____

WORD BUILDING

Write a word for the following definitions using the word parts provided. Each word part can be used more than once.

-lysis	onych/o	-sis	myc/o	path/o	dermat/o	-y	log/o	-oid	trich/o

61. loosening or separation of the skin _____
62. fungal infection of a nail _____
63. resembling a hair _____
64. study of hair _____
65. loosening of a nail _____
66. like or resembling skin _____
67. any disease of a nail _____
68. fungal infection of the hair _____
69. any disease of the skin _____
70. study and treatment of the skin _____

ELIMINATIONS

In each of the sets below, underline the word that does not fit in with the rest, and explain the reason for your choice.

71. nodule — vesicle — keloid — macule — papule

_____

72. impetigo — escharotomy — psoriasis — dermatitis — pemphigus

_____

73. SLE — PSS — SCLE — BSA — DLE

_____

extern.ir

WORD ANALYSIS

Define the following words, and give the meaning of the word parts in each. Use a dictionary if necessary.

74. dermatophytosis (*der-mah-to-fi-TO-sis*)
    a. dermat/o _____
    b. phyt/o _____
    c. -sis _____
75. hidradenoma (*hi-drad-eh-NO-mah*)
    a. hidr/o _____
    b. aden/o _____
    c. -oma _____
76. onychocryptosis (*on-ih-ko-krip-TO-sis*)
    a. onych/o _____
    b. crypt/o _____
    c. -sis _____
77. achromotrichia (*ah-kro-mo-TRIK-e-ah*)
    a. a- _____
    b. chrom/o _____
    c. trich/o _____
    d. -ia _____

extern.ir

Additional Case Studies

Case Study 4-1: Basal Cell Carcinoma

Joanne, a 32 y/o fitness instructor, had noticed a "tiny hard lump" at the base of her left nostril while cleansing her face. The lesion had been present for about 2 months when she consulted a dermatologist. She had recently moved north from Florida, where she had worked as a lifeguard. She thought the lump might have been triggered by the regular tanning salon sessions she had used to retain her tan because it did not resemble the acne pustules, blackheads, or resulting scars of her adolescent years. Although dermabrasion had removed the obvious acne scars and left several areas of dense skin, this lump was brown-pigmented and different. Joanne was afraid it might be a malignant melanoma. On examination, the dermatologist noted a small pearly-white nodule at the lower portion of the left ala (outer flared portion of the nostril). There were no other lesions on her face or neck.

A plastic surgeon excised the lesion and was able to reapproximate the wound edges without a full-thickness skin graft (FTSG). The pathology report identified the lesion as a basal cell carcinoma with clean margins of normal skin and subcutaneous tissue and stated that the entire lesion had been excised. Joanne was advised to wear SPF 30 sun protection on her face at all times and to avoid excessive sun exposure and tanning salons.

Case Study 4-1 Questions

Follow the instructions for each question and check your answers in Appendix 11.

Multiple Choice. *Select the best answer, and write the letter of your choice to the left of each number.*

_____ 1. Joanne's basal cell carcinoma may have been caused by chronic exposure to the sun and use of an ultraviolet tanning bed. The scientific explanation for this is the
   a. autoimmune response
   b. actinic effect
   c. allergic reaction
   d. sunblock tanning lotion theory

_____ 2. The characteristic pimples of adolescent acne are whiteheads and blackheads. The medical terms for these lesions are
   a. vesicles and macules
   b. pustules and blisters
   c. pustules and comedones
   d. furuncles and sebaceous cysts

_____ 3. Which skin cancer is an overgrowth of pigment-producing epidermal cells?
   a. basal cell carcinoma
   b. Kaposi sarcoma
   c. cutaneous lymphoma
   d. melanoma

_____ 4. Basal cell carcinoma involves
   a. subcutaneous tissue
   b. hair follicles
   c. connective tissue
   d. epithelial cells

Write terms from the case study with the following meanings.

5. skin sanding procedure _____
6. a solid raised lesion larger than a papule _____
7. physician who cares for patients with skin diseases _____
8. layer of connective tissue and fat beneath the dermis _____

Define the following abbreviations. See Appendix 2 if needed.

9. FTSG _____
10. SPF _____

extern.ir

Case Study 4-2: Cutaneous Lymphoma

Laurie, a 52 y/o female research chemist, has had a history of T-cell lymphoma for 8 years. She was initially treated with systemic chemotherapy with methotrexate, until she developed mouth ulcers. Continued therapy with topical chemotherapeutic agents brought measurable improvement. She also had a history of hidradenitis.

A recent physical examination showed diffuse erythroderma with scaling and hyperkeratosis, plus alopecia. She had painful leukoplakia and ulcerations of the mouth and tongue. Laurie was hospitalized and given two courses of topical chemotherapy. She was referred to dental medicine for treatment of the oral lesions and was discharged in stable condition with an appointment for follow-up in 4 weeks. Her discharge medications included the application of 2% hydrocortisone ointment to the affected lesions hs, Keralyt gel bid for the hyperkeratosis, and Dyclone and Benadryl for her stomatitis prn.

Case Study 4-2 Questions

Follow the instructions for each question and check your answers in Appendix 11.

Multiple Choice. *Select the best answer, and write the letter of your choice to the left of each number.*

_____ 1. Hidradenitis is inflammation of a
- a. sweat gland
- b. salivary gland
- c. sebaceous gland
- d. meibomian gland

_____ 2. Leukoplakia is
- a. baldness
- b. ulceration
- c. formation of white patches in the mouth
- d. formation of yellow patches on the skin

_____ 3. Hydrocortisone is a(n)
- a. vitamin
- b. steroid
- c. analgesic
- d. diuretic

_____ 4. An example of a topical drug is a
- a. systemic chemotherapeutic agent
- b. drug derived from rainforest plants
- c. skin ointment
- d. Benadryl capsule, 25 mg

_____ 5. Stomatitis, a common side effect of systemic chemotherapy, is an inflammatory condition of the
- a. mouth
- b. stomach
- c. teeth and hair
- d. debridement

Write terms from the case study with the following meanings.

6. diffuse redness of the skin _____
7. increased production of keratin in the skin _____

Define the following abbreviations. See Appendix 2 if needed.

8. hs _____
9. bid _____
10. prn _____

extern.ir

CHAPTER 5

Skeletal System

Pretest

Multiple Choice. **Select the best answer, and write the letter of your choice to the left of each number. To check your answers go to Appendix 11.**

_____ 1. The root *oste/o* means
a. cartilage
b. fat
c. heart
d. bone

_____ 2. The root *myel/o* used in reference to bones means
a. bone marrow
b. joint
c. bone shaft
d. membrane

_____ 3. A bone of the spinal column is a
a. ventricle
b. cortex
c. labyrinth
d. vertebra

_____ 4. The large, flared superior bone of the pelvis is the
a. phalange
b. ilium
c. thorax
d. duodenum

_____ 5. The bones of the wrist are the
a. digits
b. cervices
c. carpals
d. ribs

_____ 6. The bone of the thigh is the
a. patella
b. cranium
c. umbilicus
d. femur

_____ 7. A general term for inflammation of a joint is
a. arthritis
b. conjunctivitis
c. epididymitis
d. myocarditis

_____ 8. Chondrosarcoma is a tumor that originates in
a. adipose tissue
b. bone
c. cartilage
d. muscle

extern.ir

Learning Objectives

After careful study of this chapter, you should be able to:

1. Compare the axial skeleton and the appendicular skeleton. ***P152***
2. Briefly describe the formation of bone tissue. ***P155***
3. Describe the structure of a long bone. ***P155***
4. Compare a suture, a symphysis, and a synovial joint. ***P156***
5. Describe the structure of a synovial joint. ***P156***
6. Identify and use roots pertaining to the skeleton. ***P158***
7. Describe six disorders that affect the skeleton and joints. ***P160***
8. Interpret abbreviations used in relation to the skeleton. ***P174***
9. Identify and analyze medical terms and abbreviations in chapter case studies. ***PP151, 184***

Case Study: Rachel's Idiopathic Adolescent Scoliosis

Chief Complaint

Four years ago, Rachel, a 15 y/o female, had a posterior spinal fusion (PSF) for correction of idiopathic adolescent scoliosis in a pediatric orthopedic hospital in another state. Rachel is a gifted musician, and her favorite pastime is playing the piano, guitar, and other musical instruments. Lately she has experienced considerable back pain that she attributed to long hours at the piano or playing the guitar. It was time for her routine follow-up orthopedic visit, and now she presents with a significant prominence of the right scapula and back pain in the mid- and lower back.

Examination

A history was taken and medical records were reviewed followed by a physical examination. The medical records indicated that the patient's spinal curvature had been surgically corrected with the insertion of bilateral laminar and pedicle hooks and two 3/16-in rods. A bone autograft was taken from Rachel's right posterior superior ilium and applied along the lateral processes of T4 to L2 to complete the fusion. The physical examination was normal except for surgical scarring along the spine, a projecting right scapula, and asymmetry of the rib cage. During the history, Rachel denied numbness or tingling of the lower extremities, bowel or bladder problems, chest pain, or shortness of breath. The physician ordered a CT scan to determine if there had been continued growth on the anterior portion of the spine following the posterior fusion.

Clinical Course

The results of the CT scan of the upper thoracic spine showed a prominent rotatory scoliosis deformity of the right posterior thorax with acute angulation of the ribs. Rachel's deformity is a common consequence of overcorrection of prior spinal fusion surgery, called crankshaft phenomenon.

Rachel was referred to the chief spinal surgeon of a local pediatric orthopedic hospital for removal of the spinal instrumentation, posterior spinal osteotomies from T4 to L2, insertion of replacement hooks and rods, bilateral rib resections, autograft bone from the resected ribs, partial scapulectomy and possible bone allograft, and bilateral chest tube placement. The surgical plan was explained to her and her mother, and consent was obtained and signed. The surgical procedure and the potential benefits versus risks were discussed. Rachel and her parents stated that they fully understood and provided consent to proceed with the plan for surgery.

Case Study Revisited: Once you complete this chapter, please review the case follow-up on p. 175.

Ancillaries *At-A-Glance*

Visit the web resource to access the following resources.

extern.ir

Learning Resources

- eBook
- A&P Module with Heart & Lung Sounds
- Image Bank
- TestPrep
- Animations
- Audio Pronunciation Glossary

Introduction

The **skeleton** forms the framework of the body, protects vital organs, and works with the muscular system to produce movement at the **joints**. The human adult skeleton is composed of 206 **bones**, which are organized for study into two divisions.

Divisions of the Skeleton

The axial skeleton forms the central core or "axis" of the body's bony framework **(FIG. 5-1)**. It consists of:

- The skull, made up of 8 cranial bones and 14 bones of the face **(FIG. 5-2)**. The skull bones are joined by immovable joints (sutures), except for the joint between the lower jaw (mandible) and the temporal bone of the cranium, the temporomandibular joint (TMJ).
- The spinal column **(FIG. 5-3)** consisting of 26 vertebrae. Between the vertebrae are disks of cartilage that add strength and flexibility to the spine. The five groups of vertebrae, listed from superior to inferior with the number of bones in each group are:

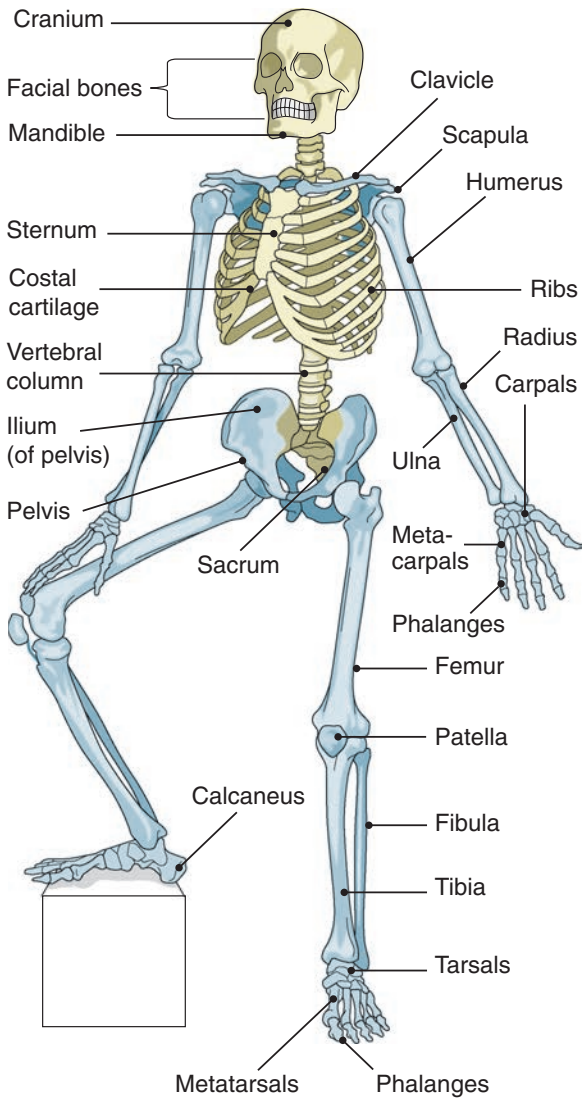

FIGURE 5-1 The skeleton. The skeleton is divided into two portions. The axial skeleton is shown here in yellow; the appendicular in blue.

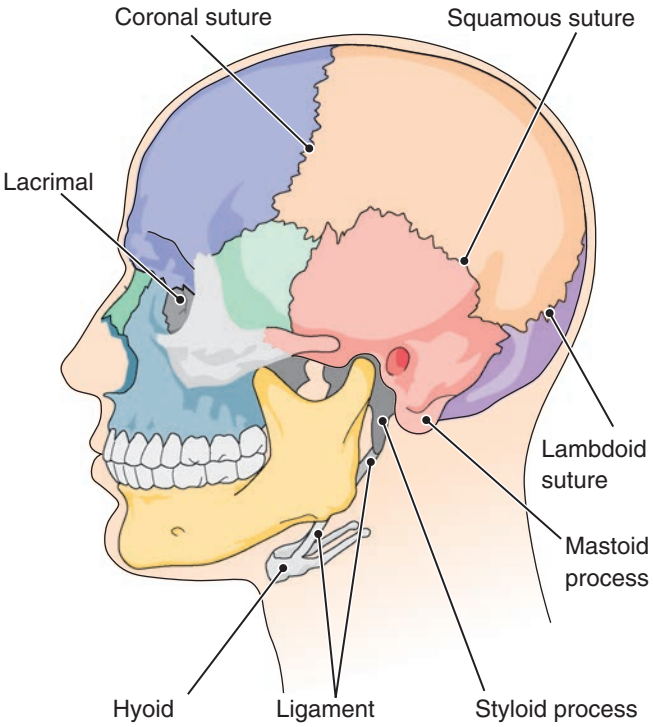

Bones of the skull:

- Frontal
- Parietal
- Sphenoid
- Temporal
- Nasal
- Maxilla
- Occiptial
- Zygomatic
- Mandible

FIGURE 5-2 The skull from the left. An additional cranial bone, the ethmoid (*ETH-moyd*), is visible mainly from the interior of the skull. The hyoid is considered part of the axial skeleton but is not attached to any other bones. The tongue and other muscles are attached to the hyoid.

extern.ir

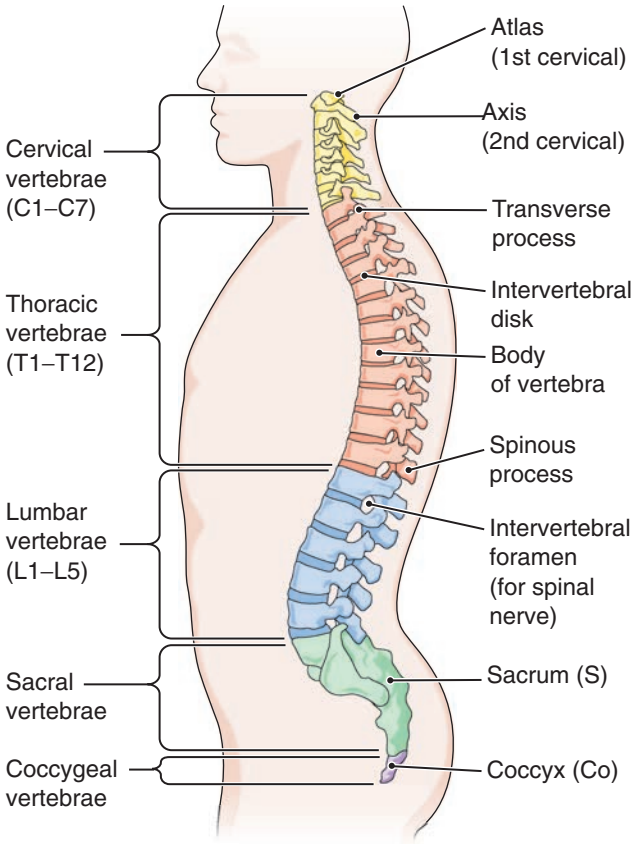

FIGURE 5-3 Vertebral column, left lateral view. The number of vertebrae in each group and the abbreviations for each are shown. The sacrum and coccyx are formed from fused bones.

1. Cervical (7), designated C1 to C7. The first and second cervical vertebrae also have specific names, the **atlas** and the **axis**, respectively (see **FIG. 5-3**).
2. Thoracic (12), designated T1 to T12
3. Lumbar (5), designated L1 to L5
4. The sacrum (S), composed of five fused bones
5. The coccyx (Co), composed of four to five fused bones

- The **thorax**, consisting of 12 pairs of ribs joined by cartilage to the sternum (breastbone). The rib cage encloses and protects the thoracic organs.

The appendicular skeleton is attached or "appended" to the axial skeleton (see **FIG. 5-1**). The upper division includes:

- The bones of the shoulder girdle, the clavicle (collar bone), and scapula (shoulder blade)
- The bones of the upper extremities (arms), the humerus, radius, ulna, carpals (wrist bones), metacarpals (bones of the palm), and phalanges (finger bones)

The lower division includes:

- The pelvic bones, two large bones that join the sacrum and coccyx to form the bony **pelvis.** Each pelvic or hip bone (os coxae) is formed by three fused bones: the large, flared **ilium**; the ischium; and the pubis **(FIG. 5-4)**. The deep socket in the hip bone that holds the head of the femur is the **acetabulum.** The female pelvis is wider than the male pelvis and has other differences to accommodate childbirth.
- The bones of the lower extremities (legs), the femur, patella (kneecap), tibia, fibula, tarsals (ankle bones), metatarsals (bones of the instep), and phalanges (toe bones). The large tarsal bone that forms the heel is the calcaneus (*kal-KA-ne-us*), shown in **FIGURE 5-1**.

All of these bone groups, and also the hyoid under the jaw and the ear ossicles, are listed with phonetic pronunciations and described in **BOX 5-1**.

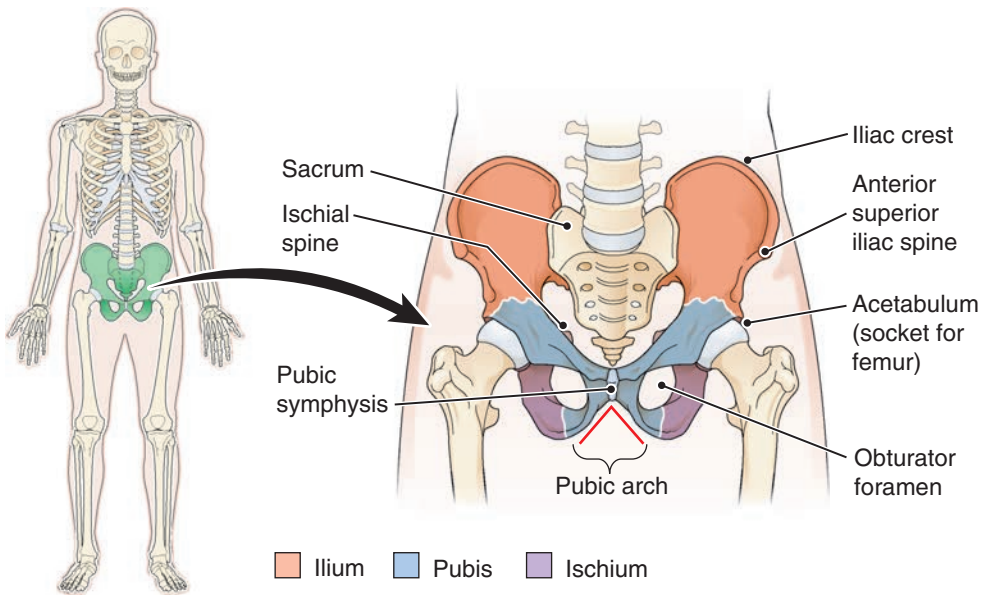

FIGURE 5-4 The pelvic bones. Each pelvic or hip bone is formed from three fused bones, the ilium, ischium, and pubis. Together with the sacrum and coccyx, they form the bony pelvis. The acetabulum is the socket for the femur.

extern.ir

FOR YOUR REFERENCE
Bones of the Skeleton

BOX 5-1

Region	Bones	Description
AXIAL SKELETON (*AK-se-al*)		
SKULL		
cranium (*KRA-ne-um*)	cranial bones (8)	form the chamber enclosing the brain; house the ear and form part of the eye socket
facial portion (*FA-shal*)	facial bones (14)	form the face and chambers for sensory organs
hyoid (*HI-oyd*)		U-shaped bone under mandible (lower jaw); used for muscle attachments
ossicles (*OS-ih-klz*)	ear bones (3)	transmit sound waves through middle ear
TRUNK		
vertebral column (*VER-teh-bral*)	vertebrae (26) (*VER-teh-bre*)	enclose the spinal cord
thorax (*THO-raks*)	sternum (*STER-num*) ribs (12 pairs)	anterior bone of the thorax enclose the organs of the thorax
APPENDICULAR SKELETON (*ap-en-DIK-u-lar*)		
UPPER DIVISION		
shoulder girdle	clavicle (*KLAV-ih-kl*) scapula (*SKAP-u-lah*)	anterior, between sternum and scapula posterior, anchors muscles that move arm
upper extremity	humerus (*HU-mer-us*) ulna (*UL-nah*) radius (*RA-de-us*) carpals (8) (*KAR-palz*) metacarpals (5) (*met-ah-KAR-palz*) phalanges (14) (*fah-LAN-jeze*)	proximal arm bone medial bone of forearm lateral bone of forearm wrist bones bones of palm bones of fingers
LOWER DIVISION		
pelvic bones (*PEL-vic*)	os coxae (2) (*os KOK-se*)	join sacrum and coccyx of vertebral column to form the bony pelvis
lower extremity	femur (*FE-mur*) patella (*pah-TEL-ah*) tibia (*TIB-e-ah*) fibula (*FIB-u-lah*) tarsal bones (7) (*TAR-sal*) metatarsals (5) (*met-ah-TAR-salz*) phalanges (14) (*fah-LAN-jeze*)	thigh bone kneecap medial bone of leg lateral bone of leg ankle bones; the large heel bone is the calcaneus (*kal-KA-ne-us*) bones of instep bones of toes

extern.ir

Bone Formation

Most bone tissue is formed by the gradual addition of calcium and phosphorus salts to **cartilage**, a type of dense connective tissue. (In a few places, such as the flat bones of the skull, bone forms from fibrous connective tissue.) The bone-forming process of **ossification** begins before birth and continues to adulthood. The fibrous protein, collagen, gives bone tissue its strength and resiliency. Although bone appears to be inert, it is actually living tissue that is constantly being replaced and remodeled throughout life. Three types of cells are involved in these changes:

- **Osteoblasts**, the cells that produce bone
- **Osteocytes**, mature bone cells that help to maintain bone tissue
- **Osteoclasts**, involved in the breakdown of bone tissue to release needed minerals or to allow for reshaping and repair

The process of destroying bone so that its components can be taken into the circulation is called **resorption.** This activity occurs continuously and is normally in balance with bone formation. In disease states, resorption may occur more rapidly or more slowly than bone production.

Structure of a Long Bone

A typical long bone (FIG. 5-5) has a shaft or **diaphysis** composed of compact bone tissue. Within the shaft is a medullary (marrow) cavity containing the yellow form of **bone marrow**, which is high in fat. The irregular **epiphysis** at either end is made of a less dense, spongy (cancellous) bone tissue (FIG. 5-6). This type of bone tissue encloses red bone marrow, where blood cells are formed.

The spaces in spongy bone contain the blood-forming red bone marrow. A layer of cartilage covers the epiphysis to protect the bone surface at a joint. The thin layer of fibrous tissue, or **periosteum**, that covers the bone's outer surface nourishes and protects the bone and also generates new bone cells for growth and repair.

Between the diaphysis and the epiphysis at each end, in a region called the **metaphysis**, is the growth region or **epiphyseal plate**. Long bones continue to grow in length at these regions throughout childhood and into early adulthood. When the bone stops elongating, this area becomes fully calcified but remains visible as the epiphyseal line (see FIG. 5-5).

Long bones are found in the arms, legs, hands, and feet. Other bones are described as:

- Flat (e.g., cranial bones, ribs, scapulae)
- Short (e.g., wrist and ankle bones)
- Irregular (e.g., facial bones, vertebrae)

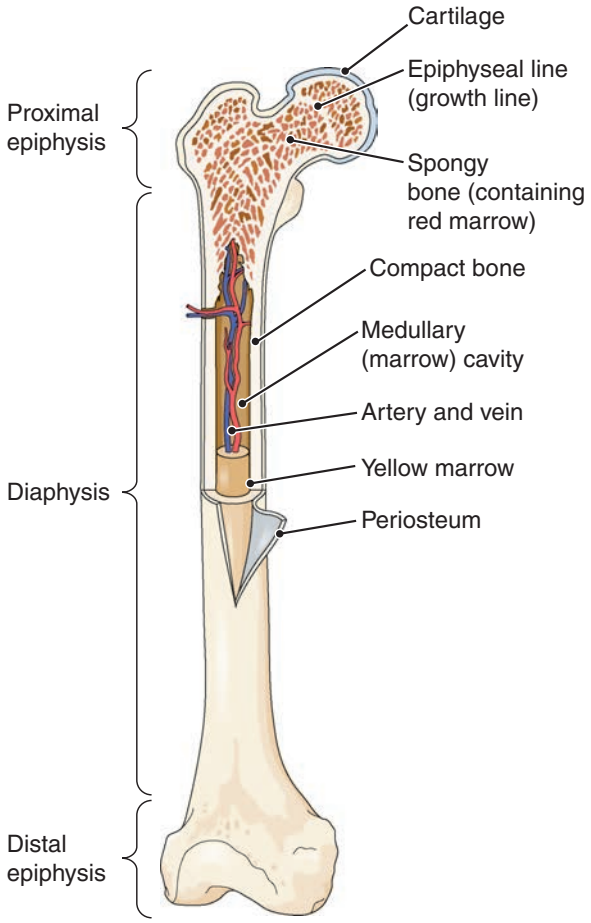

FIGURE 5-5 Structure of a long bone.

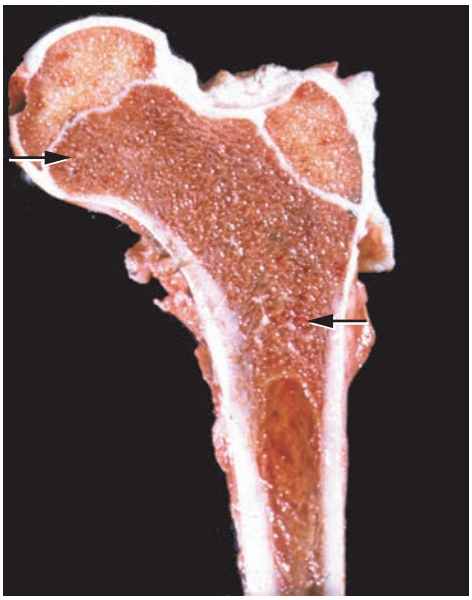

FIGURE 5-6 Bone tissue, longitudinal section. The epiphysis (end) of this long bone has an outer layer of compact bone. The remainder of the tissue is spongy (cancellous) bone, shown by the *arrows*. Transverse growth lines are also visible.

extern.ir

Joints

The joints, or **articulations**, are classified according to the degree of movement they allow:

- A **suture** is an immovable joint held together by fibrous connective tissue, as is found between the bones of the skull (see **FIG. 5-2**).
- A **symphysis** is a slightly movable joint connected by fibrous cartilage. Examples are the joints between the bodies of the vertebrae (see **FIG. 5-3**) and the joint between the pubic bones (see **FIG. 5-4**).
- A **synovial joint**, or **diarthrosis**, is a freely movable joint. Such joints allow for a wide range of movements, as described in Chapter 6. **Tendons** attach muscles to bones to produce movement at the joints.

Freely movable joints are subject to wear and tear, and they therefore have some protective features **(FIG. 5-7)**. The cavity of a diarthrotic joint contains **synovial fluid**, which cushions and lubricates the joint. This fluid is produced by the synovial membrane that lines the joint cavity. The ends of the articulating bones are cushioned and protected by cartilage. A fibrous capsule, continuous with the periosteum, encloses the joint. Synovial joints are stabilized and strengthened by **ligaments**, which connect the articulating bones. A **bursa** is a small sac of synovial fluid that cushions the area around a joint. Bursae are found at stress points between tendons, ligaments, and bones (see **FIG. 5-7**).

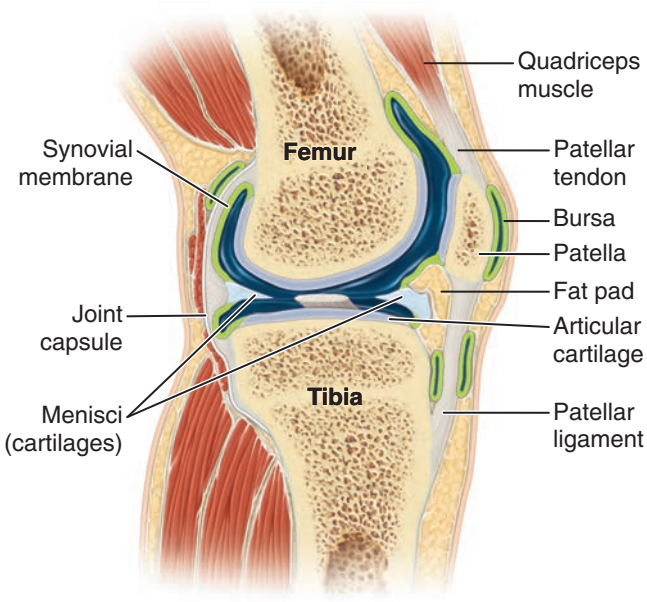

FIGURE 5-7 The knee joint, sagittal section. The knee joint is an example of a freely movable, synovial joint, also called a diarthrosis. Synovial fluid fills the joint cavity. Other protective structures such as cartilage, the joint capsule, ligaments, and bursae are also shown.

Terminology *Key Terms*

The terms listed below are emphasized in this chapter. Knowing them will help you organize and prioritize your learning. These boldface terms are also found, collectively, with all chapter key terms in the Glossary.

Normal Structure and Function

acetabulum *as-eh-TAB-u-lum*	The bony socket in the hip bone that holds the head of the femur (from the Latin word for vinegar because it resembles the base of a vinegar cruet) (see **FIG 5-4**)
articulation *ar-tik-u-LA-shun*	A joint (adjective: articular)
atlas *AT-las*	The first cervical vertebra (see **FIG. 5-3**) (root: atlant/o)
axis *AK-sis*	The second cervical vertebra (see **FIG. 5-3**)
bone	A calcified form of dense connective tissue; osseous tissue; also an individual unit of the skeleton made of such tissue (root: oste/o)
bone marrow	The soft material that fills bone cavities; yellow marrow fills the central cavity of the long bones; blood cells are formed in red bone marrow, which is located in spongy bone tissue (root: myel/o)
bursa *BUR-sah*	A fluid-filled sac that reduces friction near a joint (root: burs/o)
cartilage *KAR-tih-lij*	A type of dense connective tissue that is found in the skeleton, larynx, trachea, and bronchi; it is the precursor to most bone tissue (root: chondr/o)
diarthrosis *di-ar-THRO-sis*	A freely movable joint; also called a synovial joint (adjective: diarthrotic)

extern.ir

Terminology Key Terms (Continued)

diaphysis *di-AF-ih-sis*	The shaft of a long bone
epiphyseal plate *ep-ih-FIZ-e-al*	The growth region of a long bone; located in the metaphysis, between the diaphysis and epiphysis; when bone growth ceases, this area appears as the epiphyseal line; also spelled epiphysial
epiphysis *eh-PIF-ih-sis*	The irregularly shaped end of a long bone
ilium *IL-e-um*	The large, flared, superior portion of the pelvic bone (root: ili/o) (adjective: iliac)
joint	The junction between two bones; articulation (root: arthr/o)
ligament *LIG-ah-ment*	A strong band of connective tissue that joins one bone to another
metaphysis *meh-TAF-ih-sis*	The region of a long bone between the diaphysis (shaft) and epiphysis (end); during development, the growing region of a long bone
ossification *os-ih-fih-KA-shun*	The formation of bone tissue (from Latin *os*, meaning "bone")
osteoblast *OS-te-o-blast*	A cell that produces bone tissue
osteoclast *OS-te-o-clast*	A cell that destroys bone tissue
osteocyte *OS-te-o-site*	A mature bone cell that nourishes and maintains bone tissue
pelvis *(PEL-vis)*	The large ring of bone at the inferior trunk formed of the two hip bones (ossa coxae) joined to the sacrum and coccyx; each os coxae is formed of three bones: the superior, flared ilium (*IL-e-um*); ischium (*IS-ke-um*); and pubis (*PU-bis*) (plural: pelves [*PEL-veze*])
periosteum *per-e-OS-te-um*	The fibrous membrane that covers a bone's surface
resorption *re-SORP-shun*	Removal of bone by breakdown and absorption into the circulation
skeleton *SKEL-eh-ton*	The body's bony framework, consisting of 206 bones; the axial portion (80 bones) is composed of the skull, spinal column, ribs, and sternum; the appendicular skeleton (126 bones) contains the bones of the arms and legs, shoulder girdle, and pelvis (root: skelet/o)
suture *SU-chur*	An immovable joint, such as the joints between the skull bones
symphysis *SIM-fih-sis*	A slightly movable joint
synovial fluid *sih-NO-ve-al*	The fluid contained in a freely movable (diarthrotic) joint; synovia (root: synov/i)
synovial joint	A freely movable joint; has a joint cavity containing synovial fluid; a diarthrosis
tendon *TEN-don*	A fibrous band of connective tissue that attaches a muscle to a bone
thorax *THO-raks*	The upper part of the trunk between the neck and the abdomen; formed by the 12 pairs of ribs and sternum

extern.ir

Roots Pertaining to the Skeletal System

See TABLES 5-1 and 5-2.

Table 5-1 Roots for Bones and Joints

Root	Meaning	Example	Definition of Example
oste/o	bone	osteopenia *os-te-o-PE-ne-ah*	deficiency of bone tissue
myel/o	bone marrow; also, spinal cord	myeloid *MI-eh-loyd*	pertaining to or resembling bone marrow
chondr/o	cartilage	chondroblast *KON-dro-blast*	a cartilage-forming cell
arthr/o	joint	arthrosis *ar-THRO-sis*	joint; condition affecting a joint
synov/i	synovial fluid, joint, or membrane	asynovia *ah-sin-O-ve-ah*	lack of synovial fluid
burs/o	bursa	peribursal *per-ih-BER-sal*	around a bursa

Exercise 5-1

Complete the exercise. To check your answers go to Appendix 11.

Fill in the blanks.

1. Arthrodesis (*ar-THROD-eh-sis*) is fusion of a(n) _____ .
2. Myelogenous (*mi-eh-LOJ-eh-nus*) means originating in _____ .
3. Osteolysis (*os-te-OL-ih-sis*) is destruction of _____ .
4. A chondrocyte (*KON-dro-site*) is a cell found in _____ .
5. A bursolith (*BUR-so-lith*) is a stone in a(n) _____ .

Define the following words.

6. arthrocentesis (*ar-thro-sen-TE-sis*) _____
7. myelopoiesis (*mi-eh-lo-poy-E-sis*) _____
8. chondrodynia (*kon-dro-dih-ne-ah*) _____
9. osteoid (*OS-te-oyd*) _____
10. bursitis (*bur-SI-tis*) _____
11. synovial (*sih-NO-ve-al*) _____

extern.ir

Exercise 5-1 *(Continued)*

Write words for the following definitions.

12. inflammation of bone and bone marrow _____
13. a bone-forming cell _____
14. pertaining to or resembling cartilage _____
15. any disease of a joint _____
16. inflammation of a synovial membrane _____
17. radiography of the spinal cord _____
18. incision of a bursa _____
19. tumor of bone marrow _____
20. instrument for examining the interior of a joint _____

The word ostosis means "bone growth." Use this as a suffix for the following two words.

21. excess growth of bone _____
22. abnormal growth of bone _____

Table 5-2 Roots for the Skeleton

Root	Meaning	Example	Definition of Example
crani/o	skull, cranium	craniometry *kra-ne-OM-eh-tre*	measurement of the cranium
spondyl/o	vertebra	spondylolysis *spon-dih-LOL-ih-sis*	destruction and separation of a vertebra
vertebr/o	vertebra, spinal column	paravertebral *pah-rah-VER-te-bral*	near the vertebrae or spinal column
rachi/o	spine	rachischisis *ra-KIS-kih-sis*	fissure (-schisis) of the spine; spina bifida
cost/o	rib	costochondral *kos-to-KON-dral*	pertaining to a rib and its cartilage
sacr/o	sacrum	presacral *pre-SA-kral*	in front of the sacrum
coccy, coccyg/o	coccyx	coccygeal[a] *kok-SIJ-e-al*	pertaining to the coccyx
pelvi/o	pelvis	pelviscope *PEL-vih-skope*	endoscope for examining the pelvis
ili/o	ilium	iliopelvic *il-e-o-PEL-vik*	pertaining to the ilium and pelvis

[a]Note spelling.

extern.ir

Exercise 5-2

Complete the exercise. To check your answers go to Appendix 11.

Write adjectives for the following definitions. The adjective endings are provided in parentheses.

1. pertaining to (-al) the skull _____
2. pertaining to (-al) a rib _____
3. pertaining to (-ic) the pelvis _____
4. pertaining to (-ac) the ilium _____
5. pertaining to (-al) the spinal column _____
6. pertaining to (-al) the sacrum _____

Define the following terms.

7. craniotomy (*kra-ne-OT-o-me*) _____
8. prevertebral (*pre-VER-teh-bral*) _____
9. spondylodynia (*spon-dih-lo-DIN-e-ah*) _____
10. pelvimetry (*pel-VIM-eh-tre*) _____

Write words for the following definitions.

11. fissure of the skull _____
12. above the pelvis _____
13. pertaining to the cranium and sacrum _____
14. pertaining to the sacrum and ilium _____
15. surgical puncture of the spine; spinal tap _____
16. surgical excision of a rib _____
17. plastic repair of a vertebra (use vertebr/o) _____
18. inflammation of the vertebrae (use spondyl/o) _____
19. around the sacrum _____
20. below the ribs _____
21. pertaining to the ilium and coccyx _____
22. excision of the coccyx _____

Clinical Aspects of the Skeleton

Disorders of the skeleton often involve surrounding tissues—ligaments, tendons, and muscles—and may be studied together as diseases of the musculoskeletal system. (The muscular system is described in Chapter 6.) The medical specialty that concentrates on diseases of the skeletal and muscular systems is **orthopedics.** Physical therapists and occupational therapists must also understand these systems (**BOX 5-2**). (Some colorful terms used to describe musculoskeletal abnormalities are given in **BOX 5-3**.)

Most abnormalities of the bones and joints appear on simple radiographs (**FIG. 5-8** shows a radiograph of a normal joint). Radioactive bone scans, computed tomography (CT), and magnetic resonance imaging (MRI) scans are used as well. Also indicative of disorders are changes in blood levels of calcium and **alkaline phosphatase**, an enzyme needed for bone calcification.

extern.ir

HEALTH PROFESSIONS
Careers in Physical Therapy

BOX 5-2

Physical therapy restores mobility and relieves pain in cases of arthritis or musculoskeletal injuries. Individuals who are recovering from neuromuscular, cardiovascular, pulmonary, and integumentary events are also candidates for physical therapy. Some examples include traumatic brain injury (TBI), myocardial infarction (MI), chronic obstructive pulmonary disease (COPD), and burns, respectively.

Physical therapists (PTs) work closely with physicians, nurses, occupational therapists, and other allied healthcare professionals. Some treat a wide range of ailments, whereas others focus on a particular age group, medical field, or sports medicine. Regardless of specialty, PTs are responsible for examining their patients and developing individualized treatment programs. The examination includes a medical history and tests measuring strength, mobility, balance, coordination, and endurance. The treatment plan may include stretching and exercise to improve mobility; hot packs, cold compresses, and massage to reduce pain; and the use of crutches, prostheses, and wheelchairs. Physical therapy assistants (PTAs) work directly under the supervision of a physical therapist. PTAs are responsible for implementing a pre-established treatment plan, teaching patients exercises and equipment use, and reporting results back to the physical therapist.

Whereas many practicing physical therapists in the United States have bachelor's or master's degrees, most accredited physical therapy schools now offer doctoral programs requiring 3 years of postgraduate education. PTAs in the United States usually graduate with an associate degree from a community college and must pass a licensing exam. PTs and PTAs practice in hospitals and clinics and may also visit homes and schools. As the U.S. population continues to age and the need for rehabilitative therapy increases, job prospects are good. For more information about careers in physical therapy, contact the American Physical Therapy Association at apta.org.

FOCUS ON WORDS
Names That Are Like Pictures

BOX 5-3

Some conditions are named by terms that are very descriptive. In orthopedics, several names for types of bursitis are based on the repetitive stress that leads to the irritation. For example, "tailor's bottom" involves the ischial ("sit") bones of the pelvis, as might be irritated by sitting tailor-fashion to sew. "Housemaid's knee" comes from the days of scrubbing floors on hands and knees, and "tennis elbow" is named for the sport that is its most common cause. "Student's elbow" results from leaning to pore over books while studying, although today a student is more likely to have neck and wrist problems from working at a computer.

The term *knock-knee* describes genu valgum, in which the knees are abnormally close and the space between the ankles is wide. The opposite is genu varum, in which the knees are far apart and the bottom of the legs are close together, giving rise to the term *bowleg.* A dowager's hump appears dorsally between the shoulders as a result of osteoporosis and is most commonly seen in elderly women.

Injury to the roots of nerves that supply the arm may cause the arm to abduct slightly and rotate medially with the wrist flexed and the fingers pointing backward, a condition colorfully named "waiter's tip position." "Popeye's shoulder" is a sign of a separation or tear at the head of the biceps tendon. The affected arm, when abducted with the elbow flexed, reveals a bulge on the upper arm—just like Popeye's!

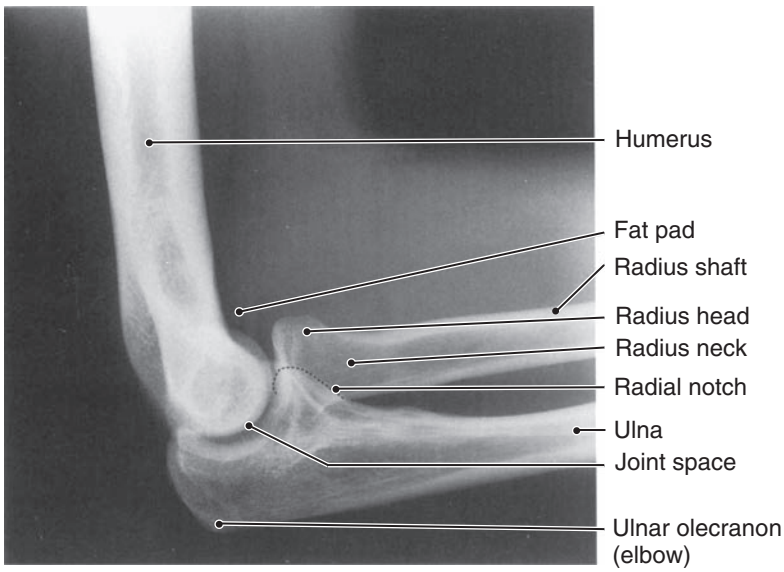

FIGURE 5-8 Radiograph of a normal left elbow joint, lateral view. The olecranon (*o-LEK-rah-non*) is the proximal ulnar enlargement that forms the prominent bone of the elbow.

extern.ir

INFECTION

Osteomyelitis is an inflammation of bone caused by pus-forming bacteria that enter through a wound or are carried by the blood. Often the blood-rich ends of the long bones are invaded, and the infection then spreads to other regions, such as the bone marrow and even the joints. The use of antibiotics has greatly reduced the threat of osteomyelitis.

Tuberculosis may spread to bone, especially the long bones of the arms and legs and the bones of the wrist and ankle. Tuberculosis of the spine is **Pott disease.** Infected vertebrae are weakened and may collapse, causing pain, deformity, and pressure on the spinal cord. Antibiotics can control tuberculosis as long as the strains are not resistant to these drugs and the host is not weakened by other diseases.

FRACTURES

A **fracture** is a break in a bone, usually caused by trauma. The effects of a fracture depend on the break's location and severity; the amount of associated injury; possible complications, such as infections; and success of healing, which may take months. Healing may be promoted by injecting a synthetic bone cement or applying an external magnetic field. In a closed or simple fracture, the skin is not broken. If the fracture is accompanied by a wound in the skin, it is described as an open fracture. Various types of fractures are listed in **BOX 5-4** and illustrated in **FIGURE 5-9**.

Reduction of a fracture refers to realignment of the broken bone. If no surgery is required, the reduction is described as closed; an open reduction is one that requires surgery to place the bone in proper position. Rods, plates, or screws might be needed to ensure proper healing. A splint or cast is often needed during the healing phase to immobilize the bone. **Traction** refers to using pulleys and weights to maintain alignment of a fractured bone during healing. A traction device may be attached to the skin or attached to the bone itself by means of a pin or wire.

METABOLIC BONE DISEASES

Osteoporosis is a loss of bone mass that results in bone weakening **(FIG. 5-10)**. A decrease in estrogens after menopause makes women over age 50 most susceptible to the effects of this disorder. Efforts to prevent osteoporosis include a healthful diet, adequate intake of calcium and vitamin D, and engaging in regular weight-bearing exercises, such as walking, running, aerobics, and weight training. These exercises stimulate bone growth and also contribute to the balance and muscle strength needed to prevent falls. Postmenopausal hormone replacement therapy (HRT) prevents bone loss, but medical researchers continue to evaluate the safety of this treatment. Long-term HRT has been implicated in breast and uterine cancers as well as increased risk of heart attack or stroke. The therapy is now recommended for short-term treatment of perimenopausal symptoms. Some drugs are available for reducing bone resorption and increasing bone density. These include the **bisphosphonates** and **selective estrogen receptor modulators** (**SERMs**) described in Chapter 16. Bisphosphonates are used with caution, as they have been

FOR YOUR REFERENCE — BOX 5-4
Types of Fractures

Fracture	Description
closed	a simple fracture with no open wound
Colles *KOL-eze*	fracture of the distal end of the radius with backward displacement of the hand
comminuted *COM-ih-nu-ted*	fracture in which the bone is splintered or crushed
compression	fracture caused by force from both ends, as to a vertebra
greenstick	one side of the bone is broken and the other side is bent
impacted	one fragment is driven into the other
oblique	break occurs at an angle across the bone; usually one fragment slips by the other
open	fracture is associated with an open wound, or broken bone protrudes through the skin
Pott	fracture of the distal end of the fibula with injury to the tibial joint
spiral	fracture is in a spiral or S shape; usually caused by twisting injuries
transverse	a break at right angles to the long axis of a bone

extern.ir

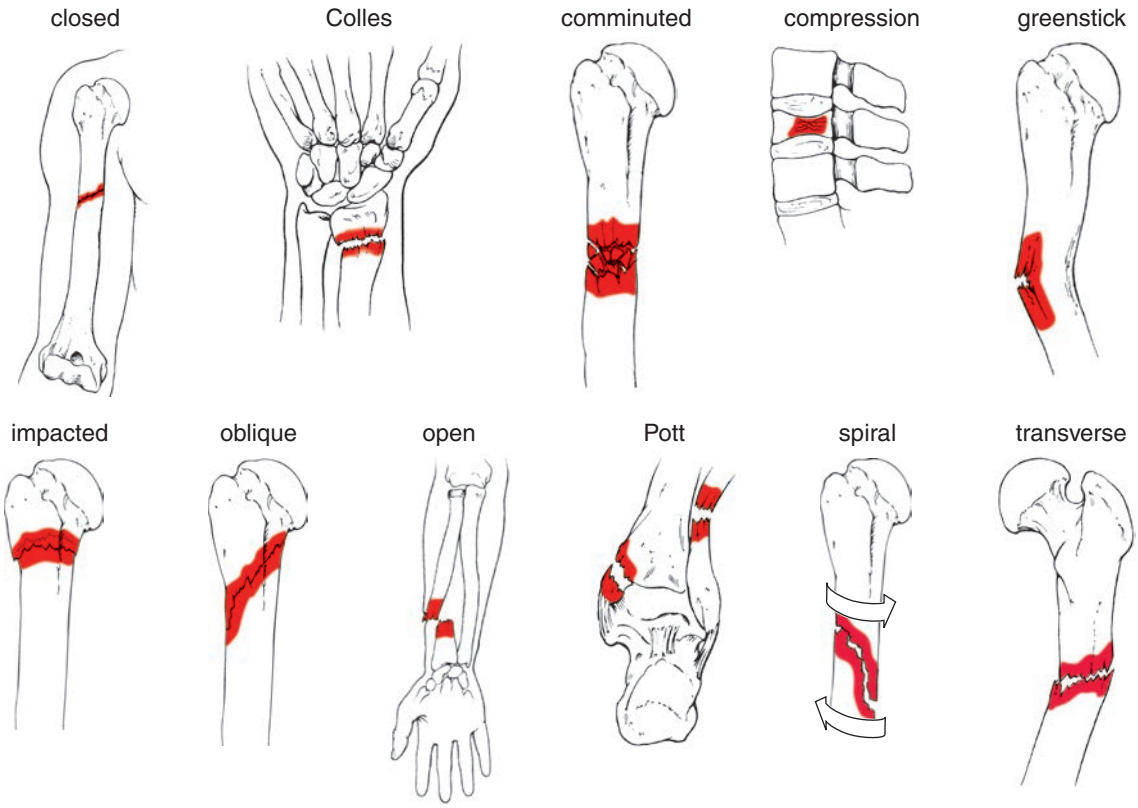

FIGURE 5-9 Types of fractures.

associated with unexplained bone fractures, necrosis of the jaw, and damage to the digestive tract.

Osteoporosis is diagnosed and monitored using a DEXA (dual-energy x-ray absorptiometry) scan, an imaging technique that measures bone mineral density (BMD). The diagnostic term **osteopenia** refers to a lower-than-average bone density, which is not considered to be abnormal. Osteopenia may progress to osteoporosis, but does not necessarily need treatment.

Other conditions that can lead to bone loss include nutritional deficiencies; disuse, as in paralysis or immobilization in a cast; and excess adrenocortical steroids. Overactivity of the parathyroid glands also leads to osteoporosis because parathyroid hormone causes calcium release from bones to raise blood calcium levels. Certain drugs, smoking, lack of exercise, and high intake of alcohol, caffeine, and proteins may also contribute to the development of osteoporosis.

In **osteomalacia** there is a softening of bone tissue because of diminished calcium salt formation. Possible causes include deficiency of vitamin D, needed to absorb calcium and phosphorus from the intestine; renal disorders; liver disease; and certain intestinal disorders. When

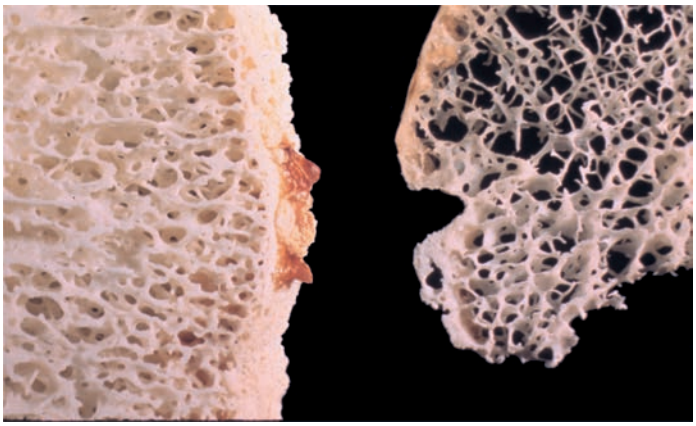

FIGURE 5-10 Osteoporosis. Femoral head showing osteoporosis (*right*) compared with a normal control (*left*).

extern.ir

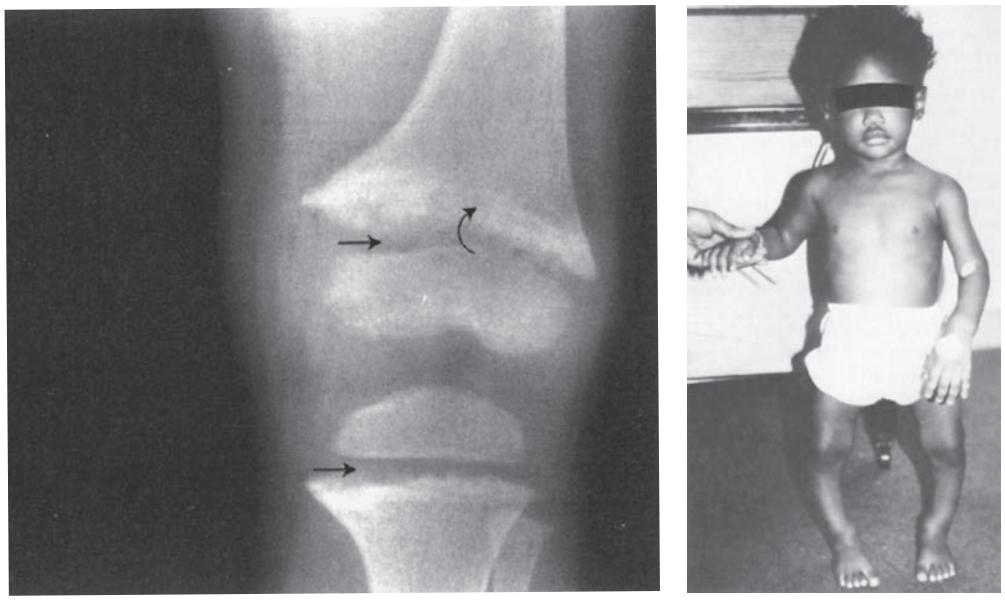

A B

FIGURE 5-11 Rickets. A. Radiograph of the left knee joint showing widening of the growth regions of the bones (*arrows*). **B.** Young child showing rickets.

osteomalacia occurs in children, the disease is called **rickets** (FIG. 5-11). Rickets is usually caused by a vitamin D deficiency.

Paget disease (osteitis deformans) is a disorder of aging in which bones become overgrown and thicker but deformed (FIG. 5-12). The disease results in bowing of the long bones and distortion of the flat bones, such as the skull bones. Paget disease usually involves the bones of the axial skeleton, causing pain, fractures, and hearing loss. With time, there may be neurologic signs, heart failure, and predisposition to bone cancer.

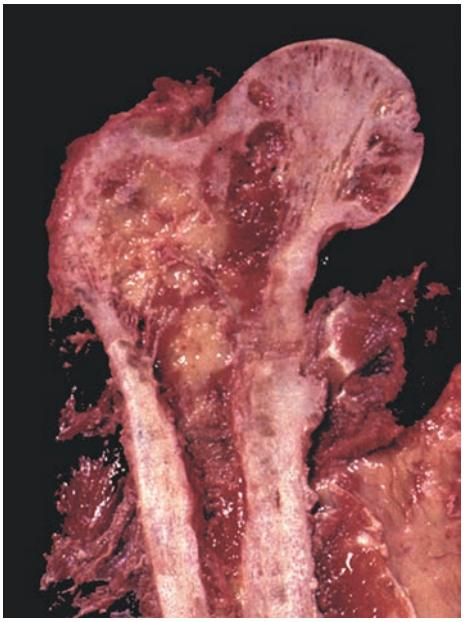

FIGURE 5-12 Paget disease. A section of the femur shows bone overgrowth in the diaphysis.

NEOPLASMS

Osteogenic sarcoma (osteosarcoma) most commonly occurs in a bone's growing region, especially around the knee. This is a highly malignant tumor that often requires amputation. It most commonly metastasizes to the lungs.

Chondrosarcoma usually appears in midlife. As the name implies, this tumor arises in cartilage. It may require amputation and most frequently metastasizes to the lungs.

In cases of malignant bone tumors, early surgical removal is important for prevention of metastasis. Signs of bone tumors are pain, easy fracture, and increases in serum calcium and alkaline phosphatase levels. Aside from primary tumors, neoplasms at other sites often metastasize to bone, most commonly to the spine.

JOINT DISORDERS

Some sources of joint problems include congenital malformations; infectious disease of the joint or adjacent bones; injury leading to degeneration; and necrosis resulting from loss of blood supply. **Arthritis** is a term broadly used to mean any inflammation of a joint. Based on the cause, several types are recognized.

extern.ir

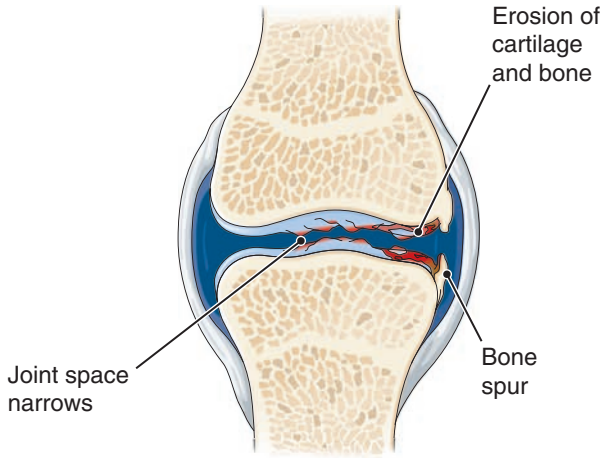

FIGURE 5-13 Joint changes in osteoarthritis (OA). The left side of the joint shows early changes with breakdown of cartilage and narrowing of the joint space. The right side shows progression of the disease with loss of cartilage and a bone overgrowth (spur).

Arthritis

The most common form of arthritis is **osteoarthritis** (**OA**) or **degenerative joint disease** (**DJD**) **(FIG. 5-13)**. This involves a gradual degeneration of articular (joint) cartilage as a result of wear and tear. Predisposing factors for OA are age, heredity, injury, congenital skeletal abnormalities, and endocrine disorders. OA usually appears at midlife and beyond and involves the weight-bearing joints, such as the knees, hips, and finger joints. Radiographs show a narrowing of the joint cavity and bone thickening. Cartilage may crack and break loose, causing inflammation in the joint and exposing the underlying bone.

OA is treated with analgesics to relieve pain; **anti-inflammatory agents**, such as corticosteroids; **nonsteroidal anti-inflammatory drugs** (**NSAIDs**); and physical therapy. Steroids can be injected directly into an arthritic joint, but because they may ultimately cause cartilage damage, only a few injections can be given within a year at intervals of several months. Treatment may include drainage of excess fluid from the joint in an **arthrocentesis.** Application of ice, elevation, and acupuncture may also help to relieve pain in cases of joint inflammation.

Rheumatoid arthritis (**RA**) is a systemic inflammatory joint disease that commonly appears in young adult women. Its exact causes are unknown, but it may involve immunologic reactions. A group of antibodies called **rheumatoid factor** often appears in the blood, but it is not always specific for RA as it may occur in other systemic diseases as well. There is an overgrowth of the synovial membrane that lines the joint cavity. As this membrane covers and destroys the joint cartilage, synovial fluid accumulates, causing joint swelling **(FIG. 5-14)**. There is degeneration of the underlying bones, eventually causing fusion, or **ankylosis.** Treatment includes rest, physical therapy, analgesics, and anti-inflammatory drugs.

FIGURE 5-14 Advanced rheumatoid arthritis. The hands show swelling of the joints and deviation of the fingers.

5

Gout is caused by an increased level of uric acid in the blood, salts of which are deposited in the joints. It mostly occurs in middle-aged men and almost always involves pain at the base of the great toe. Gout may result from a primary metabolic disturbance or may be a secondary effect of another disease, as of the kidneys. It is treated with drugs to suppress formation of uric acid or to increase its elimination (uricosuric agent).

Joint Repair

In **arthroscopy**, orthopedic surgeons use a type of endoscope called an arthroscope to examine a joint's interior and perform surgical repairs if needed **(FIG. 5-15)**. With an arthroscope, it is possible to remove or reshape articular cartilage and repair or replace ligaments.

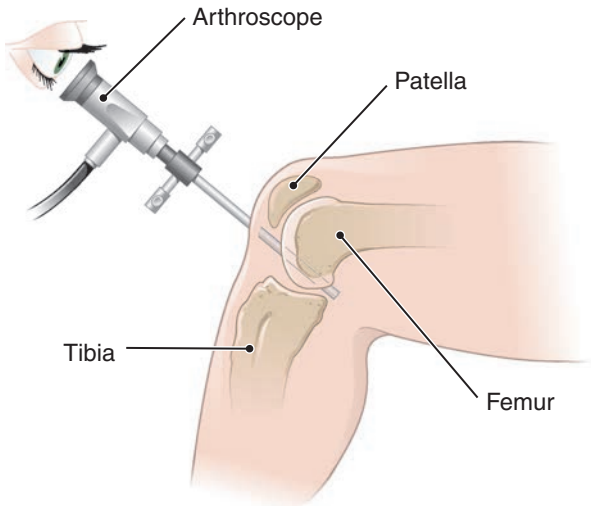

FIGURE 5-15 Arthroscopic examination of the knee. An arthroscope (a type of endoscope) is inserted between projections at the end of the femur to view the posterior of the knee.

extern.ir

CLINICAL PERSPECTIVES

BOX 5-5

Arthroplasty: Bionic Parts for a Better Life

Since the first total hip replacement in the early 1960s, millions of joint replacements, called arthroplasties, have been performed successfully. Most are done to decrease joint pain in older people with osteoarthritis and other chronic degenerative bone diseases after other treatments such as weight loss, physical therapy, and medication have been tried. Hips and knees are most commonly restored, with over 300,000 hip arthroplasties and more than 700,000 knee replacements performed each year in the United States. Orthopedic surgeons can also replace shoulder, elbow, wrist, hand, ankle, and foot joints.

Artificial, or *prosthetic*, joints are engineered to be strong, nontoxic, corrosion-resistant, and firmly bondable to the patient. Computer-controlled machines now produce individualized joints in less time and at less cost than in the past. Ball-and-socket joint prostheses, like those used in total hip replacement, consist of a cup, ball, and stem. The cup replaces the hip socket (acetabulum) and is bonded to the pelvis using screws or specialized cements. The cup is usually plastic but may also be made of longer-lasting ceramic or metal. The ball, made of metal or ceramic, replaces the femoral head and is attached to the stem, which is implanted into the femoral shaft. Stems are made of various metal alloys such as cobalt and titanium and are often glued into place. Stems designed to promote bone growth into them are commonly used in younger, more active patients because it is believed that they will remain firmly attached for a longer time.

Until recently, arthroplasty was rarely performed on young people because prostheses had life spans of only about 10 years. Today's materials and surgical techniques could increase this time to 20 years or more, and young people who undergo arthroplasty will require fewer replacements later on. This improvement is important because the incidence of sports-related joint injuries in young adults is increasing.

If more conservative treatments do not bring relief, orthopedists may recommend an arthroplasty. This term generally means any joint reconstruction but usually applies to a total or partial joint replacement. Hips, knees, shoulders, and other joints can be replaced with prostheses to eliminate pain and restore mobility, as explained in **BOX 5-5**.

A final alternative to relieve pain and provide stability at a joint is fusion, or **arthrodesis**, which results in total loss of joint mobility. Surgeons use pins or bone grafts to stabilize the joint and allow bone surfaces to adhere.

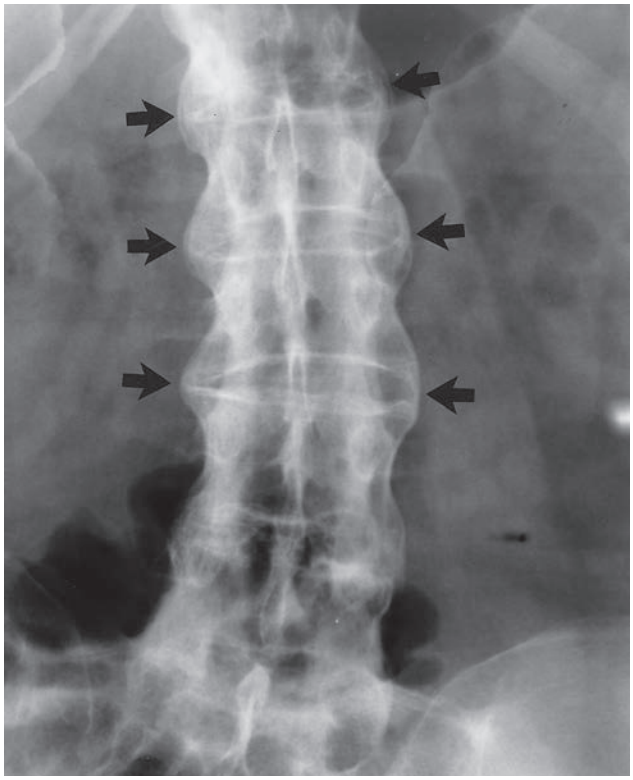

FIGURE 5-16 Ankylosing spondylitis. A frontal lumbar radiograph showing bone formation bridging the intervertebral disk spaces (*arrows*) and fusing the vertebrae.

DISORDERS OF THE SPINE

Ankylosing spondylitis is a disease of the spine that appears mainly in males. Joint cartilage is destroyed; eventually, the disks between the vertebrae calcify and there is ankylosis (fusion) of the bones **(FIG. 5-16)**. Changes begin low in the spine and progress upward, limiting mobility.

Spondylolisthesis is a forward sliding of a vertebra over the vertebra below (-listhesis means "a slipping") **(FIG. 5-17)**. The condition follows **spondylolysis,** degeneration of the joint structures that normally stabilize the vertebrae. Spondylolisthesis is most common in the spine's weight-bearing lumbar region, where it causes low back pain and sometimes leg pain resulting from irritation of spinal nerve roots.

Herniated Disk

In cases of a **herniated disk (FIG. 5-18)**, the central mass (nucleus pulposus) of an intervertebral disk protrudes through the disk's weakened outer ring (annulus fibrosus) into the spinal canal. This commonly occurs in the spine's lumbosacral or cervical regions as a result of injury or heavy lifting. The herniated or "slipped" disk puts pressure on the spinal cord or spinal nerves, often causing **sciatica**, which is pain along the sciatic nerve in the thigh. There may be spasms of the back muscles, leading to disability.

A herniated disk is diagnosed by myelography, CT scan, MRI, and neuromuscular tests. Treatment is bed rest and

extern.ir

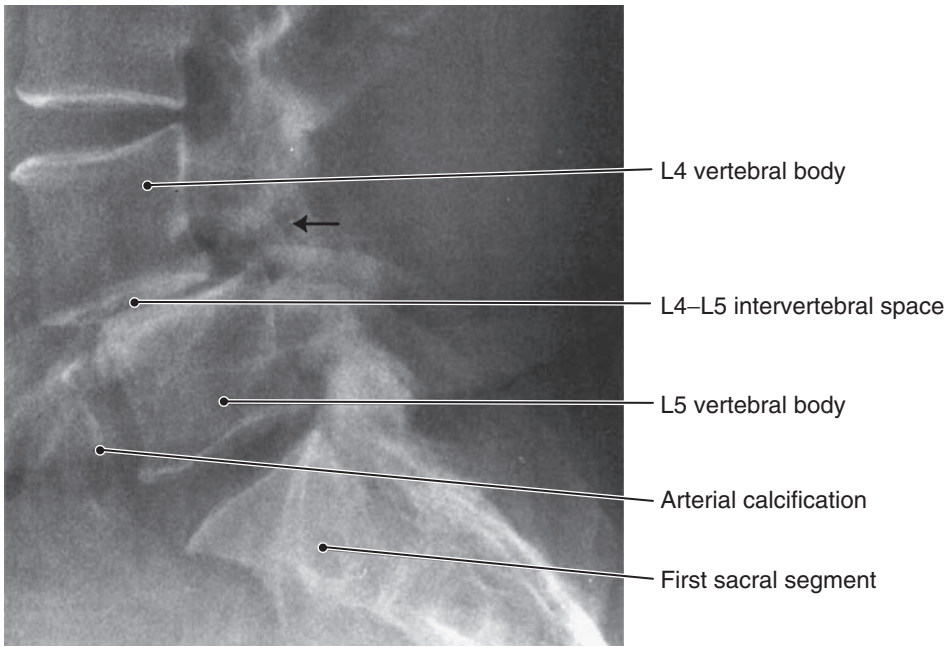

FIGURE 5-17 Spondylolisthesis. The L4 vertebral body has slid forward over L5, and there is marked narrowing of the L4–L5 intervertebral disk space.

drugs to reduce pain, muscle spasms, and inflammation followed by an exercise program to strengthen core and associated muscles. In severe cases, it may be necessary to remove the disk surgically in a **diskectomy**, sometimes followed by vertebral fusion with a bone graft to stabilize the spine. Using techniques of microsurgery (surgery done under magnification through a small incision), it is now possible to remove an exact amount of extruded disk tissue instead of the entire disk.

Curvatures of the Spine

The spine has four normal curves—two directed toward the anterior in the cervical and lumbar regions and two directed toward the posterior in the thoracic and sacral regions

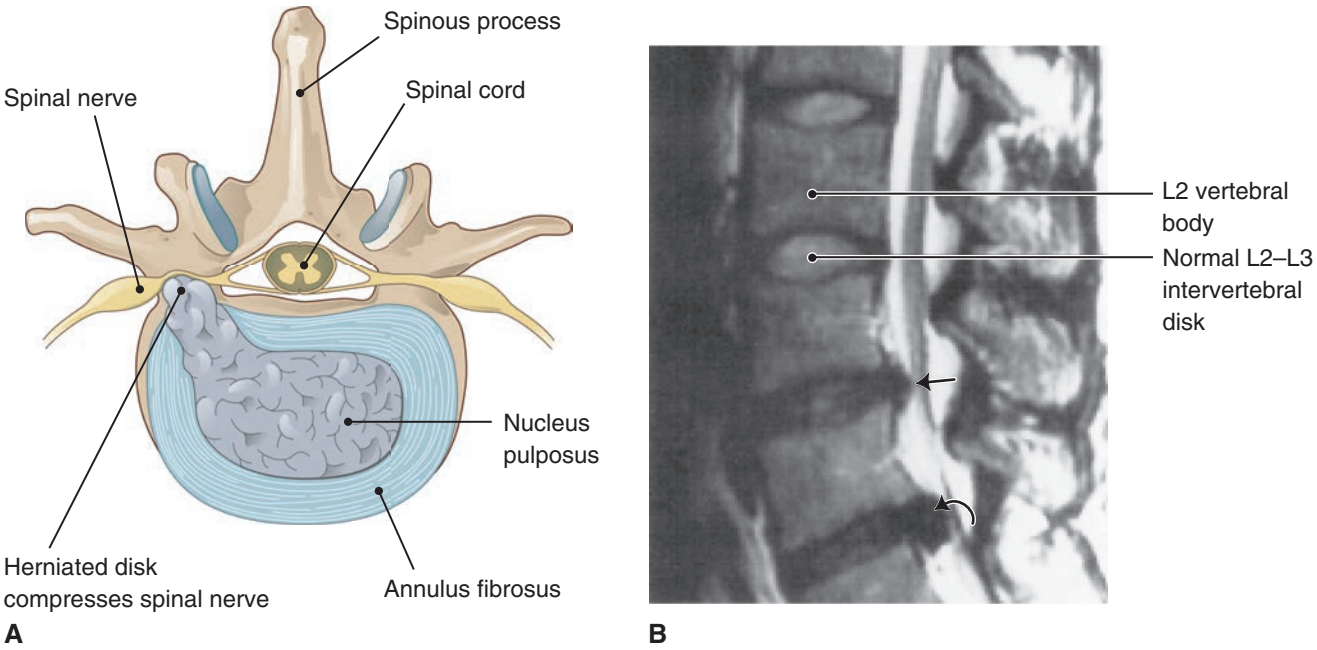

FIGURE 5-18 Herniated disk. A. The central mass of the disk protrudes into the spinal canal, putting pressure on the spinal nerve. **B.** Magnetic resonance image (MRI) of the lumbar spine, sagittal section, showing herniated disks at multiple levels. There is a bulging L3–L4 disk (*straight arrow*) and an extruded L4–L5 lumbar disk (*curved arrow*).

extern.ir

(see FIG. 5-3). Any exaggeration or deviation of these curves is described as **curvature of the spine.** Three common types of spinal curvatures are shown in FIGURE 5-19 and described as follows:

- **Kyphosis** is an exaggerated curve in the thoracic region, popularly known as "hunchback."
- **Lordosis** is an exaggerated curve in the lumber region, popularly known as "swayback."
- **Scoliosis** is a sideways curvature of the spine in any region. (A case of scoliosis is described in Rachel's opening case study.)

Spinal curvatures may be congenital or may result from muscle weakness or paralysis, poor posture, joint problems, disk degeneration, extreme obesity, or disease, such as spinal tuberculosis, rickets, or osteoporosis. Extreme cases may cause pain, breathing problems, or degenerative changes.

Bracing the spine during childhood may help to correct a curvature. If surgery is needed, vertebrae are fused and bone grafts and implants are used to stabilize the spine. It is now sometimes possible for surgeons to make these corrections endoscopically.

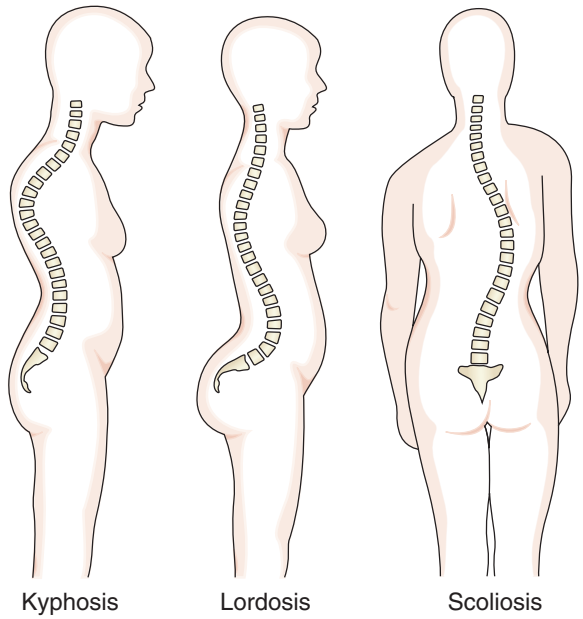

FIGURE 5-19 Curvatures of the spine. Kyphosis is an exaggerated thoracic curve; lordosis is an exaggerated lumbar curve; scoliosis is a sideways curve in any region.

Terminology *Key Terms*

The terms listed below are emphasized in this chapter. Knowing them will help you organize and prioritize your learning. These boldface terms are also found, collectively, with all chapter key terms in the Glossary.

Disorders

ankylosing spondylitis *ang-kih-LO-sing spon-dih-LI-tis*	A chronic, progressive inflammatory disease involving the spinal joints and surrounding soft tissue, most common in young males; also called rheumatoid spondylitis
ankylosis *ang-kih-LO-sis*	Immobility and fixation of a joint
arthritis *ar-THRI-tis*	Inflammation of a joint
chondrosarcoma *kon-dro-sar-KO-mah*	A malignant tumor of cartilage
curvature of the spine *KER-vah-chure*	An exaggerated spinal curve, such as scoliosis, lordosis, or kyphosis (see FIG. 5-19)
degenerative joint disease *(DJD)*	Osteoarthritis (see below)
fracture *FRAK-chure*	A break in a bone; in a closed or simple fracture, the broken bone does not penetrate the skin; in an open fracture, there is an accompanying wound in the skin (see FIG. 5-9)
gout *gowt*	A form of acute arthritis, usually beginning in the knee or foot, caused by deposit of uric acid salts in the joints
herniated disk *HER-ne-a-ted*	Protrusion of the center (nucleus pulposus) of an intervertebral disk into the spinal canal; ruptured or "slipped" disk
kyphosis *ki-FO-sis*	An exaggerated curve of the spine in the thoracic region; hunchback, humpback (see FIG. 5-19)

extern.ir

Terminology Key Terms (Continued)

lordosis *lor-DO-sis*	An exaggerated curve of the spine in the lumbar region; swayback (see **FIG. 5-19**)
osteoarthritis (OA) *os-te-o-ar-THRI-tis*	Progressive deterioration of joint cartilage with growth of new bone and soft tissue in and around the joint; the most common form of arthritis; results from wear and tear, injury, or disease; also called degenerative joint disease (DJD)
osteogenic sarcoma *os-te-o-JEN-ik*	A malignant bone tumor; osteosarcoma
osteomalacia *os-te-o-mah-LA-she-ah*	A softening and weakening of the bones due to vitamin D deficiency or other disease
osteomyelitis *os-te-o-mi-eh-LI-tis*	Inflammation of bone and bone marrow caused by infection, usually bacterial
osteopenia *os-te-o-PE-ne-ah*	A lower-than-average bone density, which may foreshadow osteoporosis
osteoporosis *os-te-o-po-RO-sis*	A condition characterized by reduction in bone density, most common in white women past menopause; predisposing factors include poor diet, inactivity, and low estrogen levels
Paget disease *PAJ-et*	Skeletal disease of the elderly characterized by bone thickening and distortion with bowing of long bones; osteitis deformans
Pott disease	Inflammation of the vertebrae, usually caused by tuberculosis
rheumatoid arthritis (RA) *RU-mah-toyd*	A chronic autoimmune disease of unknown origin resulting in inflammation of peripheral joints and related structures; more common in women than in men
rheumatoid factor	A group of antibodies found in the blood in cases of rheumatoid arthritis and other systemic diseases
rickets *RIK-ets*	Faulty bone formation in children, usually caused by a deficiency of vitamin D
sciatica *si-AT-ih-kah*	Severe pain in the leg along the course of the sciatic nerve, usually related to spinal nerve root irritation
scoliosis *sko-le-O-sis*	A sideways curvature of the spine in any region (see **FIG. 5-19**)
spondylolisthesis *spon-dih-lo-lis-THE-sis*	A forward displacement of one vertebra over another (-listhesis means "a slipping"); also pronounced *spon-dih-lo-LIS-theh-sis*
spondylolysis *spon-dih-LOL-ih-sis*	Degeneration of the articulating portions of a vertebra allowing for spinal distortion, specifically in the lumbar region
Treatment	
alkaline phosphatase *AL-kah-lin FOS-fah-tase*	An enzyme needed in the formation of bone; serum activity of this enzyme is useful in diagnosis
arthrocentesis *ar-thro-sen-TE-sis*	Aspiration of fluid from a joint by needle puncture
arthrodesis *ar-THROD-eh-sis*	Surgical immobilization (fusion) of a joint; artificial ankylosis
arthroplasty *AR-thro-plas-te*	Partial or total replacement of a joint with a prosthesis
arthroscopy *ar-THROS-ko-pe*	Use of an endoscope to examine the interior of a joint or to perform surgery on the joint (see **FIG. 5-14**); the instrument used is an arthroscope

(continued)

extern.ir

Terminology Key Terms (Continued)

diskectomy *dis-KEK-to-me*	Surgical removal of a herniated intervertebral disk; also spelled discectomy
orthopedics	The study and treatment of disorders of the skeleton, muscles, and associated structures; literally "straight" (ortho) "child" (ped); also spelled orthopaedics
reduction of a fracture	Return of a fractured bone to a normal position; may be closed (not requiring surgery) or open (requiring surgery)
traction *TRAK-shun*	The process of drawing or pulling, such as traction of the head in the treatment of injuries to the cervical vertebrae
Drugs	
anti-inflammatory agent	Drug that reduces inflammation; includes steroids, such as hydrocortisone, and nonsteroidal anti-inflammatory drugs (NSAIDs)
bisphosphonate *bis-FOS-fo-nate*	Agent used to prevent and treat osteoporosis; increases bone mass by decreasing bone turnover; examples are alendronate (Fosamax), risedronate (Actonel), and ibandronate (Boniva)
nonsteroidal anti-inflammatory drug (NSAID)	Drug that reduces inflammation but is not a steroid; examples include aspirin and ibuprofen and other inhibitors of prostaglandins, naturally produced substances that promote inflammation
selective estrogen receptor modulator (SERM)	Drug that acts on estrogen receptors; raloxifene (Evista) is used to prevent bone loss after menopause; other SERMs are used to prevent and treat estrogen-sensitive breast cancer

Terminology Enrichment Terms

The terms listed below expand on the key terms to increase your knowledge of this chapter topic.

Normal Structure and Function[a]

annulus fibrosus *AN-u-lus fi-BRO-sus*	Outer ring-like portion of an intervertebral disk (see **FIG. 5-17**)
calvaria *kal-VAR-e-ah*	The dome-like upper portion of the skull
coxa *KOK-sa*	Hip
cruciate ligaments *KRU-she-ate*	Ligaments that cross in the knee joint to connect the tibia and fibula; they are the anterior cruciate ligament (ACL) and the posterior cruciate ligament (PCL); *cruciate* means "shaped like a cross"
genu *JE-nu*	The knee
glenoid cavity *GLEN-oyd*	The bony socket in the scapula that articulates with the head of the humerus
hallux *HAL-uks*	The great toe
malleolus *mah-LE-o-lus*	The projection of the tibia or fibula on either side of the ankle
meniscus *meh-NIS-kus*	Crescent-shaped disk of cartilage found in certain joints, such as the knee joint; in the knee, the medial meniscus and the lateral meniscus separate the tibia and femur; *meniscus* means "crescent"; (plural: menisci [*meh-NIS-si*])

extern.ir

Terminology Enrichment Terms (Continued)

nucleus pulposus *NU-kle-us pul-PO-sus*	The central mass of an intervertebral disk (see **FIG. 5-17**)
olecranon *o-LEK-rah-non*	The process of the ulna that forms the elbow
os	Bone (plural: ossa)
osseous *OS-e-us*	Pertaining to bone
symphysis pubis *SIM-fih-sis*	The anterior pelvic joint, formed by the union of the two pubic bones (see **FIG. 5-4**); also called pubic symphysis
Symptoms and Conditions	
achondroplasia *ah-kon-dro-PLA-ze-ah*	Decreased growth of cartilage in the growth plate of long bones resulting in dwarfism; a genetic disorder
Baker cyst	Mass formed at the knee joint by distention of a bursa with excess synovial fluid resulting from chronic irritation
bunion *BUN-yun*	Inflammation and enlargement of the metatarsal joint of the great toe, usually with displacement of the great toe toward the other toes
bursitis *bur-SI-tis*	Inflammation of a bursa, a small fluid-filled sac near a joint; causes include injury, irritation, and joint disease; the shoulder, hip, elbow, and knee are common sites
carpal tunnel syndrome	Numbness and weakness of the hand caused by pressure on the median nerve as it passes through a channel formed by carpal bones
chondroma *kon-DRO-mah*	A benign tumor of cartilage
Ewing tumor *YU-ing*	A bone tumor that usually appears in children 5 to 15 years of age; it begins in the shaft of a bone and spreads readily to other bones; it may respond to radiation therapy but then returns; also called Ewing sarcoma
exostosis *eks-os-TO-sis*	A bony outgrowth from the surface of a bone
giant cell tumor	A bone tumor that usually appears in children and young adults; the ends of the bones are destroyed, commonly at the knee, by a large mass that does not metastasize
hammertoe	Change in position of the toe joints so that the toe takes on a claw-like appearance and the first joint protrudes upward, causing irritation and pain on walking
hallux valgus	Painful condition involving lateral displacement of the great toe at the metatarsal joint; there is also enlargement of the metatarsal head and bunion formation
Heberden nodes *HE-ber-den*	Small, hard nodules formed in the cartilage of the distal finger joints in osteoarthritis
hemarthrosis *heme-ar-THRO-sis*	Bleeding into a joint cavity
Legg–Calvé–Perthes disease *leg kahl-VA PER-tez*	Degeneration (osteochondrosis) of the femur's proximal growth center; the bone is eventually restored, but there may be deformity and weakness; most common in young boys; also called coxa plana
multiple myeloma *mi-eh-LO-mah*	A cancer of blood-forming cells in bone marrow (see Chapter 11)
neurogenic arthropathy *nu-ro-JEN-ikar-THROP-ah-the*	Degenerative joint disease caused by impaired nervous stimulation; most common cause is diabetes mellitus; Charcot (*shar-KO*) arthropathy

(continued)

extern.ir

Terminology *Enrichment Terms (Continued)*

Osgood–Schlatter disease *OZ-good SHLAHT-er*	Degeneration (osteochondrosis) of the tibia's proximal growth center causing pain and tendinitis at the knee
osteochondroma *os-te-o-kon-DRO-mah*	A benign tumor consisting of cartilage and bone
osteochondrosis *os-te-o-kon-DRO-sis*	Disease of a bone's growth center in children; tissue degeneration is followed by recalcification
osteodystrophy *os-te-o-DIS-tro-fe*	Abnormal bone development
osteogenesis imperfecta (OI) *os-te-o-JEN-eh-sis im-per-FEK-tah*	A hereditary disease resulting in the formation of brittle bones that fracture easily; there is faulty synthesis of collagen, the main structural protein in connective tissue
osteoma *os-te-O-mah*	A benign bone tumor that usually remains small and localized
Reiter syndrome *RI-ter*	Chronic polyarthritis that usually affects young men; occurs after a bacterial infection and is common in those infected with HIV; may also involve the eyes and genitourinary tract
spondylosis *spon-dih-LO-sis*	Degeneration and ankylosis of the vertebrae resulting in pressure on the spinal cord and spinal nerve roots; often applied to any degenerative lesion of the spine
subluxation *sub-luk-SA-shun*	A partial dislocation
talipes *TAL-ih-peze*	A deformity of the foot, especially one occurring congenitally; clubfoot
valgus *VAL-gus*	Bent outward
varus *VAR-us*	Bent inward
von Recklinghausen disease *fon REK-ling-how-zen*	Loss of bone tissue caused by increased parathyroid hormone; bones become decalcified and deformed and fracture easily
Diagnosis and Treatment	
allograft *AL-o-graft*	Graft of tissue between individuals of the same species but different genetic makeup; homograft, allogeneic graft (see autograft)
arthroclasia *ar-thro-KLA-ze-ah*	Surgical breaking of an ankylosed joint to provide movement
aspiration *as-pih-RA-shun*	Removal by suction, as removal of fluid from a body cavity; also inhalation, such as accidental inhalation of material into the respiratory tract
autograft *AW-to-graft*	Graft of tissue taken from a site on or in the body of the person receiving the graft; autologous graft (see allograft)
chondroitin *kon-DRO-ih-tin*	A complex polysaccharide found in connective tissue; used as a dietary supplement, usually with glucosamine, for treatment of joint pain
glucosamine *glu-KOS-ah-mene*	A dietary supplement used in the treatment of joint pain
goniometer *go-ne-OM-eh-ter*	A device used to measure joint angles and movements (root goni/o means "angle")
iontophoresis *i-on-to-for-E-sis*	Introduction into the tissue by means of electric current, using the ions of a given drug; used in the treatment of musculoskeletal disorders

extern.ir

Terminology *Enrichment Terms (Continued)*

laminectomy *lam-ih-NEK-to-me*	Excision of the posterior arch (lamina) of a vertebra
meniscectomy *men-ih-SEK-to-me*	Removal of the crescent-shaped cartilage (meniscus) of the knee joint
myelogram *MI-eh-lo-gram*	Radiograph of the spinal canal after injection of a radiopaque dye; used to evaluate a herniated disk
osteoplasty *OS-te-o-plas-te*	Scraping and removal of damaged bone from a joint
prosthesis *PROS-the-sis*	An artificial organ or part, such as an artificial limb

[a]See **BOX 5-6** for a list of bone markings.

FOR YOUR REFERENCE
Bone Markings

BOX 5-6

Marking	Description
condyle *KON-dile*	smooth, rounded protuberance at a joint
crest	raised, narrow ridge (see iliac crest in **FIG. 5-4**)
epicondyle *ep-ih-KON-dile*	projection above a condyle
facet *FAS-et*	small, flattened surface
foramen *for-A-men*	rounded opening (see foramen for spinal nerve in **FIG. 5-3**)
fossa *FOS-ah*	hollow cavity
meatus *me-A-tus*	passage or channel, such as a long channel within a bone; also the external opening of a canal, such as the urinary meatus
process	projection (see mastoid process and styloid process in **FIG. 5-2**)
sinus *SI-nus*	a space or channel, such as the air-filled spaces in certain skull bones **(FIG. 5-20)**
spine	sharp projection (see ischial spine in **FIG. 5-4**)
trochanter *tro-KAN-ter*	large, blunt projection as at the top of the femur
tubercle *TU-ber-kl*	small, rounded projection
tuberosity *tu-ber-OS-ih-te*	large, rounded projection

extern.ir

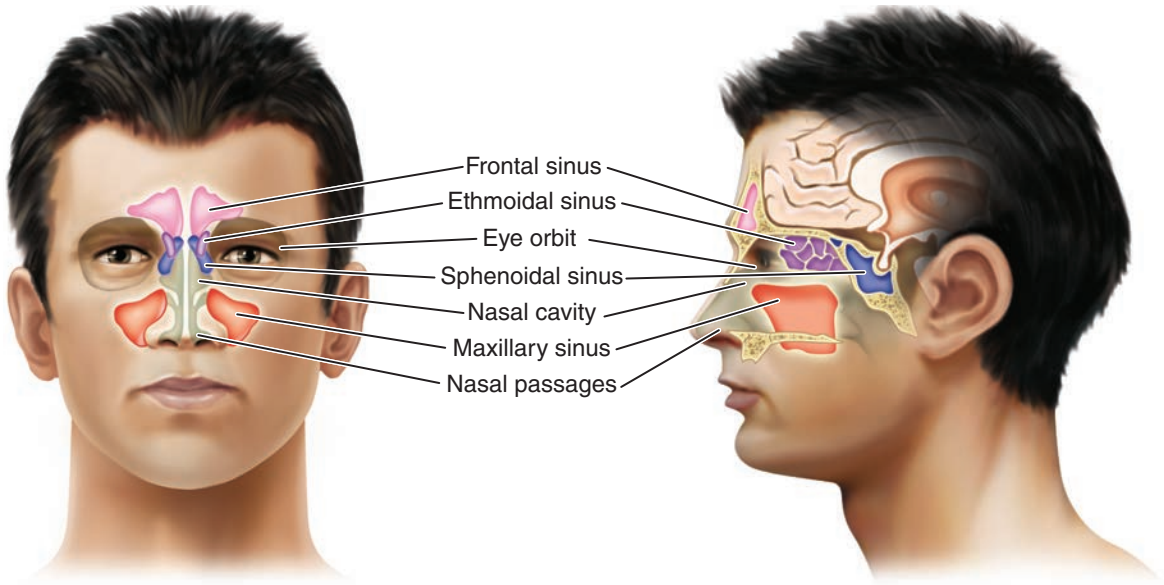

A Frontal View **B** Lateral View

FIGURE 5-20 Sinuses. A sinus is a cavity or hollow space, such as the air-filled chambers in certain skull bones that lighten the skull's weight. **A.** Frontal view of the head showing sinuses. **B.** Lateral view.

Terminology *Abbreviations*

The abbreviations listed below are emphasized in this chapter. These are also found, collectively, with all chapter abbreviations in Appendix 2.

ACL	Anterior cruciate ligament	**NSAID(s)**	Nonsteroidal anti-inflammatory drug(s)
AE	Above the elbow	**OA**	Osteoarthritis
AK	Above the knee	**OI**	Osteogenesis imperfecta
ASF	Anterior spinal fusion	**ORIF**	Open reduction internal fixation
BE	Below the elbow, also barium enema	**ortho, ORTH**	Orthopedics
BK	Below the knee	**PCL**	Posterior cruciate ligament
BMD	Bone mineral density	**PIP**	Proximal interphalangeal (joint)
C	Cervical vertebra; numbered C1 to C7	**PSF**	Posterior spinal fusion
Co	Coccyx; coccygeal	**RA**	Rheumatoid arthritis
DEXA	Dual-energy x-ray absorptiometry (scan)	**S**	Sacrum; sacral
DIP	Distal interphalangeal (joint)	**SERM**	Selective estrogen receptor modulator
DJD	Degenerative joint disease	**T**	Thoracic vertebra; numbered T1 to T12
Fx	Fracture	**THA**	Total hip arthroplasty
HNP	Herniated nucleus pulposus	**THP**	Total hip precautions
IM	Intramedullary, also intramuscular	**THR**	Total hip replacement
L	Lumbar vertebra; numbered L1 to L5	**TKA**	Total knee arthroplasty
MCP	Metacarpophalangeal (joint)	**TMJ**	Temporomandibular joint
MTP	Metatarsophalangeal (joint)	**Tx**	Traction

extern.ir

Case Study Revisited

Rachel's Follow-Up

Rachel underwent a successful surgical procedure and was transferred to the pediatric ICU. While in the ICU she was monitored and cared for by experienced pediatric RNs. She had round the clock assessments on her musculoskeletal and nervous systems, including checking for movement and sensation in her legs. Her vital signs, including pain scale, were monitored. The surgical sites were checked for any appearance of infection. And, proper nutrition was maintained to ensure her body stayed strong. Rachel did need some interventions such as oxygen, an adjustment of her pain meds, and comfort measures during the first days of recovery. She was also seen by the physical therapist (PT) who helped her learn how to ease herself into a seated position in the hospital bed. With further help from the PT Rachel was able to stand, pivot, and take two steps to the bedside chair. After 30 minutes sitting in the chair, Rachel was helped back to bed. On the PT's next visit Rachel was able to take a short walk in the hallway with assistance. Soon Rachel was feeling stronger. She was able to stand and walk with supervision and a walker. Her pain medicine was changed from IV to pill form.

Rachel felt well enough after four nights in the hospital to be discharged to home and was excited to get back to her own room. Her postoperative course progressed well. Her parents took her to her scheduled outpatient physical therapy and follow-up visits to the see the surgeon. Rachel had excellent compliance with all postoperative instructions and was able to resume her musical activities sooner than expected.

extern.ir

CHAPTER 5

Review

This review tests your understanding of the content introduced in this chapter. Follow the instructions for each exercise and check your answers in Appendix 11.

LABELING EXERCISE

THE SKELETON

Write the name of each numbered part on the corresponding line.

Calcaneus
Carpals
Clavicle
Cranium
Facial bones
Femur
Fibula
Humerus
Ilium
Mandible
Metacarpals
Metatarsals
Patella
Pelvis
Phalanges
Radius
Ribs
Sacrum
Scapula
Sternum
Tarsals
Tibia
Ulna
Vertebral column

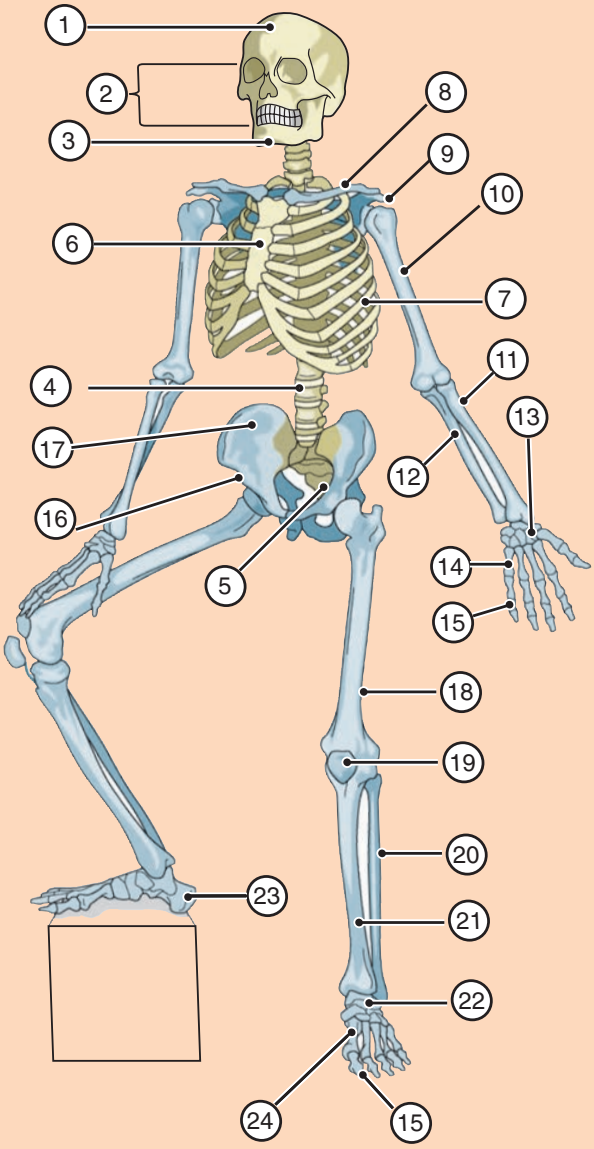

1. _____
2. _____
3. _____
4. _____
5. _____
6. _____
7. _____
8. _____
9. _____
10. _____
11. _____
12. _____
13. _____
14. _____
15. _____
16. _____
17. _____
18. _____
19. _____
20. _____
21. _____
22. _____
23. _____
24. _____

extern.ir

SKULL FROM THE LEFT

Write the name of each numbered part on the corresponding line.

Frontal
Hyoid
Lacrimal
Mandible
Maxilla
Nasal
Occipital
Parietal
Sphenoid
Temporal
Zygomatic

1. _____
2. _____
3. _____
4. _____
5. _____
6. _____
7. _____
8. _____
9. _____
10. _____
11. _____

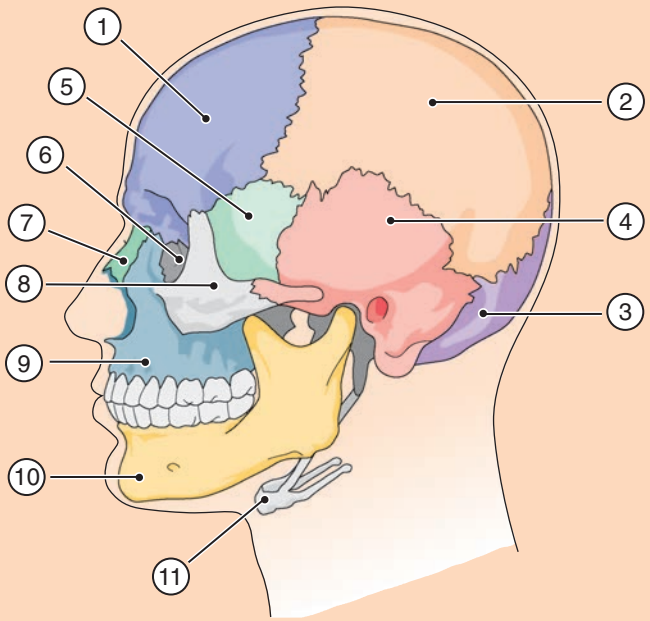

VERTEBRAL COLUMN

Write the name of each numbered part on the corresponding line.

Body of vertebra
Cervical vertebrae
Coccyx
Intervertebral disk
Lumbar vertebrae
Sacrum
Thoracic vertebrae

1. _____
2. _____
3. _____
4. _____
5. _____
6. _____
7. _____

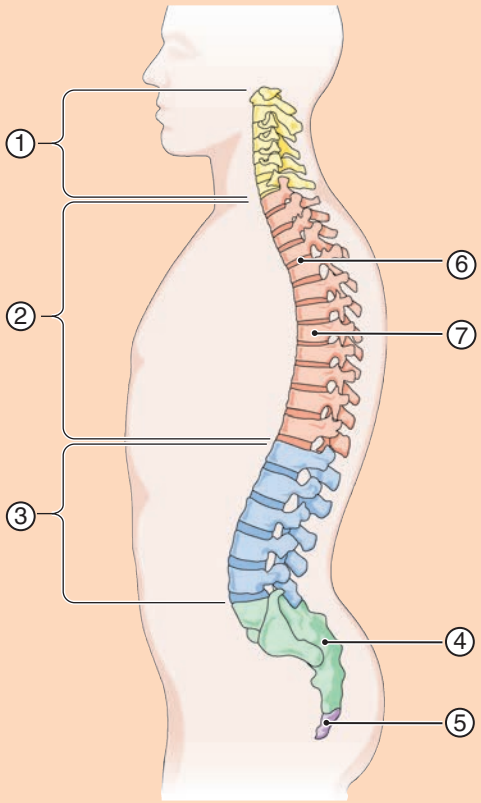

extern.ir

THE PELVIC BONES

Write the name of each numbered part on the corresponding line.

Ilium
Ischium
Pubis
Pubic symphysis
Acetabulum
Sacrum

1. _____
2. _____
3. _____
4. _____
5. _____
6. _____

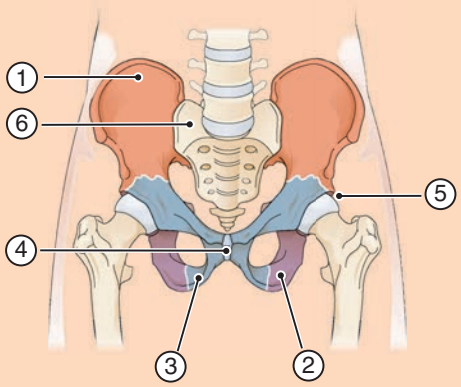

STRUCTURE OF A LONG BONE

Write the name of each numbered part on the corresponding line.

Artery and vein
Cartilage
Compact bone
Diaphysis
Distal epiphysis
Epiphyseal line (growth line)
Medullary cavity
Periosteum
Proximal epiphysis
Spongy bone (containing red marrow)
Yellow marrow

1. _____
2. _____
3. _____
4. _____
5. _____
6. _____
7. _____
8. _____
9. _____
10. _____
11. _____

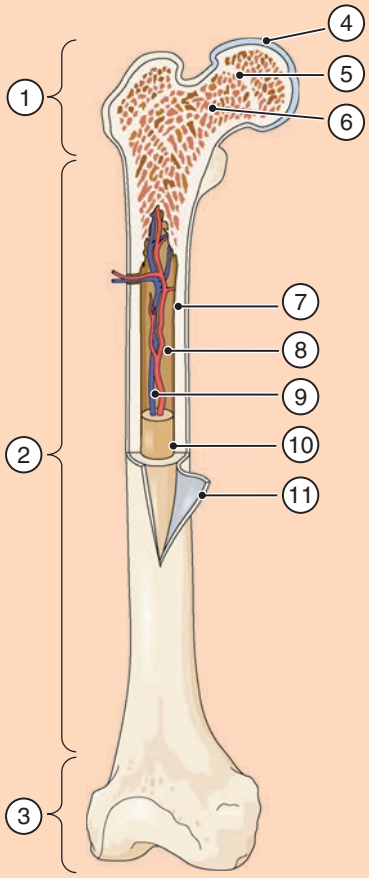

extern.ir

TERMINOLOGY

MATCHING

Match the following terms, and write the appropriate letter to the left of each number.

____ 1.	periosteum	a. an immovable joint
____ 2.	epiphysis	b. breakdown and removal of tissue
____ 3.	suture	c. cell that breaks down bone
____ 4.	osteoclast	d. membrane that covers a bone
____ 5.	resorption	e. end of a long bone

____ 6.	osteopenia	a. immobility of a joint
____ 7.	ankylosis	b. spinal tap
____ 8.	kyphosis	c. displacement of a vertebra
____ 9.	spondylolisthesis	d. exaggerated curve of the thoracic spine
____ 10.	rachiocentesis	e. deficiency of bone tissue

Enrichment Terms

____ 11.	laminectomy	a. great toe
____ 12.	chondroitin	b. dietary supplement for treatment of joint pain
____ 13.	subluxation	c. excision of part of a vertebra
____ 14.	hallux	d. part of the ulna that forms the elbow
____ 15.	olecranon	e. partial dislocation

____ 16.	meniscus	a. breaking of a joint
____ 17.	goniometer	b. device used to measure joint angles
____ 18.	arthroclasia	c. knee
____ 19.	genu	d. crescent-shaped cartilage
____ 20.	prosthesis	e. artificial part

FILL IN THE BLANKS

Complete the sentence with the correct term(s).

21. A fibrous band of connective tissue that connects a muscle to a bone is a(n) _____ .
22. The type of tissue that covers the ends of the bones at the joints is _____ .
23. The study and treatment of disorders of the skeleton, muscles, and associated structures is _____ .
24. The part of the vertebral column that articulates with the ilium is the _____ .
25. Chondrosarcoma (*kon-dro-sar-KO-mah*) is a malignant tumor of _____ .
26. The fluid that fills a freely movable joint is _____ .
27. A fluid-filled sac near a joint is a(n) _____ .
28. Myelogenesis (*mi-eh-lo-JEN-eh-sis*) is the formation of _____ .
29. Hemarthrosis (*heme-ar-THRO-sis*) is bleeding into a(n) _____ .
30. Spondylarthritis (*spon-dil-ar-THRI-tis*) is arthritis of the _____ .
31. Rachischisis (*ra-KIS-kih-sis*) is fissure of the _____ .

extern.ir

DEFINITIONS

Define the following words. Remember to use the phonetics in the following exercises to pronounce each word as you work.

32. myelitis (*mi-eh-LI-tis*) _____
33. ossification (*os-sih-fih-KA-shun*) _____
34. arthrodesis (*ar-THROD-eh-sis*) _____
35. synovectomy (*sin-o-VEK-to-me*) _____
36. chondrocyte (*KON-dro-site*) _____
37. subcostal (*sub-KOS-tal*) _____
38. coccydynia (*kok-se-DIN-e-ah*) _____
39. spondylitis (*spon-dih-LI-tis*) _____
40. polyarticular (*pol-e-ar-TIK-u-lar*) _____
41. intraosteal (*in-trah-OS-te-al*) _____
42. peribursal (*per-ih-BER-sal*) _____

Write words for the following definitions.

43. formation of cartilage _____
44. surgical immobilization of a joint _____
45. measurement of the pelvis _____
46. tumor of bone and cartilage _____
47. narrowing of a joint _____
48. death (necrosis) of bone tissue _____
49. stone in a bursa _____
50. incision into the cranium _____
51. near the sacrum _____
52. pertaining to the sacrum and ilium _____
53. surgical excision of the coccyx _____
54. endoscopic examination of a joint _____

Find a word in Rachel's opening case study for each of the following.

55. describing a disease with no known cause _____
56. a bone of the shoulder girdle _____
57. a bone of the pelvis _____
58. the area where T4 is located _____
59. incisions into bones _____
60. sideways curvature of the spine _____

extern.ir

ADJECTIVES

Write the adjective form of the following words.

61. sacrum _____
62. vertebra _____
63. coccyx _____
64. pelvis _____
65. ilium _____

TRUE–FALSE

Examine each of the following statements. If the statement is true, write T in the first blank. If the statement is false, write F in the first blank, and correct the statement by replacing the underlined word in the second blank.

	True or False	Correct Answer
66. The growth region of a long bone is in the diaphysis.	_____	_____
67. The tarsal bones are found in the ankle.	_____	_____
68. A slightly moveable joint is a symphysis.	_____	_____
69. The femur is part of the axial skeleton.	_____	_____
70. The cervical vertebrae are located in the neck.	_____	_____
71. The cells that produce cartilage are chondroblasts.	_____	_____
72. Blood cells are formed in yellow bone marrow.	_____	_____
73. An exaggerated lumbar curve of the spine is scoliosis.	_____	_____
74. The term *varus* means bent inward.	_____	_____

ELIMINATIONS

In each of the sets below, underline the word that does not fit in with the rest, and explain the reason for your choice.

75. trochanter — process — hyoid — meatus — condyle

_____

76. lambdoid — occipital — parietal — frontal — sphenoid

_____

77. sacr/o — rachi/o — spondyl/o — vertebr/o — cost/o

_____

78. Pott — sciatic — impacted — comminuted — greenstick

_____

79. T — C — L — Co — OA

_____

extern.ir

WORD BUILDING

Write words for the following definitions using the word parts provided. Each word part can be used more than once.

spondyl/o	-plasty	arthr/o	-lysis	-odynia	oste/o	-tome

80. pain in a joint _____
81. destruction of a vertebra _____
82. pain in a vertebra _____
83. loosening or separation of a joint _____
84. instrument for cutting bone tissue _____
85. plastic repair of a joint _____
86. pain in a bone _____
87. instrument for incising a joint _____
88. destruction of bone tissue _____
89. plastic repair of a bone _____

WORD ANALYSIS

Define the following words, and give the meaning of the word parts in each. Use a dictionary if necessary.

90. osteochondrosis (*os-te-o-kon-DRO-sis*)
    a. oste/o _____
    b. chondr/o _____
    c. -sis _____
91. spondylosyndesis (*spon-dih-lo-SIN-deh-sis*)
    a. spondyl/o _____
    b. syn- _____
    c. -desis _____
92. exostosis (*eks-os-TO-sis*)
    a. ex/o _____
    b. ost(e)/o _____
    c. -sis _____

extern.ir

93. achondroplasia (*ah-kon-dro-PLA-ze-ah*)

    a. a- _____

    b. chondr/o _____

    c. plas _____

    d. -ia _____

94. osteoporosis (*os-te-o-po-RO-sis*)

    a. osteo- _____

    b. poro- _____

    c. -sis _____

extern.ir

Additional Case Studies

Case Study 5-1: Arthroplasty of the Right TMJ

Susan, a 38 y/o teacher, was admitted for surgery for degenerative joint disease (DJD) of her right temporomandibular joint (TMJ). She has experienced chronic pain in her right jaw, neck, and ear since her automobile accident the previous year. Susan's diagnosis was confirmed by CT scan and was followed up with conservative therapy, which included a bite plate, NSAIDs, and steroid injections. She had also tried hypnosis in an attempt to manage her pain but was not able to gain relief. Her doctor referred her to an oral surgeon who specializes in TMJ disorders. Susan was scheduled for an arthroplasty of the right TMJ to remove diseased bone on the articular surface of the right mandibular condyle.

On the following day, she was transported to the OR for surgery. She was given general endotracheal anesthesia, and a vertical incision was made from the superior aspect of the right ear down to the base of the attachment of the right earlobe. After appropriate dissection and retraction, the posterior–superior aspect of the right zygomatic arch was bluntly dissected anteroposteriorly. With a nerve stimulator, the zygomatic branch of the facial nerve was identified and retracted from the surgical field with a vessel loop. The periosteum was then incised along the superior aspect of the arch. An inferior dissection was then made along the capsular ligament and retracted posteriorly. With a Freer elevator, the meniscus was freed, and a horizontal incision was made to the condyle. With a Hall drill and saline coolant, a high condylectomy of approximately 3 mm of bone was removed while conserving function of the external pterygoid muscle. The stump of the condyle was filed smooth and irrigated copiously with NS. The lateral capsule, periosteum, subcutaneous tissue, and skin were then closed with sutures. The facial nerve was tested before closing and confirmed to be intact. A pressure pack and Barton bandage were applied. The sponge, needle, and instrument counts were correct. Estimated blood loss (EBL) was approximately 50 mL.

Susan was discharged on the second postoperative day with instructions for a soft diet, daily mouth-opening exercises, an antibiotic (Keflex 500 mg po q6h), Tylenol no. 3 po q4h p.r.n. for pain, and four weekly postoperative appointments.

extern.ir

Case Study 5-1 Questions

Follow the instructions for each question and check your answers in Appendix 11.

Multiple Choice. *Select the best answer, and write the letter of your choice to the left of each number.*

_____ 1. A condylectomy is
   a. removal of a joint capsule
   b. removal of a rounded bone protuberance
   c. enlargement of a cavity
   d. removal of a tumor

_____ 2. The articular surface of a bone is located
   a. under the epiphysis
   b. at a joint
   c. at a muscle attachment
   d. at a tendon attachment

_____ 3. The dissection directed anteroposteriorly was done
   a. posterior–superior
   b. circumferentially
   c. front to back
   d. top to bottom

5

Write terms from the case study that means the following.

4. pertaining to the cheek bone _____
5. the membrane around a bone _____
6. a crescent-shaped cartilage in a joint _____
7. plastic repair of a joint _____

Define the following abbreviations. Refer to Appendix 2, if needed.

8. DJD _____
9. NS _____
10. TMJ _____
11. EBL _____

extern.ir

Case Study 5-2: Osteogenesis Imperfecta

Cooper, a 3 y/o boy with osteogenesis imperfecta (OI) type III, was admitted to the pediatric orthopedic hospital for treatment of yet another fracture. Since birth he has had 15 arm and leg fractures as a result of his congenital disease. This latest fracture occurred when he twisted at the hip while standing in his wheeled walker. He has been in a research study and receives a bisphosphonate infusion every 2 months. He is short in stature with short limbs for his age and has bowing of both legs.

Cooper was transferred to the OR and carefully lifted to the OR table by the staff. After he was anesthetized, he was positioned with gentle manipulation, and his left hip was elevated on a small gel pillow. After skin preparation and sterile draping, a stainless-steel rod was inserted into the medullary canal of his left femur to reduce and stabilize the femoral fracture. The muscle, fascia, subcutaneous tissue, and skin were sutured closed. Three nurses gently held Cooper in position on a pediatric spica box while the surgeon applied a hip spica (body cast) to stabilize the fixation, protect the leg, and maintain abduction. Cooper was transferred to the postanesthesia care unit (PACU) for recovery. The surgeon dictated the procedure as an open reduction internal fixation (ORIF) of the left femur with intramedullary (IM) rodding and application of spica cast.

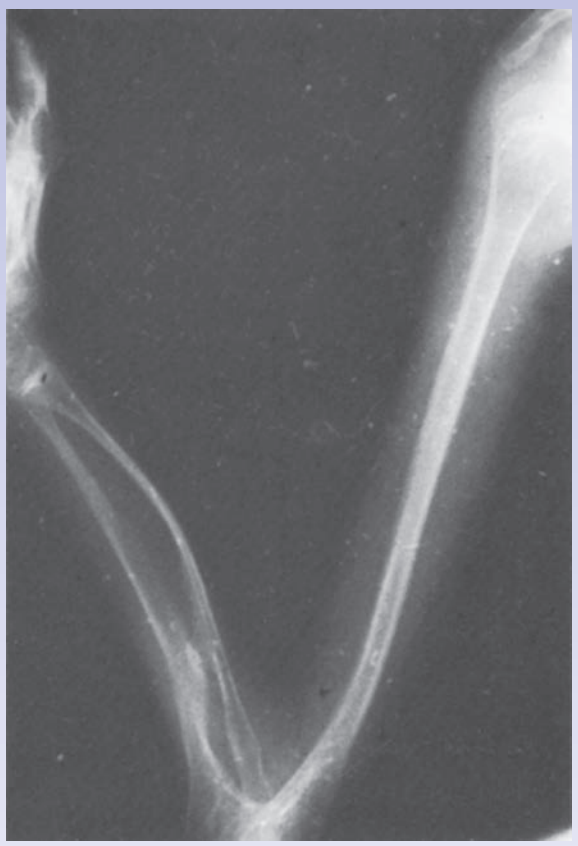

Osteogenesis imperfecta. X-ray of the upper extremity shows the thin bones and fractures that result from defective collagen production.

extern.ir

Case Study 5-2 Questions

Follow the instructions for each question and check your answers in Appendix 11.

Multiple Choice. *Select the best answer, and write the letter of your choice to the left of each number.*

_____ 1. Another term for bow-legged is
- a. knock-kneed
- b. adduction
- c. varus
- d. valgus

_____ 2. An IM rod is placed
- a. inferior to the femoral condyle
- b. into the acetabulum
- c. within the medullary canal
- d. lateral to the epiphysial growth plates

Write terms from the case study that means the following.

3. formation of bone tissue _____
4. a break in a bone _____
5. present at birth _____
6. the thigh bone _____

Define the following abbreviations.

7. OI _____
8. ORIF _____
9. OR _____
10. IM _____
11. PACU _____

extern.ir

CHAPTER 6

Muscular System

Pretest

Multiple Choice. **Select the best answer, and write the letter of your choice to the left of each number. To check your answers go to Appendix 11.**

_____ 1. The neuromuscular junction is between a muscle and a
a. gland
b. neuron
c. bone
d. gonad

_____ 2. In the muscular system, the opposite of the origin is the
a. counterorigin
b. agonist
c. insertion
d. diaphragm

_____ 3. The quadriceps femoris muscle forms the anterior part of the
a. neck
b. back
c. abdomen
d. thigh

_____ 4. The opposite of flexion is
a. rotation
b. antiflexion
c. relaxation
d. extension

_____ 5. The opposite of abduction is
a. adduction
b. circumduction
c. periduction
d. pronation

_____ 6. The band of connective tissue that attaches a muscle to a bone is a
a. cartilage
b. tendon
c. bursa
d. diaphysis

_____ 7. Polymyositis is inflammation of many
a. sense organs
b. glands
c. muscles
d. bones

_____ 8. The word *kinesis* means
a. movement
b. bending
c. stretching
d. pain

extern.ir



Learning Objectives

After careful study of this chapter, you should be able to:

1. Compare the location and function of smooth, cardiac, and skeletal muscles. ***P190***
2. Describe the typical structure of a skeletal muscle. ***P190***
3. Briefly describe the mechanism of muscle contraction. ***P190***
4. Explain how muscles work together to produce movement. ***P191***
5. Describe the main types of movements produced by muscles. ***P192***
6. List some of the criteria for naming muscles, and give examples of each. ***P192***
7. Identify and use the roots pertaining to the muscular system. ***P197***
8. Describe at least seven disorders that affect muscles. ***P198***
9. Interpret abbreviations pertaining to muscles. ***P204***
10. Analyze several case studies involving muscles. ***PP189, 212***

Case Study: Thomas's Brachial Plexus Injury

Chief Complaint

Thomas, a 16 y/o high school student, had a severe lacrosse accident that resulted in a flail arm. He had sustained right brachial plexus injury and had no recovery. He has continued to take medication for neurologic pain. He was scheduled to see his orthopedic surgeon for a possible brachial plexus exploration.

Examination

The orthopedic surgeon examined Thomas and noted that there had not been any change in his condition since the previous visit. Thomas still had no feeling or motion in his right shoulder or arm. He had atrophy over the supraspinatus and infraspinatus muscles and also subluxation of his shoulder and deltoid atrophy. He had no active motion of the right upper extremity and no sensation. The rest of his orthopedic exam showed full ROM of his hips, knees, and ankles with intact sensation and palpable distal pulses as well as normal motor function. He was diagnosed with a possible middle trunk brachial plexus injury from C7.

Clinical Course

Thomas and his parents had previous discussions with the surgeon and were aware of the prognosis and treatment plan. With middle trunk brachial plexus injury, damage to the subscapular nerve will interrupt conduction to the subscapularis and teres major muscles. Damage to the long thoracic nerve prevents conduction to the serratus anterior muscles. Injury to the pectoral nerves affects the pectoralis major and minor muscles.

Thomas was scheduled for an EMG, nerve conduction studies, and somatosensory evoked potentials (SSEPs). His diaphragm was examined under fluoroscopy to R/O phrenic nerve injury. The results of the diagnostic studies indicated that Thomas had most likely sustained a middle trunk brachial plexus injury. Thomas was scheduled for a brachial plexus exploration with possible bilateral sural (calf) nerve graft, nerve transfer, or gracilis muscle graft from his right thigh.

Case Study Revisited: Once you complete this chapter, please review the case follow-up on p. 205.

Ancillaries *At-A-Glance*

Visit the web resource to access the following resources.

Learning Resources

- eBook
- A&P Module with Heart & Lung Sounds
- Image Bank
- TestPrep
- Animations
- Audio Pronunciation Glossary

extern.ir

Introduction

The main characteristic of **muscle** tissue is its ability to contract. When stimulated, muscles shorten to produce movement of the skeleton, vessel walls, or internal organs. Muscles may also remain partially contracted to maintain posture. In addition, the heat generated by muscle contraction is the main source of body heat.

Types of Muscles

There are three types of muscle tissue in the body (FIG. 6-1):

- **Smooth** (visceral) **muscle** makes up the walls of the hollow organs, such as the stomach, intestines, and uterus, and the walls of ducts, such as the blood vessels and bronchioles. Smooth muscle operates involuntarily and is responsible for peristalsis, the wave-like movements that propel materials through the systems.
- **Cardiac muscle** makes up the myocardium of the heart wall. It functions involuntarily and is responsible for the heart's pumping action.
- **Skeletal muscle** is attached to bones and is responsible for voluntary movement. It also maintains posture and generates a large proportion of body heat. All of these voluntary muscles together make up the muscular system.

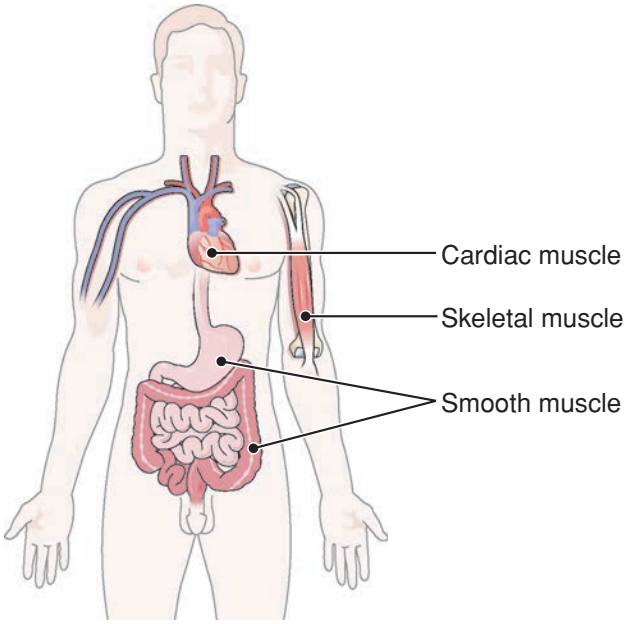

FIGURE 6-1 Muscle types. Smooth muscle makes up the walls of ducts and hollow organs, such as the stomach and intestine; cardiac muscle makes up the heart wall; skeletal muscle is attached to bones.

Skeletal Muscle

The discussion that follows describes the characteristics of skeletal muscle, which has been the most extensively studied of the three muscle types.

MUSCLE STRUCTURE

Muscles are composed of individual cells, often referred to as fibers because they are so long and thread-like. These cells are held together in **fascicles** (bundles) by connective tissue (FIG. 6-2). Covering each muscle is a sheath of connective tissue or **fascia**. These supporting tissues merge to form the **tendons** that attach the muscle to bones.

MUSCLE ACTION

Skeletal muscles are stimulated to contract by motor neurons of the nervous system (FIG. 6-3). At the **neuromuscular junction** (NMJ), the synapse (junction) where a branch of a neuron meets a muscle cell, the neurotransmitter **acetylcholine** (ACh) is released from small vesicles (sacs) in an axon branch. ACh interacts with the muscle cell membrane to prompt cellular contraction. Two special protein filaments in muscle cells, **actin** and **myosin**, interact to produce the contraction. ATP (the cell's energy compound) and calcium are needed for this response. BOX 6-1 discusses the use of steroids to increase muscle development and strength.

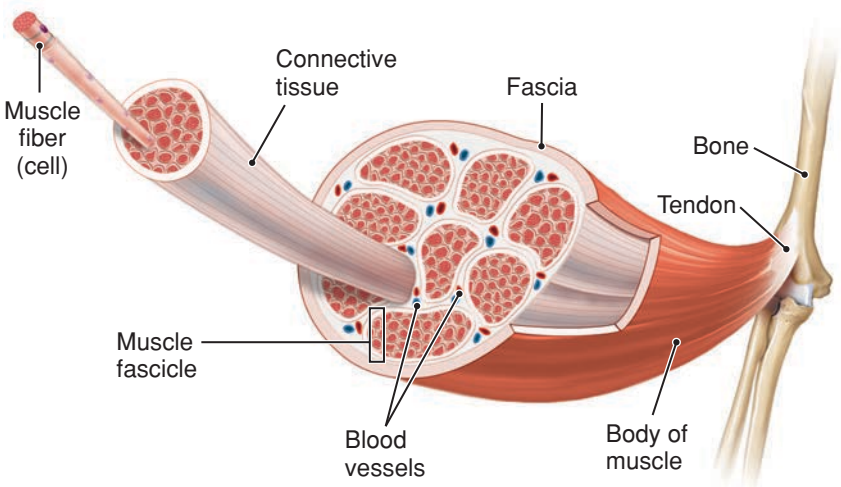

FIGURE 6-2 Structure of a skeletal muscle. Connective tissue coverings are shown as is the tendon that attaches the muscle to a bone.

extern.ir

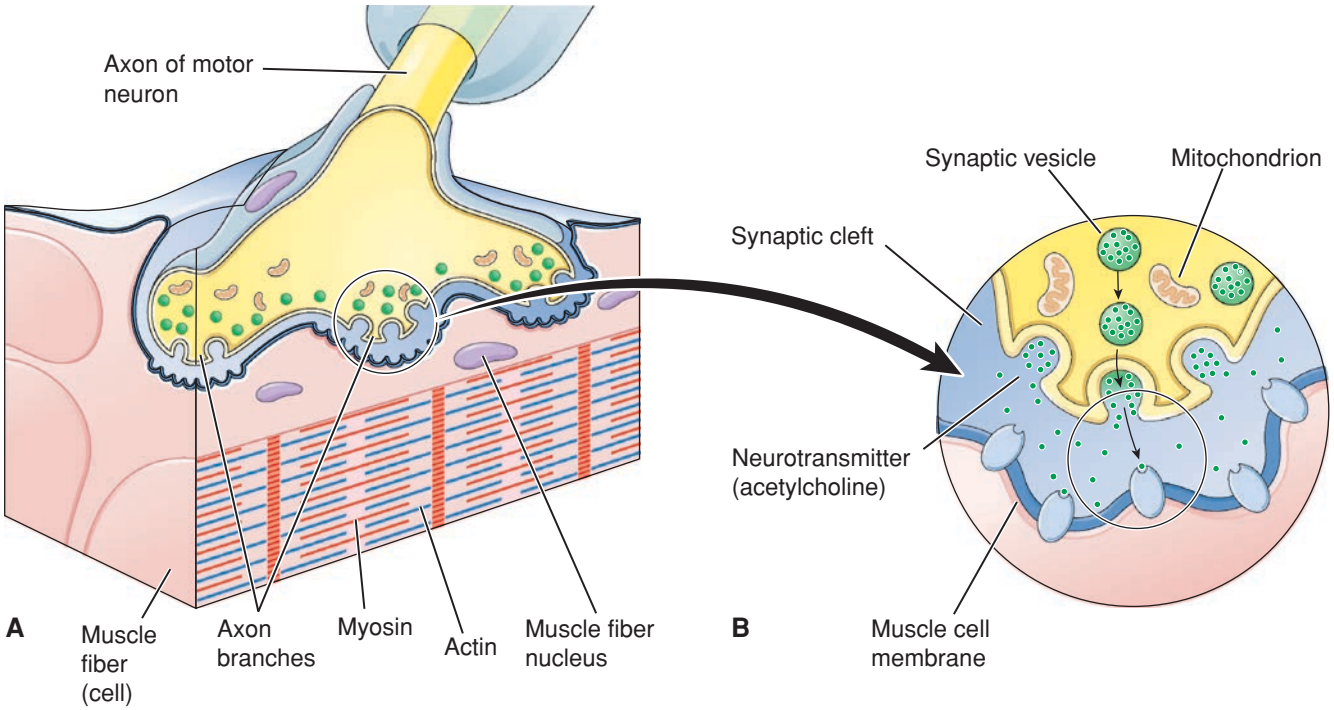

FIGURE 6-3 Neuromuscular junction (NMJ). A. The branched end of a motor neuron makes contact with the membrane of a muscle fiber (cell). **B.** Enlarged view of the NMJ showing release of neurotransmitter (acetylcholine) from a neuron and its attachment to a muscle cell membrane. Mitochondria generate ATP, the cells' energy compound.

Most skeletal muscles contract rapidly to produce movement and then relax rapidly unless stimulation continues. Sometimes muscles are kept in a steady partially contracted state, to maintain posture, for example. This state of firmness is called **tonus**, or *muscle tone*.

Muscles work in pairs to produce movement at the joints. Any muscle that produces a given movement is described as an **agonist**. If a group of muscles is involved in the action, the main one is called the **prime mover**. When an agonist contracts, an opposing muscle, the **antagonist**, must relax. For example, when the brachialis muscle on the anterior surface of the upper arm contracts as the prime mover to flex the arm, the triceps brachii on the posterior surface must relax (FIG. 6-4). When the arm is extended, these actions are reversed; the triceps brachii contracts, and

CLINICAL PERSPECTIVES

BOX 6-1

Anabolic Steroids: Winning at All Costs?

Anabolic steroids mimic the effects of the male sex hormone testosterone by promoting metabolism and stimulating growth. These drugs are legally prescribed to promote muscle regeneration and prevent atrophy from disuse after surgery. However, athletes also purchase them illegally, using them to increase muscle size and strength and improve endurance.

When steroids are used illegally to enhance athletic performance, the doses needed are large enough to cause serious side effects. They increase blood cholesterol levels, which may lead to atherosclerosis, heart disease, kidney failure, and stroke. Steroids damage the liver, making it more susceptible to disease and cancer, and they suppress the immune system, increasing the risk of infection and cancer. In men, steroids cause impotence, testicular atrophy, low sperm count, infertility, and the development of female sex characteristics such as breasts (gynecomastia). In women, steroids disrupt ovulation and menstruation and produce male sex characteristics such as breast atrophy, clitoral enlargement, increased body hair, and deepening of the voice. In both sexes, steroids increase the risk for baldness, and especially in men, they cause mood swings, depression, and violence.

extern.ir

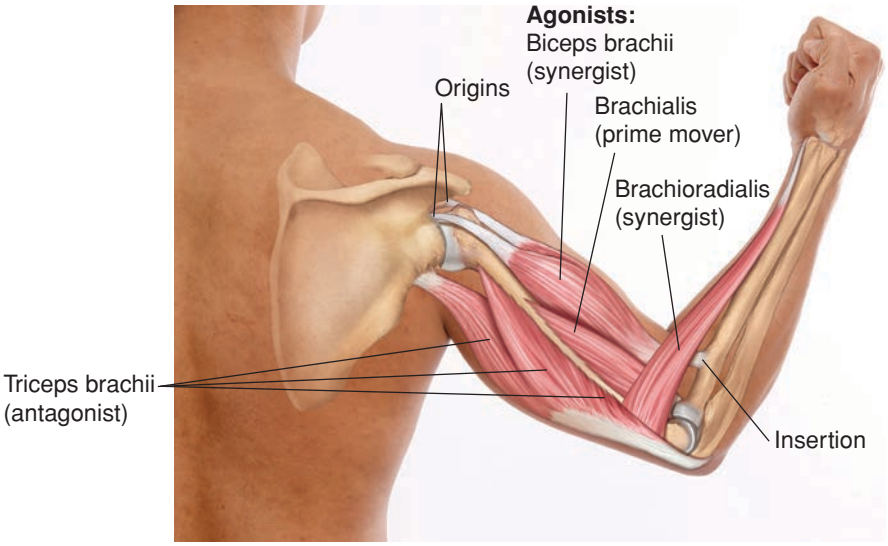

FIGURE 6-4 Muscles work together. When the brachialis, the agonistic prime mover, flexes the arm, the triceps brachii, the antagonist, must relax. Synergists, the biceps brachii and the brachioradialis, assist in this action. When the arm is extended, these muscle actions are reversed. This figure also shows three attachments of the biceps brachii, two origins and one insertion.

the brachialis must relax. Any muscle that assists the prime mover to produce an action is called a **synergist**. For example, the biceps brachii (most visible on the anterior surface when the arm is flexed) and the brachioradialis assist the brachialis to flex the arm.

In a given movement, the point where the muscle is attached to a stable part of the skeleton is the **origin**; the point where a muscle is attached to a moving part of the skeleton is the **insertion** (see FIG. 6-4).

BOX 6-2 describes various types of movements at the joints; these are illustrated in FIGURE 6-5. See also BOX 6-3 for a description of careers in physical fitness.

FOR YOUR REFERENCE
Types of Movement

BOX 6-2

Movement	Definition	Example
flexion *FLEK-shun*	closing the angle at a joint	bending at the knee or elbow
extension *eks-TEN-shun*	opening the angle at a joint	straightening at the knee or elbow
abduction *ab-DUK-shun*	movement away from the midline of the body	outward movement of the arm at the shoulder
adduction *ah-DUK-shun*	movement toward the midline of the body	return of lifted arm to the body
rotation *ro-TA-shun*	turning of a body part on its own axis	turning of the forearm from the elbow
circumduction *ser-kum-DUK-shun*	circular movement from a central point	tracing a circle with an outstretched arm
pronation *pro-NA-shun*	turning downward	turning the palm of the hand downward
supination *su-pin-A-shun*	turning upward	turning the palm of the hand upward
eversion *e-VER-zhun*	turning outward	turning the sole of the foot outward
inversion *in-VER-zhun*	turning inward	turning the sole of the foot inward
dorsiflexion *dor-shi-FLEK-shun*	bending backward	moving the foot so that the toes point upward, away from the sole of the foot
plantar flexion	bending the sole of the foot	pointing the toes downward

extern.ir

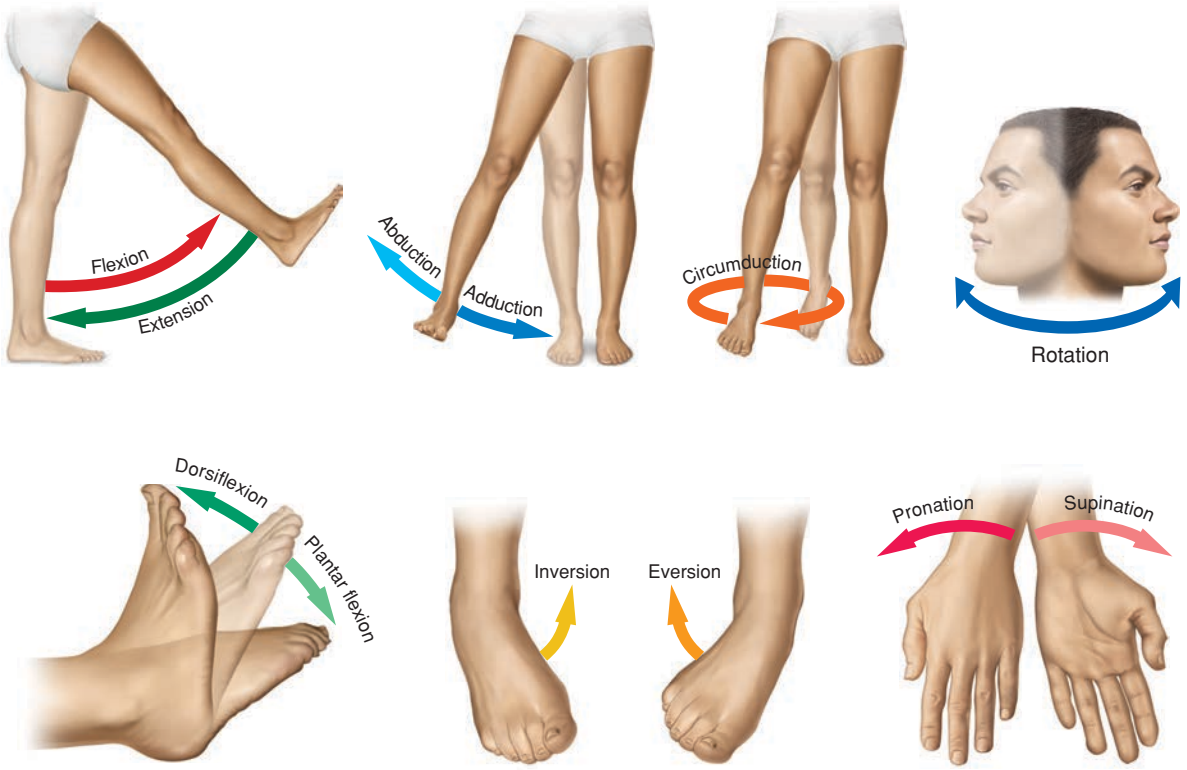

FIGURE 6-5 Types of movement. Muscle contraction produces movement at the joints. All movements are shown in reference to the anatomic position. Some muscles are named for the type of movement they produce, such as flexor, extensor, and adductor.

HEALTH PROFESSIONS

BOX 6-3

Careers in Exercise and Fitness

Several related careers are concerned with the management of exercise programs for therapy, health maintenance, and recreation. The American College of Sports Medicine (ACSM) at acsm.org has information on these fields and some certification programs.

- Exercise physiologists study the mechanisms involved in physical exercise and the body's physiologic responses to exercise. They design programs for general health, athletics, and rehabilitation for disability or disease, such as cardiovascular and respiratory diseases. They may work in clinical settings in cooperation with physicians, in private industry, in health clubs, or in teaching. Most exercise physiologists (EPs) have master's degrees, but some jobs may require only a bachelor's degree. A PhD is needed for teaching or research. EPs may be certified through ACSM or the Center for Exercise Physiology (CEP). The American Society of Exercise Physiologists at asep.org has information about this profession.
- Athletic trainers specialize in the prevention and treatment of musculoskeletal injuries. They advise clients on the proper use of exercise equipment and devices, such as braces, that help prevent injuries. They work in cooperation with physicians in private establishments, in health care facilities, and with athletes and sports teams. An athletic trainer's job may have a set schedule, but if the job is for a sports team, it may require long and irregular hours. A majority of athletic trainers have master's degrees or higher. Employment opportunities in health care and teaching are expected to be good, although jobs with sports teams are limited. The National Athletic Trainers' Association at nata.org has more information on this career.
- Fitness workers make up a category that includes a variety of career activities, such as personal trainers and group fitness, yoga, and Pilates instructors. These professionals lead, instruct, and motivate individuals or groups in all types of exercise activities. Traditionally, they have worked in studios, health clubs, or private homes, but they are increasingly found in the workplace, where they organize and direct fitness programs for employees. Their jobs may involve administrative duties as well. Personal trainers must be certified, and certification is encouraged for other fitness professionals. Candidates must have a high school diploma and certification in CPR, and must pass a written exam and sometimes a practical exam as well. Increasingly, a bachelor's degree is required, and those who wish to progress to management jobs may need a higher degree. Instructors who specialize in a particular exercise method, such as Pilates or yoga, must pass their own training standards. Job opportunities in these fields are expected to increase with an aging population and increasing concern for good health and physical fitness. The National Commission for Certifying Agencies at credentialingexcellence.org can help locate accredited fitness certification programs.

extern.ir

NAMING OF MUSCLES

A muscle can be named by its location (e.g., near a bone), by the direction of its fibers, or by its size, shape, or number of attachment points (heads), as indicated by the suffix *-ceps* (see **FIG. 6-4**). It may also be named for its action, adding the suffix *-or* to the root for the action. For example, a muscle that produces flexion at a joint is a flexor. Examine the muscle diagrams in **FIGURES 6-6** and **6-7**. See how many of these criteria you can find in the muscle names. Note that sometimes more than one criterion is used in the name.

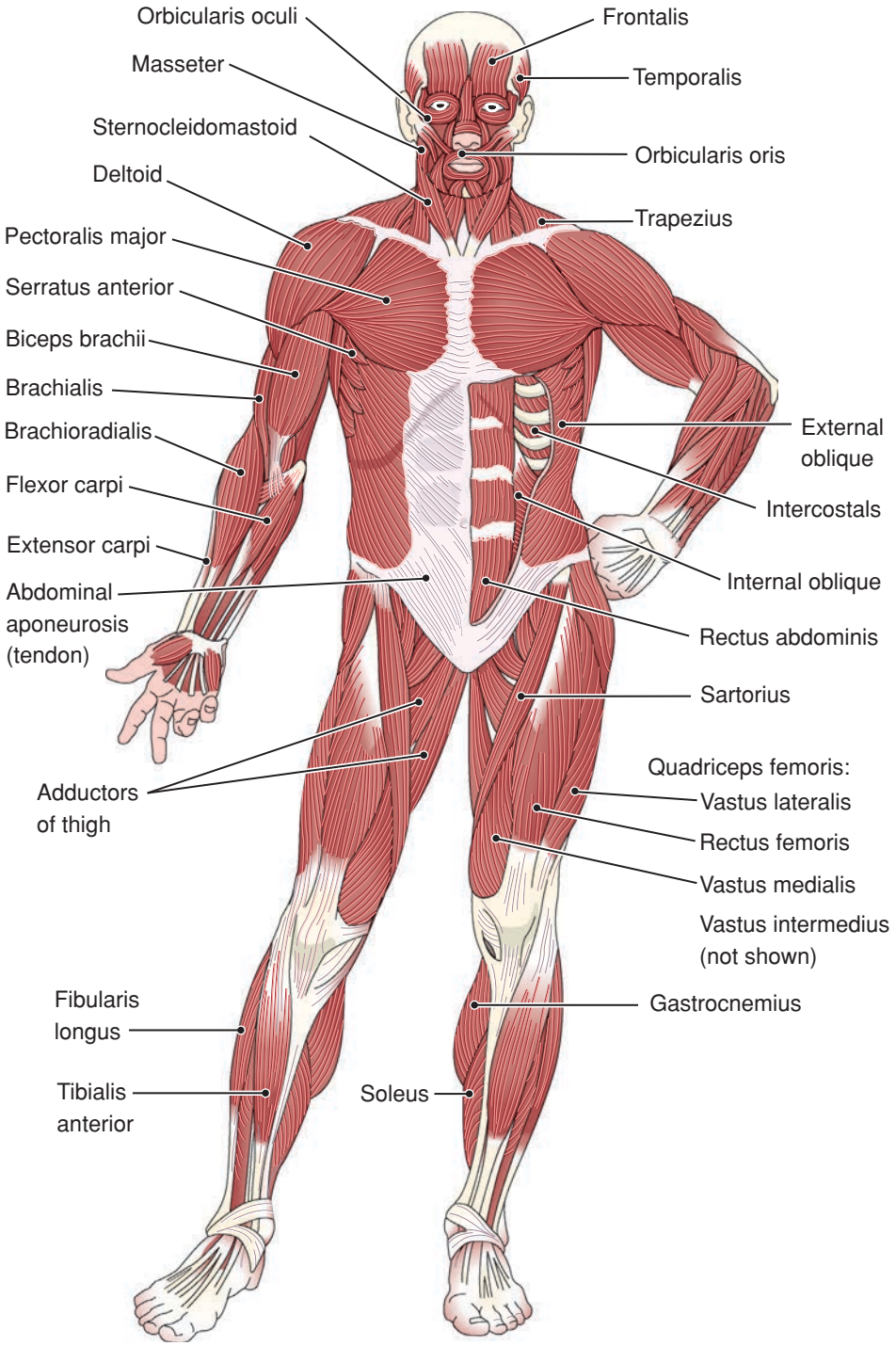

FIGURE 6-6 Superficial muscles, anterior view.

extern.ir

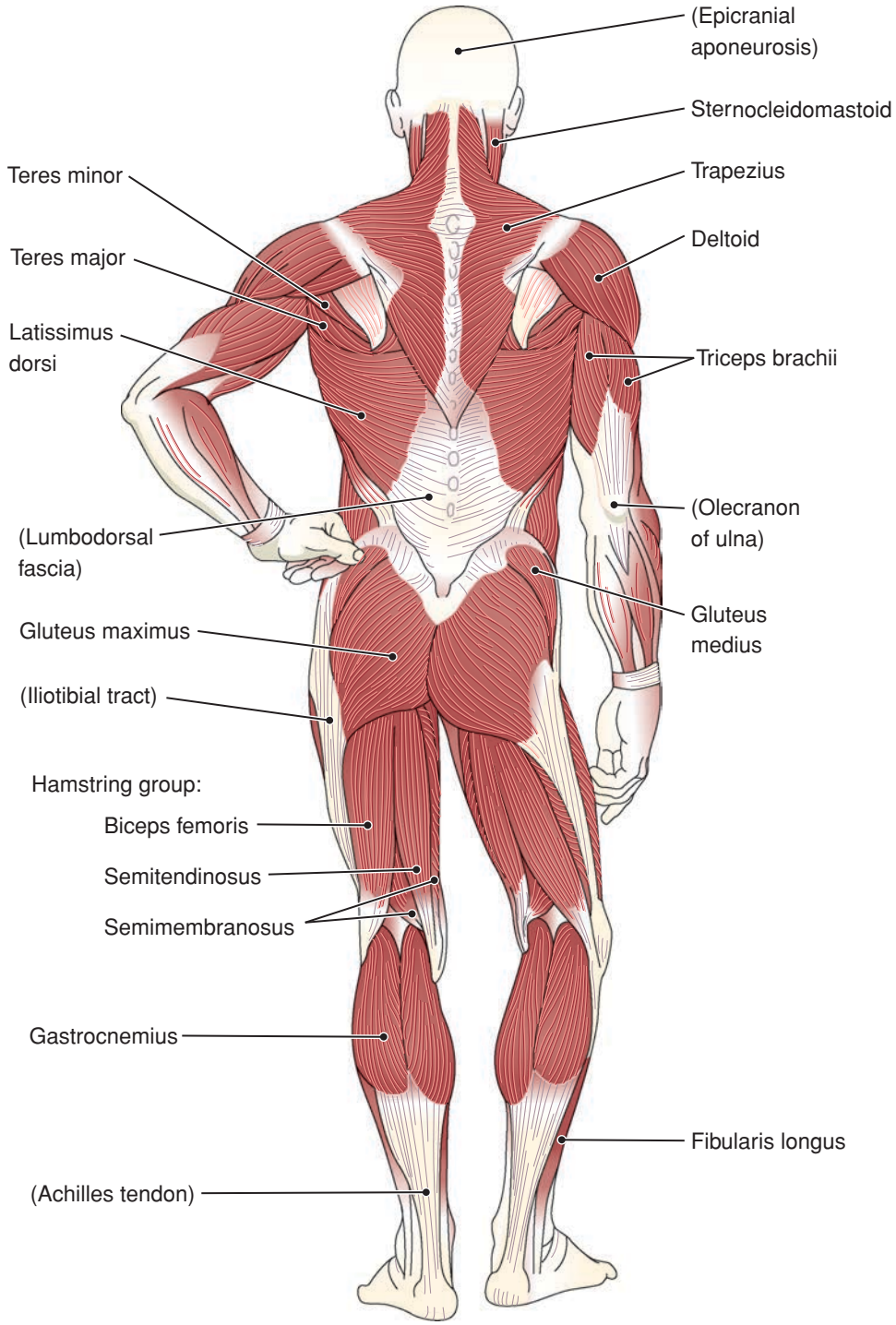

FIGURE 6-7 Superficial muscles, posterior view. Associated structures are labeled in parentheses.

extern.ir

Terminology *Key Terms*

The terms listed below are emphasized in this chapter. Knowing them will help you organize and prioritize your learning. These boldface terms are also found, collectively, with all chapter key terms in the Glossary.

Normal Structure and Function

acetylcholine (ACh) *as-eh-til-KO-lene*	A neurotransmitter that stimulates contraction of skeletal muscles
actin *AK-tin*	One of the two contractile proteins in muscle cells; the other is myosin
agonist *AG-on-ist*	A muscle that carries out a given movement (from Greek *agon* meaning "contest," "struggle")
antagonist *an-TAG-o-nist*	The muscle that opposes an agonist; it must relax when the agonist contracts
cardiac muscle *KAR-de-ak*	Involuntary muscle that makes up the heart wall
fascia *FASH-e-ah*	The fibrous sheath of connective tissue that covers a muscle; called deep fascia to differentiate it from the superficial fascia that underlies the skin (root: fasci/o) (plural: fasciae)
fascicle *FAS-ih-kl*	A small bundle, as of muscle or nerve fibers
insertion *in-SER-shun*	In a given movement, the point where a muscle is attached to a moving part of the skeleton
muscle *MUS-el*	An organ that produces movement by contracting; also the tissue that composes such organs (roots: my/o, muscul/o)
myosin *MI-o-sin*	One of the two contractile proteins in muscle cells; the other is actin
neuromuscular junction (NMJ) *nu-ro-MUS-ku-lar JUNK-shun*	The point of contact, or synapse, between a branch of a motor neuron and a muscle cell
origin *OR-ih-jin*	In a given movement, the point where a muscle is attached to a stable part of the skeleton
prime mover	The main muscle involved in a given movement
skeletal muscle *SKEL-eh-tal*	Voluntary muscle that moves the skeleton and maintains posture
smooth muscle	Involuntary muscle that makes up the wall of hollow organs, vessels, and ducts; visceral muscle
synergist *SIN-er-jist*	A muscle that assists a prime mover to produce a given movement
tendon *TEN-dun*	A fibrous band of connective tissue that attaches a muscle to a bone (roots: ten/o, tendin/o)
tonus *TO-nus*	A state of steady, partial muscle contraction that maintains firmness; muscle tone (root: ton/o)

extern.ir

Roots Pertaining to Muscles

See **TABLE 6-1**.

Table 6-1 Roots Pertaining to Muscles

Root	Meaning	Example	Definition of Example
my/o	muscle	myositis[a] *mi-o-SI-tis*	inflammation of muscle
muscul/o	muscle	musculature *MUS-kyu-lah-chur*	muscle arrangement in a part or the whole body
in/o	fiber	inotropic *in-o-TROP-ik*	acting on (muscle) fibers
fasci/o	fascia	fasciodesis *fash-e-OD-eh-sis*	binding (suture) of a fascia to a tendon or other fascia
ten/o, tendin/o	tendon	tenostosis *ten-os-TO-sis*	ossification of a tendon
ton/o	tone	cardiotonic *kar-de-o-TON-ik*	having a strengthening action on the heart muscle
erg/o	work	ergonomics *er-go-NOM-iks*	study of the efficient use of energy during work
kin/o-, kine, kinesi/o, kinet/o	movement	kinesis *ki-NE-sis*	movement (adjective: kinetic)

[a]Note addition of *s* to this root before the suffix *-itis*.

Exercise 6-1

Complete the exercise. To check your answers go to Appendix 11.

Define the following adjectives.

1. muscular _____
2. fascial _____
3. kinetic _____
4. tendinous _____
5. tonic _____

Write words for the following definitions.

6. incision into a muscle _____
7. inflammation of a muscle with its tendon _____
8. study of movement _____
9. excision of fascia _____
10. pain in a tendon _____

Fill in the blanks.

11. Myoglobin (*mi-o-GLO-bin*) is a type of protein (globin) found in _____ .
12. Inosclerosis (*in-o-skle-RO-sis*) is hardening of tissue from an increase in _____ .
13. Fasciitis (*fash-e-I-tis*) is inflammation of _____ .
14. Dystonia (*dis-TO-ne-ah*) is abnormal muscle _____ .

(continued)

extern.ir

Exercise 6-1 *(Continued)*

15. An ergograph (*ER-go-graf*) is an instrument for recording muscle _____ .
16. Kinesia (*ki-NE-se-ah*) is a term for sickness caused by _____ .
17. Myofibrils (*mi-o-FI-brils*) are small fibers found in _____ .
18. The muscularis layer in the wall of a hollow organ or duct is composed of _____ .

Define the following terms.

19. hypermyotonia (*hi-per-mi-o-TO-ne-ah*) _____
20. fasciorrhaphy (*fash-e-OR-ah-fe*) _____
21. tendinitis (*ten-dih-NI-tis*), also tendonitis (*ten-don-I-tis*) _____
22. musculotendinous (*mus-ku-lo-TEN-dih-nus*) _____
23. tenodesis (*ten-OD-eh-sis*) _____
24. myalgia (*mi-AL-je-ah*) _____
25. kinesitherapy (*ki-ne-sih-THER-ah-pe*) _____
26. dyskinesia (*dis-ki-NE-se-ah*) _____
27. atony (*AT-o-ne*) _____
28. ergogenic (*er-go-JEN-ik*) _____
29. myofascial (*mi-o-FASH-e-al*) _____
30. myotenositis (*mi-o-ten-o-SI-tis*) _____

Clinical Aspects of the Muscular System

Muscle function may be affected by disorders elsewhere, particularly in the nervous system and connective tissue. The conditions described below affect the muscular system directly or involve the muscles but have not been described in other chapters. Any disorder of muscles is described as a myopathy.

Techniques for diagnosing muscle disorders include electrical studies of muscle in action, **electromyography** (**EMG**), and serum assay of enzymes released in increased amounts from damaged muscles, mainly **creatine kinase** (**CK**).

MUSCULAR DYSTROPHY

Muscular dystrophy refers to a group of hereditary diseases involving progressive, noninflammatory muscular degeneration. There is weakness and wasting of muscle tissue with its gradual replacement by connective tissue and fat. There may also be cardiomyopathy (cardiac muscle disease) and mental impairment.

Duchenne muscular dystrophy, is an inherited form of the disease found most frequently in male children. It results from a defect in a protein that stabilizes the links between myofibrils within the muscle cell and the cell membrane. When this protein (dystrophin) is abnormal, every muscle contraction damages the cells, eventually leading to the replacement of muscle tissue with scar tissue. The result is progressive weakness, and eventual paralysis. Even heart muscle is affected, so that death usually comes from weakness of the cardiac muscle (heart failure) or paralysis of the respiratory muscles.

Life expectancy is about 25 years for the most common type of muscular dystrophy and about 40 years for the other types. Progress toward definitive treatment for inherited forms of the disease may be possible now that scientists have identified the genetic defects that cause them.

MULTIPLE-SYSTEM DISORDERS INVOLVING MUSCLES

Polymyositis

Polymyositis is inflammation of skeletal muscle leading to weakness, frequently associated with dysphagia (difficulty in swallowing) or cardiac problems. The cause is unknown and may be related to viral infection or autoimmunity. Often the disorder is associated with some other

extern.ir

systemic disease such as rheumatoid arthritis or lupus erythematosus.

When the skin is involved, the condition is termed **dermatomyositis.** In this case, there is erythema (redness of the skin), dermatitis (inflammation of the skin), and a typical lilac-colored rash, predominantly on the face. In addition to enzyme studies and EMG, clinicians use muscle biopsy in diagnosis.

Fibromyalgia Syndrome

Fibromyalgia syndrome (FMS) is a difficult-to-diagnose condition involving the muscles. It is associated with widespread muscle aches, tenderness, and stiffness, along with fatigue and sleep disorders in the absence of neurologic abnormalities or any other known cause. The disorder may coexist with other chronic diseases, may follow a viral infection, and may involve immune system dysfunction. A current theory is that FMS results from hormonal or neurotransmitter imbalances that increase sensitivity to pain. Treatments for FMS include a carefully planned exercise program and medication with pain relievers, muscle relaxants, or antidepressants.

Chronic Fatigue Syndrome

Chronic fatigue syndrome (CFS) involves persistent fatigue of no known cause that may be associated with impaired memory, sore throat, painful lymph nodes, muscle and joint pain, headaches, sleep problems, and immune disorders. The condition often occurs after a viral infection. Epstein–Barr virus (the cause of mononucleosis), herpesvirus, and other viruses have been suggested as possible causes of CFS. No traditional or alternative therapies have been consistently successful in treating CFS.

Myasthenia Gravis

Myasthenia gravis (MG) is an acquired autoimmune disease caused by the loss of acetylcholine receptors in the muscle cell membrane when a person's immune system mistakenly recognizes these receptors as foreign and attacks them with antibodies. Without these receptors, the neurons cannot trigger muscle contraction. There is a progressive loss of muscle power characterized by chronic muscular fatigue brought on by the slightest exertion. It affects adults and begins with the muscles of the head. Drooping of the eyelids (ptosis) is a common early sign.

Amyotrophic Lateral Sclerosis

Also named *Lou Gehrig disease* after a famous baseball player who died of the disorder, **amyotrophic lateral sclerosis (ALS)** is a progressive degeneration of motor neurons that leads to muscle atrophy (amyotrophy). Early signs are weakness, cramping, and muscle twitching. The facial or respiratory muscles may be affected early depending on the site of degeneration. Mental function, sensory perception, and bowel and bladder function usually remain intact. The disease progresses and eventually leads to death from respiratory muscle paralysis in 3 to 5 years.

STRESS INJURIES

Not as grave as the above diseases perhaps, but much more common, are musculoskeletal disorders caused by physical stress. These include accidental injuries and work- or sports-related damage caused by overexertion or repetitive motion, so-called **repetitive strain injury (RSI).** Damages to soft tissues include **sprain**, injury to a ligament caused by abnormal or excessive force at a joint but without bone dislocation or fracture; muscle **strain**, inflammation or tearing of ligaments and tendons; and bursitis. **Tenosynovitis**, commonly called **tendinitis**, is inflammation of a tendon, tendon sheath, and the synovial membrane at a joint. The signs of these injuries are pain, fatigue, weakness, stiffness, numbness, and reduced range of motion (ROM). (The origins of some colorful terms for such conditions are given in **BOX 6-4**.)

Stress injuries may involve any muscles or joints, but some common upper extremity conditions are:

- Rotator cuff (RTC) injury—The RTC, which strengthens the shoulder joint, is formed by four muscles, the supraspinatus, infraspinatus, teres minor, and subscapularis, the "SITS" muscles **(FIG. 6-8)**. Inflammation or tearing of the RTC can occur in people who repeatedly perform overhead activities, such as swimming, painting, or pitching.
- Epicondylitis—The medial and lateral epicondyles (projections) of the distal humerus are attachment points for muscles that flex and extend the wrist and fingers. Inflammation of these tendons of origin causes pain at

FOCUS ON WORDS

BOX 6-4

Some Colorful Musculoskeletal Terms

Some common terms for musculoskeletal disorders have interesting origins. A charley horse describes muscular strain and soreness, especially in the legs. The term comes from common use of the name Charley for old lame horses that were kept around for family use when they could no longer be used for hard work. Wryneck, technically torticollis, uses the word *wry*, meaning twisted or turned, as in the word awry (*ah-RI*), meaning amiss or out of position.

A bunion, technically called hallux valgus, is an enlargement of the first joint of the great toe with bursitis at the joint. It probably comes from the word bony, changed to bunny, and used to mean a bump on the head and then a swelling on a joint. A clavus is commonly called a corn because it is a hardened or horny thickening of the skin in an area of friction or pressure.

extern.ir

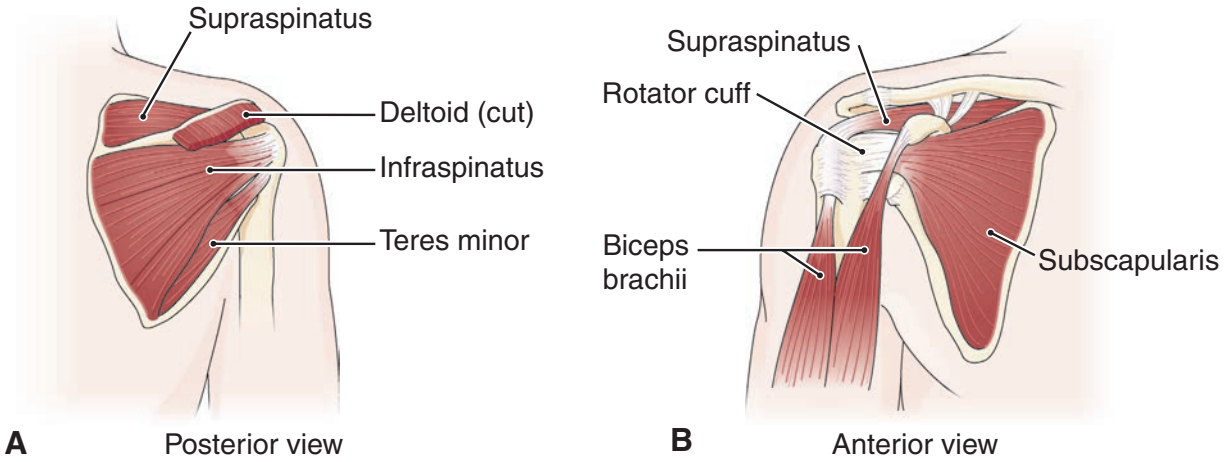

FIGURE 6-8 Anatomy of the rotator cuff. Four muscles contribute to the rotator cuff that strengthens the shoulder. They are the supraspinatus, infraspinatus, teres minor, and subscapularis. Two adjacent muscles are also shown, the deltoid and biceps brachii. **A.** Posterior. **B.** Anterior.

the elbow and forearm on lifting, carrying, squeezing, or typing. These stress injuries are often sports-related, leading to the terms "golfer's elbow" and "tennis elbow" for medial and lateral epicondylitis, respectively. A brace worn below the elbow to distribute stress on the joint may be helpful.

- Carpal tunnel syndrome (CTS)—CTS involves the tendons of the finger flexor muscles and the nerves that supply the hand and fingers **(FIG. 6-9)**. Hand numbness and weakness are caused by pressure on the median nerve as it passes through a channel formed by the carpal (wrist) bones. CTS commonly appears in people who use their

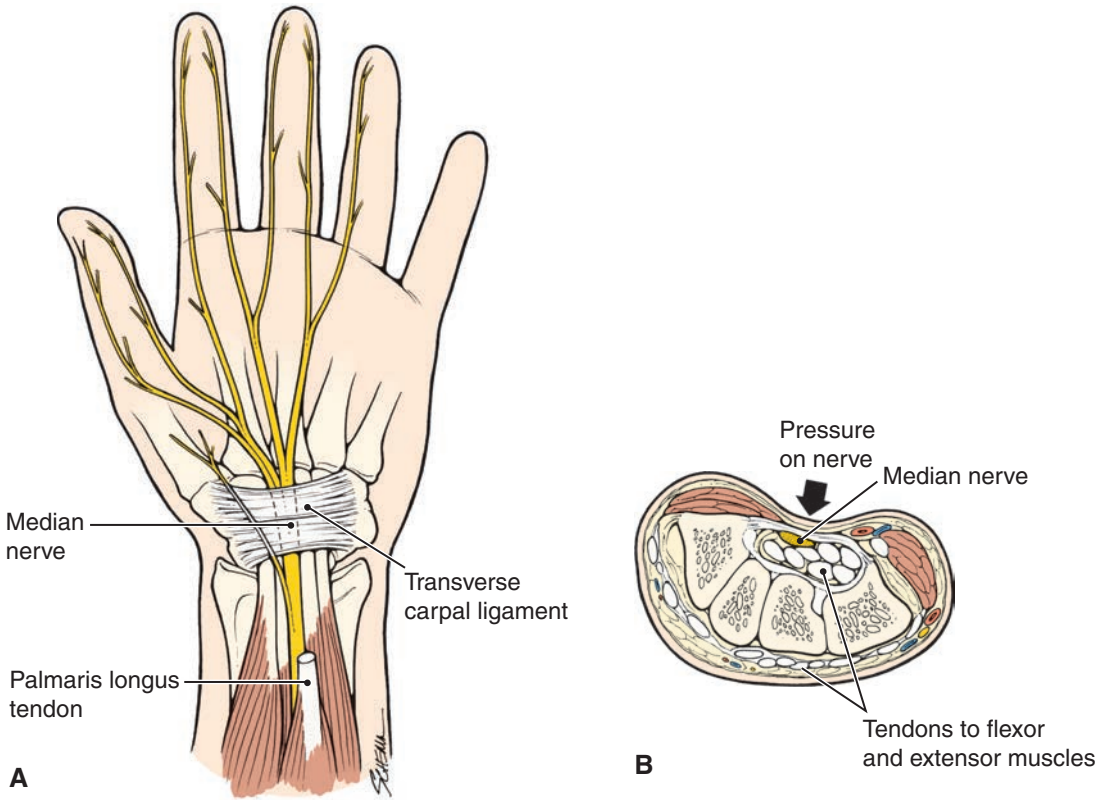

FIGURE 6-9 Carpal tunnel syndrome. A. Pressure on the median nerve as it passes through the carpal (wrist) bones causes numbness and weakness in the areas of the hand supplied by the nerve. **B.** Cross-section of the wrist showing compression of the median nerve.

extern.ir

hands and fingers strenuously, such as musicians and keyboarders.

- Trigger finger—This is a painful snapping, triggering, or locking of a finger as it is moved. It is caused by inflammation and swelling of the flexor tendon sheath at the metacarpophalangeal joint that prevents the tendon from sliding back and forth.

Some stress injuries that involve the lower extremities are:

- Hamstring strain—The hamstring is a large muscle group in the posterior thigh that extends from the hip to the knee and flexes the knee (see **FIG. 6-7**). A "pulled hamstring" is common in athletes who stop and start running suddenly. It is treated with stretching and strengthening activities.
- Shin-splint—This is pain in the leg's anterior tibial region from running on hard surfaces or overuse of the foot flexors, as in athletes and dancers. Help comes from good shoes with adequate support and avoidance of hard surfaces for exercise.
- Achilles tendinitis—The Achilles (*a-KIL-eze*) tendon is a large tendon that attaches the calf muscles to the heel and is used to plantar flex the foot at the ankle (see **FIGS. 6-5** and **6-7**). Damage to the Achilles tendon hampers or prevents walking and running.

Treatment

Orthopedists diagnose musculoskeletal disorders by MRI and other imaging techniques, ROM measurements, and strength testing. Treatment of stress injuries usually begins conservatively with rest, elevation, ice packs, bracing, and medications, such as analgesics, anti-inflammatory agents, and muscle relaxants. (The acronym RICE represents this simple approach—rest, ice, compression, elevation.) Treatment may progress to steroid injections, ultrasound therapy for deep heat, strengthening exercises, or even surgery.

Terminology *Key Terms*

The terms listed below are emphasized in this chapter. Knowing them will help you organize and prioritize your learning. These boldface terms are also found, collectively, with all chapter key terms in the Glossary.

Disorders

amyotrophic lateral sclerosis (ALS) *ah-mi-o-TROF-ik*	A disease caused by motor neuron degeneration resulting in muscular weakness and atrophy; Lou Gehrig disease
chronic fatigue syndrome (CFS) *KRON-ik fah-TEGE SIN-drome*	A disease of unknown cause that involves persistent fatigue along with muscle and joint pain and other symptoms; may be virally induced
dermatomyositis *der-mah-to-mi-o-SI-tis*	A disease of unknown origin involving muscular inflammation as well as dermatitis and skin rashes
fibromyalgia syndrome (FMS) *fi-bro-mi-AL-je-ah*	A disorder associated with widespread muscular aches and stiffness and having no known cause
muscular dystrophy *DIS-tro-fe*	A group of hereditary muscular disorders marked by progressive weakness and muscular atrophy
myasthenia gravis (MG) *mi-as-THE-ne-ah GRAH-vis*	A disease characterized by progressive muscular weakness; an autoimmune disease affecting the neuromuscular junction
polymyositis *pol-e-mi-o-SI-tis*	A disease of unknown cause involving muscular inflammation and weakness
repetitive strain injury (RSI)	Tissue damage caused by repeated motion, usually overuse of the arm or hand in occupational activities such as writing, typing, painting, or using hand tools; also called repetitive motion injury, cumulative trauma injury, overuse syndrome
sprain *sprane*	Injury to a ligament caused by abnormal or excessive force at a joint, but without bone dislocation or fracture
strain *strane*	Trauma to a muscle because of overuse or excessive stretch; if severe, may involve muscular tearing, bleeding, separation of a muscle from its tendon, or tendon separation from a bone
tendinitis *ten-dih-NI-tis*	Inflammation of a tendon, usually caused by injury or overuse; the shoulder, elbow, and hip are common sites; also spelled tendonitis

(continued)

extern.ir

Terminology Key Terms (Continued)

tenosynovitis *ten-o-sin-o-VI-tis*	Inflammation of a tendon and its sheath
Diagnosis	
creatine kinase (CK) *KRE-ah-tin KI-nase*	An enzyme found in muscle tissue; the serum CK level increases in cases of muscle damage; creatine phosphokinase (CPK)
electromyography (EMG) *e-lek-tro-mi-OG-rah-fe*	Study of the electrical activity of muscles during contraction

Terminology Enrichment Terms

The terms listed below expand on the key terms to increase your knowledge of this chapter topic.

Normal Structure and Function	
aponeurosis *ap-o-nu-RO-sis*	A flat, white, sheet-like tendon that connects a muscle with the part that it moves (see abdominal aponeurosis, **FIG. 6-6**)
creatine *KRE-ah-tin*	A substance in muscle cells that stores energy for contraction
glycogen *GLI-ko-jen*	A complex sugar that is stored for energy in muscles and in the liver
isometric *i-so-MET-rik*	Pertaining to a muscle action in which the muscle tenses but does not shorten (literally: same measurement)
isotonic *i-so-TON-ik*	Pertaining to a muscle action in which the muscle shortens to accomplish movement (literally: same tone)
kinesthesia *kin-es-THE-ze-ah*	Awareness of movement; perception of the weight, direction, and degree of movement (-esthesia means "sensation")
lactate *LAK-tate*	An organic compound that accumulates in muscle cells functioning without enough oxygen (anaerobically), as in times of great physical exertion
motor unit	A single motor neuron and all of the muscle cells that its branches stimulate
myoglobin *mi-o-GLO-bin*	A protein similar to hemoglobin that stores oxygen in muscle cells
Symptoms and Conditions	
asterixis *as-ter-IK-sis*	Rapid, jerky movements, especially in the hands, caused by intermittent loss of muscle tone
asthenia *as-THE-ne-ah*	Weakness (prefix a- meaning "without" with root sthen/o meaning "strength")
ataxia *ah-TAK-se-ah*	Lack of muscle coordination (from root *tax/o* meaning "order, arrangement") (adjective: ataxic)
athetosis *ath-eh-TO-sis*	A condition marked by slow, irregular, twisting movements, especially in the hands and fingers (adjective: athetotic)

extern.ir

Terminology — *Enrichment Terms (Continued)*

atrophy *AT-ro-fe*	A wasting away; a decrease in the size of a tissue or organ, such as muscular wasting from disuse
avulsion *ah-VUL-shun*	Forcible tearing away of a part
clonus *KLO-nus*	Alternating spasmodic contraction and relaxation in a muscle (adjective: clonic)
contracture *kon-TRAK-chur*	Permanent contraction of a muscle
fasciculation *fah-sik-u-LA-shun*	Involuntary small contractions or twitching of muscle fiber groups (fasciculi)
fibromyositis *fi-bro-mi-o-SI-tis*	A nonspecific term for pain, tenderness, and stiffness in muscles and joints
fibrositis *fi-bro-SI-tis*	Inflammation of fibrous connective tissue, especially the muscle fasciae; marked by pain and stiffness
restless legs syndrome (RLS)	Uneasiness, twitching, or restlessness in the legs that occurs after going to bed and often leading to insomnia; may be caused by poor circulation or drug side effects
rhabdomyolysis *rab-do-mi-OL-ih-sis*	An acute disease involving diffuse destruction of skeletal muscle cells (root *rhabd/o* means "rod," referring to the long, rod-like muscle cells)
rhabdomyoma *rab-do-mi-O-mah*	A benign tumor of skeletal muscle
rhabdomyosarcoma *rab-do-mi-o-sar-KO-mah*	A highly malignant tumor of skeletal muscle
rheumatism *RU-mah-tizm*	A general term for inflammation, soreness, and stiffness of muscles associated with joint pain (adjectives: rheumatic, rheumatoid)
spasm *spazm*	A sudden, involuntary muscle contraction; may be clonic (contraction alternating with relaxation) or tonic (sustained); a strong and painful spasm may be called a cramp (adjectives: spastic, spasmodic)
spasticity *spas-TIS-ih-te*	Increased tone or contractions of muscles causing stiff and awkward movements
tetanus *TET-ah-nus*	An acute infectious disease caused by the anaerobic bacillus *Clostridium tetani*; marked by persistent painful spasms of voluntary muscles; lockjaw
tetany *TET-ah-ne*	A condition marked by spasms, cramps, and muscle twitching caused by a metabolic imbalance, such as low blood calcium resulting from underactivity of the parathyroid glands
torticollis *tor-tih-KOL-is*	Spasmodic contraction of the neck muscles causing stiffness and twisting of the neck; wryneck
Diagnosis and Treatment	
Chvostek sign *VOS-tek*	Spasm of facial muscles after a tap over the facial nerve; evidence of tetany
dynamometer *di-nah-MOM-eh-ter*	Instrument for measuring degree of muscle power; from root dynam/o meaning "force, energy"; also called ergometer
occupational therapy (OT)	Health profession concerned with increasing function and preventing disability through work and play activities; the goal of occupational therapy is to increase the patient's independence and quality of daily life (see **BOX 7-2**)

(continued)

extern.ir

Terminology Enrichment Terms (Continued)

physical therapy (PT)	Health profession concerned with physical rehabilitation and prevention of disability; exercise, massage, and other therapeutic methods are used to restore proper movement (see **BOX 5-2**)
rheumatology *ru-mah-TOL-o-je*	The study and treatment of rheumatic diseases
Trousseau sign *tru-SO*	Spasmodic contractions caused by pressing the nerve supplying a muscle; seen in tetany
Drugs	
anti-inflammatory agent	Drug that reduces inflammation; includes steroids, such as cortisol, and nonsteroidal anti-inflammatory drugs
COX-2 inhibitor	Nonsteroidal anti-inflammatory drug that does not cause the stomach problems associated with other NSAIDs; inhibits the cyclooxygenase (COX)-2 enzyme without affecting the COX-1 enzyme, a lack of which can cause stomach ulcers; example is celecoxib (Celebrex); some of these drugs have been withdrawn from the market because of cardiac risk
muscle relaxant *re-LAX-ant*	A drug that reduces muscle tension; different forms may be used to relax muscles during surgery, to control spasticity, or to relieve musculoskeletal pain
nonsteroidal anti-inflammatory drug (NSAID)	Drug that reduces inflammation but is not a steroid; examples include aspirin, ibuprofen, naproxen, and other inhibitors of prostaglandins, naturally produced substances that promote inflammation

Terminology Abbreviations

The abbreviations listed below are emphasized in this chapter. These are also found, collectively, with all chapter abbreviations in Appendix 2.

ACh	Acetylcholine
ALS	Amyotrophic lateral sclerosis
CFS	Chronic fatigue syndrome
C(P)K	Creatine (phospho) kinase
CTS	Carpal tunnel syndrome
EMG	Electromyography, electromyogram
FMS	Fibromyalgia syndrome
LLE	Left lower extremity
LUE	Left upper extremity
MG	Myasthenia gravis
MMT	Manual muscle test(ing)
NMJ	Neuromuscular junction
OT	Occupational therapy/therapist
PACU	Postanesthesia care unit
PT	Physical therapy/therapist
RICE	Rest, ice, compression, elevation
RLE	Right lower extremity
RLS	Restless legs syndrome
ROM	Range of motion
RSI	Repetitive strain injury
RTC	Rotator cuff
RUE	Right upper extremity
SITS	Supraspinatus, infraspinatus, teres minor, subscapularis (muscles)

extern.ir

Case Study Revisited

Thomas's Follow-Up

The exploratory surgery confirmed the brachial plexus injury with a gap between several torn nerve ends where it was not possible to have a tension-free repair and nerve grafting was required. Thomas underwent a bilateral sural (calf) nerve graft. The sural nerve is an easily harvested nerve graft that allows the surgeon to implant healthy nerves to replace the damaged nerves in the brachial plexus. Following the four-hour procedure, Thomas was admitted to the pediatric ICU. After 6 days, he was discharged home with his right arm in a shoulder immobilizer. The incisions from the nerve graft donor sites on his right and left calf were healing nicely. He was given antibiotic ointment to apply for the next week to prevent infection. He was also told to elevate his legs, for several days, when he was sitting or in bed.

Thomas received instructions on activities that he could or could not perform and was told to see the orthopedic surgeon in 1 week and again 3 weeks later. Physical therapy was ordered to prevent further atrophy and to begin rebuilding the arm muscles. At his 1-week follow-up, Thomas stated his frustration with the slow progress. The orthopedic surgeon had said that in time, he should regain full use of his right arm and normal activities of daily living should be restored.

extern.ir

CHAPTER 6

Review

This review tests your understanding of the content introduced in this chapter. Follow the instructions for each exercise and check your answers in Appendix 11.

LABELING EXERCISE

SUPERFICIAL MUSCLES, ANTERIOR VIEW

Write the name of each numbered part on the corresponding line.

Adductors of thigh	Frontalis	Rectus abdominis
Biceps brachii	Gastrocnemius	Sartorius
Brachialis	Intercostals	Serratus anterior
Brachioradialis	Internal oblique	Soleus
Deltoid	Masseter	Sternocleidomastoid
Extensor carpi	Orbicularis oculi	Temporalis
External oblique	Orbicularis oris	Tibialis anterior
Fibularis longus	Pectoralis major	Trapezius
Flexor carpi	Quadriceps femoris	

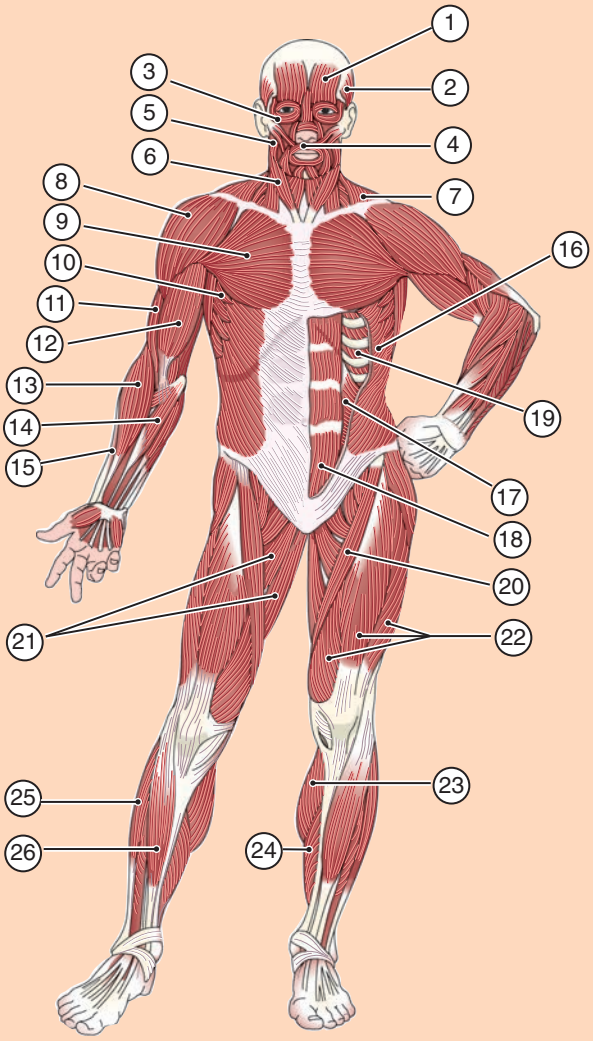

Anterior view

1. _____
2. _____
3. _____
4. _____
5. _____
6. _____
7. _____
8. _____
9. _____
10. _____
11. _____
12. _____
13. _____
14. _____
15. _____
16. _____
17. _____
18. _____
19. _____
20. _____
21. _____
22. _____
23. _____
24. _____
25. _____
26. _____

extern.ir

SUPERFICIAL MUSCLES, POSTERIOR VIEW

Write the name of each numbered part on the corresponding line.

Deltoid
Fibularis longus
Gastrocnemius
Gluteus maximus
Gluteus medius
Hamstring group
Latissimus dorsi
Sternocleidomastoid
Teres major
Teres minor
Trapezius
Triceps brachii

1. _____
2. _____
3. _____
4. _____
5. _____
6. _____
7. _____
8. _____
9. _____
10. _____
11. _____
12. _____

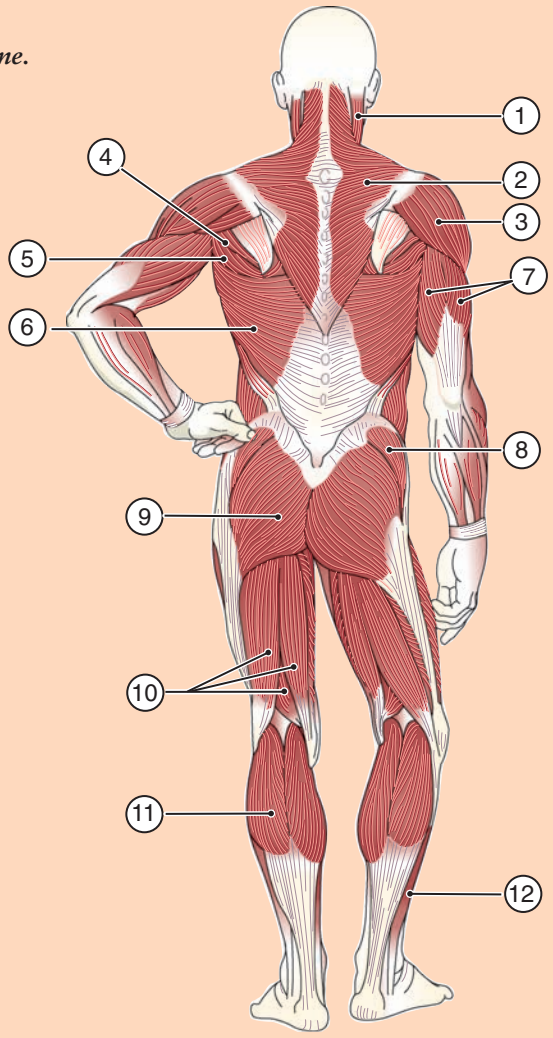

Posterior view

TERMINOLOGY

MATCHING

Match the following terms, and write the appropriate letter to the left of each number.

____	1. masseter	a. muscle used in chewing; jaw muscle
____	2. quadriceps femoris	b. large muscle of the upper chest
____	3. pectoralis major	c. a group of four muscles in the thigh
____	4. gastrocnemius	d. main muscle of the calf
____	5. trapezius	e. muscle of the upper back and neck

____	6. akinesia	a. instrument for measuring muscle work
____	7. fascicle	b. absence of movement
____	8. inotropic	c. a small bundle of fibers
____	9. dystonia	d. acting on muscle fibers
____	10. ergometer	e. abnormal muscle tone

extern.ir

Enrichment Terms

____ 11. lactate	a. protein that stores oxygen in muscle cells
____ 12. aponeurosis	b. flat, white, sheet-like tendon
____ 13. tetany	c. muscular spasms and cramps
____ 14. myoglobin	d. complex sugar stored in muscles
____ 15. glycogen	e. byproduct of anaerobic muscle contractions

____ 16. asterixis	a. awareness of movement
____ 17. ataxia	b. weakness
____ 18. torticollis	c. rapid, jerky movements, especially of the hands
____ 19. asthenia	d. wryneck
____ 20. kinesthesia	e. lack of muscle coordination

____ 21. athetosis	a. forcible tearing away of a part
____ 22. clonus	b. acute infectious disease that affects muscles
____ 23. spasm	c. intermittent muscle contractions
____ 24. avulsion	d. sudden involuntary muscle contraction
____ 25. tetanus	e. condition marked by slow, twisting movements

Refer to Thomas's case study.

____ 26. deltoid	a. partial dislocation
____ 27. atrophy	b. shoulder muscle
____ 28. subluxation	c. network
____ 29. plexus	d. pertaining to the diaphragm
____ 30. phrenic	e. tissue wasting

FILL IN THE BLANKS

Complete the sentence with the correct term(s).

31. A band of connective tissue that attaches a muscle to a bone is a(n) _____ .
32. A musculotropic substance acts on _____ .
33. The number of origins (heads) in the triceps brachii muscle is _____ .
34. A muscle that produces extension at a joint is called a(n) _____ .
35. The neurotransmitter released at the neuromuscular junction is _____ .
36. The strong, cord-like tendon that attaches the calf muscle to the heel is the _____ .
37. Movement toward the midline of the body is termed _____ .
38. The sheath of connective tissue that covers a muscle is called _____ .

Refer to Thomas's case study.

39. The nerves of the brachial plexus supply the _____ .
40. The muscle above the spine of the scapula is the _____ .
41. The vertebra C7 is in the region of the _____ .

DEFINITIONS

Define the following words.

42. myofascial (*mi-o-FASH-e-al*) _____
43. tendinoplasty (*TEN-din-o-plas-te*) _____
44. hypotonia (*hi-po-TO-ne-ah*) _____

extern.ir

45. hyperkinesia (*hi-per-ki-NE-se-ah*) _____

46. inotropic (*in-o-TROP-ik*) _____

47. myositis (*mi-o-SI-tis*) _____

Write words for the following definitions.

48. suture of fascia _____

49. death of muscle tissue _____

50. study of movement _____

51. absence of muscle tone _____

52. surgical incision of a tendon (use ten/o-) _____

53. study of muscles _____

54. excision of fascia _____

55. pertaining to a tendon _____

OPPOSITES

Write a word that means the opposite of the following terms as they pertain to muscles.

56. agonist _____

57. origin _____

58. abduction _____

59. pronation _____

60. extension _____

ADJECTIVES

From the enrichment terms, write the adjective form of the following words.

61. ataxia _____

62. athetosis _____

63. spasm _____

64. clonus _____

TRUE–FALSE

Examine the following statements. If the statement is true, write T in the first blank. If the statement is false, write F in the first blank, and correct the statement by replacing the underlined word in the second blank.

	True or False	Correct Answer
65. The part of a neuron that contacts a muscle cell is the <u>dendrite</u>.	_____	_____
66. Skeletal muscle is <u>involuntary</u>.	_____	_____
67. The quadriceps muscle has <u>three</u> components.	_____	_____
68. <u>Pronation</u> means turning downward.	_____	_____
69. The hamstring group is in the <u>anterior</u> thigh.	_____	_____
70. Smooth muscle is also called <u>visceral</u> muscle.	_____	_____
71. The <u>origin</u> of a muscle is attached to a moving part.	_____	_____
72. In an <u>isotonic</u> contraction, a muscle shortens.	_____	_____

extern.ir

ELIMINATIONS

In each of the sets below, underline the word that does not fit in with the rest, and explain the reason for your choice.

73. fascicle — fiber — tendon — osteoblast — fascia

_____

74. soleus — flexor carpi — biceps brachii — brachioradialis — extensor carpi

_____

75. vastus intermedius — intercostals — vastus lateralis — vastus medialis — rectus femoris

_____

76. circumduction — inversion — actin — dorsiflexion — rotation

_____

77. EMG — ALS — FMS — CFS — MG

_____

ABBREVIATIONS

Write the meaning of each of the following.

78. RICE _____
79. RTC _____
80. CTS _____
81. NMJ _____
82. EMG _____

WORD BUILDING

Write a word for the following definitions using the word parts provided. Each word part can be used more than once.

-ia	ten/o	-al	alg/o	-itis	-desis	-blast	-lysis	fasci/o	my/o

83. inflammation of fascia _____
84. binding of a tendon _____
85. pain in a tendon _____
86. destruction of muscle tissue _____
87. binding of a fascia _____
88. an immature muscle cell _____
89. separation of a tendon _____
90. pertaining to fascia _____
91. pain in a muscle _____

extern.ir

WORD ANALYSIS

Define each of the following words, and give the meaning of the word parts in each. Use a dictionary if necessary.

92. fibromyositis (*fi-bro-mi-o-SI-tis*)
    a. fibr/o _____
    b. my/o(s) _____
    c. -itis _____
93. myasthenia (*mi-as-THE-ne-ah*)
    a. my/o _____
    b. a- _____
    c. sthen/o _____
    d. -ia _____
94. dyssynergia (*dis-in-ER-je-ah*)
    a. dys- _____
    b. syn- _____
    c. erg/o _____
    d. -ia _____
95. amyotrophic (*ah-mi-o-TRO-fik*)
    a. a- _____
    b. my/o _____
    c. troph/o _____
    d. -ic _____

extern.ir

Additional Case Studies

Case Study 6-1: Rotator Cuff Tear

Michael, a 56 y/o business executive and former college football player, was referred to an orthopedic surgeon for recurrent shoulder pain. Michael was unable to abduct his right arm without pain even after 6 months of physical therapy and NSAIDs. In addition, he had taken supplements of glucosamine, chondroitin, and *S*-adenosylmethionine for several months in an effort to protect the flexibility of his shoulder joint. Michael recalled a shoulder dislocation resulting from a football injury 35 years earlier. An MRI scan confirmed a complete rotator cuff tear. The surgeon recommended the Bankart procedure for Michael's injury to restore his joint stability, alleviate his pain, and permit him to return to his former normal activities, including golf.

After anesthesia induction and positioning in a semisitting (beach chair) position, the surgeon made an anterosuperior deltoid incision (the standard deltopectoral approach) and divided the coracoacromial ligament at the acromial attachment. The rotator cuff was identified after the deltoid was retracted and the clavipectoral fascia was incised. The subscapularis tendon was incised proximal to its insertion. After capsular incision, inspection showed a large pouch inferiorly in the capsule, consistent with laxity (looseness). The capsule's torn edges were anchored to the rim of the glenoid fossa with heavy nonabsorbable sutures. A flap from the subscapularis tendon was transposed and sutured to the supraspinatus and infraspinatus muscles to bridge the gap. An intraoperative ROM examination showed that the external rotation could be performed past neutral and that the shoulder did not dislocate. The wound was closed, and a shoulder immobilizer sling was applied. Michael was referred to PT to begin therapy in 3 weeks and was assured he would be able to play golf in 6 months.

extern.ir



Case Study 6-1 Questions

Follow the instructions for each question and check your answers in Appendix 11.

Multiple Choice. *Select the best answer, and write the letter of your choice to the left of each number.*

_____ 1. The insertion of the muscle is
- a. the thick middle portion
- b. the point of attachment to a moving bone
- c. the point of attachment to a stable bone
- d. the fibrous sheath

_____ 2. Michael was unable to abduct his affected arm. This motion is
- a. toward the midline
- b. circumferential
- c. away from the midline
- d. a position with the palm facing upward

_____ 3. An anterosuperior deltoid incision would be made
- a. perpendicular to the muscle fibers
- b. below the fascial sheath
- c. behind the glenoid fossa
- d. at the top and to the front of the deltoid muscle

_____ 4. The subscapularis tendon arises from the subscapularis
- a. fascia
- b. nerve
- c. bone
- d. flexor

_____ 5. The intraoperative ROM examination was performed
- a. in the OR corridor
- b. during surgery
- c. before surgery
- d. after surgery

_____ 6. Michael's arm and shoulder were placed in a sling after surgery to
- a. encourage movement beyond the point of pain
- b. minimize rapid ROM
- c. maintain adduction and external rotation
- d. prevent movement

Write terms from the case study with the following meanings.

7. pertaining to treatment of skeletal and muscular disorders _____

8. a term that means looseness _____

Define the following abbreviations.

9. PT _____

10. ROM _____

extern.ir

Case Study 6-2: "Wake-Up" Test During Spinal Fusion Surgery

Lynn's somatosensory evoked potentials (SSEPs) were monitored throughout her spinal fusion surgery to provide continuous information on the functional state of her sensory pathways from the median and posterior tibial nerves through the dorsal column to the primary somatosensory cortex. Before surgery, needle electrodes were inserted into Lynn's right and left quadriceps muscles to determine nerve conduction through L2 to L4, into the anterior tibialis muscles to measure passage through L5, and into the gastrocnemius muscles to measure S1 to S2. Electrodes were placed in her rectus abdominis to monitor S1 to S2. All electrodes were taped in place, and the wires were plugged into a transformer box with feedback to a computer. A neuromonitoring technologist placed the electrodes and attended the computer monitor throughout the case. During the procedure, selected muscle groups were stimulated with 15 to 40 milliamperes (mA) of current to test the nerves and muscles. Data fed back into the computer confirmed the neuromuscular integrity and status of the spinal fixation, the instrumentation, and implants.

After the pedicle screws, hooks, and wires were in place and the spinal rods were cinched down to straighten the spine, Lynn was permitted to emerge temporarily from anesthesia and muscle paralysis medication to a lightly sedated but pain-free state. She was given commands to move her feet, straighten her legs, and wiggle her toes to test all neuromuscular groups that could be affected by misplaced or compressed spinal fixation devices. Her feet were watched, and movement was announced to the team. Dorsiflexion cleared the tibialis anterior muscles; plantar flexion cleared the gastrocnemius muscles. Knee flexion cleared the hamstring muscle group, and knee extension determined function of the quadriceps group. Lynn had a successful "wake-up" test. She was put back into deep anesthesia, and her incision was closed. A postoperative "wake-up" test was repeated after she was moved to her bed. The surgical instruments and tables were kept sterile until after all of the monitored muscle groups were tested and showed voluntary movement. The electrodes were removed, and she was taken to the postanesthesia care unit (PACU) for recovery.

Case Study 6-2 Questions

Follow the instructions for each question and check your answers in Appendix 11.

Multiple Choice. *Select the best answer, and write the letter of your choice to the left of each number.*

_____ 1. The quadriceps muscle group is made up of
   a. smooth and cardiac muscle fibers
   b. four muscles in the thigh
   c. three muscles in the leg and one in the foot
   d. fascia and tendon sheaths

_____ 2. The anterior tibialis muscle is in the
   a. thigh
   b. spine
   c. foot
   d. leg

_____ 3. The nerve supply for the rectus abdominis muscle runs through S1 to S2. This anatomic region is
   a. the first and second sural sheath
   b. subluxation and suppuration
   c. sacral disk space 1 and 2
   d. sacral disk space 3

_____ 4. The movement of elevating the toes toward the anterior ankle is
   a. supination
   b. pronation
   c. dorsiflexion
   d. plantar flexion

_____ 5. Knee extension results in
   a. a bent knee
   b. a ballet position with the toes turned out
   c. bilateral abduction
   d. a straight leg

extern.ir

Write terms from the case study with the following meanings.

6. bending at a joint _____
7. to point the toes downward _____

Define the following abbreviations.

8. SSEP _____
9. PACU _____

extern.ir

CHAPTER 7

Nervous System and Mental Health

Pretest

Multiple Choice. **Select the best answer, and write the letter of your choice to the left of each number. To check your answers go to Appendix 11.**

_____ 1. The basic cell of the nervous system is a(n)
a. myofiber
b. neuron
c. osteoblast
d. chondrocyte

_____ 2. The largest part of the brain is the
a. cerebrum
b. adrenal
c. cortex
d. pituitary

_____ 3. The midbrain, pons, and medulla oblongata make up the
a. ventricle
b. spinal cord
c. cerebellum
d. brainstem

_____ 4. Involuntary responses are controlled by the
a. somatic nervous system
b. voluntary nervous system
c. autonomic nervous system
d. diaphragm

_____ 5. A simple response that requires few cells is a
a. reflex
b. mutation
c. sensation
d. stimulus

_____ 6. A disorder, often of unknown cause, characterized by seizures is called
a. cystic fibrosis
b. spina bifida
c. epilepsy
d. thyrotoxicosis

_____ 7. An instrument used to study the electric activity of the brain is the
a. electrocardiograph
b. electroencephalograph
c. CT scanner
d. sonograph

_____ 8. An extreme, persistent fear is a(n)
a. palliative
b. prognosis
c. analgesic
d. phobia

extern.ir

Learning Objectives

After careful study of this chapter, you should be able to:

1. Describe the components of the nervous system. ***P218***
2. Describe the structure of a neuron. ***P218***
3. Briefly describe the regions of the brain and their functions. ***P219***
4. Describe how the central nervous system is protected. ***P220***
5. Describe the structure of the spinal cord. ***P222***
6. Name the components of a simple reflex. ***P222***
7. Compare the sympathetic and parasympathetic systems. ***P224***
8. Identify and use word parts pertaining to the nervous system. ***P227***
9. Describe eight major types of disorders affecting the nervous system. ***P231***
10. Describe five major categories of behavioral disorders. ***P235***
11. Define abbreviations used in neurology. ***P245***
12. Analyze medical terms in several case studies involving the nervous system. ***PP217, 256***

Case Study: William's Diving Accident and Spinal Cord Injury

Chief Complaint

William, a 12 y/o male, was transported to the emergency department after diving into a shallow backyard cement pool. He c/o severe head and neck pain and has minimal movement of his arms. He is not able to move his legs.

Examination

A well-nourished 12 y/o male is awake and oriented, initially hypotensive and bradycardic, but vital signs are stabilizing. He reports being at a backyard pool party for his friend's birthday and remembers diving into the pool head first. The next thing he recalls is waking up on the deck of the pool with his friends standing all around him. He has a large erythematous and bruised area centered on the upper part of his forehead. William has full head and neck movement with fair muscle strength. He has weak shoulder movement and is able to slightly flex his elbows and extend his wrists. His legs are flexic and flaccid. He has no finger movement. Past medical history is noncontributory.

Clinical Course

William is diagnosed with a burst or comminuted fracture of the C6 vertebra that may potentially result in quadriplegia. After surgical stabilization of the cervical fracture, William was transferred to the spinal cord unit where his vital signs could be monitored closely along with frequent assessments for orthostatic hypotension and possible complications following spinal surgery. He will be moved to a rehabilitation center in about 2 weeks for physical and occupational therapy (OT). His medical team consists of his primary physician (pediatrician), a neurosurgeon, a neurologist, and a physical medicine and rehabilitation (PM&R) specialist. Because a spinal cord injury can result in psychological as well as permanent physical damage, William's condition will require a full complement of healthcare team members, including nurses, psychologists, physical and occupational therapists, pharmacists, and social workers.

Case Study Revisited: Once you complete this chapter, please review the case follow-up on p. 246.

Ancillaries *At-A-Glance*

Visit the web resource to access the following resources.

extern.ir

Learning Resources

- eBook
- A&P Module with Heart & Lung Sounds
- Image Bank
- TestPrep
- Animations
- Audio Pronunciation Glossary

Introduction

The nervous system and the endocrine system coordinate and control the body. Together they regulate our responses to the environment and maintain homeostasis. Whereas the endocrine system functions by means of circulating hormones, the nervous system functions by means of electric impulses and locally released chemicals called neurotransmitters.

Organization of the Nervous System

For study purposes, the nervous system may be divided structurally into two parts:

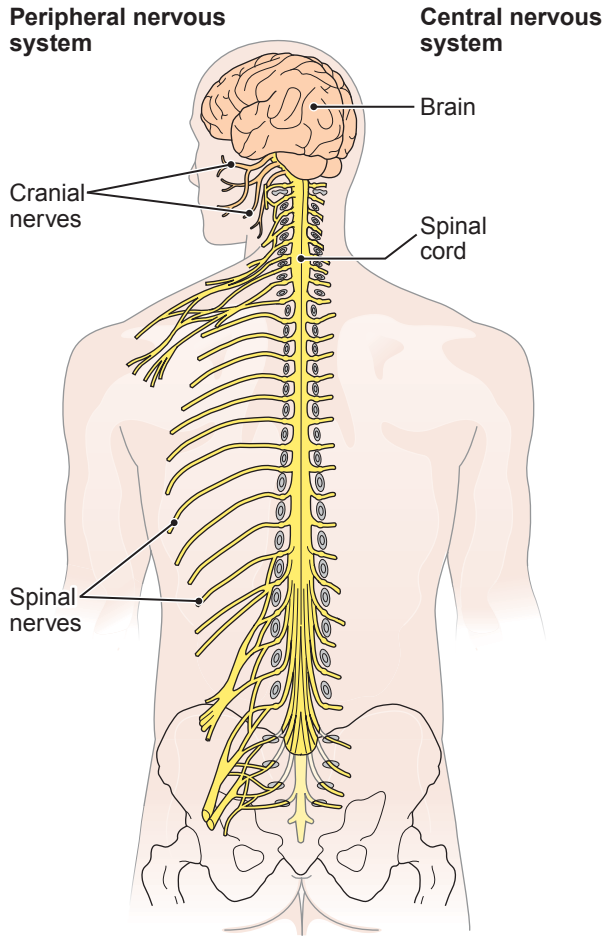

FIGURE 7-1 Anatomic divisions of the nervous system.

- The **central nervous system** (CNS), consisting of the **brain** and **spinal cord** (FIG. 7-1)
- The **peripheral nervous system** (PNS), consisting of all nervous tissue outside the brain and spinal cord (see FIG. 7-1)

Functionally, the nervous system can be divided into the:

- **Somatic nervous system**, which controls skeletal muscles
- **Autonomic nervous system** (ANS), or **visceral nervous system**, which controls smooth muscle, cardiac muscle, and glands; regulates responses to stress; and helps to maintain homeostasis

Two types of cells are found in the nervous system. **Neurons**, or nerve cells, make up the conducting tissue of the nervous system. **Neuroglia** are the cells that support and protect nervous tissue.

THE NEURON

The neuron is the nervous system's basic functional unit (FIG. 7-2). Each neuron has two types of fibers extending from the cell body:

- A **dendrite** carries impulses toward the cell body.
- An **axon** carries impulses away from the cell body.

Some axons are covered with **myelin**, a whitish, fatty material that insulates and protects the axon and speeds electric conduction. Axons so covered are described as *myelinated*, and they make up the **white matter** of the nervous system. Unmyelinated tissue makes up the nervous system's **gray matter.** The myelin sheath consists of individual cells that wrap around the axon. The spaces between these cells are called *nodes*. Myelinated axons conduct nerve impulses more rapidly than unmyelinated axons because the electric impulse can skip from node to node.

Each neuron is part of a pathway that carries information through the nervous system. A neuron that transmits impulses toward the CNS is a **sensory**, or **afferent**, neuron; a neuron that transmits impulses away from the CNS is a **motor**, or **efferent**, neuron. There are also connecting cells within the CNS called **interneurons.**

extern.ir

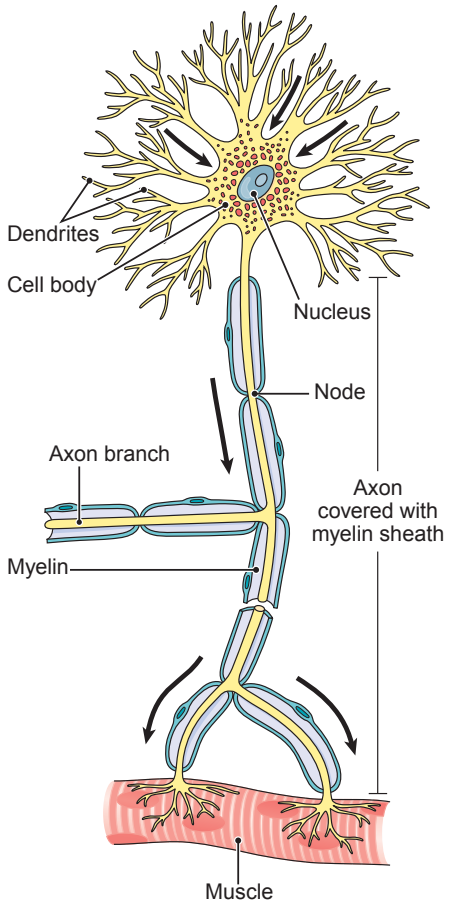

FIGURE 7-2 A motor neuron. The break in the axon denotes length. The *arrows* show the direction of the nerve impulse.

A **synapse** is the point of contact between two neurons. At the synapse, energy is passed from one cell to another, usually by means of a **neurotransmitter** and sometimes by direct transfer of electric current.

NERVES

Individual neuron fibers are held together in bundles like wires in a cable. If this bundle is part of the PNS, it is called a **nerve.** A collection of cell bodies along the pathway of a nerve is a **ganglion.** A few nerves (sensory nerves) contain only sensory neurons, and a few (motor nerves) contain only motor neurons, but most contain both types of fibers and are described as *mixed nerves*.

7

The Brain

The brain is nervous tissue contained within the cranium. It consists of the **cerebrum, diencephalon, brainstem,** and **cerebellum.** The cerebrum is the largest part of the brain (FIG. 7-3); it is composed largely of white matter with a thin outer layer of gray matter, the **cerebral cortex.** It is within the cortex that the higher brain functions of memory, reasoning, and abstract thought occur. The cerebrum's distinct surface is formed by grooves, or **sulci** (singular: sulcus), and raised areas, or **gyri** (singular: gyrus), that provide additional

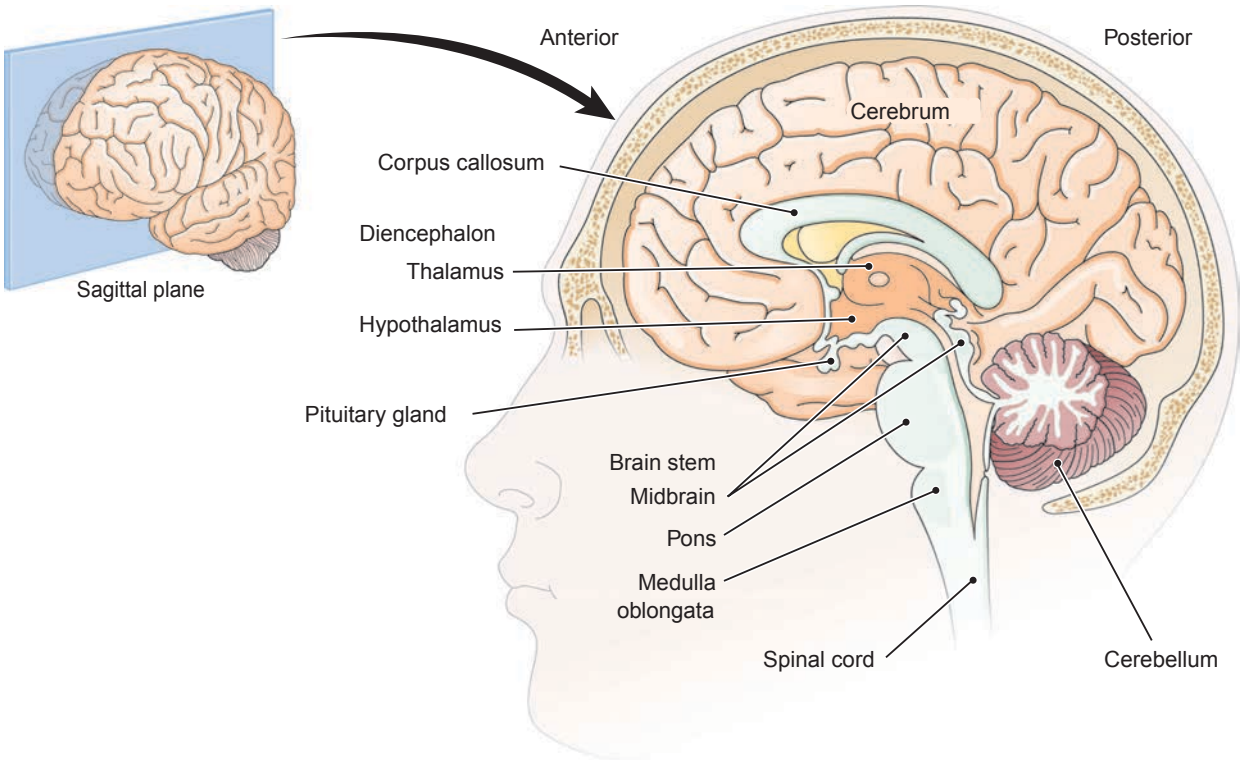

FIGURE 7-3 Brain, sagittal section. The main divisions are shown.

extern.ir

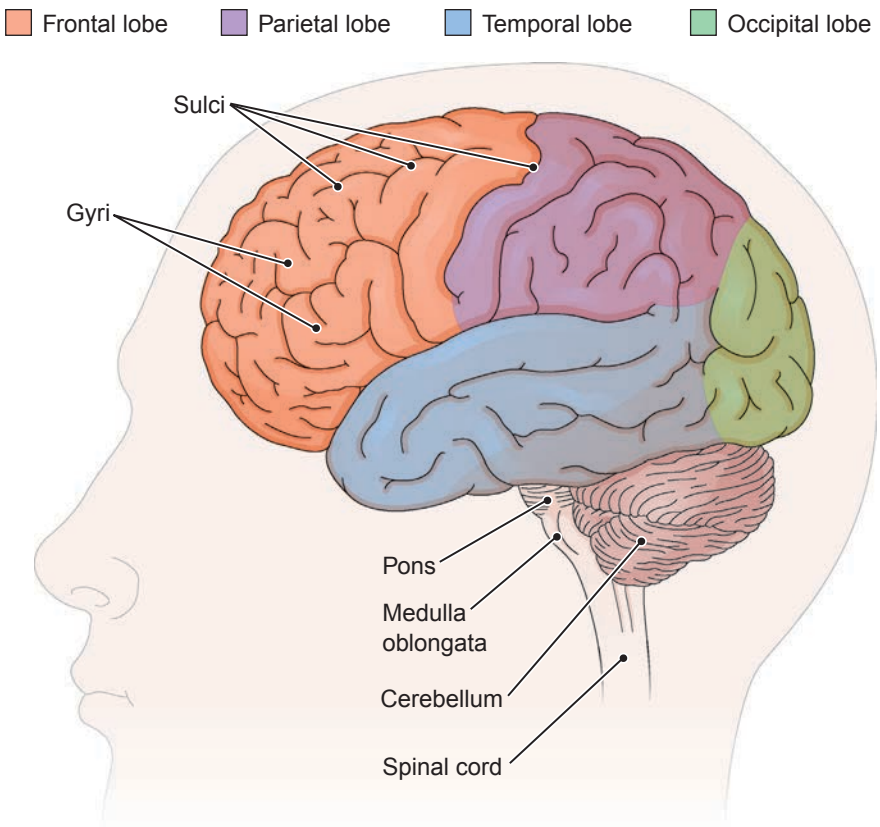

FIGURE 7-4 External surface of the brain, lateral view. The lobes and surface features of the cerebrum are shown as well as other divisions of the brain and the spinal cord.

surface area (FIG. 7-4). The cerebrum is divided into two hemispheres by a deep groove, the longitudinal fissure. Each hemisphere is further divided into lobes with specialized functions (see FIG. 7-4). The lobes are named for the skull bones under which they lie.

The remaining parts of the brain, shown in FIGURE 7-3, are as follows:

- The diencephalon contains the **thalamus**, the **hypothalamus**, and the pituitary gland. The thalamus receives sensory information and directs it to the proper portion of the cortex. The hypothalamus controls the pituitary and forms a link between the endocrine and nervous systems.
- The brainstem consists of the:
  - **Midbrain**, which contains reflex centers for improved vision and hearing.
  - **Pons**, which forms a bulge on the anterior surface of the brainstem. It contains fibers that connect the brain's different regions.
  - **Medulla oblongata**, which connects the brain with the spinal cord. All impulses passing to and from the brain travel through this region. The medulla also has vital centers for control of heart rate, respiration, and blood pressure.
- The cerebellum is under the cerebrum and dorsal to the pons and medulla. Like the cerebrum, it is divided into two hemispheres. The cerebellum helps to control voluntary muscle movements and to maintain posture, coordination, and balance.

PROTECTING THE BRAIN

Within the brain are four **ventricles** (cavities) in which **cerebrospinal fluid** (CSF) is formed. This fluid circulates around the brain and spinal cord, acting as a protective cushion for these tissues.

Covering the brain and the spinal cord are three protective layers, together called the **meninges** (FIG. 7-5). All are named with the Latin word *mater*, meaning "mother," to indicate their protective function. They are the:

- **Dura mater**, the outermost and toughest of the three. *Dura* means "hard."
- **Arachnoid mater**, the thin, web-like middle layer. It is named for the Latin word for spider, because it resembles a spider web.
- **Pia mater**, the thin, vascular inner layer, attached directly to the tissue of the brain and spinal cord. *Pia* means "tender."

Twelve pairs of **cranial nerves** connect with the brain (FIG. 7-6). These nerves are identified by Roman numerals and also by name. BOX 7-1 is a summary chart of the cranial nerves.

extern.ir

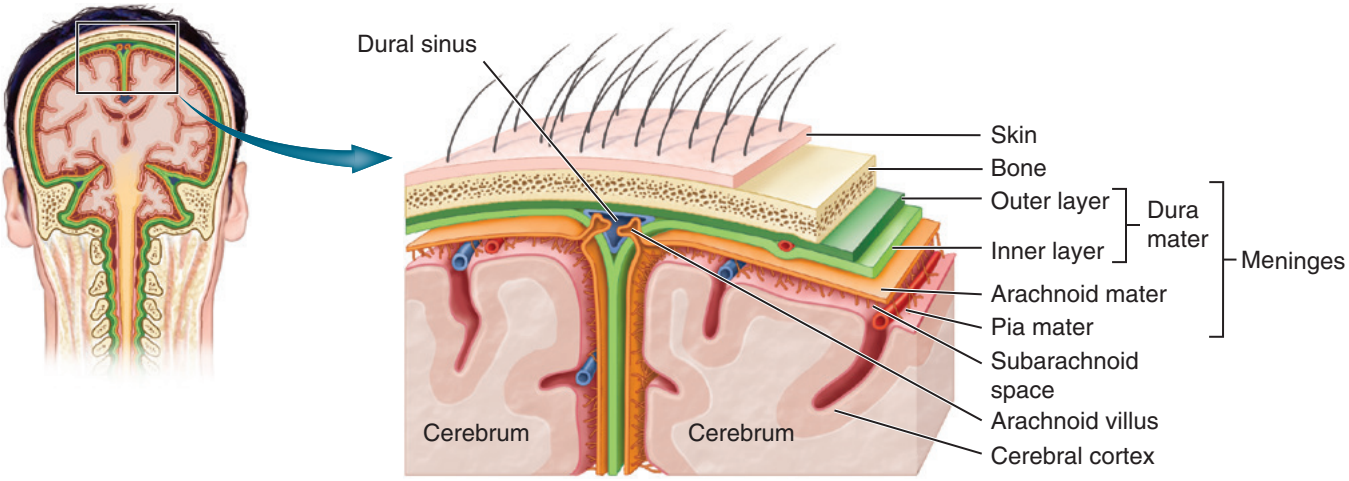

FIGURE 7-5 The meninges. The three protective layers and adjacent tissue are shown in a frontal section of the head.

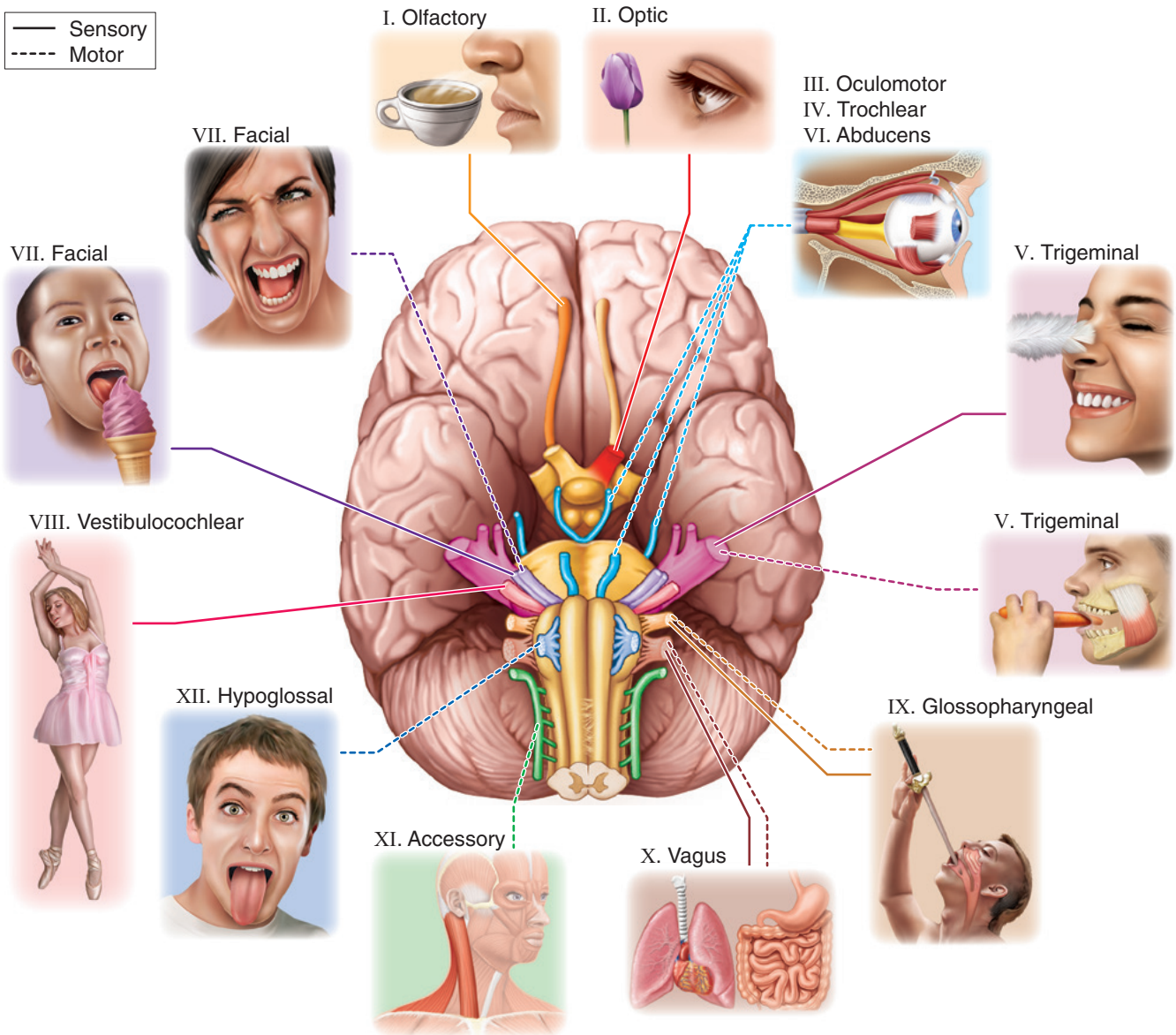

FIGURE 7-6 Cranial nerves. The 12 nerves are shown from the base of the brain.

extern.ir

FOR YOUR REFERENCE
The Cranial Nerves

BOX 7-1

Number	Name	Function
I	**olfactory** *ol-FAK-to-re*	carries impulses for the sense of smell toward the brain
II	**optic** *OP-tik*	carries visual impulses from the eye to the brain
III	**oculomotor** *ok-u-lo-MO-tor*	controls movement of eye muscles; carries the parasympathetic fibers that constrict the pupil
IV	**trochlear** *TROK-le-ar*	controls a muscle of the eyeball
V	**trigeminal** *tri-JEM-ih-nal*	carries sensory impulses from the eye, upper jaw, and lower jaw toward the brain; controls chewing muscles
VI	**abducens** *ab-DU-sens*	controls a muscle of the eyeball
VII	**facial** *FA-shal*	controls muscles of facial expression, carries sensation for taste, stimulates small salivary glands and lacrimal (tear) glands
VIII	**vestibulocochlear** *ves-tib-u-lo-KOK-le-ar*	carries impulses for hearing and equilibrium from the inner ear toward the brain; also called auditory or acoustic nerve
IX	**glossopharyngeal** *glos-o-fah-RIN-je-al*	carries sensory impulses from the tongue and pharynx (throat), controls swallowing muscles, and stimulates the parotid salivary gland
X	**vagus** *VA-gus*	supplies most of the organs in the thoracic and abdominal cavities; carries motor impulses to the larynx (voice box) and pharynx
XI	**spinal accessory** *ak-SES-o-re*	controls muscles in the neck and larynx
XII	**hypoglossal** *hi-po-GLOS-al*	controls muscles of the tongue

The Spinal Cord

The spinal cord begins at the medulla oblongata and tapers to an end between the first and second lumbar vertebrae (FIG. 7-7). It has enlargements in the cervical and lumbar regions, where nerves for the arms and legs join the cord. Seen in cross-section (FIG. 7-8), the spinal cord has a central area of gray matter surrounded by white matter. The gray matter projects toward the posterior and the anterior as the dorsal and ventral horns. The white matter contains the ascending and descending **tracts** (fiber bundles) that carry impulses to and from the brain. A central canal contains CSF.

THE SPINAL NERVES

Thirty-one pairs of **spinal nerves** connect with the spinal cord (see FIG. 7-7). These nerves are grouped in the segments of the cord as follows:

- Cervical: 8
- Thoracic: 12
- Lumbar: 5
- Sacral: 5
- Coccygeal: 1

Each nerve joins the cord by two **roots** (see FIG. 7-8). The dorsal, or posterior, root carries sensory impulses into the cord; the ventral, or anterior, root carries motor impulses away from the cord and out toward a muscle or gland. An enlargement on the dorsal root, the dorsal root ganglion, has the cell bodies of sensory neurons carrying impulses toward the CNS.

REFLEXES

A simple response that requires few neurons is a **reflex** (FIG. 7-9). In a spinal reflex, impulses travel through the spinal cord only and do not reach the brain. An example of this type of response is the knee-jerk reflex used in physical examinations. However, most neurologic responses involve complex interactions among multiple neurons in the CNS.

extern.ir

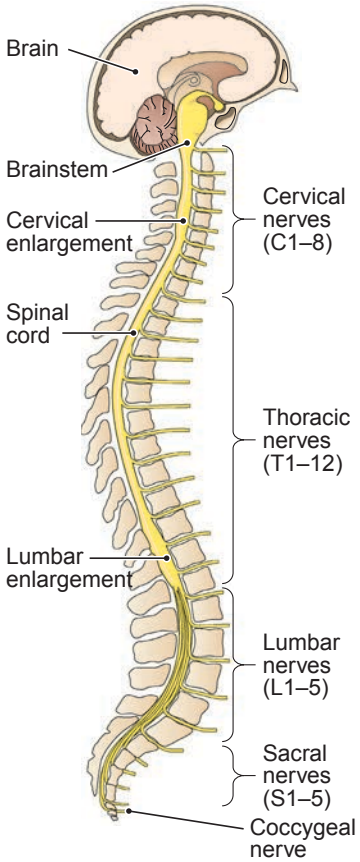

FIGURE 7-7 Spinal cord, lateral view. The divisions of the spinal nerves are shown.

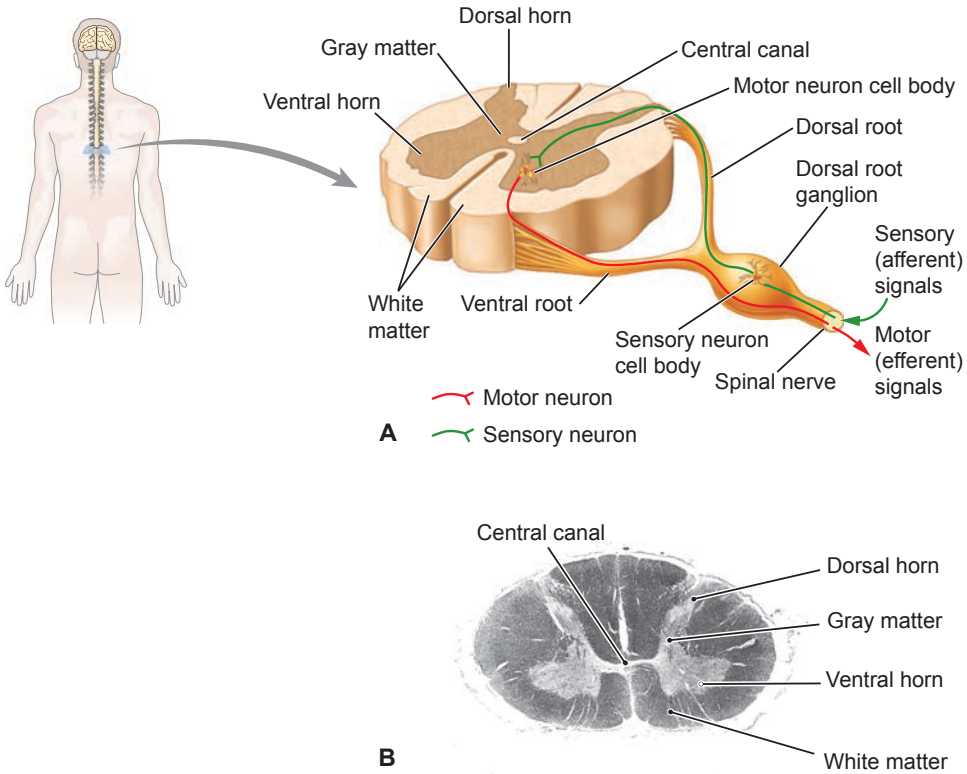

FIGURE 7-8 Spinal cord, cross-section. A. Diagram shows the organization of gray and white matter in the cord. The roots of the spinal nerves and the pathway of nerve impulses through the spinal cord are also shown. **B.** Microscopic view of the spinal cord in cross-section (magnification 5×).

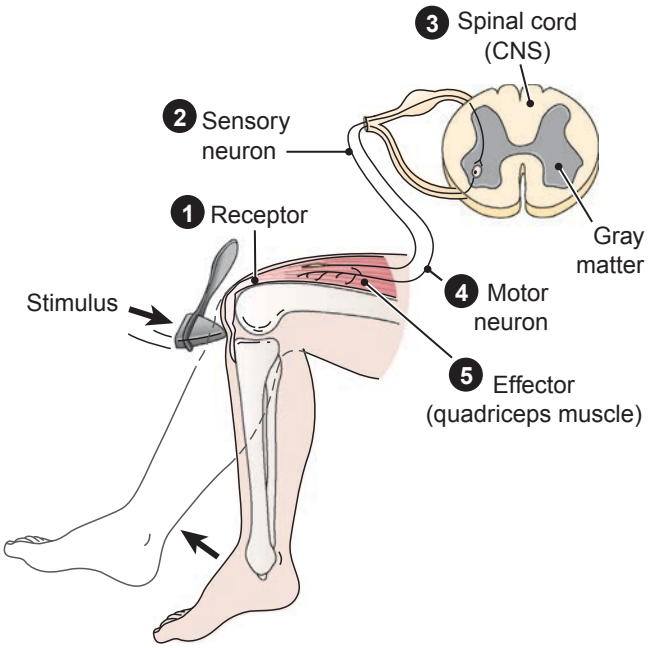

FIGURE 7-9 A reflex pathway (arc). The patellar (knee-jerk) reflex is shown, with numbers indicating the sequence of impulses.

extern.ir

The Autonomic Nervous System

The ANS is the division of the nervous system that controls the involuntary actions of muscles and glands (FIG. 7-10). The ANS itself has two divisions:

- The **sympathetic nervous system** motivates our response to stress, the so-called fight-or-flight response. It increases heart rate and respiration rate, stimulates the adrenal gland, and delivers more blood to skeletal muscles.
- The **parasympathetic nervous system** returns the body to a steady state and stimulates maintenance activities, such as digestion of food. Most organs are controlled by both systems, and in general, the two systems have opposite effects on a given organ.

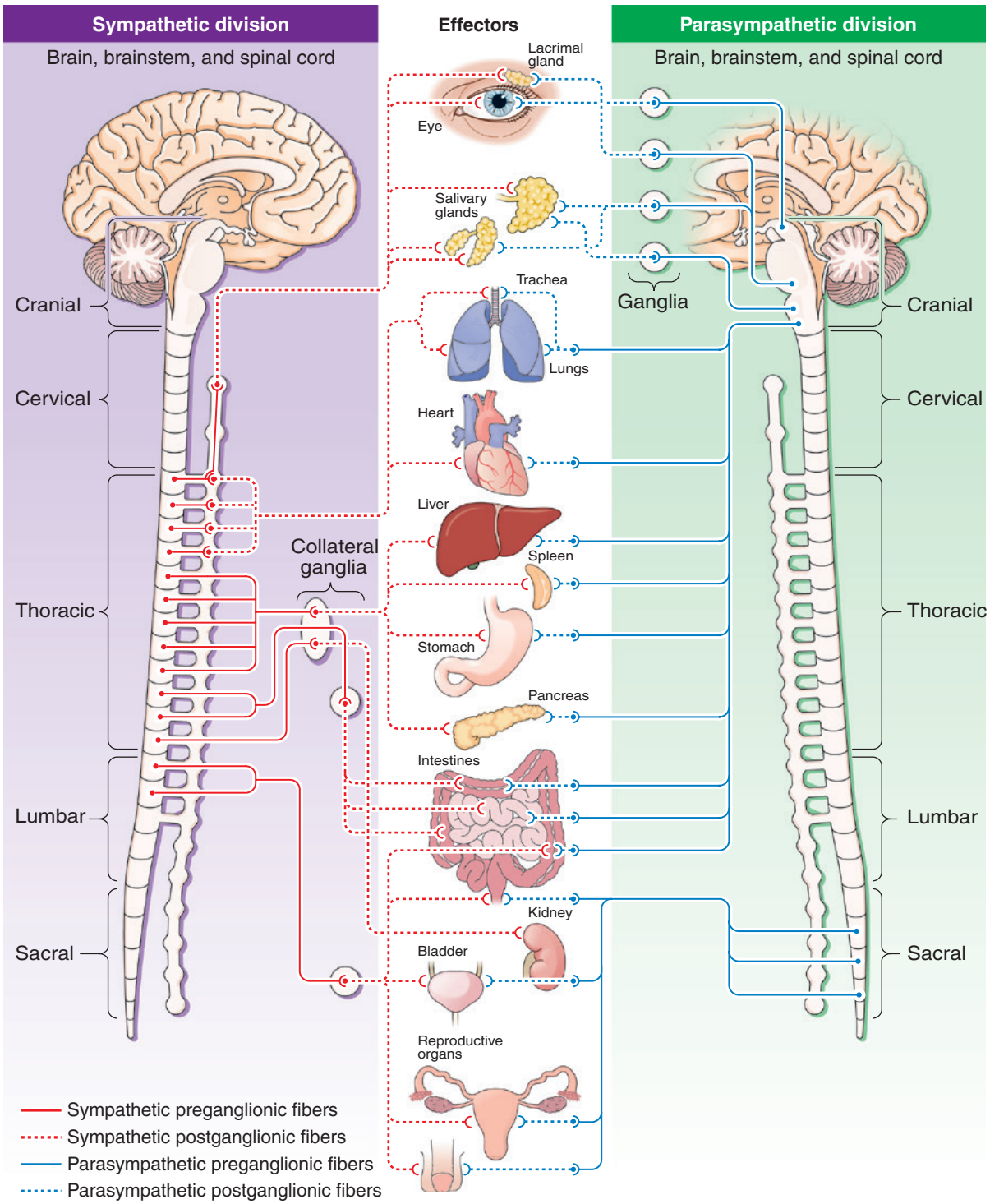

FIGURE 7-10 Autonomic nervous system. Each ANS pathway has two neurons, as shown by the *solid* and *dashed lines*. The diagram shows only one side of the body for each division (sympathetic and parasympathetic).

extern.ir

Terminology *Key Terms*

The terms listed below are emphasized in this chapter. Knowing them will help you organize and prioritize your learning. These boldface terms are also found, collectively, with all chapter key terms in the Glossary.

Normal Structure and Function

afferent *AF-er-ent*	Carrying toward a given point, such as the sensory neurons and nerves that carry impulses toward the CNS (root *fer* means "to carry")
arachnoid mater *ah-RAK-noyd*	The middle layer of the meninges (from the Greek word for spider, because this tissue resembles a spider web)
autonomic nervous system (ANS) *aw-to-NOM-ik*	The division of the nervous system that regulates involuntary activities, controlling smooth muscles, cardiac muscle, and glands; the visceral nervous system
axon *AK-son*	The fiber of a neuron that conducts impulses away from the cell body
brain *brane*	The nervous tissue contained within the cranium; consists of the cerebrum, diencephalon, brainstem, and cerebellum (root: encephal/o)
brainstem	The part of the brain that consists of the midbrain, pons, and medulla oblongata
central nervous system (CNS)	The brain and spinal cord
cerebellum *ser-eh-BEL-um*	The posterior portion of the brain dorsal to the pons and medulla; helps to coordinate movement and to maintain balance and posture (cerebellum means "little brain") (root: cerebell/o)
cerebral cortex *SER-eh-bral*	The cerebrum's thin surface layer of gray matter (the cortex is the outer region of an organ) (root: cortic/o)
cerebrum *SER-eh-brum*	The large upper portion of the brain; it is divided into two hemispheres by the longitudinal fissure (root: cerebr/o)
cerebrospinal fluid (CSF) *ser-eh-bro-SPI-nal*	The watery fluid that circulates in and around the brain and spinal cord for protection
cranial nerves	The 12 pairs of nerves that are connected to the brain
dendrite *DEN-drite*	A fiber of a neuron that conducts impulses toward the cell body
diencephalon *di-en-SEF-ah-lon*	The part of the brain that contains the thalamus, hypothalamus, and pituitary gland; located between the cerebrum and the brainstem
dura mater *DU-rah MA-ter*	The strong, fibrous outermost layer of the meninges
efferent *EF-er-ent*	Carrying away from a given point, such as the motor neurons and nerves that carry impulses away from the CNS (root *fer* means "to carry")
ganglion *GANG-gle-on*	A collection of neuron cell bodies outside the CNS (plural: ganglia) (roots: gangli/o, ganglion/o)
gray matter	Unmyelinated tissue of the nervous system
gyrus *JI-rus*	A raised convolution of the surface of the cerebrum (see **FIG. 7-4**) (plural: gyri)
hypothalamus *hi-po-THAL-ah-mus*	The part of the brain that controls the pituitary gland and maintains homeostasis
interneuron *in-ter-NU-ron*	Any neuron located between a sensory and a motor neuron in a neural pathway, such as the neurons that transmit impulses within the CNS

(continued)

extern.ir

Terminology Key Terms (Continued)

medulla oblongata *meh-DUL-lahob-long-GAH-tah*	The portion of the brain that connects with the spinal cord; it has vital centers for control of respiration, heart rate, and blood pressure (root: medull/o); often called simply medulla
meninges *men-IN-jeze*	The three membranes that cover the brain and spinal cord (see **FIG. 7-5**) (singular: meninx) (roots: mening/o, meninge/o)
midbrain	The part of the brainstem between the diencephalon and the pons; contains centers for coordination of reflexes for vision and hearing
motor	Producing movement; describes efferent neurons and nerves that carry impulses away from the CNS
myelin *MI-eh-lin*	A whitish, fatty substance that surrounds certain axons of the nervous system
neuroglia *nu-ROG-le-ah*	The support cells of the nervous system; also called glial cells (from glia meaning "glue") (root: gli/o)
neuron *NU-ron*	The basic unit of the nervous system; a nerve cell
neurotransmitter *nu-ro-TRANS-mit-er*	A chemical that transmits energy across a synapse; examples are norepinephrine (*nor-ep-ih-NEF-rin*), acetylcholine (*ah-se-til-KO-lene*), serotonin (*ser-o-TO-nin*), and dopamine (*DO-pah-mene*)
nerve	A bundle of neuron fibers outside the CNS (root: neur/o)
parasympathetic nervous system *par-ah-sim-pah-THET-ik*	The part of the autonomic nervous system that reverses the response to stress and restores homeostasis; it slows heart rate and respiration rate and stimulates digestive, urinary, and reproductive activities
peripheral nervous system (PNS) *per-IF-er-al*	The portion of the nervous system outside the CNS
pia mater *PE-ah MA-ter*	The innermost layer of the meninges
pons *ponz*	A rounded area on the ventral surface of the brainstem; contains fibers that connect brain regions (adjective: pontine [*PON-tene*])
reflex *RE-fleks*	A simple, rapid, and automatic response to a stimulus
root *rute*	The fundamental unit of a word. A branch of a spinal nerve that connects with the spinal cord; the dorsal (posterior) root joins the spinal cord's dorsal gray horn; the ventral (anterior) root joins the spinal cord's ventral gray horn (root: radicul/o)
sensory *SEN-so-re*	Pertaining to the senses or sensation; describing afferent neurons and nerves that carry impulses toward the CNS
somatic nervous system *so-MAT-ik*	The division of the nervous system that controls skeletal (voluntary) muscles
spinal cord	The nervous tissue contained within the spinal column; extends from the medulla oblongata to the second lumbar vertebra (root: myel/o)
spinal nerves	The 31 pairs of nerves that connect with the spinal cord
sulcus *SUL-kus*	A shallow furrow or groove, as on the surface of the cerebrum (see **FIG. 7-4**) (plural: sulci)
sympathetic nervous system *sim-pah-THET-ik*	The part of the autonomic nervous system that mobilizes a response to stress, increases heart rate and respiration rate, and delivers more blood to skeletal muscles
synapse *SIN-aps*	The junction between two neurons; also the junction between a motor neuron and a muscle or gland

extern.ir

Terminology Key Terms (Continued)

thalamus *THAL-ah-mus*	The part of the brain that receives all sensory impulses, except those for the sense of smell, and directs them to the proper portion of the cerebral cortex (root: thalam/o)
tract *trakt*	A bundle of neuron fibers within the CNS
ventricle *VEN-trik-l*	A small cavity, such as one of the cavities in the brain in which CSF is formed. One of the two lower pumping chambers of the heart (root: ventricul/o)
visceral nervous system *VIS-er-al*	The autonomic nervous system
white matter	Myelinated tissue of the nervous system

Word Parts Pertaining to the Nervous System

See **TABLES 7-1** to **7-3**.

Table 7-1 Roots for the Nervous System and the Spinal Cord

Root	Meaning	Example	Definition of Example
neur/o, neur/i	nervous system, nervous tissue, nerve	neurotrophin *nu-ro-TRO-fin*	factor that promotes nerve growth (troph/o means "nourish")
gli/o	neuroglia	glial *GLI-al*	pertaining to neuroglia
gangli/o, ganglion/o	ganglion	ganglioma *gang-gle-O-mah*	tumor of a ganglion
mening/o, meninge/o	meninges	meningocele *meh-NING-go-sele*	hernia of the meninges
myel/o	spinal cord (also bone marrow)	hematomyelia *he-mah-to-mi-E-le-ah*	hemorrhage into the spinal cord
radicul/o	spinal nerve root	radiculopathy *rah-dik-u-LOP-ah-the*	any disease of a spinal nerve root

Exercise 7-1

Complete the exercise. To check your answers go to Appendix 11.

Define the following adjectives.

1. neural (*NU-ral*) pertaining to a nerve or the nervous system _____
2. neuroglial (*nu-ROG-le-al*) _____
3. radicular (*rah-DIK-u-lar*) _____
4. meningeal (*meh-NIN-je-al*) _____
5. ganglionic (*gang-gle-ON-ik*) _____

(continued)

extern.ir

Exercise 7-1 *(Continued)*

Fill in the blanks.

6. A meningioma (*meh-nin-je-O-mah*) is a tumor affecting the _____ .
7. A neurotropic (*nu-ro-TROP-ik*) dye has an affinity for the _____ .
8. Meningococci (*meh-ning-go-KOK-si*) are bacteria (cocci) that infect the _____ .
9. Myelodysplasia (*mi-eh-lo-dis-PLA-se-ah*) is abnormal development of the _____ .

Define the following terms.

10. ganglionectomy (*gang-gle-o-NEK-to-me*) _____
11. polyradiculitis (*pol-e-rah-dik-u-LI-tis*) _____
12. neurolysis (*nu-ROL-ih-sis*) _____
13. radiculalgia (*rah-dik-u-LAL-je-ah*) _____
14. myelography (*mi-eh-LOG-rah-fe*) _____

Write words for the following definitions.

15. tumor of glial cells _____
16. x-ray image of the spinal cord _____
17. pain in a nerve _____
18. inflammation of the spinal cord _____
19. any disease of the nervous system _____

Table 7-2 Roots for the Brain

Root	Meaning	Example	Definition of Example
encephal/o	brain	anencephaly *an-en-SEF-ah-le*	absence of a brain
cerebr/o	cerebrum (loosely, brain)	infracerebral *in-frah-SER-eh-bral*	below the cerebrum
cortic/o	cerebral cortex, outer portion	corticospinal *kor-tih-ko-SPI-nal*	pertaining to the cerebral cortex and spinal cord
cerebell/o	cerebellum	supracerebellar *su-prah-ser-eh-BEL-ar*	above the cerebellum
thalam/o	thalamus	thalamotomy *thal-ah-MOT-o-me*	incision of the thalamus
ventricul/o	cavity, ventricle	intraventricular *in-trah-ven-TRIK-u-lar*	within a ventricle
medull/o	medulla oblongata (also spinal cord)	medullary *MED-u-lar-e*	pertaining to the medulla
psych/o	mind	psychogenic *si-ko-JEN-ik*	originating in the mind
narc/o	stupor, unconsciousness	narcosis *nar-KO-sis*	state of stupor induced by drugs
somn/o, somn/i	sleep	somnolence *SOM-no-lens*	sleepiness

extern.ir

Exercise 7-2

Complete the exercise. To check your answers go to Appendix 11.

Fill in the blanks.

1. Somnambulism (*som-NAM-bu-lizm*) means walking during _____ .
2. The term decerebrate (*de-SER-eh-brate*) refers to functional loss in the _____ .
3. The hypothalamus (*hi-po-THAL-ah-mus*) is below the _____ .
4. A psychoactive (*si-ko-AK-tiv*) drug has an effect on the _____ .
5. A narcotic (*nar-KOT-ik*) is a drug that causes _____ .
6. An electroencephalogram (*e-lek-tro-en-SEF-ah-lo-gram*) (EEG) is a record of the electric activity of the _____ .
7. The term cerebrovascular (*ser-e-bro-VAS-ku-lar*) refers to blood vessels in the _____ .

Write an adjective for the following definitions. Note the endings.

8. pertaining to (-ic) the mind _____
9. pertaining to (-al) the cerebral cortex _____
10. pertaining to (-ic) the thalamus _____
11. pertaining to (-al) the cerebrum _____
12. pertaining to (-ar) a ventricle _____

Define the following words.

13. encephalopathy (*en-sef-ah-LOP-ah-the*) _____
14. insomnia (*in-SOM-ne-ah*) _____
15. psychology (*si-KOL-oje*) _____
16. cerebrospinal (*ser-eh-bro-SPI-nal*) _____
17. extramedullary (*eks-trah-MED-u-lar-e*) _____
18. ventriculotomy (*ven-trik-u-LOT-o-me*) _____

Write words for the following definitions.

19. radiograph of a ventricle _____
20. pertaining to the cerebral cortex and the thalamus _____
21. within the cerebellum _____
22. inflammation of the brain _____
23. above the cerebrum _____

extern.ir

Table 7-3 Suffixes for the Nervous System

Suffix	Meaning	Example	Definition of Example
-phasia	speech	heterophasia *het-er-o-FA-ze-ah*	uttering words that are different from those intended
-lalia	speech, babble	coprolalia *kop-ro-LA-le-ah*	compulsive use of obscene words (copro- means "feces")
-lexia	reading	bradylexia *brad-e-LEK-se-ah*	slowness in reading
-plegia	paralysis	tetraplegia *tet-rah-PLE-je-ah*	paralysis of all four limbs
-paresis[a]	partial paralysis, weakness	hemiparesis *hem-e-pah-RE-sis*	partial paralysis of one side of the body
-lepsy	seizure	narcolepsy *NAR-ko-lep-se*	condition marked by sudden episodes of sleep
-phobia[a]	persistent, irrational fear	agoraphobia *ag-o-rah-FO-be-ah*	fear of being in a public place (from Greek *agora*, meaning "marketplace")
-mania[a]	excited state, obsession	megalomania *meg-ah-lo-MA-ne-ah*	exaggerated self-importance; "delusions of grandeur"

[a]May be used alone as a word.

Exercise 7-3

Complete the exercise. To check your answers go to Appendix 11.

Fill in the blanks.

1. Epilepsy (*EP-ih-lep-se*) is a disease characterized by _____ .
2. A person with alexia (*ah-LEK-se-ah*) lacks the ability to _____ .
3. Echolalia (*ek-o-LA-le-ah*) refers to repetitive _____ .
4. Another term for quadriplegia (*kwah-drih-PLE-je-ah*) is _____ .
5. In myoparesis (*mi-o-pah-RE-sis*), a muscle shows _____ .

Define the following words.

6. cardioplegia (*kar-de-o-PLE-je-ah*) _____
7. aphasia (*ah-FA-ze-ah*) _____
8. alexia (*ah-LEK-se-ah*) _____
9. pyromania (*pi-ro-MA-ne-ah*) _____
10. gynephobia (*gi-neh-FO-be-ah*) _____
11. quadriparesis (*kwah-drih-pah-RE-sis*) _____

Write words for the following definitions.

12. fear of (or abnormal sensitivity to) light _____
13. fear of night and darkness _____
14. paralysis of one side (hemi-) of the body _____
15. slowness in speech (-lalia) _____

extern.ir

Clinical Aspects of the Nervous System

VASCULAR DISORDERS

The term **cerebrovascular accident (CVA)**, or **stroke**, applies to any occurrence that deprives brain tissue of oxygen. These events include blockage in a vessel that supplies the brain, a ruptured blood vessel, or some other damage that leads to hemorrhage within the brain. Stroke is the fourth leading cause of death in developed countries and is a leading cause of **paralysis** and other neurologic disabilities. Risk factors for a stroke include hypertension, atherosclerosis, heart disease, diabetes mellitus, and cigarette smoking. Heredity is also a factor.

Thrombosis

Thrombosis is the formation of a blood clot in a vessel. Often, in cases of CVA, thrombosis occurs in the carotid artery, the large vessel in the neck that supplies the brain. Sudden blockage by an obstruction traveling from another part of the body is described as an **embolism.** In cases of stroke, the embolus usually originates in the heart.

These obstructions can be diagnosed by **cerebral angiography** with radiopaque dye, computed tomographic (CT) scans, and other radiographic techniques. In cases of thrombosis, surgeons can remove the blocked section of a vessel and insert a graft. If the carotid artery leading to the brain is involved, a **carotid endarterectomy** may be performed to open the vessel. Thrombolytic drugs for dissolving ("busting") such clots are also available.

Aneurysm

An **aneurysm** (FIG. 7-11) is a localized dilation of a vessel that may rupture and cause hemorrhage. An aneurysm may be congenital or may arise from other causes, especially atherosclerosis, which weakens the vessel wall. Hypertension then contributes to its rupture.

The effects of cerebral hemorrhage vary from massive functional loss to mild sensory or motor impairment depending on the degree of damage. **Aphasia**, loss or impairment of speech communication, is a common aftereffect. **Hemiplegia** (paralysis of one side of the body) on the side opposite the damage is also seen. It has been found in cases of hemorrhage, as in other forms of brain injury, that immediate retraining therapy may help to restore lost function.

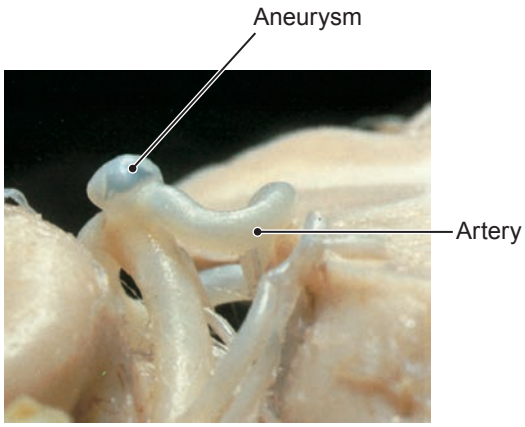

FIGURE 7-11 Aneurysm. A thin-walled aneurysm protrudes from an artery.

HEAD INJURY

A **cerebral contusion** is a bruise to the brain's surface, usually caused by a blow to the head. Blood escapes from local vessels, but the injury is not deep. Cerebral **concussion**, also known as a **mild traumatic brain injury (MTBI)**, refers to a transient alteration in brain function resulting from head trauma or from acceleration–deceleration events where a head in motion suddenly comes to a stop. The effects include amnesia, headache, dizziness, vomiting, disorientation, and sometimes loss of consciousness. Damage that occurs on the side of the brain opposite a blow as the brain is thrown against the skull is described as a **contrecoup** (*kon-treh-KU*) **injury** (from French, meaning "counterblow").

Postconcussion syndrome describes symptoms that persist or develop a month or more after the injury, such as headache, fatigue, mood changes, and cognitive deficits. Individuals who have suffered one concussion are more susceptible to future concussions, and subsequent concussions can cause more severe and long-lasting symptoms. So, athletes diagnosed with concussion should not return to play until a medical professional certifies the absence of any symptoms. New research has shown that psychological factors play a large role in the severity of the symptoms and the speed of recovery. Concussions are treated with physical and cognitive rest, including restrictions on sports, computer use, reading, and even texting.

A more serious result of head trauma is bleeding into or around the meninges. Damage to an artery from a skull fracture, usually on the side of the head, may result in bleeding between the dura mater and the skull, an **epidural hematoma** (FIG. 7-12). The rapidly accumulating blood puts pressure on blood vessels and interrupts blood flow to the brain. Symptoms include headache, vomiting, confusion, aphasia (loss of speech), **hemiparesis** (partial paralysis) on the side opposite the blow, dilated pupils, seizures, and coma. Diagnosis is made by CT scan or magnetic resonance imaging (MRI). If pressure is not relieved within 1 or 2 days, death results. An epidural hematoma requires an immediate neurosurgery consultation, because early surgical intervention often provides the best hope of recovery.

A tear in the wall of a dural sinus causes a **subdural hematoma** (see FIG. 7-12). This often results from a blow to the front or back of the head that separates the dura from the arachnoid, as occurs when the moving head hits a stationary object. Blood gradually accumulates in the subdural space, putting pressure on the brain and causing headache, weakness, and confusion. Death results from continued untreated bleeding. Note that blood can accumulate over time in older people with less brain tissue and more

extern.ir

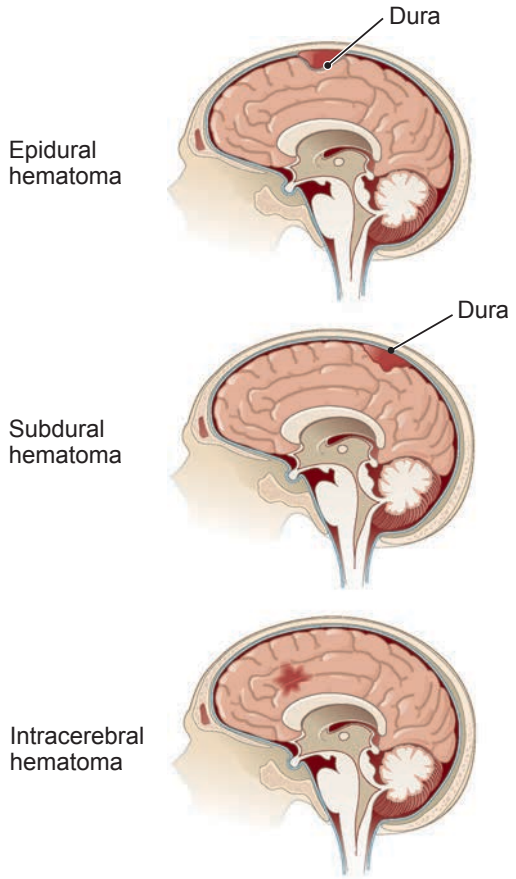

FIGURE 7-12 Cranial hematomas. Location of epidural, subdural, and intracerebral hematomas are shown.

intracranial space. Healthcare providers should consider the possibility of subdural hematoma in an older person who shows increasing confusion and has a history of recent head trauma. FIGURE 7-12 also shows a site of bleeding into the brain tissue itself, forming an intracerebral hematoma.

Other injuries may damage the brain directly. Injury to the base of the brain may involve vital centers in the medulla and interfere with respiration and cardiac functions.

CONFUSION AND COMA

Confusion is a state of reduced comprehension, coherence, and reasoning ability resulting in inappropriate responses to environmental stimuli. Confusion may worsen to include loss of language ability, memory loss, reduced alertness, and emotional changes. This condition may accompany a head injury, drug toxicity, extensive surgery, organ failure, infection, or degenerative disease.

Coma is a state of unconsciousness from which one cannot be aroused. Causes of coma include brain injury, **epilepsy**, toxins, metabolic imbalance (such as the ketoacidosis or glucose imbalances associated with diabetes mellitus), and respiratory, hepatic, or renal failure.

Healthcare professionals use various responses to evaluate coma, for example, reflex behavior and responses to touch, pressure, and mild pain, as from a light pin prick. Laboratory tests, **electroencephalography** (EEG), and sometimes CT and MRI scans help to identify the causes of coma.

INFECTION

Inflammation of the meninges, or **meningitis**, is usually caused by bacteria that enter through the ear, nose, or throat or are carried by the blood. One of these organisms, the meningococcus (*Neisseria meningitidis*), is responsible for meningitis epidemics among individuals living in close quarters. Other bacteria implicated in cases of meningitis include *Haemophilus influenzae*, *Streptococcus pneumoniae*, and *Escherichia coli*. A stiff neck is a common symptom. The presence of pus or lymphocytes in spinal fluid is also characteristic.

Physicians can withdraw fluid for diagnosis by a **lumbar puncture** (FIG. 7-13), using a needle to remove CSF from the meninges in the lumbar region of the spine. A laboratory can examine this fluid for white blood cells and bacteria in the case of meningitis; for red blood cells in the case of brain injury; or for tumor cells. The fluid can also be analyzed

A

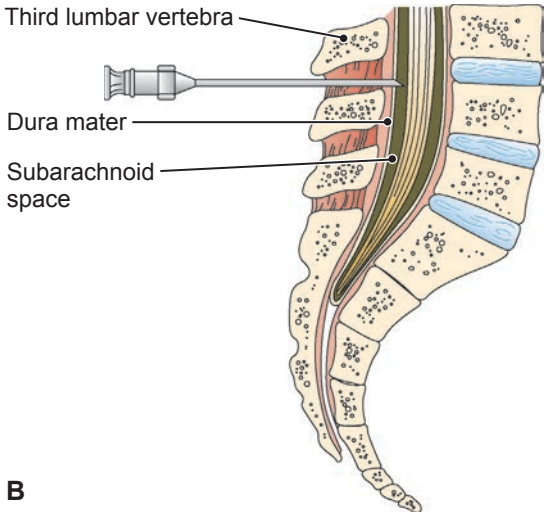

B

FIGURE 7-13 Lumbar puncture. A. Position of the patient for a lumbar puncture. **B.** CSF is withdrawn from the subarachnoid space between the third and fourth or fourth and fifth lumbar vertebrae.

extern.ir

chemically. Normally, spinal fluid is clear, with glucose and chlorides present but no protein and very few cells.

Other conditions that can cause meningitis and **encephalitis** (inflammation of the brain) include viral infections, tuberculosis, and syphilis. Viruses that can involve the CNS include the poliovirus; rabies virus; herpes virus; HIV (human immunodeficiency virus); tick- and mosquito-borne viruses, such as West Nile virus; and rarely, viruses that ordinarily cause relatively mild diseases, such as measles and chickenpox. Aseptic meningitis is a benign, nonbacterial form of the disease caused by a virus.

Varicella-zoster virus, which causes chickenpox, is also responsible for **shingles**, a nerve infection. If someone had chickenpox as a child, the latent virus can become reactivated later in life and spread along peripheral nerves, causing an itching, blistering rash. The name *shingles* comes from the Latin word for belt, as the shingles rash is often near or around the waist. A vaccine is now available for people over 60.

NEOPLASMS

Almost all tumors that originate in the nervous system are tumors of nonconducting support cells, the neuroglia. These growths are termed **gliomas** and may be named for the specific cell type involved, such as **astrocytoma**, a tumor of astrocytes, or **neurilemmoma** (schwannoma), a tumor of the cells that make the myelin sheath. Because they tend not to metastasize, these tumors may be described as benign. However, they do harm by compressing brain tissue **(FIG. 7-14)**. The symptoms they cause depend on their size and location. There may be **seizures**, headache, vomiting, muscle weakness, or interference with a special sense, such as vision or hearing. If present, edema and **hydrocephalus**, accumulation of excess CSF in the ventricles, add to the tumor's effects **(FIG. 7-15)**.

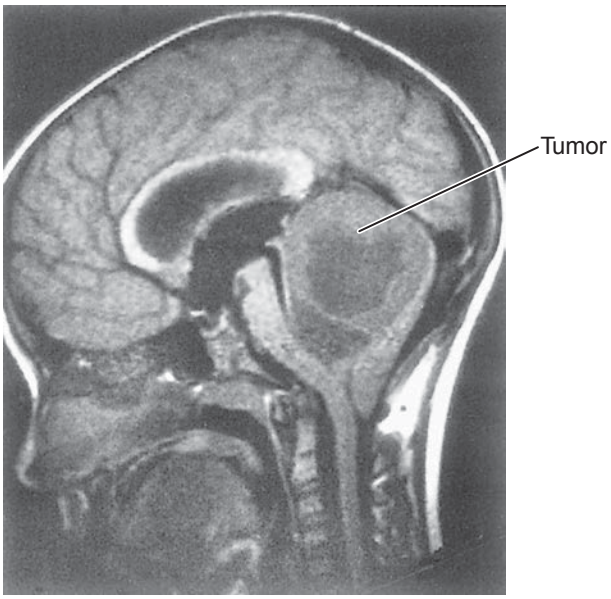

FIGURE 7-14 Brain tumor. MRI shows a large tumor that arises from the cerebellum and pushes the brainstem forward.

FIGURE 7-15 Hydrocephalus. Coronal section of the brain showing marked enlargement of the ventricles caused by a tumor that obstructed the flow of CSF.

A **meningioma** is a tumor of the meninges. Because a meningioma does not spread and is localized at the surface, a surgeon can usually remove it completely.

Tumors of nervous tissue generally occur in childhood and may even originate before birth, when this tissue is actively multiplying. Also, cancer may metastasize to the brain from elsewhere in the body. For unknown reasons, certain forms of cancer, especially melanoma, breast cancer, and lung cancer, tend to spread to the brain.

DEGENERATIVE DISEASES

Multiple sclerosis (**MS**) is an autoimmune disease resulting in the demyelination (loss of the myelin sheath) of CNS axons and eventually neuronal death. In this disease, the immune system mistakenly attacks oligodendrocytes, destroying myelin and often the cells as well. Demyelination slows the speed of nerve impulse conduction and disrupts nervous system communication. Both the spinal cord and the brain can be affected. The symptoms include vision problems, tingling or numbness in the arms and legs, urinary incontinence, **tremor** (shaking), and stiff gait. The advancement of newer drugs helps prevent antibodies from accessing the CNS and causing additional lesions.

Parkinsonism occurs when, for unknown reasons, certain neurons in the midbrain fail to secrete the neurotransmitter dopamine. This leads to tremors, muscle rigidity, flexion at the joints, akinesia (loss of movement), and emotional problems. Parkinsonism is treated with daily administration of the drug **L-dopa** (levodopa), a form of dopamine that the circulation can carry into the brain.

Alzheimer disease (**AD**) results from unexplained degeneration of neurons and atrophy of the cerebral cortex **(FIG. 7-16)**. These changes cause progressive loss of recent memory, confusion, and mood changes. Dangers associated with AD are injury, infection, malnutrition, and aspiration

extern.ir

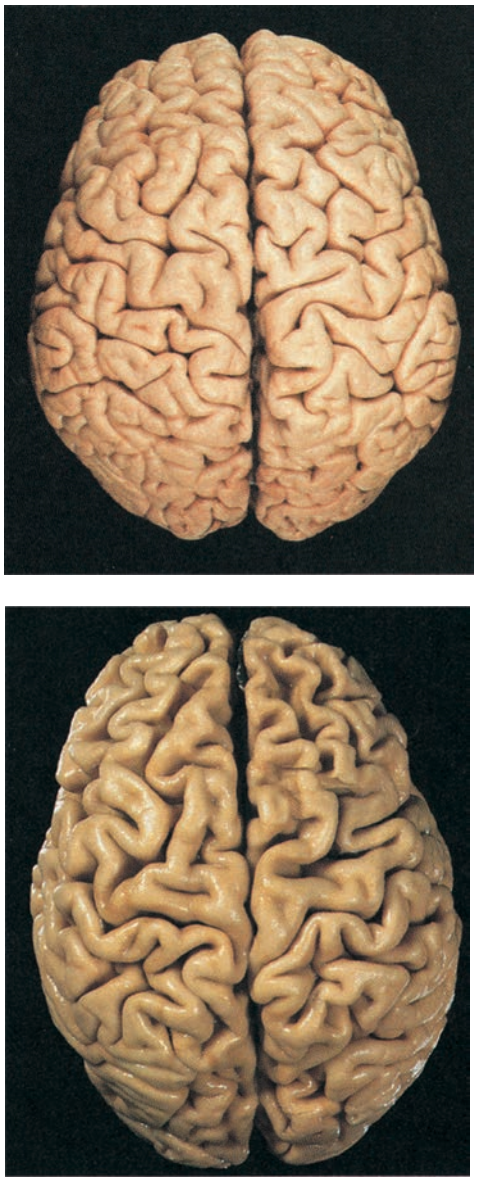

FIGURE 7-16 Effects of Alzheimer disease. A. Normal brain. **B.** Brain of a patient with Alzheimer disease, showing atrophy of the cortex with narrow gyri and enlarged sulci.

of food or fluids into the lungs. Originally called *presenile dementia* and used only to describe cases in patients about 50 years of age, the term is now applied to these same changes when they occur in elderly patients.

AD is diagnosed by CT or MRI scans and confirmed at autopsy. Histologic (tissue) studies show deposits of a substance called **amyloid** in the tissues. The disease may be hereditary. AD commonly develops in people with Down syndrome after age 40, indicating that AD is associated with abnormality on chromosome 21, the same chromosome that is involved in Down syndrome.

Multi-infarct dementia (MID) resembles AD in that it is a progressive cognitive impairment associated with loss of memory, loss of judgment, aphasia, altered motor and sensory function, repetitive behavior, and loss of social skills. The disorder is caused by multiple small strokes that interrupt blood flow to brain tissue and deprive areas of oxygen.

EPILEPSY

A prime characteristic of epilepsy is recurrent seizures brought on by abnormal electric activity of the brain. These attacks may vary from brief and mild episodes known as absence (petit mal) seizures to major tonic–clonic (grand mal) seizures with loss of consciousness, **convulsion** (intervals of violent involuntary muscle contractions), and sensory disturbances. In other cases (psychomotor seizures), there is a 1- to 2-minute period of disorientation. Epilepsy may be the result of a tumor, injury, or neurologic disease, but in most cases, the cause is unknown.

EEG reveals abnormalities in brain activity and can be used in the diagnosis and treatment of epilepsy. The disorder is treated with antiepileptic and anticonvulsive drugs to control seizures, and sometimes surgery is of help. If seizures cannot be controlled, the individual with epilepsy may have to avoid certain activities that can lead to harm.

SLEEP DISTURBANCES

The general term *dyssomnia* includes a variety of possible disorders that result in excessive sleepiness or difficulty in beginning or maintaining sleep. Simple causes for such disorders include schedule changes or travel to different time zones (jet lag). **Insomnia** refers to insufficient or nonrestorative sleep despite ample opportunity to sleep. There may be physical causes for insomnia, but often it is related to emotional upset caused by stressful events. **Narcolepsy** is characterized by brief, uncontrollable attacks of sleep during the day. The disorder is treated with stimulants, regulation of sleep habits, and short daytime naps.

Sleep apnea refers to failure to breathe for brief periods during sleep. It usually results from upper airway obstruction, often associated with obesity, alcohol consumption, or weakened throat muscles, and is usually accompanied by loud snoring with brief periods of silence. Dental appliances that move the tongue and jaw forward may help to prevent sleep apnea. Other options are surgery to correct an obstruction or positive air pressure delivered through a mask.

Sleep disorders are diagnosed by physical examination, a sleep history, and a log of sleep habits, including details of the sleep environment and note of any substances consumed that may interfere with sleep. Study in a sleep laboratory with a variety of electric and other studies, constituting **polysomnography**, may also be needed.

Sleep studies identify two components of normal sleep, each showing a specific EEG pattern. Nonrapid eye movement (NREM) sleep has four stages, which take a person progressively into the deepest level of sleep. If sleepwalking (somnambulism) occurs, it occurs during this stage. NREM sleep is interrupted about every 1.5 hours by episodes of rapid eye movement (REM) sleep, during which the eyes move rapidly, although they are closed. Dreaming occurs during REM sleep and muscles lose tone, while heart rate, blood pressure, and brain activity increase.

extern.ir

HEALTH PROFESSIONS
Careers in Occupational Therapy

BOX 7-2

Occupational therapy (OT) helps people with physical or mental disability achieve independence at home and at work by teaching them "skills for living." Many people can benefit, including those:

- Recovering from traumas such as fractures, amputations, burns, spinal cord injury, stroke, and heart attack
- With chronic conditions such as arthritis, multiple sclerosis, Alzheimer disease, and schizophrenia
- With developmental disabilities such as Down syndrome, cerebral palsy, spina bifida, muscular dystrophy, and autism

OTs work as part of multidisciplinary teams, which include but are not limited to physicians, nurses, physical therapists, speech pathologists, and social workers. OTs also work closely with families to educate and instruct them on how to assist in the client's progress. They assess their clients' capabilities and develop individualized treatment programs that help them recover from injury or compensate for permanent disability. Treatment may include teaching activities ranging from work tasks to dressing, cooking, and eating, and using adaptive equipment such as wheelchairs and computers.

OT assistants implement treatment plans developed by an occupational therapist and regularly consult with the occupational therapist on progress and possible reassessment of goals. To perform their duties, OTs and assistants need a thorough scientific education and clinical background. A current practicing OT in the United States has either a bachelor's or master's degree. As of 2007, OTs must earn a master's degree in OT in order to practice. After graduation, they must pass a national certification examination and, where necessary, be licensed by the state to practice. Assistants typically train in 2-year programs and also take a certification examination.

OTs and their assistants work in hospitals, clinics, and nursing care facilities, and also visit homes and schools. As the population continues to age and the need for rehabilitative therapy increases, job prospects remain good. The American Occupational Therapy Association at aota.org has more information on OT careers.

OTHERS

Many hereditary diseases affect the nervous system. Some of these are described in Chapter 16. Hormonal imbalances that involve the nervous system are described in Chapter 9. Finally, drugs, alcohol, toxins, and nutritional deficiencies may act on the nervous system in a variety of ways.

BOX 7-2 has information on occupational therapists, who are often involved in treating people with neurologic disturbances.

Behavioral Disorders

This section is an introduction to some of the behavioral disorders that involve the nervous system. Criteria for clinical diagnosis of these and other behavioral and mental disorders are set forth in the *Diagnostic and Statistical Manual of Mental Disorders* (DSM) published by the American Psychiatric Association.

ANXIETY DISORDERS

Anxiety is a feeling of fear, worry, uneasiness, or dread. It may be associated with physical problems or drugs and is often prompted by feelings of helplessness or loss of self-esteem. Generalized anxiety disorder (GAD) is characterized by chronic excessive and uncontrollable worry about various life circumstances, often with no basis. It may be accompanied by muscle tensing, restlessness, dyspnea, palpitations, insomnia, irritability, or fatigue.

Panic disorder is a form of anxiety disorder marked by episodes of intense fear. A person with panic disorder may isolate himself or herself or avoid social situations for fear of having a panic attack or in response to attacks.

A **phobia** is an extreme, persistent fear of a specific object or situation (BOX 7-3). It may center on social situations, particular objects, such as animals or blood, or activities, such as flying or driving through tunnels.

FOCUS ON WORDS
Phobias and Manias

BOX 7-3

Some of the terms for phobias and manias are just as strange and interesting as the behaviors themselves.

Agoraphobia is fear of being in a public place. The agora in ancient Greece was the marketplace. Xenophobia is an irrational fear of strangers, taken from the Greek root *xen/o*, which means strange or foreign. Acrophobia, a fear of heights, is taken from the root *acro-*, meaning terminal, highest, or topmost. In most medical terms, this root is used to mean extremity, as in *acrocyanosis*. Hydrophobia is a fear of or aversion to water (*hydr/o*). The term was used as an alternative name for rabies, because people infected with this paralytic disease had difficulty swallowing water and other liquids.

Trichotillomania is the odd practice of compulsively pulling out one's hair in response to stress. The word comes from the root for hair (*trich/o*) plus a Greek word that means "to pull." Kleptomania, also spelled cleptomania, is from the Greek word for thief and describes an irresistible urge to steal in the absence of need.

extern.ir

CLINICAL PERSPECTIVES

BOX 7-4

Psychoactive Drugs: Adjusting Neurotransmitters to Alter Mood

Many psychoactive drugs used today operate by affecting levels and activities of neurotransmitters, such as serotonin, norepinephrine, and dopamine, in the brain. Examples are fluoxetine (Prozac) and related compounds, which are prescribed to alter mood.

Prozac increases serotonin's activity by blocking its reuptake—that is, it blocks transporters that carry serotonin back into the secreting cell at the synapse. Like other selective serotonin reuptake inhibitors (SSRIs), Prozac prolongs the neurotransmitter's activity at the synapse, producing a mood-elevating effect. Prozac is used to treat depression, anxiety, and symptoms of obsessive–compulsive disorder.

Other psychoactive drugs are less selective than Prozac. Venlafaxine (Effexor) blocks reuptake of serotonin and norepinephrine and is used to treat depression and GAD. Bupropion (Zyban) inhibits reuptake of norepinephrine and dopamine and is prescribed for depression and smoking cessation. Another class of antidepressants, the monoamine oxidase inhibitors (MAOIs), prevents an enzyme from breaking down serotonin in the synapse. Like SSRIs, MAOIs increase the amount of serotonin available in the synapse. Examples are phenelzine (Nardil) and tranylcypromine (Parnate).

Some herbal remedies are also used to treat depression. St. John's wort contains the active ingredient hypericin, which appears to both nonselectively inhibit serotonin reuptake and block norepinephrine and dopamine reuptake. As with any drug, care must be taken when using St. John's wort, especially if it is combined with other antidepressant medications, and healthcare providers should always be informed of any drugs, including herbal preparations, that a person is taking.

Obsessive–compulsive disorder (**OCD**) is a condition marked by disturbing thoughts or images that are persistent and intrusive. To relieve anxiety about these thoughts or images, the person with OCD engages in repetitive behavior that interferes with normal daily activities, although he or she knows that such behavior is unreasonable. These patterns include repeated washing; performing rituals; arranging, touching, or counting objects; and repeating words or phrases. OCD is associated with perfectionism and rigidity in behavior. Some specialists believe that OCD is related to low levels of the neurotransmitter serotonin in the brain. Treatment is with behavioral therapy and antidepressant drugs that increase the brain's serotonin levels **(BOX 7-4)**.

When a highly stressful, catastrophic event results in persistent emotional difficulties, the condition is described as **posttraumatic stress disorder** (**PTSD**). People who are abused, have their lives threatened, witness a crime, experience a natural disaster, and combat veterans are subject to PTSD. Responses include anger, fear, sleep disturbances, and physical symptoms, including changes in brain chemistry and hormone imbalances. PTSD is often associated with other emotional problems such as depression, withdrawal, substance abuse, and impaired social and family relationships. Patients need early treatment with emotional support, protection, psychotherapy, and drugs to treat depression and anxiety.

MOOD DISORDERS

Depression is a mental state characterized by profound feelings of sadness, emptiness, hopelessness, inability to concentrate, and lack of interest or pleasure in activities. Depression is often accompanied by insomnia, loss of appetite, and suicidal tendencies, and it frequently coexists with other physical or emotional conditions.

Dysthymia is a chronic mood disorder that lasts for several months to years and is often triggered by a serious event. Depression is a common symptom, as well as eating disorders, sleep disturbances, fatigue, lack of concentration, indecision, and feelings of hopelessness.

In **bipolar disorder** (formerly called manic–depressive illness), normal moods alternate with episodes of depression and **mania**, a state of elation that may include agitation, hyperexcitability, or hyperactivity. Treatment for bipolar disorder may differ from therapy for depression alone and includes mood-stabilizing drugs and professional mental health therapy.

Most of the drugs used to treat mood disorders affect the level of neurotransmitters in the brain, such as the SSRIs, which prolong the action of serotonin.

PSYCHOSIS

Psychosis is a mental state in which there is gross misperception of reality. This loss of touch with reality may be evidenced by **delusions** (false beliefs), including **paranoia**, delusions of persecution or threat, or **hallucinations**, imagined sensory experiences. Although the patient's condition makes it impossible for him or her to cope with the ordinary demands of life, there is lack of awareness that this behavior is inappropriate.

Schizophrenia is a form of chronic psychosis that may include bizarre behavior, paranoia, anxiety, delusions, withdrawal, and suicidal tendencies. The diagnosis of schizophrenia encompasses a broad category of disorders with many subtypes. The causes of schizophrenia are unknown, but there is evidence of hereditary factors and imbalance in brain chemistry.

ATTENTION DEFICIT HYPERACTIVITY DISORDER

Attention deficit hyperactivity disorder (**ADHD**) is difficult to diagnose because many of its symptoms overlap or coexist

extern.ir

with other behavioral disorders. Although inattention and hyperactivity usually appear together in these cases, one component may predominate. ADHD commonly begins in childhood and is characterized by attention problems, easy boredom, impatience, and impulsive behavior. Associated hyperactivity may be manifested by fidgeting, squirming, rapid motion, or excessive talking. In adults, the signs of ADHD may be confused with other disorders, such as mood disturbances, substance abuse, and endocrine problems.

ADHD has been correlated with alterations in brain structure and metabolism. Treatment is with psychotherapy or behavioral therapy and certain drugs. A stimulant, methylphenidate (Ritalin) has traditionally been prescribed for children with ADHD, but more recently, the antidepressant atomoxetine (Strattera) has given positive results.

AUTISM SPECTRUM DISORDER

The term autism spectrum disorder (ASD) applies to a range of impairments that appear early in life and affect social interactions and communication skills. Despite their limitations, a person with ASD may be of normal or above average intelligence, and even brilliant. Each individual with ASD is unique and has his or her own specific needs. All of these conditions fall into a continuum that ranges from classic **autism**, at its most severe, to milder conditions known as high functioning autism, previously called Asperger syndrome, or other forms of developmental disorders.

Autism is a complex disorder of unknown cause that usually appears between the ages of 2 and 6 years as a child fails to reach appropriate developmental signposts. It is marked by self-absorption and lack of response to social contact and affection. Autistic children may have low intelligence and poor language skills. They often appear to be disconnected and out of place. They may overrespond to stimuli and may show self-destructive behavior. There may also be stereotyped (repetitive) behavior, preoccupations, mood swings, and resistance to change. Autism may be accompanied by neurologic problems and problems with sleeping and eating. Those with autism may need the help of mental health specialists; social workers; and occupational, physical, and speech therapists. Levels of autism are determined by the extent of disability and need for support services.

People with less extreme forms of autism are often highly intelligent and verbal, but have trouble with social interactions and understanding others' behaviors. Thus, as children, they are often isolated and bullied. Repetitive behaviors may develop. These children also may develop a strong interest in specific topics. They need help in learning to interpret social cues but often can apply their talents in satisfying occupations.

DRUGS USED IN TREATMENT

A psychotropic or psychoactive drug is one that acts on the mental state. This category of drugs includes antianxiety drugs or anxiolytics, mood stabilizers, antidepressants, and antipsychotics, also called *neuroleptics*. Many of these drugs work by increasing the brain's levels of neurotransmitters. Note that psychoactive drugs do not work in the same way for everyone. It is often necessary to try different therapies until the right drug is found. Also, it may take several weeks for a drug to become effective. For more information, see descriptions and examples of specific types of psychoactive drugs in the supplementary terms.

Terminology *Key Terms*

The terms listed below are emphasized in this chapter. Knowing them will help you organize and prioritize your learning. These boldface terms are also found, collectively, with all chapter key terms in the Glossary.

Neurologic Disorders

Alzheimer disease (AD) *ALTS-hi-mer*	A form of dementia caused by atrophy of the cerebral cortex; presenile dementia (see **FIG. 7-16**)
amyloid *AM-ih-loyd*	A starch-like substance of unknown composition that accumulates in the brain in Alzheimer and other diseases
aneurysm *AN-u-rizm*	A localized abnormal dilation of a blood vessel that results from weakness of the vessel wall (see **FIG. 7-11**), usually of an artery; may eventually burst
aphasia *ah-FA-ze-ah*	Specifically, loss or defect in speech communication (from Greek *phasis*, meaning "speech"); in practice, the term is applied more broadly to a range of language disorders, both spoken and written, that may affect the ability to understand speech (receptive aphasia) or the ability to produce speech (expressive aphasia); both forms are combined in global aphasia
astrocytoma *as-tro-si-TO-mah*	A neuroglial tumor composed of astrocytes
cerebral contusion *kon-TU-zhun*	A bruise to the surface of the brain following a blow to the head

(continued)

extern.ir

Terminology Key Terms (Continued)

cerebrovascular accident (CVA) *ser-eh-bro-VAS-ku-lar*	Sudden damage to the brain resulting from reduction of cerebral blood flow; possible causes are atherosclerosis, thrombosis, or a ruptured aneurysm; commonly called stroke
coma *KO-mah*	State of deep unconsciousness from which one cannot be roused
concussion *kon-KUSH-un*	Injury resulting from a violent blow or shock; a brain concussion usually results in loss of consciousness
confusion *kon-FU-zhun*	A state of reduced comprehension, coherence, and reasoning ability resulting in inappropriate responses to environmental stimuli
contrecoup injury *kon-treh-KU*	Damage to the brain on the side opposite the point of a blow as a result of the brain hitting the skull (from French, meaning "counterblow")
convulsion *kon-VUL-shun*	A series of violent, involuntary muscle contractions; a tonic convulsion involves prolonged muscle contraction; in a clonic convulsion, there is alternation of contraction and relaxation; both forms appear in grand mal epilepsy
dementia *de-MEN-she-ah*	A gradual and usually irreversible loss of intellectual function
embolism *EM-bo-lizm*	Obstruction of a blood vessel by a blood clot or other material carried in the circulation
encephalitis *en-sef-ah-LI-tis*	Inflammation of the brain
epidural hematoma *he-mah-TO-mah*	Accumulation of blood in the epidural space (between the dura mater and the skull) (see **FIG. 7-12**)
epilepsy *EP-ih-lep-se*	A chronic disease involving periodic sudden bursts of electric activity from the brain, resulting in seizures
glioma *gli-O-mah*	A tumor of neuroglial cells
hemiparesis *hem-ih-pah-RE-sis*	Partial paralysis or weakness of one side of the body
hemiplegia *hem-ih-PLE-je-ah*	Paralysis of one side of the body
hydrocephalus *hi-dro-SEF-ah-lus*	Increased accumulation of CSF in or around the brain as a result of obstructed flow; may be caused by tumor, inflammation, hemorrhage, or congenital abnormality (see **FIG. 7-15**)
insomnia *in-SOM-nee-ah*	Insufficient or nonrestorative sleep despite ample opportunity to sleep
meningioma *men-nin-je-O-mah*	Tumor of the meninges
meningitis *men-in-JI-tis*	Inflammation of the meninges
multi-infarct dementia (MID)	Dementia caused by chronic cerebral ischemia (lack of blood supply) as a result of multiple small strokes; there is progressive loss of cognitive function, memory, and judgment as well as altered motor and sensory function
multiple sclerosis (MS)	A chronic, progressive disease involving loss of myelin in the CNS
narcolepsy *NAR-ko-lep-se*	Brief, uncontrollable episodes of sleep during the day
neurilemmoma *nu-rih-lem-O-mah*	A tumor of a peripheral nerve sheath (neurilemma); schwannoma

extern.ir

Terminology Key Terms (Continued)

paralysis *pah-RAL-ih-sis*	Temporary or permanent loss of function; flaccid paralysis involves loss of muscle tone and reflexes and muscular degeneration; spastic paralysis involves excess muscle tone and reflexes but no degeneration
parkinsonism *PAR-kin-son-izm*	A disorder originating in the brain's basal ganglia (nuclei) and characterized by slow movements, tremor, rigidity, and mask-like face; also called Parkinson disease
seizure *SE-zhur*	A sudden attack, as seen in epilepsy; the most common forms of seizure are tonic–clonic, or grand mal (*gran mal*) (from French, meaning "great illness"); absence seizure, or petit mal (*pet-E mal*), meaning "small illness"; and psychomotor seizure
shingles	An acute viral infection that follows nerve pathways causing small lesions on the skin; caused by reactivation of the virus that also causes chickenpox (varicella-zoster virus); also called herpes zoster (*HER-peze ZOS-ter*)
sleep apnea *ap-NE-ah*	Brief periods of breathing cessation during sleep
stroke	Sudden interference with blood flow in one or more cerebral vessels leading to oxygen deprivation and necrosis of brain tissue; caused by a blood clot in a vessel (ischemic stroke) or rupture of a vessel (hemorrhagic stroke); cerebrovascular accident (CVA)
subdural hematoma *sub-DU-ral he-mah-TO-mah*	Accumulation of blood beneath the dura mater (see **FIG. 7-12**)
thrombosis *throm-BO-sis*	Development of a blood clot within a vessel
tremor *TREM-or*	A shaking or involuntary movement
Diagnosis and Treatment	
carotid endarterectomy *end-ar-ter-EK-to-me*	Surgical removal of the lining of the carotid artery, the large artery in the neck that supplies blood to the brain
cerebral angiography *SER-eh-bral an-je-OG-rah-fe*	Radiographic study of the brain's blood vessels after injection of a contrast medium
electroencephalography (EEG) *e-lek-tro-en-sef-ah-LOG-rah-fe*	Amplification, recording, and interpretation of the brain's electric activity
L-dopa *DO-pah*	A drug used in the treatment of parkinsonism; levodopa
lumbar puncture	Puncture of the subarachnoid space in the lumbar region of the spinal cord to remove spinal fluid for diagnosis or to inject anesthesia (see **FIG. 7-13**); spinal tap
polysomnography *pol-e-som-NOG-rah-fe*	Simultaneous monitoring of a variety of physiologic functions during sleep to diagnose sleep disorders
Behavioral Disorders	
anxiety *ang-ZI-eh-te*	A feeling of fear, worry, uneasiness, or dread
attention deficit hyperactivity disorder (ADHD)	A condition that begins in childhood and is characterized by attention problems, easy boredom, impulsive behavior, and hyperactivity
autism *AW-tizm*	A disorder of unknown cause consisting of self-absorption, lack of response to social contact and affection, preoccupations, stereotyped behavior, and resistance to change (from auto-, "self," and -ism, "condition of")
autism spectrum disorder (ASD)	A disability that falls within a range of neurodevelopmental impairments that appears early in life and affects social interactions and communications skills

(continued)

extern.ir

Terminology Key Terms (Continued)

bipolar disorder *bi-PO-lar*	A form of depression with episodes of mania (a state of elation); manic depressive illness
delusion *de-LU-zhun*	A false belief inconsistent with knowledge and experience
depression *de-PRESH-un*	A mental state characterized by profound feelings of sadness, emptiness, hopelessness, and lack of interest or pleasure in activities
dysthymia *dis-THI-me-ah*	A mild form of depression that usually develops in response to a serious life event (from dys- and Greek *thymos*, meaning "mind, emotion")
hallucination *hah-lu-sih-NA-shun*	A false perception unrelated to reality or external stimuli
mania *MA-ne-ah*	A state of elation, which may include agitation, hyperexcitability, or hyperactivity (adjective: manic)
obsessive–compulsive disorder (OCD) *ob-SES-iv kom-PUL-siv*	A condition associated with recurrent and intrusive thoughts, images, and repetitive behaviors performed to relieve anxiety
panic disorder	A form of anxiety disorder marked by episodes of intense fear
paranoia *par-ah-NOY-ah*	A mental state characterized by jealousy, delusions of persecution, or perceptions of threat or harm
phobia *FO-be-ah*	An extreme, persistent fear of a specific object or situation
posttraumatic stress disorder (PTSD)	Persistent emotional disturbances that follow exposure to life-threatening, catastrophic events, such as trauma, abuse, natural disasters, and warfare
psychosis *si-KO-sis*	A mental disorder extreme enough to cause gross misperception of reality with delusions and hallucinations
schizophrenia *skiz-o-FRE-ne-ah*	A poorly understood group of severe mental disorders with features of psychosis, delusions, hallucinations, and withdrawn or bizarre behavior (schizo means "split," and phren/o means "mind")

Terminology Enrichment Terms

The terms listed below expand on the key terms to increase your knowledge of this chapter topic.

Normal Structure and Function

acetylcholine (ACh) *as-e-til-KO-lene*	A neurotransmitter; activity involving acetylcholine is described as cholinergic
basal ganglia	Four masses of gray matter in the cerebrum and upper brainstem that are involved in movement and coordination; basal nuclei
blood–brain barrier	A special membrane between circulating blood and the brain that prevents certain damaging substances from reaching brain tissue
Broca area *BRO-kah*	An area in the left frontal lobe of the cerebrum that controls speech production
cerebral arterial circle	An interconnection (anastomosis) of several arteries supplying the brain; located at the base of the cerebrum; circle of Willis
contralateral *kon-trah-LAT-er-al*	Affecting the opposite side of the body

extern.ir

Terminology Enrichment Terms (Continued)

corpus callosum *KOR-pus kah-LO-sum*	A large band of connecting fibers between the cerebral hemispheres
dermatome *DER-mah-tome*	The area of the skin supplied by a spinal nerve; term also refers to an instrument used to cut skin for grafting (see Chapter 4)
ipsilateral *ip-sih-LAT-er-al*	On the same side; unilateral
leptomeninges *lep-to-men-IN-jeze*	The pia mater and arachnoid together
norepinephrine *nor-ep-ih-NEF-rin*	A neurotransmitter very similar in chemical composition and function to the hormone epinephrine; also called noradrenaline
nucleus *NU-kle-us*	A collection of nerve cells within the central nervous system
plexus *PLEKS-us*	A network, as of nerves or blood vessels
pyramidal tracts *pih-RAM-ih-dal*	A group of motor tracts involved in fine coordination; most of the fibers in these tracts cross in the medulla to the opposite side of the spinal cord and affect the opposite side of the body; fibers not included in the pyramidal tracts are described as extrapyramidal
reticular activating system (RAS) *reh-TIK-u-lar*	A widespread system in the brain that maintains wakefulness
Schwann cells *shvon*	Cells that produce the myelin sheath around peripheral axons
Wernicke area *VER-nih-ke*	An area in the temporal lobe concerned with speech comprehension
Symptoms and Conditions	
amyotrophic lateral sclerosis (ALS) *ah-mi-o-TROF-ik*	A disorder marked by muscular weakness, spasticity, and exaggerated reflexes caused by degeneration of motor neurons; Lou Gehrig disease
amnesia *am-NE-ze-ah*	Loss of memory (from Greek word *mneme* meaning "memory" and the negative prefix *a-*)
apraxia *ah-PRAK-se-ah*	Inability to move with purpose or to use objects properly
ataxia *ah-TAK-se-ah*	Lack of muscle coordination; dyssynergia
athetosis *ath-eh-TO-sis*	Involuntary, slow, twisting movements in the arms, especially the hands and fingers
Bell palsy *PAWL-ze*	Paralysis of the facial nerve
berry aneurysm *AN-u-rizm*	A small sac-like aneurysm of a cerebral artery
catatonia *kat-ah-TO-ne-ah*	A phase of schizophrenia in which the patient is unresponsive; there is a tendency to remain in a fixed position without moving or talking
cerebral palsy *SER-eh-bral PAWL-ze*	A nonprogressive neuromuscular disorder usually caused by damage to the CNS near the time of birth; may include spasticity, involuntary movements, or ataxia
chorea *KOR-e-ah*	A nervous condition marked by involuntary twitching of the limbs or facial muscles

(continued)

extern.ir

Terminology Enrichment Terms (Continued)

claustrophobia *claws-tro-FO-be-ah*	Fear of being shut in or enclosed (from Latin *claudere*, "to shut")
compulsion *kom-PUL-shun*	A repetitive, stereotyped act performed to relieve tension
Creutzfeldt–Jakob disease (CJD) *KROITS-felt YAH-kob*	A slow-growing degenerative brain disease caused by a prion (*PRI-on*), an infectious protein; related to bovine spongiform encephalopathy (BSE, "mad cow disease") in cattle
delirium *de-LIR-e-um*	A sudden and temporary state of confusion marked by excitement, physical restlessness, and incoherence
dysarthria *dis-AR-thre-ah*	Defect in speech articulation caused by lack of control over the required muscles
dysmetria *dis-ME-tre-ah*	Disturbance in the path or placement of a limb during active movement; in hypometria, the limb falls short; in hypermetria, the limb extends beyond the target
euphoria *u-FOR-e-ah*	An exaggerated feeling of well-being; elation
glioblastoma *gli-o-blas-TO-mah*	A malignant astrocytoma
Guillain–Barré syndrome *ge-YAN bar-RA*	An acute polyneuritis with progressive muscular weakness that usually occurs after a viral infection; in most cases recovery is complete, but it may take several months to years
hematomyelia *he-mah-to-mi-E-le-ah*	Hemorrhage of blood into the spinal cord, as from an injury
hemiballism *hem-e-BAL-izm*	Jerking, twitching movements of one side of the body
Huntington disease	A hereditary disease of the CNS that usually appears between ages 30 and 50; the patient shows progressive dementia and chorea, and death occurs within 10 to 15 years
hypochondriasis *hi-po-kon-DRI-ah-sis*	Abnormal anxiety about one's health
ictus *IK-tus*	A blow or sudden attack, such as an epileptic seizure
lethargy *LETH-ar-je*	A state of sluggishness or stupor
migraine *MI-grane*	Chronic intense, throbbing headache that may result from vascular changes in cerebral arteries; possible causes include genetic factors, stress, trauma, and hormonal fluctuations; headache might be signaled by visual disturbances, nausea, photophobia, and tingling sensations
neurofibromatosis *nu-ro-fi-bro-mah-TO-sis*	A condition involving multiple tumors of peripheral nerves
neurosis *nu-RO-sis*	An emotional disorder caused by unresolved conflicts, with anxiety as a main characteristic
paraplegia *par-ah-PLE-je-ah*	Paralysis of the legs and lower part of the body
parasomnia *par-ah-SOM-ne-ah*	Condition of having undesirable phenomena, such as nightmares, occur during sleep or become worse during sleep
quadriplegia *kwah-drih-PLE-je-ah*	Paralysis of all four limbs; tetraplegia

extern.ir

Terminology Enrichment Terms (Continued)

Reye syndrome *ri*	A rare acute encephalopathy occurring in children after viral infections; the liver, kidney, and heart may be involved; linked to administration of aspirin during a viral illness
sciatica *si-AT-ih-kah*	Neuritis characterized by severe pain along the sciatic nerve and its branches
somatoform disorders *so-MAH-to-form*	Conditions associated with symptoms of physical disease, such as pain, hypertension, or chronic fatigue, with no physical basis
somnambulism *som-NAM-bu-lizm*	Walking or performing other motor functions while asleep and out of bed; sleepwalking
stupor *STU-por*	A state of unconsciousness or lethargy with loss of responsiveness
syringomyelia *sir-in-go-mi-E-le-ah*	A progressive disease marked by formation of fluid-filled cavities in the spinal cord
tic *tik*	Involuntary, spasmodic, recurrent, and purposeless motor movements or vocalizations
tic douloureux *tik du-lu-RU*	Episodes of extreme pain in the area supplied by the trigeminal nerve; also called trigeminal neuralgia
tabes dorsalis *TA-bezedor-SAL-is*	Destruction of the dorsal (posterior) portion of the spinal cord with loss of sensation and awareness of body position, as seen in advanced cases of syphilis
Tourette syndrome *tu-RET*	A tic disorder with intermittent motor and vocal manifestations that begins in childhood; there also may be obsessive and compulsive behavior, hyperactivity, and distractibility
transient ischemic attack (TIA) *is-KE-mik*	A sudden, brief, and temporary cerebral dysfunction usually caused by interruption of blood flow to the brain
Wallerian degeneration *wahl-LE-re-an*	Degeneration of a nerve distal to an injury
whiplash	Cervical injury caused by rapid acceleration and deceleration, resulting in damage to muscles, ligaments, disks, and nerves
Additional terms related to neurologic symptoms can be found in Chapters 6 (on the muscular system) and 8 (on the sensory system)	
Diagnosis and Treatment	
Babinski reflex *bah-BIN-ske*	A spreading of the outer toes and extension of the big toe over the others when the sole of the foot is stroked; this response is normal in infants but indicates a lesion of specific motor tracts in adults **(FIG. 7-17)**
evoked potentials	Record of the brain's electric activity after sensory stimulation; included are visual evoked potentials (VEPs), brainstem auditory evoked potentials (BAEPs), and somatosensory evoked potentials (SSEPs), obtained by stimulating the hand or leg; these tests are used to evaluate CNS function
Glasgow Coma Scale	A system for assessing level of consciousness (LOC) by assigning a score to each of three responses: eye opening, motor responses, and verbal responses
positron emission tomography (PET)	Use of radioactive glucose or other metabolically active substance to produce images of biochemical activity in tissues; used for study of the living brain, both healthy and diseased, and also in cardiology; **FIGURE 7-18** compares brain CT, MRI, and PET scans
Romberg sign	Inability to maintain balance when the eyes are shut and the feet are close together
sympathectomy *sim-pah-THEK-to-me*	Interruption of sympathetic nerve transmission either surgically or chemically
trephination *tref-ih-NA-shun*	Cutting a piece of bone out of the skull; the instrument used is a trepan (*tre-PAN*) or trephine (*tre-FIN*)

(continued)

extern.ir

Terminology *Enrichment Terms (Continued)*

Psychoactive Drugs	
antianxiety agent *an-te-ang-ZI-eh-te*	Relieves anxiety by means of a calming, sedative effect on the CNS; examples are chlordiazepoxide (Librium), diazepam (Valium), alprazolam (Xanax); anxiolytic
antidepressant (other than those listed in separate categories below)	Blocks the reuptake of neurotransmitters such as serotonin, norepinephrine, and dopamine, alone or in combination; examples are bupropion (Wellbutrin, Zyban), mirtazapine (Remeron), nefazodone (Serzone), venlafaxine (Effexor XR), atomoxetine (Strattera)
monoamine oxidase inhibitor (MAOI) *mo-no-AH-mene OK-sih-dase*	Blocks an enzyme that breaks down norepinephrine and serotonin, thus prolonging their action; examples are phenelzine (Nardil), tranylcypromine (Parnate), isocarboxazid (Marplan)
neuroleptic *nu-ro-LEP-tik*	Drug used to treat psychosis, including schizophrenia; examples are clozapine (Clozaril), haloperidol (Haldol), risperidone (Risperdal), olanzapine (Zyprexa); antipsychotic; action mechanism unknown, but may interfere with neurotransmitters
selective serotonin reuptake inhibitor (SSRI) *ser-o-TO-nin*	Blocks the reuptake of serotonin in the brain, thus increasing levels; examples are fluoxetine (Prozac), citalopram (Celexa), paroxetine (Paxil), sertraline (Zoloft)
stimulant *STIM-u-lant*	Promotes activity and a sense of well-being; examples are methylphenidate (Ritalin), dextroamphetamine (Dexedrine), amphetamine + dextroamphetamine (Adderall)
tricyclic antidepressant (TCA) *tri-SI-klik*	Blocks the reuptake of norepinephrine, serotonin, or both; examples are amitriptyline (Elavil), clomipramine (Anafranil), imipramine (Tofranil), doxepin (Sinequan), trimipramine (Surmontil)

FIGURE 7-17 Babinski reflex. The big toe bends backward and the other toes spread out when the sole of the foot is stroked. This response is normal in infants but indicates a motor lesion in adults.

extern.ir

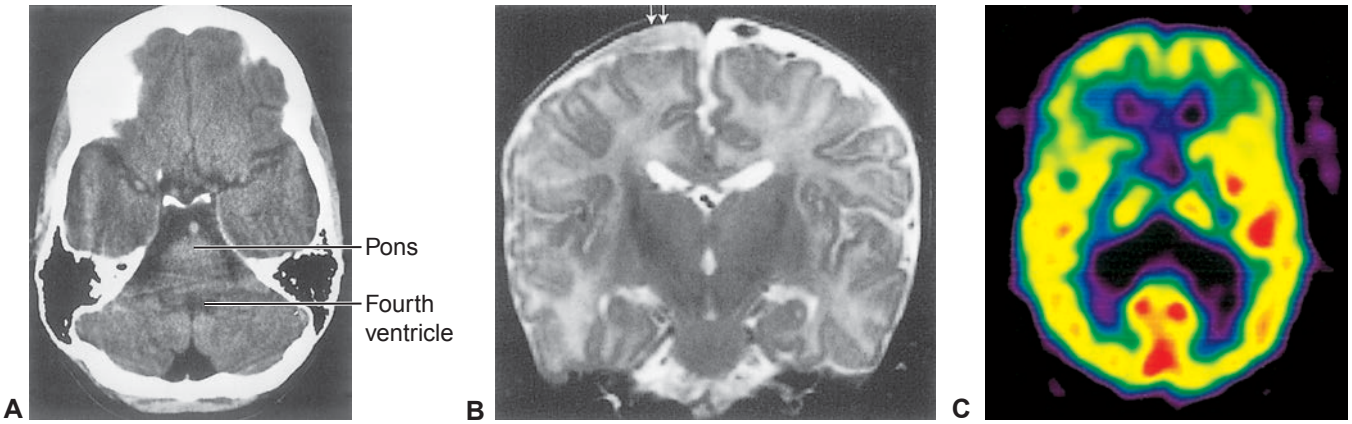

FIGURE 7-18 Brain images. A. CT scan of a normal adult brain. **B.** MRI of the brain showing a subdural hematoma (*arrows*). **C.** PET scan showing regions of different metabolic activity.

Terminology *Abbreviations*

The abbreviations listed below are emphasized in this chapter. These are also found, collectively, with all chapter abbreviations in Appendix 2.

Ach	Acetylcholine
AD	Alzheimer disease
ADHD	Attention deficit hyperactivity disorder
ALS	Amyotrophic lateral sclerosis
ANS	Autonomic nervous system
ASD	Autism spectrum disorder
BAEP	Brainstem auditory evoked potentials
CBF	Cerebral blood flow
CJD	Creutzfeldt–Jakob disease
CNS	Central nervous system
CP	Cerebral palsy
CSF	Cerebrospinal fluid
CTE	Chronic traumatic encephalopathy
CVA	Cerebrovascular accident
CVD	Cerebrovascular disease; also cardiovascular disease
DSM	*Diagnostic and Statistical Manual of Mental Disorders*
DTR	Deep tendon reflexes
EEG	Electroencephalogram; electroencephalograph(y)
GAD	Generalized anxiety disorder
ICP	Intracranial pressure
LMN	Lower motor neuron
LOC	Level of consciousness
LP	Lumbar puncture
MAOI	Monoamine oxidase inhibitor
MID	Multi-infarct dementia
MTBI	Mild traumatic brain injury
MS	Multiple sclerosis
NICU	Neurologic intensive care unit; also neonatal intensive care unit
NPH	Normal pressure hydrocephalus
NREM	Nonrapid eye movement (sleep)
OCD	Obsessive–compulsive disorder
PDD	Pervasive developmental disorder
PET	Positron emission tomography
PNS	Peripheral nervous system
PTSD	Posttraumatic stress disorder
RAS	Reticular activating system
REM	Rapid eye movement (sleep)
SSEP	Somatosensory evoked potentials
SSRI	Selective serotonin reuptake inhibitor
TBI	Traumatic brain injury, thrombotic brain infarction
TCAV	Tricyclic antidepressant
TIA	Transient ischemic attack
UMN	Upper motor neuron
VEP	Visual evoked potentials

extern.ir

Case Study Revisited

William's Therapy

From the hospital, William was transferred to a rehabilitation center for further evaluation and therapy. At this point in his recovery, he was unable to move his legs and had limited movement of his arms. He is participating in a plan of care with physical and OT and is working on performing basic activities of daily living. Within therapy, he is practicing wheelchair functional operations, transfers, and safe propulsions. The goal is to progress toward independence within his home lifestyle and regain status as an active member in his school and community.

Recovery from cervical spine injury can take 3 to 6 months and is easier for some individuals than for others. Because William was active in many sports prior to his injury, his limited mobility in the rehabilitation center was emotionally challenging. In addition to the support and encouragement of his family and many friends, William received psychological counseling to help with his depression and anxiety. After 3 weeks of intense rehabilitation William was able to take small steps and move his shoulders, arms, and fingers. He was discharged home with his parents and after 4 months was able to regain most of his normal functions and participate in moderate activities. After 6 months of recovery, William's surgeon advised him against contact sports, but encouraged him to participate in other sports and pursue a healthy, active lifestyle.

extern.ir

CHAPTER 7

Review

This review tests your understanding of the content introduced in this chapter. Follow the instructions for each exercise and check your answers in Appendix 11.

LABELING EXERCISE

ANATOMIC DIVISIONS OF THE NERVOUS SYSTEM

Write the name of each numbered part on the corresponding line.

Brain
Central nervous system
Cranial nerves
Peripheral nervous system
Spinal cord
Spinal nerves

1. _____
2. _____
3. _____
4. _____
5. _____
6. _____

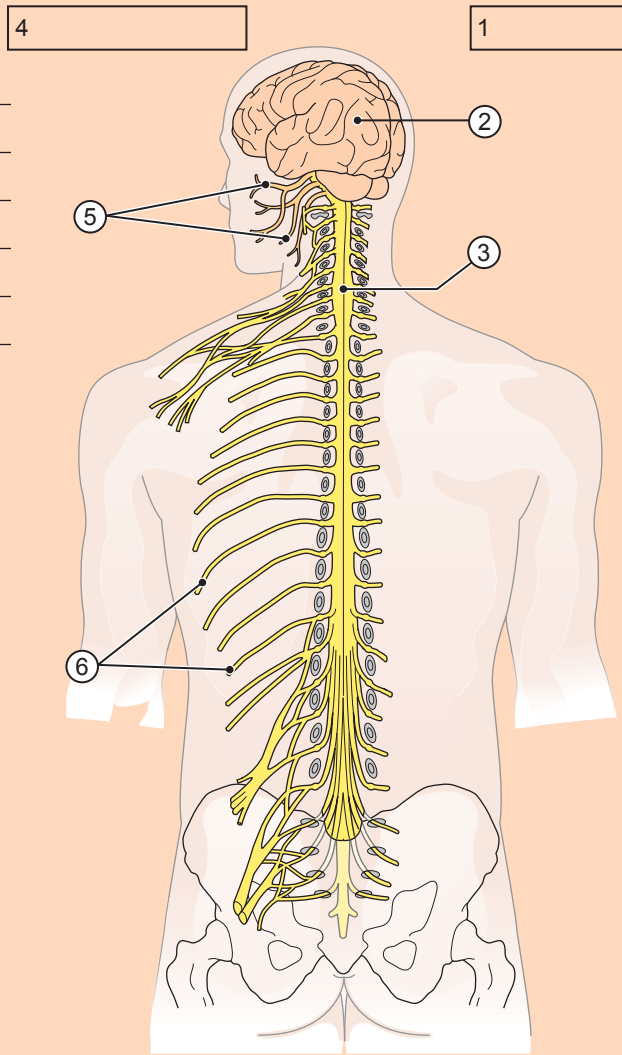

extern.ir

MOTOR NEURON

Write the name of each numbered part on the corresponding line.

Axon branch
Axon covered with myelin sheath
Cell body
Dendrites
Muscle
Myelin
Node
Nucleus

1. _____
2. _____
3. _____
4. _____
5. _____
6. _____
7. _____
8. _____

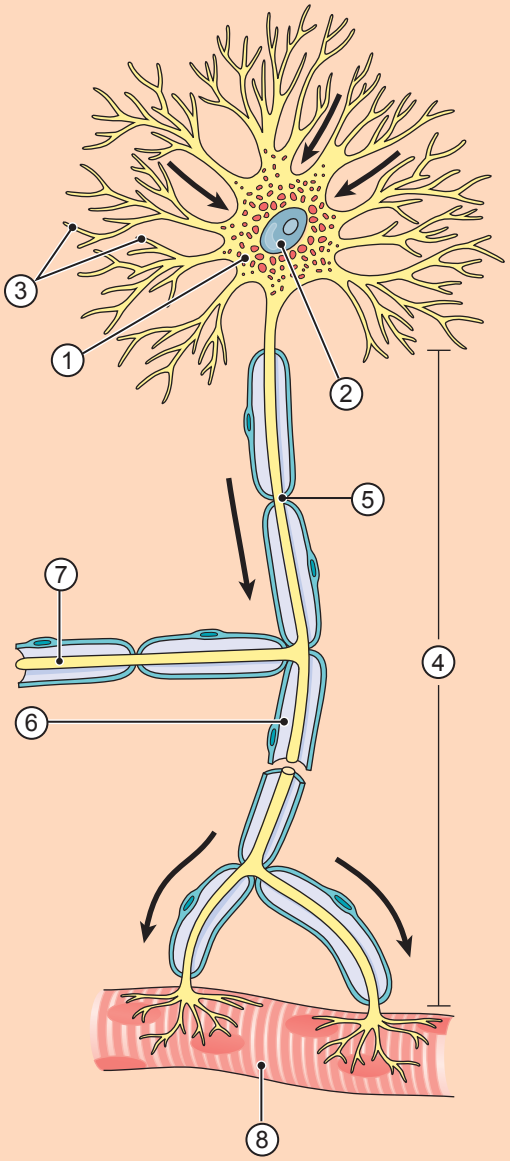

extern.ir

EXTERNAL SURFACE OF THE BRAIN

Write the name of each numbered part on the corresponding line.

Cerebellum
Frontal lobe
Gyri
Medulla oblongata
Occipital lobe
Parietal lobe
Pons
Spinal cord
Sulci
Temporal lobe

1. _____
2. _____
3. _____
4. _____
5. _____
6. _____
7. _____
8. _____
9. _____
10. _____

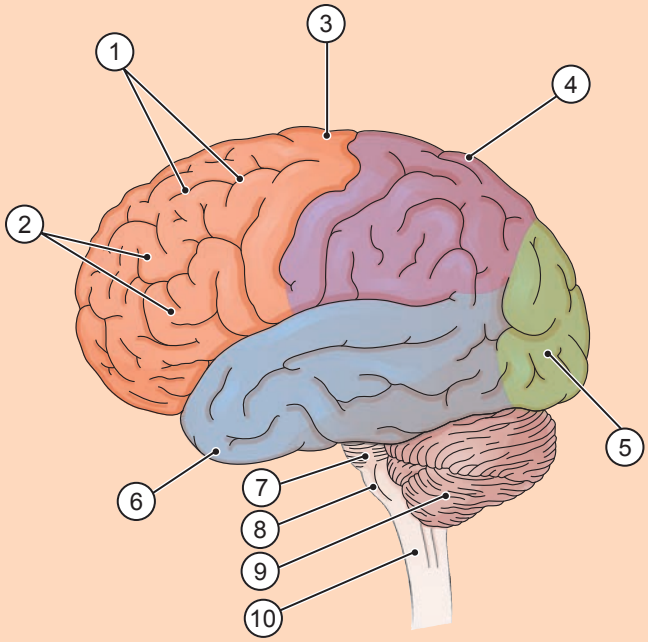

SPINAL CORD, LATERAL VIEW

Write the name of each numbered part on the corresponding line.

Brain
Brainstem
Cervical enlargement
Cervical nerves
Coccygeal nerve
Lumbar enlargement
Lumbar nerves
Sacral nerves
Spinal cord
Thoracic nerves

1. _____
2. _____
3. _____
4. _____
5. _____
6. _____
7. _____
8. _____
9. _____
10. _____

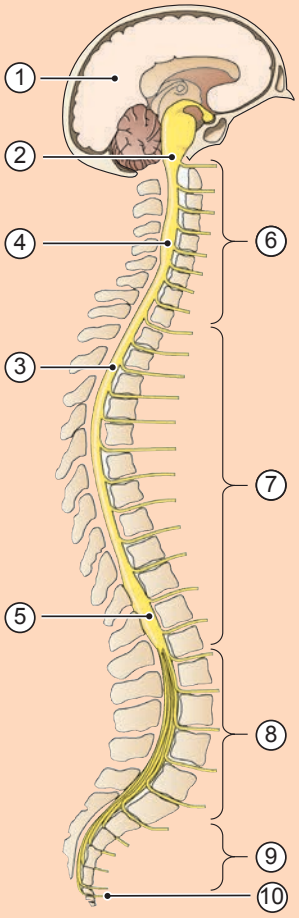

extern.ir

SPINAL CORD, CROSS-SECTION

Write the name of each numbered part on the corresponding line.

Central canal
Dorsal horn
Dorsal root
Dorsal root ganglion
Gray matter
Motor (efferent) signals
Sensory (afferent) signals
Spinal nerve
Ventral horn
Ventral root
White matter

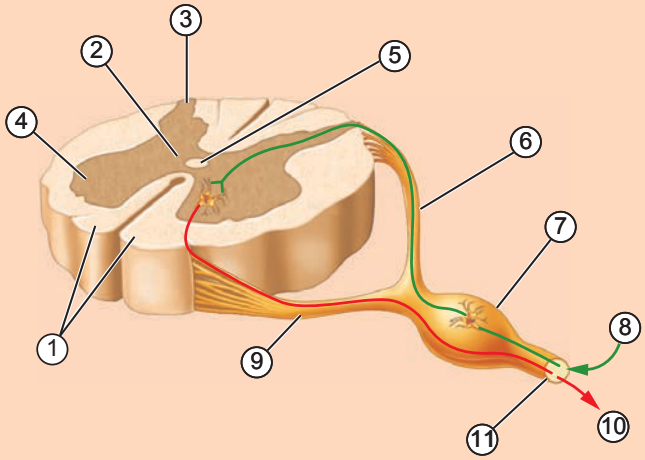

1. _____
2. _____
3. _____
4. _____
5. _____
6. _____
7. _____
8. _____
9. _____
10. _____
11. _____

REFLEX PATHWAY

Write the name of each numbered part on the corresponding line.

Effector
Motor neuron
Receptor
Sensory neuron
Spinal cord (CNS)

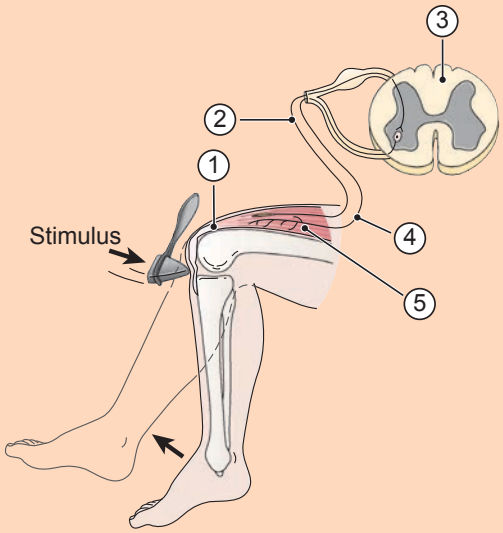

1. _____
2. _____
3. _____
4. _____
5. _____

extern.ir

TERMINOLOGY

MATCHING

Match the following terms, and write the appropriate letter to the left of each number.

____ 1.	dendrite	a. region that connects the brain and spinal cord
____ 2.	medulla oblongata	b. part of the brain that contains the thalamus and pituitary
____ 3.	pons	c. whitish material that covers some axons
____ 4.	myelin	d. rounded area on the ventral surface of the brainstem
____ 5.	diencephalon	e. fiber of a neuron that conducts impulses toward the cell body

____ 6.	contrecoup injury	a. mental disorder associated with delusions of persecution
____ 7.	aphasia	b. excessive fear of pain
____ 8.	hydrocephalus	c. loss of speech communication
____ 9.	paranoia	d. accumulation of CSF in the brain
____ 10.	odynophobia	e. damage to the brain on the side opposite the point of a blow

____ 11.	cystoplegia	a. partial paralysis or weakness
____ 12.	paresis	b. paralysis of the bladder
____ 13.	meningomyelocele	c. series of violent, involuntary muscle contractions
____ 14.	convulsion	d. localized dilation of a blood vessel
____ 15.	aneurysm	e. hernia of the meninges and spinal cord

Enrichment Terms

____ 16.	plexus	a. a sudden blow or attack
____ 17.	ipsilateral	b. a neurotransmitter
____ 18.	dermatome	c. area of skin supplied by a spinal nerve
____ 19.	acetylcholine	d. on the same side; unilateral
____ 20.	ictus	e. network

____ 21.	amnesia	a. fear of being enclosed
____ 22.	euphoria	b. state of sluggishness
____ 23.	claustrophobia	c. loss of memory
____ 24.	ataxia	d. lack of muscle coordination
____ 25.	lethargy	e. sense of elation

____ 26.	REM	a. type of psychoactive drug
____ 27.	SSRI	b. eye movement during sleep
____ 28.	DSM	c. mental disturbances that follow trauma
____ 29.	PTSD	d. procedure to remove fluid from the spinal column
____ 30.	LP	e. reference for diagnosis of mental disorders

extern.ir

FILL IN THE BLANKS

Complete the sentence with the correct term(s).

31. The largest part of the brain is the _____ .
32. The fluid that circulates around the central nervous system is _____ .
33. The support cells of the nervous system are the _____ .
34. The junction between two nerve cells is a(n) _____ .
35. The scientific name for a nerve cell is _____ .
36. The membranes that cover the brain and spinal cord are the _____ .
37. A simple, rapid, automatic response to a stimulus is a(n) _____ .
38. The sympathetic and parasympathetic systems make up the _____ .
39. A chemical that acts at a synapse is a(n) _____ .
40. The posterior portion of the brain that coordinates muscle movement is the _____ .
41. The strong, fibrous, outermost cover of the brain and spinal cord is the _____ .

DEFINITIONS

Define the following words.

42. corticothalamic (*kor-tih-ko-thah-LAM-ik*) _____
43. polyneuritis (*pol-e-nu-RI-tis*) _____
44. anencephaly (*an-en-SEF-ah-le*) _____
45. hemiparesis (*hem-e-pah-RE-sis*) _____
46. radicular (*rah-DIK-u-lar*) _____
47. psychotherapy (*si-ko-THER-ah-pe*) _____
48. panplegia (*pan-PLE-je-ah*) _____
49. encephalomalacia (*en-sef-ah-lo-mah-LA-she-ah*) _____
50. dyssomnia (*dis-SOM-ne-ah*) _____

Write words for the following definitions.

51. study of the nervous system _____
52. inflammation of the meninges and spinal cord _____
53. excision of a ganglion _____
54. any disease of the nervous system _____
55. creation of an opening into a brain ventricle _____
56. paralysis of one side of the body _____
57. within the cerebellum _____
58. difficulty in reading _____
59. fear of water _____
60. paralysis of one limb _____

extern.ir

TRUE–FALSE

Examine the following statements. If the statement is true, write T in the first blank. If the statement is false, write F in the first blank, and correct the statement by replacing the underlined word in the second blank.

	True or False	Correct Answer
61. Sensory fibers conduct impulses toward the CNS.	_____	_____
62. The spinal nerves are part of the central nervous system.	_____	
63. The cervical nerves are in the region of the neck.	_____	_____
64. Myelinated neurons make up the gray matter of the CNS.	_____	
65. CSF forms in the ventricles of the brain.	_____	_____
66. The fiber that carries impulses toward the neuron cell body is the axon.	_____	_____
67. There are 12 pairs of cranial nerves.	_____	_____
68. The innermost layer of the meninges is the pia mater.	_____	_____
69. Hyperlexia refers to increased skill in reading.	_____	_____

OPPOSITES

Write a word that means the opposite of the following words.

70. extramedullary _____
71. ipsilateral _____
72. postganglionic _____
73. tachylalia _____
74. motor _____
75. dorsal _____
76. afferent _____

ADJECTIVES

Write the adjective form of the following words.

77. ganglion _____
78. thalamus _____
79. dura _____
80. meninges _____
81. psychosis _____

PLURALS

Write the plural form of the following words.

82. ganglion _____
83. ventricle _____
84. meninx _____
85. embolus _____

extern.ir

ELIMINATIONS

In each of the sets below, underline the word that does not fit in with the rest, and explain the reason for your choice.

86. CVA — lumbar puncture — embolism — thrombus — TIA

_____

87. glioma — astrocytoma — meningioma — hematoma — neurilemmoma

_____

88. gyri — sulci — mania — ventricles — lobes

_____

89. MID — CNS — ADHD — OCD — GAD

_____

WORD BUILDING

Write a word for the following definitions using the word parts provided. Each word part can be used more than once.

-plegia	myel/o	-a-	-itis	dys-	brady-	my/o	tetra-	-paresis	-phasia	gangli/o	hemi-

90. paralysis of the spinal cord _____
91. lack of speech _____
92. partial paralysis of one side of the body _____
93. muscle weakness _____
94. abnormal or difficult speech production _____
95. paralysis of a ganglion _____
96. paralysis of all four limbs _____
97. inflammation of the spinal cord _____
98. slowness of speech _____
99. paralysis of one side of the body _____
100. inflammation of a ganglion _____

WORD ANALYSIS

Define each of the following words, and give the meaning of the word parts in each. Use a dictionary if necessary.

101. hematomyelia (*he-mah-to-mi-E-le-ah*)
    a. hemat/o _____
    b. myel/o _____
    c. -ia _____
102. myelodysplasia (*mi-eh-lo-dis-PLA-se-ah*)
    a. myel/o _____
    b. dys- _____
    c. plas _____
    d. -ia _____

extern.ir

103. polyneuroradiculitis (*pol-e-nu-ro-rah-dik-u-LI-tis*)

a. poly- _____

b. neur/o _____

c. radicul/o _____

d. -itis _____

104. dyssynergia (*dis-sin-ER-je-ah*)

a. dys- _____

b. syn- _____

c. erg _____

d. -ia _____

extern.ir

Additional Case Studies

Case Study 7-1: Cerebrovascular Accident (CVA)

Allen, a 62 y/o man, was admitted to the ED with right hemiplegia and aphasia. He had a history of hypertension and recent transient ischemic attacks (TIAs), yet was in good health when he experienced a sudden onset of right-sided weakness. He arrived in the ED via ambulance within 15 minutes of onset and was received by a member of the hospital's stroke team. He had a rapid general assessment and neuro examination including a Glasgow Coma Scale (GCS) rating to determine his candidacy for fibrinolytic (clot-dissolving) therapy.

He was sent for a noncontrast CT scan to look for evidence of either hemorrhagic or ischemic stroke, postcardiac arrest ischemia, hypertensive encephalopathy, craniocerebral or cervical trauma, meningitis, encephalitis, brain abscess, tumor, and subdural or epidural hematoma. The CT scan, read by the radiologist, did not show intracerebral or subarachnoid hemorrhage. Allen was diagnosed with probable acute ischemic stroke within 1 hour of the onset of symptoms and was cleared as a candidate for immediate fibrinolytic treatment.

He was admitted to the NICU for 48-hour observation to monitor his neuro status and vital signs. He was discharged after 3 days with a prognosis of full recovery.

Case Study 7-1 Questions

Follow the instructions for each question and check your answers in Appendix 11.

Multiple Choice. *Select the best answer, and write the letter of your choice to the left of each number.*

_____ 1. Ischemic stroke is generally caused by
   a. hemorrhage
   b. hematoma
   c. thrombosis
   d. hemangioma

_____ 2. Fibrinolytic therapy is directed toward
   a. stabilizing blood cells
   b. destroying RBCs
   c. triggering blood clotting
   d. dissolving a blood clot

_____ 3. A general term for any disorder or alteration of brain tissue is
   a. encephalopathy
   b. neurocytoma
   c. dysencephaloma
   d. psychosomatic

Write terms from the case study with the following meanings.

4. pertaining to a lack of blood supply _____
5. inflammation of the meninges _____
6. collection of blood below the dura mater _____
7. inability to speak or understand speech _____
8. partial paralysis on one side _____

Define the following abbreviations.

9. GCS _____
10. CT _____
11. NICU _____
12. CVA _____
13. TIA _____

extern.ir

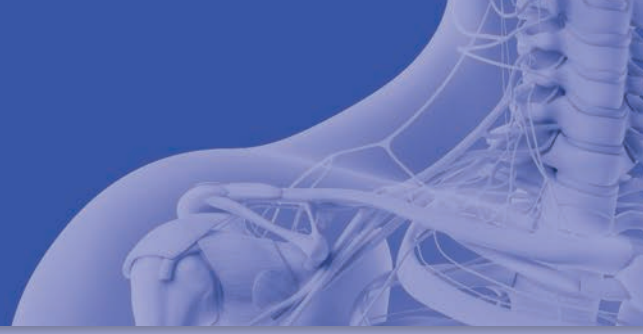

Case Study 7-2: Neuroleptic Malignant Syndrome

Jane, a 21 y/o woman with chronic paranoid schizophrenia, was admitted to the hospital with a diagnosis of pneumonia. She was brought to the ED by her mother, who said Jane had been very lethargic, had a temperature of 104°F, and had had muscular rigidity for 3 days. Her daily medications included Haldol (haloperidol) and Cogentin (benztropine mesylate). Her mother stated that Jane's psychiatrist had changed her neuroleptic medication the week before. Her secondary diagnosis was stated as neuroleptic malignant syndrome, a rare and life-threatening disorder associated with the use of antipsychotic medications. This drug-induced condition is usually characterized by alterations in mental status, temperature regulation, and autonomic and extrapyramidal functions.

Jane was monitored for potential hypotension, tachycardia, diaphoresis, dyspnea, dysphagia, and changes in her LOC. Her medications were discontinued, she was hydrated with IV fluids, and her body temperature was monitored for fluctuations. She was treated with bromocriptine, a dopamine antagonist, and dantrolene, a muscle relaxant and antispasmodic.

After 5 days, Jane was transferred to a mental health facility and restarted on low-dose neuroleptics. She was monitored to prevent a recurrence of the syndrome. Both Jane and her family were educated about neuroleptic malignant syndrome in preparation for her discharge back home in 2 weeks.

Case Study 7-2 Questions

Follow the instructions for each question and check your answers in Appendix 11.

Multiple Choice. *Select the best answer, and write the letter of your choice to the left of each number.*

_____ 1. Jane had disease manifestations related to involuntary functions and to movement controlled by motor fibers outside the pyramidal tracts. These functions are
   a. autonomic and neuroleptic
   b. autonomic and voluntary
   c. extrapyramidal and pyramidal
   d. autonomic and extrapyramidal

_____ 2. Neuroleptic malignant syndrome is associated with the use of
   a. steroids
   b. antipsychotic medications
   c. fibrinolytic therapy
   d. pain medications

Write terms from the case study with the following meanings.

3. describing a state of sluggishness or stupor _____
4. physician who treats psychiatric disorders _____
5. antipsychotic medications _____
6. pertaining to a perceived feeling of threat or harm _____
7. drug that relieves muscle spasms _____
8. profuse sweating _____

extern.ir

CHAPTER 8

Special Senses: Ear and Eye

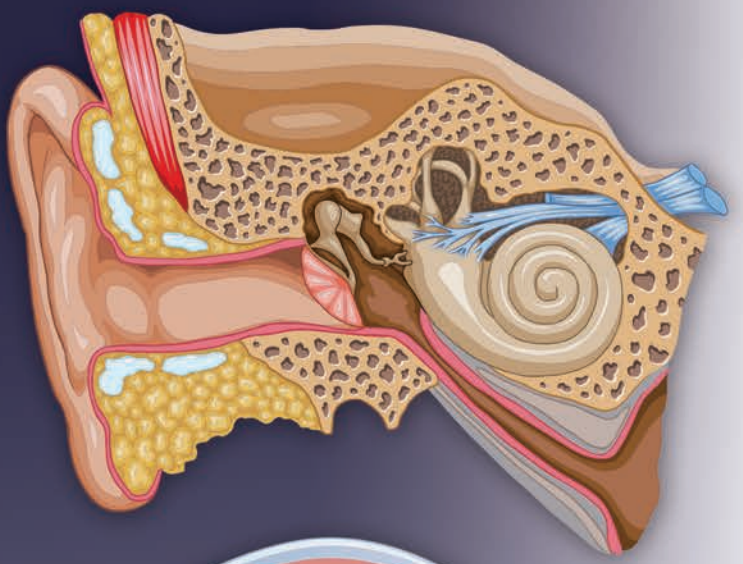

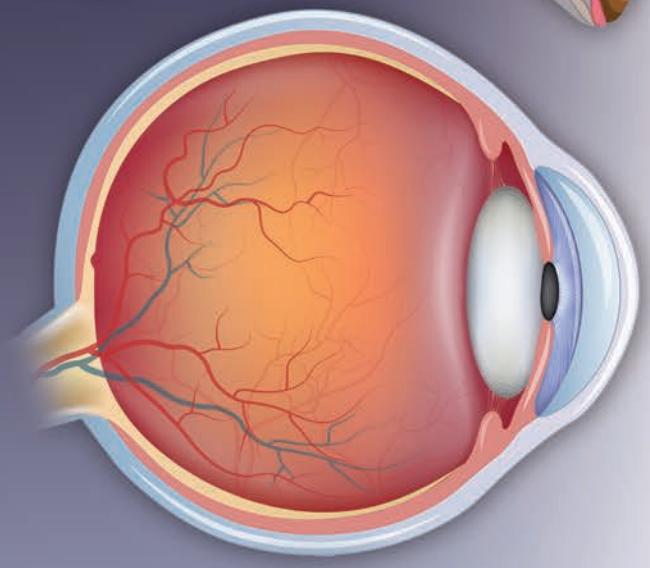

Pretest

Multiple Choice. **Select the best answer, and write the letter of your choice to the left of each number. To check your answers go to Appendix 11.**

_____ 1. The scientific name for the sense of smell is
a. osmosis
b. olfaction
c. gustation
d. dialysis

_____ 2. The term *tactile* refers to the sense of
a. touch
b. taste
c. pain
d. temperature

_____ 3. The two senses located in the ear are
a. hearing and pressure
b. vision and hearing
c. balance and taste
d. hearing and equilibrium

_____ 4. The receptor layer of the eye is the
a. lens
b. cornea
c. retina
d. pinna

_____ 5. The scientific name for the white of the eye is
a. pupil
b. vitreous body
c. sclera
d. conjunctiva

_____ 6. Clouding of the lens is termed
a. vertigo
b. cataract
c. tinnitus
d. glaucoma

_____ 7. The scientific name for the sense of taste is
a. gustation
b. olfaction
c. proprioception
d. osmosis

_____ 8. Acoustic neuroma is a tumor of which cranial nerve sheath?
a. fifth
b. sixth
c. seventh
d. eighth

extern.ir

Learning Objectives

After careful study of this chapter, you should be able to:

1. Explain the role of the sensory system. ***P260***
2. List the parts of the ear and the eye, and briefly describe the function of each structure. ***P261***
3. Describe the pathway of nerve impulses from the ear to the brain. ***P262***
4. Describe the roles of the retina and the optic nerve in vision. ***P270***
5. Identify and use word parts pertaining to the senses. ***P273***
6. Describe the main disorders pertaining to the ear and the eye. ***P273***
7. Interpret abbreviations used in the study of the ear and the eye. ***P282***
8. Analyze medical terms in several case studies pertaining to hearing or vision. ***PP259, 290***

Case Study: Kelly's Amblyopia

Chief Complaint

Kelly, a recently adopted 7 y/o female, was seeing a pediatrician, Dr. McLaren, for the first time. Her new family was concerned that Kelly might have visual problems resulting in self-image and schoolwork issues as one of her eyes appeared to deviate inward. Her physical examination was unremarkable except for the eye examination. Dr. McLaren explained to the parents that Kelly had a condition known as strabismic amblyopia, or a "lazy eye," and made a referral to an ophthalmologist.

Examination

Upon examining Kelly, the ophthalmologist noted that the left eye deviated toward the medial canthus (angle). A complete visual examination was conducted, and the diagnosis was confirmed. Kelly did have amblyopia, in which one eye has lower visual acuity and is used less than the other eye. She also had slight hyperopia, commonly known as farsightedness. A treatment plan was devised and directed toward the development of normal visual acuity. It was discussed with the parents, who decided to move forward with the therapy.

Clinical Course

The ophthalmologist explained to Kelly that they wanted to make her weak eye stronger so she would see much better. This would be accomplished by putting a patch over the strong eye, which should correct the deviation. She would need to wear the patch for a prescribed number of hours each day, and she would also need to wear glasses. She would need to return to see the ophthalmologist so progress could be measured. While Kelly was not sure of the patch, she was excited about wearing glasses since her new mom and sister also wore glasses. She was fitted for glasses and provided with the "bandaid" type of patch to apply over her right eye.

Case Study Revisited: Once you complete this chapter, please review the case follow-up on p. 282.

Ancillaries *At-A-Glance*

Visit the web resource to access the following resources.

Learning Resources

- eBook
- A&P Module with Heart & Lung Sounds
- Image Bank
- TestPrep
- Animations
- Audio Pronunciation Glossary

extern.ir

Introduction

The sensory system is our network for detecting stimuli from the internal and external environments. It is needed to maintain homeostasis, provide us with pleasure, and protect us from harm. Pain, for example, is an important warning sign of tissue damage. The signals generated in the various **sensory receptors** must be transmitted to the central nervous system for interpretation.

The Senses

The senses are divided according to whether they are widely distributed or localized in special sense organs. The receptors for the general senses are found throughout the body. Many are located in the skin **(FIG. 8-1)**. These senses include the following:

- Pain. These receptors are found in the skin and also in muscles, joints, and internal organs.
- Touch, the **tactile** sense, located in the skin. Sensitivity to touch depends on the concentration of these receptors in different areas—high on the fingers, lips, and tongue, for example, but low at the back of the neck or back of the hand.
- Pressure, or deep touch, located beneath the skin and in deeper tissues.
- Temperature. Receptors for heat and cold are located in the skin and also in the hypothalamus, which regulates body temperature.
- **Proprioception**, the awareness of body position. Receptors in muscles, tendons, and joints help to judge body position and coordinate muscle activity. They also help to maintain muscle tone.

The special senses are localized within complex sense organs in the head. These include the following:

- **Gustation** (taste) is located in receptors in taste buds on the tongue. These receptors basically detect only sweet, sour, bitter, salty, and umami (*oo-MOM-e*), a savory flavor triggered by certain amino acids and found in proteins and the flavor enhancer MSG. Researchers have also identified receptors for alkali (bases) and metallic tastes. The senses of smell and taste are chemical senses, that is, they respond to chemicals in solution.
- **Olfaction** (smell) is located in receptors in the nose. Many more chemicals can be discriminated by smell than by taste. Both senses are important in stimulating appetite and warning of harmful substances.

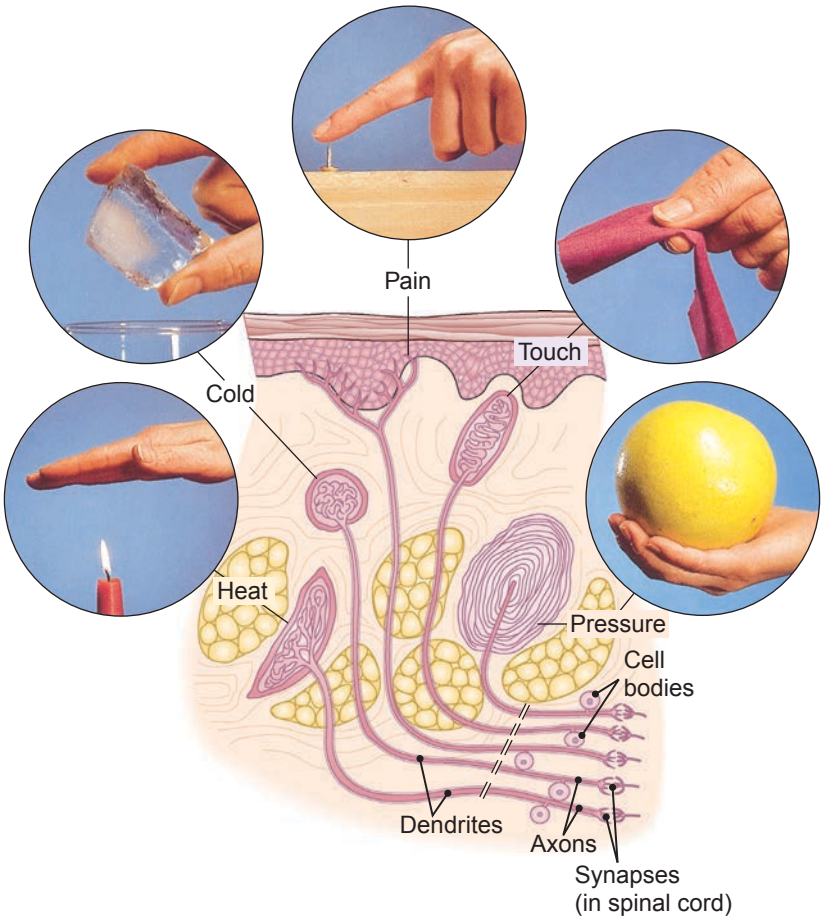

FIGURE 8-1 Receptors for general senses in the skin. Synapses for these pathways are in the spinal cord.

extern.ir

- **Hearing** receptors are located in the ear. These receptors respond to movement created by sound waves as they travel through the ear.
- **Equilibrium** receptors are also located in the ear. These receptors are activated by changes in the position of cells in the inner ear as we move.
- **Vision** receptors are light-sensitive and located deep within the eye, protected by surrounding bone and other support structures. The coordinated actions of external and internal eye muscles help in the formation of a clear image.

Suffixes pertaining to the senses are listed in **TABLE 8-1**. The remainder of this chapter concentrates on hearing and vision, the senses that have received the most clinical attention.

Terminology *Key Terms*

The terms listed below are emphasized in this chapter. Knowing them will help you organize and prioritize your learning. These boldface terms are also found, collectively, with all chapter key terms in the Glossary.

Senses

Normal Structure and Function

equilibrium *e-kwih-LIB-re-um*	The sense of balance
gustation *gus-TA-shun*	The sense of taste (Latin *geusis* means "taste")
hearing *HERE-ing*	The sense or perception of sound
olfaction *ol-FAK-shun*	The sense of smell (root *osm/o* means "smell")
proprioception *pro-pre-o-SEP-shun*	The awareness of posture, movement, and changes in equilibrium; receptors are located in muscles, tendons, and joints
sensory receptor *re-SEP-tor*	A sensory nerve ending or a specialized structure associated with a sensory nerve that responds to a stimulus
tactile *TAK-til*	Pertaining to the sense of touch
vision *VIZH-un*	The sense by which the shape, size, and color of objects are perceived by means of the light they give off

Table 8-1 Suffixes Pertaining to the Senses

Suffix	Meaning	Example	Definition of Example
-esthesia	sensation	cryesthesia *kri-es-THE-ze-ah*	sensitivity to cold
-algesia	pain	hypalgesia[a] *hi-pal-JE-ze-ah*	decreased sensitivity to pain
-osmia	sense of smell	pseudosmia *su-DOS-me-ah*	false sense of smell
-geusia	sense of taste	parageusia *par-ah-GU-ze-ah*	abnormal (para-) sense of taste

[a]Prefix hyp/o.

extern.ir

Exercise 8-1

Complete the exercise. To check your answers go to Appendix 11.

Define the following words.

1. analgesia (*an-al-JE-ze-ah*) _____
2. parosmia (*par-OZ-me-ah*) _____
3. ageusia (*ah-GU-ze-ah*) _____

Write words for the following definitions.

4. muscular (my/o-) sensation _____
5. false sense of taste _____
6. sensitivity to temperature _____
7. excess sensitivity to pain _____
8. abnormal (dys-) sense of taste _____
9. lack (an-) of sensation _____

The Ear

The ear has the receptors for both hearing and equilibrium. For study purposes, it may be divided into three parts: the outer, middle, and inner ear (FIG. 8-2).

The outer ear consists of the projecting **pinna** (auricle) and the **external auditory canal** (meatus). This canal ends at the **tympanic membrane**, or eardrum, which transmits sound waves to the middle ear. Glands in the external canal produce a waxy material, **cerumen**, which protects the ear and helps to prevent infection.

Spanning the middle ear cavity are three **ossicles** (small bones), each named for its shape: the **malleus** (hammer), **incus** (anvil), and **stapes** (stirrup) (see FIG. 8-2). Sound waves

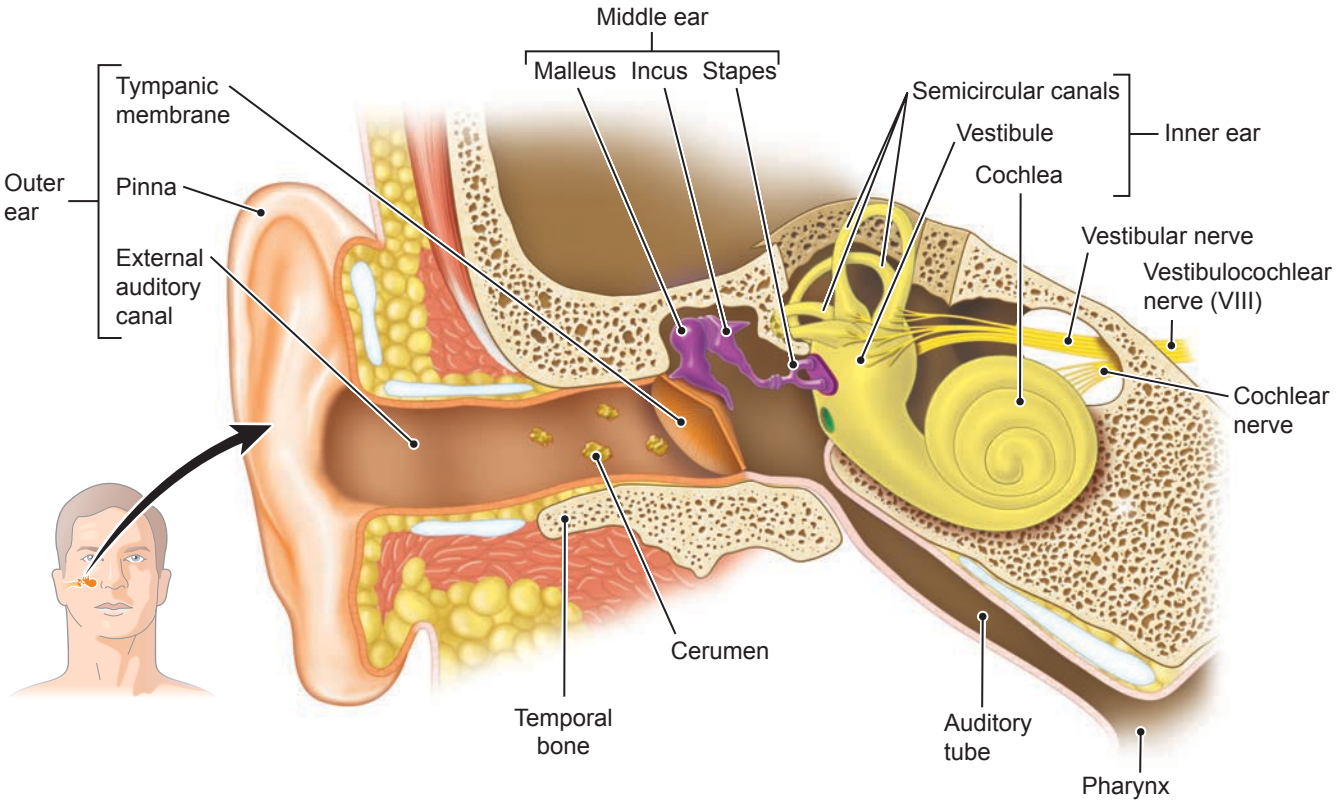

FIGURE 8-2 The ear. Structures in the outer, middle, and inner divisions are shown.

extern.ir

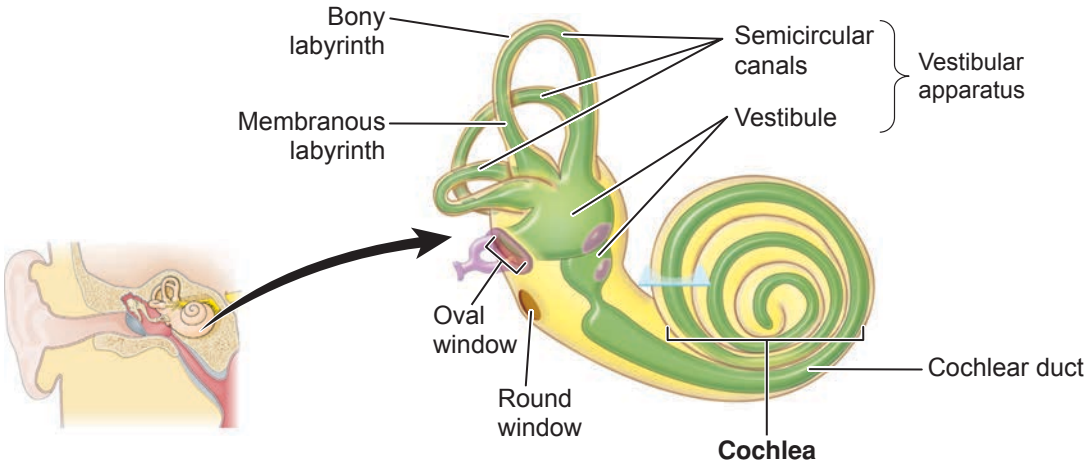

FIGURE 8-3 The inner ear. The outer bony labyrinth contains the membranous labyrinth. Receptors for equilibrium are in the vestibule and the semicircular canals. The cochlea contains the hearing receptor, the spiral organ. Sound waves enter the cochlea through the oval window, travel through the cochlea, and exit through the round window. The inner ear transmits impulses to the brain in the vestibulocochlear nerve (eighth cranial nerve).

traveling over the ossicles are transmitted from the footplate of the stapes to the inner ear. The **auditory tube**, also called the *eustachian tube*, connects the middle ear with the nasopharynx and serves to equalize pressure between the outer ear and the middle ear.

The inner ear, because of its complex shape, is described as a **labyrinth**, which means "maze" (FIG. 8-3). It consists of an outer bony framework containing a similarly shaped membranous channel. The entire labyrinth is filled with fluid.

The **cochlea**, shaped like a snail's shell, has the specialized **spiral organ** (organ of Corti), which is concerned with hearing. Cells in this receptor organ respond to sound waves traveling through the cochlea's fluid-filled ducts. Sound waves enter the cochlea from the base of the stapes through an opening, the oval window, and leave through another opening, the round window (see FIG. 8-3).

The sense of equilibrium is localized in the **vestibular apparatus.** This structure consists of the chamber-like **vestibule** and three projecting **semicircular canals.** Special cells within the vestibular apparatus respond to movement. (The senses of vision and proprioception are also important in maintaining balance.)

Nerve impulses are transmitted from the ear to the brain by way of the **vestibulocochlear nerve**, the eighth cranial nerve, also called the acoustic or auditory nerve. The cochlear branch of this nerve transmits impulses for hearing from the cochlea; the vestibular branch transmits impulses concerned with equilibrium from the vestibular apparatus (see FIG. 8-3). Roots pertaining to the ear and hearing are in TABLE 8-2.

Terminology *Key Terms*

The terms listed below are emphasized in this chapter. Knowing them will help you organize and prioritize your learning. These boldface terms are also found, collectively, with all chapter key terms in the Glossary.

The Ear

Normal Structure and Function

auditory tube *aw-dih-TO-re*	The tube that connects the middle ear with the nasopharynx and serves to equalize pressure between the outer and middle ear (root: salping/o); pharyngotympanic tube; originally called the eustachian (*u-STA-shen*) tube
cerumen *seh-RU-men*	The brownish, wax-like secretion formed in the external ear canal to protect the ear and prevent infection (adjective: ceruminous [*seh-RU-mih-nus*])
cochlea *KOK-le-ah*	The coiled portion of the inner ear that contains the receptors for hearing (root: cochle/o)
external auditory canal *aw-dih-TO-re*	Tube that extends from the pinna of the ear to the tympanic membrane; external auditory meatus

(continued)

extern.ir

Terminology Key Terms (Continued)

incus *ING-kus*	The middle ossicle of the ear
labyrinth *LAB-ih-rinth*	The inner ear, named for its complex structure, which resembles a maze
malleus *MAL-e-us*	The ossicle of the middle ear that is in contact with the tympanic membrane and the incus
ossicles *OS-ih-klz*	The small bones of the middle ear; the malleus, incus, and stapes
pinna *PIN-ah*	The projecting part of the outer ear; auricle (*AW-ri-kl*)
semicircular canals	The three curved channels of the inner ear that hold receptors for equilibrium
spiral organ *SPI-ral*	The hearing receptor, which is located in the cochlea of the inner ear; organ of Corti (*KOR-te*)
stapes *STA-peze*	The ossicle that is in contact with the inner ear (roots: staped/o, stapedi/o)
tympanic membrane *tim-PAN-ik*	The membrane between the external auditory canal and the middle ear (tympanic cavity); the eardrum; it serves to transmit sound waves to the ossicles of the middle ear (roots: myring/o, tympan/o)
vestibular apparatus *ves-TIB-u-lar*	The portion of the inner ear that is concerned with the sense of equilibrium; it consists of the vestibule and the semicircular canals (root: vestibul/o)
vestibule *VES-tih-bule*	The chamber in the inner ear that holds some of the receptors for equilibrium
vestibulocochlear nerve *ves-tib-u-lo-KOK-le-ar*	The nerve that transmits impulses for hearing and equilibrium from the ear to the brain; eighth cranial nerve; auditory or acoustic nerve

Table 8-2 Roots Pertaining to the Ear and Hearing

Root	Meaning	Example	Definition of Example
audi/o	hearing	audiology *aw-de-OL-o-je*	the study of hearing
acous, acus, cus	sound, hearing	acoustic *ah-KU-stik*	pertaining to sound or hearing
ot/o	ear	ototoxic *o-to-TOKS-ik*	poisonous or harmful to the ear
myring/o	tympanic membrane	myringotome *mih-RING-go-tome*	knife used for surgery on the eardrum
tympan/o	tympanic cavity (middle ear), tympanic membrane	tympanometry *tim-pah-NOM-eh-tre*	measurement of transmission through the tympanic membrane and middle ear
salping/o	tube, auditory tube	salpingoscopy *sal-ping-GOS-ko-pe*	endoscopic examination of the auditory tube
staped/o, stapedi/o	stapes	stapedoplasty *sta-pe-do-PLAS-te*	plastic repair of the stapes

extern.ir

Table 8-2 Roots Pertaining to the Ear and Hearing *(Continued)*

Root	Meaning	Example	Definition of Example
labyrinth/o	labyrinth (inner ear)	labyrinthitis *lab-ih-rin-THI-tis*	inflammation of the inner ear (labyrinth)
vestibul/o	vestibule, vestibular apparatus	vestibulotomy *ves-tib-u-LOT-o-me*	incision of the vestibule of the inner ear
cochle/o	cochlea (of inner ear)	retrocochlear *ret-ro-KOK-le-ar*	behind the cochlea

Exercise 8-2

Complete the exercise. To check your answers go to Appendix 11.

Fill in the blanks.

1. Audition (*aw-DISH-un*) is the act of _____ .
2. Hyperacusis (*hi-per-ah-KU-sis*) is abnormally high sensitivity to _____ .
3. Otopathy (*o-TOP-ah-the*) means any disease of the _____ .

Define the following adjectives.

4. stapedial (*sta-PE-de-al*) _____
5. cochlear (*KOK-le-ar*) _____
6. vestibular (*ves-TIB-u-lar*) _____
7. auditory (*AW-dih-tor-e*) _____
8. labyrinthine (*lab-ih-RIN-thene*) _____
9. otic (*O-tik*) _____

Write words for the following definitions.

10. pain in the ear _____
11. incision of the labyrinth _____
12. endoscope for examining the auditory tube _____
13. instrument used to examine the ear _____
14. within the cochlea _____
15. pertaining to the vestibular apparatus and cochlea _____
16. measurement of hearing (audi/o-) _____
17. plastic repair of the middle ear _____
18. excision of the stapes _____

Define the following words.

19. tympanitis (*tim-pah-NI-tis*) _____
20. audiometer (*aw-de-OM-eh-ter*) _____
21. vestibulopathy (*ves-tib-u-LOP-ah-the*) _____
22. salpingopharyngeal (*sal-ping-go-fah-RIN-je-al*) _____
23. myringostapediopexy (*mih-RING-go-sta-pe-de-o-PEK-se*) _____

extern.ir

Clinical Aspects of Hearing

HEARING LOSS

Hearing impairment may result from disease, injury, or developmental problems that affect the ear itself or any nervous pathways concerned with the sense of hearing.

Sensorineural hearing loss results from damage to the inner ear, the eighth cranial nerve, or central auditory pathways. Heredity, toxins, exposure to loud noises, and the aging process are possible causes for this type of hearing loss. It may range from inability to hear certain sound frequencies to a complete loss of hearing (deafness). People with extreme hearing loss that originates in the inner ear may benefit from a cochlear implant. This prosthesis stimulates the cochlear nerve directly, bypassing the receptor cells of the inner ear, and may allow the recipient to hear medium to loud sounds.

Conductive hearing loss results from blockage in sound transmission to the inner ear. Causes include obstruction, severe infection, or fixation of the middle ear ossicles. Often, physicians can successfully treat the conditions that cause conductive hearing loss.

BOX 8-1 has information on careers in audiology, the study, and treatment of hearing disorders.

OTITIS

Otitis is any inflammation of the ear. **Otitis media** refers to an infection that leads to fluid accumulation in the middle ear cavity. One cause is malfunction or obstruction of the auditory tube, as by allergy, enlarged adenoids, injury, or congenital abnormalities. Another cause is infection that spreads to the middle ear, most commonly from the upper respiratory tract. Continued infection may lead to accumulation of pus and perforation of the eardrum. Otitis media usually affects children under 5 years of age and may result in hearing loss. If not treated with antibiotics, the infection may spread to other regions of the ear and head. An incision, a **myringotomy**, and placement of a tube in the tympanic membrane helps to ventilate and drain the middle ear cavity in cases of otitis media.

Otitis externa is inflammation of the external auditory canal caused by repeated fungal or bacterial infections. It is most common among those living in hot climates and among swimmers, leading to the alternative name, "swimmer's ear."

OTOSCLEROSIS

In **otosclerosis**, the bony structure of the inner ear deteriorates and then reforms into spongy bone tissue that may eventually harden. Most commonly, the stapes becomes fixed against the inner ear and is unable to vibrate, resulting in conductive hearing loss. The cause of otosclerosis is unknown, but some cases are hereditary. Surgeons usually can remove the damaged bone. In a **stapedectomy**, the stapes is removed, and a prosthetic bone is inserted.

MÉNIÈRE DISEASE

Ménière disease is a disorder that affects the inner ear. It seems to involve production and circulation of the fluid that fills the inner ear, but the cause is unknown. The symptoms include **vertigo** (dizziness), hearing loss, **tinnitus** (ringing in the ears), and a feeling of pressure in the ear. The course of the disease is uneven, and symptoms may become less severe with time. Ménière disease is treated with drugs to control nausea and dizziness, such as those used to treat motion sickness. In severe cases, the inner ear or part of the eighth cranial nerve may be surgically destroyed.

ACOUSTIC NEUROMA

An **acoustic neuroma** (also called schwannoma or neurilemmoma) is a tumor that arises from the neurilemma (sheath) of the eighth cranial nerve. As the tumor enlarges, it presses on surrounding nerves and interferes with blood supply. This leads to tinnitus, dizziness, and progressive hearing loss. Other symptoms develop as the tumor presses on the brainstem and other cranial nerves. Usually, it is necessary to remove the tumor surgically.

HEALTH PROFESSIONS — BOX 8-1

Audiologists

Audiologists specialize in preventing, diagnosing, and treating hearing disorders that may be caused by injury, infection, birth defects, noise, or aging. They take a complete patient history to diagnose hearing disorders and use specialized equipment to measure hearing acuity. Audiologists design and implement individualized treatment plans, which may include fitting clients with assistive listening devices, such as hearing aids, or teaching alternative communication skills, such as lip reading. Audiologists also measure workplace and community noise levels and teach the public how to prevent hearing loss. Whereas in the past, audiologists had to have a master's degree, a doctoral degree is becoming more commonly the entry degree required for licensure in the United States. All 50 states require practicing audiologists to pass a national licensing exam and be registered or licensed. In some states, audiologists who dispense hearing aids must have a hearing aid dispenser license, which is separate from their license to practice audiology.

Audiologists work in a variety of settings, such as hospitals, nursing care facilities, schools, clinics, and industry. Job prospects are good, as the need for audiologists' specialized skills will increase as populations age. The American Academy of Audiology at audiology.org has more information on this career.

extern.ir

Terminology *Key Terms*

The terms listed below are emphasized in this chapter. Knowing them will help you organize and prioritize your learning. These boldface terms are also found, collectively, with all chapter key terms in the Glossary.

The Ear

Disorders

acoustic neuroma *ah-KU-stik nu-RO-mah*	A tumor of the eighth cranial nerve sheath; although benign, it can press on surrounding tissue and produce symptoms; also called an acoustic or vestibular schwannoma or acoustic neurilemmoma
conductive hearing loss	Hearing impairment that results from blockage of sound transmission to the inner ear
Ménière disease *men-NYARE*	A disease associated with increased fluid pressure in the inner ear and characterized by hearing loss, vertigo, and tinnitus
otitis externa *o-TI-tis ex-TER-nah*	Inflammation of the external auditory canal; swimmer's ear
otitis media *o-TI-tis ME-de-ah*	Inflammation of the middle ear with accumulation of serous (watery) or mucoid fluid
otosclerosis *o-to-skleh-RO-sis*	Formation of abnormal and sometimes hardened bony tissue in the ear; it usually occurs around the oval window and the footplate (base) of the stapes, causing immobilization of the stapes and progressive hearing loss
sensorineural hearing loss *sen-so-re-NU-ral*	Hearing impairment that results from damage to the inner ear, eighth cranial nerve, or auditory pathways in the brain
tinnitus *TIN-ih-tus*	A sensation of noises, such as ringing or tinkling, in the ear; also pronounced *tih-NI-tus*
vertigo *VER-tih-go*	An illusion of movement, as of the body moving in space or the environment moving about the body; usually caused by disturbances in the vestibular apparatus; used loosely to mean dizziness or lightheadedness

Treatment

myringotomy *mir-in-GOT-o-me*	Surgical incision of the tympanic membrane; performed to drain the middle ear cavity or to insert a tube into the tympanic membrane for drainage
stapedectomy *sta-pe-DEK-to-me*	Surgical removal of the stapes; it may be combined with insertion of a prosthesis to correct otosclerosis

Terminology *Enrichment Terms*

The terms listed below expand on the key terms to increase your knowledge of this chapter topic.

Normal Structure and Function

aural *AW-ral*	Pertaining to or perceived by the ear
decibel (dB) *DES-ih-bel*	A unit for measuring the relative intensity of sound
hertz (Hz)	A unit for measuring the frequency (pitch) of sound
mastoid process	A small projection of the temporal bone behind the external auditory canal; it consists of loosely arranged bony material and small, air-filled cavities
stapedius *sta-PE-de-us*	A small muscle attached to the stapes; it contracts in the presence of a loud sound, producing the acoustic reflex

Symptoms and Conditions

cholesteatoma *ko-les-te-ah-TO-mah*	A cyst-like mass containing cholesterol that is most common in the middle ear and mastoid region; a possible complication of chronic middle ear infection

(continued)

extern.ir

Terminology — *Enrichment Terms (Continued)*

labyrinthitis *lab-ih-rin-THI-tis*	Inflammation of the ear's labyrinth (inner ear); otitis interna
mastoiditis *mas-toyd-I-tis*	Inflammation of the air cells of the mastoid process
presbyacusis *prez-be-ah-KU-sis*	Loss of hearing caused by aging
Diagnosis and Treatment	
audiometry *aw-de-OM-eh-tre*	Measurement of hearing
electronystagmography (ENG) *e-lek-tro-nis-tag-MOG-rah-fe*	A method for recording eye movements by means of electrical responses; such movements may reflect vestibular dysfunction
otorhinolaryngology (ORL) *o-to-ri-no-lar-in-GOL-o-je*	The branch of medicine that deals with diseases of the ear(s), nose, and throat (ENT); also called otolaryngology (OL)
otoscope *O-to-skope*	Instrument for examining the ear (see **FIG. 3-11B**)
Rinne test *RIN-ne*	Test that measures hearing by comparing results of bone conduction and air conduction **(FIG. 8-4)**; bone conduction is tested through the mastoid process behind the ear
spondee *spon-de*	A two-syllable word with equal stress on each syllable; used in hearing tests; examples are toothbrush, baseball, cowboy, pancake
Weber test	Test for hearing loss that uses a vibrating tuning fork placed at the center of the head **(FIG. 8-5)**

FIGURE 8-4 The Rinne test. This test assesses both bone and air conduction of sound. **A.** Test of bone conduction through the mastoid process behind the ear. **B.** Test of air conduction.

FIGURE 8-5 The Weber test. This test assesses bone conduction of sound.

extern.ir

Terminology *Abbreviations*

The abbreviations listed below are emphasized in this chapter. These are also found, collectively, with all chapter abbreviations in Appendix 2.

The Ear

ABR	Auditory brainstem response	**Hz**	Hertz
AC	Air conduction	**OL**	Otolaryngology
BAEP	Brainstem auditory evoked potentials	**OM**	Otitis media
BC	Bone conduction	**ORL**	Otorhinolaryngology
dB	Decibel	**ST**	Speech threshold
ENG	Electronystagmography	**TM**	Tympanic membrane
ENT	Ear(s), nose, and throat	**TTS**	Temporary threshold shift
HL	Hearing level		

The Eye and Vision

The eye is protected by its position within a bony socket or **orbit.** It is also protected by the eyelids, or **palpebrae;** eyebrows; and eyelashes (FIG. 8-6). The **lacrimal** (tear) **glands** constantly bathe and cleanse the eyes with a lubricating fluid that drains into the nose. The protective **conjunctiva** is a thin membrane that lines the eyelids and covers the anterior portion of the eye. This membrane folds back to form a narrow space between the eyeball and the eyelids. Medications, such as eye drops and eye ointments, can be instilled into this conjunctival sac.

The wall of the eye is composed of three layers (FIG. 8-7). Named from outermost to innermost, they are as follows:

1. The **sclera,** commonly called the *white of the eye*, is the tough surface protective layer. The sclera extends over the eye's anterior portion as the transparent **cornea.**
2. The **uvea** is the middle layer, which consists of the:
   - **Choroid,** a vascular and pigmented layer located in the posterior portion of the eyeball. The choroid provides nourishment for the retina.

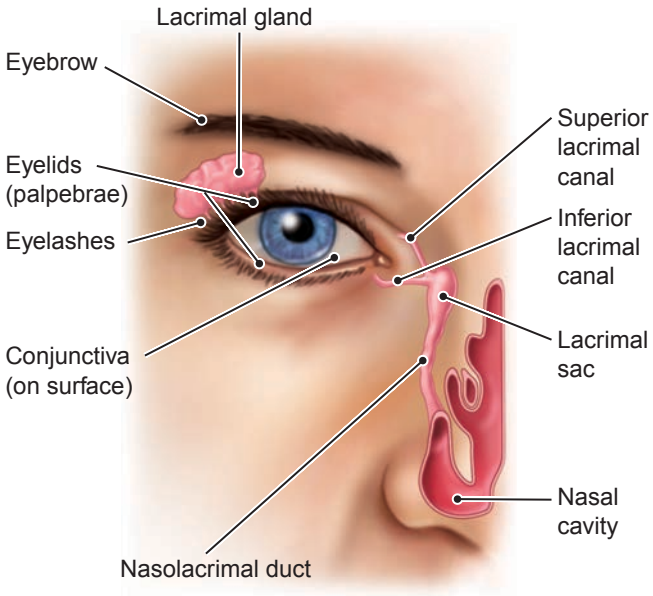

FIGURE 8-6 The eye's protective structures. The lacrimal gland produces tears that flow across the eye and drain into the lacrimal canals.

extern.ir

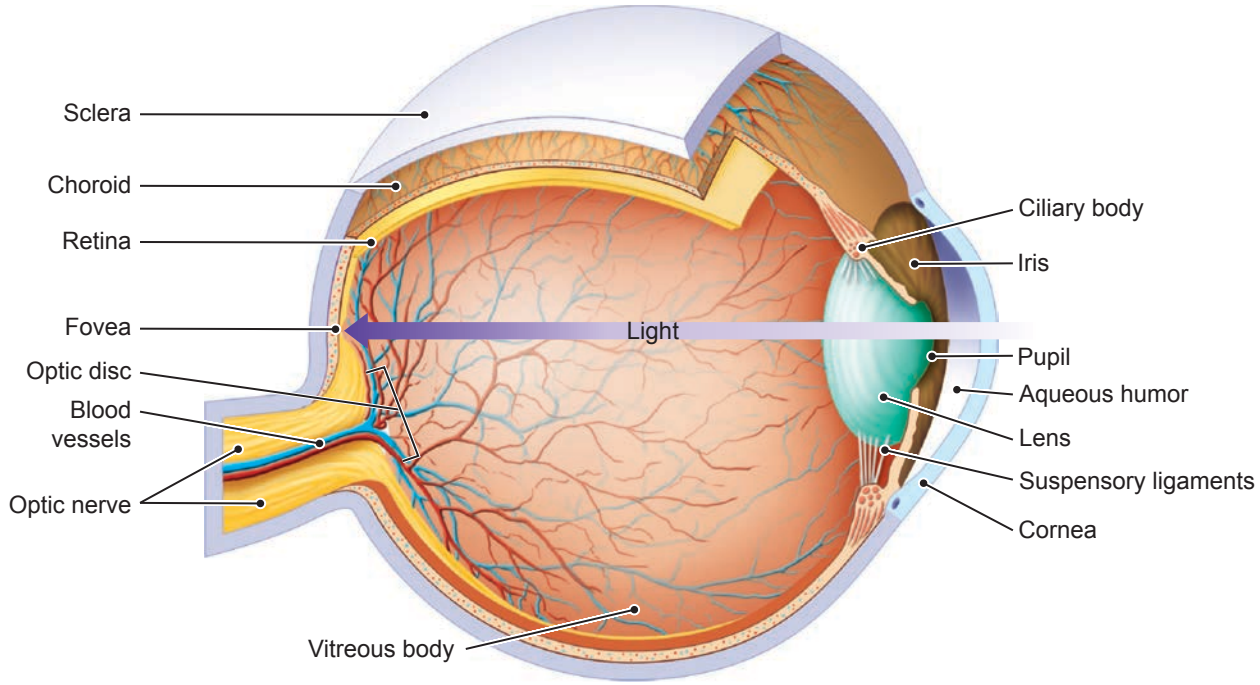

FIGURE 8-7 The eye. The three layers of the eyeball are shown along with other structures involved in vision.

- **Ciliary body**, which contains a muscle that controls the shape of the **lens** to allow for near and far vision, a process known as **accommodation** (FIG. 8-8). The lens must become more rounded for viewing close objects.
- **Iris**, a muscular ring that controls the size of the **pupil**, thus regulating the amount of light that enters the eye (FIG. 8-9). The genetically controlled pigments of the iris determine eye color.

3. The **retina** is the innermost layer and the actual visual receptor. It consists of two types of specialized cells that respond to light:
   - The **rods** function in dim light, provide low **visual acuity** (sharpness), and do not respond to color.
   - The **cones** are active in bright light, have high visual acuity, and respond to color.

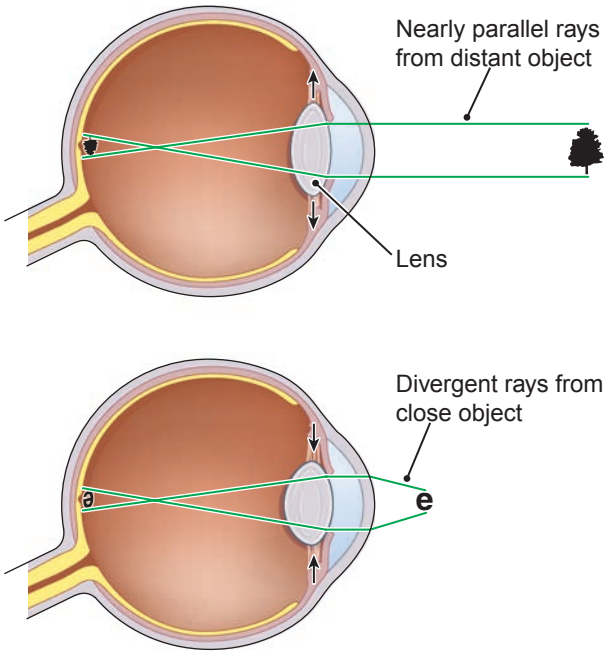

FIGURE 8-8 Accommodation for near vision. When viewing a close object, the lens must become more rounded to focus light rays on the retina.

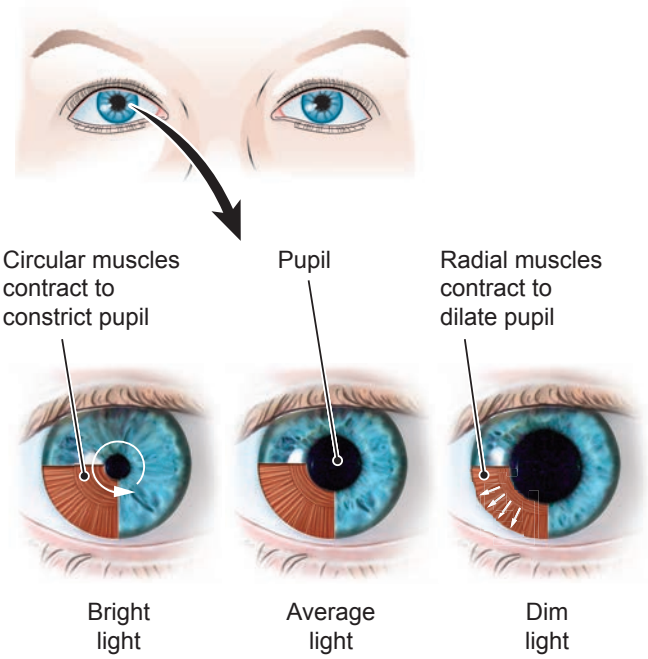

FIGURE 8-9 Function of the iris. In bright light, muscles in the iris constrict the pupil, limiting the light that enters the eye. In dim light, the iris dilates the pupil to allow more light to enter the eye.

extern.ir

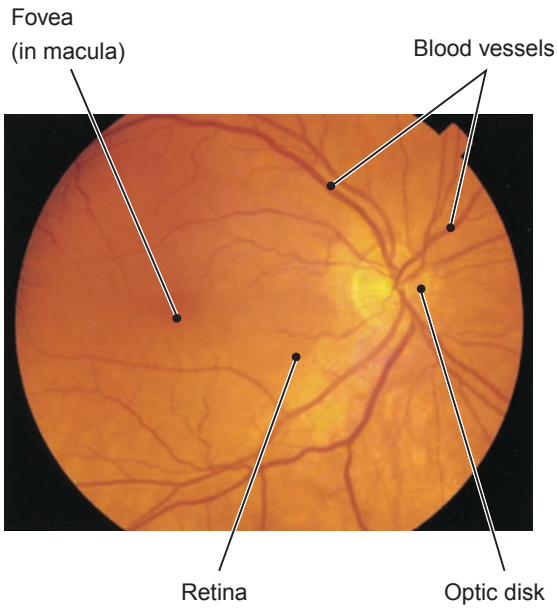

FIGURE 8-10 The fundus (back) of the eye as seen through an ophthalmoscope. The optic disk (blind spot) is shown as well as the fovea, the point of sharpest vision, in the retina.

Proper vision requires the **refraction** (bending) of light rays as they pass through the eye to focus on a specific point on the retina. The impulses generated within the rods and cones are transmitted to the brain by way of the optic nerve (second cranial nerve). Where the optic nerve connects to the retina, there are no rods or cones. This point, at which there is no visual perception, is called the **optic disk**, or *blind spot* (see **FIG. 8-7**). The **fovea** is a tiny depression in the retina near the optic nerve that has a high concentration of cones and is the point of greatest visual acuity. The fovea is surrounded by a yellowish spot called the **macula** **(FIG. 8-10)**.

The eyeball is filled with a jelly-like **vitreous body** (see **FIG. 8-7**), which helps maintain the shape of the eye and also refracts light. The **aqueous humor** is the fluid that fills the eye anterior to the lens, maintaining the cornea's shape and refracting light. This fluid is constantly produced and drained from the eye.

Six muscles attached to the outside of each eye coordinate eye movements to achieve **convergence**, that is, coordinated movement of the eyes so that they both are fixed on the same point.

BOX 8-2 explores the Greek origins of some medical words, including some pertaining to the eye.

FOCUS ON WORDS
The Greek Influence

BOX 8-2

Some of our most beautiful (and difficult to spell and pronounce) words come from Greek. *Esthesi/o* means "sensation." It appears in the word *anesthesia*, a state in which there is lack of sensation, particularly pain. It is found in the word *esthetics* (also spelled aesthetics), which pertains to beauty, artistry, and appearance. The prefix *presby*, in the terms *presbycusis* and *presbyopia*, means "old," and these conditions appear with aging. The root *cycl/o*, pertaining to the ring-like ciliary body of the eye, is from the Greek word for circle or wheel. The same root appears in the words *bicycle* and *tricycle.* Also pertaining to the eye, the term *iris* means "rainbow" in Greek, and the iris is the colored part of the eye.

The root *-sthen/o* means "strength" and occurs in the words *asthenia*, meaning lack of strength, or weakness, and *neurasthenia*, an old term for vague "nervous exhaustion" now applied to conditions involving chronic symptoms of generalized fatigue, anxiety, and pain. The root also appears in the word *calisthenics* in combination with the root *cali-*, meaning "beauty." So the rhythmic strengthening and conditioning exercises that are done in calisthenics literally give us beauty through strength.

The Greek root *steth/o* means "chest," although a stethoscope is used to listen to sounds in other parts of the body as well as the chest.

Asphyxia is derived from the Greek root *sphygm/o* meaning "pulse." The word is literally "stoppage of the pulse," which is exactly what happens when one suffocates. This same root is found in *sphygmomanometer*, the apparatus used to measure blood pressure. One look at the word and one attempt to pronounce it makes it clear why most people call the device a blood pressure cuff!

extern.ir

Terminology Key Terms

The terms listed below are emphasized in this chapter. Knowing them will help you organize and prioritize your learning. These boldface terms are also found, collectively, with all chapter key terms in the Glossary.

The Eye

Normal Structure and Function

accommodation *ah-kom-o-DA-shun*	Adjustment of the lens's curvature to allow for vision at various distances
aqueous humor *AK-we-us*	Fluid that fills the eye anterior to the lens
choroid *KOR-oyd*	The dark, vascular, middle layer of the eye (roots: chori/o, choroid/o); part of the uvea (see below)
ciliary body *SIL-e-ar-e*	The muscular portion of the uvea that surrounds the lens and adjusts its shape for near and far vision (root: cycl/o)
cone	A specialized cell in the retina that responds to light; cones have high visual acuity, function in bright light, and respond to colors
conjunctiva *kon-junk-TI-vah*	The mucous membrane that lines the eyelids and covers the eyeball's anterior surface
convergence *kon-VER-jens*	Coordinated movement of the eyes toward fixation on the same point
cornea *KOR-ne-ah*	The clear, anterior portion of the sclera (roots: corne/o, kerat/o)
fovea *FO-ve-ah*	The tiny depression in the retina that is the point of sharpest vision; fovea centralis, central fovea
iris *I-ris*	The muscular colored ring between the lens and the cornea; regulates the amount of light that enters the eye by altering the size of the pupil at its center (roots: ir, irid/o, irit/o) (plural: irides [*IR-ih-deze*])
lacrimal gland *LAK-rih-mal*	A gland above the eye that produces tears (roots: lacrim/o, dacry/o)
lens *lenz*	The transparent, biconvex structure in the anterior portion of the eye that refracts light and functions in accommodation (roots: lent/i, phak/o)
macula *MAK-u-lah*	A small spot or colored area; used alone to mean the yellowish spot in the retina that contains the fovea
optic disk	The point where the optic nerve joins the retina; at this point, there are no rods or cones; also called the blind spot or optic papilla
orbit *OR-bit*	The bony cavity that contains the eyeball
palpebra *PAL-peh-brah*	An eyelid; a protective fold (upper or lower) that closes over the anterior surface of the eye (roots: palpebr/o, blephar/o) (adjective: palpebral) (plural: palpebrae [*pal-PE-bre*])
pupil *PU-pil*	The opening at the center of the iris (root: pupil/o)
refraction *re-FRAK-shun*	The bending of light rays as they pass through the eye to focus on a specific point on the retina; also the determination and correction of ocular refractive errors
retina *RET-ih-nah*	The innermost, light-sensitive layer of the eye; contains the rods and cones, the specialized receptor cells for vision (root: retin/o)
rod	A specialized cell in the retina that responds to light; rods have low visual acuity, function in dim light, and do not respond to color

extern.ir

Terminology *Key Terms (Continued)*

sclera *SKLE-rah*	The tough, white, fibrous outermost layer of the eye; the white of the eye (root: scler/o)
uvea *U-ve-ah*	The middle, vascular layer of the eye (root: uve/o); consists of the choroid, ciliary body, and iris
visual acuity *ah-KU-ih-te*	Sharpness of vision
vitreous body *VIT-re-us*	The transparent jelly-like mass that fills the eyeball's main cavity; also called vitreous humor

Word Parts Pertaining to the Eye and Vision

See **TABLES 8-3** to **8-5**.

Table 8-3 Roots for External Eye Structures

Root	Meaning	Example	Definition of Example
blephar/o	eyelid	symblepharon *sim-BLEF-ah-ron*	adhesion of the eyelid to the eyeball (sym- means "together")
palpebr/o	eyelid	palpebral *PAL-peh-bral*	pertaining to an eyelid
dacry/o	tear, lacrimal apparatus	dacryorrhea *dak-re-o-RE-ah*	discharge from the lacrimal apparatus
dacryocyst/o	lacrimal sac	dacryocystocele *dak-re-o-SIS-to-sele*	hernia of the lacrimal sac
lacrim/o	tear, lacrimal apparatus	lacrimation *lak-rih-MA-shun*	secretion of tears

Exercise 8-3

Complete the exercise. To check your answers go to Appendix 11.

Define the following words.

1. nasolacrimal (*na-zo-LAK-rih-mal*) _____
2. interpalpebral (*in-ter-PAL-peh-bral*) _____
3. blepharoplasty (*blef-ah-ro-PLAS-te*) _____
4. dacryocystectomy (*dak-re-o-sis-TEK-to-me*) _____

Use the roots indicated to write words that mean the following.

5. paralysis of the eyelid (blephar/o) _____
6. stone in the lacrimal apparatus (dacry/o) _____
7. inflammation of a lacrimal sac _____

extern.ir

Table 8-4 Roots for the Eye and Vision

Root	Meaning	Example	Definition of Example
opt/o	eye, vision	optometer *op-TOM-eh-ter*	instrument for measuring the refractive power of the eye
ocul/o	eye	sinistrocular *sih-nis-TROK-u-lar*	pertaining to the left eye
ophthalm/o	eye	exophthalmos *eks-of-THAL-mos*	protrusion of the eyeball
scler/o	sclera	episcleritis *ep-ih-skle-RI-tis*	inflammation of the tissue on the surface of the sclera
corne/o	cornea	circumcorneal *sir-kum-KOR-ne-al*	around the cornea
kerat/o	cornea	keratoplasty *KER-ah-to-plas-te*	plastic repair of the cornea; corneal transplant
lent/i	lens	lentiform *LEN-tih-form*	resembling a lens
phak/o, phac/o	lens	aphakia *ah-FA-ke-ah*	absence of a lens
uve/o	uvea	uveal *U-ve-al*	pertaining to the uvea
chori/o, choroid/o	choroid	subchoroidal *sub-kor-OYD-al*	below the choroid
cycl/o	ciliary body, ciliary muscle	cycloplegic *si-klo-PLE-jik*	pertaining to or causing paralysis of the ciliary muscle
ir, irit/o, irid/o	iris	iridoschisis *ir-ih-DOS-kih-sis*	splitting of the iris
pupill/o	pupil	iridopupillary *ir-ih-do-PU-pih-lar-e*	pertaining to the iris and the pupil
retin/o	retina	retinoscopy *ret-in-OS-ko-pe*	examination of the retina

Exercise 8-4

Complete the exercise. To check your answers go to Appendix 11.

Fill in the blanks.

1. In the opening case study, the medical specialist Kelly saw for her vision problems was a(n) _____ .
2. Lenticonus is conical protrusion of the _____ .
3. The oculomotor (*ok-u-lo-MO-tor*) nerve controls movements of the _____ .
4. The science of orthoptics (*or-THOP-tiks*) deals with correcting defects in _____ .
5. The term *phacolysis* (*fah-KOL-ih-sis*) means destruction of the _____ .
6. A keratometer (*ker-ah-TOM-eh-ter*) is an instrument for measuring the curves of the _____ .

extern.ir

Exercise 8-4 *(Continued)*

Identify and define the roots pertaining to the eye in the following words.

	Root	Meaning of Root
7. optometrist (*op-TOM-eh-trist*)	_____	_____
8. microphthalmos (*mi-krof-THAL-mus*)	_____	_____
9. interpupillary (*in-ter-PU-pih-ler-e*)	_____	_____
10. retrolental (*ret-ro-LEN-tal*)	_____	_____
11. iridodilator (*ir-id-o-DI-la-tor*)	_____	_____
12. uveitis (*u-ve-I-tis*)	_____	_____
13. phacotoxic (*fak-o-TOK-sik*)	_____	_____

Write words for the following definitions.

14. inflammation of the uvea and sclera _____
15. hardening of the lens (use phac/o) _____
16. pertaining to the cornea _____
17. surgical fixation of the retina _____
18. inflammation of the ciliary body _____

Use the root *ophthalm/o* to write words for the following definitions.

19. an instrument used to examine the eye _____
20. the medical specialty that deals with the eye and diseases of the eye _____

Use the root *irid/o* to write words for the following definitions.

21. surgical removal of (part of) the iris _____
22. paralysis of the iris _____

Define the following words.

23. dextrocular (*deks-TROK-u-lar*) _____
24. lenticular (*len-TIK-u-lar*) _____
25. iridocyclitis (*ir-ih-do-si-KLI-tis*) _____
26. chorioretinal (*kor-e-o-RET-ih-nal*) _____
27. keratitis (*ker-ah-TI-tis*) _____
28. cyclotomy (*si-KLOT-o-me*) _____
29. optical (*OP-tih-kal*) _____
30. sclerotome (*SKLERE-o-tome*) _____
31. retinoschisis (*ret-ih-NOS-kih-sis*) _____

extern.ir

Table 8-5 Suffixes for the Eye and Vision[a]

Suffix	Meaning	Example	Definition of Example
-opsia	condition of vision	heteropsia *het-er-OP-se-ah*	unequal vision in the two eyes
-opia	condition of the eye, vision	hemianopia *hem-e-an-O-pe-ah*	blindness in half the visual field

[a]Compounds of -ops (eye) + -ia.

Exercise 8-5

Complete the exercise. To check your answers go to Appendix 11.

Use the suffix *-opsia* to write words for the following definitions.

1. a visual defect in which objects seem larger (macr/o) than they are _____
2. lack of (a-) color (chromat/o) vision (complete color blindness) _____

Use the suffix *-opia* to write words for the following definitions.

3. double vision _____
4. changes in vision due to old age (use the prefix presby- meaning "old") _____
5. In the opening case study, Kelly was diagnosed with "lazy eye," technically known as _____

The suffix *-opia* is added to the root *metr/o* (measure) to form words pertaining to the refractive power of the eye. Add a prefix to *-metropia* to form words for the following.

6. a lack of refractive power in the eye _____
7. unequal refractive powers in the two eyes _____

Clinical Aspects of Vision

ERRORS OF REFRACTION

If the eyeball is too long, images will form in front of the retina. To focus clearly, one must bring an object closer to the eye. This condition of *nearsightedness* is technically called **myopia** (FIG. 8-11). The opposite condition is **hyperopia**, or *farsightedness*, in which the eyeball is too short and images form behind the retina. One must move an object away from the eye for clear focus. The same effect is produced by **presbyopia**, which accompanies aging. The lens loses elasticity and can no longer accommodate for near vision, so a person gradually becomes farsighted.

Astigmatism is an irregularity in the curve of the cornea or lens that distorts light entering the eye and blurs vision.

Glasses can compensate for most of these refractive impairments, as shown for nearsightedness and farsightedness in FIGURE 8-11. See also BOX 8-3 for information on a surgical technique to correct refractive errors.

INFECTION

Several microorganisms can cause **conjunctivitis** (inflammation of the conjunctiva). This is a highly infectious disease commonly called "pink eye."

The bacterium *Chlamydia trachomatis* causes **trachoma**, inflammation of the cornea and conjunctiva that results in scarring. This disease is rare in the United States and other industrialized countries but is a common cause of blindness in underdeveloped countries, although it is easily cured with sulfa drugs and antibiotics.

Gonorrhea is the usual cause of an acute conjunctivitis in newborns called **ophthalmia neonatorum.** An antibiotic ointment is routinely used to prevent such eye infections in newborns.

DISORDERS OF THE RETINA

In cases of **retinal detachment**, the retina separates from the underlying choroid layer of the eye as a result of trauma or an accumulation of fluid or tissue between the layers (FIG. 8-12). This disorder may develop slowly or may occur suddenly. If it is left untreated, complete detachment can occur, resulting in blindness. Treatment includes use of an electric current or weak laser beam to create pinpoint scars that reattach the retina. Posterior detachment of the vitreous body, as may occur in middle age and beyond, can

extern.ir

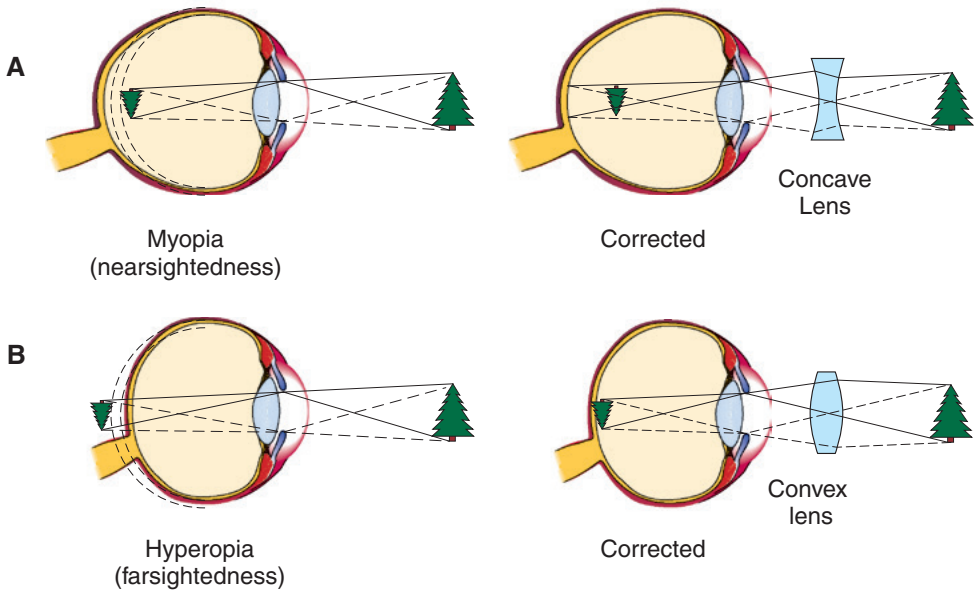

FIGURE 8-11 Errors of refraction. A. Myopia (nearsightedness). **B.** Hyperopia (farsightedness). A concave (inwardly curved) lens corrects for myopia; a convex (outwardly curved) lens corrects for hyperopia.

CLINICAL PERSPECTIVES

BOX 8-3

Eye Surgery: A Glimpse of the Cutting Edge

Cataracts, glaucoma, and refractive errors are common eye disorders. In the past, cataract and glaucoma treatments concentrated on managing the diseases. Refractive errors were corrected using eyeglasses and, more recently, contact lenses. Today, using laser and microsurgical techniques, ophthalmologists can remove cataracts, reduce glaucoma, and allow people with refractive errors to put their eyeglasses and contacts away. These cutting-edge procedures include:

- LASIK (laser in situ keratomileusis) to correct refractive errors. During this procedure, a surgeon uses a laser to reshape the cornea so that it refracts light directly onto the retina, rather than in front of or behind it. A microkeratome (surgical knife) is used to cut a flap in the cornea's outer layer. A computer-controlled laser sculpts the middle layer of the cornea and then the flap is replaced. The procedure takes only a few minutes, and patients recover their vision quickly and usually with little postoperative pain.
- Phacoemulsification to remove cataracts. During this procedure, a surgeon makes a very small incision (~3 mm long) through the sclera near the cornea's outer edge. An ultrasonic probe is inserted through this opening and into the center of the lens. The probe uses sound waves to emulsify the lens's central core, which is then suctioned out. An artificial lens is then permanently implanted in the lens capsule (see **FIG. 8-14**). The procedure is typically painless, although the patient may feel some discomfort for one to two days afterward.
- Laser trabeculoplasty to treat glaucoma. This procedure uses a laser to help drain fluid from the eye and lower intraocular pressure. The laser is aimed at drainage canals located between the cornea and iris and makes several burns that are believed to open the canals and allow better fluid drainage. The procedure is typically painless and takes only a few minutes.

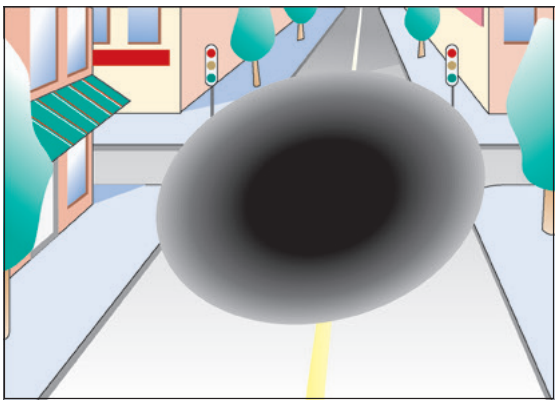

FIGURE 8-12 Retinal detachment.

also pull the retina away. Danger signs include light flashes with eye movement, floater showers, or the appearance of a "black curtain" over part of the visual field. If any of these symptoms appear, a person should consult an ophthalmologist immediately.

Degeneration of the macula, the point of sharpest vision, is a common cause of visual problems in the elderly. When associated with aging, this deterioration is described as **age-related macular degeneration (AMD).** In nonexudative ("dry") macular degeneration, material accumulates on the retina. Vitamins C and E, beta carotene, and zinc supplements may delay this process. In neovascular ("wet") AMD, abnormal blood vessels grow under the retina, causing it to detach. Laser surgery may stop the growth of these

extern.ir



FIGURE 8-13 A–D. Visual disorders.

vessels and delay vision loss. More recently, ophthalmologists have had success in delaying the progress of wet AMD with regular intraocular injections of a drug (e.g., Lucentis) that inhibits blood vessel formation. Macular degeneration typically affects central vision but not peripheral vision (FIG. 8-13B). Other causes of macular degeneration are drug toxicity and hereditary diseases.

Circulatory problems associated with diabetes mellitus eventually cause changes in the retina referred to as **diabetic retinopathy.** In addition to vascular damage, there is a yellowish, waxy exudate high in lipoproteins. With time, new blood vessels form and penetrate the vitreous humor, causing hemorrhage, detachment of the retina, and blindness. The visual effects of diabetic retinopathy can be seen in FIGURE 8-13C.

CATARACT

A **cataract** is an opacity (cloudiness) of the lens that blurs vision (see FIG. 8-13D). Causes of cataract include disease, injury, chemicals, and exposure to physical forces, especially the ultraviolet radiation in sunlight. The cataracts that frequently appear with age may result from exposure to environmental factors in combination with degeneration attributable to aging.

To prevent blindness, an ophthalmologist must remove the cloudy lens surgically. Commonly, the lens's anterior capsule is removed along with the cataract, leaving the posterior capsule in place (FIG. 8-14). In **phacoemulsification**, the lens is fragmented with high-frequency ultrasound and extracted through a small incision (see BOX 8-3). After cataract removal, an artificial intraocular lens (IOL) is usually implanted to compensate for the missing lens. The original type of implant provides vision only within a fixed distance; newer implants are designed to allow for near and far accommodation. Alternatively, a person can wear a contact lens or special glasses.

GLAUCOMA

Glaucoma is an abnormal increase in pressure within the eyeball. It occurs when more aqueous humor is produced than can be drained away from the eye. There is pressure on blood vessels in the eye and on the optic nerve, leading to blindness. There are many causes of glaucoma, and screening for this disorder should be a part of every routine eye examination. Fetal infection with rubella (German measles) early in pregnancy can cause glaucoma, as well as cataracts and hearing impairment. Glaucoma is usually treated with medication to reduce pressure in the eye and occasionally is treated with surgery (see BOX 8-3).

extern.ir

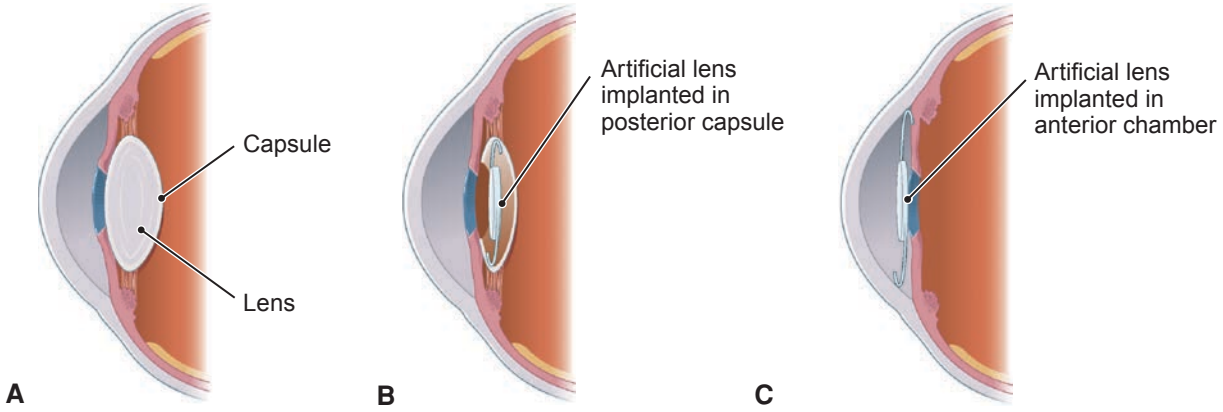

FIGURE 8-14 Cataract extraction surgeries. A. Cross-section of normal eye anatomy. **B.** Extracapsular lens extraction involves removing the lens but leaving the posterior capsule intact to receive a synthetic intraocular lens. **C.** Intracapsular lens extraction involves removing the lens and lens capsule and implanting a synthetic intraocular lens in the anterior chamber.

Terminology *Key Terms*

The terms listed below are emphasized in this chapter. Knowing them will help you organize and prioritize your learning. These boldface terms are also found, collectively, with all chapter key terms in the Glossary.

The Eye

Disorders	
age-related macular degeneration (AMD) *MAK-u-lar de-jen-er-A-shun*	Deterioration of the macula associated with aging; macular degeneration impairs central vision
astigmatism *ah-STIG-mah-tizm*	An error of refraction caused by irregularity in the curvature of the cornea or lens
cataract *KAT-ah-rakt*	Opacity of the lens of the eye
conjunctivitis *kon-junk-tih-VI-tis*	Inflammation of the conjunctiva; pink eye
diabetic retinopathy *ret-ih-NOP-ah-the*	Degenerative changes in the retina associated with diabetes mellitus
glaucoma *glaw-KO-mah*	An eye disease caused by increased intraocular pressure that damages the optic disk and causes vision loss; usually results from faulty fluid drainage from the anterior eye
hyperopia *hi-per-O-pe-ah*	A refractive error in which light rays focus behind the retina and objects can be seen clearly only when far from the eye; farsightedness; also called hypermetropia
myopia *mi-O-pe-ah*	A refractive error in which light rays focus in front of the retina and objects can be seen clearly only when very close to the eye; nearsightedness
ophthalmia neonatorum *of-THAL-me-ah ne-o-na-TOR-um*	Severe conjunctivitis usually caused by infection with gonococcus during birth
phacoemulsification *fak-o-e-MUL-sih-fih-ka-shun*	Removal of a cataract by ultrasonic destruction and extraction of the lens
presbyopia *prez-be-O-pe-ah*	Changes in the eye that occur with age; the lens loses elasticity and the ability to accommodate for near vision
retinal detachment	Separation of the retina from its underlying layer
trachoma *trah-KO-mah*	An infection caused by *Chlamydia trachomatis* leading to inflammation and scarring of the cornea and conjunctiva; a common cause of blindness in underdeveloped countries

extern.ir

Terminology *Enrichment Terms*

The terms listed below expand on the key terms to increase your knowledge of this chapter topic.

The Eye

Normal Structure and Function

canthus *KAN-thus*	The angle at either end of the slit between the eyelids
diopter *DI-op-ter*	A measurement unit for the refractive power of a lens
emmetropia *em-eh-TRO-pe-ah*	The normal condition of the eye in refraction, in which parallel light rays focus exactly on the retina
fundus *FUN-dus*	A bottom or base; the region farthest from the opening of a structure; the eye's fundus is the posterior portion of the interior eyeball as seen with an ophthalmoscope
meibomian gland *mi-BO-me-an*	A sebaceous gland in the eyelid
tarsus *TAR-sus*	The framework of dense connective tissue that gives shape to the eyelid; tarsal plate
zonule *ZONE-ule*	A system of fibers that holds the lens in place; also called suspensory ligaments

Symptoms and Conditions

amblyopia *am-ble-O-pe-ah*	A condition that occurs when visual acuity is not the same in the two eyes in children (prefix ambly means "dim"); disuse of the poorer eye will result in blindness if not corrected; also called "lazy eye"; see Kelly's opening case study on amblyopia
anisocoria *an-i-so-KO-re-ah*	Condition in which the two pupils (root: cor/o) are not of equal size
blepharoptosis *blef-ah-rop-TO-sis*	Drooping of the eyelid (see **FIG. 3-5**)
chalazion *kah-LA-ze-on*	A small mass on the eyelid resulting from inflammation and blockage of a meibomian gland
drusen *DRU-zen*	Small growths that appear as tiny yellowish spots beneath the retina of the eye; typically occur with age but also occur in certain abnormal conditions
floater *FLO-ter*	A small moving object in the field of vision that originates in the vitreous body; floaters appear as spots or threads and are caused by benign degenerative or embryonic deposits in the vitreous body that cast a shadow on the retina
hordeolum *hor-DE-o-lum*	Inflammation of a sebaceous gland of the eyelid; a sty
keratoconus *ker-ah-to-KO-nus*	Conical protrusion of the corneal center
miosis *mi-O-sis*	Abnormal contraction of the pupils (from Greek *meiosis* meaning "diminution")
mydriasis *mih-DRI-ah-sis*	Pronounced or abnormal dilation of the pupil
nyctalopia *nik-tah-LO-pe-ah*	Night blindness; inability to see well in dim light or at night (root: nyct/o); often due to lack of vitamin A, which is used to make the pigment needed for vision in dim light
nystagmus *nis-TAG-mus*	Rapid, involuntary, rhythmic movements of the eyeball; may occur in neurologic diseases or disorders of the inner ear's vestibular apparatus
papilledema *pap-il-eh-DE-mah*	Swelling of the optic disk (papilla); choked disk
phlyctenule *FLIK-ten-ule*	A small blister or nodule on the cornea or conjunctiva

extern.ir

Terminology *Enrichment Terms (Continued)*

pseudophakia *su-do-FA-ke-ah*	A condition in which a cataractous lens has been removed and replaced with a plastic lens implant
retinitis *ret-in-I-tis*	Inflammation of the retina; causes include systemic disease, infection, hemorrhage, exposure to light
retinitis pigmentosa *ret-in-I-tis pig-men-TO-sah*	A hereditary chronic degenerative disease of the retina that begins in early childhood; there is atrophy of the optic nerve and clumping of pigment in the retina
retinoblastoma *ret-in-o-blas-TO-mah*	A malignant glioma of the retina; usually appears in early childhood and is sometimes hereditary; fatal if untreated, but current cure rates are high
scotoma *sko-TO-mah*	An area of diminished vision within the visual field
strabismus *strah-BIZ-mus*	A deviation of the eye in which the visual lines of each eye are not directed to the same object at the same time; also called heterotropia or squint; the various forms are referred to as -tropias, with the direction of turning (trop/o) indicated by a prefix, such as esotropia (inward), exotropia (outward), hypertropia (upward), and hypotropia (downward); the suffix -phoria is also used, as in esophoria.
synechia *sin-EK-e-ah*	Adhesion of parts, especially adhesion of the iris to the lens and cornea (plural: synechiae)
xanthoma *zan-THO-mah*	A soft, slightly raised, yellowish patch or nodule usually on the eyelids; occurs in the elderly; also called xanthelasma
Diagnosis and Treatment	
canthotomy *kan-THOT-o-me*	Surgical division of a canthus
cystotome *SIS-tih-tome*	Instrument for incising the lens capsule
electroretinography (ERG) *e-lek-tro-ret-ih-NOG-rah-fe*	Study of the retina's electrical response to light stimulation
enucleation *e-nu-kle-A-shun*	Surgical removal of the eyeball
gonioscopy *go-ne-OS-ko-pe*	Examination of the angle between the cornea and the iris (anterior chamber angle) in which fluids drain out of the eye (root *gonio* means "angle")
keratometer *ker-ah-TOM-eh-ter*	An instrument for measuring the curvature of the cornea
mydriatic *mid-re-AT-ik*	A drug that causes dilation of the pupil
phorometer *fo-ROM-eh-ter*	An instrument for determining the degree and kind of strabismus
retinoscope *RET-in-o-skope*	An instrument used to determine refractive errors of the eye; also called a skiascope (*SKI-ah-skope*)
slit-lamp biomicroscope	An instrument for examining the eye under magnification
Snellen chart *SNEL-en*	A chart printed with letters of decreasing size used to test visual acuity when viewed from a set distance; results reported as a fraction giving a subject's vision compared with normal vision at a distance of 20 ft
tarsorrhaphy *tar-SOR-ah-fe*	Suturing together of all or part of the upper and lower eyelids
tonometer *to-NOM-eh-ter*	An instrument used to measure fluid pressure in the eye

extern.ir

Terminology *Abbreviations*

The abbreviations listed below are emphasized in this chapter. These are also found, collectively, with all chapter abbreviations in Appendix 2.

The Eye

A, Acc	Accommodation	**HM**	Hand movements
AMD	Age-related macular degeneration	**IOL**	Intraocular lens
ARC	Abnormal retinal correspondence	**IOP**	Intraocular pressure
As, AST	Astigmatism	**NRC**	Normal retinal correspondence
cc	With correction	**NV**	Near vision
Em	Emmetropia	**sc**	Without correction
EOM	Extraocular movement, muscles	**VA**	Visual acuity
ERG	Electroretinography	**VF**	Visual field
ET	Esotropia	**XT**	Exotropia
FC	Finger counting		

Case Study Revisited

Kelly's Follow-Up

Kelly started wearing the patch on her right eye during waking hours. She progressed to wearing it 4 to 5 hours a day as ordered by the ophthalmologist. The glasses she obtained from the optician were helping her to focus, and she was able to read her schoolwork. Kelly's mother made sure the glasses were fun and attractive for Kelly to wear and found some colorful patches that helped Kelly accept wearing a patch to school. She also met with the school counselor and Kelly's teacher to explain why her daughter had been falling behind in her schoolwork and had some self-image issues. The counselor said she would come up with ideas to involve Kelly in fun school activities with her classmates. And, the teacher said she would help guide Kelly through her schoolwork while her vision was being corrected.

A month later Kelly had an appointment with her ophthalmologist. The physician said she had adjusted well to the treatment plan and showed improved vision. Kelly's schoolwork also improved and she had made new friends.

extern.ir

CHAPTER 8

Review

This review tests your understanding of the content introduced in this chapter. Follow the instructions for each exercise and check your answers in Appendix 11.

LABELING EXERCISE

THE EAR

Write the name of each numbered part on the corresponding line.

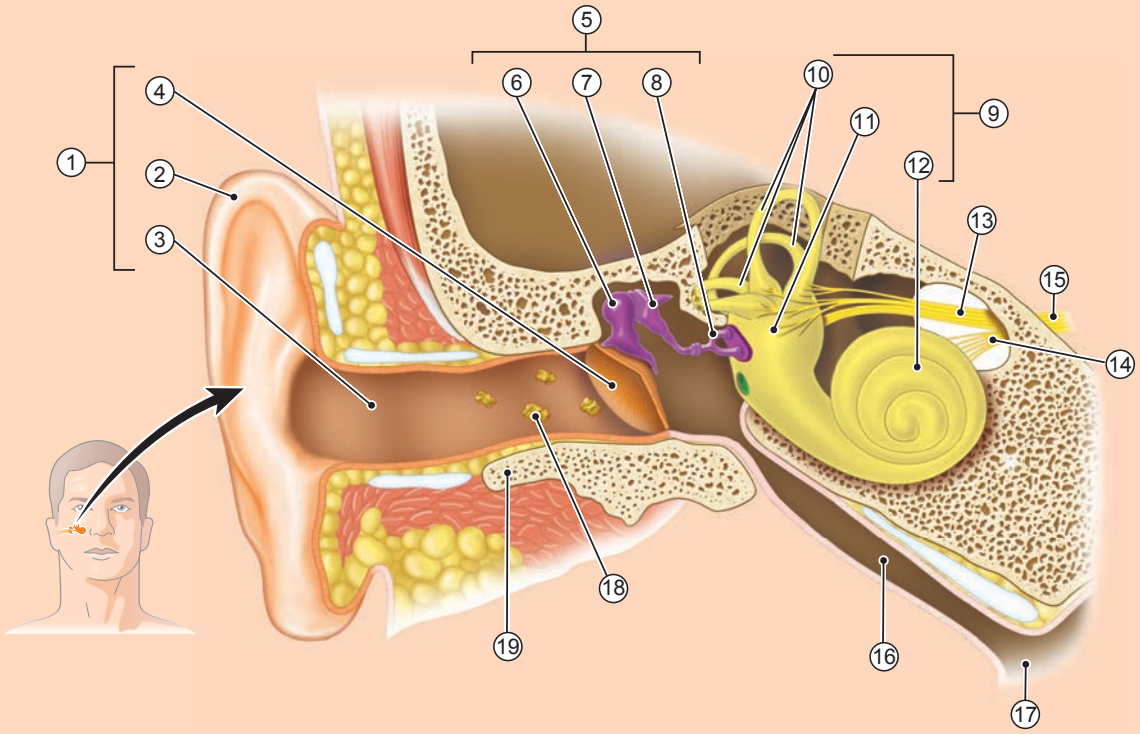

Auditory tube	Incus	Pharynx	Stapes
Cerumen	Inner ear	Pinna	Vestibular nerve
Cochlea	Malleus	Semicircular canals	Vestibulocochlear nerve (VIII)
Cochlear nerve	Middle ear	Temporal bone	Vestibule
External auditory canal	Outer ear	Tympanic membrane	

1. _____
2. _____
3. _____
4. _____
5. _____
6. _____
7. _____
8. _____
9. _____
10. _____
11. _____
12. _____
13. _____
14. _____
15. _____
16. _____
17. _____
18. _____
19. _____

extern.ir

THE EYE

Write the name of each numbered part on the corresponding line.

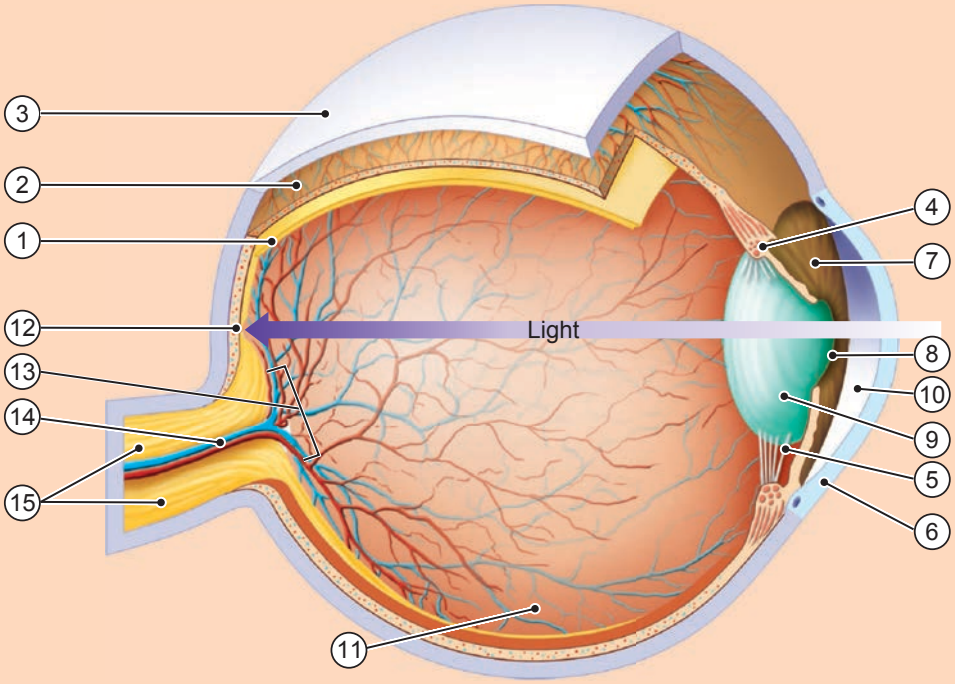

Aqueous humor
Blood vessels
Choroid
Ciliary body
Cornea
Fovea
Iris
Lens
Optic disk
Optic nerve
Pupil
Retina
Sclera
Suspensory ligaments
Vitreous body

1. _____
2. _____
3. _____
4. _____
5. _____
6. _____
7. _____
8. _____
9. _____
10. _____
11. _____
12. _____
13. _____
14. _____
15. _____

extern.ir

TERMINOLOGY

MATCHING

Match the following terms, and write the appropriate letter to the left of each number.

____ 1. palpebra	a. small bone
____ 2. ossicle	b. structure that changes shape for near and far vision
____ 3. rods and cones	c. an eyelid
____ 4. vestibular apparatus	d. location of equilibrium receptors
____ 5. lens	e. vision receptors

____ 6. tactile	a. increased sensation
____ 7. tinnitus	b. blindness in half the visual field
____ 8. hyperesthesia	c. point of sharpest vision
____ 9. fovea	d. pertaining to touch
____ 10. hemianopia	e. sensation of noises in the ear

____ 11. anacusis	a. corneal transplant
____ 12. ophthalmoplegia	b. abnormal smell perception
____ 13. phacomalacia	c. paralysis of an eye muscle
____ 14. parosmia	d. softening of the lens
____ 15. keratoplasty	e. total loss of hearing

Enrichment Terms

____ 16. diopter	a. angle between the eyelids
____ 17. mastoid process	b. small muscle attached to an ear ossicle
____ 18. stapedius	c. projection of the temporal bone
____ 19. canthus	d. unit of sound intensity
____ 20. decibel	e. unit for measuring the refractive power of the lens

____ 21. emmetropia	a. abnormal dilation of the pupil
____ 22. nystagmus	b. small growths beneath the retina
____ 23. mydriasis	c. rapid, involuntary eye movements
____ 24. drusen	d. normal refraction of the eye
____ 25. amblyopia	e. commonly called "lazy eye"

____ 26. AMD	a. irregularity in the curve of the eye
____ 27. Hz	b. an implanted lens
____ 28. AST	c. otorhinolaryngology
____ 29. ENT	d. eye disorder associated with aging
____ 30. IOL	e. a unit for measuring pitch of sound

extern.ir

FILL IN THE BLANKS

Complete the sentence with the correct term(s).

31. The scientific name for the eardrum is _____ .
32. The type of hearing loss resulting from damage to the eighth cranial nerve is described as _____ .
33. The ossicle that is in contact with the inner ear is the _____ .
34. The outermost layer of the eye wall is the _____ .
35. The bending of light rays as they pass through the eye is _____ .
36. The innermost layer of the eye that contains the receptors for vision is the _____ .
37. The transparent extension of the sclera that covers the front of the eye is the _____ .
38. The sense of awareness of body position is _____ .

DEFINITIONS

Define the following words.

39. audiologist (*aw-de-OL-o-jist*) _____
40. ophthalmometer (*of-thal-MOM-eh-ter*) _____
41. aphakia (*ah-FA-ke-ah*) _____
42. subscleral (*sub-skle-ral*) _____
43. iridotomy (*ir-ih-DOT-o-me*) _____
44. myringoscope (*mih-RING-go-skope*) _____
45. perilental (*per-e-LEN-til*) _____
46. dacryorrhea (*dak-re-o-RE-ah*) _____
47. presbycusis (*pres-be-KU-sis*) _____
48. keratoiritis (*ker-ah-to-i-RI-tis*) _____

Write words for the following definitions.

49. softening of the lens _____
50. measurement of the pupil _____
51. surgical removal of the stapes _____
52. drooping of the eyelid _____
53. plastic repair of the ear _____
54. pertaining to the vestibular apparatus and cochlea _____
55. any disease of the retina _____
56. absence of pain _____
57. pertaining to tears _____
58. excision of (part of) the ciliary body _____
59. endoscopic examination of the auditory tube _____
60. technical name for farsightedness _____

extern.ir

ADJECTIVES

Write the adjective form of the following words.

61. cochlea _____
62. palpebra _____
63. choroid _____
64. uvea _____
65. cornea _____
66. sclera _____
67. pupil _____

OPPOSITES

Write words that mean the opposite of the following.

68. hyperesthesia _____
69. hypalgesia _____
70. cc _____
71. hyperopia _____
72. mydriasis _____
73. esotropia _____

WORD BUILDING

Write words for the following definitions using the word parts provided. Each word part can be used more than once.

-pexy	-ia	osm/o	kerat/o	-al	-schisis	-scopy	pseud/o-	retin/o	an-	-plasty	salping/o	sub	-myring/o

74. false sense of smell _____
75. plastic repair of the tympanic membrane _____
76. examination of the retina _____
77. examination of the auditory tube _____
78. absence of the sense of smell _____
79. splitting of the retina _____
80. examination of the tympanic membrane _____
81. beneath the retina _____
82. surgical fixation of the retina _____
83. examination of the cornea _____

extern.ir

TRUE–FALSE

Examine the following statements. If the statement is true, write T in the first blank. If the statement is false, write F in the first blank, and correct the statement by replacing the underlined word in the second blank.

	True or False	Correct Answer
84. The spiral organ is located in the vestibule of the inner ear.	_____	_____
85. An osmoceptor is a receptor for the sense of smell.	_____	_____
86. The malleus is located in the middle ear.	_____	_____
87. Gustation is the sense of taste.	_____	_____
88. Hypergeusia is an abnormal increase in the sense of touch.	_____	_____
89. In bright light the pupils dilate.	_____	_____
90. A myringotomy is incision of the stapes.	_____	_____
91. The lacrimal gland produces aqueous humor.	_____	_____

ELIMINATION

In each of the sets below, underline the word that does not fit in with the rest, and explain the reason for your choice.

92. pressure — temperature — smell — touch — pain

_____

93. cochlea — pinna — vestibule — oval window — semicircular canals

_____

94. incus — lacrimal gland — eyelash — conjunctiva — palpebra

_____

95. glaucoma — myopia — cataract — macular degeneration — presbycusis

_____

WORD ANALYSIS

Define the following words, and give the meaning of the word parts in each. Use a dictionary if necessary.

96. asthenopia (*as-the-NO-pe-ah*)
    a. a- _____
    b. sthen/o _____
    c. -op(s) _____
    d. -ia _____
97. pseudophakia (*su-do-FA-ke-ah*)
    a. pseudo _____
    b. phak/o _____
    c. -ia _____
98. cholesteatoma (*ko-les-te-ah-TO-mah*)
    a. chol/e _____
    b. steat/o _____
    c. -oma _____

extern.ir

99. exotropia (*ek-so-TRO-pe-ah*)

a. ex/o- _____

b. trop/o _____

c. -ia _____

100. anisometropia (*an-i-so-meh-TRO-pe-ah*)

a. an- _____

b. iso- _____

c. metr/o _____

d. op(s) _____

e. -ia _____

extern.ir

Additional Case Studies

Case Study 8-1: Audiology Report

George, a 55 y/o man, reported decreased hearing sensitivity in his left ear for the past 3 years. In addition to hearing loss, he was experiencing tinnitus and aural fullness. Pure-tone test results revealed normal hearing sensitivity for the right ear and a moderate sensorineural hearing loss in the left ear. Speech thresholds were appropriate for the degree of hearing loss noted. Word recognition was excellent for the right ear and poor for the left ear when the signal was present at a suprathreshold level. Tympanograms were characterized by normal shape, amplitude, and peak pressure points bilaterally. The contralateral acoustic reflex was normal for the right ear but absent for the left ear at the frequencies tested (500 to 4,000 Hz). The ipsilateral acoustic reflex was present with the probe in the right ear and absent with the probe in the left ear. Brainstem auditory evoked potentials (BAEPs) were within normal range for the right ear. No repeatable response was observed from the left ear. A subsequent MRI showed a 1-cm acoustic neuroma.

Case Study 8-1 Questions

Follow the instructions for each question and check your answers in Appendix 11.

Multiple Choice. *Select the best answer, and write the letter of your choice to the left of each number.*

_____ 1. The study of hearing is termed
   a. acousticology
   b. radio frequency
   c. audiology
   d. otology

_____ 2. Sensorineural hearing loss may result from
   a. damage to the second cranial nerve
   b. damage to the eighth cranial nerve
   c. otosclerosis
   d. otitis media

_____ 3. The term that means "on the same side" is
   a. contralateral
   b. bilateral
   c. distal
   d. ipsilateral

_____ 4. Another name for an acoustic neuroma is
   a. macular degeneration
   b. acoustic neurilemmoma
   c. auditory otosclerosis
   d. acoustic glaucoma

Write terms from the case study with the following meanings.

5. above a minimum level _____
6. pertaining to or perceived by the ear _____
7. record obtained by tympanometry _____
8. pertaining to sound or hearing _____
9. perception of sounds, such as ringing or tinkling in the ear _____

Define the following abbreviations.

10. Hz _____
11. BAEP _____

extern.ir

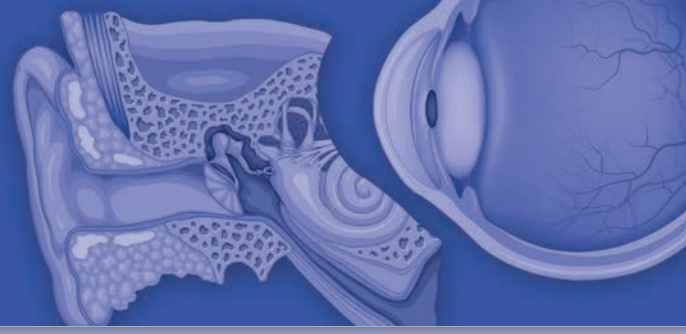

Case Study 8-2: Phacoemulsification With Intraocular Lens Implant

Ginny, a 68 y/o, was scheduled for surgery for a cataract and relief from "floaters," which she had noticed in her visual field since her surgery for a retinal detachment the previous year. She reported to the ambulatory surgery center an hour before her scheduled procedure. Before transfer to the operating room, she spoke with her ophthalmologist, who reviewed the surgical plan. Her right eye was identified as the operative eye, and it was marked with a "yes" and the surgeon's initials on the lid. She was given anesthetic drops in the right eye and an intravenous bolus of 2 mg of midazolam (Versed).

In the OR, Ginny and her operative eye were again identified by the surgeon, anesthetist, and nurses. After anesthesia and akinesia were achieved, the eye area was prepped and draped in sterile sheets. An operating microscope with video system was positioned over her eye. A 5-0 silk suture was placed through the superior rectus muscle to retract the eye. A lid speculum was placed to open the eye. A minimal conjunctival peritomy was performed, and hemostasis was achieved with wet-field cautery. The anterior chamber was entered at the 10:30 o'clock position. A capsulotomy was performed after Healon was placed in the anterior chamber. Phacoemulsification was carried out without difficulty. The remaining cortex was removed by irrigation and aspiration.

An intraocular lens (IOL) was placed into the posterior chamber. Miochol was injected to achieve papillary miosis, and the wound was closed with one 10-0 suture. Subconjunctival Celestone and Garamycin were injected. The lid speculum and retraction suture were removed. After application of Eserine and Bacitracin ointments, the eye was patched, and a shield was applied. Ginny left the OR in good condition and was discharged to home 4 hours later.

Case Study 8-2 Questions

Follow the instructions for each question and check your answers in Appendix 11.

Multiple Choice. *Select the best answer, and write the letter of your choice to the left of each number.*

_____ 1. Ultrasound destruction and aspiration of the lens is called
   a. catarectomy
   b. phacoemulsification
   c. stapedectomy
   d. radial keratotomy

_____ 2. The term akinesia means
   a. movement
   b. lack of sensation
   c. washing
   d. lack of movement

Write terms from the case study with the following meanings.

3. physician who specializes in conditions of the eye _____
4. a circular incision through the conjunctiva _____
5. within the eye _____
6. abnormal contraction of the pupil _____
7. below the conjunctiva _____

Define the following abbreviation.

8. IOL _____

extern.ir

CHAPTER 9

Endocrine System

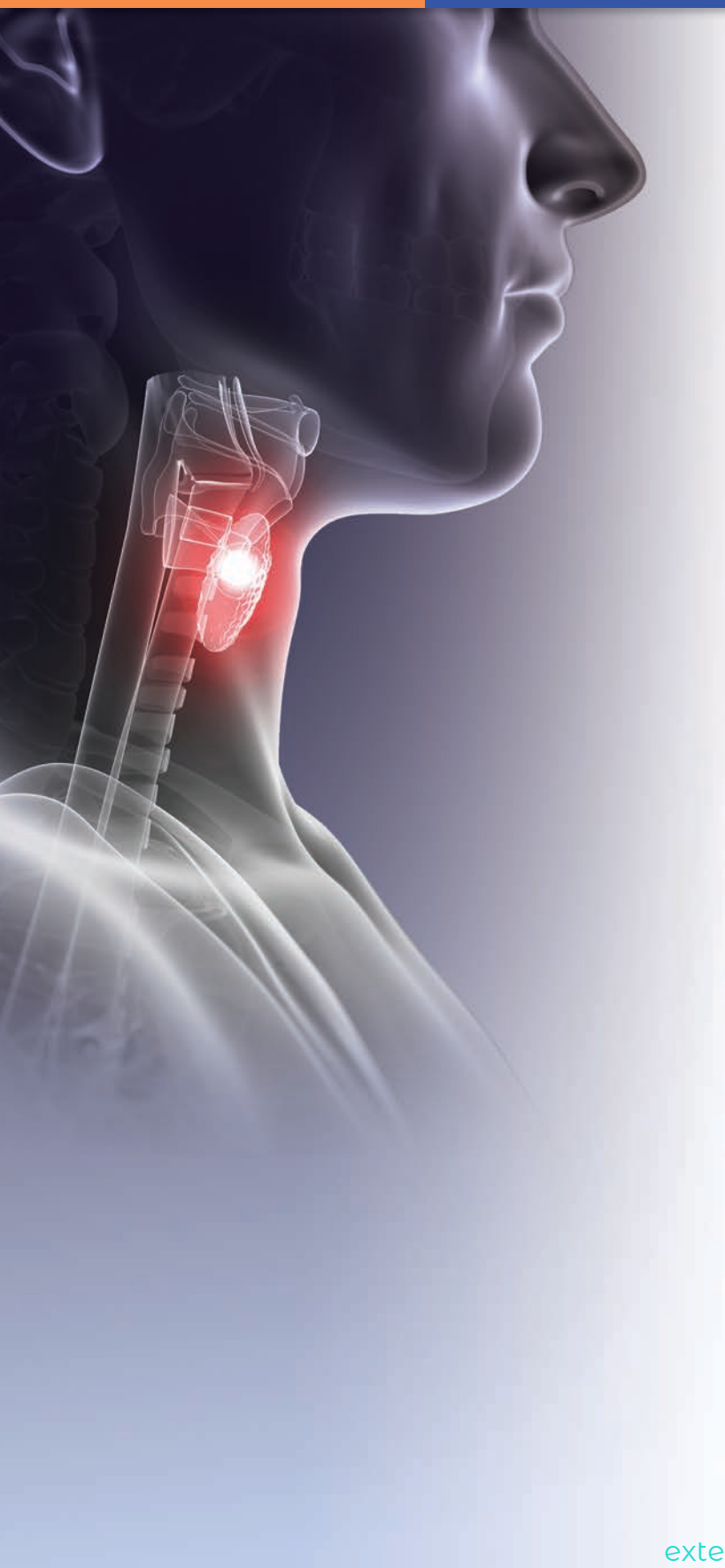

Pretest

Multiple Choice. **Select the best answer, and write the letter of your choice to the left of each number. To check your answers go to Appendix 11.**

_____ 1. The secretions of the endocrine glands are called
a. enzymes
b. sera
c. lymph
d. hormones

_____ 2. The small gland in the brain that controls other glands is the
a. thymus
b. pituitary
c. appendix
d. corpus luteum

_____ 3. The glands that are located above the kidneys are the
a. adrenals
b. thyroid
c. follicles
d. fimbriae

_____ 4. Gigantism results from overproduction of
a. erythropoietin
b. oxytocin
c. growth hormone
d. prolactin

_____ 5. Diabetes mellitus involves the hormone insulin, which is made in the
a. kidney
b. seminal vesicle
c. thymus
d. pancreas

_____ 6. A goiter involves the
a. zygote
b. calyx
c. adrenal
d. thyroid

_____ 7. Parathyroid hormone regulates
a. magnesium
b. calcium
c. cortisol
d. glucose

_____ 8. Cushing disease is overactivity of the
a. thyroid
b. parathyroid
c. adrenal cortex
d. adrenal medulla

extern.ir

Learning Objectives

After careful study of this chapter, you should be able to:

1. Define hormones. ***P294***
2. Compare steroid and amino acid hormones. ***P294***
3. Give the location and structure of the endocrine glands. ***P294***
4. Name the hormones produced by the endocrine glands, and briefly describe the function of each. ***P295***
5. Identify and use roots pertaining to the endocrine system. ***P299***
6. Describe the main disorders of the endocrine system. ***P300***
7. Interpret abbreviations used in endocrinology. ***P307***
8. Analyze medical terms in several case studies concerning the endocrine system. ***PP293, 312***

Case Study: Jasmine's Graves Disease

Chief Complaint

Jasmine is a 35 y/o second grade teacher. Her husband has been noticing that she has been very energetic over the past few months, more so than usual. She is constantly working or cleaning, and she is up during the night, unable to sleep. Jasmine says that she has felt nervous and jittery for the past few months. Her husband encouraged her to make an appointment with her physician.

Examination

Jasmine's internist, Dr. Gilbert, was able to make a few observations when he walked into the examination room. Jasmine had lost weight since her last appointment, and her eyes were protruding. Normally a quiet and happy person, she appeared irritable and abrupt. She complained about her edginess, dry eyes, and inability to sleep. She also mentioned that she cannot tolerate the heat and frequently perspires. She said she just has not been "feeling herself" as of late. Dr. Gilbert examined her, and when palpating her neck, he noted an enlarged thyroid. He also noted a dermopathy on her shins where the skin had thickened and had red patches. Her vital signs were pretty consistent with previous examinations, except that she was a bit tachycardic. Dr. Gilbert suspected hyperthyroidism. He ordered some blood work to check her thyroid levels and confirm his diagnosis.

Clinical Course

Results of the laboratory work verified Dr. Gilbert's suspicion. He discussed with Jasmine and her husband the diagnosis of Graves disease, an autoimmune disorder that is the most common form of hyperthyrodism. He provided them the results of the T_3 and T_4 laboratory work and explained that the high levels meant her thyroid was overactive. He then explained the treatment options, including antithyroid medication, partial or total thyroidectomy, or radiation therapy. Dr. Gilbert felt that a medical regime would be appropriate for Jasmine and ordered the antithyroid drug Tapazole. He also ordered eye drops for the exophthalmos.

Case Study Revisited: Once you complete this chapter, please review the case follow-up on p. 307.

Ancillaries *At-A-Glance*

Visit the web resource to access the following resources.

Learning Resources

- eBook
- A&P Module with Heart & Lung Sounds
- Image Bank
- TestPrep
- Animations
- Audio Pronunciation Glossary

extern.ir

Introduction

The body's main controlling systems are the endocrine system and the nervous system (discussed in this chapter and Chapter 7, respectively). The endocrine system consists of a widely distributed group of glands that secrete regulatory substances called **hormones.** Because hormones are released into the blood, the **endocrine** glands are known as the *ductless glands*, as compared to exocrine glands such as sweat glands and digestive glands, that secrete through ducts to the outside. Despite the fact that hormones circulating in the blood reach all parts of the body, only certain tissues respond to a specific hormone. The tissue that is influenced by a specific hormone is called the **target tissue.** The cells in a target tissue have specific **receptors** on their membranes or within the cell to which the hormone attaches, enabling it to act.

Hormones

Hormones are produced in extremely small amounts and are highly potent. By means of their actions on various target tissues, they affect growth, metabolism, reproductive activity, and behavior. (**BOX 9-1** describes some old ideas about the effects of substances circulating in the blood.)

Chemically, hormones fall into two categories:

- **Steroid hormones,** which are made from lipids. Steroids are produced by the sex glands (gonads) and the outer region (cortex) of the **adrenal glands.**
- Hormones made of amino acids, which include proteins and protein-like compounds. All of the endocrine glands aside from the gonads and adrenal cortex produce amino acid hormones.

The production of hormones is controlled mainly by negative feedback—that is, the hormone itself, or some product of hormone activity, acts as a control over further manufacture of the hormone—a self-regulating system. Hormone production may also be controlled by the nervous system or by other hormones.

The Endocrine Glands

Refer to **FIGURE 9-1** to locate the endocrine glands described below. **BOX 9-2** lists the endocrine glands, along with the hormones they secrete and their functions.

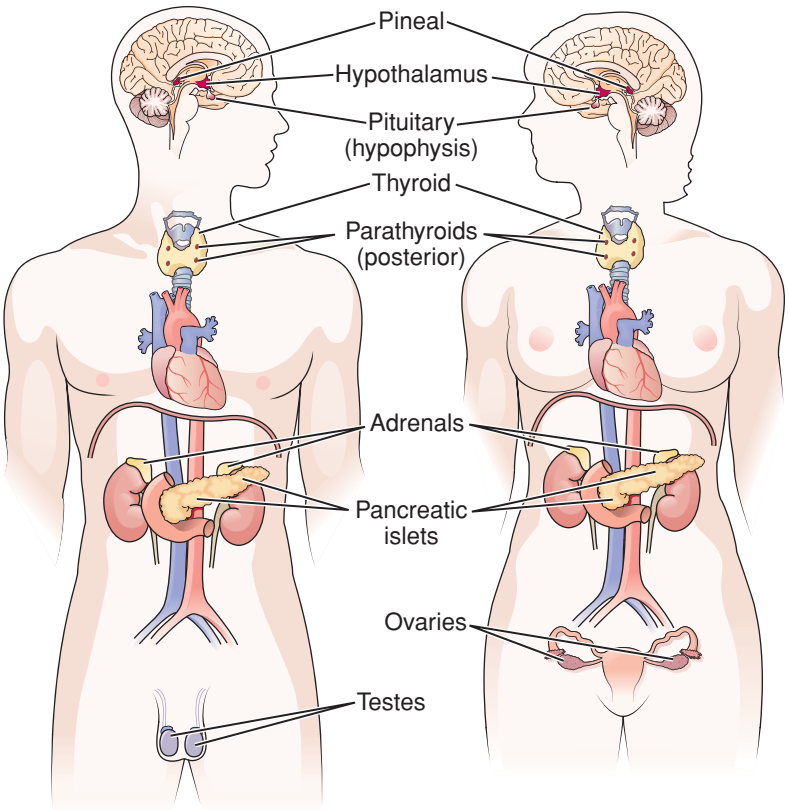

FIGURE 9-1 The endocrine glands.

FOCUS ON WORDS
Are You in a Good Humor?

BOX 9-1

In ancient times, people accepted the theory that a person's state of health depended on the balance of four body fluids. These fluids, called "humors," were yellow bile, black bile, phlegm, and blood. A predominance of any one of these humors would determine a person's mood or temperament. Yellow bile caused anger; black bile caused depression; phlegm (mucus) made a person sluggish; blood resulted in cheerfulness and optimism.

Although we no longer believe in humoralism, we still have adjectives in our vocabulary that reflect these early beliefs. Choleric describes a person under the influence of yellow bile; melancholic describes the effects of black bile (melan/o- means black or dark); a phlegmatic person is slow to respond; a sanguine individual "goes with the flow." (*Sanguine* is derived from the Greek word for blood.)

The humors persist today in the adjective *humoral*, which describes substances carried in the blood or other body fluids. The term applies to hormones and other circulating materials that influence body responses. Humoral immunity is immunity based on antibodies carried in the bloodstream.

extern.ir

FOR YOUR REFERENCE

BOX 9-2

Endocrine Glands and Their Hormones

Gland	Hormone	Principal Functions
anterior pituitary *pih-TU-ih-tar-e*	GH (growth hormone), also called somatotropin (*so-mah-to-TRO-pin*)	Promotes growth of all body tissues
	TSH (thyroid-stimulating hormone)	Stimulates thyroid gland to produce thyroid hormones
	ACTH (adrenocorticotropic hormone) (*ah-dre-no-kor-tih-ko-TRO-pik*)	Stimulates adrenal cortex to produce cortical hormones; aids in protecting body in stress situations (injury, pain)
	FSH (follicle-stimulating hormone)	Stimulates growth and hormonal activity of ovarian follicles; stimulates growth of testes; promotes sperm cell development
	LH (luteinizing hormone) (*LU-te-in-i-zing*)	Causes development of corpus luteum at the site of ruptured ovarian follicle in female; stimulates testosterone secretion in male
	PRL (prolactin) (*pro-LAK-tin*)	Stimulates milk secretion by mammary glands
posterior pituitary	ADH (antidiuretic hormone; vasopressin) (*an-te-di-u-RET-ik; va-so-PRES-in*)	Promotes water reabsorption in kidney tubules; causes blood vessels to constrict
	oxytocin (*ok-se-TO-sin*)	Causes uterine contraction; causes milk ejection from mammary glands
thyroid	thyroxine or tetraiodothyronine (T_4) and triiodothyronine (T_3) (*thi-ROK-sin; tri-i-o-do-THI-ro-nene*)	Increase metabolic rate and heat production, influencing both physical and mental activities; required for normal growth
parathyroid	parathyroid hormone (PTH) (*par-ah-THI-royd*)	Regulates calcium exchange between blood and bones; increases blood calcium level
adrenal cortex	cortisol (hydrocortisone) (*KOR-tih-sol*)	Aids in metabolism of carbohydrates, proteins, and fats; active during stress
	aldosterone (*al-DOS-ter-one*)	Aids in regulating electrolytes and water balance
	sex hormones	May influence secondary sexual characteristics
adrenal medulla	epinephrine (*adrenaline*) (*ep-ih-NEF-rin; ah-DREN-ah-lin*)	Response to stress; increases respiration, blood pressure, and heart rate
pancreatic islet	insulin (*IN-su-lin*)	Aids glucose transport into cells; required for cellular metabolism of nutrients, especially glucose; decreases blood glucose levels
	glucagon (*GLU-kah-gon*)	Stimulates liver to release glucose, thereby increasing blood glucose levels
pineal	melatonin (*mel-ah-TONE-in*)	Regulates mood, sexual development, and daily cycles in response to environmental light
testis	testosterone (*tes-TOS-teh-rone*)	Stimulates growth and development of sexual organs plus development of secondary sexual characteristics; stimulates maturation of sperm cells
ovary	estrogen (*ES-tro-jen*)	Stimulates growth of primary sexual organs and development of secondary sexual characteristics
	progesterone (*pro-JES-ter-one*)	Prepares uterine lining for implantation of fertilized ovum; aids in maintaining pregnancy; stimulates development of mammary glands' secretory tissue

extern.ir

CLINICAL PERSPECTIVES

BOX 9-3

Growth Hormone: Its Clinical Use Is Growing

Growth hormone (GH) is produced by the anterior pituitary. It is released mainly at the beginning of deep sleep, so the old belief that you grow while you sleep has some basis in fact. Although GH primarily affects bone and muscle development during early growth, it has a general stimulating effect on most other tissues throughout life. Its alternative name, somatotropin, comes from *soma* meaning "body" and *tropin* meaning "acting on." GH is released during times of stress to boost the liver's output of energy-rich fatty acids when blood glucose levels drop. A lack of GH in childhood results in dwarfism, and the hormone was initially prescribed only for children with a GH deficiency. Now it has also been approved for children who are in the lowest percentile of height for their age. If a child is still growing, as shown by x-rays of the hand and wrist, GH will lead to some ultimate increase in height. Because GH increases lean muscle mass, it is also touted as a bodybuilding and antiaging medication. However, it may have some side effects, and its long-term effects are not known. GH for clinical use was initially obtained from cadaver pituitaries, but it is now made by genetic engineering.

PITUITARY

The **pituitary gland**, or **hypophysis**, is a small gland beneath the brain. It is divided into an anterior lobe (adenohypophysis) and a posterior lobe (neurohypophysis). The **hypothalamus**, a part of the brain that regulates homeostasis, is connected to and controls both lobes. Because the hypothalamus secretes hormones and is active in controlling the pituitary gland, it is considered to be part of the endocrine system as well as the nervous system.

The anterior pituitary produces six hormones. One of these is growth hormone (somatotropin), which stimulates bone growth and acts on other tissues as well (**BOX 9-3**). The remainder of the pituitary hormones regulate other glands, including the thyroid, adrenals, gonads, and mammary glands (see **BOX 9-2**). The ending *-tropin*, as in *gonadotropin*, indicates a hormone that acts on another gland. The adjective ending is *-tropic*, as in *adrenocorticotropic*.

The posterior pituitary releases two hormones that are actually produced in the hypothalamus. These hormones are stored in the posterior pituitary until they are needed:

- Antidiuretic hormone (ADH) acts on the kidneys to conserve water and also promotes constriction of blood vessels. Both of these actions increase blood pressure.
- Oxytocin stimulates uterine contractions and promotes milk "letdown" in the breasts during lactation.

THYROID AND PARATHYROIDS

The **thyroid gland** consists of two lobes on either side of the larynx and upper trachea. The lobes are connected by a narrow band (isthmus) **(FIG. 9-2)**. The thyroid secretes a mixture of hormones, mainly thyroxine (T_4) and triiodothyronine (T_3). Because thyroid hormones contain iodine, laboratories

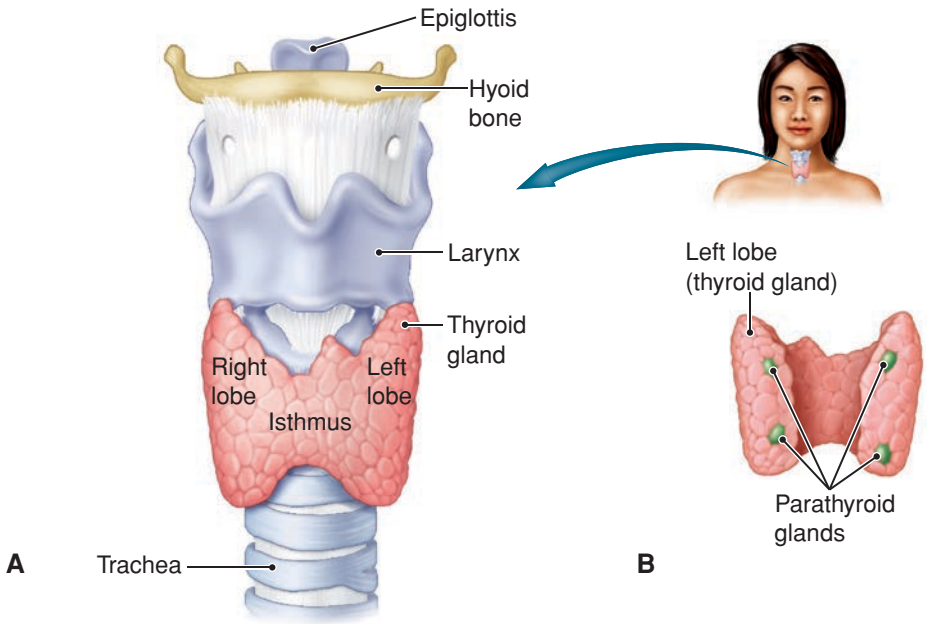

FIGURE 9-2 The thyroid and parathyroid glands. A. The thyroid has two lobes connected by an isthmus. This anterior view shows the gland in relation to other structures in the throat. **B.** The parathyroid glands are embedded in the posterior portion of the thyroid.

extern.ir

can measure these hormones and study thyroid gland activity by following iodine levels. Most thyroid hormone in the blood is bound to protein, primarily thyroxine-binding globulin (TBG).

On the posterior surface of the thyroid are four to six tiny **parathyroid glands** that affect calcium metabolism (see FIG. 9-2). Parathyroid hormone (PTH) regulates calcium exchange between the blood and bones. It increases the blood level of calcium when needed.

ADRENALS

The adrenal glands, located atop the kidneys, are divided into two distinct regions: an outer cortex and an inner medulla (FIG. 9-3). The hormones produced by this gland are involved in the body's response to stress. The cortex produces steroid hormones:

- Cortisol (hydrocortisone) mobilizes fat and carbohydrate reserves to increase these nutrients in the blood. It also reduces inflammation and is used clinically for this purpose.

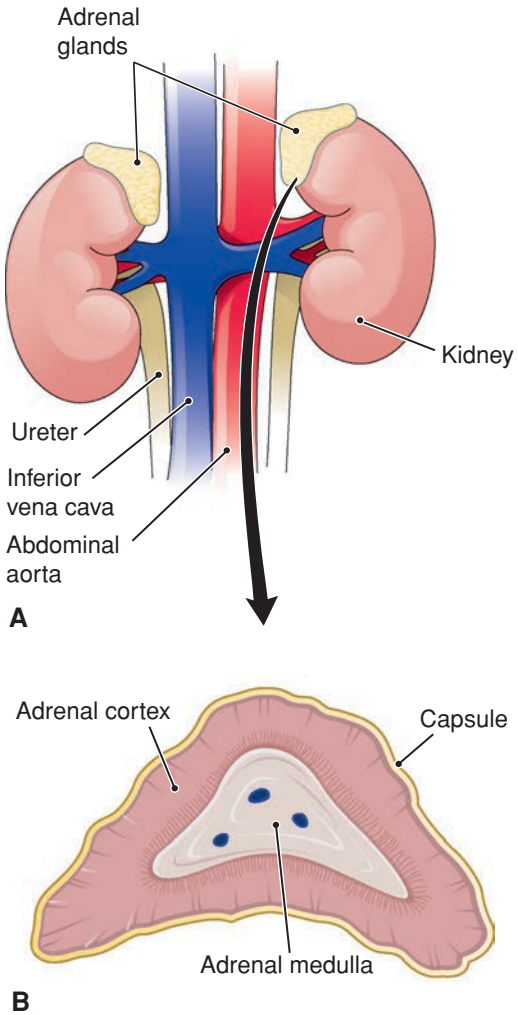

FIGURE 9-3 Adrenal glands. A. The adrenal glands shown on top of the kidneys. **B.** The adrenal gland is divided into a medulla and cortex, each secreting different hormones.

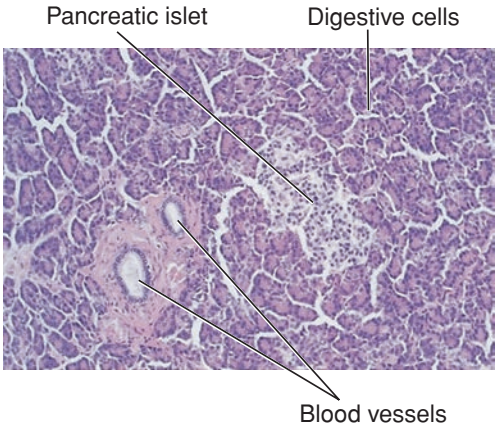

FIGURE 9-4 Pancreatic cells, microscopic view. Light-staining islet cells are seen among the cell clusters that produce digestive juices.

- Aldosterone causes the kidneys to conserve sodium and water while eliminating potassium.
- Sex hormones, mainly testosterone, are also produced in small amounts, but their importance is not well understood. Some athletes, illegally and dangerously, take testosterone-like steroids to increase muscle size, strength, and endurance (see BOX 6-1).

The medulla of the adrenal gland produces the hormone epinephrine (adrenaline) in response to stress. Epinephrine works with the nervous system to help the body meet physical and emotional challenges.

PANCREAS

The endocrine portions of the pancreas are the **pancreatic islets**, small cell clusters within the pancreatic tissue. The term *islet*, meaning "small island," is used because these cells look like little islands in the midst of the many pancreatic cells that secrete digestive juices (FIG. 9-4). The islet cells produce two hormones, insulin and glucagon, that regulate glucose metabolism. Insulin increases cellular use of glucose, thus decreasing blood glucose levels. Glucagon has the opposite effect, increasing blood glucose levels.

Other Endocrine Tissues

There are three additional types of glands that secrete hormones:

- The **pineal gland** is a small gland in the brain (see FIG. 9-1). It regulates mood, daily rhythms, and sexual development in response to environmental light. Its hormone is melatonin, which some people take to help regulate sleep–wake cycles when they travel between time zones.
- The thymus, described in Chapter 10, secretes the hormone thymosin that aids in the development of the immune system's T cells. The thymus lies in the upper

extern.ir

chest above the heart. It is important in early years but shrinks and becomes less important in adults.

- The gonads, testes, and ovaries, described in Chapters 15 and 16, are also included because they secrete hormones in addition to producing the sex cells.

Other organs, including the stomach, kidney, heart, and small intestine, also produce hormones. However, they have other major functions and are discussed with the systems to which they belong.

Finally, **prostaglandins** are a group of hormones produced by many cells. They have a variety of effects, including stimulation of uterine contractions, promotion of inflammation, and vasomotor activities. They are called prostaglandins because they were first discovered in the prostate gland.

Terminology *Key Terms*

The terms listed below are emphasized in this chapter. Knowing them will help you organize and prioritize your learning. These boldface terms are also found, collectively, with all chapter key terms in the Glossary.

Normal Structure and Function

adrenal gland *ah-DRE-nal*	A gland on the superior surface of the kidney; the outer region (cortex) secretes steroid hormones; the inner region (medulla) secretes epinephrine (adrenaline) in response to stress (root: adren/o)
endocrine *EN-do-krin*	Pertaining to a ductless gland that secretes hormones into the blood
hormone *HOR-mone*	A secretion of an endocrine gland; a substance that travels in the blood and has a regulatory effect on tissues, organs, or glands
hypophysis *hi-POF-ih-sis*	The pituitary gland; named from *hypo*, meaning "below," and *physis*, meaning "growing," because the gland develops below the hypothalamus (root: hypophysi/o)
hypothalamus *hi-po-THAL-ah-mus*	A portion of the brain that controls the pituitary gland, produces hormones, and is active in maintaining homeostasis
pancreatic islet *I-let*	Cluster of endocrine cells in the pancreas that secretes hormones to regulate glucose metabolism; also called islet of Langerhans or islet cells (root insul/o means "island")
parathyroid gland *par-ah-THI-royd*	A small endocrine gland on the posterior thyroid that acts to increase blood calcium levels; there are usually four to six parathyroid glands (roots: parathyr/o, parathyroid/o); the name literally means "near the thyroid"
pineal gland *PIN-e-al*	A small gland in the brain (see **FIG. 9-1**); appears to regulate mood, daily rhythms, and sexual development in response to environmental light; secretes the hormone melatonin
pituitary gland *pih-TU-ih-tar-e*	A small endocrine gland at the base of the brain; the anterior lobe secretes growth hormone and hormones that stimulate other glands; the posterior lobe releases ADH and oxytocin manufactured in the hypothalamus (root: pituitar/i); hypophysis
prostaglandins *pros-tah-GLAN-dinz*	A group of hormones produced throughout the body that have a variety of effects, including stimulation of uterine contractions and regulation of blood pressure, blood clotting, and inflammation
receptor *re-SEP-tor*	A site on the cell membrane or within the cell to which a substance, such as a hormone, attaches
steroid hormone *STER-oyd*	A hormone made from lipids; includes the sex hormones and the hormones of the adrenal cortex
target tissue	The specific tissue on which a hormone acts; may also be called the target organ
thyroid gland *THI-royd*	An endocrine gland on either side of the larynx and upper trachea; it secretes hormones that affect metabolism and growth (roots: thyr/o, thyroid/o)

extern.ir

Roots Pertaining to the Endocrine System

See **TABLE 9-1**.

Table 9-1 Roots Pertaining to the Endocrine System

Root	Meaning	Example	Definition of Example
endocrin/o	endocrine glands or system	endocrinopathy *en-do-krih-NOP-ah-the*	any disease of the endocrine glands
pituitar/i	pituitary gland, hypophysis	pituitarism *pih-TU-ih-tah-rizm*	condition caused by any disorder of pituitary function
hypophysi/o	pituitary gland, hypophysis	hypophysial *hi-po-FIZ-e-al* (also spelled hypophyseal)	pertaining to the pituitary gland
thyr/o, thyroid/o	thyroid gland	thyrolytic *thi-ro-LIT-ik*	destroying the thyroid gland
parathyr/o, parathyroid/o	parathyroid gland	hyperparathyroidism *hi-per-par-ah-THI-royd-izm*	overactivity of a parathyroid gland
adren/o, adrenal/o	adrenal gland, epinephrine	adrenergic *ad-ren-ER-jik*	activated (erg) by or related to epinephrine (adrenaline)
adrenocortic/o	adrenal cortex	adrenocorticotropic *ah-dre-no-kor-tih-ko-TRO-pik*	acting on the adrenal cortex
insul/o	pancreatic islets	insular *IN-su-lar*	pertaining to islet cells

9

Exercise 9-1

Complete the exercise. To check your answers go to Appendix 11.

Define the following words.

1. hypoadrenalism (*hi-po-ah-DRE-nal-izm*) _____
2. thyrotropic (*thi-ro-TROP-ik*) _____
3. hypophysectomy (*hi-pof-ih-SEK-to-me*) _____
4. endocrinology (*en-do-krin-OL-o-je*) _____
5. insuloma (*in-su-LO-mah*) _____

Words for conditions resulting from endocrine dysfunctions are formed by adding the suffix *-ism* to the name of the gland or its root and adding the prefix *hyper-* or *hypo-* for overactivity or underactivity of the gland. Use the full name of the gland to form words with the following definitions.

6. condition of overactivity of the thyroid gland, as seen in Jasmine's opening case study _____
7. condition of underactivity of the parathyroid gland _____
8. condition of overactivity of the adrenal gland _____

Use the word root for the gland to form words with the following definitions.

9. condition of overactivity of the adrenal cortex _____
10. condition of underactivity of the pituitary gland (use pituitar/i) _____

(continued)

extern.ir

Exercise 9-1 *(Continued)*

Write a word for the following definitions.

11. enlargement of the adrenal gland _____
12. excision of the thyroid gland, as mentioned in Jasmine's opening case study _____
13. any disease of the adrenal gland _____
14. physician who specializes in study of the endocrine system _____
15. inflammation of the pancreatic islets _____

Clinical Aspects of the Endocrine System

Endocrine diseases usually result from the overproduction (hypersecretion) or underproduction (hyposecretion) of hormones. They may also result from secretion at the wrong time or from an inadequate target tissue response. The causes of abnormal secretion may originate in the gland itself or may result from failure of the hypothalamus or the pituitary to release the proper amount of stimulating hormones. Some of the common endocrine disorders are described below. Conditions resulting from hypersecretion or hyposecretion of hormones are summarized in **BOX 9-4**.

PITUITARY

A pituitary **adenoma** (glandular tumor) usually increases secretion of growth hormone or adrenocorticotropic hormone (ACTH). Less commonly, a tumor affects the secretion of prolactin. An excess of growth hormone in children causes **gigantism.** In adults it causes **acromegaly,** characterized by enlargement of the hands, feet, jaw, and facial features. Treatment is by surgery to remove the tumor (adenomectomy) or by drugs to reduce the blood levels of growth hormone. Excess ACTH overstimulates the adrenal cortex, resulting in Cushing disease. Increased prolactin causes milk secretion (galactorrhea) in both males and females. Radiographic studies in cases of pituitary adenoma usually show enlargement of the bony socket (sella turcica) that contains the pituitary.

Pituitary hypofunction, as caused by tumor or interruption of blood supply to the gland, may involve a single hormone but usually affects all functions and is referred to as **panhypopituitarism.** This condition's widespread effects include dwarfism (from lack of growth hormone), lack of sexual development and sexual function, fatigue, and weakness.

A specific lack of ADH from the posterior pituitary results in **diabetes insipidus** in which the kidneys have a decreased ability to conserve water. Symptoms are polyuria (excessive urination) and polydipsia (excessive thirst). Diabetes insipidus should not be confused with **diabetes**

FOR YOUR REFERENCE BOX 9-4

Disorders Associated With Endocrine Dysfunction[a]

Hormone	Hypersecretion	Hyposecretion
growth hormone	gigantism (children), acromegaly (adults)	dwarfism (children)
antidiuretic hormone	syndrome of inappropriate ADH (SIADH)	diabetes insipidus
aldosterone	aldosteronism	Addison disease
cortisol	Cushing syndrome	Addison disease
thyroid hormone	Graves disease, thyrotoxicosis	congenital and adult hypothyroidism
insulin	hypoglycemia	diabetes mellitus
parathyroid hormone	bone degeneration	tetany (muscle spasms)

[a]Refer to key terms for pronunciations and descriptions.

extern.ir

mellitus (DM), a disorder of glucose metabolism described later. The two diseases share the symptoms of polyuria and polydipsia but have entirely different causes. DM is the more common disorder, and when the term *diabetes* is used alone, it generally refers to DM. The word *diabetes* is from the Greek meaning "siphon," referring to the large urinary output in both forms of diabetes.

THYROID

Because thyroid hormone affects the growth and function of many tissues, a deficiency of this hormone in infancy causes physical and mental retardation as well as other symptoms that together constitute **congenital hypothyroidism**, also called *infantile hypothyroidism*. If not diagnosed at birth and treated, hypothyroidism will lead to mental retardation within 6 months. The United States and other developed countries now require testing of all newborns for hypothyroidism.

In adults, thyroid deficiency causes weight gain; lethargy; rough, dry skin; hair loss; and facial swelling. There may be reproductive problems and muscular weakness, pain, and stiffness. A common cause of **adult hypothyroidism** is autoimmune destruction of the thyroid. Hypothyroidism in both children and adults is easily treated with thyroid hormone.

The most common form of hyperthyroidism is **Graves disease**, also called *diffuse toxic goiter*. This is an autoimmune disorder in which antibodies stimulate an increased production of thyroid hormone. There is weight loss, irritability, hand tremor, and rapid heart rate (tachycardia). A most distinctive sign is bulging eyeballs, termed **exophthalmos**, caused by swelling of the tissues behind the eyes (FIG. 9-5). Treatment for Graves disease may include antithyroid drugs, surgical removal of all or part of the thyroid, or radiation delivered in the form of radioactive iodine.

A common sign in thyroid disease is an enlarged thyroid, or **goiter**. However, a goiter is not necessarily accompanied by thyroid malfunction. A simple or nontoxic goiter is caused by a dietary iodine deficiency. Such cases are rare in industrialized countries because of iodine addition to salt and other commercial foods.

Thyroid function is commonly tested by measuring the gland's radioactive iodine uptake (RAIU). Laboratories use radioimmunoassays to measure blood levels of pituitary thyroid-stimulating hormone (TSH), which varies with changing levels of thyroid hormones. Total and free thyroxine (T_4) and triiodothyronine (T_3) are also measured, as are the levels of TBG, a blood protein that binds to thyroid hormones. Thyroid scans following administration of radioactive iodine are also used to study this gland's activity.

PARATHYROIDS

Overactivity of the parathyroid glands, usually from a tumor, causes a high level of calcium in the blood. Because this calcium is obtained from the bones, there is also skeletal degeneration and bone pain. A common side effect is the development of kidney stones from the high levels of circulating calcium.

FIGURE 9-5 Graves disease. A young woman with hyperthyroidism showing a mass in the neck and exophthalmos.

Damage to the parathyroids or their surgical removal, as during thyroid surgery, results in a decrease in blood calcium levels. This causes numbness and tingling in the arms and legs and around the mouth (perioral), as well as **tetany** (muscle spasms). Treatment consists of supplying calcium.

ADRENALS

Hypofunction of the adrenal cortex, or **Addison disease**, is usually caused by autoimmune destruction of the gland. It may also result from a deficiency of pituitary ACTH. The lack of aldosterone results in water loss, low blood pressure, and electrolyte imbalance. There is also weakness and nausea and an increase in brown pigmentation. This last symptom is caused by release of a pituitary hormone that stimulates the skin's pigment cells (melanocytes). Once diagnosed, Addison disease is treated with replacement of cortical hormones.

An excess of adrenal cortical hormones results in **Cushing syndrome.** Patients with this syndrome have moon-shaped faces, obesity localized in the torso, weakness, excess hair

extern.ir

FIGURE 9-6 Cushing syndrome. The woman has a moon face, buffalo hump, increased facial hair, and thinning of the scalp hair.

growth (hirsutism), and fluid retention (FIG. 9-6). The most common cause of Cushing syndrome is the therapeutic administration of steroid hormones. An adrenal tumor is another possible cause. If the disorder is caused by a pituitary tumor that increases ACTH production, it is referred to as **Cushing disease.**

THE PANCREAS AND DIABETES

The most common endocrine disorder, and a serious public health problem, is diabetes mellitus (DM), a failure of the body cells to use glucose effectively. The excess glucose accumulates in the blood, causing **hyperglycemia.** Increased urination (polyuria) marks the effort to eliminate the excess glucose in the urine, a condition termed **glycosuria.** The result is dehydration and excessive thirst (polydipsia). There is also weakness, weight loss, and extreme hunger (polyphagia). Unable to use carbohydrates, the body burns more fat. This leads to accumulation of ketone bodies in the blood and a shift toward acidosis, a condition termed **ketoacidosis.** If untreated, diabetes will lead to starvation of the central nervous system and coma. Diabetic patients are prone to cardiovascular, neurologic, and visual problems; infections; and renal failure.

Types of Diabetes Mellitus

There are two main types of DM:

- Type 1 diabetes mellitus (T1DM) is caused by autoimmune destruction of pancreatic islet cells and failure of the pancreas to produce insulin. It has an abrupt onset and usually appears in children and teenagers. Because insulin levels are very low or absent, patients need careful monitoring and regular administration of this hormone.
- Type 2 diabetes mellitus (T2DM) accounts for about 90% of diabetes cases. Heredity plays a much greater role in this form of diabetes than in type 1. Type 2 diabetes is initiated by cellular resistance to insulin. Feedback stimulation of the pancreatic islets leads to insulin overproduction followed by a failure of the overworked cells to produce enough insulin. Most cases of type 2 diabetes are linked to obesity, especially upper-body obesity. Although seen mostly in older people, the incidence of type 2 diabetes is increasing among younger generations, presumably because of increased obesity, poor diet, and sedentary habits.

Metabolic syndrome, also called *syndrome X* or *insulin resistance syndrome*, is related to T2DM and describes a state of hyperglycemia caused by insulin resistance in association with some metabolic disorders, including high levels of plasma triglycerides (fats), low levels of high-density lipoproteins (HDLs), hypertension, and coronary heart disease.

Gestational diabetes mellitus (GDM) refers to glucose intolerance during pregnancy. This imbalance usually appears in women with family histories of diabetes and in those who are obese. Women, especially those with predisposing factors, must be monitored during pregnancy for signs of DM because this condition can cause complications for both the mother and the fetus. Gestational diabetes usually disappears after childbirth, but it may be a sign that diabetes will develop later in life. As with other forms of diabetes, a proper diet is the first step to management, with insulin treatment if needed.

DM may also follow other endocrine disorders or treatment with corticosteroids and may be caused by a genetic disorder of the pancreatic islets.

Diagnosis

Diabetes is diagnosed by measuring glucose levels in blood plasma with or without fasting. The standard for diagnosis of diabetes in a random test is greater than 200 mg/dL and for a fasting plasma glucose (FPG) greater than 126 mg/dL. Measuring blood glucose levels after oral administration of glucose is an oral glucose tolerance test (OGTT). Categories of impaired fasting blood glucose (IFG) and impaired glucose tolerance (IGT) are intermediate stages between a normal response to glucose and confirmed diabetes.

Treatment

People with T1DM must monitor blood glucose levels four to eight times a day. Traditionally, this is done with blood obtained by a finger stick, but new methods of monitoring glucose through the skin are available. Systems for continuous monitoring are also available, and these can alert patients to high and low blood glucose levels. Readings can be sent wirelessly to a cell phone, which is a boon to parents of juvenile diabetics who previously had to wake their children several times a night to check on blood glucose levels.

Insulin may be given in divided doses by injection or by means of an insulin pump that delivers the hormone around the clock as continuous subcutaneous insulin infusion (CSII). The pump delivers a basal dose of insulin hourly, supplemented by the patient before each meal based the meal's anticipated carbohydrate content. The device injects

extern.ir

HEALTH PROFESSIONS
Dietitians and Nutritionists

BOX 9-5

Dietitians and nutritionists specialize in planning and supervising food programs for institutions, such as hospitals, schools, and nursing care facilities, and for individuals with specific disease states, such as diabetes, renal disease, or heart disease. They assess their clients' nutritional needs and design individualized meal plans. Dietitians and nutritionists also work in community settings, educating the public about disease prevention through healthy eating. Increased public awareness about food and nutrition has also led to new opportunities in the food manufacturing industry. To perform their duties, dietitians and nutritionists need a thorough scientific and clinical background. Most dietitians and nutritionists in the United States receive their training from colleges or universities, complete internships, and take licensing or registration examinations.

Job prospects for dietitians and nutritionists are good. As the American population continues to age, the need for nutritional planning in hospital and nursing care settings is expected to rise. In addition, many people now place an emphasis on healthy eating and may consult nutritionists privately. The Academy of Nutrition and Dietetics at eatright.org has information about these careers.

insulin through tubing into the subcutaneous tissues of the abdomen. Diet must be carefully regulated to keep glucose levels as steady as possible.

While managing diabetes, patients monitor their own glucose levels on a daily basis. Every few months, physicians obtain more precise indications of long-term glucose control with a **glycated hemoglobin (HbA1c) test.** This test is based on glucose uptake by red blood cells and reflects the average blood glucose levels for 2 to 3 months before the test.

Exercise and weight loss for those who are overweight are the first approaches to treating type 2 DM, and these measures often lead to management of the disorder. Drugs for increasing insulin production or improving cellular responses to insulin may also be prescribed, with insulin treatment given if necessary.

Insulin is now made by genetic engineering. There are various forms with different action times that can be alternated to achieve glucose regulation. Excess insulin may result from a pancreatic tumor, but more often it occurs after administration of too much hormone to a diabetic patient. The resultant **hypoglycemia** leads to **insulin shock**, which is treated by the administration of glucose. People taking insulin injections should carry notification of their disease. A novel approach to preventing hypoglycemic episodes is through the help of dogs. These assist animals are trained to detect breath odors associated with hypoglycemia and alert their owners by nudging or pawing them, most importantly when the person is asleep and unaware of the danger.

Methods of administering insulin in pills or capsules, inhaler spray, or skin patches are under study. Researchers are also studying the possibility of transplanting healthy islet cells to compensate for failed cells. Another area of research is the use of immunosuppression to halt T1DM.

Also used to diagnose endocrine disorders are imaging techniques; other measurements of hormones or their metabolites in plasma and urine; and studies involving hormone stimulation or suppression.

BOX 9-5 has information on dieticians and nutritionists. These healthcare professionals work with people, including those with diabetes and other metabolic disorders, to plan healthful diets.

Terminology *Key Terms*

The terms listed below are emphasized in this chapter. Knowing them will help you organize and prioritize your learning. These boldface terms are also found, collectively, with all chapter key terms in the Glossary.

Disorders

acromegaly *ak-ro-MEG-ah-le*	Overgrowth of bone and soft tissue, especially in the hands, feet, and face, caused by excess growth hormone in an adult; the name comes from acro meaning "extremity" and megal/o meaning "enlargement"
Addison disease	A disease resulting from deficiency of adrenocortical hormones; it is marked by darkening of the skin, weakness, and alterations in salt and water balance
adenoma *ad-eh-NO-mah*	A neoplasm of a gland

(continued)

extern.ir

Terminology Key Terms (Continued)

adult hypothyroidism *hi-po-THI-royd-izm*	A condition caused by hypothyroidism in an adult; there is dry, waxy swelling, most notable in the face; formerly called myxedema (*miks-eh-DE-mah*)
congenital hypothyroidism *kon-JEN-ih-tal hi-po-THI-royd-izm*	A condition caused by lack of thyroid secretion during development and marked by arrested physical and mental growth; also called infantile hypothyroidism
Cushing disease	Overactivity of the adrenal cortex resulting from excess production of ACTH by the pituitary
Cushing syndrome	A condition resulting from an excess of hormones from the adrenal cortex; it is associated with obesity, weakness, hyperglycemia, hypertension, and hirsutism (excess hair growth)
diabetes insipidus *di-ah-BE-teze in-SIP-ih-dus*	A disorder caused by insufficient release of ADH from the posterior pituitary; it results in excessive thirst and production of large amounts of very dilute urine; *insipidus* means "tasteless," referring to the dilution of the urine
diabetes mellitus (DM) *MEL-ih-tus*	A disorder of glucose metabolism caused by deficiency of insulin production or inadequate tissue response to insulin; type 1 results from autoimmune destruction of pancreatic islet cells; it generally appears in children and requires insulin administration; type 2 generally occurs in obese adults; it is treated with diet, exercise, and drugs to improve insulin production or activity, and sometimes insulin; *mellitus* comes from the Latin root for honey, referring to the urine's glucose content
exophthalmos *ek-sof-THAL-mos*	Protrusion of the eyeballs, as seen in Graves disease
gigantism *JI-gan-tizm*	Overgrowth caused by excess growth hormone from the pituitary during childhood; also called gigantism
glycated hemoglobin (HbA1c) test *GLI-ka-ted*	A test that measures the binding of glucose to hemoglobin during the lifespan of a red blood cell; it reflects the average blood glucose level over 2 to 3 months and is useful in evaluating long-term therapy for diabetes mellitus; also called A1c test
glycosuria *gli-ko-SU-re-ah*	Excess glucose in the urine
goiter *GOY-ter*	Enlargement of the thyroid gland; a simple (nontoxic) goiter is caused by iodine deficiency
Graves disease	An autoimmune disease resulting in hyperthyroidism; a prominent symptom is exophthalmos (protrusion of the eyeballs); also called diffuse toxic goiter
hyperglycemia *hi-per-gli-SE-me-ah*	Excess glucose in the blood
hypoglycemia *hi-po-gli-SE-me-ah*	Abnormally low level of glucose in the blood
insulin shock	A condition resulting from an overdose of insulin, causing hypoglycemia
ketoacidosis *ke-to-as-ih-DO-sis*	Acidosis (increased acidity of body fluids) caused by excess ketone bodies, as in diabetes mellitus; diabetic acidosis
metabolic syndrome	A state of hyperglycemia caused by cellular resistance to insulin, as seen in type 2 diabetes, in association with other metabolic disorders; also called syndrome X or insulin resistance syndrome
panhypopituitarism *pan-hi-po-pih-TU-ih-tah-rism*	Underactivity of the entire pituitary gland
tetany *TET-ah-ne*	Irritability and spasms of muscles; may be caused by low blood calcium and other factors

extern.ir

Terminology *Enrichment Terms*

The terms listed below expand on the key terms to increase your knowledge of this chapter topic.

Normal Structure and Function	
sella turcica *SEL-ah TUR-sih-kah*	A saddle-shaped depression in the sphenoid bone that contains the pituitary gland (literally means "Turkish saddle")
sphenoid bone *SFE-noyd*	A bone at the base of the skull that houses the pituitary gland
Symptoms and Conditions	
adrenogenital syndrome *ad-re-no-JEN-ih-tal*	Condition caused by overproduction of androgens from the adrenal cortex, resulting in masculinization; may be congenital or acquired, usually as a result of an adrenal tumor
Conn syndrome	Hyperaldosteronism caused by an adrenal tumor
craniopharyngioma *kra-ne-o-far-in-je-O-mah*	A benign tumor of the pituitary gland
Hashimoto disease *hah-she-MO-to*	A chronic thyroiditis of autoimmune origin
impaired glucose tolerance (IGT)	High blood glucose levels after glucose intake that may signal borderline diabetes mellitus
ketosis *ke-TO-sis*	Accumulation of ketone bodies, such as acetone, in the body; usually results from deficiency or faulty metabolism of carbohydrates, as in cases of diabetes mellitus and starvation
multiple endocrine neoplasia (MEN)	A hereditary disorder that causes tumors in several endocrine glands; classified according to the combination of glands involved
pheochromocytoma *fe-o-kro-mo-si-TO-mah*	A usually benign tumor of the adrenal medulla or other structures containing chromaffin cells (cells that stain with chromium salts) (phe/o means "brown" or "dusky"); the adrenal tumor causes increased production of epinephrine
pituitary apoplexy *AP-o-plek-se*	Sudden massive hemorrhage and degeneration of the pituitary gland associated with a pituitary tumor; common symptoms include severe headache, visual problems, and loss of consciousness
seasonal affective disorder (SAD)	A mood disorder with lethargy, depression, excessive need for sleep, and overeating that generally occurs in winter; thought to be related to melatonin levels as influenced by environmental light (**BOX 9-6**)
Simmonds disease	Hypofunction of the anterior pituitary (panhypopituitarism), usually because of an infarction; pituitary cachexia (*ka-KEK-se-a*)
thyroid storm	A sudden onset of thyrotoxicosis symptoms occurring in patients with hyperthyroidism who are untreated or poorly treated; may be brought on by illness or trauma; also called thyroid crisis
thyrotoxicosis *thi-ro-tok-sih-KO-sis*	Condition resulting from overactivity of the thyroid gland; symptoms include anxiety, irritability, weight loss, and sweating; the main example of thyrotoxicosis is Graves disease
von Recklinghausen disease *REK-ling-how-zen*	Bone degeneration caused by excess production of parathyroid hormone; also called Recklinghausen disease of bone

(continued)

extern.ir

Terminology *Enrichment Terms (Continued)*

Diagnosis and Treatment	
fasting plasma glucose (FPG)	Measurement of blood glucose after a fast of at least 8 hours; a reading equal to or greater than 126 mg/dL indicates diabetes; also called fasting blood glucose (FBG) or fasting blood sugar (FBS)
free thyroxine index (FTI, T_7)	Calculation based on the amount of T_4 present and T_3 uptake, used to diagnose thyroid dysfunction
oral glucose tolerance test (OGTT)	Measurement of glucose levels in blood plasma after administration of a challenge dose of glucose to a fasting patient; used to measure patient's ability to metabolize glucose; a value equal to or greater than 200 mg/dL in the two-hour sample indicates diabetes
radioactive iodine uptake test (RAIU)	A test that measures thyroid uptake of radioactive iodine as an evaluation of thyroid function
radioimmunoassay (RIA)	A method of measuring very small amounts of a substance, especially hormones, in blood plasma using radioactively labeled hormones and specific antibodies
thyroid scan	Visualization of the thyroid gland after administration of radioactive iodine
thyroxine-binding globulin (TBG) test	Test that measures the main protein that binds T_4 in the blood
transsphenoidal adenomectomy *trans-sfe-NOY-dal ad-eh-no-MEK-to-me*	Removal of a pituitary tumor through the sphenoid sinus (space in the sphenoid bone)

CLINICAL PERSPECTIVES

BOX 9-6

Seasonal Affective Disorder: Some Light on the Subject

We all sense that long dark days make us blue and sap our motivation. Are these learned responses, or is there a physical basis for them? Studies have shown that the amount of light in the environment does have a physical effect on behavior. Evidence that light alters mood comes from people who are intensely affected by the dark days of winter—people who suffer from *seasonal affective disorder*, aptly abbreviated SAD. When days shorten, these people feel sleepy, depressed, and anxious. They tend to overeat, especially carbohydrates.

As light strikes the retina of the eye, it starts nerve impulses that decrease the amount of melatonin produced by the pineal gland in the brain. Because melatonin depresses mood, the final effect of light is to elevate mood. Daily exposure to bright lights has been found to improve the mood of most people with SAD. Exposure for 15 minutes after rising in the morning may be enough, but some people require longer sessions both morning and evening. Other aids include aerobic exercise, stress management techniques, and antidepressant medications.

extern.ir

Terminology *Abbreviations*

The abbreviations listed below are emphasized in this chapter. These are also found, collectively, with all chapter abbreviations in Appendix 2.

A1c	Glycated hemoglobin (test)
ACTH	Adrenocorticotropic hormone
ADH	Antidiuretic hormone
BS	Blood sugar
CSII	Continuous subcutaneous insulin infusion
DM	Diabetes mellitus
FBG	Fasting blood glucose
FBS	Fasting blood sugar
FPG	Fasting plasma glucose
FSH	Follicle-stimulating hormone
FTI	Free thyroxine index
GDM	Gestational diabetes mellitus
GH	Growth hormone
HbA1c	Hemoglobin A1c; glycated hemoglobin
^{131}I	Iodine-131 (radioactive iodine)
IFG	Impaired fasting blood glucose
IGT	Impaired glucose tolerance
LH	Luteinizing hormone
MEN	Multiple endocrine neoplasia
NPH	Neutral protamine Hagedorn (insulin)
OGTT	Oral glucose tolerance test
PRL	Prolactin
PTH	Parathyroid hormone
RAIU	Radioactive iodine uptake
RIA	Radioimmunoassay
SIADH	Syndrome of inappropriate antidiuretic hormone (secretion)
T1DM	Type 1 diabetes mellitus
T2DM	Type 2 diabetes mellitus
T_3	Triiodothyronine
T_4	Thyroxine; tetraiodothyronine
T_7	Free thyroxine index
TBG	Thyroxine-binding globulin
TSH	Thyroid-stimulating hormone

Case Study Revisited

Jasmine's Follow-Up

Jasmine stopped by her local pharmacy to pick up her prescription for Tapazole. She asked the pharmacist to clarify the information Dr. Gilbert had given her about the medication. The pharmacist told Jasmine that Tapazole (generic name: methimazole) acts to prevent the thyroid gland from producing too much thyroid hormone. Some common side effects include nausea, vomiting, upset stomach; headache, dizziness, drowsiness; muscle or joint pain, and decreased sense of taste. Jasmine was told to get emergency help if she had signs of an allergic reaction: hives, difficulty breathing, swelling of the face, lips, tongue, or throat. The pharmacist dispensed the medication and emphasized the importance of following the directions on the prescription label. Since Jasmine was around young school children during the day the medication was dispensed in a child proof container.

After beginning her antithyroid medication therapy Jasmine began to feel better and told her husband she was able to concentrate more at work and found she was not as irritable with the children in school. She was sleeping better and began to add a few of the pounds she had previously lost. Her husband said he also noticed the difference. At her follow-up appointment with Dr. Gilbert, Jasmine was told that the medication was working. Her dosage would be the same over the next several months and would be reevaluated at her next appointment.

extern.ir

CHAPTER 9

Review

This review tests your understanding of the content introduced in this chapter. Follow the instructions for each exercise and check your answers in Appendix 11.

LABELING EXERCISE

GLANDS OF THE ENDOCRINE SYSTEM

Write the name of each numbered part on the corresponding line.

Adrenals
Hypothalamus
Ovaries
Pancreatic islets
Parathyroids
Pineal
Pituitary (hypophysis)
Testes
Thyroid

1. _____
2. _____
3. _____
4. _____
5. _____
6. _____
7. _____
8. _____
9. _____

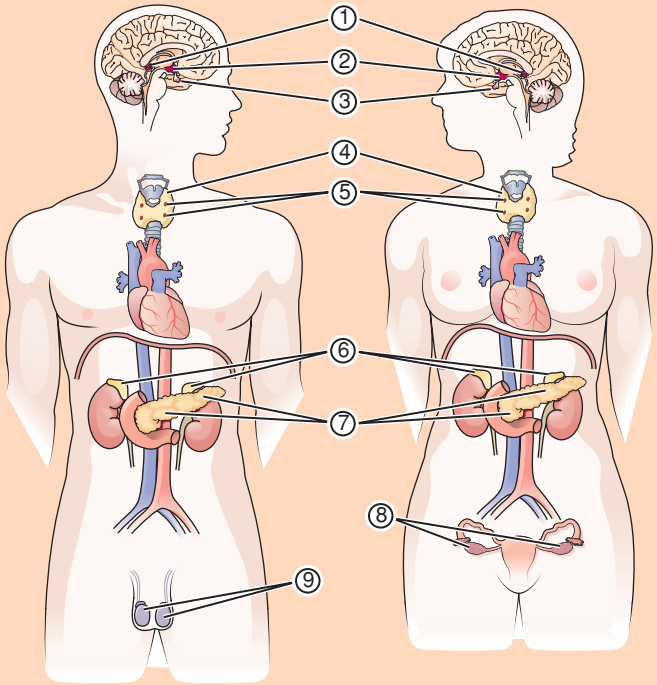

TERMINOLOGY

MATCHING

Match the following terms, and write the appropriate letter to the left of each number.

____	1. parathyroid	a. gland that is regulated by light
____	2. posterior pituitary	b. small gland that acts to increase blood calcium levels
____	3. hypothalamus	c. part of the brain that controls the pituitary
____	4. anterior pituitary	d. gland that secretes ACTH
____	5. pineal	e. gland that releases oxytocin

____	6. epinephrine	a. hormone produced by the adrenal cortex
____	7. growth hormone	b. somatotropin
____	8. cortisol	c. pancreatic hormone that regulates glucose metabolism
____	9. glucagon	d. hormone produced by the adrenal medulla
____	10. melatonin	e. hormone from the pineal gland

extern.ir

____ 11. ADH
____ 12. T_4
____ 13. ACTH
____ 14. T2DM
____ 15. HbA1c

a. substance used to monitor blood glucose levels
b. pituitary hormone that regulates water balance
c. a form of diabetes
d. thyroxine
e. hormone that stimulates the adrenal cortex

____ 16. ketoacidosis
____ 17. adenoma
____ 18. Cushing syndrome
____ 19. acromegaly
____ 20. diabetes insipidus

a. disorder that results from excess growth hormone
b. disorder caused by insufficient release of ADH
c. a result of uncontrolled diabetes
d. disorder caused by overactivity of the adrenal cortex
e. neoplasm of a gland

Enrichment Terms

____ 21. craniopharyngioma
____ 22. Simmonds disease
____ 23. pheochromocytoma
____ 24. Hashimoto disease
____ 25. sella turcica

a. panhypopituitarism
b. tumor of the pituitary gland
c. chronic thyroiditis
d. bony depression that holds the pituitary
e. tumor of the adrenal medulla

FILL IN THE BLANKS

Complete the sentence with the correct term(s).

26 The gland under the brain that controls other glands is the _____ .

27. The gland in the neck that affects metabolic rate is the _____ .

28. The endocrine glands located above the kidneys are the _____ .

29. The most common endocrine disorder is _____ .

30. Excess glucose in the blood is called _____ .

DEFINITIONS

Define the following words.

31. thyrotomy (*thi-ROT-o-me*) _____

32. hypopituitarism (*hi-po-pih-TU-ih-tah-rizm*) _____

33. hypophysiotropic (*hi-po-fiz-e-o-TROP-ik*) _____

34. adrenopathy (*ah-dre-NOP-ah-the*) _____

35. adrenomegaly (*ah-dre-no-MEG-ah-le*) _____

36. endocrinologist (*en-do-krih-NOL-o-jist*) _____

Write words for the following definitions.

37. tumor of the pancreatic islets _____

38. destroying the thyroid gland _____

39. pertaining to the adrenal cortex _____

Use the full name of the gland as the root to write words for the following definitions.

40. inflammation of the thyroid gland _____

41. removal of one half (hemi-) of the thyroid gland _____

42. surgical removal of parathyroid gland _____

43. overactivity of the adrenal gland _____

extern.ir

Use the root thyr/o to write words for the following definitions.

44. acting on the thyroid gland _____
45. downward displacement of the thyroid gland _____
46. any disease of the thyroid gland _____

TRUE–FALSE

Examine the following statements. If the statement is true, write T in the first blank. If the statement is false, write F in the first blank, and correct the statement by replacing the underlined word in the second blank.

	True or False	Correct Answer
47. Diabetes insipidus is caused by a lack of <u>thymosin</u>.	_____	_____
48. The hypophysis is the <u>pituitary</u> gland.	_____	_____
49. The outer region of an organ is the <u>medulla</u>.	_____	_____
50. The parathyroids regulate the element <u>sodium</u>.	_____	_____
51. Goiter is an enlargement of the <u>pineal</u> gland.	_____	_____
52. <u>Type 1</u> diabetes mellitus always requires insulin.	_____	_____
53. Thyroid hormones contain the element <u>iodine</u>.	_____	_____
54. The adrenal cortex produces <u>steroid</u> hormones.	_____	_____
55. Exophthalmos is protrusion of the <u>eyes</u>.	_____	_____
56. <u>Melatonin</u> regulates mood and daily cycles.	_____	_____

ELIMINATIONS

In each of the sets below, underline the term that does not fit in with the rest, and explain the reason for your choice.

57. GH — TSH — FSH — PTH — ACTH

_____

58. Cushing syndrome — gigantism — dwarfism — acromegaly — thyrotoxicosis

_____

59. TBG — GDM — FPG — IGT — IFG

_____

60. testis — spleen — adrenals — parathyroids — pituitary

_____

WORD BUILDING

Write words for the following definitions using the word parts provided. Each word part can be used more than once.

-ar	adren/o	-megal/o	-oma	thyr/o	-ic	-al	trop	-y	insul/o	path/o	-lytic

61. any disease of the thyroid gland _____
62. acting on the adrenal gland _____
63. enlargement of the thyroid gland _____
64. pertaining to the gland above the kidney _____
65. enlargement of the adrenal gland _____
66. tumor of islet cells _____

extern.ir

67. destructive of thyroid tissue _____
68. any disease of the adrenal gland _____
69. acting on the thyroid gland _____
70. pertaining to pancreatic islet cells _____

WORD ANALYSIS

Define each of the following words, and give the meaning of the word parts in each. Use a dictionary if necessary.

71. craniopharyngioma (*kra-ne-o-fah-rin-je-O-mah*)
    a. crani/o _____
    b. pharyng/i _____
    c. -oma _____
72. panhypopituitarism (*pan-hi-po-pih-TU-ih-tah-rism*)
    a. pan- _____
    b. hypo- _____
    c. pituitar _____
    d. -ism _____
73. pheochromocytoma (*fe-o-kro-mo-si-TO-mah*)
    a. phe/o _____
    b. chrom/o _____
    c. cyt/o _____
    d. -oma _____
74. thyrotoxicosis (*thi-ro-tok-sih-KO-sis*)
    a. thyr/o _____
    b. toxic/o _____
    c. -sis _____
75. acromegaly
    a. acr/o _____
    b. megal/o _____
    c. y _____

NAME THE GLAND

Identify the gland associated with the following conditions.

76. diabetes mellitus _____
77. Addison disease _____
78. Graves disease _____
79. tetany _____
80. Simmonds disease _____

extern.ir

Additional Case Studies

Case Study 9-1: Hyperparathyroidism

Beth, a 58 y/o woman with a history of hypertension (HTN), had a partial nephrectomy 4 years ago for renal calculi. During a routine physical examination, her total serum calcium level was 10.8 mg/dL. Her parathyroid hormone level was WNL; she was in no apparent distress, and the remainder of her physical examination and laboratory data were noncontributory.

Beth underwent exploratory surgery for an enlarged right superior parathyroid gland. The remaining three glands appeared normal. The enlarged gland was excised, and a biopsy was performed on the remaining glands. The pathology report showed an adenoma of the abnormal gland. On her first postoperative day, she reported perioral numbness and tingling. She had no other symptoms, but her serum calcium level was subnormal. She was given one ampule of calcium gluconate. Within 2 days, her calcium level had improved, and she was discharged.

Case Study 9-1 Questions

Follow the instructions for each question and check your answers in Appendix 11.

Multiple Choice. *Select the best answer, and write the letter of your choice to the left of each number.*

_____ 1. Renal calculi are
   a. kidney stones
   b. gallstones
   c. stomach ulcers
   d. bile obstructions

_____ 2. Beth's serum calcium was 10.8 mg/dL, which is
   a. 5.4 µg of calcium in her serous fluid
   b. 10.8 g of electrolytes in parathyroid hormone
   c. 10.8 mg of calcium in 100 mL of blood
   d. 21.6 L of calcium in 100 g of serum

_____ 3. Beth had perioral numbness and tingling. Perioral is
   a. peripheral to any orifice
   b. lateral to the eye
   c. within the buccal mucosa
   d. around the mouth

Write the terms from the case study with the following meanings.

4. surgical excision of a kidney _____

5. tumor of a gland _____

6. single-use glass injectable medication container _____

Define the following abbreviations.

7. HTN _____

8. WNL _____

extern.ir

Case Study 9-2: Diabetes Treatment With an Insulin Pump

Maria, a 32 y/o marketing executive, was diagnosed with type 1 diabetes at the age of 3. She vividly remembers her mother taking her to the doctor because she had an illness that caused her to feel extremely tired and very thirsty and hungry. She also had begun to wet her bed and had a cut on her knee that would not heal. Her mother had had gestational diabetes during her pregnancy with Maria, and at birth, Maria was described as having "macrosomia" because she weighed 10 pounds.

Maria has managed her disease with meticulous attention to her diet, exercise, preventive health care, regular blood glucose monitoring, and twice-daily injections of regular and NPH insulin, which she rotates among her upper arms, thighs, and abdomen. She continues in a smoking cessation program supported by weekly acupuncture treatments. She maintains good control of her disease in spite of the inconvenience and time it consumes each day. She will be married next summer and would like to start a family. Maria's doctor suggested she try an insulin pump to give her more freedom and enhance her quality of life. After intensive training, she has received her pump. It is about the size of a deck of cards with a thin catheter that she introduces through a needle into her abdominal subcutaneous tissue. She can administer her insulin in a continuous subcutaneous insulin infusion (CSII) and in calculated meal bolus doses. She still has to test her blood for hyperglycemia and hypoglycemia and her urine for ketones when her blood glucose is too high. She hopes one day to have an islet transplantation.

Case Study 9-2 Questions

Follow the instructions for each question and check your answers in Appendix 11.

Multiple Choice. *Select the best answer, and write the letter of your choice to the left of each number.*

_____ 1. Gestational diabetes occurs
- a. in a pregnant woman
- b. to any large fetus
- c. during menopause
- d. in a large baby with high blood glucose

_____ 2. The term macrosomia describes
- a. excessive weight gain during pregnancy
- b. a large body
- c. an excessive amount of sleep
- d. inability to sleep during pregnancy

_____ 3. Maria injected the insulin into the subcutaneous tissue, which is
- a. present only in the abdomen, thighs, and upper arms
- b. a topical application
- c. below the skin
- d. above the pubic bone

_____ 4. An islet transplantation refers to
- a. transfer of insulin-secreting cells into a pancreas
- b. transfer of parathyroid cells to the liver
- c. surgical insertion of an insulin pump into the abdomen
- d. a total pancreas and kidney transplantation

Write the terms from the case study with the following meanings.

5. high serum glucose _____
6. a large dose of a therapeutic agent _____

Define the following abbreviations.

7. NPH _____
8. CSII _____

extern.ir

CHAPTER 10

Cardiovascular and Lymphatic Systems

Pretest

Multiple Choice. **Select the best answer, and write the letter of your choice to the left of each number. To check your answers go to Appendix 11.**

_____ 1. The cardiovascular system includes the heart and
a. lungs
b. digestive organs
c. blood vessels
d. endocrine system

_____ 2. The thick, muscular layer of the heart wall is the
a. endocardium
b. valve
c. myocardium
d. apex

_____ 3. An upper chamber of the heart is a(n)
a. ventricle
b. atrium
c. base
d. systole

_____ 4. A vessel that carries blood away from the heart is a(n)
a. vein
b. chamber
c. lymph node
d. artery

_____ 5. The tonsils, spleen, and thymus are part of the
a. digestive system
b. endocrine system
c. epicardium
d. lymphatic system

_____ 6. The medical term for a "heart attack" is
a. cerebrovascular accident
b. myocardial infarction
c. aneurysm
d. pneumonia

_____ 7. The accumulation of fatty deposits in the lining of a vessel is called
a. obesity
b. stent
c. atherosclerosis
d. angiogenesis

_____ 8. Phlebitis is inflammation of a
a. vein
b. heart
c. blood cell
d. nerve

extern.ir

Learning Objectives

After careful study of this chapter, you should be able to:

1. Describe the structure of the heart. ***P317***
2. Trace the path of blood flow through the heart. ***P317***
3. Trace the path of electrical conduction through the heart. ***P319***
4. Identify the components of an electrocardiogram. ***P319***
5. Differentiate among arteries, arterioles, capillaries, venules, and veins. ***P321***
6. Explain blood pressure and describe how blood pressure is measured. ***P321***
7. Identify and use the roots pertaining to the cardiovascular and lymphatic systems. ***PP326, 340***
8. Describe the main disorders that affect the cardiovascular and lymphatic systems. ***PP328, 341***
9. Define medical terms pertaining to the cardiovascular and lymphatic systems. ***PP334, 342***
10. List the functions and components of the lymphatic system. ***P337***
11. Interpret medical abbreviations referring to circulation. ***P346***
12. Analyze medical terms in case studies involving circulation. ***PP315, 354***

Case Study: Carlos's Arrhythmia During Army Boot Camp

Chief Complaint

Carlos, a 19 y/o man recently enlisted into the army, successfully passed the army physicals and reported to Fort Knox for basic training. The first 2 weeks were uneventful as Carlos became acclimated to the vigorous daily schedules of army life. As the physical training progressed, the platoon would go on long runs in full gear. Carlos passed out during two of these runs. The first time he was taken to the infirmary, where he was examined, cleared, and returned to duty. With the second incident, he was put on a sick leave and sent home for additional follow-up.

Examination

When Carlos came home, his family took him to see his primary care physician, who referred him to a cardiologist. Carlos explained to the physician that on some of the long, rigorous runs with full gear he would become short of breath and feel his heart start to race. He would then become dizzy and pass out. When he woke up, he would be lying on the ground with his sergeant standing over him.

The physician ordered some laboratory tests and also a Holter monitor that Carlos was to wear for the next 48 hours. The physician explained that the Holter monitor is a portable electrocardiogram (ECG) that continuously records the heart's electrical activity. Electrodes (small, plastic patches that stick to the skin) were placed at certain locations on Carlos's chest and abdomen. The electrodes were attached to the small ECG box by wires. The physician further explained to Carlos and his family that he suspected an abnormal heartbeat had caused the fainting spells. The monitor would record any arrhythmias or other abnormalities that might occur during the next 48 hours. He told Carlos to keep a diary of his activities and symptoms during the test.

Clinical Course

At the conclusion of the 48-hour test, Carlos saw the cardiologist again. The results of the Holter monitor indicated that he had an abnormal heart rhythm known as atrial fibrillation. The physician explained the two methods of treatment for the condition: a medical approach using anticoagulants to prevent blood clots and medication to slow the heart rate, and a surgical procedure called an ablation. It was decided after reviewing the test results and discussion with family on the pros and cons of the various treatment options that a pulmonary vein catheter ablation was the treatment of choice for Carlos.

Case Study Revisited: Once you complete this chapter, please review the case follow-up on p. 347.

extern.ir

Ancillaries *At-A-Glance*

Visit the web resource to access the following resources.

Learning Resources

- eBook
- A&P Module with Heart & Lung Sounds
- Image Bank
- TestPrep
- Animations
- Audio Pronunciation Glossary

Introduction

Blood circulates throughout the body in the **cardiovascular system**, which consists of the **heart** and the blood **vessels** (FIG. 10-1). This system forms a continuous circuit that delivers oxygen and nutrients to all cells and carries away waste products. The lymphatic system also functions in circulation. Its vessels drain fluid and proteins left in the tissues and return them to the bloodstream. The lymphatic system plays a part in immunity and in the digestive process as well, as explained in Chapters 11 and 13. This chapter discusses the circulatory system in detail, in both its normal and clinical aspects, and then proceeds to study the lymphatic system.

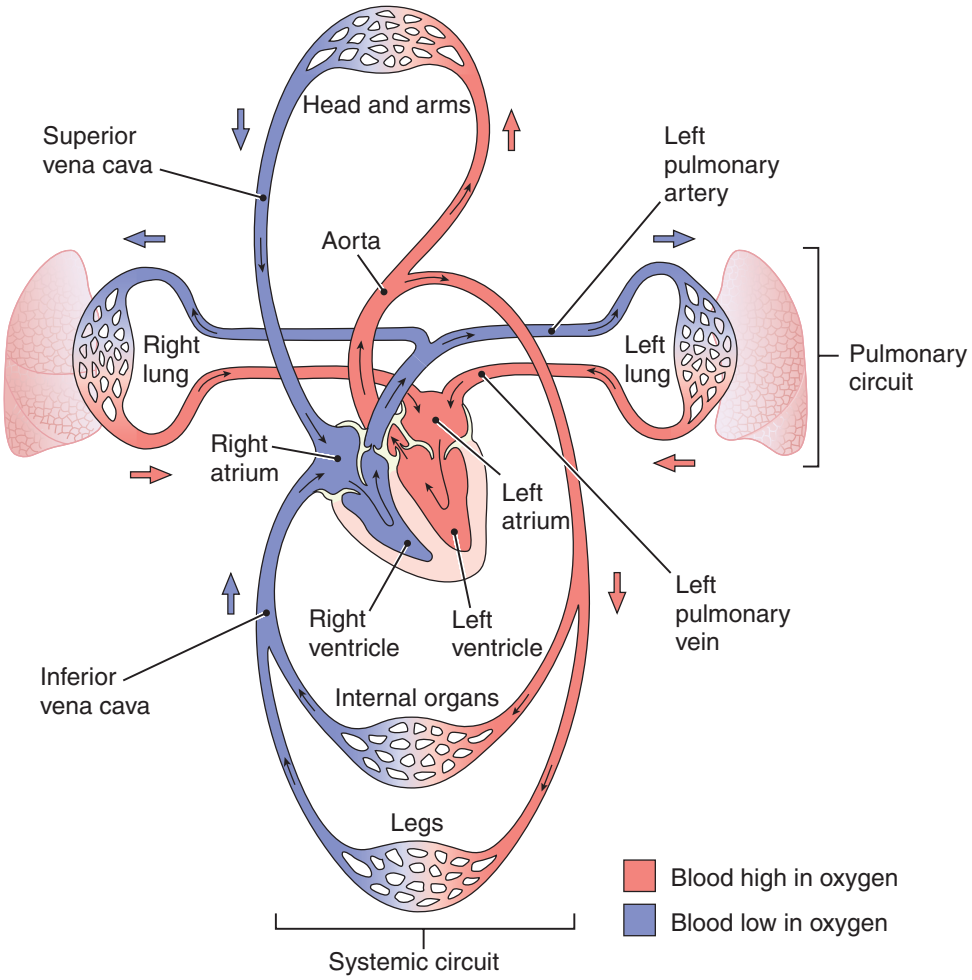

FIGURE 10-1 The cardiovascular system. The pulmonary circuit carries blood to and from the lungs; the systemic circuit carries blood to and from all other parts of the body.

extern.ir

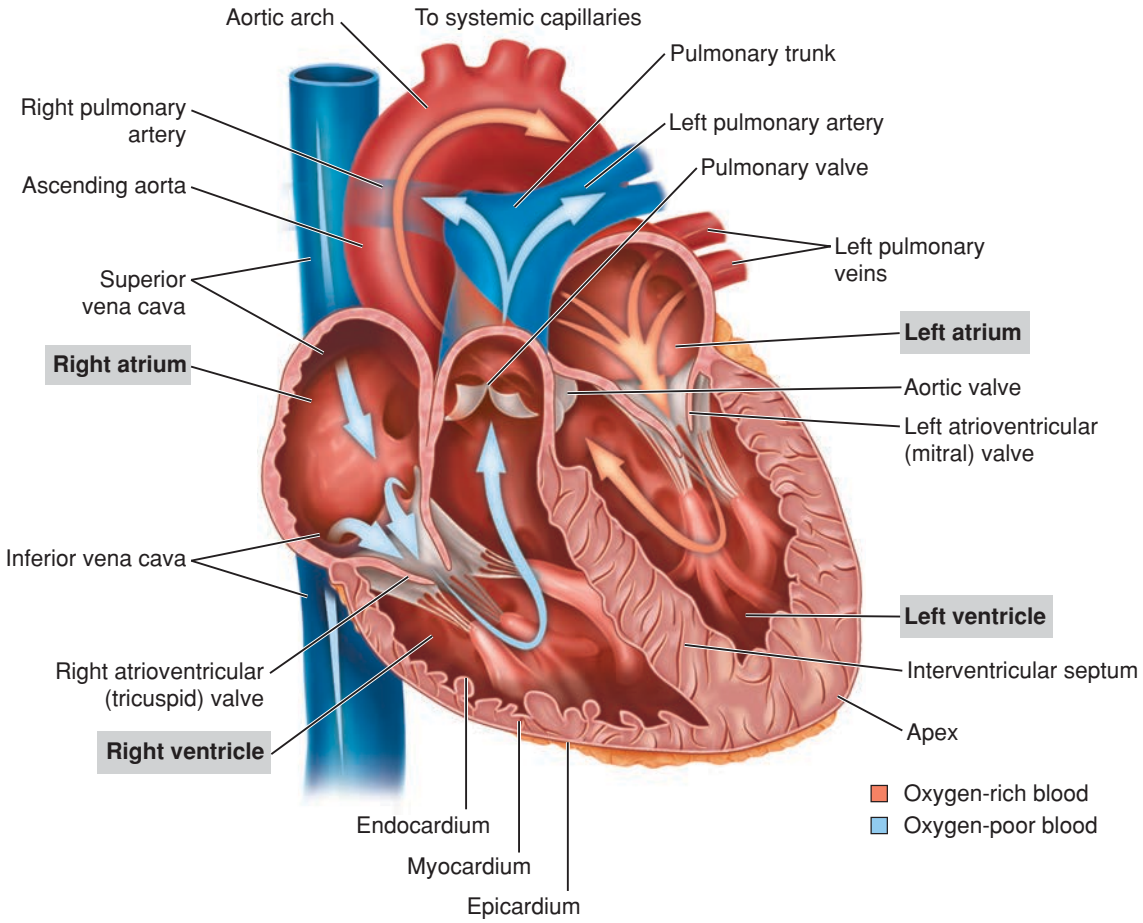

FIGURE 10-2 The heart and great vessels. The *arrows* show the direction of blood flow through the heart. The right heart has blood low in oxygen; the left heart has blood high in oxygen.

The Heart

The heart is located between the lungs, with its point, or **apex**, directed toward the inferior and left (FIG. 10-2). The wall of the heart consists of three layers, all named with the root *cardi*, meaning "heart." Moving from the innermost to the outermost layer, these are the:

1. **Endocardium**—a thin membrane that lines the chambers and valves (the prefix *endo-* means "within").
2. **Myocardium**—a thick muscle layer that makes up most of the heart wall (the root *my/o* means "muscle").
3. **Epicardium**—a thin membrane that covers the heart (the prefix *epi-* means "on").

A fibrous sac, the **pericardium**, contains the heart and anchors it to surrounding structures, such as the sternum (breastbone) and diaphragm (the prefix *peri-* means "around").

Each of the heart's upper receiving chambers is an **atrium** (plural: atria). Each of the lower pumping chambers is a **ventricle** (plural: ventricles). The chambers of the heart are divided by walls, each of which is called a **septum.** The interventricular septum separates the two ventricles; the interatrial septum divides the two atria. There is also a septum between the atrium and ventricle on each side.

The heart pumps blood through two circuits. The right side pumps blood to the lungs to be oxygenated through the **pulmonary circuit.** The left side pumps to the remainder of the body through the **systemic circuit** (see FIG. 10-1).

BLOOD FLOW THROUGH THE HEART

The pathway of blood through the heart is shown by the arrows in FIGURE 10-2. The sequence is as follows.

1. The right atrium receives blood low in oxygen from all body tissues through the **superior vena cava** and the **inferior vena cava.**
2. The blood then enters the right ventricle and is pumped to the lungs through the **pulmonary artery.**
3. Blood returns from the lungs high in oxygen and enters the left atrium through the **pulmonary veins.**
4. Blood enters the left ventricle and is forcefully pumped into the **aorta** to be distributed to all tissues.

One-way **valves** in the heart keep blood moving in a forward direction. The valves between the atrium and ventricle on each side are the **atrioventricular** (AV) **valves** (see FIG. 10-2).

extern.ir

The valve between the right atrium and ventricle is the **right AV valve**, also known as the tricuspid valve because it has three cusps (flaps). The valve between the left atrium and ventricle is the **left AV valve**, which is a bicuspid valve with two cusps; it is often called the **mitral valve** (named for a miter, the pointed, two-sided hat worn by bishops).

The valves leading into the pulmonary artery and the aorta have three cusps. Each cusp is shaped like a half-moon, so these valves are described as *semilunar valves* (*lunar* refers to the moon). The valve at the entrance to the pulmonary artery is specifically named the **pulmonary valve;** the valve at the entrance to the aorta is the **aortic valve.**

Heart sounds are produced as the heart functions. The loudest of these, the familiar "lub" and "dup" that can be heard through the chest wall, are produced by alternate closings of the valves. The first heart sound (S_1) is heard when the valves between the chambers close. The second heart sound (S_2) is produced when the valves leading into the aorta and pulmonary artery close. Any sound made as the heart functions normally is termed a **functional murmur.** (The word *murmur* used alone with regard to the heart describes an abnormal sound.)

BLOOD SUPPLY TO THE MYOCARDIUM

Only the endocardium comes into contact with the blood that flows through the heart chambers. Therefore, the myocardium must have its own blood vessels to provide oxygen and nourishment and to remove waste products. Together, these blood vessels form the **coronary circulation**. The main arteries that supply blood to the heart muscle are the right and left coronary arteries **(FIG. 10-3)**, named because they encircle the heart like a crown. These arteries, which are the first to branch off the aorta, arise just above the cusps of the aortic valve and branch to all regions of the heart muscle. They receive blood only when the ventricles relax because the aortic valve must be closed to expose the entrance to these vessels. The left coronary artery (LCA) branches into the circumflex artery and the left anterior descending (LAD) artery (also known as the anterior interventricular branch of the LCA). The right coronary artery (RCA) snakes around the heart just inferior to the right atrium, giving off a major branch called the posterior descending artery (also known as the posterior interventricular artery). After passing through the capillaries in the myocardium, blood drains into a system of cardiac veins that brings blood back toward the right atrium. Blood finally collects in the coronary sinus, a dilated vein that opens into the right atrium near the inferior vena cava.

THE HEARTBEAT

Each contraction of the heart, termed **systole** (*SIS-to-le*), is followed by a relaxation phase, **diastole** (*di-AS-to-le*), during which the chambers fill. Each time the heart beats,

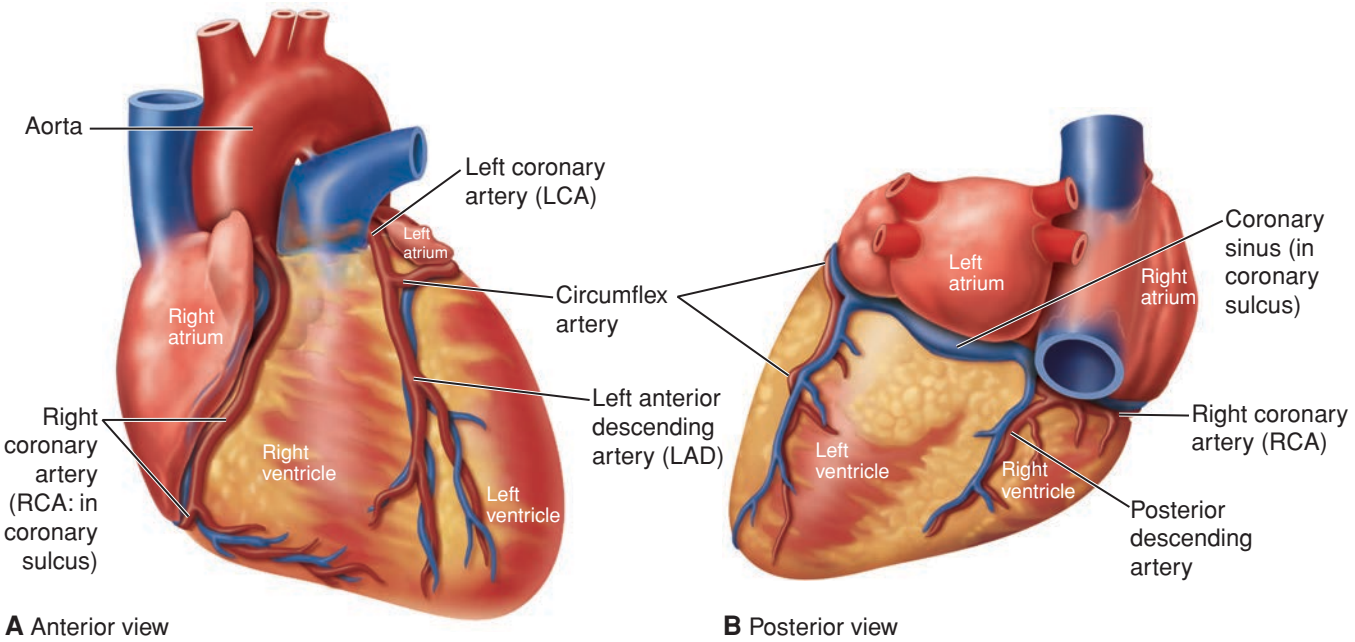

A Anterior view **B** Posterior view

FIGURE 10-3 Blood vessels that supply the myocardium. Coronary arteries and cardiac veins constitute the heart's circulatory pathways. **A.** Anterior view. **B.** Posterior view.

extern.ir

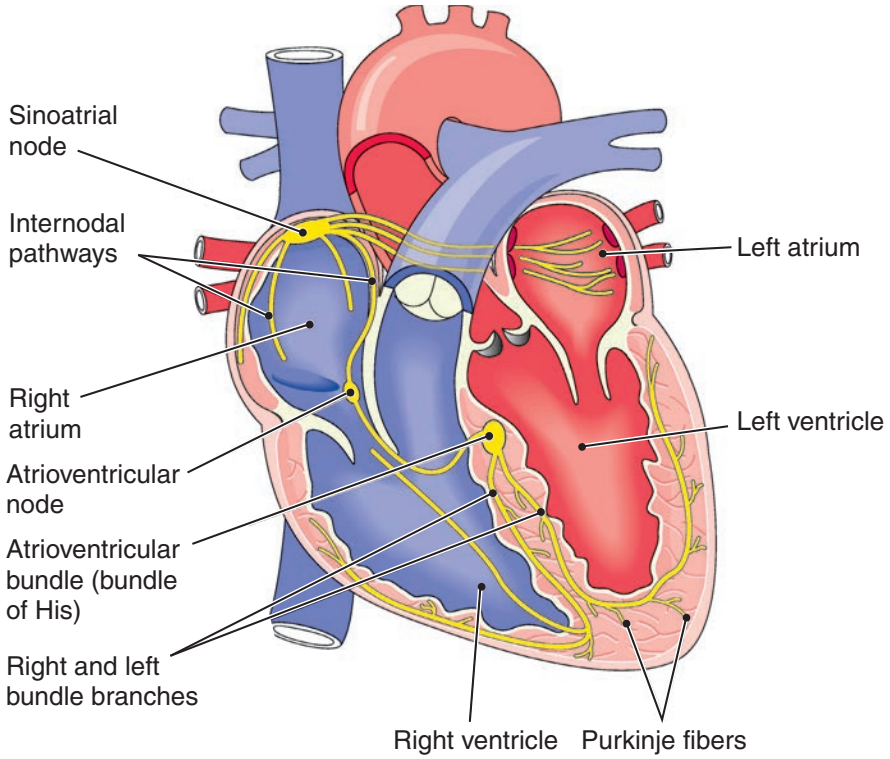

FIGURE 10-4 The heart's electrical conduction system. Impulses travel from the sinoatrial (SA) node to the atrioventricular (AV) node, then to the atrioventricular bundle, bundle branches, and Purkinje fibers. Internodal pathways carry impulses throughout the atria.

both atria contract, and immediately thereafter both ventricles contract. The number of times the heart contracts per minute is the **heart rate.** The wave of increased pressure produced in the vessels each time the ventricles contract is the **pulse.** Pulse rate is usually counted by palpating a peripheral artery, such as the radial artery at the wrist or the carotid artery in the neck (see **FIG. 3-9**).

Cardiac contractions are stimulated by a built-in system that regularly transmits electrical impulses through the heart. The components of this conduction system are shown in **FIGURE 10-4**. In the sequence of action, they include the:

1. **Sinoatrial (SA) node,** located in the upper right atrium and called the *pacemaker* because it sets the rate of the heartbeat.
2. **Atrioventricular (AV) node,** located at the bottom of the right atrium near the ventricle. Internodal fibers between the SA and AV nodes carry stimulation throughout both atria.
3. **AV bundle** (bundle of His) at the top of the interventricular septum.
4. Left and right **bundle branches,** which travel along the left and right sides of the septum.
5. **Purkinje** (*pur-KIN-je*) **fibers,** which carry stimulation throughout the walls of the ventricles (see information on naming in **BOX 10-1**).

Although the heart itself generates the heartbeat, factors such as nervous system stimulation, hormones, and drugs can influence the rate and the force of contractions.

ELECTROCARDIOGRAPHY

Electrocardiography (ECG) measures the heart's electrical activity as it functions **(FIG. 10-5)**. Electrodes (leads) placed on the body's surface detect the electrical signals, which are then amplified and recorded as a tracing. A normal, or **sinus rhythm,** which originates at the SA node, is shown in **FIGURE 10-5A**. **FIGURE 10-5B** shows the letters assigned to individual components of one complete cycle:

1. The P wave represents electrical change, or **depolarization,** of the atrial muscles.
2. The QRS component shows depolarization of the ventricles.
3. The T wave shows return, or **repolarization,** of the ventricles to their resting state. Atrial repolarization is hidden by the QRS wave.
4. The small U wave, if present, follows the T wave. It is of uncertain origin.

An *interval* measures the distance from one wave to the next; a *segment* is a smaller component of the tracing. Many heart disorders, some of which are described later in the chapter, appear as abnormalities in ECG components.

extern.ir

FOCUS ON WORDS
Name That Structure

BOX 10-1

An eponym (*EP-o-nim*) is a name that is based on the name of a person, usually the one who discovered a particular structure, disease, principle, or procedure. Everyday examples are graham cracker, Ferris wheel, and boycott. In the heart, the bundle of His and Purkinje fibers are part of that organ's electrical conduction system. Korotkoff sounds are heard in the vessels when taking blood pressure. Cardiovascular disorders named for people include the tetralogy of Fallot, a combination of four congenital heart defects; Raynaud disease of small vessels; and the cardiac arrhythmia known as Wolff–Parkinson–White syndrome. In treatment, Doppler echocardiography is named for a physicist of the 19th century. The Holter monitor and the Swan–Ganz catheter give honors to their developers.

In other systems, the islets of Langerhans are cell clusters in the pancreas that secrete insulin. The graafian follicle in the ovary surrounds a mature egg cell. The eustachian tube connects the middle ear to the throat.

Many disease names are eponymic: Parkinson and Alzheimer, which affect the brain; Graves, a disorder of the thyroid; Addison and Cushing, involving the adrenal cortex; and Down syndrome, a hereditary disorder. The genus and species names of microorganisms often are based on the names of their discoverers: *Escherichia, Salmonella, Pasteurella,* and *Rickettsia* to name a few.

Many reagents, instruments, and procedures are named for their developers too. The original name for a radiograph was roentgenograph (*RENT-jen-o-graf*), named for Wilhelm Roentgen, discoverer of x-rays. A curie is a measure of radiation, derived from the name of Marie Curie, a co-discoverer of radioactivity.

Although eponyms give honor to physicians and scientists of the past, they do not convey any information and may be more difficult to learn. There is a trend to replace these names with more descriptive ones; for example, auditory tube instead of eustachian tube, mature ovarian follicle for graafian follicle, pancreatic islets for islets of Langerhans, and trisomy 21 for Down syndrome.

A

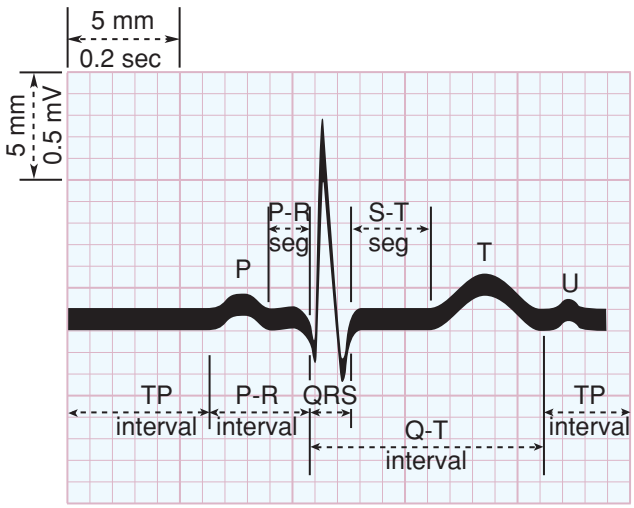

B

FIGURE 10-5 Electrocardiography (ECG). A. ECG tracing showing a normal sinus rhythm. **B.** Components of a normal ECG tracing. Shown are the P, QRS, T, and U waves, which represent electrical activity in different parts of the heart. Intervals measure from one wave to the next; segments are smaller components of the tracing.

extern.ir

The Vascular System

The vascular system consists of:

1. **Arteries** that carry blood away from the heart (FIG. 10-6)
2. **Arterioles,** vessels smaller than arteries that lead into the capillaries
3. **Capillaries,** the smallest vessels, through which exchanges take place between the blood and the tissues
4. **Venules,** small vessels that receive blood from the capillaries and drain into the veins
5. **Veins** that carry blood back to the heart (FIG. 10-7)

All arteries, except the pulmonary artery (and the umbilical artery in the fetus), carry highly oxygenated blood. They are thick-walled, elastic vessels that carry blood under high pressure. All veins, except the pulmonary vein (and the umbilical vein in the fetus), carry blood low in oxygen. Veins have thinner, less elastic walls and tend to give way under pressure. Like the heart, veins have one-way valves that keep blood flowing forward. Veins are classified as superficial or deep. The deep veins usually parallel arteries and carry the same names (see FIG. 10-7).

Nervous system stimulation can cause the diameter of a vessel to increase (vasodilation) or decrease (vasoconstriction). These changes alter blood flow to the tissues and affect blood pressure.

BLOOD PRESSURE

Blood pressure (BP) is the force exerted by blood against the wall of a blood vessel. It falls as the blood travels away from the heart and is influenced by a variety of factors,

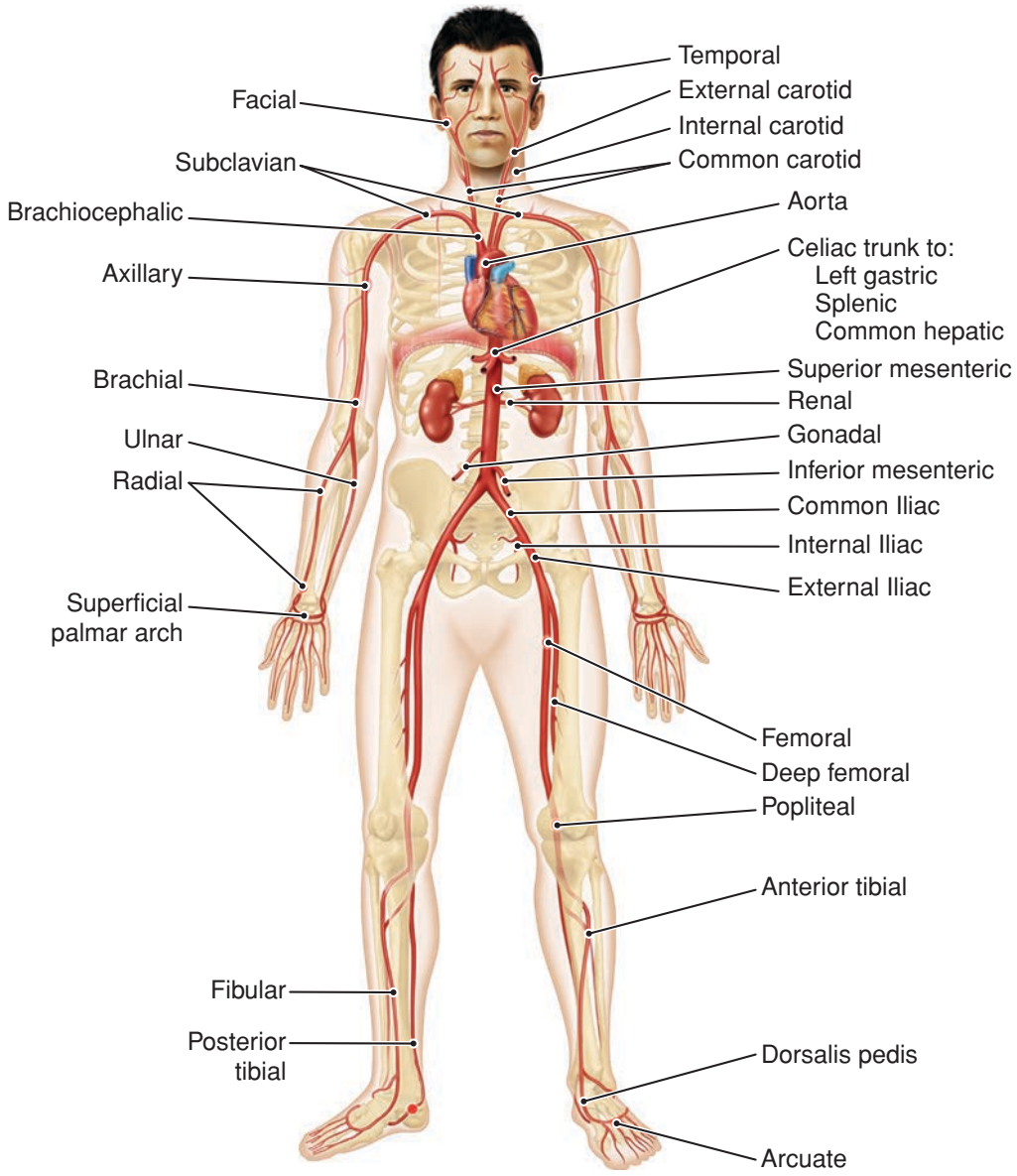

FIGURE 10-6 Principal systemic arteries.

extern.ir

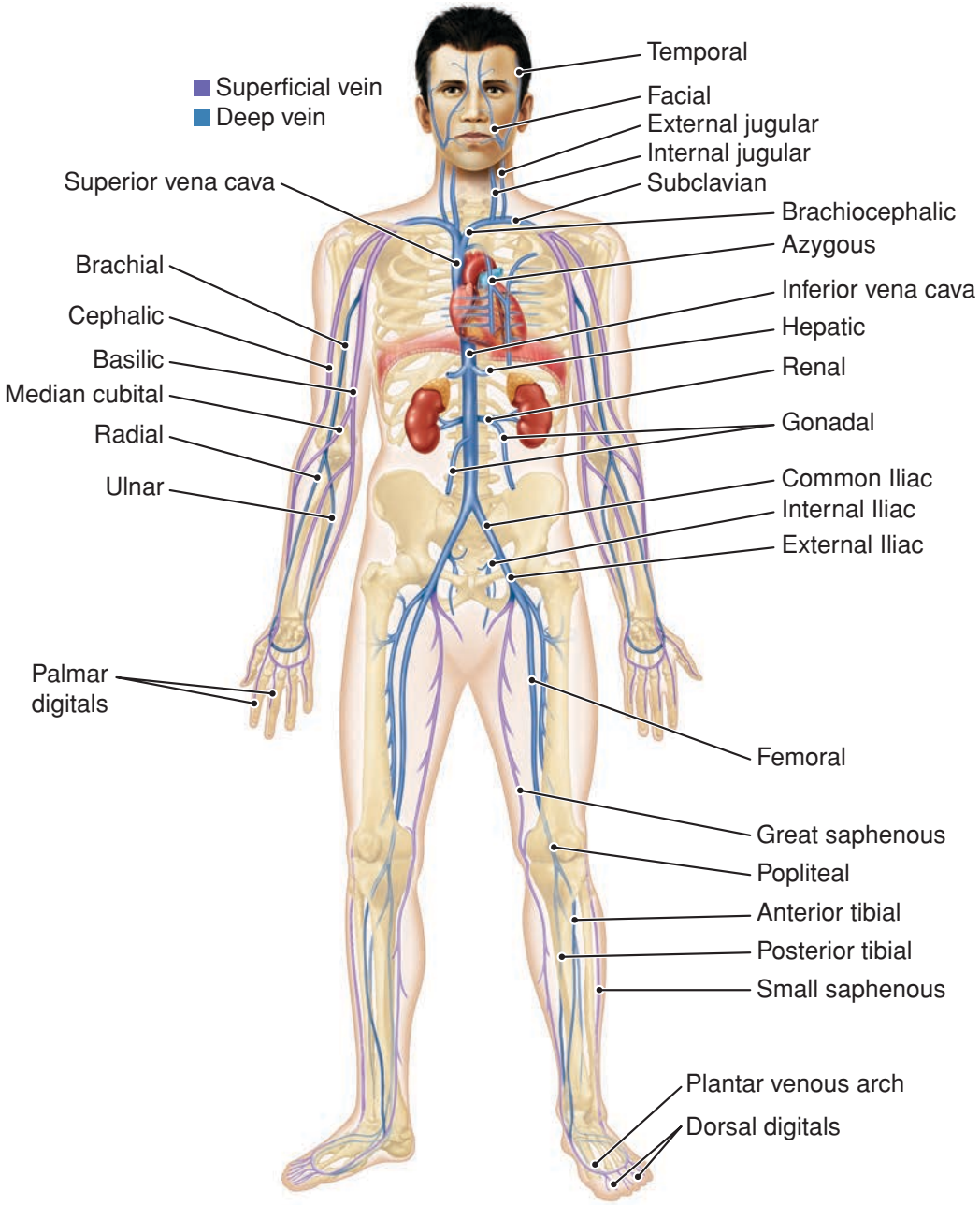

FIGURE 10-7 Principal systemic veins.

including cardiac output, vessel diameters, and total blood volume. Vasoconstriction increases BP in a vessel; vasodilation decreases pressure.

The most common site for BP measurement is the brachial artery of the arm. In taking blood pressure, both systolic (heart contracts) and diastolic (heart relaxes) pressures are measured.

The instrument used to measure blood pressure is a **sphygmomanometer** (*sfig-mo-mah-NOM-eh-ter*) **(FIG. 10-8)**, more simply called a blood pressure cuff or blood pressure apparatus. The sphygmomanometer is an inflatable cuff attached to a pressure gauge. Pressure is expressed in millimeters mercury (mm Hg), that is, the height to which the pressure can push a column of mercury in a tube. The examiner wraps the cuff around the patient's upper arm and inflates it with air until the brachial artery is compressed and the blood flow is cut off. Then, listening with a stethoscope, he or she slowly lets air out of the cuff until the first pulsations (Korotkoff sounds) are heard. At this point, the pressure in the cuff is equal to the systolic pressure, and this pressure is read. Then, more air is let out gradually until a characteristic muffled sound indicates that the vessel is open and the diastolic pressure is read off of a gauge or digital display. Newer devices measure blood pressure electronically:

extern.ir

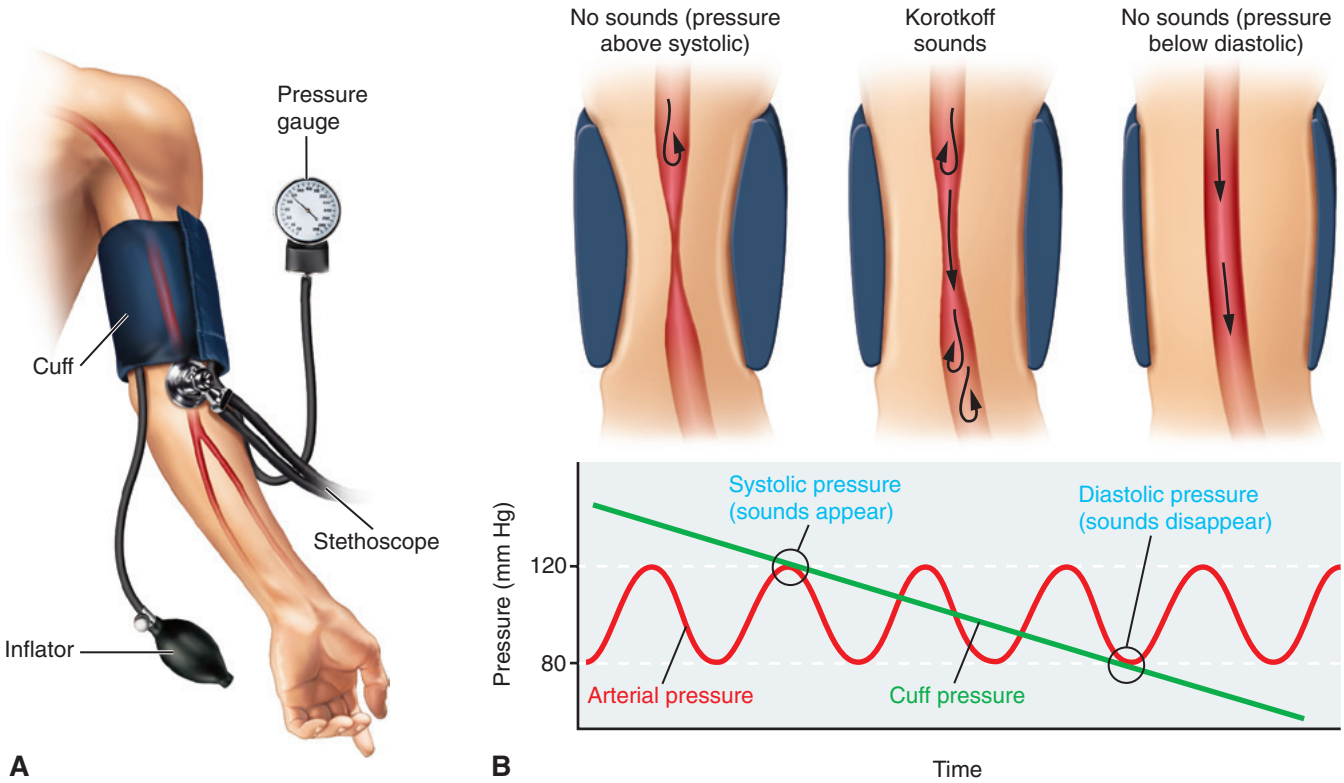

FIGURE 10-8 Measurement of blood pressure. A. A sphygmomanometer, or blood pressure cuff set to measure pressure in the left brachial artery. **B.** As the clinician lowers the cuff pressure, Korotkoff sounds begin at the systolic pressure and disappear at the diastolic pressure.

the examiner simply applies the cuff, which self-inflates and provides a digital reading. A typical normal systolic pressure is less than 120 mm Hg; a typical normal diastolic pressure is less than 80 mm Hg. Blood pressure is reported as systolic pressure first, then diastolic pressure, separated by a slash, such as 120/80. This reading would be reported verbally as "120 over 80." (See **BOX 10-2** for more information on blood pressure measurement.)

CLINICAL PERSPECTIVES

BOX 10-2

Hemodynamic Monitoring: Measuring Blood Pressure From Within

Because arterial blood pressure decreases as blood flows farther away from the heart, measurement of blood pressure with a simple inflatable cuff around the arm is only a reflection of the pressure in the heart and pulmonary arteries. Precise measurement of pressure in these parts of the cardiovascular system is useful in diagnosing certain cardiac and pulmonary disorders.

More accurate readings can be obtained using a catheter (thin tube) inserted directly into the heart and large vessels. One type commonly used is the pulmonary artery catheter (also known as the Swan–Ganz catheter), which has an inflatable balloon at the tip. This device is threaded into the right side of the heart through a large vein. Typically, the right internal jugular vein is used because it is the shortest and most direct route to the heart, but the subclavian and femoral veins may also be used. The catheter's position in the heart is confirmed by a chest x-ray, and when appropriately positioned, the atrial and ventricular blood pressures are recorded. As the catheter continues into the pulmonary artery, pressure in this vessel is readable. When the balloon is inflated, the catheter becomes wedged in a branch of the pulmonary artery, blocking blood flow. The reading obtained is called the pulmonary capillary wedge pressure (PCWP). It gives information on pressure in the heart's left side and on resistance in the lungs. Combined with other tests, hemodynamic monitoring with a Swan–Ganz catheter can be used to diagnose cardiac and pulmonary disorders such as shock, pericarditis, congenital heart disease, and heart failure.

extern.ir

Terminology Key Terms

The terms listed below are emphasized in this chapter. Knowing them will help you organize and prioritize your learning. These boldface terms are also found, collectively, with all chapter key terms in the Glossary.

Cardiovascular System

Normal Structure and Function

aorta *a-OR-tah*	The largest artery; it receives blood from the left ventricle and branches to all parts of the body (root: aort/o)
aortic valve *a-OR-tik*	The valve at the entrance to the aorta
apex *A-peks*	The point of a cone-shaped structure (adjective: apical); the apex of the heart is formed by the left ventricle and is pointed toward the inferior and left
artery *AR-teh-re*	A vessel that carries blood away from the heart; all except the pulmonary and umbilical arteries carry oxygenated blood (roots: arter, arteri/o)
arteriole *ar-TE-re-ole*	A small vessel that carries blood from the arteries into the capillaries (root: arteriol/o)
atrioventricular (AV) node *a-tre-o-ven-TRIK-u-lar*	A small mass in the lower septum of the right atrium that passes impulses from the sinoatrial (SA) node toward the ventricles
atrioventricular (AV) valve	A valve between the atrium and ventricle on the right and left sides of the heart; the right AV valve is the tricuspid valve; the left is the mitral valve
atrium *A-tre-um*	An entrance chamber, one of the two upper receiving chambers of the heart (root: atri/o)
AV bundle	A band of fibers that transmits impulses from the atrioventricular (AV) node to the top of the interventricular septum; it divides into the right and left bundle branches, which descend along the two sides of the septum; the bundle of His
blood pressure	The force exerted by blood against the wall of a vessel
bundle branches	Branches of the AV bundle that divide to the right and left sides of the interventricular septum
capillary *KAP-ih-lar-e*	A microscopic blood vessel through which materials are exchanged between the blood and the tissues
cardiovascular system *kar-de-o-VAS-ku-lar*	The part of the circulatory system that consists of the heart and the blood vessels
coronary circulation *KOR-o-na-re*	The blood vessels in the heart that provide oxygen and nourishment and remove waste products from the myocardium
depolarization *de-po-lar-ih-ZA-shun*	A change in electrical charge from the resting state in nerves or muscles
diastole *di-AS-to-le*	The relaxation phase of the heartbeat cycle (adjective: diastolic)
electrocardiography (ECG) *e-lek-tro-kar-de-OG-rah-fe*	Study of the electrical activity of the heart as detected by electrodes (leads)placed on the surface of the body; also abbreviated EKG from the German electrocardiography
endocardium *en-do-KAR-de-um*	The thin membrane that lines the chambers of the heart and covers the valves
epicardium *ep-ih-KAR-de-um*	The thin outermost layer of the heart wall
functional murmur	Any sound produced as the heart functions normally
heart *hart*	The muscular organ with four chambers that contracts rhythmically to propel blood through vessels to all parts of the body (root: cardi/o)

extern.ir

Terminology Key Terms (Continued)

heart rate	The number of times the heart contracts per minute; recorded as beats per minute (bpm)
heart sounds	Sounds produced as the heart functions: the two loudest sounds are produced by alternate closing of the valves and are designated S_1 and S_2
inferior vena cava *VE-nah KA-vah*	The large inferior vein that brings blood low in oxygen back to the right atrium of the heart from the lower body
left AV valve	The valve between the left atrium and the left ventricle; the mitral valve or bicuspid valve
mitral valve *MI-tral*	The valve between the left atrium and the left ventricle; the left AV valve or bicuspid valve
myocardium *mi-o-KAR-de-um*	The thick middle layer of the heart wall composed of cardiac muscle
pericardium *per-ih-KAR-de-um*	The fibrous sac that surrounds the heart
pulmonary artery *PUL-mo-nar-e*	The vessel that carries blood from the right side of the heart to the lungs
pulmonary circuit *SER-kit*	The system of vessels that carries blood from the right side of the heart to the lungs to be oxygenated and then back to the left side of the heart
pulmonary veins	The vessels that carry blood from the lungs to the left side of the heart
pulmonary valve	The valve at the entrance to the pulmonary artery
pulse *puls*	The wave of increased pressure produced in the vessels each time the ventricles contract
Purkinje fibers *pur-KIN-je*	The terminal fibers of the cardiac conducting system; they carry impulses through the walls of the ventricles
repolarization *re-po-lar-ih-ZA-shun*	A return of electrical charge to the resting state in nerves or muscles
right AV valve	The valve between the right atrium and right ventricle; the tricuspid valve
septum *SEP-tum*	A wall dividing two cavities, such as two chambers of the heart
sinus rhythm *SI-nus RITH-um*	Normal heart rhythm
sinoatrial (SA) node *si-no-A-tre-al*	A small mass in the upper part of the right atrium that initiates the impulse for each heartbeat; the pacemaker
sphygmomanometer *sfig-mo-mah NOM–eh-ter*	An instrument for determining arterial blood pressure (root sphygm/o means "pulse"); blood pressure apparatus or cuff
superior vena cava *VE-nah KA-vah*	The large superior vein that brings blood low in oxygen back to the right atrium from the upper body
systemic circuit *sis-TEM-ik SER-kit*	The system of vessels that carries oxygenated blood from the left side of the heart to all tissues except the lungs and returns deoxygenated blood to the right side of the heart
systole *SIS-to-le*	The contraction phase of the heartbeat cycle (adjective: systolic)
valve *valv*	A structure that keeps fluid flowing in a forward direction (roots: valv/o, valvul/o)
vein *vane*	A vessel that carries blood back to the heart. All except the pulmonary and umbilical veins carry blood low in oxygen (roots: ven/o, phleb/o)

(continued)

extern.ir

Terminology Key Terms (Continued)

ventricle *VEN-trik-l*	A small cavity. One of the two lower pumping chambers of the heart (root: ventricul/o)
venule *VEN-ule*	A small vessel that carries blood from the capillaries to the veins
vessel *VES-el*	A tube or duct to transport fluid (roots: angi/o, vas/o, vascul/o)

Roots Pertaining to the Cardiovascular System

See **TABLES 10-1** and **10-2**.

Table 10-1 Roots for the Heart

Root	Meaning	Example	Definition of Example
cardi/o	heart	cardiomyopathy[a] *kar-de-o-mi-OP-ah-the*	any disease of the heart muscle
atri/o	atrium	atriotomy *a-tre-OT-o-me*	surgical incision of an atrium
ventricul/o	cavity, ventricle	supraventricular *su-prah-ven-TRIK-u-lar*	above a ventricle
valv/o, valvul/o	valve	valvulotome *VAL-vu-lo-tome*	instrument for incising a valve

[a]Preferred over myocardiopathy.

Exercise 10-1

Complete the exercise. To check your answers go to Appendix 11.

Fill in the blanks.

1. A valvuloplasty (*val-vu-lo-PLAS-te*) is plastic repair of a(n) _____ .
2. Atriotomy (*a-tre-OT-to-me*) means surgical incision of a(n) _____ .
3. Interventricular (*in-ter-ven-TRIK-u-lar*) means between the _____ .
4. The word *cardiomegaly* (*kar-de-o-MEG-ah-le*) means enlargement of the _____ .

Write the adjective for the following definitions. The proper suffix is given for each.

5. Pertaining to an atrium (-al) _____
6. Pertaining to the myocardium (-al; ending differs from adjective ending for the heart) _____
7. Pertaining to the heart (-ac) _____
8. Pertaining to a valve (-ar) _____
9. Pertaining to a ventricle (-ar) _____
10. Pertaining to the pericardium (-al) _____

extern.ir

Exercise 10-1 *(Continued)*

Following the example, write a word for the following definitions pertaining to the tissues of the heart.

11. Inflammation of the fibrous sac around the heart _____
12. Inflammation of the heart's lining (usually at a valve) _____
13. Inflammation of the heart muscle _____

Write a word for the following definitions.

14. Originating (-genic) in the heart _____
15. Surgical incision of a valve _____
16. Pertaining to an atrium and a ventricle _____
17. Between (inter-) the atria _____
18. Study (-logy) of the heart _____

Table 10-2 Roots for the Blood Vessels

Root	Meaning	Example	Definition of Example
angi/o[a]	vessel	angiography *an-je-OG-rah-fe*	x-ray imaging of a vessel
vas/o, vascul/o	vessel, duct	vasospasm *VA-so-spazm*	sudden contraction of a vessel
arter/o, arteri/o	artery	endarterial *end-ar-TE-re-al*	within an artery
arteriol/o	arteriole	arteriolar *ar-te-re-O-lar*	pertaining to an arteriole
aort/o	aorta	aortoptosis *a-or-top-TO-sis*	downward displacement of the aorta
ven/o, ven/i	vein	venous *VE-nus*	pertaining to a vein
phleb/o	vein	phlebotomy *fleh-BOT-o-me*	incision of a vein to withdraw blood

[a]The root *angi/o* usually refers to a blood vessel but is used for other types of vessels as well. *Hemangi/o* refers specifically to a blood vessel.

Exercise 10-2

Complete the exercise. To check your answers go to Appendix 11.

Fill in the blanks.

1. Angioedema (*an-je-o-eh-DE-mah*) is localized swelling caused by changes in _____ .
2. Vasodilation (*vas-o-DI-la-shun*) means dilation of a(n) _____ .
3. Aortostenosis (*a-or-to-steh-NO-sis*) is narrowing of _____ .
4. Endarterectomy (*end-ar-ter-EK-to-me*) is removal of the inner lining of a(n) _____ .
5. Arteriolitis (*ar-te-re-o-LI-tis*) is inflammation of a(n) _____ .
6. Phlebectasia (*fleb-ek-TA-ze-ah*) is dilatation of a(n) _____ .
7. The term *microvascular* (*mi-kro-VAS-ku-lar*) means pertaining to small _____ .

(continued)

extern.ir

Exercise 10-2 *(Continued)*

Define the following words.

8. arteriorrhexis (*ar-te-re-o-REK-sis*) _____
9. intraaortic (*in-trah-a-OR-tik*) _____
10. angiitis (*an-je-I-tis*) (note spelling); also angitis or vasculitis _____
11. phlebitis (*fleb-I-tis*) _____
12. cardiovascular (*kar-de-o-VAS-ku-lar*) _____

Use the ending *-gram* to form a word for a radiograph of the following.

13. vessels (use angi/o) _____
14. aorta _____
15. veins _____

Use the root *angi/o* to write words with the following meanings.

16. Plastic repair (-plasty) of a vessel _____
17. Any disease (-pathy) of a vessel _____
18. Dilatation (-ectasis) of a vessel _____
19. Formation (-genesis) of a vessel _____

Use the appropriate root to write words with the following meanings.

20. Excision of a vein _____
21. Hardening (-sclerosis) of the aorta _____
22. Within (intra-) a vein _____
23. Incision of an artery _____

Clinical Aspects of the Cardiovascular System

ATHEROSCLEROSIS

The accumulation of fatty deposits within the lining of an artery is termed **atherosclerosis** (FIG. 10-9). This type of deposit, called **plaque** (*plak*), begins to form when a vessel receives tiny injuries, usually at a point of branching. Plaques gradually thicken and harden with fibrous material, cells, and other deposits, restricting the vessel's lumen (opening) and reducing blood flow to the tissues, a condition known as **ischemia** (*is-KE-me-ah*). A major risk factor for the development of atherosclerosis is **dyslipidemia**, abnormally high levels or imbalance in **lipoproteins** that are carried in the blood, especially high levels of cholesterol-containing, low-density lipoproteins (LDLs). Other risk factors for atherosclerosis include smoking, high blood pressure, poor diet, inactivity, stress, and a family history of the disorder. Atherosclerosis may involve any arteries, but most of its effects are seen in the coronary vessels of the heart, the aorta, the carotid arteries in the neck, and vessels in the brain. The techniques described later for treating coronary artery disease (CAD) are used for these other vessels as well.

Atherosclerosis is the most common form of a more general condition known as **arteriosclerosis** in which vessel walls harden from any cause. In addition to plaque, calcium salts and scar tissue may contribute to arterial wall thickening, with a narrowing of the lumen and loss of elasticity.

THROMBOSIS AND EMBOLISM

Atherosclerosis predisposes a person to **thrombosis**, the formation of a blood clot within a vessel (see FIG. 10-9). The clot, called a **thrombus**, interrupts blood flow to the tissues supplied by that vessel, resulting in necrosis (tissue death). Blockage of a vessel by a thrombus or other mass carried in the bloodstream is **embolism**, and the mass

extern.ir

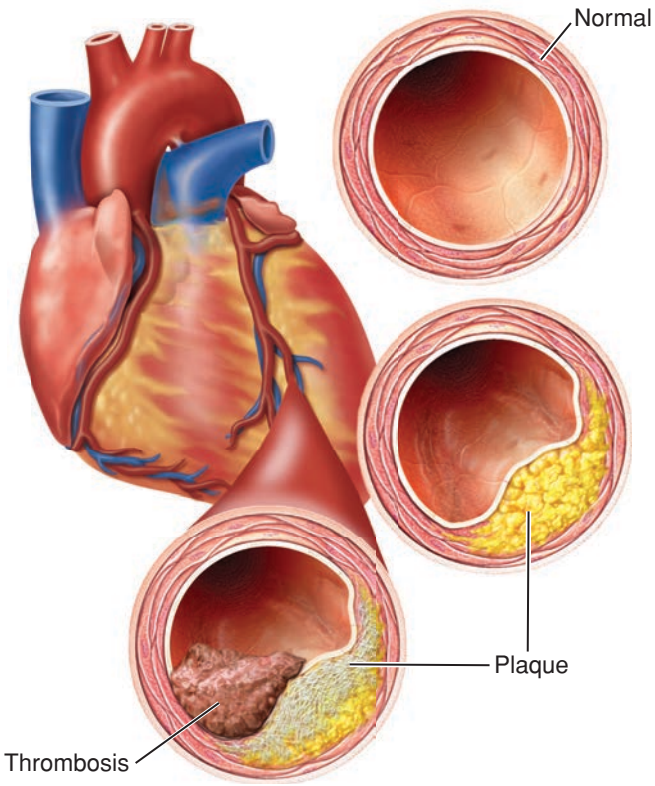

FIGURE 10-9 Coronary atherosclerosis. In this example, a branch of the left coronary artery is shown in cross-section during three stages of atherosclerosis: no plaque present (**top**), a well-formed plaque blocking 30% of the vessel lumen (**middle**), and formation of a thrombus (blood clot) (**bottom**).

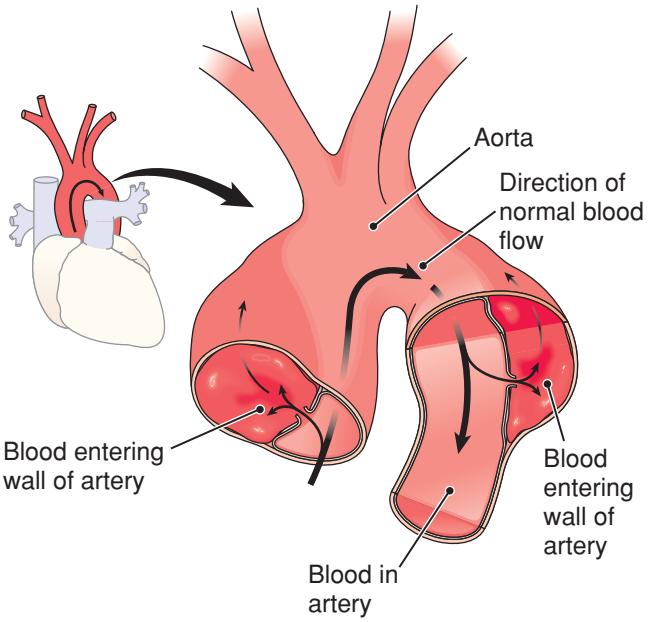

FIGURE 10-10 Dissecting aortic aneurysm. Blood separates the layers of the arterial wall.

itself is called an **embolus.** Usually, the mass is a blood clot that breaks loose from a vessel's wall, but it may also be air (as from injection or trauma), fat (as from marrow released after a bone break), bacteria, or other solid materials. Often a venous thrombus will travel through the heart and then lodge in an artery of the lungs, resulting in a life-threatening pulmonary embolism. An embolus from a carotid artery often blocks a cerebral vessel, causing a **cerebrovascular accident (CVA)**, commonly called **stroke** (Chapter 7).

The use of anticoagulant drugs ("blood thinners") when appropriate has greatly reduced the incidence of these conditions. These drugs include heparin, which inhibits thrombin formation; warfarin (Coumadin), which inhibits formation of vitamin K; and newer oral anticoagulants that interfere with thrombin formation and do not require regular tests of blood levels, as does Coumadin.

ANEURYSM

An arterial wall weakened by atherosclerosis, malformation, injury, or other changes may balloon out, forming an **aneurysm.** If an aneurysm ruptures, hemorrhage results. Rupture of a cerebral artery is another cause of stroke. The abdominal aorta and carotid arteries are also common aneurysm sites. In a **dissecting aneurysm** (FIG. 10-10), blood hemorrhages into the arterial wall's thick middle layer, separating the muscle as it spreads and sometimes rupturing the vessel. The aorta is most commonly involved. Surgeons can replace the damaged arterial segment of a dissecting aneurysm surgically with a graft. In many cases they can insert a stent (small tube) to seal off the aneurysm and carry blood through the expanded portion of the vessel.

HYPERTENSION

High blood pressure, or **hypertension** (HTN), is a contributing factor in all of the conditions described above. In simple terms, HTN is defined as a systolic pressure greater than 140 mm Hg or a diastolic pressure greater than 90 mm Hg. HTN causes the left ventricle to enlarge (hypertrophy) as a result of increased work. Some cases of HTN are secondary to other disorders, such as kidney malfunction or endocrine disturbance, but most of the time, the causes are unknown, a condition described as primary, or essential, HTN.

Treatment of Hypertension

Even though there is much individual variation in blood pressure, physicians have established guidelines for the diagnosis and treatment of hypertension. Blood pressure readings of 120/80 to 139/89 describe *prehypertension*, a warning sign for the future development of high blood pressure. This condition is treated by lifestyle modifications such as increased physical exercise, a low-salt, low-fat diet, and if necessary, weight loss and smoking cessation. Any confirmed blood pressure over 140/90 (at least two readings on two separate occasions) is treated with medication as well as lifestyle changes. A physician may opt to prescribe antihypertensive medication for someone in the upper range of

extern.ir

prehypertension who is at risk of a heart attack or stroke. Drugs used to treat hypertension include the following:

- Diuretic (*di-u-RET-ik*) drugs that promote salt and water loss through the kidneys
- Drugs that limit production of renin or block its action
- Drugs that relax blood vessels, including adrenergic blockers and calcium channel blockers

HEART DISEASE

Coronary Artery Disease

Coronary artery disease (CAD) results from atherosclerosis in the vessels that supply blood to the heart muscle. It is a leading cause of death in industrialized countries (see **FIG. 10-9**). An early sign of CAD is the type of chest pain known as **angina pectoris.** This is a feeling of constriction around the heart or pain that may radiate to the left arm or shoulder, usually brought on by exertion. Often there is anxiety, **diaphoresis** (profuse sweating), and **dyspnea** (difficulty in breathing). CAD is diagnosed by ECG, **stress tests, echocardiography**, and **coronary angiography.** This invasive x-ray imaging method requires injection of a dye into the coronary arteries by means of a catheter threaded through blood vessels into the heart **(FIG. 10-11)**. Coronary **CT angiography** (CTA) is a noninvasive procedure that can be used in the diagnosis of heart disease. It employs computed tomography scans following injection of a small amount of dye into the arm. A **coronary calcium scan** (heart scan) reveals vessel-narrowing calcium deposits in the coronary arterial walls. Researchers have also found that a substance called **C-reactive protein** (CRP) is associated with poor cardiovascular health. This protein is produced during systemic inflammation, which may contribute to atherosclerosis. CRP levels can indicate cardiovascular disease and predict its outcome (prognosis). A more specific test for heart attack risk is the more accurate hs-CRP (high-sensitivity CRP) test.

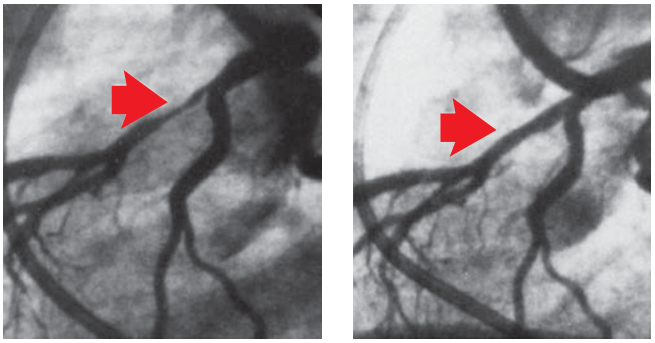

A B

FIGURE 10-11 Coronary angiography. Coronary vessels are imaged after administration of a dye during cardiac catheterization. **A.** Angiography shows narrowing in the mid-left anterior descending (LAD) artery (*arrow*). **B.** The same vessel after angioplasty, a procedure to distend narrowed vessels. Note the improved blood flow through the artery distal to the repair.

CAD is treated by control of exercise and diet and by drug therapy and surgical intervention when appropriate. Drugs, such as nitroglycerin, may be used to dilate coronary vessels. Other drugs may be used to regulate the heartbeat, strengthen the force of heart contraction, lower cholesterol, or prevent blood clot formation.

Patients with severe CAD may be candidates for **angioplasty**, surgical dilatation of the blocked vessel by means of a balloon catheter, a procedure technically called **percutaneous transluminal coronary angioplasty** (PTCA) (**FIGS. 10-11** and **10-12**). Angioplasty may include placement of a **stent**, a small mesh tube, to keep the vessel open **(FIG. 10-13)**. Stents prevent recoil of the vessel and are available in different versions. The basic type is the bare metal stent; another is the drug-eluting stent, which releases drugs to prevent vascular restenosis. The newest form of stent is a completely

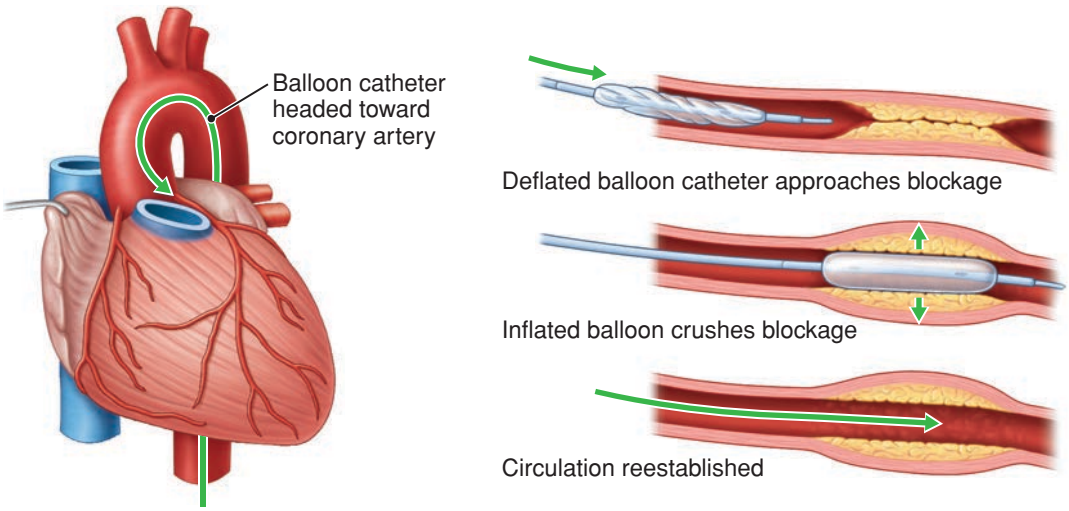

FIGURE 10-12 Coronary angioplasty (PTCA).

extern.ir

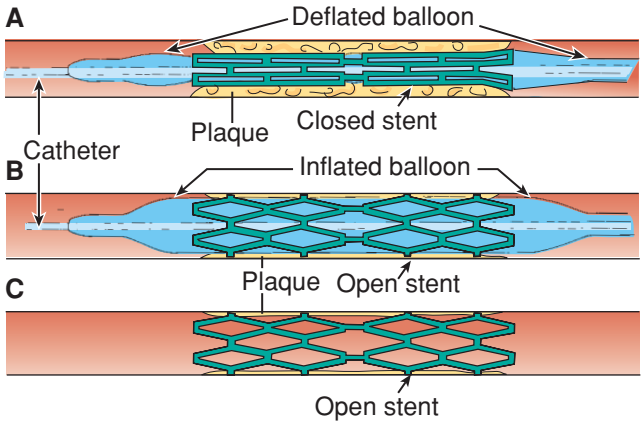

FIGURE 10-13 Arterial stent. A. Stent closed, before balloon inflation. **B.** Stent open, balloon inflated; stent will remain expanded after balloon is deflated and removed. **C.** Stent open, balloon removed.

bioabsorbable device that is gradually metabolized and absorbed into the body.

If further intervention is required, surgeons can bypass the blocked vessel or vessels with a vascular graft (FIG. 10-14). In this procedure, known as a **coronary artery bypass graft** (CABG), another vessel or a piece of another vessel, usually the left internal mammary artery or part of the leg's saphenous vein, is grafted to carry blood from the aorta to a point past the coronary vessel obstruction.

Myocardial Infarction

Degenerative changes in the arteries predispose a person to thrombosis and sudden coronary artery **occlusion** (obstruction). The resultant area of myocardial necrosis is termed an **infarct**, and the process is known as **myocardial infarction** (MI), the "heart attack" that may cause sudden death. Symptoms of MI include pain over the heart (precordial pain) or upper part of the abdomen (epigastric pain) that may extend to the jaw or arms, pallor (paleness), diaphoresis, nausea, fatigue, anxiety, and dyspnea. There may be a burning sensation similar to indigestion or heartburn. In women, because degenerative changes more commonly affect multiple small vessels rather than the major coronary pathways, MI symptoms are often more long-term and are more subtle and diffuse than the intense chest pain that is more typical in men.

MI is diagnosed by ECG and assays for specific substances in the blood. Creatine kinase (CK) is an enzyme normal to muscle cells. It is released in increased amounts when muscle tissue is injured. The form of CK specific to cardiac muscle cells is **creatine kinase MB** (CK-MB). **Troponin** (Tn) is a protein that regulates contraction in muscle cells. Increased serum levels, particularly the forms TnT and TnI, indicate MI.

Patient outcome is based on the degree of damage and the speed of treatment to dissolve the clot and to reestablish normal blood flow and heart rhythm.

Arrhythmia

Arrhythmia is any irregularity of heart rhythm, such as an altered heart rate, extra beats, or a change in the pattern of the beat. **Bradycardia** is a slower-than-average rate, and **tachycardia** is a higher-than-average rate.

Damage to cardiac tissue, as by MI, may result in **heart block**, an interruption in the heart's electrical conduction

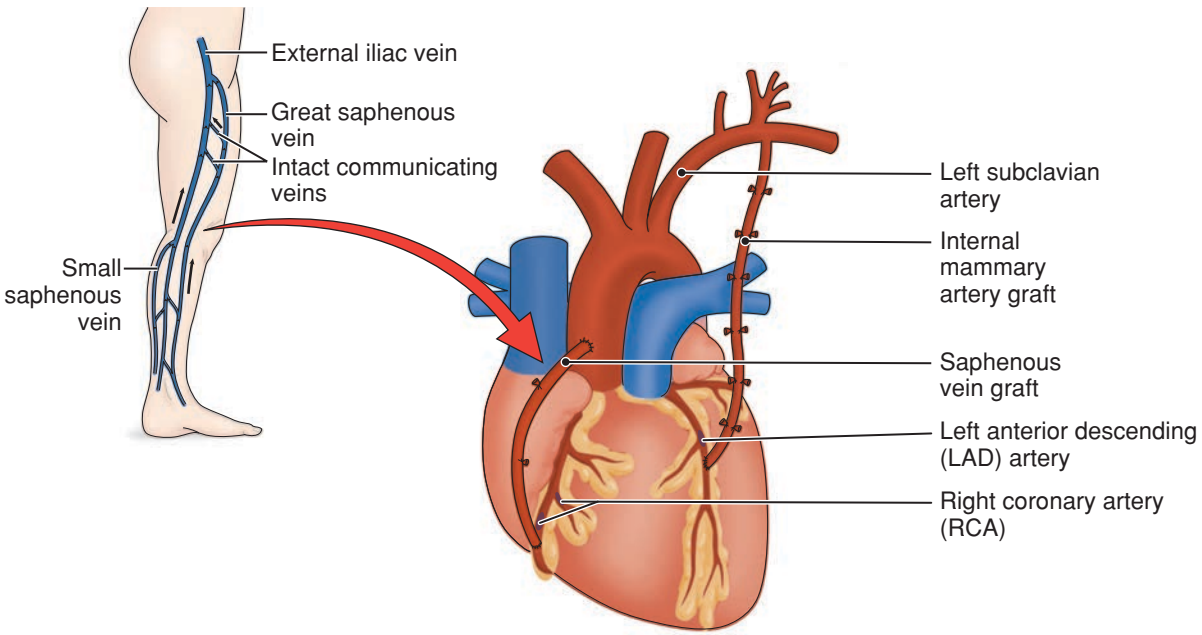

FIGURE 10-14 Coronary artery bypass graft (CABG). In a bypass graft, a healthy vessel segment is used to carry blood around an arterial blockage. This figure shows two CABGs. On the left, a segment of the saphenous vein is used to carry blood from the aorta to a part of the right coronary artery that is distal to the occlusion. On the right, the mammary artery is grafted to bypass an obstruction in the LAD artery.

extern.ir

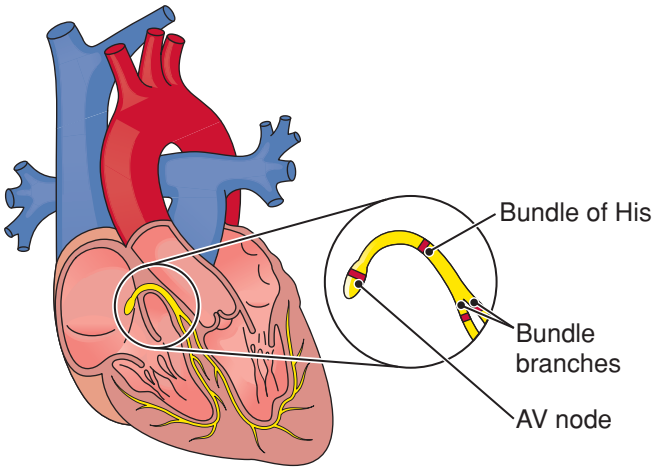

FIGURE 10-15 Potential sites for heart block in the atrioventricular (AV) portion of the heart's conduction system.

system resulting in arrhythmia (FIG. 10-15). Heart block is classified in order of increasing severity as first-, second-, or third-degree heart block. Block in a bundle branch is designated as a left or right bundle branch block (BBB).

If, for any reason, the SA node is not generating a normal heartbeat or there is heart block, an **artificial pacemaker** may be implanted to regulate the beat (FIG. 10-16). Usually, the pacemaker is inserted under the skin below the clavicle, and leads are threaded through veins into one or both of the right chambers. Some pacemakers act only when the heart is not functioning on its own, and others adjust to the need for a change in heart rate based on activity.

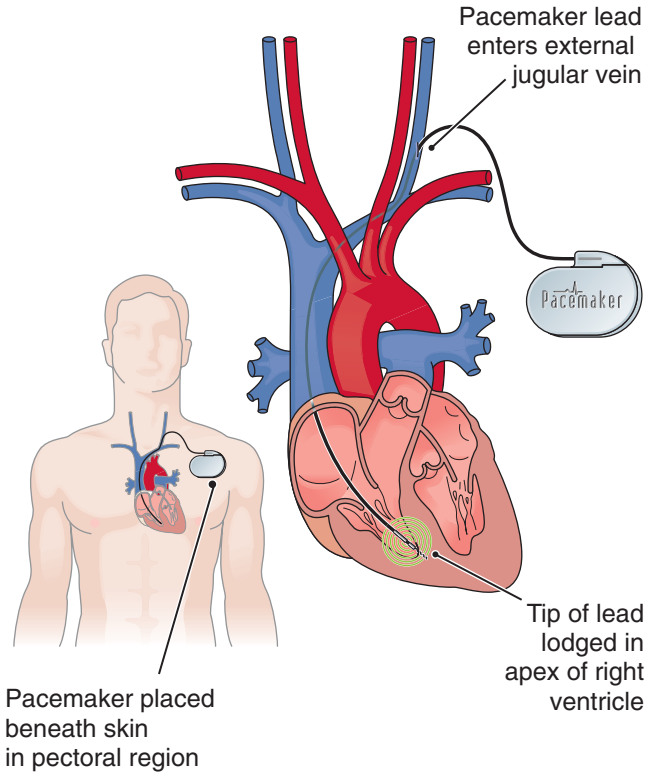

FIGURE 10-16 Placement of a pacemaker. The lead is placed in an atrium or ventricle, usually on the right side. A dual-chamber pacemaker has leads in both chambers.

MI is also a common cause of **fibrillation**, an extremely rapid, ineffective heartbeat, especially dangerous when it affects the ventricles. (Carlos in the opening case study had atrial fibrillation.) **Cardioversion** is the general term for restoration of a normal heart rhythm, either by drugs or application of electric current. Hospital personnel use external chest "paddles" or "pads" for emergency electrical **defibrillation.** In addition to **cardiopulmonary resuscitation** (CPR), automated external defibrillators (AEDs) can help save lives when available for high-risk patients or in public places, such as malls, schools, churches, aircrafts, and sports venues. The AED detects fatal arrhythmia and automatically delivers a correct preprogrammed shock. An implantable cardioverter defibrillator (ICD), applied much like a pacemaker, detects potential fibrillation and automatically shocks the heart to restore normal rhythm.

A newer approach to the treatment of heart rhythm irregularities is cardiac **ablation**, destruction of that portion of the conduction pathway that is involved in the arrhythmia. Electrode catheter ablation uses high-frequency sound waves, freezing (cryoablation), or electrical energy delivered through an intravascular catheter to ablate a defect in the conduction pathway.

Heart Failure

The general term **heart failure** refers to any condition in which the heart fails to empty effectively. The resulting increased pressure in the venous system leads to **edema**, justifying the description *congestive heart failure* (CHF). Left-side failure results in pulmonary edema with breathing difficulties (dyspnea); right-side failure causes peripheral edema with tissue swelling, especially in the legs, along with weight gain from fluid retention. Other symptoms of CHF are **cyanosis** and **syncope** (fainting).

Heart failure is treated with rest, drugs to strengthen heart contractions, diuretics to eliminate fluid, and restriction of salt in the diet.

Heart failure is one cause of **shock**, a severe disturbance in the circulatory system resulting in inadequate blood delivery to the tissues. Shock is classified according to cause as:

- Cardiogenic shock, caused by heart failure
- Hypovolemic shock, caused by loss of blood volume
- Septic shock, caused by bacterial infection
- Anaphylactic shock, caused by severe allergic reaction

Congenital Heart Disease

A congenital defect is any defect that is present at birth. The most common type of congenital heart defect is a **septal defect**, a hole in the septum (wall) that separates the atria or

extern.ir

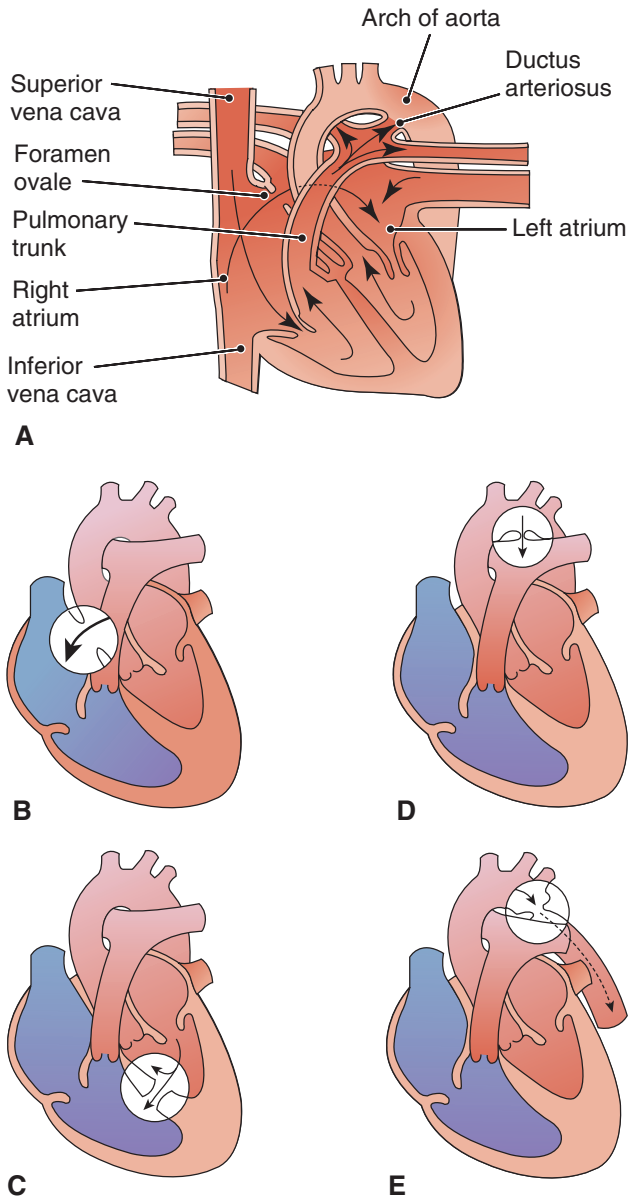

FIGURE 10-17 Congenital heart defects. A. Normal fetal heart showing the foramen ovale and ductus arteriosus. **B.** Persistence of the foramen ovale results in an atrial septal defect. **C.** A ventricular septal defect. **D.** Persistence of the ductus arteriosus (patent ductus arteriosus) forces blood back into the pulmonary artery. **E.** Coarctation of the aorta restricts outward blood flow in the aorta.

the septum that separates the ventricles (FIG. 10-17). An atrial septal defect often results from persistence of an opening, the foramen ovale, that allows blood to bypass the lungs in fetal circulation. A septal defect permits blood to shunt from the left to the right side of the heart and return to the lungs instead of flowing out to the body. The heart has to work harder to meet the tissue's oxygen needs. Symptoms of septal defect include cyanosis (leading to the description "blue baby"), syncope, and **clubbing** of the fingers.

Most U.S. hospitals are now required to screen for congenital heart defects at birth with pulse oximetry, a test that measures oxygen levels in the blood. Low oxygen levels may indicate heart abnormalities that could be treated immediately but might not otherwise become evident until after the baby leaves the hospital. The test is inexpensive and has a low false-positive rate.

Another congenital defect that results from persistence of a fetal modification is **patent ductus arteriosus** (see FIG. 10-17D). In this case, a small bypass between the pulmonary artery and the aorta fails to close at birth. Blood then can flow from the aorta to the pulmonary artery and return to the lungs.

Heart valve malformation is another type of congenital heart defect. Failure of a valve to open or close properly is evidenced by a **murmur**, an abnormal sound heard as the heart cycles. A localized aortic narrowing, or **coarctation of the aorta**, is a congenital defect that restricts blood flow through that vessel (see FIG. 10-17E). Most of the congenital defects described now can be corrected surgically. A patent ductus arteriosus may also respond to drug treatment.

Rheumatic Heart Disease

In **rheumatic heart disease**, infection with a specific type of *Streptococcus* sets up an immune reaction that ultimately damages the heart valves. The infection usually begins as a "strep throat," and most often the mitral valve is involved. Scar tissue fuses the valve's leaflets, causing a narrowing or **stenosis** that interferes with proper function. People with rheumatic heart disease are subject to repeated valvular infections and may need to take antibiotics prophylactically (preventively) before invasive medical or dental procedures. Severe cases of rheumatic heart disease may require surgical correction or even valve replacement. The incidence of rheumatic heart disease has declined with the use of antibiotics.

DISORDERS OF THE VEINS

A breakdown in the valves of the veins in combination with a chronic dilatation of these vessels results in **varicose veins** (FIG. 10-18). These appear twisted and swollen under the skin,

FIGURE 10-18 Varicose veins.

extern.ir

most commonly in the legs. Contributing factors include heredity, obesity, prolonged standing, and pregnancy, which increase pressure in the pelvic veins. Varicosities can impede blood flow and lead to edema, thrombosis, hemorrhage, or ulceration. Treatment includes the wearing of elastic stockings and, in some cases, surgical removal of the varicose veins, after which collateral circulation is naturally established. A varicose vein in the rectum or anal canal is referred to as a **hemorrhoid.**

Phlebitis is any inflammation of the veins and may be caused by infection, injury, poor circulation, or damage to valves in the veins. Such inflammation typically initiates blood clot formation, resulting in **thrombophlebitis.** Any veins are subject to thrombophlebitis, but the more serious condition involves the deep veins as opposed to the superficial veins, in the condition termed **deep vein thrombosis** (DVT). The most common sites for DVT are the deep leg veins, causing serious reduction in venous drainage from these areas.

Vascular technologists obtain information on the blood vessels and circulation to aid in diagnosis. **BOX 10-3** for information on this career.

HEALTH PROFESSIONS
Vascular Technologists

BOX 10-3

Vascular technologists perform noninvasive diagnostic studies to evaluate the blood vessels (arteries and veins) in the head, neck, extremities, and abdomen to help physicians diagnose vascular disorders. Vascular technologists obtain two-dimensional images of the blood vessels using ultrasound and measure the velocity and direction of blood flow using Doppler ultrasound. They use other instrumentation to measure blood pressure, changes in blood volume, and the blood's oxygen saturation.

Most vascular technologists work in hospitals, where they prepare patients for tests, take clinical histories, perform limited physical examinations, carry out diagnostic tests, and report results. They may also work in offices, clinics, or laboratories. Although most of their patients are elderly, vascular studies may be required on patients of any age.

Unlike early workers in this field who were often trained on the job, vascular technologists today complete a 2- or 4-year educational program accredited by the Commission on Accreditation of Allied Health Education Programs (CAAHEP). Certification specific to vascular technology is available from the American Registry for Diagnostic Medical Sonography at ardms.org and from other organizations. Certification requires appropriate education, clinical experience, examination, and continuing education. Certification will be a requirement of all vascular technologists working in IAC (Intersocietal Accreditation Commission) accredited vascular laboratories beginning in 2017. Additional information on this career is available from the Society for Vascular Ultrasound at svunet.org.

Terminology *Key Terms*

The terms listed below are emphasized in this chapter. Knowing them will help you organize and prioritize your learning. These boldface terms are also found, collectively, with all chapter key terms in the Glossary.

Cardiovascular Disorders

aneurysm *AN-u-rizm*	A localized abnormal dilation of a blood vessel, usually an artery, caused by weakness of the vessel wall; may eventually burst
angina pectoris *an-JI-nah PEK-to-ris*	A feeling of constriction around the heart or pain that may radiate to the left arm or shoulder, usually brought on by exertion; caused by insufficient blood supply to the heart
arrhythmia *ah-RITH-me-ah*	Any abnormality in the rate or rhythm of the heartbeat (literally "without rhythm"; note doubled r); also called dysrhythmia
arteriosclerosis *ar-tere-e-o-skler-O-sis*	Hardening (sclerosis) of the arteries, with loss of capacity and loss of elasticity, as from fatty deposits (plaque), deposit of calcium salts, or scar tissue formation
atherosclerosis *ath-er-o-skler-O-sis*	The development of fatty, fibrous patches (plaques) in the lining of arteries, causing narrowing of the lumen and hardening of the vessel wall; the most common form of arteriosclerosis (hardening of the arteries) (root ather/o means "porridge" or "gruel")
bradycardia *brad-e-KAR-de-ah*	A slow heart rate of less than 60 bpm
cerebrovascular accident (CVA) *ser-eh-bro-VAS-ku-lar*	Sudden damage to the brain resulting from reduction of blood flow; causes include atherosclerosis, embolism, thrombosis, or hemorrhage from a ruptured aneurysm; commonly called stroke

extern.ir

Terminology *Key Terms (Continued)*

clubbing *KLUB-ing*	Enlargement of the ends of the fingers and toes caused by growth of the soft tissue around the nails (see **FIG. 3-17**); seen in a variety of diseases in which there is poor peripheral circulation
coarctation of the aorta *ko-ark-TA-shun*	Localized narrowing of the aorta with restriction of blood flow (see **FIG. 10-17E**)
C-reactive protein (CRP)	Protein produced during systemic inflammation, which may contribute to atherosclerosis; high CRP levels can indicate cardiovascular disease and its prognosis
cyanosis *si-ah-NO-sis*	Bluish discoloration of the skin caused by lack of oxygen in the blood (adjective: cyanotic) (see **FIG. 1-17**)
deep vein thrombosis (DVT) *throm-BO-sis*	Thrombophlebitis involving the deep veins
diaphoresis *di-ah-fo-RE-sis*	Profuse sweating
dissecting aneurysm	An aneurysm in which blood enters the arterial wall and separates the layers; usually involves the aorta (see **FIG. 10-10**)
dyslipidemia *dis-lip-ih-DE-me-ah*	Disorder in serum lipid levels, which is an important factor in development of atherosclerosis; includes hyperlipidemia (high lipids), hypercholesterolemia (high cholesterol), and hypertriglyceridemia (high triglycerides)
dyspnea *DISP-ne-ah*	Difficult or labored breathing (-pnea)
edema *eh-DE-mah*	Swelling of body tissues caused by the presence of excess fluid (see **FIG. 3-2**); causes include cardiovascular disturbances, kidney failure, inflammation, and malnutrition
embolism *EM-bo-lizm*	Obstruction of a blood vessel by a blood clot or other matter carried in the circulation
embolus *EM-bo-lus*	A mass carried in the circulation; usually a blood clot, but also may be air, fat, bacteria, or other solid matter from within or from outside the body
fibrillation *fih-brih-LA-shun*	Spontaneous, quivering, and ineffectual contraction of muscle fibers, as in the atria or the ventricles
heart block	An interference in the electrical conduction system of the heart resulting in arrhythmia (see **FIG. 10-15**)
heart failure	A condition caused by the inability of the heart to maintain adequate blood circulation
hemorrhoid *HEM-o-royd*	A varicose vein in the rectum
hypertension *hi-per-TEN-shun*	A condition of higher-than-normal blood pressure; essential (primary, idiopathic) hypertension has no known cause
infarct *in-FARKT*	An area of localized tissue necrosis (death) resulting from a blockage or a narrowing of the artery that supplies the area
ischemia *is-KE-me-ah*	Local deficiency of blood supply caused by circulatory obstruction (root: hem/o)
murmur	An abnormal heart sound
myocardial infarction (MI) *mi-o-KAR-de-al in-FARK-shun*	Localized necrosis (death) of cardiac muscle tissue resulting from blockage or narrowing of the coronary artery that supplies that area; myocardial infarction is usually caused by formation of a thrombus (clot) in a vessel

(continued)

extern.ir

Terminology — Key Terms (Continued)

occlusion *o-KLU-zhun*	A closing off or obstruction, as of a vessel
patent ductus arteriosus *PA-tent DUK-tus ar-tere-e-O-sus*	Persistence of the ductus arteriosus after birth; the ductus arteriosus is a vessel that connects the pulmonary artery to the descending aorta in the fetus to bypass the lungs (see **FIG. 10-17D**)
phlebitis *fleh-BI-tis*	Inflammation of a vein
plaque *Plak*	A patch; with regard to the cardiovascular system, a deposit of fatty material and other substances on a vessel wall that impedes blood flow and may block the vessel; atheromatous plaque
rheumatic heart disease *ru-MAT-ik*	Damage to heart valves after infection with a type of *Streptococcus* (group A hemolytic *Streptococcus*); the antibodies produced in response to the infection produce valvular scarring usually involving the mitral valve
septal defect *SEP-tal*	An opening in the septum between the atria or ventricles; a common cause is persistence of the foramen ovale (*for-A-men o-VAL-e*), an opening between the atria that bypasses the lungs in fetal circulation (see **FIG. 10-17B,C**)
shock	Circulatory failure resulting in an inadequate blood supply to the tissues; cardiogenic shock is caused by heart failure; hypovolemic shock is caused by a loss of blood volume; septic shock is caused by bacterial infection
stenosis *steh-NO-sis*	Constriction or narrowing of an opening
stroke	See cerebrovascular accident
syncope *SIN-ko-pe*	A temporary loss of consciousness caused by inadequate blood flow to the brain; fainting
tachycardia *tak-ih-KAR-de-ah*	An abnormally rapid heart rate, usually over 100 bpm
thrombophlebitis *throm-bo-fleh-BI-tis*	Inflammation of a vein associated with formation of a blood clot
thrombosis *throm-BO-sis*	Development of a blood clot within a vessel
thrombus *THROM-bus*	A blood clot that forms within a blood vessel (root: thromb/o)
varicose vein *VAR-ih-kose*	A twisted and swollen vein resulting from breakdown of the valves, pooling of blood, and chronic dilatation of the vessel (root: varic/o); also called varix (*VAR-iks*) or varicosity (*var-ih-KOS-ih-te*) (see **FIG. 10-18**)
Diagnosis and Treatment	
ablation *ab-LA-shun*	Removal or destruction. In cardiac ablation, a catheter is used to destroy a portion of the heart's conduction pathway to correct an arrhythmia
angioplasty *AN-je-o-plas-te*	A procedure that reopens a narrowed vessel and restores blood flow; commonly accomplished by surgically removing plaque, inflating a balloon within the vessel, or installing a device (stent) to keep the vessel open (see **FIGS. 10-11** to **10-13**)
artificial pacemaker	A battery-operated device that generates electrical impulses to regulate the heartbeat; it may be external or implanted, may be designed to respond to need, and may have the capacity to prevent tachycardia (see **FIG. 10-16**)

extern.ir

Terminology *Key Terms (Continued)*

cardiopulmonary resuscitation (CPR) *kar-de-o-PUL-mo-nar-e re-sus-ih-TA-shun*	Restoration of cardiac output and pulmonary ventilation after cardiac arrest using artificial respiration and chest compression or cardiac massage
cardioversion *KAR-de-o-ver-zhun*	Correction of an abnormal cardiac rhythm; may be accomplished pharmacologically, with antiarrhythmic drugs, or by application of electric current (see defibrillation)
coronary angiography *KOR-o-na-re an-je-OG-rah-fe*	Radiographic study of the coronary arteries after introduction of an opaque dye by means of a catheter threaded through blood vessels into the heart (see **FIG. 10-11**)
coronary artery bypass *graft (CABG)*	Surgical creation of a shunt to bypass a blocked coronary artery; the aorta is connected to a point past the obstruction with another vessel or a piece of another vessel, usually the left internal mammary artery or part of the leg's saphenous vein (see **FIG. 10-14**)
coronary calcium scan	Method for visualizing vessel-narrowing calcium deposits in coronary arteries; useful for diagnosing coronary artery disease in people at moderate risk or those who have undiagnosed chest pain; also known as a heart scan
creatine kinase MB (CK-MB) *KRE-ah-tin KI-naze*	Enzyme released in increased amounts from cardiac muscle cells following myocardial infarction (MI); serum assays help diagnose MI and determine the extent of muscle damage
CT angiography (CTA) *an-je-OG-rah-fe*	Computed tomography scan used to visualize vessels in the heart and other organs; requires only a small amount of dye injected into the arm; can rule out blocked coronary arteries that may cause a myocardial infarction (heart attack) in people with chest pain or abnormal stress tests
defibrillation *de-fib-rih-LA-shun*	Use of an electronic device (defibrillator) to stop fibrillation by delivering a brief electric shock to the heart; the shock may be delivered to the surface of the chest, as by an automated external defibrillator (AED), or directly into the heart through wire leads, using an implantable cardioverter defibrillator (ICD)
echocardiography *ek-o-kar-de-OG-rah-fe*	A noninvasive method that uses ultrasound to visualize internal cardiac structures
lipoprotein *lip-o-PRO-tene*	A compound of protein with lipid; lipoproteins are classified according to density as very low-density (VLDL), low-density (LDL), and high-density (HDL); relatively higher levels of HDLs have been correlated with cardiovascular health
percutaneous transluminal coronary angioplasty (PTCA)	Dilatation of a sclerotic blood vessel by means of a balloon catheter inserted into the vessel and then inflated to flatten plaque against the arterial wall (see **FIG. 10-12**)
stent	A small metal device in the shape of a coil or slotted tube that is placed inside an artery to keep the vessel open, for example, after balloon angioplasty (see **FIG. 10-13**)
stress test	Evaluation of physical fitness by continuous ECG monitoring during exercise; in a thallium stress test, a radioactive isotope of thallium is administered to trace blood flow through the heart during exercise
troponin (Tn) *tro-PO-nin*	A protein in muscle cells that regulates contraction; increased serum levels, primarily in the forms TnT and TnI, indicate recent myocardial infarction (MI)

The Lymphatic System

The **lymphatic system** is a widely distributed system with multiple functions **(FIG. 10-19)**. Its role in circulation is to return excess fluid and proteins from the tissues to the bloodstream. Blind-ended lymphatic capillaries pick up these materials in the tissues and carry them into larger vessels **(FIG. 10-20)**. The fluid carried in the lymphatic system is called **lymph.** Lymph drains from the lower part of the body and the upper left side into the **thoracic duct** (left lymphatic duct), which travels upward through the chest and empties into the left subclavian vein near the heart (see **FIG. 10-19**). The **right lymphatic duct** drains the body's upper right side and empties into the right subclavian vein.

Another major function of the lymphatic system is to protect the body from impurities and invading microorganisms (see discussion of immunity in Chapter 11). Along the path of the lymphatic vessels are small masses of lymphoid

extern.ir

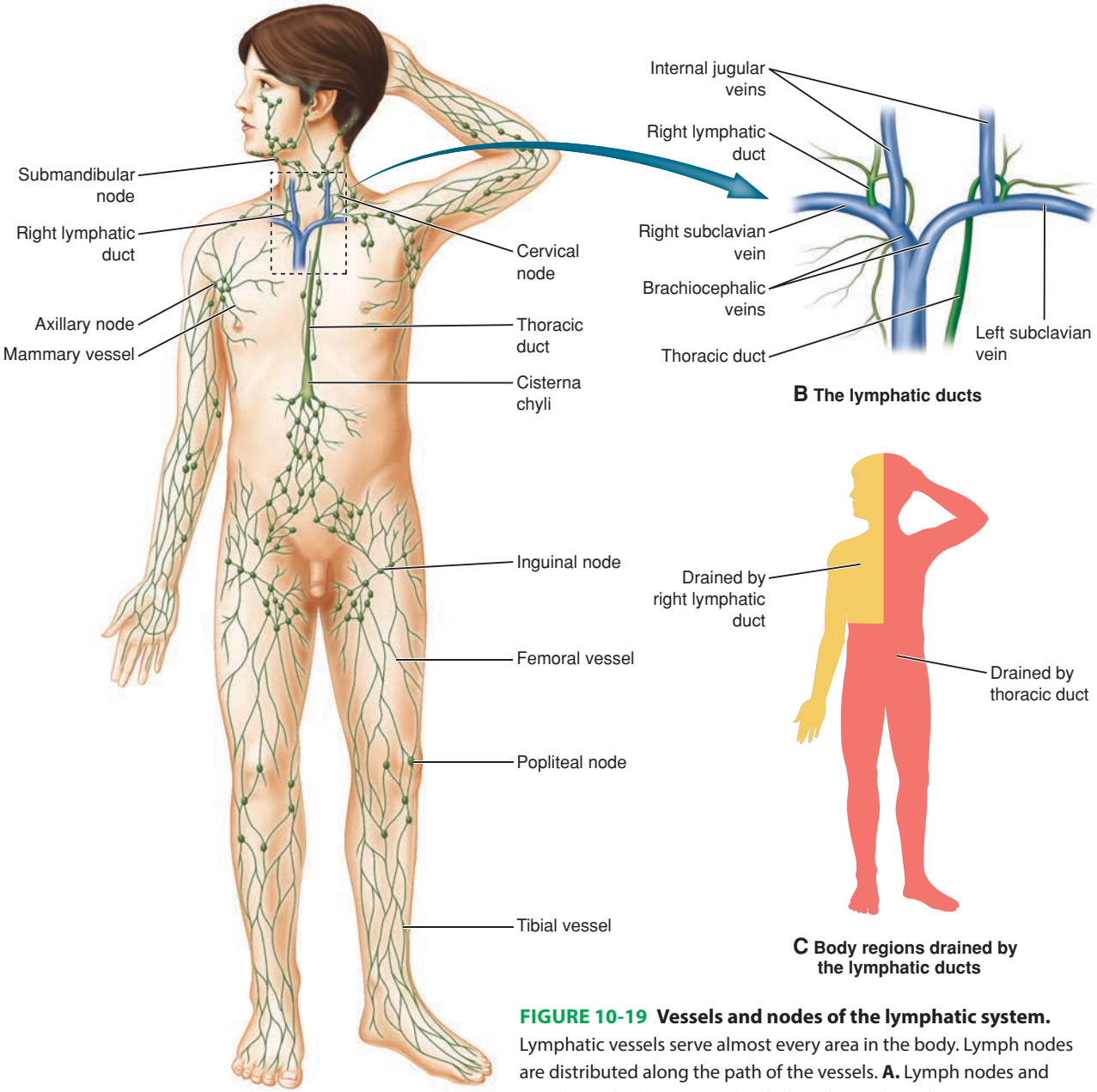

A The lymphatic network

B The lymphatic ducts

C Body regions drained by the lymphatic ducts

FIGURE 10-19 Vessels and nodes of the lymphatic system. Lymphatic vessels serve almost every area in the body. Lymph nodes are distributed along the path of the vessels. **A.** Lymph nodes and vessels. **B.** The thoracic and right lymphatic ducts drain into the subclavian veins. **C.** Body regions drained by the two lymphatic ducts.

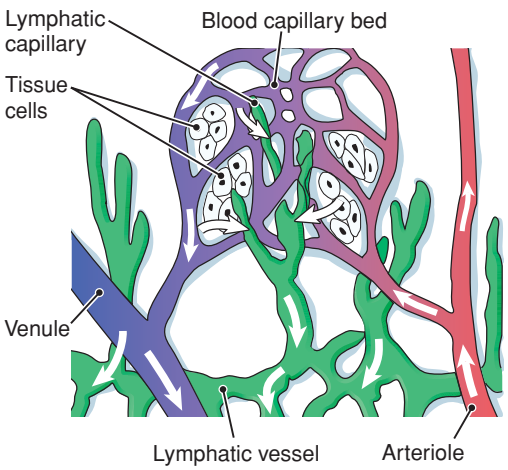

FIGURE 10-20 Lymphatic drainage in the tissues. Lymphatic capillaries pick up fluid and proteins left in the tissues and carry them back to the bloodstream.

extern.ir

tissue, the **lymph nodes** (FIG. 10-21). Their function is to filter the lymph as it passes through. They are concentrated in the cervical (neck), axillary (armpit), mediastinal (chest), and inguinal (groin) regions. Other protective organs and tissues of the lymphatic system include the following:

- **Tonsils**, located in the throat (pharynx). They filter inhaled or swallowed materials and aid in immunity early in life. The tonsils are further discussed in Chapter 12.
- **Thymus**, in the chest, above the heart. It processes and stimulates lymphocytes active in immunity.
- **Spleen**, in the upper left region of the abdomen. It filters blood and destroys old red blood cells.
- **Appendix**, attached to the large intestine. It may aid in the development of immunity.
- **Peyer patches**, in the lining of the intestine. They help protect against invading microorganisms.

A final function of the lymphatic system is to absorb digested fats from the small intestine (Chapter 13). These fats are then added to the blood with the lymph that drains from the thoracic duct.

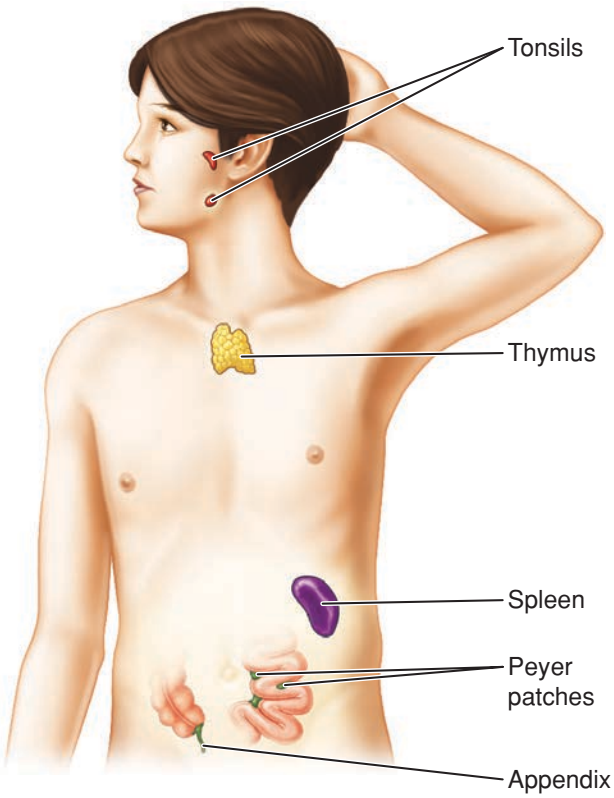

FIGURE 10-21 Location of lymphoid organs and tissue.

Terminology *Key Terms*

The terms listed below are emphasized in this chapter. Knowing them will help you organize and prioritize your learning. These boldface terms are also found, collectively, with all chapter key terms in the Glossary.

Lymphatic System

Normal Structure and Function	
appendix *ah-PEN-diks*	A small, finger-like mass of lymphoid tissue attached to the first part of the large intestine
lymph *Limf*	The thin, plasma-like fluid that drains from the tissues and is transported in lymphatic vessels (root: lymph/o)
lymph node	A small mass of lymphoid tissue along the path of a lymphatic vessel that filters lymph (root: lymphaden/o)
lymphatic system *lim-FAT-ik*	The system that drains fluid and proteins from the tissues and returns them to the bloodstream; this system also participates in immunity and aids in absorption of fats from the digestive tract
Peyer patches *PI-er*	Aggregates of lymphoid tissue in the lining of the intestine
right lymphatic duct	The lymphatic duct that drains fluid from the body's upper right side
spleen	A large reddish-brown organ in the upper left region of the abdomen; it filters blood and destroys old red blood cells (root: splen/o)

(continued)

extern.ir

Terminology Key Terms (Continued)

thoracic duct	The lymphatic duct that drains fluid from the upper left side of the body and all of the lower body; left lymphatic duct
thymus *THI-mus*	A lymphoid organ in the upper part of the chest beneath the sternum; it functions in immunity (root: thym/o)
tonsil *TON-sil*	Small mass of lymphoid tissue located in region of the throat (pharynx)

Roots Pertaining to the Lymphatic System

See **TABLE 10-3**.

Table 10-3 Roots for the Lymphatic System

Root	Meaning	Example	Definition of Example
lymph/o	lymph, lymphatic system	lymphoid *LIM-foyd*	resembling lymph or lymphatic tissue
lymphaden/o	lymph node	lymphadenitis *lim-fad-eh-NI-tis*	inflammation of a lymph node
lymphangi/o	lymphatic vessel	lymphangiogram *lim-FAN-je-o-gram*	x-ray image of lymphatic vessels
splen/o	spleen	splenalgia *sple-NAL-je-ah*	pain in the spleen
thym/o	thymus	athymia *ah-THI-me-ah*	absence of the thymus
tonsil/o	tonsil	tonsillar *TON-sil-ar*	pertaining to a tonsil

Exercise 10-3

Complete the exercise. To check your answers go to Appendix 11.

Fill in the blanks.

1. Tonsillectomy (*ton-sil-EK-to-me*) is surgical removal of a(n) _____ .
2. Thymopathy (*thi-MOP-ah-the*) is any disease of the _____ .
3. Lymphadenectomy (*lim-fad-eh-NEK-to-me*) is surgical removal of a(n) _____ .
4. Lymphedema (*limf-eh-DE-mah*) means swelling caused by obstruction of the flow of _____ .
5. A lymphangioma (*lim-fan-je-O-mah*) is a tumor of _____ .
6. Splenic (*SPLEN-ik*) means pertaining to the _____ .

extern.ir

Exercise 10-3 *(Continued)*

Identify and define the root in the following words.

	Root	Definition
7. lymphangial (*lim-FAN-je-al*)	_____	_____
8. perisplenitis (*per-e-sple-NI-tis*)	_____	_____
9. lymphadenography (*lim-fad-eh-NOG-rah-fe*)	_____	_____
10. tonsillectomy (*ton-sil-EK-to-me*)	_____	_____
11. hypothymism (*hi-po-THI-mizm*)	_____	_____

Use the appropriate root to write words with the following meanings.

12. Enlargement (-megaly) of the spleen	_____	_____
13. Inflammation of a tonsil	_____	_____
14. Any disease (-pathy) of the lymph nodes	_____	_____
15. Inflammation of lymphatic vessels	_____	_____
16. Pertaining to (-ic) the thymus	_____	_____
17. A tumor (-oma) of lymphatic tissue	_____	_____

Clinical Aspects of the Lymphatic System

Changes in the lymphatic system are often related to infection and may consist of inflammation and enlargement of the nodes, called **lymphadenitis**, or inflammation of the vessels, called **lymphangitis.** Obstruction of lymphatic vessels because of surgical excision or infection results in tissue swelling, or **lymphedema** (BOX 10-4). Any neoplastic disease involving lymph nodes is termed **lymphoma.** These neoplastic disorders affect the white blood cells found in the lymphatic system, and they are discussed more fully in Chapter 11.

CLINICAL PERSPECTIVES — BOX 10-4

Lymphedema: When Lymph Stops Flowing

Fluid balance in the body requires appropriate distribution of fluid among the cardiovascular system, lymphatic system, and the tissues. Edema occurs when the balance is tipped toward excess fluid in the tissues. Often, edema is due to heart failure. However, blockage of lymphatic vessels (with resulting fluid accumulation in the tissues) can cause another form of edema, called lymphedema. The clinical hallmark of lymphedema is chronic swelling of an arm or leg, whereas heart failure usually causes swelling of both legs.

Lymphedema may be either primary or secondary. Primary lymphedema is a rare congenital condition caused by abnormal development of lymphatic vessels. Secondary lymphedema, or acquired lymphedema, can develop as a result of trauma to a limb, surgery, radiation therapy, or infection of the lymphatic vessels (lymphangitis). One of the most common causes of lymphedema is the removal of axillary lymph nodes during mastectomy, which disrupts lymph flow from the adjacent arm. Lymphedema may also occur following prostate surgery.

Therapies that encourage the flow of fluid through the lymphatic vessels are useful in treating lymphedema. These therapies may include elevation of the affected limb, manual lymphatic drainage through massage, light exercise, and firm wrapping of the limb to apply compression. In addition, changes in daily habits can lessen the effects of lymphedema. For example, further blockage of lymph drainage can be prevented by wearing loose clothing and jewelry, carrying a purse or handbag on the unaffected arm, and not crossing the legs when sitting. Lymphangitis requires the use of appropriate antibiotics. Prompt treatment is necessary because in addition to swelling, other complications include poor wound healing, skin ulcers, and increased risk of infection.

extern.ir

Terminology Key Terms

The terms listed below are emphasized in this chapter. Knowing them will help you organize and prioritize your learning. These boldface terms are also found, collectively, with all chapter key terms in the Glossary.

Lymphatic Disorders

lymphadenitis *lim-fad-eh-NI-tis*	Inflammation and enlargement of lymph nodes, usually as a result of infection
lymphangitis *lim-fan-JI-tis*	Inflammation of lymphatic vessels as a result of bacterial infection; appears as painful red streaks under the skin **(FIG. 10-22A)**
lymphedema *lim-feh-DE-mah*	Swelling of tissues with lymph caused by obstruction or excision of lymphatic vessels (see **FIG. 10-22B** and **BOX 10-4**)
lymphoma *lim-FO-mah*	Any neoplastic disease of lymphoid tissue

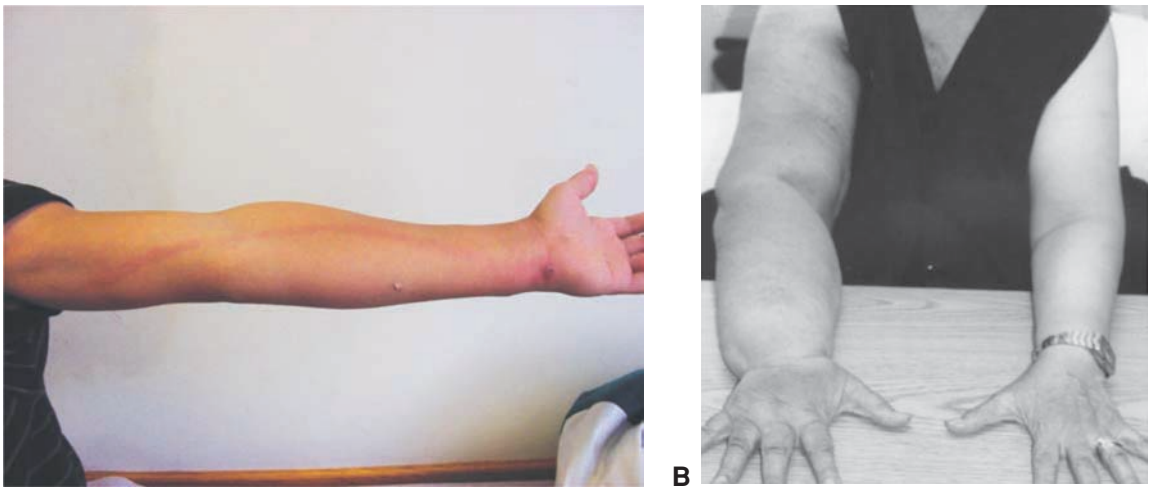

FIGURE 10-22 Lymphatic disorders. A. Lymphangitis is inflammation of lymphatic vessels. Note the linear red streak proximal to a skin infection. **B.** Lymphedema of the upper right extremity following removal of axillary lymph nodes and blockage of lymph flow.

Terminology Enrichment Terms

The terms listed below expand on the key terms to increase your knowledge of this chapter topic.

Normal Structure and Function

apical pulse *AP-ih-kal*	Pulse felt or heard over the heart's apex; it is measured in the fifth left intercostal space (between the ribs) about 8 to 9 cm from the midline
cardiac output	The amount of blood pumped from the right or left ventricle per minute
compliance	The ease with which a structure expands under pressure, as in a blood vessel expanding to receive blood
Korotkoff sounds *ko-ROT-kof*	Arterial sounds heard with a stethoscope during determination of blood pressure with a cuff
perfusion *per-FU-zhun*	The passage of fluid, such as blood, through an organ or tissue
precordium *pre-KOR-de-um*	The anterior region over the heart and the lower part of the thorax; adjective: precordial

extern.ir

Terminology — *Enrichment Terms (Continued)*

pulse pressure	The difference between systolic and diastolic pressure
stroke volume	The amount of blood ejected by the left ventricle with each beat
Valsalva maneuver *val-SAL-vah*	Bearing down, as in childbirth or defecation, by attempting to exhale forcefully with the nose and throat closed; this action has an effect on the cardiovascular system
Symptoms and Conditions	
bruit *brwe*	An abnormal sound heard in auscultation
cardiac tamponade *tam-pon-ADE*	Pathologic accumulation of fluid in the pericardial sac; may result from pericarditis or injury to the heart or great vessels
ectopic beat *ek-TOP-ik*	A heartbeat that originates from some part of the heart other than the SA node
extrasystole *eks-trah-SIS-to-le*	Premature heart contraction that occurs separately from the normal beat and originates from a part of the heart other than the SA node
flutter	Very rapid (200–300 bpm) but regular contractions, as in the atria or the ventricles
hypotension *hi-po-TEN-shun*	A condition of lower-than-normal blood pressure
intermittent claudication *claw-dih-KA-shun*	Pain in a muscle during exercise caused by inadequate blood supply; the pain disappears with rest
mitral valve prolapse *PRO-laps*	Movement of the mitral valve cusps into the left atrium when the ventricles contract
occlusive vascular disease	Arteriosclerotic disease of the vessels, usually peripheral vessels
palpitation *pal-pih-TA-shun*	A sensation of abnormally rapid or irregular heartbeat
pitting edema	Edema that retains the impression of a finger pressed firmly into the skin **(FIG. 10-23)**

(continued)

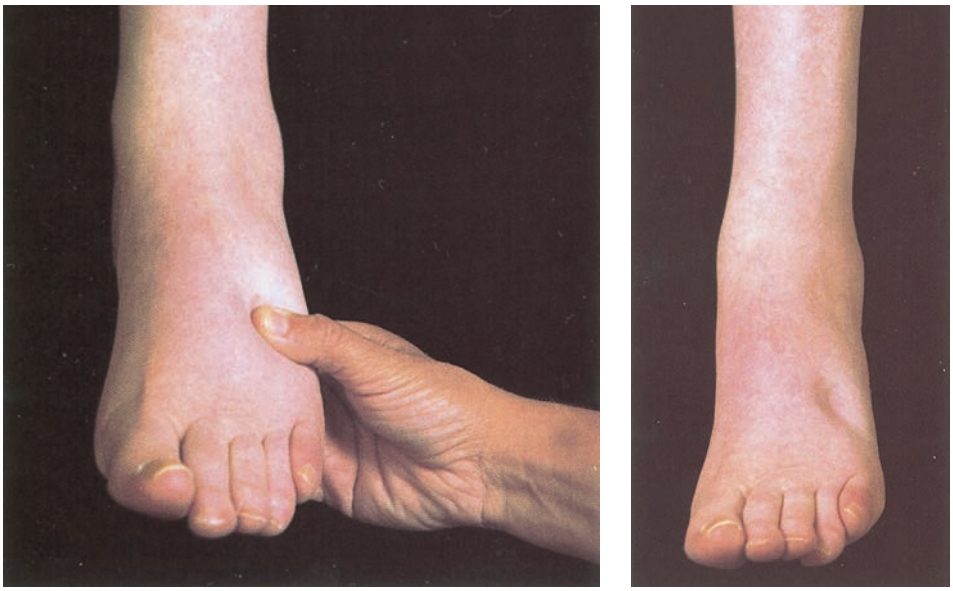

A B

FIGURE 10-23 Pitting edema. When the skin is pressed firmly with the finger (**A**), a pit remains after the finger is removed (**B**).

extern.ir

Terminology — *Enrichment Terms (Continued)*

polyarteritis nodosa *no-DO-sah*	Potentially fatal collagen disease causing inflammation of small visceral arteries; symptoms depend on the organ affected
Raynaud disease *ra-NO*	A disorder characterized by abnormal constriction of peripheral vessels in the arms and legs on exposure to cold
regurgitation *re-gur-jih-TA-shun*	A backward flow, such as the backflow of blood through a defective valve
stasis *STA-sis*	Stoppage of normal flow, as of blood or urine; blood stasis may lead to dermatitis and ulcer formation
subacute bacterial endocarditis (SBE)	Bacterial growth in a heart or valves previously damaged by rheumatic fever
tetralogy of Fallot *fal-O*	A combination of four congenital heart abnormalities: pulmonary artery stenosis, interventricular septal defect, displacement of the aorta to the right, and right ventricular hypertrophy
thromboangiitis obliterans	Inflammation and thrombus formation resulting in occlusion of small vessels, especially in the legs; most common in young men and correlated with heavy smoking; thrombotic occlusion of leg vessels may lead to gangrene of the feet; patients show a hypersensitivity to tobacco; also called Buerger disease
vegetation	Irregular bacterial outgrowths on the heart valves; associated with rheumatic fever
Wolff–Parkinson–White syndrome (WPW)	A cardiac arrhythmia consisting of tachycardia and a premature ventricular beat caused by an alternative conduction pathway
Diagnosis	
cardiac catheterization	Passage of a catheter into the heart through a vessel to inject a contrast medium for imaging, diagnosis, obtaining samples, or measuring pressure
central venous pressure (CVP)	Pressure in the superior vena cava
cineangiocardiography *sin-eh-an-je-o-kar-de-OG-rah-fe*	The photographic recording of fluoroscopic images of the heart and large vessels using motion picture techniques
Doppler echocardiography	An imaging method used to study the rate and pattern of blood flow
Holter monitor	A portable device that can record from 24 hours to 1 month of an individual's ECG readings during normal activity
homocysteine *ho-mo-SIS-te-ene*	An amino acid in the blood that at higher-than-normal levels is associated with increased risk of cardiovascular disease
phlebotomist *fleh-BOT-o-mist*	Technician who specializes in drawing blood
phonocardiography *fo-no-kar-de-OG-rah-fe*	Electronic recording of heart sounds
plethysmography *pleh-thiz-MOG-rah-fe*	Measurement of changes in the size of a part based on the amount of blood contained in or passing through it; impedance plethysmography measures changes in electrical resistance and is used in the diagnosis of deep vein thrombosis
pulmonary capillary wedge pressure (PCWP)	Pressure measured by a catheter in a branch of the pulmonary artery. It is an indirect measure of pressure in the left atrium (see **BOX 10-2**)
radionuclide heart scan	Imaging of the heart after injection of a radioactive isotope; the PYP (pyrophosphate) scan using technetium-99m (^{99m}Tc) is used to test for myocardial infarction because the isotope is taken up by damaged tissue; the MUGA (multigated acquisition) scan gives information on heart function
Swan–Ganz catheter	A cardiac catheter with a balloon at the tip that is used to measure pulmonary arterial pressure; it is flow guided through a vein into the right side of the heart and then into the pulmonary artery

extern.ir

Terminology *Enrichment Terms (Continued)*

transesophageal *echocardiography (TEE)*	Use of an ultrasound transducer placed endoscopically into the esophagus to obtain images of the heart
triglyceride *tri-GLIS-er-ide*	Simple fat that circulates in the bloodstream
ventriculography *ven-trik-u-LOG-rah-fe*	X-ray study of the heart's ventricles after introduction of an opaque dye by means of a catheter
Treatment and Surgical Procedures	
atherectomy *ath-er-EK-to-me*	Removal of atheromatous plaque from the lining of a vessel; may be done by open surgery or through the vessel's lumen
commissurotomy *kom-ih-shur-OT-o-me*	Surgical incision of a scarred mitral valve to increase the size of the valvular opening
embolectomy *em-bo-LEK-to-me*	Surgical removal of an embolus
intraaortic balloon pump (IABP)	A mechanical assist device that consists of an inflatable balloon pump inserted through the femoral artery into the thoracic aorta; it inflates during diastole to improve coronary circulation and deflates before systole to allow blood ejection from the heart
ventricular assist device (VAD)	A pump that takes over a ventricle's function in delivering blood into the pulmonary or systemic circuit; these devices are used to assist patients awaiting heart transplantation or those who are recovering from heart failure; most common is a left ventricular assist device (LVAD)
Drugs	
angiotensin-converting enzyme (ACE) inhibitor	A drug that lowers blood pressure by blocking the formation of angiotensin II, a substance that normally acts to increase blood pressure
angiotensin receptor blocker (ARB)	A drug that blocks tissue receptors for angiotensin II; angiotensin II receptor antagonist
antiarrhythmic agent	A drug that regulates the rate and rhythm of the heartbeat
beta-adrenergic blocking agent	Drug that decreases the rate and strength of heart contractions; beta-blocker
calcium-channel blocker	Drug that controls the rate and force of heart contraction by regulating calcium entrance into the cells
Coumadin *KU-mah-din*	Drug that inhibits clotting by inhibiting formation of vitamin K, a factor necessary for blood coagulation. Trade name for the generic warfarin
digitalis *dij-ih-TAL-is*	A drug that slows and strengthens heart muscle contractions
diuretic *di-u-RET-ik*	Drug that eliminates fluid by increasing the kidney's output of urine; lowered blood volume decreases the heart's workload
heparin *HEP-ah-rin*	Substance that inhibits blood clotting by interfering with the conversion of prothrombin to thrombin (Chapter 11)
hypolipidemic agent *hi-po-lip-ih-DE-mik*	Drug that lowers serum cholesterol
lidocaine *LI-do-kane*	A local anesthetic that is used intravenously to treat cardiac arrhythmias
loop diuretic	Drug that increases urine output by inhibiting electrolyte reabsorption in the kidney nephrons (loops) (Chapter 14)

(continued)

extern.ir

Terminology Enrichment Terms (Continued)

nitroglycerin *ni-tro-GLIS-er-in*	A drug used in the treatment of angina pectoris to dilate coronary vessels
statins	Drugs that act to lower lipids in the blood; the drug names end with *-statin*, such as lovastatin, pravastatin, and atorvastatin
streptokinase (SK) *strep-to-KI-nase*	An enzyme used to dissolve blood clots
tissue plasminogen activator (tPA)	A drug used to dissolve blood clots; it activates production of a substance (plasmin) in the blood that normally dissolves clots
vasodilator *vas-o-di-LA-tor*	A drug that widens blood vessels and improves blood flow

Terminology Abbreviations

The abbreviations listed below are emphasized in this chapter. These are also found, collectively, with all chapter abbreviations in Appendix 2.

ACE	Angiotensin-converting enzyme
AED	Automated external defibrillator
AF	Atrial fibrillation
AMI	Acute myocardial infarction
APC	Atrial premature complex
AR	Aortic regurgitation
ARB	Angiotensin receptor blocker
AS	Aortic stenosis; arteriosclerosis
ASCVD	Arteriosclerotic cardiovascular disease
ASD	Atrial septal defect
ASHD	Arteriosclerotic heart disease
AT	Atrial tachycardia
AV	Atrioventricular
BBB	Bundle branch block (left or right)
BP	Blood pressure
bpm	Beats per minute
CABG	Coronary artery bypass graft
CAD	Coronary artery disease
CCU	Coronary/cardiac care unit
CHD	Coronary heart disease
CHF	Congestive heart failure
CK-MB	Creatine kinase MB
CPR	Cardiopulmonary resuscitation
CRP	C-reactive protein
CTA	Computed tomography angiography
CVA	Cerebrovascular accident
CVD	Cardiovascular disease
CVI	Chronic venous insufficiency
CVP	Central venous pressure
DOE	Dyspnea on exertion
DVT	Deep vein thrombosis
ECG (EKG)	Electrocardiogram, electrocardiography
HDL	High-density lipoprotein
hs-CRP	High-sensitivity C-reactive protein (test)
HTN	Hypertension
IABP	Intra-aortic balloon pump
ICD	Implantable cardioverter defibrillator
IVCD	Intraventricular conduction delay
JVP	Jugular venous pulse
LAD	Left anterior descending (coronary artery)
LAHB	Left anterior hemiblock
LDL	Low-density lipoprotein
LV	Left ventricle
LVAD	Left ventricular assist device

extern.ir

Terminology *Abbreviations (Continued)*

LVEDP	Left ventricular end-diastolic pressure
LVH	Left ventricular hypertrophy
MI	Myocardial infarction
mm Hg	Millimeters of mercury
MR	Mitral regurgitation, reflux
MS	Mitral stenosis
MUGA	Multigated acquisition (scan)
MVP	Mitral valve prolapse
MVR	Mitral valve replacement
NSR	Normal sinus rhythm
P	Pulse
PAC	Premature atrial contraction
PAP	Pulmonary arterial pressure
PCI	Percutaneous coronary intervention
PCWP	Pulmonary capillary wedge pressure
PMI	Point of maximal impulse
PSVT	Paroxysmal supraventricular tachycardia
PTCA	Percutaneous transluminal coronary angioplasty
PVC	Premature ventricular contraction
PVD	Peripheral vascular disease
PYP	Pyrophosphate (scan)
S_1	First heart sound
S_2	Second heart sound
SA	Sinoatrial
SBE	Subacute bacterial endocarditis
SK	Streptokinase
SVT	Supraventricular tachycardia
^{99m}Tc	Technetium-99m
TEE	Transesophageal echocardiography
Tn	Troponin
tPA	Tissue plasminogen activator
VAD	Ventricular assist device
VF, v fib	Ventricular fibrillation
VLDL	Very-low-density lipoprotein
VPC	Ventricular premature complex
VSD	Ventricular septal defect
VT	Ventricular tachycardia
VTE	Venous thromboembolism
WPW	Wolff–Parkinson–White syndrome

Case Study Revisited

Carlos's Follow-Up

Carlos was scheduled the next day for his procedure. He arrived at the hospital in the morning and was taken to the operating room after the nurse prepared him for surgery. His cardiologist performed a pulmonary vein catheter ablation. The procedure involved destruction of that portion of the heart's conduction pathway that is involved in the arrhythmia. The surgery was uneventful with no complications and Carlos was released to go home that day. He was told he might feel some discomfort at the catheter insertion site and might also experience mild chest discomfort, mild shortness of breath, and fatigue. Discharge instructions included restricted activity during the next week, including not lifting an object weighing more than 10 pounds, no pushing or pulling heavy objects, such as mowing the lawn, and to stop any activity before becoming tired. Before his parents took him home, Carlos scheduled a follow-up appointment with the cardiologist in 1 week.

At his 1-week follow-up appointment Carlos said he initially had some mild chest pain for 2 days following the surgery but that pain had since gone away. His procedure site had healed nicely and his ECG showed normal sinus rhythm. At his extended follow-up appointments with the cardiologist he had no recurrence of the atrial fibrillation. Carlos's pre-existing heart condition, however, prohibited him from performing required duties in the army, so he was not able to return to boot camp. He was released from the service and returned to civilian life.

extern.ir

CHAPTER 10

Review

This review tests your understanding of the content introduced in this chapter. Follow the instructions for each exercise and check your answers in Appendix 11.

LABELING EXERCISE

THE CARDIOVASCULAR SYSTEM

Write the name of each numbered part on the corresponding line of the answer sheet.

Aorta
Head and arms
Inferior vena cava
Internal organs
Left atrium
Left lung
Left pulmonary artery
Left pulmonary vein
Left ventricle
Legs
Right atrium
Right lung
Right ventricle
Superior vena cava

1. _____
2. _____
3. _____
4. _____
5. _____
6. _____
7. _____
8. _____
9. _____
10. _____
11. _____
12. _____
13. _____
14. _____

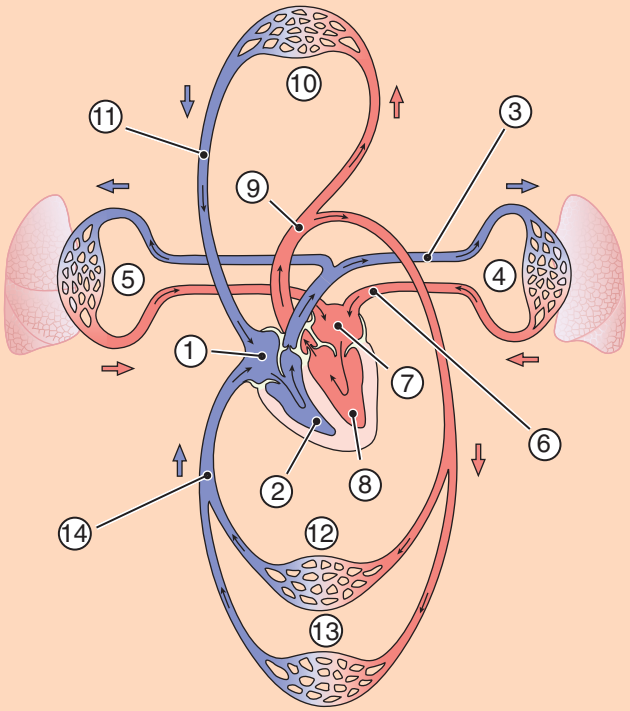

Blood high in oxygen
Blood low in oxygen

extern.ir

THE HEART AND GREAT VESSELS

Write the name of each numbered part on the corresponding line of the answer sheet.

Aortic arch
Aortic valve
Apex
Ascending aorta
Endocardium
Epicardium
Inferior vena cava
Interventricular septum
Left atrioventricular (bicuspid) valve
Left atrium
Left pulmonary artery
Left pulmonary veins
Left ventricle
Myocardium
Pulmonary trunk
Pulmonary valve
Right atrioventricular (tricuspid) valve
Right atrium
Right pulmonary artery
Right ventricle
Superior vena cava

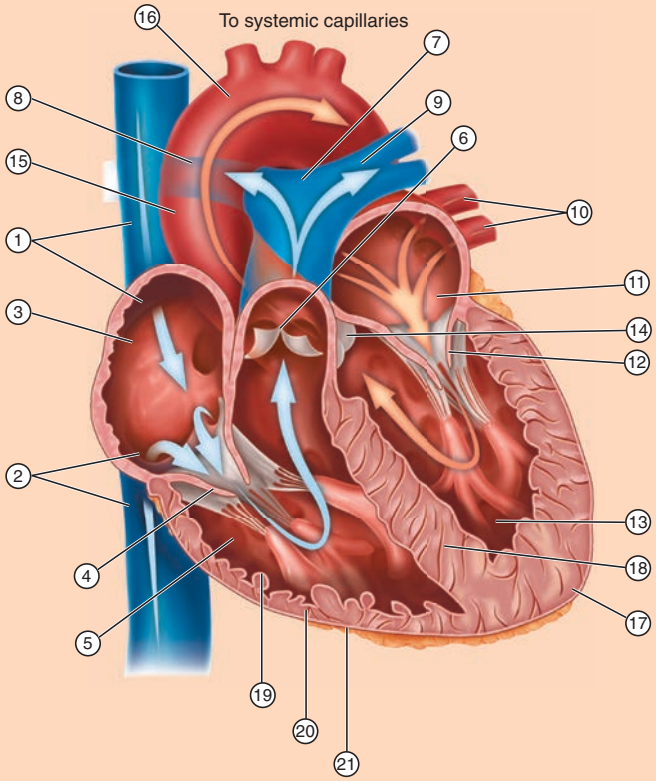

1. _____
2. _____
3. _____
4. _____
5. _____
6. _____
7. _____
8. _____
9. _____
10. _____
11. _____
12. _____
13. _____
14. _____
15. _____
16. _____
17. _____
18. _____
19. _____
20. _____
21. _____

LOCATION OF LYMPHOID ORGANS AND TISSUE

Write the name of each numbered part on the corresponding line of the answer sheet.

Appendix
Peyer patches
Spleen
Thymus
Tonsils

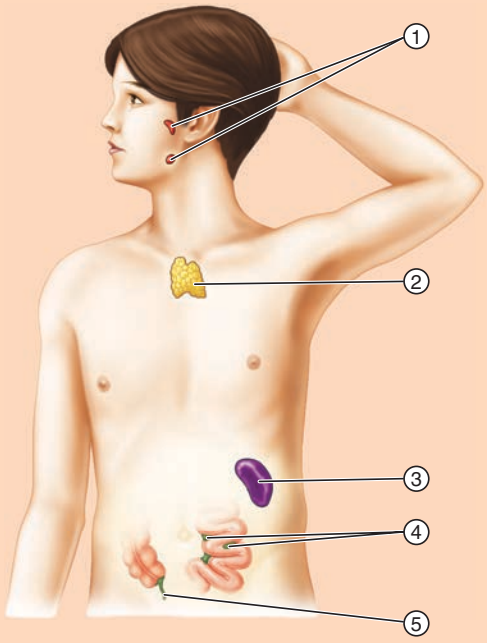

1. _____
2. _____
3. _____
4. _____
5. _____

extern.ir

TERMINOLOGY

MATCHING

Match the following terms, and write the appropriate letter to the left of each number.

____ 1.	atherosclerosis	a. twisted and swollen vessel
____ 2.	varix	b. blockage
____ 3.	occlusion	c. absence of a heartbeat
____ 4.	aneurysm	d. localized dilatation of a vessel
____ 5.	asystole	e. accumulation of fatty deposits

____ 6.	thrombosis	a. ineffective quivering of muscle
____ 7.	myocarditis	b. formation of a blood clot in a vessel
____ 8.	infarction	c. inflammation of the heart muscle
____ 9.	fibrillation	d. local deficiency of blood
____ 10.	ischemia	e. local death of tissue

____ 11.	lumen	a. vessel that empties into the right atrium
____ 12.	pericardium	b. fibrous sac around the heart
____ 13.	apex	c. structure that keeps fluid moving forward
____ 14.	vena cava	d. central opening of a vessel
____ 15.	valve	e. lower, pointed region of the heart

____ 16.	HDL	a. stroke
____ 17.	HTN	b. a type of blood lipid
____ 18.	VT	c. rapid beat in the heart's lower chambers
____ 19.	CVA	d. high blood pressure
____ 20.	CABG	e. surgery to bypass a blocked vessel

Enrichment Terms

____ 21.	diuretic	a. removal of plaque
____ 22.	regurgitation	b. drug that increases urinary output
____ 23.	streptokinase	c. premature contraction
____ 24.	atherectomy	d. drug used to dissolve blood clots
____ 25.	extrasystole	e. backward flow

FILL IN THE BLANKS

Complete the sentence with the correct term(s).

26. The heart muscle is the _____.
27. A microscopic vessel through which materials are exchanged between the blood and the tissues is a(n) _____.
28. Each upper receiving chamber of the heart is a(n) _____.
29. A sinus rhythm originates in the _____.
30. The largest artery is the _____.
31. A phlebotomist (*fleh-BOT-o-mist*) is one who drains blood from a(n) _____.
32. The term *varicoid* pertains to a(n) _____.
33. The lymphoid organ in the chest is the _____.
34. Blood returning to the heart from the systemic circuit enters the chamber called the _____.
35. At its termination in the abdomen, the aorta divides into the right and left (see **FIG. 10-6**) _____.
36. The large artery in the neck that supplies blood to the brain is the (see **FIG. 10-6**) _____.

extern.ir

37. The large vein that drains the lower body and empties into the heart is the (see FIG. 10-7) _____ .
38. The right lymphatic duct and the thoracic duct drain into vessels called the (see FIG. 10-19) _____ .
39. In Carlos's case study, the device he wore to record his heart rhythm is called a(n) _____ .
40. The abnormal heart rhythm that prevented Carlos from completing basic training is termed _____ .
41. The catheterization technique used to correct Carlos's arrhythmia is termed cardiac _____ .

TRUE–FALSE

Examine the following statements. If the statement is true, write T in the first blank. If the statement is false, write F in the first blank, and correct the statement by replacing the underlined word in the second blank.

	True or False	Correct Answer
42. The left AV valve is the aortic valve.	_____	_____
43. The pulmonary vein carries blood to the lungs.	_____	_____
44. The brachial artery supplies blood to the leg.	_____	_____
45. Diastole is the relaxation phase of the heart cycle.	_____	_____
46. The left ventricle pumps blood into the aorta.	_____	_____
47. Blood returning from the lungs to the heart enters the left atrium.	_____	_____
48. The systemic circuit pumps blood to the lungs.	_____	_____
49. An artery is a vessel that carries blood back to the heart.	_____	_____
50. Peyer patches are in the intestine.	_____	_____
51. Bradycardia is a lower-than-average heart rate.	_____	_____
52. A beta-adrenergic blocking agent slows the heart rate.	_____	_____

ELIMINATIONS

In each of the sets below, underline the word that does not fit in with the rest and explain the reason for your choice.

53. SA node — Purkinje fibers — apex — AV node — AV bundle

_____

54. murmur — systolic — sphygmomanometer — mm Hg — diastolic

_____

55. U — S_1 — QRS — T — P

_____

56. thymus — spleen — cusp — tonsil — Peyer patches

_____

DEFINITIONS

Define the following terms.

57. avascular (*a-VAS-ku-lar*) _____
58. atriotomy (*a-tre-OT-o-me*) _____
59. splenectomy (*sple-NEK-to-me*) _____
60. supraventricular (*su-prah-ven-TRIK-u-lar*) _____
61. phlebectasis (*fleb-EK-tah-sis*) _____

extern.ir

Write words for the following definitions.

62. An instrument (-tome) for incising a valve _____
63. Suture (-rhaphy) of the aorta _____
64. Excision of a lymph node _____
65. Physician who specializes in study and treatment of the heart _____
66. Stoppage (-stasis) of lymph flow _____
67. Surgical fixation (-pexy) of the spleen _____

Use the root aort/o to write words with the following meanings.

68. Narrowing (-stenosis) of the aorta _____
69. Downward displacement (-ptosis) of the aorta _____
70. Radiograph (-gram) of the aorta _____
71. Before or in front of (pre-) the aorta _____

ADJECTIVES

Write the adjective form of the following words.

72. ventricle _____
73. septum _____
74. valve _____
75. thymus _____
76. sclerosis _____
77. spleen _____

PLURALS

Write the plural form of the following words.

78. thrombus _____
79. varix _____
80. stenosis _____
81. septum _____

ABBREVIATIONS

Write the meaning of the following abbreviations as they apply to the cardiovascular system.

82. AED _____
83. LVAD _____
84. DVT _____
85. VF _____
86. BBB _____
87. PTCA _____

extern.ir

WORD BUILDING

Write words for the following definitions using the word parts given. Each word part can be used more than once.

-pathy	phleb	lymph/o	-oma	angi/o	-itis	aden/o	-plasty

88. inflammation of a vein _____
89. any disease of a lymph node _____
90. neoplasm involving the lymphatic system _____
91. plastic repair of any vessel _____
92. inflammation of a lymphatic vessel _____
93. any disease of a vessel _____
94. inflammation of a lymph node _____
95. plastic repair of a vein _____
96. neoplasm of a lymph node _____
97. tumor involving any vessels _____

WORD ANALYSIS

Define the following words and give the meaning of the word parts in each. Use a dictionary if necessary.

98. phonocardiography (*fo-no-kar-de-OG-rah-fe*)
    a. phon/o _____
    b. cardi/o _____
    c. -graphy _____
99. endarterectomy (*end-ar-ter-EK-to-me*)
    a. end/o _____
    b. arteri/o _____
    c. ecto- _____
    d. -tomy _____
100. telangiectasia (*tel-an-je-ek-TA-ze-ah*)
    a. tel- _____
    b. angi/o _____
    c. -ectasia _____
101. lymphangiophlebitis (*lim-fan-je-o-fleh-BI-tis*)
    a. lymph/o _____
    b. angi/o _____
    c. phleb/o _____
    d. -itis _____

extern.ir

Additional Case Studies

Case Study 10-1A: Percutaneous Transluminal Coronary Angioplasty (PTCA) and Echocardiogram

Greta, a 68 y/o woman, was admitted to the coronary care unit (CCU) with chest pain, dyspnea, diaphoresis, syncope, and nausea. She had taken three sublingual doses of nitroglycerin tablets within a 10-minute time span without relief before dialing 911. A previous stress test and thallium uptake scan suggested cardiac disease.

Her family history was significant for cardiovascular disease. Her father died at the age of 62 of an acute myocardial infarction (AMI). Her mother had bilateral carotid endarterectomies and a femoral popliteal bypass procedure and died at the age of 72 of congestive heart failure (CHF). Greta's elder sister died from a ruptured aortic aneurysm at the age of 65. Greta's electrocardiogram (ECG) on admission showed tachycardia with a rate of 126 bpm with inverted T waves. A murmur was heard at S_1. Her skin color was dusky to cyanotic on her lips and fingertips. Her admitting diagnosis was possible coronary artery disease (CAD), acute myocardial infarction, and valvular disease.

Cardiac catheterization with balloon angioplasty (PTCA) was performed the next day. Significant stenosis of the left anterior descending coronary artery was shown and treated with angioplasty and stent placement. Left ventricular function was normal.

Echocardiography, 2 days later, showed normal-sized left and enlarged right ventricular cavities. The mitral valve had normal amplitude of motion. The anterior and posterior leaflets moved in opposite directions during diastole. There was a late systolic prolapse of the mitral leaflet at rest. The left atrium was enlarged. The impression of the study was mitral prolapse with regurgitation. Surgery was recommended.

Case 10-1B: Mitral Valve Replacement (MVR) Operative Report

Greta was transferred to the operating room, placed in a supine position, and given general endotracheal anesthesia. The surgeon entered her pericardium longitudinally through a median sternotomy and found that her heart was enlarged, with a dilated right ventricle. The left atrium was dilated. Preoperative transesophageal echocardiography revealed severe mitral regurgitation with severe posterior and anterior prolapse. Extracorporeal circulation was established. The aorta was cross-clamped, and cardioplegic solution (to stop the heartbeat) was given into the aortic root intermittently for myocardial protection.

The left atrium was entered via the interatrial groove on the right, exposing the mitral valve. The middle scallop of the posterior leaflet was resected. The remaining leaflets were removed to the areas of the commissures and preserved for the sliding plasty. The elongated chordae were shortened to better anchor the valve cusps. The surgeon slid the posterior leaflet across the midline and sutured it in place. A no. 30 annuloplasty ring was sutured in place with interrupted no. 2-0 Dacron suture. The valve was tested by inflating the ventricle with NSS and proved to be competent. The left atrium was closed with continuous no. 4-0 Prolene suture. Air was removed from the heart. The cross-clamp was removed. Cardiac action resumed with normal sinus rhythm. After a period of cardiac recovery and attainment of normothermia, cardiopulmonary bypass was discontinued.

Protamine was given to counteract the heparin. Pacer wires were placed in the right atrium and ventricle. Silicone catheters were placed in the pleural and substernal spaces. The sternum and soft tissue wound was closed. Greta recovered from her surgery and was discharged 6 days later.

extern.ir

Case Studies 10-1A and 10-1B Questions

Follow the instructions for each question and check your answers in Appendix 11.

Multiple Choice. *Select the best answer, and write the letter of your choice to the left of each number.*

_____ 1. The word transluminal means
- a. across a wall
- b. between branches
- c. through a valve
- d. through a central opening

_____ 2. The term that means backflow, as of blood, is
- a. infarction
- b. regurgitation
- c. amplitude
- d. prolapse

_____ 3. The term for a narrowing of the bicuspid valve is
- a. atrial stenosis
- b. tricuspid prolapse
- c. mitral stenosis
- d. pulmonic prolapse

_____ 4. Blowout of a dilated segment of the main artery is
- a. peritoneal infarction
- b. coarctation of the aorta
- c. cardiac tamponade
- d. ruptured aortic aneurysm

_____ 5. Sternotomy is
- a. incision into the sternum
- b. removal of the sternum
- c. narrowing of the sternum
- d. surgical fixation of the sternum

_____ 6. Extracorporeal circulation occurs
- a. within the brain
- b. within the pericardium
- c. outside the body
- d. in the legs

_____ 7. Protamine was given to counteract the action of the heparin. This drug action is described as
- a. antagonistic
- b. synergy
- c. potentiating
- d. simulation

Write the word or phrase from the case studies that means each of the following.

8. Shortness of breath _____
9. An abnormal heart sound _____
10. Test of cardiac function during physical exertion _____
11. Pertaining to both the heart and blood vessels _____
12. Excision of the inner lining along with atherosclerotic plaque from an artery (plural) _____
13. Under the tongue _____
14. Bluish discoloration of the skin due to lack of oxygen _____
15. The state of profuse perspiration _____
16. Between the atria _____
17. Below the sternum _____

Define the following abbreviations.

18. ECG _____
19. AMI _____
20. CAD _____
21. LAD _____
22. CHF _____
23. TEE _____
24. MVR _____
25. CCU _____

extern.ir

CHAPTER 11

Blood and Immunity

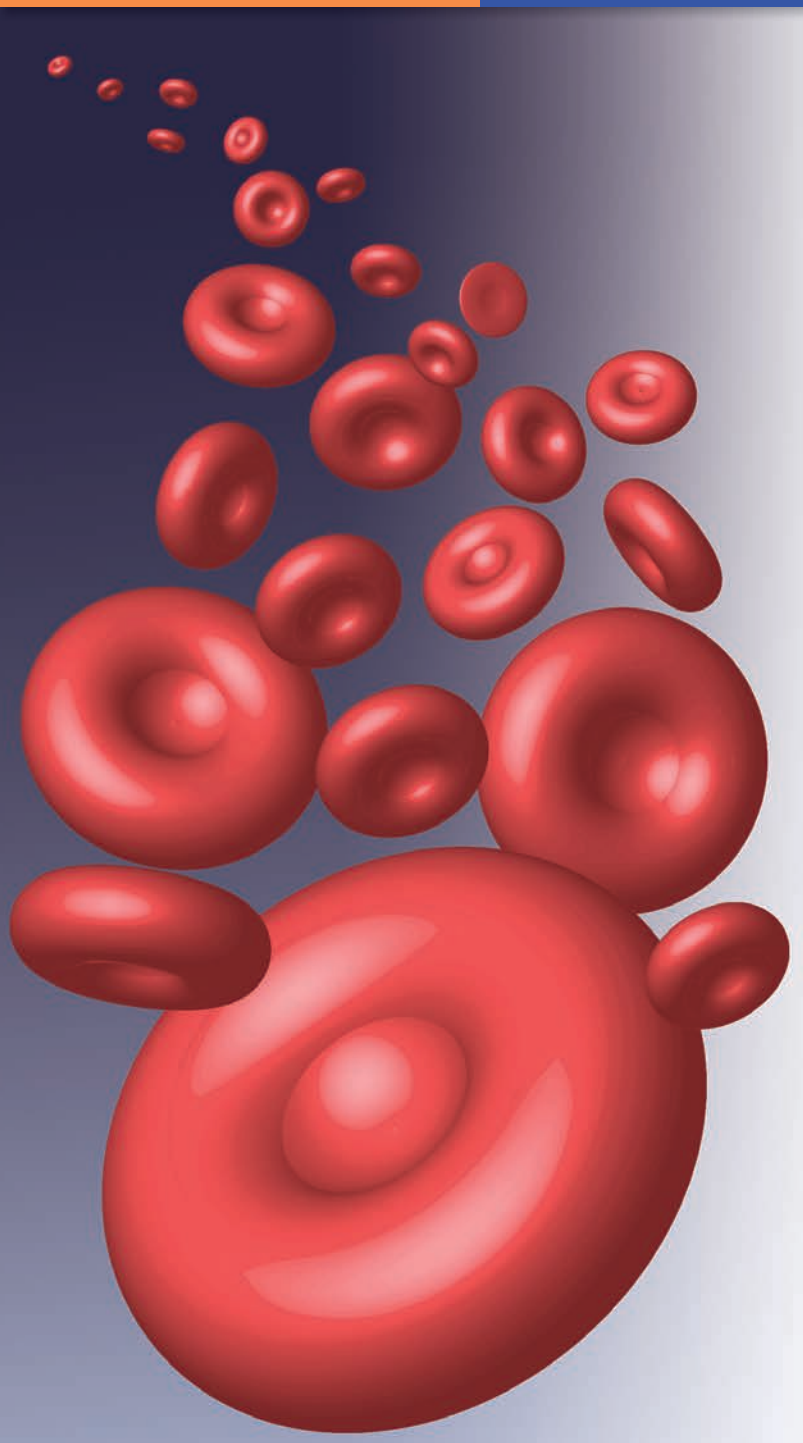

Pretest

Multiple Choice. **Select the best answer, and write the letter of your choice to the left of each number. To check your answers go to Appendix 11.**

_____ 1. Erythrocyte is the scientific name for a
a. white blood cell
b. lymphocyte
c. red blood cell
d. muscle cell

_____ 2. Platelets, or thrombocytes, are involved in
a. digestion
b. inflammation
c. immunity
d. blood clotting

_____ 3. The white blood cells active in immunity are the
a. chondrocytes
b. lymphocytes
c. adipose cells
d. hematids

_____ 4. Substances produced by immune cells that counteract microorganisms and other foreign materials are called
a. antigens
b. antibodies
c. anticoagulants
d. Rh factors

_____ 5. A deficiency of hemoglobin results in the disorder called
a. hypertension
b. chromatosis
c. anemia
d. hemophilia

_____ 6. A neoplastic overgrowth of white blood cells is called
a. leukemia
b. anemia
c. fibrosis
d. cystitis

extern.ir

Learning Objectives

After careful study of this chapter, you should be able to:

1. Describe the composition of the blood plasma. ***P358***
2. Describe and give the functions of the three types of blood cells. ***P358***
3. Differentiate the five different types of leukocytes. ***P360***
4. Explain the basis of blood types. ***P361***
5. Define immunity, and list the possible sources of immunity. ***P364***
6. Identify and use roots and suffixes pertaining to the blood and immunity. ***P367***
7. Identify and use roots pertaining to blood chemistry. ***P369***
8. List and describe three major disorders of the blood. ***P370***
9. Describe the major tests used to study blood. ***P370***
10. List and describe three major disorders of the immune system. ***P374***
11. Interpret abbreviations used in blood studies. ***P380***
12. Analyze medical terms in several case studies involving the blood. ***PP357, 388***

Case Study: Nurse Anesthetist Olivia With Latex Allergy

Chief Complaint

Olivia, a 36 y/o certified registered nurse anesthetist (CRNA), noticed that her hands had a red patchy rash when she removed her gloves following cases in the OR. They began to itch after a few minutes of donning the gloves, so she figured she might have developed an allergy to the latex they contained. When she began to have a runny nose and itchy swollen eyes, she was worried and sought medical advice from her primary care physician, who referred her to an allergist.

Examination

The allergist examined Olivia's hands and observed a localized red crusty rash that stopped at the wrists. There were a few blisters spread over the hand region. Along with the examination, a history indicated Olivia had noticed the contact dermatitis for a while when she wore powdered latex gloves in the OR, and she more recently had noted generalized allergic symptoms during surgical cases. During a recent case, she experienced some tachycardia, urticaria (hives), and rhinitis when she came in contact with latex gloves.

Clinical Course

Olivia was diagnosed with a type I hypersensitivity, IgE, T cell-mediated latex allergy, as shown by both immunologic and skin-prick tests. Although Olivia is a CRNA, she was educated on the course of latex allergies. She was reminded that there is no cure and that the only way to prevent an allergic reaction is to avoid coming into contact with latex.

This chapter describes the composition and characteristics of blood, the life-sustaining fluid that circulates throughout the body. A discussion of immunity is included because many components of the immune system are carried in the blood. Olivia's case of allergy is an example of immunologic hyperactivity. One of the symptoms, tachycardia, was discussed in Chapter 10 and rhinitis will be introduced in the next chapter on the respiratory system.

Case Study Revisited: Once you complete this chapter, please review the case follow-up on p. 381.

Ancillaries *At-A-Glance*

Visit the web resource to access the following resources.

extern.ir

Learning Resources

- eBook
- A&P Module with Heart & Lung Sounds
- Image Bank
- TestPrep
- Animations
- Audio Pronunciation Glossary

Introduction

Blood is the fluid that circulates through the vessels, bringing oxygen and nourishment to all cells and carrying away carbon dioxide and other waste products. The blood also distributes body heat and carries special substances, such as antibodies and hormones. Certain blood cells are a major component of the immune system, which protects against disease. This chapter thus includes a discussion of the immune system.

Blood

The total adult blood volume is about 5 L (5.2 qt). Whole blood can be divided into two main components: the liquid portion, or **plasma** (55%), and **formed elements**, more commonly known as blood cells (45%) (FIG. 11-1).

BLOOD PLASMA

Plasma is about 90% water. The remaining 10% contains nutrients, **electrolytes** (dissolved salts), gases, **albumin** (a protein), clotting factors, antibodies, wastes, enzymes, and hormones. Laboratories test for a multitude of these substances in blood chemistry tests. The pH (relative acidity) of the plasma remains steady at about 7.4.

BLOOD CELLS

The blood cells (FIG. 11-2) include **erythrocytes**, or red blood cells (RBCs); **leukocytes**, or white blood cells (WBCs); and **platelets**, also called **thrombocytes.** All blood cells are produced in red bone marrow. Some WBCs multiply in lymphoid tissue as well. For Your Reference BOX 11-1 summarizes the different types of blood cells; BOX 11-2 discusses time-saving acronyms, such as RBC and WBC.

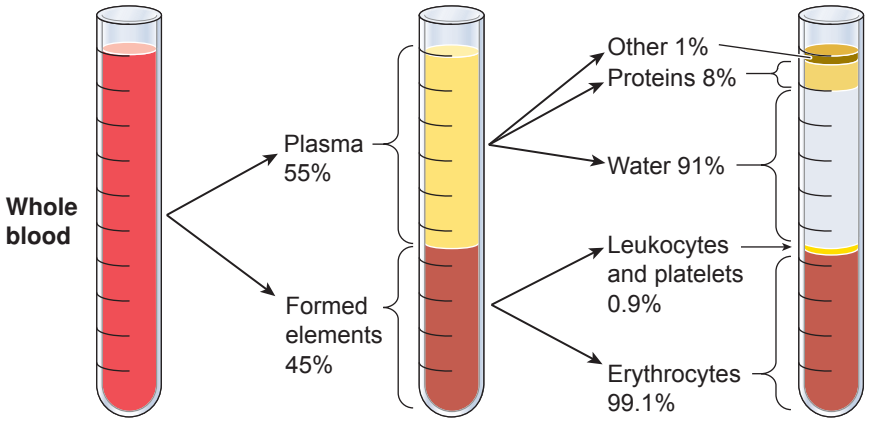

FIGURE 11-1 Composition of whole blood. Percentages show the relative proportions of the different components of plasma and formed elements.

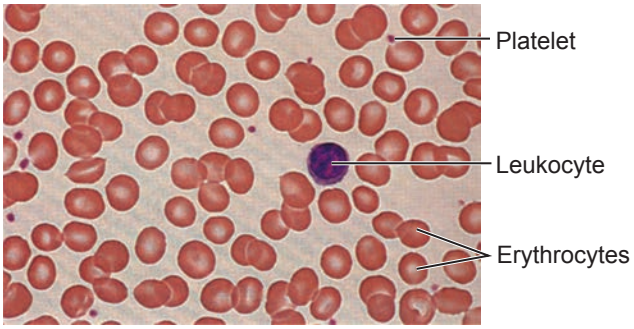

FIGURE 11-2 Blood cells. When viewed under a microscope, all three types of formed elements are visible.

extern.ir

FOR YOUR REFERENCE
Blood Cells

BOX 11-1

Cell Type	Number Per Microliter of Blood	Description	Function
Erythrocyte (red blood cell)	5 million	Tiny (7 mcm diameter), biconcave disk without nucleus (anuclear)	Carries oxygen bound to hemoglobin; also carries some carbon dioxide and buffers blood
Leukocyte (white blood cell)	5,000 to 10,000	Larger than red cell with prominent nucleus that may be segmented (granulocyte) or unsegmented (agranulocyte); types vary in staining properties	Immunity; protects against pathogens and destroys foreign matter and debris; located in blood, tissues, and lymphatic system
Platelet (thrombocyte)	150,000 to 450,000	Fragment of large cell (megakaryocyte)	Hemostasis; forms a platelet plug and starts blood clotting (coagulation)

FOCUS ON WORDS
Acronyms

BOX 11-2

Acronyms are abbreviations that use the first letters of the words in a name or phrase. They have become very popular because they save time and space in writing as the number and complexity of technical terms increases. Some examples that apply to studies of the blood are CBC (complete blood count) and RBC and WBC for red and white blood cells. Some other common acronyms are CNS (central nervous system or clinical nurse specialist), ECG (electrocardiogram), NIH (National Institutes of Health), and STI (sexually transmitted infection).

If the acronym has vowels and lends itself to pronunciation, it may be used as a word in itself, such as AIDS (acquired immunodeficiency syndrome); ELISA (enzyme-linked immunosorbent assay); *JAMA* (*Journal of the American Medical Association*); NSAID (nonsteroidal antiinflammatory drug), pronounced "en-sayd"; and CABG (coronary artery bypass graft), which inevitably becomes "cabbage." Few people even know that LASER is an acronym that means "light amplification by stimulated emission of radiation."

An acronym is usually introduced the first time a phrase appears in an article and is then used without explanation. If you have spent time searching back through an article in frustration for the meaning of an acronym, you probably wish, as do other readers, that all the acronyms used and their meanings would be listed at the beginning of each article.

Erythrocytes

The major function of erythrocytes is to carry oxygen to cells. This oxygen is bound to an iron-containing pigment in the cells called **hemoglobin.** Erythrocytes are small, disk-shaped cells with no nuclei **(FIG. 11-3)**. Their concentration of about 5 million per microliter (µL or mcL) of blood makes them by far the most numerous of the blood cells. The hemoglobin that they carry averages 15 g/dL (100 mL) of blood. An RBC gradually wears out and dies in about 120 days, so these cells must be constantly replaced. Production of red cells in the bone marrow is regulated by the hormone **erythropoietin** (EPO), which is made in the kidneys.

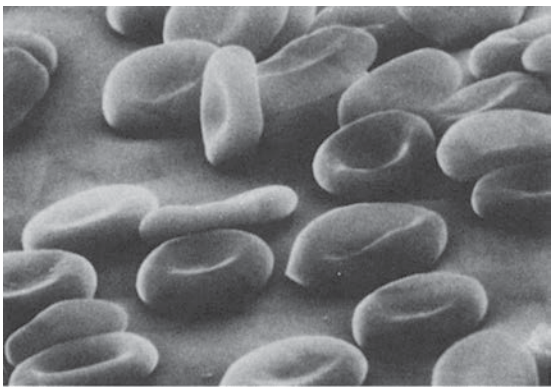

FIGURE 11-3 Erythrocytes (red blood cells). The cells are seen under a scanning electron microscope, which gives a three-dimensional view.

Leukocytes

All WBCs show prominent nuclei when stained. They total about 5,000 to 10,000/µL, but their number may increase

extern.ir

during infection. There are five types of leukocytes that vary in their relative percentages and their functions. The different types are identified by the size and appearance of the nucleus, by their staining properties, and by whether or not they show visible granules in the cytoplasm when stained. The five types are illustrated and compared in **BOX 11-3**. Classified as granulocytes or agranulocytes, they are as follows:

- **Granulocytes**, or granular leukocytes, have visible granules in the cytoplasm when stained. A granulocyte has a segmented nucleus. There are three types of granulocytes, named for the kind of stain (dye) the granules take up:
  - **Neutrophils** stain weakly with both acidic and basic dyes.
  - **Eosinophils** stain strongly with acidic dyes.
  - **Basophils** stain strongly with basic dyes.

FOR YOUR REFERENCE

BOX 11-3

Leukocytes (White Blood Cells)

Cell Type		Relative Percentage (Adult)	Function
GRANULOCYTE			
Neutrophil *NU-tro-fil*	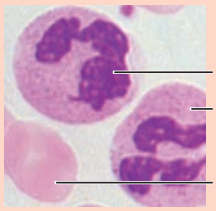	54 to 62 percent	phagocytosis
Eosinophil *e-o-SIN-o-fil*	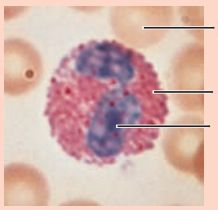	1 to 3 percent	allergic reactions; defense against parasites
Basophil *BA-so-fil*	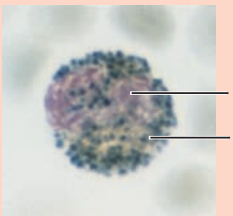	less than 1 percent	allergic reactions
AGRANULOCYTE			
Lymphocyte *LIM-fo-site*	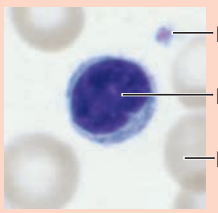	25 to 38 percent	immunity (T cells and B cells)
Monocyte *MON-o-site*	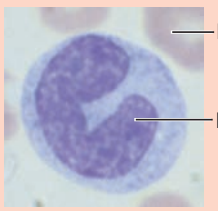	3 to 7 percent	phagocytosis

extern.ir

- **Agranulocytes** do not show visible granules when stained. An agranulocyte's nucleus is large and either round or curved. There are two types of agranulocytes:
  - **Lymphocytes** are the smaller agranulocytes.
  - **Monocytes** are the largest of all the WBCs.

WBCs protect against foreign substances. Some engulf foreign material by the process of **phagocytosis** (see Fig. 3-3); others have different functions in the immune system. In diagnosis, it is important to know not only the total number of leukocytes but also the relative number of each type, because these numbers can change in different disease conditions. Laboratories report these numbers as a differential count (Diff), which is part of a complete blood count (CBC).

The most numerous WBCs, neutrophils, are called *polymorphs* because of the various shapes of their nuclei. They are also referred to as *segs*, *polys*, or *PMNs* (*p*oly*m*orpho*n*uclear leukocytes). A **band cell**, also called a *stab cell*, is an immature neutrophil with a solid curved nucleus (FIG. 11-4). Large numbers of band cells in the blood indicate an active infection.

Platelets

The blood platelets (thrombocytes) are not complete cells, but fragments of large cells named **megakaryocytes**, which form in bone marrow (FIG. 11-5). They number from 200,000 to 400,000/μL of blood. Platelets are important in **hemostasis**, the prevention of blood loss, which includes the process of blood clotting, or **coagulation.**

When a vessel is injured, platelets stick together to form a plug at the site. Substances released from the platelets and from damaged tissue then interact with clotting factors in the plasma to produce a wound-sealing clot. Clotting factors are inactive in the blood until an injury occurs. To protect against unwanted clot formation, 12 factors must interact before blood coagulates. The final reaction is the conversion of **fibrinogen** to threads of **fibrin** that trap blood cells and plasma to produce the clot (FIG. 11-6). The plasma that remains after blood coagulates is **serum.**

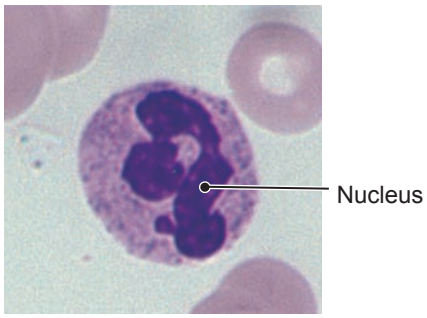

A Mature neutrophil

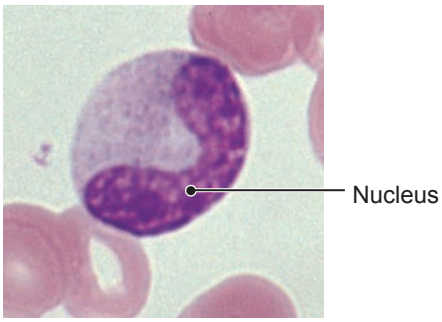

B Band cell (immature neutrophil)

FIGURE 11-4 Band cell. A. A mature neutrophil. **B.** A band cell, or stab cell, is an immature neutrophil with a thick curved nucleus.

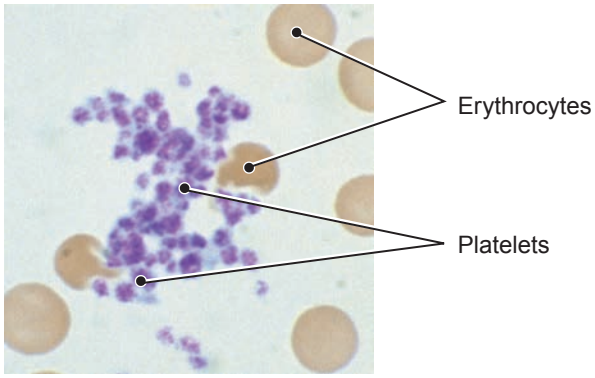

A Platelets

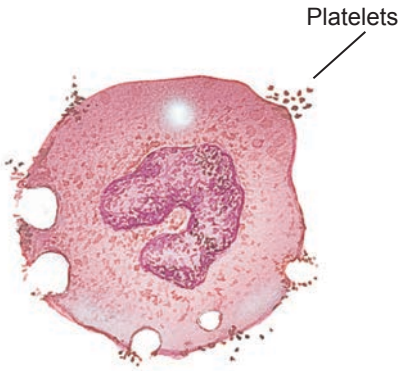

B Megakaryocyte

FIGURE 11-5 Platelets (thrombocytes). A. Platelets seen in a blood smear under the microscope. **B.** A megakaryocyte releases platelets.

extern.ir

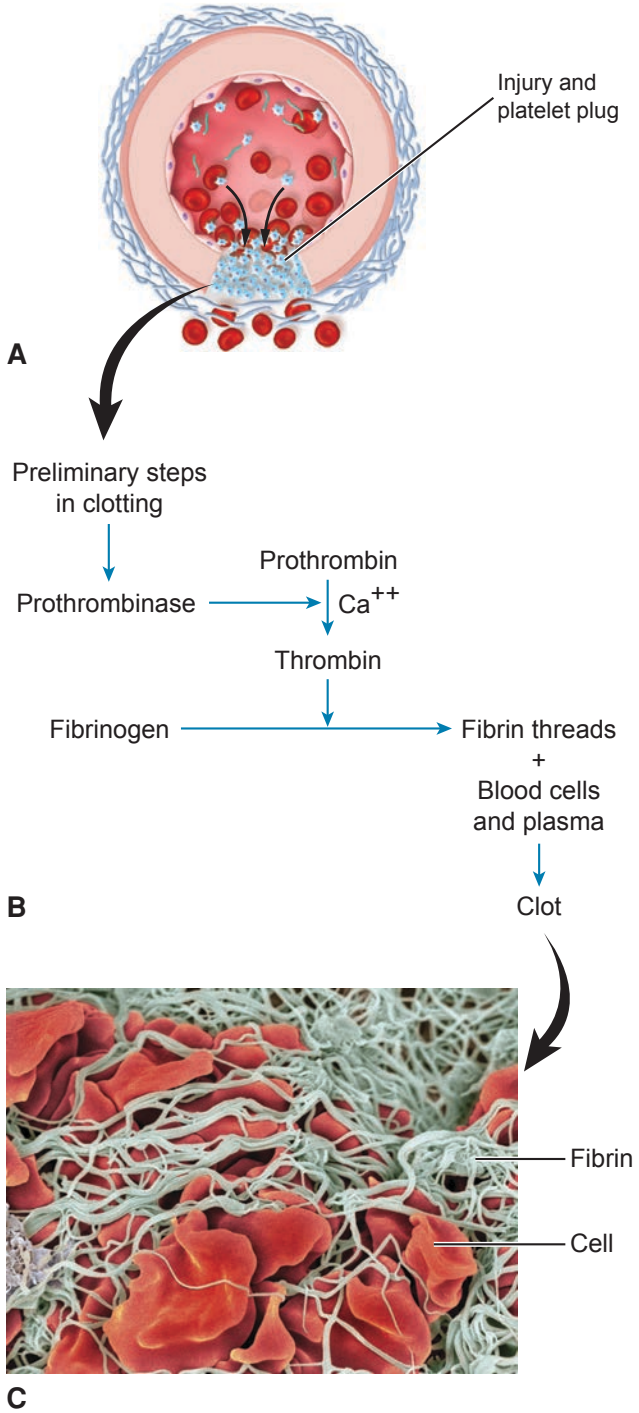

FIGURE 11-6 Blood clotting (coagulation). Blood coagulation involves a complex series of reactions that leads to formation of fibrin threads. The fibrin traps blood cells to form a clot. **A.** Substances released from damaged tissue start the clotting process. **B.** The final steps in formation of fibrin. One of these steps requires calcium (Ca^{2+}). **C.** Microscopic view of blood cells trapped in fibrin.

BLOOD TYPES

Genetically inherited proteins on the surface of RBCs determine blood type. More than 20 groups of these proteins have now been identified, but the most familiar are the ABO and Rh blood groups. The ABO system includes types A, B, AB, and O. The Rh types are Rh positive (Rh^+) and Rh negative (Rh^-). Blood is typed by mixing samples separately with different prepared antisera. Red cells in the sample will agglutinate (clump) with the antiserum that corresponds to the blood type, as shown in **FIGURE 11-7** for the ABO system.

In giving blood transfusions, it is important to use blood that is the same type as the recipient's blood or a

extern.ir

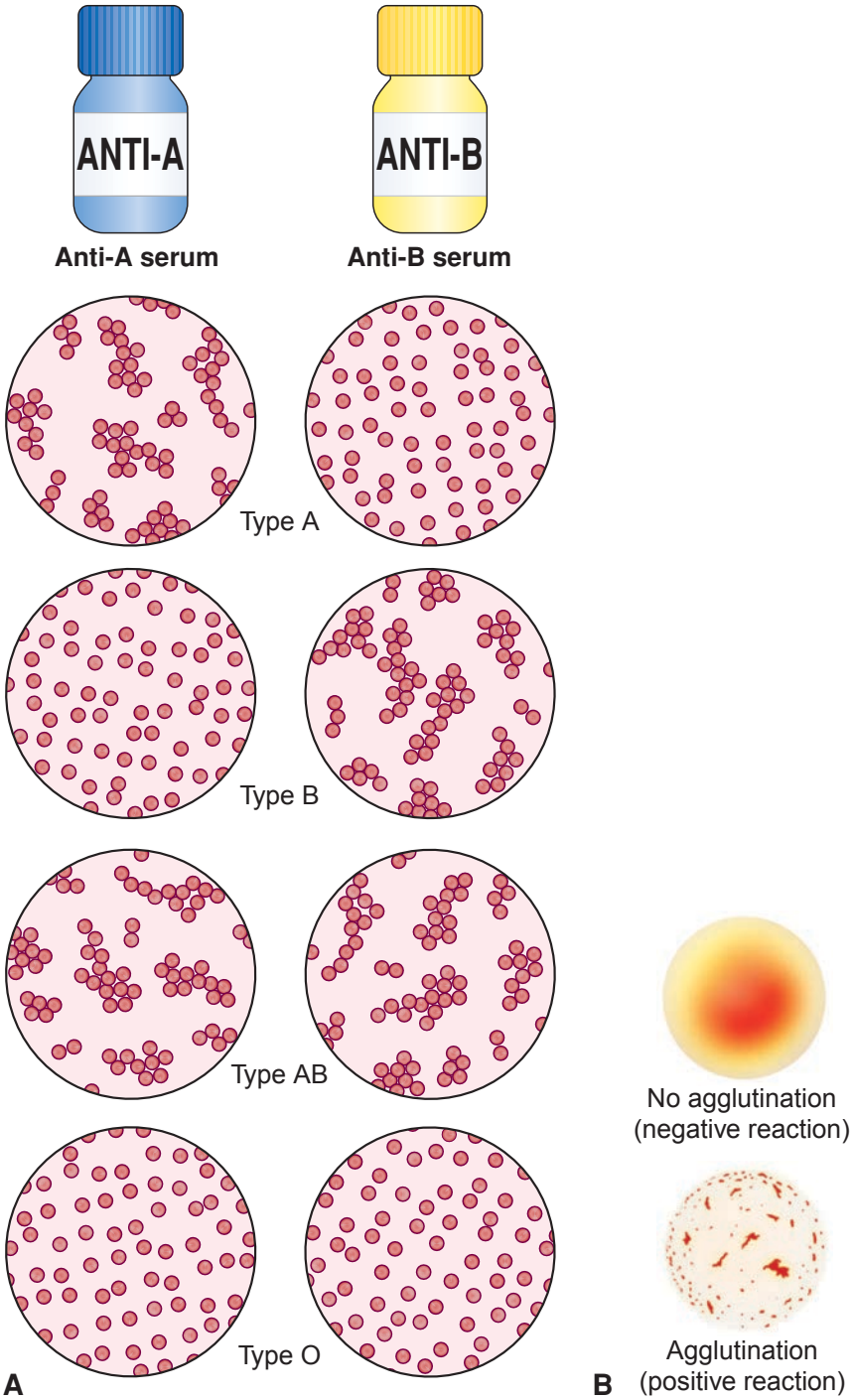

FIGURE 11-7 Blood typing. Blood type is determined by mixing samples separately with antisera prepared against the different red cell antigens. Clumping (agglutination) with an antiserum indicates the presence of the corresponding antigen. **A.** Labels at the top of each column denote the kind of antiserum added to the blood samples. Anti-A serum agglutinates red cells in type A blood, but anti-B serum does not. Anti-B serum agglutinates red cells in type B blood, but anti-A serum does not. Both sera agglutinate type AB blood cells, and neither serum agglutinates type O blood. **B.** Photographs of blood typing reactions.

type to which the recipient will not have an immune reaction. In an emergency, type O, Rh-negative blood can be used because these red cells will not induce an immune response. When there is time, laboratories perform more complete tests for compatibility that take additional blood proteins into account. In this process of **cross-matching**, donor red cells are mixed with recipient serum to test for a reaction.

Whole blood may be used to replace a large volume of blood lost, but in most cases requiring blood transfusion, a blood fraction, such as packed red cells, platelets, plasma, or specific clotting factors, is administered.

extern.ir

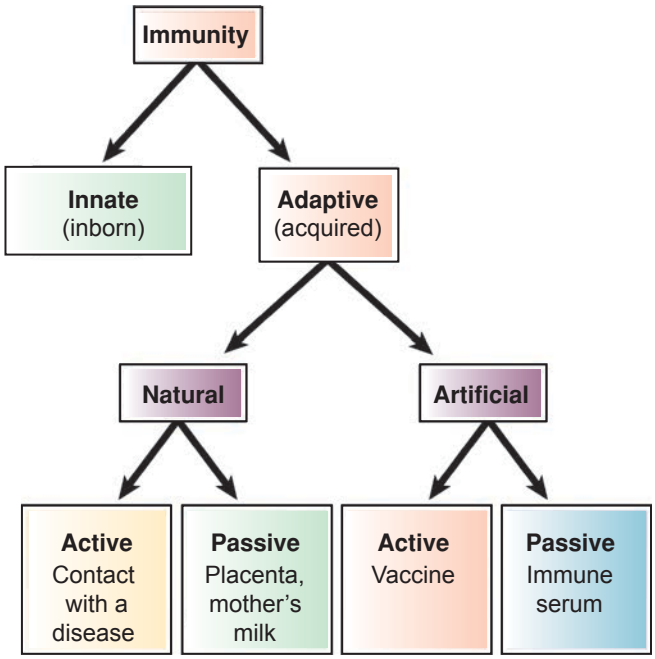

FIGURE 11-8 Types of immunity.

Immunity

Immunity is protection against disease. It includes defenses against harmful microorganisms, their products, or any other foreign substance. These defenses may be inborn or acquired during life (FIG. 11-8).

INNATE IMMUNITY

Innate defense mechanisms protect against any invading organism or harmful foreign substance, not any particular one. Thus, they are described as *nonspecific*. These defenses are inborn and are based on an individual's inherited genetic makeup. Most of these protections are physical barriers or chemical defenses and include the following:

- Unbroken skin, which acts as a barrier
- Cilia, tiny cell projections that sweep impurities out of the body, as in the respiratory tract
- Mucus that traps foreign material
- Bactericidal body secretions, as found in tears, skin, digestive tract, and reproductive tract
- Reflexes, such as coughing and sneezing, which expel impurities
- Lymphoid tissue, which filters impurities from blood and lymph, as described in Chapter 10
- Phagocytes, cells that attack, ingest, and destroy foreign organisms

ADAPTIVE IMMUNITY

Adaptive immunity is acquired during life and is *specific*, that is, directed toward a particular disease organism or other foreign substance. Protection against measles, for example, will not protect against chickenpox or any other disease.

The adaptive immune response involves complex interactions between components of the lymphatic system and the blood. Any foreign particle, but mainly proteins, may act as an **antigen**, a substance that provokes an immune response. This response comes from two types of lymphocytes that circulate in the blood and lymphatic system:

- **T cells** (T lymphocytes) mature in the thymus. They are capable of attacking a foreign cell directly, producing *cell-mediated immunity*. Immune cells known as **antigen-presenting cells (APCs)**, which take in and process foreign antigens, are important to T cell function. A T cell is activated when it contacts an antigen on an APC's surface in combination with some of the body's own proteins. Examples of APCs are dendritic cells and macrophages, which are descendants of monocytes.
- **B cells** (B lymphocytes) mature in bone marrow. When they meet a foreign antigen, they multiply rapidly and mature into **plasma cells.** These cells produce **antibodies,** also called **immunoglobulins (Ig)**, that inactivate antigens (FIG. 11-9). Antibodies remain in the blood, often providing long-term immunity to the specific organism against

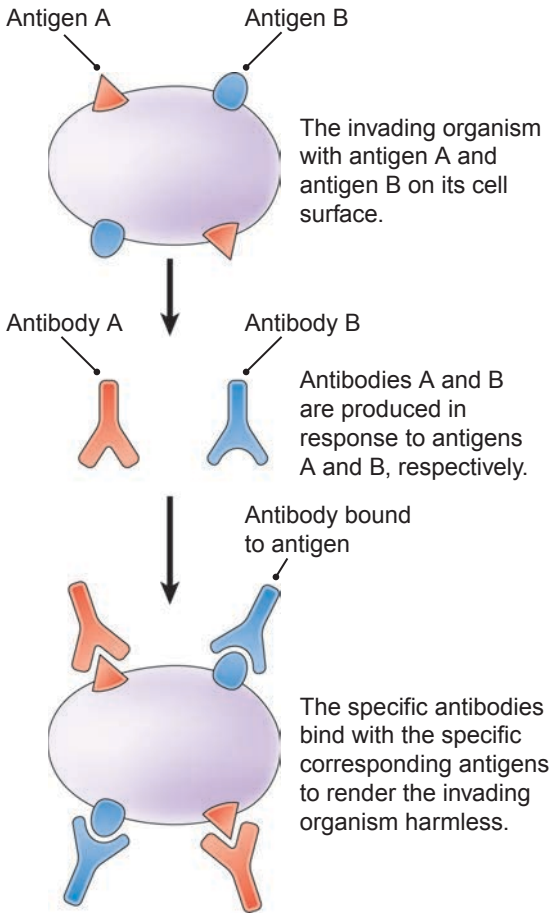

FIGURE 11-9 The antigen–antibody reaction. Antibodies produced by immune cells bind with specific antigens to aid in their inactivation and elimination.

extern.ir

which they were formed. Antibody-based immunity is referred to as *humoral immunity.*

TYPES OF ADAPTIVE IMMUNITY

Adaptive immunity may be acquired either naturally or artificially (see **FIG. 11-8**). In addition, each avenue for acquiring such immunity may be either active or passive. In active immunity, a person makes his or her own antibodies in response to contact with an antigen. In passive immunity, an antibody, known as an immune serum, is transferred from an outside source. Immune sera may come from other people or from immunized animals. The portion of the blood plasma that contains antibodies is the **gamma globulin** fraction. The types of adaptive immunity are:

- Natural adaptive immunity
  - Active—from contact with a disease organism or other foreign antigen
  - Passive—by transfer of antibodies from a mother to her fetus through the placenta or through the mother's milk
- Artificial adaptive immunity
  - Active—by administration of a vaccine, which may be a killed or weakened organism, part of an organism, or an altered toxin (toxoid)
  - Passive—by administration of an immune serum obtained from other people or animals

Immunology has long been a very active area of research. The above description is only the barest outline of the events that are known to occur in the immune response, and there is still much to be discovered. Some of the areas of research include autoimmune diseases, in which an individual produces antibodies to his or her own body tissues; hereditary and acquired immunodeficiency diseases; the relationship between cancer and immunity; and the development of techniques for avoiding rejection of transplanted tissue.

Terminology *Key Terms*

The terms listed below are emphasized in this chapter. Knowing them will help you organize and prioritize your learning. These boldface terms are also found, collectively, with all chapter key terms in the Glossary.

Normal Structure and Function

agranulocyte *A-gran-u-lo-site*	A white blood cell that does not have visible granules in its cytoplasm; agranulocytes include lymphocytes and monocytes (see **BOX 11-3**)
albumin *al-BU-min*	A simple protein found in blood plasma
antibody *AN-tih-bod-e*	A protein produced in response to and interacting specifically with an antigen
antigen *AN-tih-jen*	A substance that induces the formation of an antibody
antigen-presenting cell (APC)	Immune cell that takes in a foreign antigen, processes it, and presents it on the cell surface in combination with the body's own proteins, thus activating a T cell; examples are dendritic cells and macrophages, which are descendants of monocytes
B cell	A lymphocyte that matures in bone marrow and is active in producing antibodies; B lymphocyte (*LIM-fo-site*)
band cell	An immature neutrophil with a nucleus in the shape of a band; also called a stab cell; band cell counts are used to trace infections and other diseases (see **FIG. 11-4**)
basophil *BA-so-fil*	A granular leukocyte that stains strongly with basic dyes; active in allergic reactions
blood *blud*	The fluid that circulates in the cardiovascular system (roots: hem/o, hemat/o)
coagulation *ko-ag-u-LA-shun*	Blood clotting
cross-matching	Testing the compatibility of donor and recipient blood in preparation for a transfusion; donor red cells are mixed with recipient serum to look for an immunologic reaction; similar tests are done on tissues before transplantation

(continued)

extern.ir

Terminology Key Terms (Continued)

electrolyte *e-LEK-tro-lite*	A substance that separates into charged particles (ions) in solution; a salt; term also applied to ions in body fluids
eosinophil *e-o-SIN-o-fil*	A granular leukocyte that stains strongly with acidic dyes; active in allergic reactions and defense against parasites
erythrocyte *eh-RITH-ro-site*	A red blood cell (roots: erythr/o, erythrocyt/o) (see **FIGS. 11-2** and **11-3**)
erythropoietin (EPO) *eh-rith-ro-POY-eh-tin*	A hormone produced in the kidneys that stimulates red blood cell production in the bone marrow; this hormone is now made by genetic engineering for clinical use
fibrin *FI-brin*	The protein that forms a clot in the blood coagulation process
fibrinogen *fi-BRIN-o-jen*	The inactive precursor of fibrin
formed elements	The cellular components of blood
gamma globulin *GLOB-u-lin*	The fraction of the blood plasma that contains antibodies; given for passive transfer of immunity
granulocyte *GRAN-u-lo-site*	A white blood cell that has visible granules in its cytoplasm; granulocytes include neutrophils, basophils, and eosinophils (see **BOX 11-3**)
hemoglobin (Hb, Hgb) *HE-mo-glo-bin*	The iron-containing pigment in red blood cells that transports oxygen
hemostasis *he-mo-STA-sis*	The stoppage of bleeding
immunity *ih-MU-nih-te*	The state of being protected against a disease (root: immun/o)
immunoglobulin (Ig) *im-u-no-GLOB-u-lin*	An antibody; immunoglobulins fall into five classes, each abbreviated with a capital letter: IgG, IgM, IgA, IgD, IgE
leukocyte *LU-ko-site*	A white blood cell (roots: leuk/o, leukocyt/o)
lymphocyte *LIM-fo-site*	An agranular leukocyte active in immunity (T and B cells); found in both the blood and in lymphoid tissue (roots: lymph/o, lymphocyt/o)
megakaryocyte *meg-ah-KAR-e-o-site*	A large bone marrow cell that fragments to release platelets
monocyte *MON-o-site*	An agranular phagocytic leukocyte
neutrophil *NU-tro-fil*	A granular leukocyte that stains weakly with both acidic and basic dyes; the most numerous of the white blood cells; a type of phagocyte
phagocytosis *fag-o-si-TO-sis*	The engulfing of foreign material by white blood cells
plasma *PLAZ-mah*	The liquid portion of the blood
plasma cell	A mature form of a B cell that produces antibodies
platelet *PLATE-let*	A formed element of the blood that is active in hemostasis; a thrombocyte (root: thrombocyt/o)

extern.ir

Terminology *Key Terms (Continued)*

serum *SERE-um*	The fraction of the plasma that remains after blood coagulation; it is the equivalent of plasma without its clotting factors (plural: sera, serums)
T cell	A lymphocyte that matures in the thymus and attacks foreign cells directly; T lymphocyte
thrombocyte *THROM-bo-site*	A blood platelet (root: thrombocyt/o)

Word Parts Pertaining to Blood and Immunity

See **TABLES 11-1** to **11-3**.

Table 11-1 Suffixes for Blood

Suffix	Meaning	Example	Definition of Example
-emia,[a] -hemia	condition of blood	polycythemia *pol-e-si-THE-me-ah*	increase of cells (cyt) in the blood
-penia	decrease in, deficiency of	cytopenia *si-to-PE-ne-ah*	deficiency of cells
-poiesis	formation, production	hemopoiesis *he-mo-poy-E-sis*	production of blood cells

[a]A shortened form of the root hem plus the suffix *-ia*.

Exercise 11-1

Complete the exercise. To check your answers go to Appendix 11.

Define the following terms.

1. thrombocytopenia (*throm-bo-si-to-PE-ne-ah*) _____
2. bacteremia (*bak-ter-E-me-ah*) _____
3. leukocytopenia (*lu-ko-si-to-PE-ne-ah*) _____
4. erythropoiesis (*eh-rith-ro-poy-E-sis*) _____
5. toxemia (*tok-SE-me-ah*) _____
6. hypoproteinemia (*hi-po-pro-tene-E-me-ah*) _____
7. hyperalbuminemia (*hi-per-al-bu-mih-NE-me-ah*) _____

Use the suffix *-emia* to write words for the following definitions.

8. Presence of viruses in the blood _____
9. Presence of excess white cells (leuk/o) in the blood _____
10. Presence of pus in the blood _____

extern.ir

Many of the words relating to blood cells can be formed either with or without including the root *cyt/o*, as in erythropenia or erythrocytopenia, leukopoiesis or leukocytopoiesis. The remaining types of blood cells are designated by easily recognized roots such as *agranulocyt/o*, *monocyt/o*, *granul/o*, and so on **(TABLE 11-2)**.

Table 11-2 Roots for Blood and Immunity

Root	Meaning	Example	Definition of Example
myel/o	bone marrow	myelogenous *mi-eh-LOJ-eh-nus*	originating in bone marrow
hem/o, hemat/o	blood	hemopathy *he-MOP-ah-the*	any disorder of blood
erythr/o, erythrocyt/o	red blood cell	erythroblast *eh-RITH-ro-blast*	immature red blood cell
leuk/o, leukocyt/o	white blood cell	leukocytosis *lu-ko-si-TO-sis*	increase in the number of leukocytes in the blood
lymph/o, lymphocyt/o	lymphocyte	lymphocytic *lim-fo-SIT-ik*	pertaining to lymphocytes
thromb/o	blood clot	thrombolytic *throm-bo-LIT-ik*	dissolving a blood clot
thrombocyt/o	platelet, thrombocyte	thrombopoiesis *throm-bo-poy-E-sis*	formation of platelets
immun/o	immunity, immune system	immunization *im-u-nih-ZA-shun*	production of immunity

Exercise 11-2

Complete the exercise. To check your answers go to Appendix 11.

Identify and define the root in the following words.

1. leukocytosis (*lu-ko-si-TO-sis*) _____
2. ischemia (*is-KE-me-ah*) _____
3. preimmunization (*pre-im-u-nih-ZA-shun*) _____
4. hematology (*he-mah-TOL-o-je*) _____
5. prothrombin (*pro-THROM-bin*) _____
6. panmyeloid (*pan-MI-eh-loyd*) _____

Fill in the blanks.

7. Lymphokines (*LIM-fo-kines*) are chemicals active in immunity that are produced by _____ .
8. A hematoma (*he-mah-TO-mah*) is a swelling caused by collection of _____ .
9. Hemorrhage (*HEM-or-ij*) is a profuse flow (-rhage) of _____ .
10. Myelofibrosis (*mi-eh-lo-fi-BRO-sis*) is formation of fibrous tissue in _____ .
11. Erythroclasis (*er-ih-THROK-lah-sis*) is the breaking (-clasis) of _____ .
12. An immunocyte (*im-u-no-SITE*) is a cell active in _____ .
13. The term thrombocythemia (*throm-bo-si-THE-me-ah*) refers to a blood increase in the number of _____ .
14. Leukopoiesis (*lu-ko-poy-E-sis*) refers to the production of _____ .

extern.ir

Exercise 11-2 *(Continued)*

Write words for the following definitions.

15. Decrease in white blood cells _____
16. Tumor of bone marrow _____
17. Immature lymphocyte _____
18. Dissolving (-lysis) of a blood clot _____
19. Formation (-poiesis) of bone marrow _____

The suffix *-osis* added to a root for a type of cell means an increase in that type of cell in the blood. Use this suffix to write a word that means each of the following.

20. Increase in granulocytes in the blood _____
21. Increase in lymphocytes in the blood _____
22. Increase in red blood cells _____
23. Increase in monocytes in the blood _____
24. Increase in platelets in the blood _____

Table 11-3 Roots for Blood Chemistry

Root	Meaning	Example	Definition of Example
azot/o	nitrogenous compounds	azoturia *aze-o-TU-re-ah*	increased nitrogenous compounds in the urine (-uria)
calc/i	calcium (symbol Ca)	calcification *kal-sih-fih-KA-shun*	deposition of calcium salts
ferr/o, ferr/i	iron (symbol Fe)	ferrous *FER-ous*	pertaining to or containing iron
sider/o	iron	sideroderma *sid-er-o-DER-mah*	deposition of iron into the skin
kali	potassium (symbol K)	hyperkalemia[a] *hi-per-kah-LE-me-ah*	excess of potassium in the blood
natri	sodium (symbol Na)	natriuresis *na-tre-u-RE-sis*	excretion of sodium in the urine (ur/o)
ox/y	oxygen (symbol O)	hypoxia *hi-POK-se-ah*	deficiency of oxygen in the tissues

[a]The *i* in the root is dropped.

extern.ir

Exercise 11-3

Complete the exercise. To check your answers go to Appendix 11.

Fill in the blanks.

1. A sideroblast (*SID-er-o-blast*) is an immature cell containing _____ .
2. The term hypokalemia (*hi-po-kah-LE-me-ah*) refers to a blood deficiency of _____ .
3. The bacterial species *Azotobacter* is named for its ability to metabolize _____ .
4. Hypoxemia (*hi-pok-SE-me-ah*) is a blood deficiency of _____ .
5. Ferritin (*FER-ih-tin*) is a compound that contains _____ .
6. A calcareous (*kal-KAR-e-us*) substance contains _____ .

Use the suffix *-emia* to form words with the following meanings.

7. Presence of sodium in the blood _____
8. Presence of nitrogenous compounds in the blood _____
9. Presence of potassium in the blood _____
10. Presence of calcium in the blood _____

Clinical Aspects of Blood

ANEMIA

Anemia is defined as an abnormally low amount of hemoglobin in the blood. Anemia may result from too few RBCs or from cells that are too small (microcytic) or have too little hemoglobin (hypochromic). Key tests in diagnosing anemia are blood counts, mean corpuscular volume (MCV), and mean corpuscular hemoglobin concentration (MCHC). **BOX 11-4** describes these and other blood tests. **BOX 11-5** has information on careers in hematology.

FOR YOUR REFERENCE — BOX 11-4
Common Blood Tests

Test	Abbreviation	Description
red blood cell count	RBC	number of red blood cells per microliter of blood
white blood cell count	WBC	number of white blood cells per microliter of blood
differential count	Diff	relative percentage of the different types of leukocytes
hematocrit (FIG. 11-10)	Ht, Hct, crit	relative percentage of packed red cells in a given volume of blood
packed cell volume	PCV	hematocrit
hemoglobin	Hb, Hgb	amount of hemoglobin in g/dL (100 mL) of blood
mean corpuscular volume	MCV	volume of an average red cell
mean corpuscular hemoglobin	MCH	average weight of hemoglobin in red cells
mean corpuscular hemoglobin concentration	MCHC	average concentration of hemoglobin in red blood cells
erythrocyte sedimentation rate	ESR	rate of erythrocyte settling per unit of time; used to detect infection or inflammation
complete blood count	CBC	series of tests including cell counts, hematocrit, hemoglobin, and cell volume measurements

extern.ir

HEALTH PROFESSIONS
Careers in Hematology

BOX 11-5

Hematologists are physicians and other scientists who specialize in the study of blood and blood diseases. In medical practice, hematology is often combined with the study and treatment of blood cancers as the specialty of hematology–oncology.

Other healthcare professionals who work in hematology perform different roles depending upon their academic preparation. These careers include medical technologists, medical technicians, and phlebotomists, who are employed in hospitals, clinics, outpatient laboratories, and private offices.

Medical technologists and technicians may specialize in various clinical settings, such as blood banks and microbiology and chemistry laboratories. Each of these positions requires an advanced skill set and working knowledge of electronic equipment, instrumentation, and computers. Those working in hematology test blood for abnormalities or infections and may do cross-matching for transfusions. They examine blood cells for signs of cancer and other diseases. They must be familiar with laboratory safety policies and procedures and must exercise appropriate precautions when working with body fluids and tissues. For information on careers in medical laboratory technology, contact the American Society for Clinical Laboratory Science at ascls.org.

A phlebotomist is a healthcare professional who draws blood for testing, transfusions, or research. Phlebotomists work in hospitals, laboratories, private physicians' offices, clinics, and blood banks. They often draw blood from a vein (venipuncture), but may also draw it from an artery or by skin puncture, such as a finger or heel stick. Phlebotomists must be trained in sterile techniques and safety precautions to prevent the spread of infectious diseases. They must take specimens without harming the patient or interfering with medical care and must accurately label and transport specimens to the proper laboratory. Educational requirements vary among states. Often, in-house training with certification by the National Phlebotomy Association is acceptable (nationalphlebotomy.org).

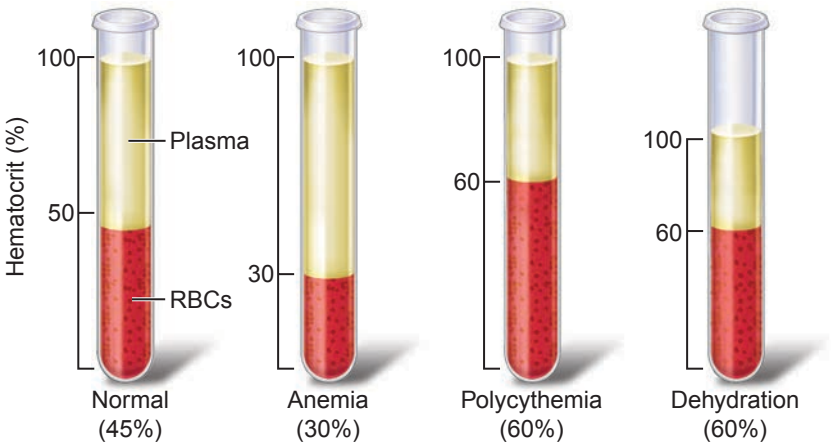

FIGURE 11-10 Hematocrit. The hematocrit tests the volume percentage of red cells in whole blood. The tube on the far left shows a normal hematocrit. The two middle tubes illustrate abnormal hematocrits. One shows a low percentage of red blood cells, indicating anemia, and the other shows an excessively high percentage of red blood cells, as seen in polycythemia. The tube on the far right shows a relatively high percentage of red cells due to dehydration.

The general symptoms of anemia include fatigue, shortness of breath, heart palpitations, pallor, and irritability. There are many different types of anemia, some of which are caused by faulty production of red cells and others by loss or destruction of red cells.

Anemia due to Impaired Production of Red Cells

- **Aplastic anemia** results from bone marrow destruction and affects all blood cells (pancytopenia). It may be caused by drugs, toxins, viruses, radiation, or bone marrow cancer. Aplastic anemia has a high mortality rate but has been treated successfully with bone marrow transplantation.
- **Nutritional anemia** may result from a deficiency of vitamin B_{12} or folate, B vitamins needed for RBC development. Most commonly, it is caused by a deficiency of iron, needed to make hemoglobin (FIG. 11-11). Folate

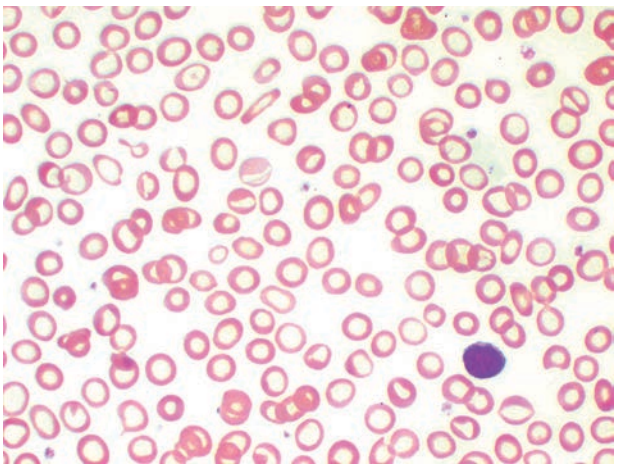

FIGURE 11-11 Iron deficiency anemia. Red cells are small (microcytic) and are lacking in hemoglobin (hypochromic).

extern.ir

deficiency commonly appears in those with poor diet, in pregnant and lactating women, and in those who abuse alcohol. Iron deficiency anemia results from poor diet, poor iron absorption, or blood loss. Both folate deficiency and iron deficiency respond to dietary supplementation.

- **Pernicious anemia** is a specific form of B_{12} deficiency. It results from the lack of **intrinsic factor** (IF), a substance produced in the stomach that aids in the intestinal absorption of B_{12}. Pernicious anemia must be treated with regular B_{12} injections.
- In **sideroblastic anemia**, adequate iron is available, but the iron is not used properly to manufacture hemoglobin. This disorder may be hereditary or acquired, as by exposure to toxins or drugs. It may also be secondary to another disease. The excess iron precipitates out in immature red cells (normoblasts).

Anemia due to Loss or Destruction of Red Cells

- **Hemorrhagic anemia** results from blood loss. This may be a sudden loss, as from injury, or loss from chronic internal bleeding, as from the digestive tract in cases of ulcers or cancer.
- **Thalassemia** is a hereditary disease that appears mostly in Mediterranean populations. A genetic mutation causes abnormal hemoglobin production and **hemolysis** (destruction) of red cells. Thalassemia is designated as α (alpha) or β (beta), according to the part of the hemoglobin molecule affected. Severe β thalassemia is also called **Cooley anemia** or *thalassemia major.*
- In **sickle cell anemia**, a mutation alters the hemoglobin molecule so that it precipitates (settles out) when it gives up oxygen, distorting the RBCs into a crescent shape **(FIG. 11-12)**. The altered cells block small blood vessels and deprive tissues of oxygen, an episode termed *sickle cell crisis*. The misshapen cells are also readily destroyed (hemolyzed). The disease predominates in black populations. Genetic carriers of the defect, those with one normal and one abnormal gene, show *sickle cell trait.* They usually have no symptoms, except when oxygen is low, such as at high altitudes. They can, however, pass the defective gene to offspring. Sickle cell anemia, as well as many other genetic diseases, can be diagnosed in carriers and in a fetus before birth.

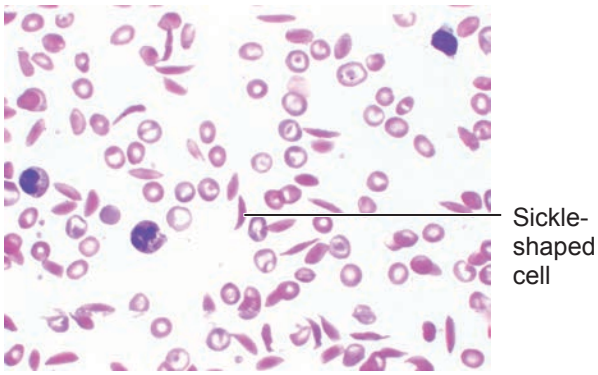

FIGURE 11-12 A blood smear in sickle cell anemia. Abnormal cells take on a crescent (sickle) shape when they give up oxygen.

Reticulocyte counts are useful in diagnosing the causes of anemia. Reticulocytes are immature RBCs that normally appear as a small percentage of the total erythrocytes. An increase in the reticulocyte count indicates increased red cell formation, as in response to hemorrhage or cell destruction. A decrease in reticulocytes indicates a failure in red cell production, as caused by nutritional deficiency or aplastic anemia **(BOX 11-6)**.

CLINICAL PERSPECTIVES
Use of Reticulocytes in Diagnosis

BOX 11-6

As erythrocytes mature in the red bone marrow, they go through a series of stages in which they lose their nuclei and most other organelles, maximizing the space available for hemoglobin. In one of the last stages of development, small numbers of ribosomes and some rough endoplasmic reticulum remain in the cell and appear as a network, or reticulum, when stained. Cells at this stage are called reticulocytes. Reticulocytes leave the red bone marrow and enter the bloodstream, where they become fully mature erythrocytes in about 24 to 48 hours. The average number of red cells maturing through the reticulocyte stage at any given time is about 1 to 2%. Changes in these numbers can be used in diagnosing certain blood disorders.

When erythrocytes are lost or destroyed, as from chronic bleeding or some form of hemolytic anemia, red cell production is "stepped up" to compensate for the loss. Greater numbers of reticulocytes are then released into the blood before reaching full maturity, and counts increase to above normal. On the other hand, a decrease in the number of circulating reticulocytes suggests a problem with red cell production, as in cases of deficiency anemias or suppression of bone marrow activity.

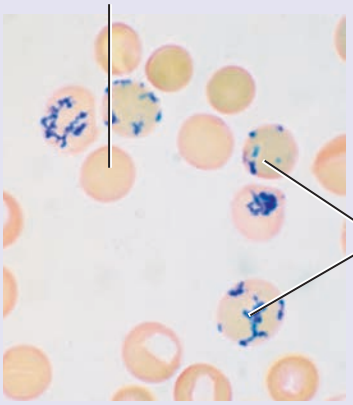

extern.ir

COAGULATION DISORDERS

The most common cause of coagulation problems is a deficiency in the number of circulating platelets, a condition termed **thrombocytopenia.** Possible causes include aplastic anemia, infections, bone marrow cancer, and agents that destroy bone marrow, such as x-rays or certain drugs. This disorder results in bleeding into the skin and mucous membranes, variously described as **petechiae** (pinpoint spots), **ecchymoses** (bruises), and **purpura** (purple lesions).

In **disseminated intravascular coagulation** (**DIC**), widespread clotting in the vessels obstructs circulation to the tissues. This is followed by diffuse hemorrhages as clotting factors are removed and the coagulation process is impaired. DIC may result from a variety of causes, including infection, cancer, hemorrhage, injury, and **allergy.**

Hemophilia is a hereditary deficiency of a specific clotting factor. It is a genetically sex-linked disease that is passed from mother to son. There is bleeding into the tissues, especially into the joints (hemarthrosis). Hemophilia must be treated with transfusions of the necessary clotting factors, which are now produced in purified form from blood products or by genetic engineering. Genetic engineering may one day provide a cure by inserting a normal gene into the patient's body to produce the deficient clotting factor.

BOX 11-7 lists tests done for these and other coagulation disorders.

NEOPLASMS

Leukemia is a neoplasm of WBCs. The rapidly dividing but incompetent white cells accumulate in the tissues and crowd out the other blood cells. The symptoms of leukemia include anemia, fatigue, easy bleeding, **splenomegaly**, and sometimes hepatomegaly (enlargement of the liver). The causes of leukemia are unknown but may include exposure to radiation or harmful chemicals, hereditary factors, and perhaps viral infection.

The two main categories of leukemia are determined by origin and the cells involved:

- Myelogenous leukemia originates in the bone marrow and involves mainly the granular leukocytes.
- Lymphocytic leukemia affects B cells and the lymphatic system, causing **lymphadenopathy** (lymph node disease) and adverse effects on the immune system.

Leukemias are further differentiated as acute or chronic based on clinical progress. Acute leukemia is the most common form of cancer in young children. The acute forms are:

- Acute myeloblastic (myelogenous) leukemia (AML). The prognosis in AML is poor for both children and adults.
- Acute lymphoblastic (lymphocytic) leukemia (ALL). With treatment, the ALL remission rate is high.

The chronic forms of leukemia are:

- Chronic myelogenous leukemia, also called chronic granulocytic leukemia, affects young to middle-aged adults **(FIG 11-13A)**. Most cases show the **Philadelphia chromosome** (**Ph**), an inherited anomaly in which part of chromosome 22 shifts to chromosome 9.
- Chronic lymphocytic leukemia (CLL) appears mostly in the elderly and is the most slowly growing form of the disease **(FIG. 11-13B)**.

Leukemia treatment includes chemotherapy, radiation therapy, and bone marrow transplantation. Bone marrow contains stem cells, immature cells that can develop into mature, functional cells. After the patient's bone marrow stem cells are destroyed, donor bone marrow can repopulate the recipient's bone marrow with normal, healthy blood-forming cells. Another option for transplantation is the use of umbilical cord blood to replace blood-forming cells in bone marrow. This blood is more readily available than bone marrow and does not have to match as closely to avoid rejection.

Hodgkin lymphoma is a cancer of the B cells in lymph nodes. In the U.S. population the incidence of the disease peaks at about 20 years of age and again at about 65 years of age. The cause is unknown, but in some cases may involve a viral infection. The disease appears as painless enlargement of a lymph node or group of nodes, often in the neck, armpit, thorax, and groin. If untreated, it may spread throughout the lymphatic system to other tissues. Early signs are weight loss, fever, night sweats, fatigue,

FOR YOUR REFERENCE — BOX 11-7
Coagulation Tests

Test	Abbreviation	Description
activated partial thromboplastin time	APTT	Measures time required for clot formation; used to evaluate clotting factors and monitor heparin therapy
bleeding time	BT	Measures capacity of platelets to stop bleeding after a standard skin incision
partial thromboplastin time	PTT	Evaluates clotting factors; similar to APTT, but less sensitive
prothrombin time	PT, pro time	Indirectly measures prothrombin; used to monitor anticoagulant therapy; also called Quick test
thrombin time (thrombin clotting time)	TT (TCT)	Measures how quickly a clot forms

extern.ir

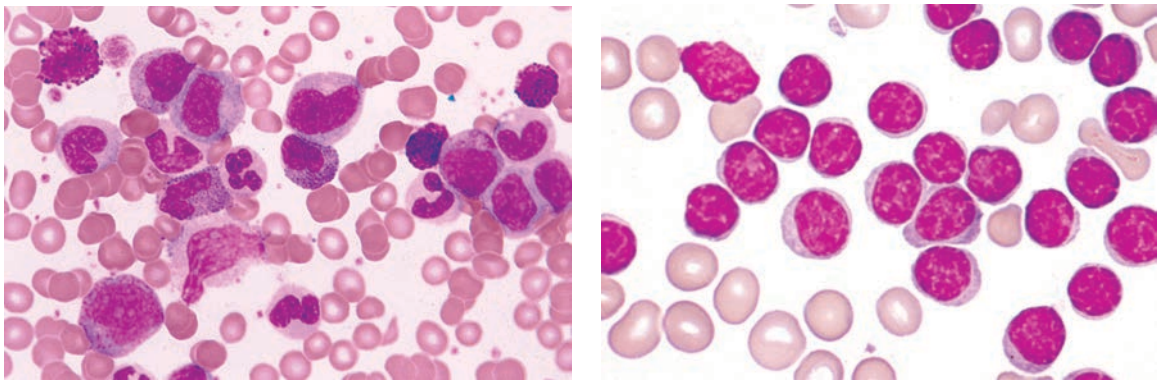

A B

FIGURE 11-13 Leukemia. Leukemia is a malignant overgrowth of white cells originating in the bone marrow (myelogenous) or lymphatic system (lymphocytic). **A.** Chronic myelogenous leukemia showing overproduction of all categories of white cells. **B.** Chronic lymphocytic leukemia showing numerous lymphocytes.

anemia, and a weakened immune system. A feature of Hodgkin lymphoma is giant cells in the lymph nodes called **Reed–Sternberg cells** (FIG. 11-14). Symptoms include fever, night sweats, weight loss, and skin itching (pruritus). Most cases can be cured with radiation and chemotherapy.

Non-Hodgkin lymphoma (NHL) is also a malignant enlargement of lymph nodes but does not show Reed–Sternberg cells. It is more common than Hodgkin disease and has a higher mortality rate. Cases vary in severity and prognosis. It is most prevalent in the older adult population and in those with AIDS and other forms of immunodeficiency. NHL involves the T or B lymphocytes, and some cases may be related to infection with certain viruses. It requires systemic chemotherapy and sometimes bone marrow transplantation.

Multiple myeloma is a cancer of the blood-forming cells in bone marrow, mainly the plasma cells that produce antibodies. The disease causes anemia, bone pain, and bone weakening. Patients have a greater susceptibility to infection because of immunodeficiency. Abnormally high levels of calcium and protein in the blood often lead to kidney failure. Multiple myeloma is treated with radiation and chemotherapy, but the prognosis is generally poor.

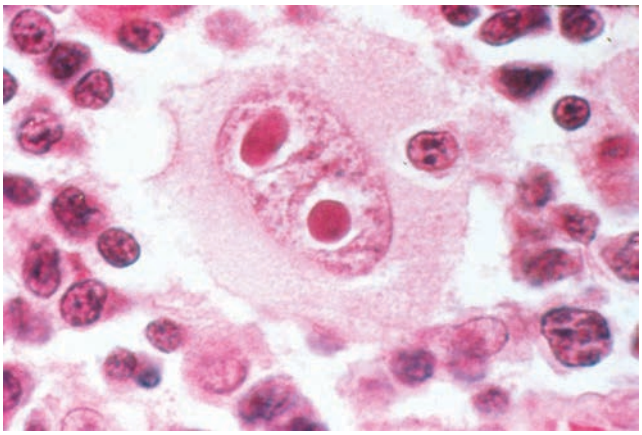

FIGURE 11-14 Reed–Sternberg cell. These cells are typical of Hodgkin disease.

Clinical Aspects of Immunity

HYPERSENSITIVITY

Hypersensitivity is any harmful overreaction of the immune system. Its forms include allergy, autoimmune disease, and transplantation reactions. In cases of **allergy**, a person is more sensitive to a particular antigen than the average individual. Common **allergens** are pollen, animal dander, dust, and foods, but there are many more. A seasonal allergy to inhaled pollens is commonly called "hay fever." Responses may include itching, redness, or tearing of the eyes (conjunctivitis), skin rash, asthma, runny nose (rhinitis), sneezing, **urticaria** (hives), and **angioedema**, a reaction similar to hives but involving deeper layers of tissue.

An **anaphylactic reaction** is a severe generalized allergic response that can rapidly lead to death as a result of shock and respiratory distress. It must be treated by immediate administration of **epinephrine** (**adrenaline**) and maintenance of open airways. Oxygen, antihistamines, and corticosteroids may also be given. Common causes of anaphylaxis are drugs, especially penicillin and other antibiotics, vaccines, diagnostic chemicals, foods, and insect venom.

A **delayed hypersensitivity reaction** involves T cells and takes at least 12 hours to develop. A common example is the reaction to contact with plant irritants such as those of poison ivy and poison oak.

IMMUNODEFICIENCY

The term **immunodeficiency** refers to any failure in the immune system. This may be congenital (present at birth) or acquired and may involve any components of the system. The deficiency may vary in severity but is always evidenced by an increased susceptibility to disease.

Acquired immunodeficiency syndrome (**AIDS**) is acquired by infection with **human immunodeficiency virus** (**HIV**), which attacks certain T cells. These cells have a specific surface attachment site, the CD4 receptor, for the virus. HIV is spread by sexual contact, use of contaminated needles, blood transfusions, and passage from an infected mother to her fetus. It leaves the host susceptible to opportunistic infections such

extern.ir

as pneumonia caused by the fungus *Pneumocystis jirovecii*; thrush, an oral fungal infection caused by *Candida albicans*; and infection with *Cryptosporidium*, a protozoon that causes cramps and diarrhea. It also predisposes the patient to **Kaposi sarcoma**, a once-rare form of skin cancer. AIDS may also induce autoimmunity or attack the nervous system.

AIDS is diagnosed and monitored by **CD4+ T lymphocyte counts**, a measure of cells with the HIV receptor. A count of less than 200/μL of blood signifies severe immunodeficiency. HIV antibody levels and direct viral blood counts are also used to track the disease's course. At present there is no vaccine or cure for AIDS, but drugs can delay its progress.

AUTOIMMUNE DISEASES

A disorder that results from an immune response to one's own tissues is classified as an **autoimmune disease.** The cause may be a failure in the immune system or a reaction to body cells that have been slightly altered by mutation or disease. The list of diseases that are believed to be caused, at least in part, by autoimmunity is long. Some, such as **systemic lupus erythematosus** (SLE), **systemic sclerosis** (scleroderma), and **Sjögren syndrome**, affect tissues in multiple systems. Others target more specific organs or systems. Examples are pernicious anemia, rheumatoid arthritis, Graves disease (of the thyroid), myasthenia gravis (a muscle disease), fibromyalgia syndrome (a musculoskeletal disorder), rheumatic heart disease, and glomerulonephritis (a kidney disease). These diseases are discussed in more detail in other chapters.

Terminology *Key Terms*

The terms listed below are emphasized in this chapter. Knowing them will help you organize and prioritize your learning. These boldface terms are also found, collectively, with all chapter key terms in the Glossary.

Disorders

acquired immunodeficiency syndrome (AIDS) *ah-KWI-erd im-u-no-de-FISH-en-se SIN-drome*	Immune system failure caused by infection with HIV (human immunodeficiency virus); the virus infects certain T cells and thus interferes with immunity
allergen *AL-er-jen*	A substance that causes an allergic response
allergy *AL-er-je*	Hypersensitivity
anaphylactic reaction *an-ah-fih-LAK-tik*	An exaggerated allergic reaction to a foreign substance; it may lead to death caused by circulatory collapse and respiratory distress if untreated; also called anaphylaxis (from Greek *phylaxis*, meaning "protection")
anemia *ah-NE-me-ah*	A deficiency in the amount of hemoglobin in the blood; may result from blood loss, malnutrition, a hereditary defect, environmental factors, and other causes (see **FIGS. 11-11** and **11-12**)
angioedema *an-je-o-eh-DE-mah*	A localized edema with large hives (wheals) similar to urticaria but involving deeper layers of the skin and subcutaneous tissue
aplastic anemia *a-PLAS-tik*	Anemia caused by bone marrow failure resulting in deficient blood cell production, especially of red cells; pancytopenia
autoimmune disease *aw-to-ih-MUNE*	A condition in which the immune system produces antibodies against an individual's own tissues (prefix *auto* means "self")
Cooley anemia	A form of thalassemia (hereditary anemia) that affects production of the β (beta) hemoglobin chain; thalassemia major
delayed hypersensitivity reaction	An allergic reaction involving T cells that takes at least 12 hours to develop; examples are various types of contact dermatitis, such as poison ivy or poison oak; the tuberculin reaction (test for TB); and rejections of transplanted tissue
disseminated intravascular coagulation (DIC)	Widespread clot formation in the microscopic vessels; may be followed by bleeding caused by depletion of clotting factors
ecchymosis *ek-ih-MO-sis*	A collection of blood under the skin caused by leakage from small vessels (root *chym* means "juice")

(continued)

extern.ir

Terminology Key Terms (Continued)

hemolysis *he-MOL-ih-sis*	The rupture of red blood cells and the release of hemoglobin (adjective: hemolytic)
hemophilia *he-mo-FIL-e-ah*	A hereditary blood disease caused by lack of a clotting factor resulting in abnormal bleeding
hemorrhagic anemia *hem-o-RAJ-ik*	Anemia that results from blood loss, as from an injury or internal bleeding
human immunodeficiency virus (HIV)	The virus that causes AIDS
Hodgkin lymphoma	A neoplastic disease of B cells that involves the lymph nodes, spleen, liver, and other tissues; characterized by the presence of giant Reed–Sternberg cells (see **FIG. 11-14**)
hypersensitivity *hi-per-sen-sih-TIV-ih-te*	An immunologic reaction to a substance that is harmless to most people; allergy
immunodeficiency *im-u-no-de-FISH-en-se*	A congenital or acquired failure of the immune system to protect against disease
intrinsic factor *In-TRIN-sik*	A substance produced in the stomach that aids in the intestinal absorption of vitamin B_{12}, necessary for the manufacture of red blood cells; lack of intrinsic factor causes pernicious anemia
Kaposi sarcoma *KAP-o-se*	Cancerous lesion of the skin and other tissues, seen most often in patients with AIDS
leukemia *lu-KE-me-ah*	Malignant overgrowth of immature white blood cells; may be chronic or acute; may affect bone marrow (myelogenous leukemia) or lymphoid tissue (lymphocytic leukemia)
lymphadenopathy *lim-fad-eh-NOP-ah-the*	Any disease of the lymph nodes
multiple myeloma *mi-eh-LO-mah*	A tumor of the blood-forming tissue in bone marrow
non-Hodgkin lymphoma (NHL)	A widespread malignant disease of lymph nodes that involves lymphocytes; it differs from Hodgkin disease in that giant Reed–Sternberg cells are absent
nutritional anemia *nu-TRISH-un-al*	Anemia resulting from a dietary deficiency, usually of iron, vitamin B_{12}, or folate
Philadelphia chromosome (Ph)	An abnormal chromosome found in the cells of most individuals with chronic granulocytic (myelogenous) leukemia
pernicious anemia *per-NISH-us*	Anemia caused by failure of the stomach to produce intrinsic factor, a substance needed for the absorption of vitamin B_{12}; this vitamin is required for the formation of erythrocytes
petechiae *pe-E-ke-e*	Pinpoint, flat, purplish-red spots caused by bleeding within the skin or mucous membrane (singular: petechia)
purpura *PUR-pu-rah*	A condition characterized by hemorrhages into the skin, mucous membranes, internal organs, and other tissues (from Greek word meaning "purple"); thrombocytopenic purpura is caused by a deficiency of platelets
sickle cell anemia *SIK-l*	A hereditary anemia caused by the presence of abnormal hemoglobin; red blood cells become sickle-shaped when they give up oxygen and interfere with normal blood flow to the tissues (see **FIG. 11-12**); most common in black populations of West African descent
sideroblastic anemia *sid-eh-ro-BLAS-tik*	Anemia caused by inability to use available iron to manufacture hemoglobin; the excess iron precipitates in normoblasts (developing red blood cells)
Sjögren syndrome *SHO-gren*	An autoimmune disease involving dysfunction of the exocrine glands and affecting secretion of tears, saliva, and other body fluids; deficiency leads to dry mouth, tooth decay, corneal damage, eye infections, and difficulty in swallowing

extern.ir

Terminology *Key Terms (Continued)*

splenomegaly *sple-no-MEG-ah-le*	Enlargement of the spleen
systemic lupus erythematosus *LU-pus er-ih-the-mah-TO-sus*	Inflammatory connective tissue disease affecting the skin and multiple organs; patients are sensitive to light and may have a red butterfly-shaped rash over the nose and cheeks
systemic sclerosis	A diffuse connective tissue disease that may involve any system causing inflammation, degeneration, and fibrosis; also called scleroderma because it causes thickening of the skin
thalassemia *thal-ah-SE-me-ah*	A group of hereditary anemias mostly found in populations of Mediterranean descent (the name comes from the Greek word for "sea")
thrombocytopenia *throm-bo-si-to-PE-ne-ah*	A deficiency of thrombocytes (platelets) in the blood
urticaria *ur-tih-KAR-e-ah*	A skin reaction consisting of round, raised eruptions (wheals) with itching; hives
Diagnosis and Treatment	
adrenaline *ah-DREN-ah-lin*	See epinephrine
CD4+ T lymphocyte count	A count of the T cells that have the CD4 receptors for the AIDS virus (HIV); a count of less than 200/μL of blood signifies severe immunodeficiency
epinephrine *ep-ih-NEF-rin*	A powerful stimulant produced by the adrenal gland and sympathetic nervous system; activates the cardiovascular, respiratory, and other systems needed to meet stress; used as a drug to treat severe allergic reactions and shock; also called adrenaline
reticulocyte counts *re-TIK-u-lo-site*	Blood counts of reticulocytes, a type of immature red blood cell; reticulocyte counts are useful in diagnosis to indicate the rate of erythrocyte formation (see **BOX 11-6**)
Reed–Sternberg cells *rede SHTERN-berg*	Giant cells that are characteristic of Hodgkin disease; they usually have two large nuclei and are surrounded by a halo (see **FIG. 11-14**)

Terminology *Enrichment Terms*

The terms listed below expand on the key terms to increase your knowledge of this chapter topic.

Normal Structure and Function	
agglutination *ah-glu-tih-NA-shun*	The clumping of cells or particles in the presence of specific antibodies
bilirubin *bil-ih-RU-bin*	A pigment derived from the breakdown of hemoglobin and eliminated by the liver in bile
complement *COM-pleh-ment*	A group of plasma enzymes that interacts with antibodies
corpuscle *KOR-pus-l*	A small mass or body; a blood corpuscle is a blood cell
hemopoietic stem cell *he-mo-poy-EH-tik*	A primitive bone marrow cell that gives rise to all varieties of blood cells
heparin *HEP-ah-rin*	A substance found throughout the body that inhibits blood coagulation; an anticoagulant

(continued)

extern.ir

Terminology *Enrichment Terms (Continued)*

plasmin *PLAZ-min*	An enzyme that dissolves clots; also called fibrinolysin
thrombin *THROM-bin*	The enzyme derived from prothrombin that converts fibrinogen to fibrin
Symptoms and Conditions	
agranulocytosis *a-gran-u-lo-si-TO-sis*	A condition involving a decrease in the number of granulocytes in the blood; also called granulocytopenia
erythrocytosis *eh-rith-ro-si-TO-sis*	Increase in the number of red cells in the blood; may be normal, such as to compensate for life at high altitudes, or abnormal, such as in cases of pulmonary or cardiac disease
Fanconi syndrome *fan-KO-ne*	Congenital aplastic anemia that appears between birth and 10 years of age; may be hereditary or caused by damage before birth, as by a virus
graft versus host reaction (GVHR)	An immunologic reaction of transplanted lymphocytes against tissues of the host; a common complication of bone marrow transplantation
hairy cell leukemia	A form of leukemia in which cells have filaments, making them look hairy
hematoma *he-mah-TO-mah*	A localized collection of blood, usually clotted, caused by a break in a blood vessel
hemolytic disease of the newborn (HDN)	Disease that results from incompatibility between the blood of a mother and her fetus, usually involving Rh factor; an Rh-negative mother produces antibody to an Rh-positive fetus that, in later pregnancies, will destroy the red cells of an Rh-positive fetus; the problem is usually avoided by treating the mother with antibodies to remove the Rh antigen; also called erythroblastosis fetalis
hemosiderosis *he-mo-sid-er-O-sis*	A condition involving the deposition of an iron-containing pigment (hemosiderin) mainly in the liver and the spleen; the pigment comes from hemoglobin released from disintegrated red blood cells
idiopathic thrombocytopenic purpura (ITP)	A clotting disorder caused by destruction of platelets that usually follows a viral illness; causes petechiae and hemorrhages into the skin and mucous membranes
infectious mononucleosis *mon-o-nu-kle-O-sis*	An acute infectious disease caused by Epstein–Barr virus (EBV); characterized by fever, weakness, lymphadenopathy, hepatosplenomegaly, and atypical lymphocytes (resembling monocytes) (see **FIG. 11-10**)
lymphocytosis *lim-fo-si-TO-sis*	An increase in the number of circulating lymphocytes
myelodysplastic syndrome *mi-eh-lo-dis-PLAS-tik*	Bone marrow dysfunction resulting in anemia and deficiency of neutrophils and platelets; may develop in time into leukemia; preleukemia
myelofibrosis *mi-eh-lo-fi-BRO-sis*	Condition in which bone marrow is replaced with fibrous tissue
neutropenia *nu-tro-PE-ne-ah*	A decrease in the number of neutrophils with increased susceptibility to infection; causes include drugs, irradiation, and infection; may be a side effect of treatment for malignancy
pancytopenia *pan-si-to-PE-ne-ah*	A decrease in all cells of the blood, as in aplastic anemia
polycythemia *pol-e-si-THE-me-ah*	Any condition in which there is a relative increase in the percent of red blood cells in whole blood; may result from excessive production of red cells because of oxygen lack, as caused by high altitudes, breathing obstruction, heart failure, or certain forms of poisoning. Apparent polycythemia results from concentration of the blood, as by dehydration **(FIG. 11-15)**
polycythemia vera *pol-e-si-THE-me-ah VE-rah*	A condition in which overactive bone marrow produces too many red blood cells (see **FIG. 11-15**) that interfere with circulation and promote thrombosis and hemorrhage; treated by blood removal; also called erythremia and Vaquez–Osler disease

extern.ir

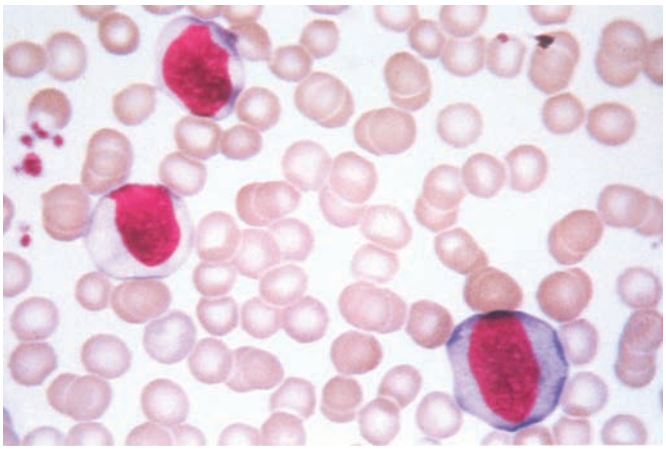

FIGURE 11-15 Infectious mononucleosis. Atypical lymphocytes characterize this viral disease.

Terminology *Enrichment Terms (Continued)*

septicemia *sep-tih-SE-me-ah*	Presence of microorganisms in the blood
spherocytic anemia *sfer-o-SIT-ik*	Hereditary anemia in which red blood cells are round instead of disk shaped and rupture (hemolyze) excessively
thrombotic thrombocytopenic purpura (TTP)	An often fatal disorder in which multiple clots form in blood vessels
von Willebrand disease	A hereditary bleeding disease caused by lack of von Willebrand factor, a substance necessary for blood clotting
Diagnosis (see also BOXES 11-4 and 11-7)	
Bence Jones protein	A protein that appears in the urine of patients with multiple myeloma
Coombs test	A test for detection of antibodies to red blood cells, such as those appearing in cases of autoimmune hemolytic anemias
electrophoresis *e-lek-tro-fo-RE-sis*	Separation of particles in a liquid by application of an electrical field; used to separate components of blood
ELISA	Enzyme-linked immunosorbent assay; a highly sensitive immunologic test used to diagnose HIV infection, hepatitis, and Lyme disease, among others
monoclonal antibody *mon-o-KLO-nal*	A pure antibody produced in the laboratory; used for diagnosis and treatment
pH	A scale that measures the relative acidity or alkalinity of a solution; represents the amount of hydrogen ion in the solution
Schilling test *SHIL-ing*	Test used to determine absorption of vitamin B_{12} by measuring excretion of radioactive B_{12} in the urine; used to distinguish pernicious from nutritional anemia
seroconversion *se-ro-con-VER-zhun*	The appearance of antibodies in the serum in response to a disease or an immunization
Western blot assay	A very sensitive test used to detect small amounts of antibodies in the blood
Wright stain	A commonly used blood stain; see **FIGURE 11-2** shows blood cells stained with Wright stain

(continued)

extern.ir

Terminology Enrichment Terms (Continued)

Treatment	
anticoagulant *an-ti-ko-AG-u-lant*	An agent that prevents or delays blood coagulation
antihistamine *an-tih-HIS-tah-meme*	A drug that counteracts the effects of histamine and is used to treat allergic reactions
apheresis *af-eh-RE-sis*	A procedure in which blood is withdrawn, a portion is separated and retained, and the remainder is returned to the donor; apheresis may be used as a suffix with a root meaning the fraction retained, such as plasmapheresis, leukapheresis
autologous blood *aw-TOL-o-gus*	A person's own blood; may be donated in advance of surgery and transfused if needed
cryoprecipitate *kri-o-pre-SIP-ih-tate*	A sediment obtained by cooling; the fraction obtained by freezing blood plasma contains clotting factors
desensitization *de-sen-sih-tih-ZA-shun*	Treatment of allergy by small injections of the offending allergen, causing an increase of antibody to destroy the antigen rapidly on contact
homologous blood *ho-MOL-o-gus*	Blood from animals of the same species, such as human blood used for transfusion from one person to another; blood used for transfusions must be compatible with the recipient's blood
immunosuppression *im-u-no-su-PRESH-un*	Depression of the immune response; may be correlated with disease but also may be induced therapeutically to prevent rejection in cases of tissue transplantation
protease inhibitor *PRO-te-ase*	An anti-HIV drug that acts by inhibiting an enzyme the virus needs to multiply

Terminology Abbreviations

The abbreviations listed below are emphasized in this chapter. These are also found, collectively, with all chapter abbreviations in Appendix 2.

Ab	Antibody
Ag	Antigen, also silver
AIDS	Acquired immunodeficiency syndrome
ALL	Acute lymphoblastic (lymphocytic) leukemia
AML	Acute myeloblastic (myelogenous) leukemia
APC	Antigen-presenting cell
APTT	Activated partial thromboplastin time
BT	Bleeding time
CBC	Complete blood count
CGL	Chronic granulocytic leukemia
CLL	Chronic lymphocytic leukemia
CML	Chronic myelogenous leukemia
crit	Hematocrit
DIC	Disseminated intravascular coagulation
Diff	Differential count
EBV	Epstein–Barr virus
ELISA	Enzyme-linked immunosorbent assay
EPO, EP	Erythropoietin
ESR	Erythrocyte sedimentation rate
FFP	Fresh frozen plasma

extern.ir

Terminology *Abbreviations (Continued)*

Hb, Hgb	Hemoglobin
Hct, Ht	Hematocrit
HDN	Hemolytic disease of the newborn
HIV	Human immunodeficiency virus
IF	Intrinsic factor
Ig	Immunoglobulin
ITP	Idiopathic thrombocytopenic purpura
lytes	Electrolytes
MCH	Mean corpuscular hemoglobin
MCHC	Mean corpuscular hemoglobin concentration
µL, mcL	Microliter
µm, mcm	Micrometer
MCV	Mean corpuscular volume
MDS	Myelodysplastic syndrome
mEq	Milliequivalent
NHL	Non-Hodgkin lymphoma
PCV	Packed cell volume
pH	Scale for measuring hydrogen ion concentration (acidity or alkalinity)
Ph	Philadelphia chromosome
PMN	Polymorphonuclear (neutrophil)
poly	Neutrophil
polymorph	Neutrophil
PT	Prothrombin time; pro time
PTT	Partial thromboplastin time
RBC	Red blood cell; red blood (cell) count
seg	Neutrophil
SLE	Systemic lupus erythematosus
T(C)T	Thrombin (clotting) time
TTP	Thrombotic thrombocytopenic purpura
vWF	von Willebrand factor
WBC	White blood cell; white blood (cell) count

Case Study Revisited

Olivia's Case Study Follow-Up

After her diagnosis, Olivia did some further research on her type I hypersensitivity to latex. She understands that she needs to avoid latex products. She also knows that the cornstarch used in powdered latex gloves serves as a carrier for allergenic proteins from latex. The powder may become airborne resulting in inhalation and subsequent allergic response in a sensitized person. However, Olivia remembers that her hospital has been latex-free for over 3 months. Too many people are allergic to it so the hospital established latex-free guidelines for employee and patient safety. For example, there are signs by the elevators reminding visitors not to bring in latex balloons for patients and the hospital gift shop only sells mylar (a nonlatex product) balloons.

Olivia spoke to the OR manager who said "Latex gloves were removed over 3 months ago in compliance with the hospital's latex-free guidelines." But another nurse stepped forward holding up a stack of sterile latex gloves. It was discovered that some of the latex gloves had not been removed from all of the ORs. By the end of the shift, any latex gloves that were accidently overlooked were removed from all areas of the hospital.

Latex safety is important for Olivia in performing her job as a CRNA but she also needs to be aware to avoid all contact with any natural rubber latex in her home and out in the community. She wears a medical alert bracelet, uses a bronchodilator inhaler at the first symptom of bronchospasm, and carries a syringe of epinephrine at all times.

extern.ir

CHAPTER 11 Review

This review tests your understanding of the content introduced in this chapter. Follow the instructions for each exercise and check your answers in Appendix 11.

LABELING EXERCISE

BLOOD CELLS

Write the name of each numbered part on the corresponding line of the answer sheet.

Erythrocyte
Leukocyte
Platelet

1. _____
2. _____
3. _____

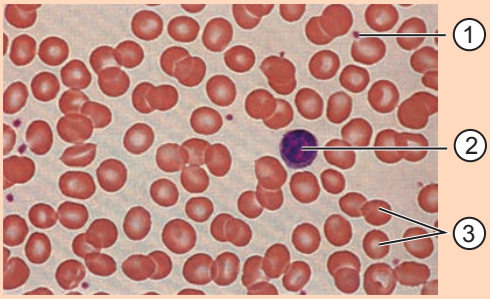

LEUKOCYTES (WHITE BLOOD CELLS)

Write the name of each numbered part on the corresponding line of the answer sheet.

Basophil
Eosinophil
Lymphocyte
Monocyte
Neutrophil

1. _____
2. _____
3. _____
4. _____
5. _____

Leukocytes (white blood cells)

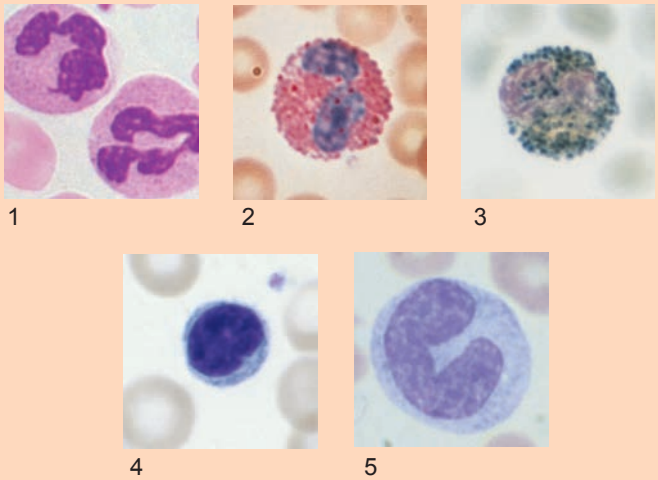

extern.ir

TERMINOLOGY

MATCHING

Match the following terms, and write the appropriate letter to the left of each number.

____ 1.	anemia	a. substance active in blood clotting
____ 2.	thrombolytic	b. cell that produces platelets
____ 3.	antibody	c. deficiency in the amount of hemoglobin in the blood
____ 4.	megakaryocyte	d. able to dissolve a blood clot
____ 5.	prothrombin	e. substance active in an immune response

____ 6.	hypokalemia	a. condition involving iron deposits
____ 7.	natriuresis	b. deficiency of potassium in the blood
____ 8.	ferric	c. urinary excretion of sodium
____ 9.	siderosis	d. urinary excretion of nitrogenous compounds
____ 10.	azoturia	e. pertaining to iron

____ 11.	hemophilia	a. allergy
____ 12.	hemostasis	b. hereditary form of anemia
____ 13.	hypersensitivity	c. stoppage of blood flow
____ 14.	thalassemia	d. hereditary clotting disorder
____ 15.	purpura	e. bleeding into the tissues

____ 16.	pH	a. laboratory test of blood
____ 17.	HIV	b. a form of leukemia
____ 18.	ALL	c. hematocrit
____ 19.	PCV	d. virus that causes an immunodeficiency disease
____ 20.	CBC	e. scale for measuring acidity or alkalinity

Enrichment Terms

____ 21.	erythrocytosis	a. separation of blood and use of components
____ 22.	heparin	b. increase in the number of RBCs in the blood
____ 23.	apheresis	c. anticoagulant
____ 24.	ELISA	d. method for separating components of a solution
____ 25.	electrophoresis	e. sensitive immunologic test

extern.ir

FILL IN THE BLANKS

Complete the sentence with the correct term(s).

26. The engulfing of foreign material by white cells is called _____ .
27. The iron-containing pigment in red blood cells that carries oxygen is called _____ .
28. A substance that separates into ions in solution is a(n) _____ .
29. The cell fragments active in blood clotting are the _____ .
30. A hemocytometer is used to count _____ .
31. Oxyhemoglobin is hemoglobin combined with _____ .
32. A hematoma is a localized collection of _____ .
33. A disorder involving lack of hemoglobin in the blood is _____ .
34. A myeloma is a neoplasm that involves the _____ .
35. The abbreviation Ig means _____ .

MULTIPLE CHOICE

Refer to Olivia's opening case study, select the best answer, and write the letter of your choice to the left of each number.

____ 36. Anaphylaxis, a life-threatening physiologic response, is an extreme form of
a. remission
b. hemostasis
c. hypersensitivity
d. homeostasis

____ 37. Urticaria is commonly called
a. hives
b. dermatitis
c. rhinitis
d. congenital

____ 38. The cells involved in a T cell-mediated allergic response are
a. basophils
b. monocytes
c. lymphocytes
d. B cells

____ 39. The natural latex protein in latex gloves may act as a(n)
a. antibody
b. allergen
c. purpura
d. immunocyte

____ 40. The common name for epinephrine is
a. cortisone
b. adrenaline
c. heparin
d. antihistamine

extern.ir

TRUE–FALSE

Examine the following statements. If the statement is true, write T in the first blank. If the statement is false, write F in the first blank, and correct the statement by replacing the underlined word in the second blank.

	True or False	Correct Answer
41. A leukocyte is also called a platelet.	_____	_____
42. A plasma cell produces antibodies.	_____	_____
43. The liquid that remains after blood coagulates is called serum.	_____	_____
44. Blood that does not react with either A or B antiserum is type O.	_____	_____
45. A band cell is an immature monocyte.	_____	_____
46. The root kali- pertains to potassium.	_____	_____

DEFINITIONS

The suffixes -ia, -osis, and -hemia all denote an increase in the type of cell indicated by the word root. Define the following terms.

47. leukocytosis (*lu-ko-si-TO-sis*) _____
48. eosinophilia (*e-o-sin-o-FIL-e-ah*) _____
49. erythrocytosis (*eh-rith-ro-si-TO-sis*) _____
50. thrombocythemia (*throm-bo-si-THE-me-ah*) _____
51. neutrophilia (*nu-tro-FIL-e-ah*) _____
52. monocytosis (*mon-o-si-TO-sis*) _____

Write a word for the following definitions.

53. An immature red blood cell _____
54. A decrease in the number of platelets (thrombocytes) in the blood _____
55. Presence of pus in the blood _____
56. Specialist in the study of immunity _____
57. Profuse flow of blood _____

Define each of the following.

58. hemolysis _____
59. neutropenia _____
60. myelotoxin _____
61. autoimmunity _____
62. viremia _____

extern.ir

ADJECTIVES

Use the ending -ic to write the adjective form of the following words.

63. hemolysis _____
64. leukemia _____
65. basophil _____
66. septicemia _____
67. thrombosis _____
68. lymphocyte _____

ELIMINATIONS

In each of the sets below, underline the word that does not fit in with the rest and explain the reason for your choice.

69. fibrin — thrombin — thrombolysis — prothrombin — fibrinogen

_____

70. Diff — Hct — MCV — EPO — MCH

_____

71. eosinophil — reticulocyte — monocyte — basophil — lymphocyte

_____

72. allergy — hypersensitivity — gamma globulin — urticaria — anaphylaxis

_____

WORD BUILDING

Write a word for the following definitions using the word parts given. Each word part can be used more than once.

-penia	-blast	leuk/o	-oid	-poiesis	myel/o	gen-	-emia	erythr/o	-ic	-oma	cyt/o

73. pertaining to a red blood cell _____
74. an immature white blood cell _____
75. pertaining to bone marrow _____
76. originating in bone marrow _____
77. an immature bone marrow cell _____
78. neoplastic overgrowth of white cells in the blood _____
79. deficiency of white cells in the blood _____
80. cancer of bone marrow _____
81. formation of red blood cells _____
82. pertaining to bone marrow cells _____

extern.ir

WORD ANALYSIS

Define the following words, and give the meaning of the word parts in each. Use a dictionary if necessary.

83. pancytopenia (*pan-si-to-PE-ne-ah*)
    a. pan- _____
    b. cyt/o _____
    c. -penia _____
84. polycythemia (*pol-e-si-THE-me-ah*)
    a. poly- _____
    b. cyt/o _____
    c. hem/o _____
    d. -ia _____
85. anisochromia (*an-i-so-KRO-me-ah*)
    a. an- _____
    b. iso- _____
    c. chrom/o _____
    d. -ia _____
86. myelodysplastic (*mi-eh-lo-dis-PLAS-tic*)
    a. myel/o _____
    b. dys- _____
    c. plast(y) _____
    d. -ic _____

extern.ir

Additional Case Studies

Case Study 11-1: Blood Replacement

Lisa, a 16 y/o, sustained a ruptured liver when she hit a tree while sledding. Emergency surgery was needed to stop the internal bleeding. During surgery, the ruptured segment of the liver was removed, and the laceration was sutured with a heavy, absorbable suture on a large smooth needle. Before surgery, her hemoglobin was 10.2 g/dL, but the reading decreased to 7.6 g/dL before hemostasis was attained. Cell salvage, or autotransfusion, was set up. In this procedure, the free blood was suctioned from her abdomen and mixed with an anticoagulant (heparin). The RBCs were washed in a sterile centrifuge with NS and transfused back to her through tubing fitted with a filter. She also received six units of homologous, leukocyte-reduced whole blood, five units of fresh frozen plasma, and two units of platelets. During the surgery, the CRNA repeatedly tested her Hgb and Hct as well as prothrombin time and partial thromboplastin time to monitor her clotting mechanisms.

Lisa is B-positive. Fortunately, there was enough B-positive blood in the hospital blood bank for her surgery. The laboratory informed her surgeon that they had two units of B-negative and six units of O-negative blood, which she could have received safely if she needed more blood during the night. However, her hemoglobin level increased to 12 g/dL, and she was stable during her recovery. She was monitored for DIC and pulmonary emboli.

Case Study 11-1 Questions

Follow the instructions for each question and check your answers in Appendix 11.

Multiple Choice. *Select the best answer, and write the letter of your choice to the left of each number.*

_____ 1. The unit for hemoglobin measurement (g/dL) means
   a. grams in decimal point
   b. grains in a deciliter
   c. drops in 50 mL
   d. grams in 100 mL

_____ 2. Heparin, an anticoagulant, is a drug that
   a. increases the rate of blood clotting
   b. takes the place of fibrin
   c. makes blood thinner than water
   d. interferes with blood clotting

_____ 3. The RBCs were washed with NS. This means the _____ were washed with _____.
   a. reticulocytes, heparin
   b. red blood cells, nutritional solution
   c. erythrocytes, normal saline
   d. red blood cells, heparin

_____ 4. Autotransfusion is transfusion of autologous blood, that is, the patient's own blood. Homologous blood is taken from
   a. another human
   b. synthetic chemicals
   c. plasma with clotting factors
   d. IV fluid with electrolytes

_____ 5. Patients who lose significant amounts of blood may lose clotting ability. Effective therapy in such cases would be replacement of
   a. IV solution with electrolytes
   b. packed RBCs
   c. platelets
   d. heparin

_____ 6. Lisa's blood type is B-positive. The best blood for her to receive is
   a. A-negative
   b. AB-positive
   c. B-negative
   d. B-positive

Define the following abbreviations.

7. PT _____
8. PTT _____
9. FFP _____
10. DIC _____

extern.ir

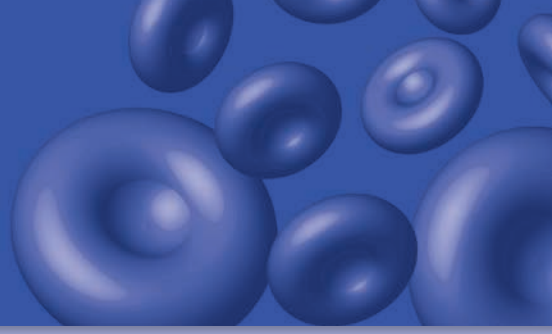

Case Study 11-2: Myelofibrosis

Ada, a 52 y/o kindergarten teacher, had myelofibrosis that had been in remission for 25 years. She had seen her hematologist regularly and had had routine blood testing since the age of 27. After several weeks of fatigue, idiopathic joint and muscle aching, weakness, and a frightening episode of syncope, she saw her hematologist for evaluation. Her hemoglobin was 9.0 g/dL and her hematocrit was 29%. Concerned that she was having an exacerbation, her doctor scheduled a bone marrow aspiration, and the results were positive for myelofibrosis.

Ada went through a 6-month therapy regimen of iron supplements in the form of ferrous sulfate tablets and received weekly vitamin B_{12} injections. Interferon was given every other week in addition to erythropoiesis therapy, which was unsuccessful. She was treated for presumed aplastic anemia. During treatment, splenomegaly developed, which compromised her abdominal organs and pulmonary function. She continued to lose weight, and her hemoglobin dropped as low as 6.0 g/dL. Weekly transfusions of packed RBCs did not improve her hemoglobin and hematocrit.

After a regimen of high-dose chemotherapy to shrink the fibers in her bone marrow and a splenectomy, Ada received a stem cell transplant. The stem cells were obtained from blood donated by her brother, who was a perfect immunologic match. After a 6-month period of recovery in a protected environment, required because of her immunocompromised state, Ada returned home and has been free of disease symptoms for over 1 year.

Case Study 11-2 Questions

Multiple Choice. *Select the best answer, and write the letter of your choice to the left of each number.*

_____ 1. Myelofibrosis, like aplastic anemia, is a disease in which there is
   a. overgrowth of RBCs
   b. destruction of the bone marrow
   c. dangerously high hemoglobin and hematocrit
   d. absence of bone marrow

_____ 2. Erythropoiesis is
   a. production of blood
   b. production of red cells
   c. destruction of platelets
   d. destruction of white cells

_____ 3. The "ferrous" in ferrous sulfate represents
   a. electrolytes
   b. B vitamins
   c. iron
   d. oxygen

_____ 4. Hemoglobin and hematocrit values pertain to
   a. leukocytes
   b. fibrinogen
   c. granulocytes
   d. red blood cells

_____ 5. Splenomegaly is
   a. prolapse of the spleen
   b. movement of the spleen
   c. enlargement of the lymph glands
   d. enlargement of the spleen

_____ 6. The stem cells Ada received were expected to develop into new
   a. spleen cells
   b. bone marrow cells
   c. hemoglobin
   d. cartilage

_____ 7. Ada's health was compromised because the high-dose chemotherapy caused
   a. immunodeficiency
   b. electrolyte imbalance
   c. anoxia
   d. autoimmunity

Define the following abbreviations.

8. Hgb _____
9. Hct _____
10. RBC _____

extern.ir

CHAPTER 12

Respiratory System

Pretest

Multiple Choice. **Select the best answer, and write the letter of your choice to the left of each number. To check your answers go to Appendix 11.**

_____ 1. The gas that is supplied to tissues by the respiratory system is
a. sulfur
b. neon
c. oxygen
d. carbon dioxide

_____ 2. The gas that is eliminated by the respiratory system is
a. chlorine
b. carbon dioxide
c. hydrogen
d. fluoride

_____ 3. The air sacs through which gases are exchanged in the lungs are the
a. trachea
b. bronchi
c. bursae
d. alveoli

_____ 4. The structure that holds the vocal folds is the
a. larynx
b. tongue
c. uvula
d. tonsils

_____ 5. The tubes that carry air from the trachea into the lungs are the
a. arteries
b. nares
c. veins
d. bronchi

_____ 6. The dome-shaped muscle under the lungs is the
a. palate
b. hiatus
c. diaphragm
d. esophagus

_____ 7. The membrane around the lungs is the
a. peritoneum
b. mucosa
c. pleura
d. mediastinum

_____ 8. A term for inflammation of the lungs is
a. bronchitis
b. pneumonia
c. pleurisy
d. laryngitis

extern.ir

Learning Objectives

After careful study of this chapter, you should be able to:

1. Compare external and internal gas exchange. ***P392***
2. Describe and give the functions of the structures in the respiratory tract. ***P392***
3. Describe the mechanism of breathing, including the roles of the diaphragm and phrenic nerve. ***P395***
4. Explain how oxygen and carbon dioxide are carried in the blood. ***P396***
5. Identify and use word parts pertaining to the respiratory system. ***P398***
6. Discuss nine disorders of the respiratory system. ***P401***
7. Name three types of organisms that can infect the respiratory system and give examples of each. ***P401***
8. List and define 10 volumes and capacities commonly used to measure pulmonary function. ***P407***
9. Interpret abbreviations commonly used with reference to the respiratory system. ***P414***
10. Analyze medical terms in case studies pertaining to respiration. ***PP391, 422***

Case Study: Preoperative Respiratory Testing for Allison, a Young Girl With Asthma

Chief Complaint

Allison, a 13 y/o, was seen in the preadmission testing unit in preparation for her elective spinal surgery for scoliosis. She has a history of mild asthma since age 4 with at least one attack a week. In an acute attack, she will have mild dyspnea, diffuse wheezing, yet an adequate air exchange that responds to bronchodilators. She was sent to pulmonary health services for a consult with a pulmonologist and pulmonary function studies to clear her for the upcoming spinal surgery.

Examination

Her physical examination was unremarkable except for her respiratory status. Her prebronchodilator spirometry showed a mild reduction in vital capacity but with a moderate to severe decrease in FEV_1 and FEV_1/FVC ratio. After bronchodilator administration, there was a mild but insignificant improvement in FEV_1. The postbronchodilator FEV_1 was 55% of predicted value and was considered moderately abnormal. The flow volume loops and spirographic curves were consistent with airflow obstruction.

Clinical Course

The anesthesiologist reviewed the pulmonologist's report. Allison's respiratory status was compromised for the surgical procedure and would require medical intervention prior to going to the OR. When the FEV_1 was acceptable, he spoke with Allison and the family and explained that her respiratory status would be closely monitored during and after surgery. Additional medications would be needed to maintain optimal airflow and oxygenation.

Case Study Revisited: Once you complete this chapter, please review the case follow-up on p. 415.

Ancillaries *At-A-Glance*

Visit the web resource to access the following resources.

Learning Resources

- eBook
- A&P Module with Heart & Lung Sounds
- Image Bank
- TestPrep
- Animations
- Audio Pronunciation Glossary

extern.ir

Introduction

The main function of the respiratory system is to provide oxygen to body cells for energy metabolism and to eliminate **carbon dioxide**, a byproduct of metabolism. Because these gases must be carried to and from the cells in the blood, the respiratory system works closely with the cardiovascular system to accomplish gas exchange (FIG. 12-1). This activity has two phases:

- External gas exchange occurs between the outside atmosphere and the blood.
- Internal gas exchange occurs between the blood and the tissues.

External exchange takes place in the **lungs**, located in the thoracic cavity. The remainder of the respiratory tract consists of a series of passageways that conduct air to and from the lungs. No gas exchange occurs in these regions. Refer to FIGURE 12-2 as you read the following description of the respiratory tract.

Upper Respiratory Passageways

The upper respiratory passageways consist of the **nose** and **pharynx** (throat). Air can also be exchanged through the mouth, but there are fewer mechanisms for cleansing the air taken in by this route.

THE NOSE

Air enters through the nose, where it is warmed, filtered, and moistened as it passes over the hair-covered mucous membranes of the nasal cavity. Cilia—microscopic hair-like projections from the cells that line the nasal passageways—sweep dirt and foreign material toward the throat for elimination. Material that is eliminated from the respiratory tract by coughing or clearing the throat is called **sputum.** Receptors for the sense of smell are located within bony side projections of the nasal cavity called **turbinate bones** or conchae.

In the bones of the skull and face near the nose are air-filled cavities lined with a mucous membrane that drain into

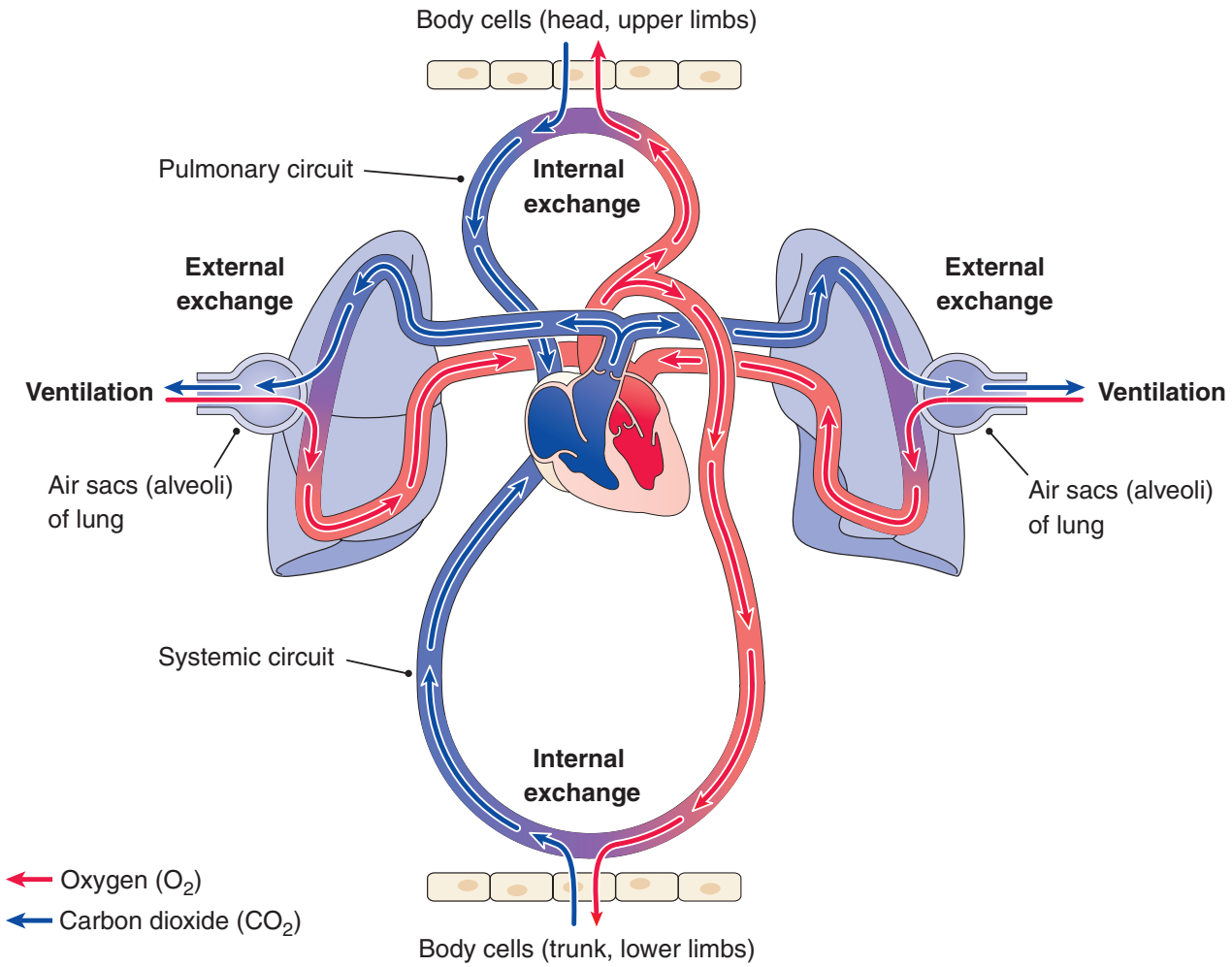

FIGURE 12-1 Respiration. In ventilation, gases are moved into and out of the lungs. In external exchange, gases move between the air sacs (alveoli) of the lungs and the blood. In internal exchange, gases move between the blood and body cells. The circulation transports gases in the blood.

extern.ir

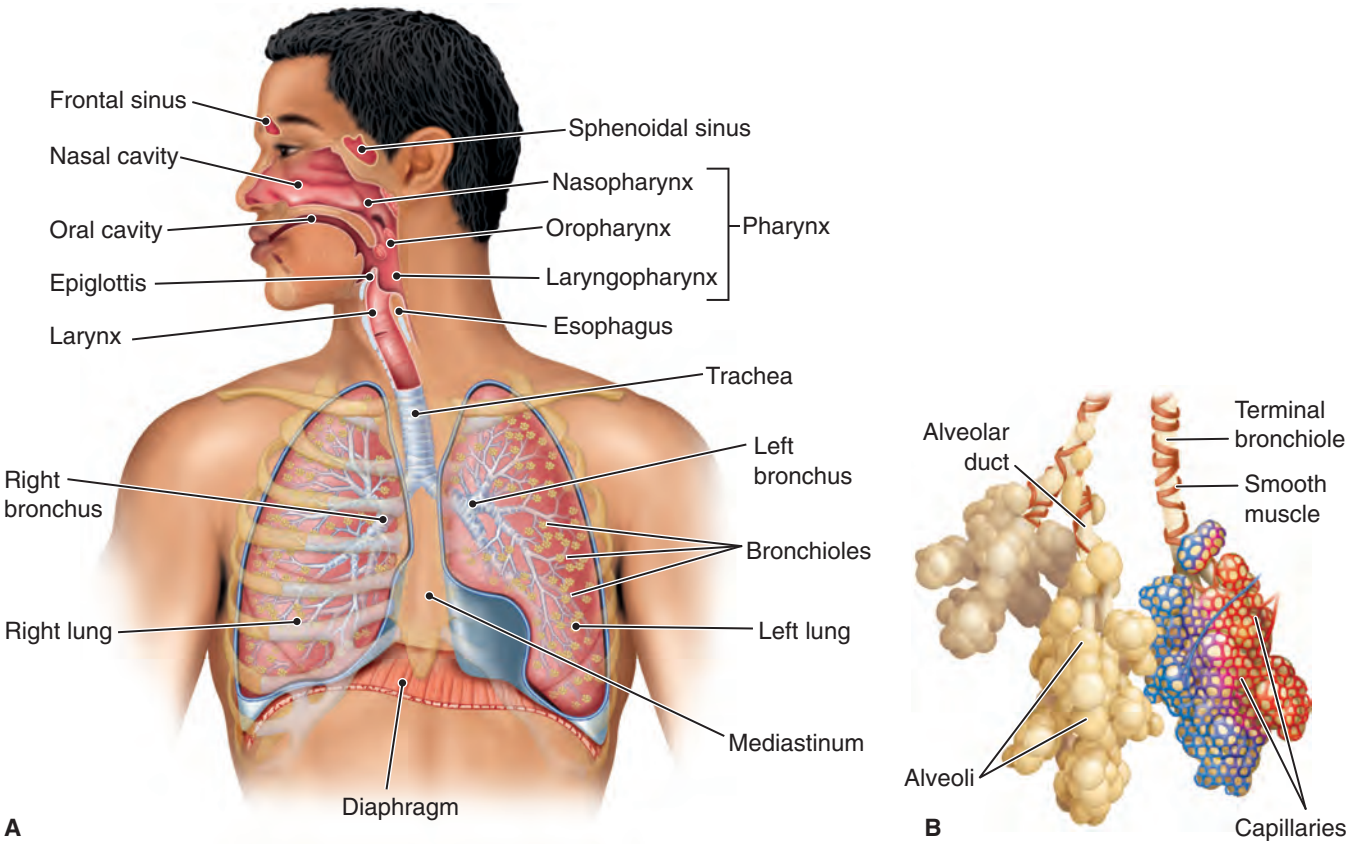

FIGURE 12-2 The respiratory system. A. Overview including some nearby structures. **B.** Enlarged section of lung tissue showing the relationship between the alveoli (air sacs) and the blood capillaries.

the nasal cavity. These chambers lighten the bones and provide resonance for speech production. These cavities, called **sinuses**, are named specifically for the bones in which they are located, such as the frontal, sphenoidal, ethmoidal, and maxillary sinuses. Together, because they are near the nose, these cavities are referred to as the paranasal sinuses. **FIGURE 12-2** shows the location of the frontal and sphenoidal sinuses.

THE PHARYNX

Inhaled air passes into the throat, or pharynx, where it mixes with air that enters through the mouth and also with food destined for the digestive tract. The pharynx is divided into three regions, which are shown in **FIGURE 12-2**:

- The nasopharynx is the superior portion located behind the nasal cavity.
- The oropharynx is the middle portion located behind the mouth.
- The laryngopharynx is the inferior portion located behind the **larynx**.

The tonsils, lymphoid tissue described in Chapter 10, are in the region of the pharynx **(FIG. 12-3)**:

- The **palatine tonsils** are on either side of the soft palate in the oropharynx.
- The single pharyngeal tonsil, commonly known as the **adenoids**, is in the nasopharynx.
- The **lingual tonsils** are small mounds of lymphoid tissue at the posterior of the tongue.

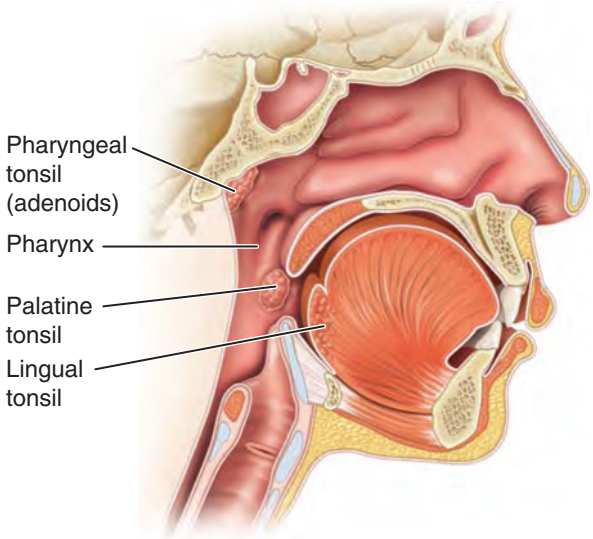

FIGURE 12-3 The tonsils. All of the tonsils are located in the vicinity of the pharynx (throat).

extern.ir

CLINICAL PERSPECTIVES

BOX 12-1

Tonsillectomy: A Procedure Reconsidered

Tonsillitis, a bacterial infection of the tonsils, is a common childhood illness. In past years, surgical removal of the infected tonsils was a standard procedure, as tonsillectomy was thought to prevent severe infections like strep throat. Because tonsils were thought to have little function, surgeons often removed infected tonsils—even healthy tonsils, in order to prevent tonsillitis later. With the discovery that tonsils play an important immune function, the number of tonsillectomies performed in the United States dropped dramatically, reaching an all-time low in the 1980s.

Today, although many cases of tonsillitis are successfully treated with appropriate antibiotics, tonsillectomy is becoming more frequent; in fact, it is the second most common surgical procedure among American children. Surgery is considered if an infection recurs or if enlarged tonsils make swallowing or breathing difficult. Many tonsillectomies are performed in children to treat obstructive sleep apnea, a condition in which the child stops breathing for a few seconds at a time during sleep. Recent studies suggest that tonsillectomy may also be beneficial for children suffering from otitis media (middle ear infection), because bacteria infecting the tonsils may travel to this region of the ear.

Most tonsillectomies are performed by electrocautery, a technique that uses an electrical current to burn the tonsils away from the throat. Now that this operation is becoming more common, surgeons are developing new techniques. For example, coblation tonsillectomy uses radio waves to break down tonsillar tissue. Studies suggest that this procedure results in a faster recovery, fewer complications, and decreased postoperative pain compared with electrocautery.

Opinions on the advisability of removing the tonsils have changed over time, as described in BOX 12-1.

Lower Respiratory Passageways and Lungs

Air moves from the pharynx into the larynx, commonly called the voice box, because it contains the **vocal folds**, or cords. The larynx is at the top of the **trachea**, commonly called the windpipe, which conducts air into the bronchial system toward the lungs.

THE LARYNX

The larynx is shaped by nine cartilages, the most prominent of which is the anterior thyroid cartilage that forms the "Adam's apple" (FIG. 12-4). The small leaf-shaped cartilage at the top of the larynx is the **epiglottis.** When one swallows, the epiglottis covers the opening of the larynx and helps prevent food from entering the respiratory tract.

The larynx contains the vocal folds, bands of tissue that are important in speech production (FIG. 12-5). Vibrations produced by air passing over the vocal folds form the basis for voice production, although portions of the throat and mouth are needed for proper speech articulation. The opening between the vocal folds is the **glottis** (the epiglottis is above the glottis).

THE TRACHEA

The trachea is a tube reinforced with C-shaped rings of cartilage to prevent its collapse (you can feel these rings if you

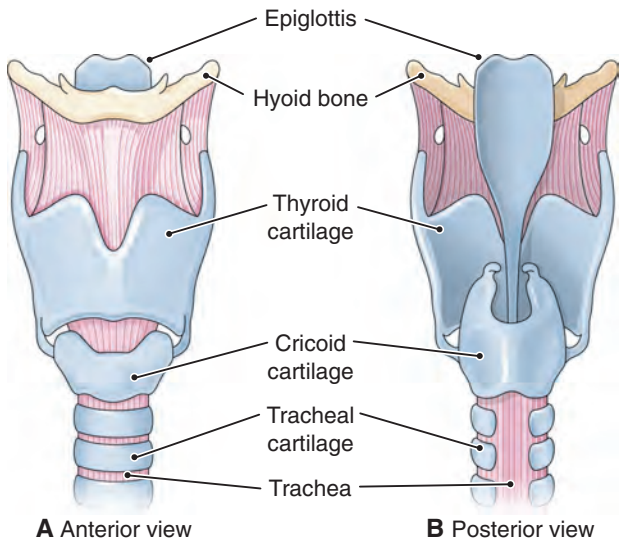

FIGURE 12-4 The larynx from anterior (A) and posterior (B) views.

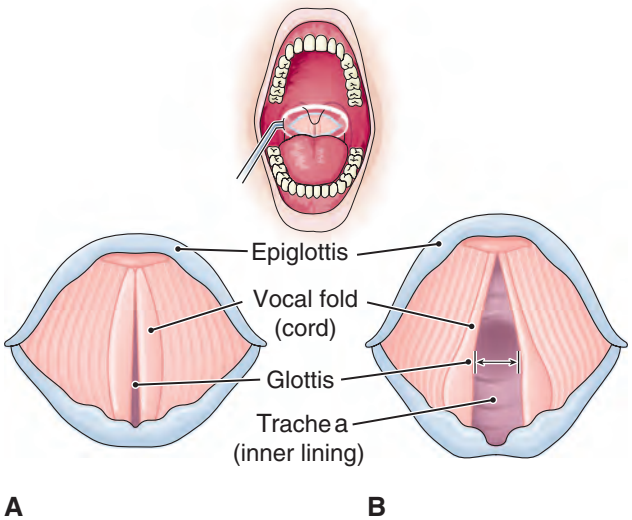

FIGURE 12-5 The vocal folds, superior view. A. The glottis in closed position. **B.** The glottis in open position.

extern.ir

press your fingers gently against the front of your throat). Cilia in the trachea's lining move impurities up toward the throat, where they can be eliminated by swallowing or by **expectoration**, coughing them up.

The trachea is contained in a region known as the **mediastinum**, which consists of the space between the lungs together with the organs contained in this space (see **FIG. 12-2**). In addition to the trachea, the mediastinum contains the heart, esophagus, large vessels, and other tissues.

THE BRONCHIAL SYSTEM

At its lower end, the trachea divides into a right and a left primary **bronchus**, which enter the lungs. The right bronchus is shorter and wider; it divides into three secondary bronchi in the right lung. The left bronchus divides into two branches that supply the left lung. Further divisions produce an increasing number of smaller tubes that supply air to smaller subdivisions of lung tissue. As the air passageways progress through the lungs, the cartilage in the walls gradually disappears and is replaced by smooth (involuntary) muscle.

The smallest of the conducting tubes, the **bronchioles**, carry air into the microscopic air sacs, the **alveoli**, through which gases are exchanged between the lungs and the blood. It is through the ultrathin walls of the alveoli and their surrounding capillaries that **oxygen** (O_2) diffuses into the blood and carbon dioxide diffuses out of the blood for elimination (see **FIG. 12-2**).

THE LUNGS

The cone-shaped lungs occupy the major portion of the thoracic cavity. The right lung is larger and divided into three lobes. The left lung, which is smaller to accommodate the heart, is divided into two lobes. The lobes are further subdivided to correspond to divisions of the bronchial network.

A double membrane, the **pleura**, covers the lungs and lines the thoracic cavity **(FIG. 12-6)**. There are two pleural layers:

- The parietal pleura, the outer layer, is attached to the wall of the thoracic cavity.
- The visceral pleura, the inner layer, is attached to the surface of the lungs.

The very narrow, fluid-filled space between the two layers is the **pleural space.** The moist pleural membranes slide easily over each other within the chest cavity, allowing the lungs to expand during breathing.

Breathing

Air is moved into and out of the lungs by the process of breathing, technically called **pulmonary ventilation.** This consists of a steady cycle of **inspiration** (inhalation) and **expiration** (exhalation), separated by a period of rest. Breathing is normally regulated unconsciously by centers in the brainstem. These centers adjust the rate and rhythm of breathing according to changes in the blood composition, especially the concentration of carbon dioxide.

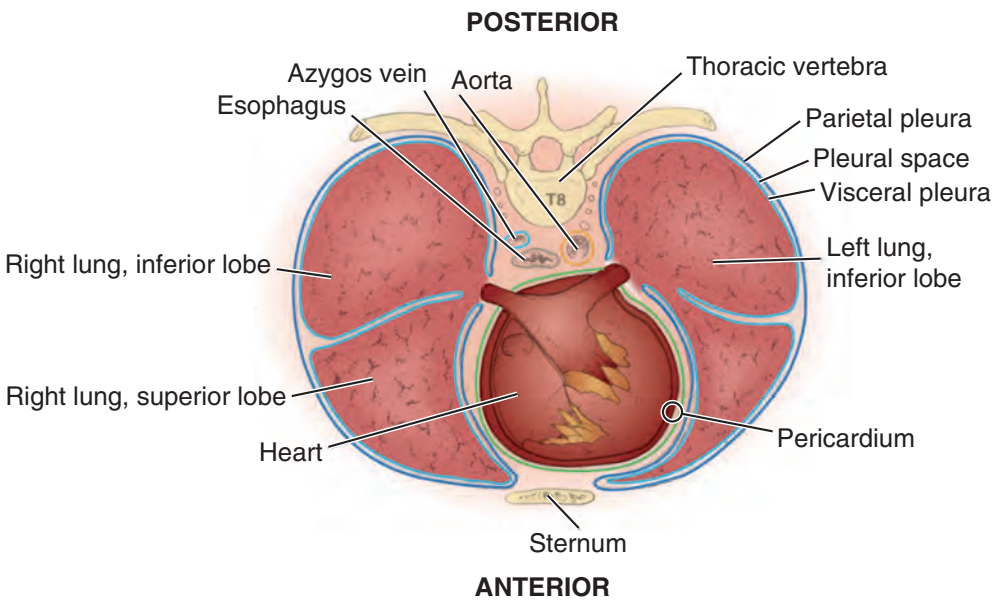

FIGURE 12-6 The pleura. A transverse section through the lungs shows the parietal and visceral layers of the pleura as well as structures in the mediastinum.

extern.ir

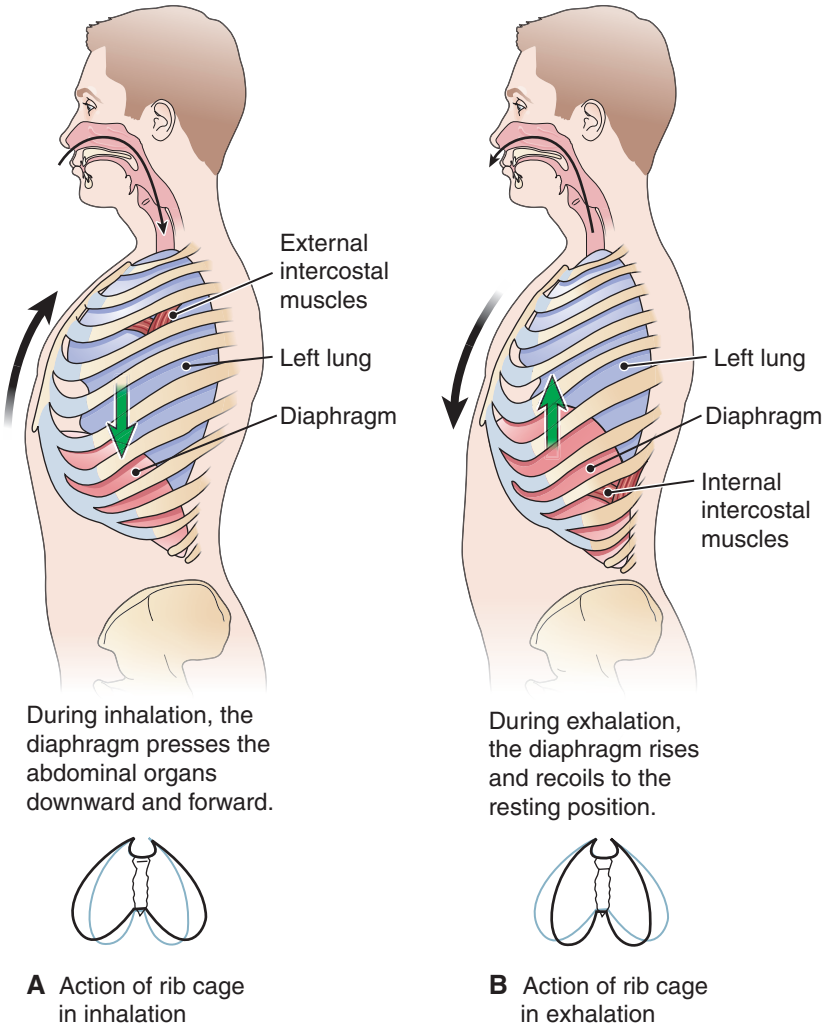

FIGURE 12-7 Pulmonary ventilation. A. In inhalation, the diaphragm lowers, and the external intercostals elevate the rib cage. **B.** In exhalation, the breathing muscles relax, the diaphragm rises, and the lungs spring back to their original size. The internal intercostals draw the ribs downward in forceful exhalation.

INSPIRATION

The breathing cycle begins when the **phrenic nerve** stimulates the **diaphragm** to contract and flatten, enlarging the chest cavity. At the same time, external intercostal muscles between the ribs elevate and expand the rib cage. A resulting decrease in pressure within the thorax causes air to flow into the lungs **(FIG. 12-7)**. Muscles of the neck and thorax are used in addition for forceful inhalation.

The measure of how easily the lungs expand under pressure is **compliance.** Fluid produced in the lungs, known as **surfactant,** aids in compliance by reducing surface tension within the alveoli.

EXPIRATION

Expiration occurs as the breathing muscles relax and the elastic lungs spring back to their original size. Increased pressure in the smaller thorax forces air out of the lungs. In forceful exhalation, the internal intercostal muscles contract to lower the rib cage, and the abdominal muscles contract, pressing internal organs upward against the diaphragm.

Gas Transport

Oxygen is carried in the blood bound to **hemoglobin** in red blood cells. The oxygen is released to the cells as needed. Carbon dioxide is carried in several ways but is mostly converted to **carbonic acid**. The amount of carbon dioxide that is exhaled is important in regulating the blood's acidity or alkalinity, based on the amount of carbonic acid that is formed. Dangerous shifts in blood pH can result from exhalation of too much or too little carbon dioxide.

extern.ir

Terminology Key Terms

The terms listed below are emphasized in this chapter. Knowing them will help you organize and prioritize your learning. These boldface terms are also found, collectively, with all chapter key terms in the Glossary.

Normal Structure and Function

adenoids *AD-eh-noyds*	Lymphoid tissue located in the nasopharynx; the pharyngeal tonsils
alveoli *al-VE-o-li*	The tiny air sacs in the lungs through which gases are exchanged between the atmosphere and the blood in respiration (singular: alveolus); an alveolus, in general, is a small hollow or cavity; the term also applies to the bony socket for a tooth
bronchiole *BRONG-ke-ole*	One of the smaller subdivisions of the bronchial tubes (root: bronchiol/o)
bronchus *BRONG-kus*	One of the larger air passageways in the lungs; the bronchi begin as two branches of the trachea and then subdivide within the lungs (plural: bronchi) (root: bronch/o)
carbon dioxide (CO_2) *KAR-bon di-OK-side*	A gas produced by energy metabolism in cells and eliminated through the lungs
carbonic acid *kar-BON-ik*	An acid formed when carbon dioxide dissolves in water; H_2CO_3
compliance *kom-PLI-ans*	A measure of how easily the lungs expand under pressure; compliance is reduced in many types of respiratory disorders
diaphragm *DI-ah-fram*	The dome-shaped muscle under the lungs that flattens during inspiration (root: phren/o)
epiglottis *ep-ih-GLOT-is*	A leaf-shaped cartilage that covers the larynx during swallowing to prevent food from entering the trachea
expectoration *ek-spek-to-RA-shun*	The act of coughing up material from the respiratory tract; also the material thus released; sputum
expiration *ek-spih-RA-shun*	The act of breathing out or expelling air from the lungs; exhalation
glottis *GLOT-is*	The opening between the vocal folds
hemoglobin *HE-mo-glo-bin*	The iron-containing pigment in red blood cells that transports oxygen
inspiration *in-spih-RA-shun*	The act of drawing air into the lungs; inhalation
larynx *LAR-inks*	The enlarged, superior portion of the trachea that contains the vocal folds (root: laryng/o)
lingual tonsils	Small mounds of lymphoid tissue at the posterior of the tongue
lung	A cone-shaped, spongy respiratory organ contained within the thorax (roots: pneum/o, pulm/o)
mediastinum *me-de-as-TI-num*	The space between the lungs together with the organs contained in this space
nose	The organ of the face used for breathing and housing receptors for the sense of smell; includes an external portion and an internal nasal cavity (roots: nas/o, rhin/o)
oxygen (O_2) *OK-sih-jen*	The gas needed by cells to release energy from food during metabolism
palatine tonsils *PAL-ah-tine*	The paired masses of lymphoid tissue located on either side of the oropharynx; usually meant when the term tonsils is used alone

(continued)

extern.ir

Terminology — Key Terms (Continued)

pharynx *FAR-inks*	The throat; a common passageway for food entering the esophagus and air entering the larynx (root: pharyng/o)
phrenic nerve *FREN-ik*	The nerve that activates the diaphragm (root: phrenic/o)
pleura *PLURE-ah*	A double-layered membrane that lines the thoracic cavity (parietal pleura) and covers the lungs (visceral pleura) (root: pleur/o)
pleural space	The thin, fluid-filled space between the two layers of the pleura; pleural cavity
pulmonary ventilation *PUL-mo-nare-e ven-tih-LA-shun*	The movement of air into and out of the lungs
sinus *SI-nus*	A cavity or channel; the paranasal sinuses are located near the nose and drain into the nasal cavity
sputum *SPU-tum*	The substance released by coughing or clearing the throat; expectoration; it may contain a variety of materials from the respiratory tract
surfactant *sur-FAK-tant*	A substance that decreases surface tension within the alveoli and eases lung expansion
trachea *TRA-ke-ah*	The air passageway that extends from the larynx to the bronchi (root: trache/o)
turbinate bones *TUR-bih-nate*	The bony projections in the nasal cavity that contain receptors for the sense of smell; also called conchae (*KON-ke*) (singular: concha [*KON-kah*])
vocal folds *VO-kal*	Membranous folds on either side of the larynx that are important in speech production; also called vocal cords

Word Parts Pertaining to the Respiratory System

See **TABLES 12-1** to **12-3.**

Table 12-1 Suffixes for Respiration

Suffix	Meaning	Example	Definition of Example
-pnea	breathing	dyspnea *disp-NE-ah*	shortness of breath; painful or difficult breathing
-oxia[a]	level of oxygen	hypoxia *hi-POK-se-ah*	decreased amount of oxygen in the tissues
-capnia[a]	level of carbon dioxide	hypocapnia *hi-po-KAP-ne-ah*	decreased carbon dioxide in the tissues
-phonia	voice	aphonia *ah-FO-ne-ah*	loss of voice

[a]When referring to levels of oxygen and carbon dioxide in the blood, the suffix *-emia* is used as in hypoxemia, hypercapnemia.

extern.ir

Exercise 12-1

Complete the exercise. To check your answers go to Appendix 11.

Use the suffix *-pnea* to form words with the following meanings.

1. breathing difficulty that is relieved by assuming an upright position (ortho) _____
2. slow (brady-) rate of breathing _____
3. easy, normal (eu-) breathing _____
4. painful or difficult breathing _____

Use the ending *-pneic* to write the adjective form of the above words.

5. _____
6. _____
7. _____
8. _____

Use the suffixes in **TABLE 12-1** to write a word for each of the following definitions.

9. difficulty speaking _____
10. decreased carbon dioxide in the tissues _____
11. lack of (an-) oxygen in the tissues _____
12. increased levels of carbon dioxide in the tissues _____

Table 12-2 Roots for the Respiratory Passageways

Root	Meaning	Example	Definition of Example
nas/o	nose	intranasal *in-trah-NA-zal*	within the nose
rhin/o	nose	rhinoplasty *RI-no-plas-te*	plastic repair of the nose
pharyng/o[a]	pharynx	pharyngeal *fah-RIN-je-al*	pertaining to the pharynx
laryng/o[a]	larynx	laryngospasm *lah-RIN-go-spazm*	spasm (sudden contraction) of the larynx
trache/o	trachea	tracheotome *TRA-ke-o-tome*	instrument used to incise the trachea
bronch/o, bronch/i	bronchus	bronchogenic *brong-ko-GEN-ik*	originating in a bronchus
bronchiol	bronchiole	bronchiolectasis *brong-ke-o-LEK-tah-sis*	dilatation of the bronchioles

[a]An *e* is added to the root before the adjective ending *-al*.

Exercise 12-2

Complete the exercise. To check your answers go to Appendix 11.

Write words for the following definitions.

1. discharge from the nose _____
2. pertaining to the larynx (see *pharynx* in **TABLE 12-2**) _____
3. inflammation of the bronchi _____

(continued)

extern.ir

Exercise 12-2 *(Continued)*

4. endoscopic examination of the pharynx _____
5. plastic repair of the larynx _____
6. surgical incision of the trachea _____
7. narrowing of a trachea _____
8. inflammation of the bronchioles _____

Define the following words (note the adjectival endings).

9. bronchiolar (*brong-KE-o-lar*) _____
10. paranasal (*par-ah-NA-zal*) _____
11. peribronchial (*per-ih-BRONG-ke-al*) _____
12. endotracheal (*en-do-TRA-ke-al*) _____
13. nasopharyngeal (*na-zo-fah-RIN-je-al*) _____
14. bronchiectasis (*brong-ke-EK-tah-sis*) _____

Table 12-3 Roots for the Lungs and Breathing

Root	Meaning	Example	Definition of Example
phren/o	diaphragm	phrenic *FREN-ik*	pertaining to the diaphragm
phrenic/o	phrenic nerve	phrenicectomy *fren-ih-SEK-to-me*	partial excision of the phrenic nerve
pleur/o	pleura	pleurodesis *plu-ROD-eh-sis*	fusion of the pleura
pulm/o, pulmon/o	lung	extrapulmonary *EKS-trah-pul-mo-nar-e*	outside the lungs
pneumon/o	lung	pneumonitis *nu-mo-NI-tis*	inflammation of the lung; pneumonia
pneum/o, pneumat/o	air, gas; also respiration, lung	pneumothorax *nu-mo-THO-raks*	presence of air in the thorax (pleural space)
spir/o	breathing	spirometer *spi-ROM-eh-ter*	instrument for measuring breathing volumes

Exercise 12-3

Complete the exercise. To check your answers go to Appendix 11.

Define the following words.

1. pleuralgia (*plu-RAL-je-ah*) _____
2. intrapulmonary (*in-trah-PUL-mo-ner-e*) _____
3. pneumonectomy (*nu-mo-NEK-to-me*) _____
4. pneumoplasty (*NU-mo-plas-te*) _____
5. pulmonology (*pul-mo-NOL-o-je*) _____
6. apneumia (*ap-NU-me-ah*) _____
7. phrenicotomy (*fren-ih-KOT-o-me*) _____

extern.ir

Exercise 12-3 *(Continued)*

Write words for the following definitions.

8. within the pleura _____
9. above the diaphragm _____
10. surgical puncture of the pleural space _____
11. any disease of the lungs (pneumon/o) _____
12. crushing of the phrenic nerve _____
13. record of breathing volumes _____

Clinical Aspects of the Respiratory System

Any disorder that causes resistance to airflow through the respiratory tract or that limits chest expansion will affect pulmonary function. These disorders may involve the respiratory system directly, such as infection, injury, allergy, **aspiration** (inhalation) of foreign bodies, or cancer; they may also originate in other systems, such as in the skeletal, muscular, cardiovascular, or nervous systems.

As noted above, changes in ventilation can affect the blood's pH (acidity or alkalinity). If too much carbon dioxide is exhaled by **hyperventilation**, the blood tends to become too alkaline, a condition termed **alkalosis.** If too little carbon dioxide is exhaled as a result of **hypoventilation**, the blood tends to become too acidic, a condition termed **acidosis**.

INFECTIONS

A variety of organisms infect the respiratory system. For your reference, some of these organisms are listed along with the diseases they cause in **BOX 12-2**. Childhood immunizations have dramatically reduced the incidence of some infectious respiratory diseases, such as **diphtheria** and **pertussis** (the "D"

FOR YOUR REFERENCE — BOX 12-2
Organisms That Infect the Respiratory System

Organism	Disease
BACTERIA	
Streptococcus pneumoniae *strep-to-KOK-us nu-MO-ne-e*	Most common cause of pneumonia; streptococcal pneumonia
Haemophilus influenzae *he-MOF-ih-lus in-flu-EN-ze*	Pneumonia, especially in debilitated patients
Klebsiella pneumoniae *kleb-se-EL-ah nu-MO-ne-e*	Pneumonia in elderly and debilitated patients
Mycoplasma pneumoniae *mi-ko-PLAZ-mah nu-MO-ne-e*	Mild pneumonia, usually in young adults and children; "walking pneumonia"
Legionella pneumophila *le-juh-NEL-lah nu-MOH-fih-lah*	Legionellosis (Legionnaire disease); respiratory disease spread through water sources, such as air conditioners, pools, humidifiers
Chlamydia psittaci *klah-MID-e-ah SIH-tah-se*	Psittacosis (ornithosis); carried by birds
Streptococcus pyogenes *strep-to-KOK-us pi-OJ-eh-neze*	"Strep throat," scarlet fever
Mycobacterium tuberculosis *mi-ko-bak-TE-re-e-um tu-ber-ku-LO-sis*	Tuberculosis
Bordetella pertussis *bor-deh-TEL-ah per-TUS-sis*	Pertussis (whooping cough)

(continued)

extern.ir

FOR YOUR REFERENCE *(Continued)*

BOX 12-2

Organisms That Infect the Respiratory System

Organism	Disease
Corynebacterium diphtheriae *ko-RI-ne-bak-te-re-e-um dif-THE-re-e*	Diphtheria
VIRUSES	
Rhinoviruses *RI-no-vi-rus-es*	Major cause of common cold; also caused by coronaviruses, adenoviruses, and others
Influenzavirus *in-flu-EN-zah-vi-rus*	Influenza
Respiratory syncytial virus (RSV) *sin-SISH-al*	Common cause of respiratory disease in infants
SARS coronavirus *ko-RO-nah-vi-rus*	Severe acute respiratory syndrome; highly infectious disease that appeared in 2003 and spreads from small mammals to humans
Hantavirus *HAN-tah-vi-rus*	Hantavirus pulmonary syndrome (HPS); spread by inhalation of virus released from dried rodent droppings
FUNGI	
Histoplasma capsulatum *his-to-PLAS-mahkap-su-LATE-um*	Histoplasmosis; spread by airborne spores
Coccidioides immitis *kok-sid-e-OY-deze IM-ih-tis*	Coccidioidomycosis (valley fever, San Joaquin fever); found in dry, alkaline soils
Blastomyces dermatitidis *blas-to-MI-seze der-mah-TIT-ih-dis*	Blastomycosis; rare but often fatal fungal disease
Pneumocystis jirovecii (formerly carinii) *nu-mo-SIS-tis jir-o-VEH-se*	*Pneumocystis* pneumonia (PCP); seen in immunocompromised hosts

and "P" in the DTaP vaccine; the "T" is for tetanus). Selected infectious diseases are described in greater detail below.

Pneumonia

Pneumonia is caused by many different microorganisms, usually bacteria or viruses. Bacterial agents are most commonly *Streptococcus pneumoniae* and *Klebsiella pneumoniae*. Viral pneumonia is more diffuse and is commonly caused by influenza virus and adenovirus. There are two forms of pneumonia **(FIG. 12-8)**:

- Lobar pneumonia, an acute disease, involves one or more lobes of the lung.
- Bronchopneumonia (bronchial pneumonia) occurs throughout the lung. It begins in terminal bronchioles that become clogged with exudate and form consolidated (solidified) patches.

Pneumonia can usually be treated successfully in otherwise healthy people, but in debilitated patients, it is a

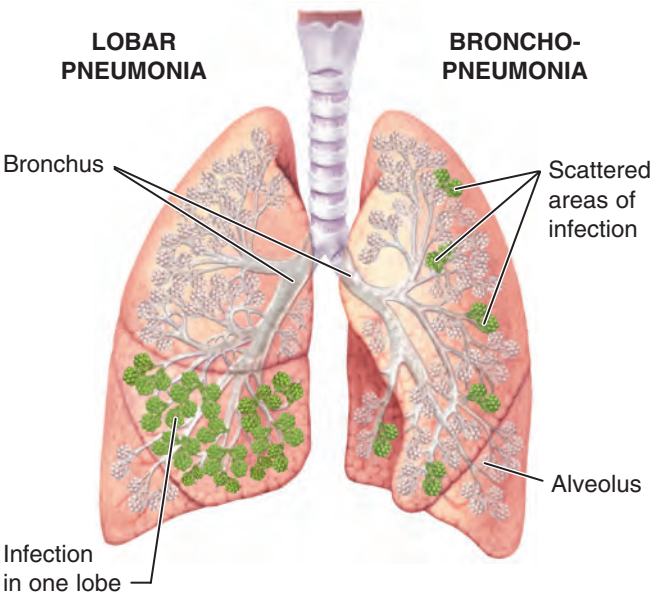

FIGURE 12-8 Pneumonia. In lobar pneumonia (right lung), an entire lobe is consolidated. In bronchopneumonia (left lung), patchy areas of consolidation occur throughout the lung.

extern.ir

leading cause of death. Immunocompromised patients, such as those with AIDS, are often subject to a form of fungal pneumonia called *Pneumocystis* pneumonia (PCP).

The term *pneumonia* is also applied to noninfectious lung inflammation, such as that caused by asthma, allergy, or inhalation of irritants. In these cases, however, the more general term **pneumonitis** is often used.

Respiratory Syncytial Virus

Respiratory syncytial virus (RSV) is the most common cause of lower respiratory tract infections in infants and young children worldwide. The name comes from the fact that the virus induces fusion of cultured cells (formation of a syncytium) when grown in the laboratory. Infection may result in bronchiolitis or pneumonia, but the virus may affect the upper respiratory tract as well. Most susceptible are premature infants, those with congenital heart disease, and those who are immunodeficient. Exposure to cigarette smoke is a definite risk factor.

The virus usually enters through the eyes and nose following contact with contaminated air, nasal secretions, or objects. The incubation period is 3 to 5 days, and an infected person sheds virus particles during the incubation period and up to 2 weeks thereafter. Infection usually resolves in 5 to 7 days, although some cases require hospitalization and antiviral drug treatments.

Tuberculosis

The incidence of **tuberculosis** (**TB**) has increased in recent years, along with the increase of AIDS and the appearance of antibiotic resistance in the causative organism, *Mycobacterium tuberculosis* (MTB). (This organism, because of its staining properties, is also referred to as AFB, meaning *acid-fast bacillus*.) The name *tuberculosis* comes from the small lesions, or tubercles, that characterize the infection. The tubercles can liquefy in the center and then rupture to release bacteria into the bloodstream. Generalized TB is known as *miliary tuberculosis* because of the many tubercles that are the size of millet seeds in infected tissue **(FIG. 12-9)**.

TB symptoms include fever, weight loss, weakness, cough, and **hemoptysis**, the coughing up of blood-containing sputum. Accumulation of exudate in the alveoli may result in consolidation of lung tissue. Active TB is diagnosed by chest x-ray and laboratory culture of sputum samples to isolate, stain, and identify any causative organisms. If found, the organisms can be tested for drug susceptibility. These laboratory studies can take up to 8 weeks, as the TB organism is very slow growing, so clinicians also use several quick tests to identify tuberculosis infections. These include:

- The **tuberculin test**, a skin test, also known as a Mantoux (*man-TOO*) test. The test material, tuberculin, is made from byproducts of the tuberculosis organism. PPD (purified protein derivative) is the form of tuberculin commonly used. In 48 to 72 hours after tuberculin is injected below the skin, a hard, raised lump appears if a person has been infected with the TB organism. This test does not distinguish active from inactive cases.
- IGRA, a rapid blood test to diagnose TB. This is an immunologic test with the full name interferon-gamma release assay. It is used to confirm results of a negative skin test in people at high risk of having TB.
- NAA, a sputum test that can confirm a positive TB diagnosis within 24 hours. The full name is nucleic acid amplification test.

BCG vaccine is used worldwide to help to prevent TB; it is not used routinely in the United States because the incidence of TB in this country is relatively low and also because it invalidates the tuberculin test. The bacillus (B) used for the vaccine is named for Calmette (C) and Guérin (G), discoverers of this avirulent mycobacterium strain.

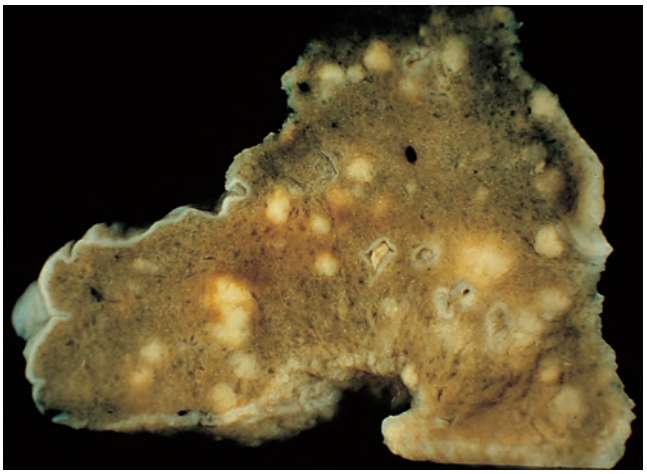

FIGURE 12-9 Tuberculosis. The cut surface of the lung reveals numerous white nodules in miliary (generalized) tuberculosis.

Influenza

Influenza ("flu") is a viral respiratory disease associated with chills, fever, headaches, muscular aches, and cold-like symptoms. It usually resolves in several days, but severe forms of influenza have caused fatal pandemics, most recently in 1918, 1957, and 1968. The virus can mutate readily and spread among animals, such as birds or pigs, and humans.

Because influenza viruses change so rapidly, scientists must prepare vaccines against the strains most likely to cause an epidemic in any given year. The virus strains are grouped into categories A to C, with A the most severe and C the least. They are further designated H and N with numbers, such as H3N2 and H5N1. The "H" and "N" represent surface proteins that the virus uses to infect a host.

Medical personnel combat influenza with vaccines, isolation of infected populations, destruction of infected animals, and antiviral medications.

Croup

Croup usually affects children under 3 years of age and is associated with a number of different infections that result in upper respiratory inflammation. Airway constriction produces a loud, barking cough, wheezing, difficulty in breathing, and hoarseness. If croup is severe, the child may produce a harsh, squeaking noise (stridor) when breathing in through a narrowed trachea. Viral infections, such as those involving parainfluenza, adenovirus, RSV, influenza, or measles, are

extern.ir

FOCUS ON WORDS
Don't Breathe a Word

BOX 12-3

Some lay terms for respiratory symptoms and conditions are so old fashioned and quaint that you might see them today only in Victorian novels. Catarrh (*kah-TAR*) is an old word for an upper respiratory infection with much mucus production. Quinsy (*KWIN-ze*) referred to a sore throat or tonsillar abscess. Consumption was tuberculosis, and dropsy referred to generalized edema. The grippe (*grip*) meant influenza, which we more often abbreviate as "flu."

Some unscientific words are still in use. These include whooping cough for pertussis, croup for laryngeal spasm, cold sore or fever blister for a herpes lesion, and phlegm for sputum.

Many people use informal terms instead of scientific words to describe their symptoms. Health professionals should be familiar with the slang or colloquialisms that patients might use so that they can better communicate with them.

usually the cause. Although croup may be frightening to parents and children, recovery is complete in most cases within a week. However, medical treatment is warranted if the child's respiratory rate is very high and if the ribs become visible with each inhalation. Home treatments include humidifying room air or having the child breathe in steam. Also, cool air may shrink the respiratory tissues enough to bring relief. Medical interventions usually involve the administration of corticosteroids and bronchodilators.

Common Cold

More than 200 viruses are known to cause the common cold. About one half of these are rhinoviruses, and the others include adenoviruses and coronaviruses. The symptoms, known to all, are sneezing; **acute rhinitis**, which is inflammation of the nasal passageways with copious secretion of watery mucus; tearing of the eyes; and congestion. The infection may spread from the nose and throat to the sinuses, middle ear, and lower respiratory tract.

Cold viruses are mostly spread by airborne virus-filled droplets released by an infected person's coughs and sneezes. Frequent hand washing and not touching one's hands to any part of the face are good preventive measures.

The disorder usually resolves in about a week. Because colds are caused by viruses, antibiotics do not cure them. Rest, fluid intake, symptomatic treatment, and time work best. The large variety of cold viruses and their frequent mutation have prevented the development of an effective vaccine.

BOX 12-3 has some history on terminology related to respiratory infections and other disorders.

EMPHYSEMA

Emphysema is a chronic disease associated with overexpansion and destruction of the alveoli **(FIG. 12-10A)**. Common causes are exposure to cigarette smoke and other forms of pollution as well as chronic infection. Emphysema is the main disorder included under the heading of **chronic**

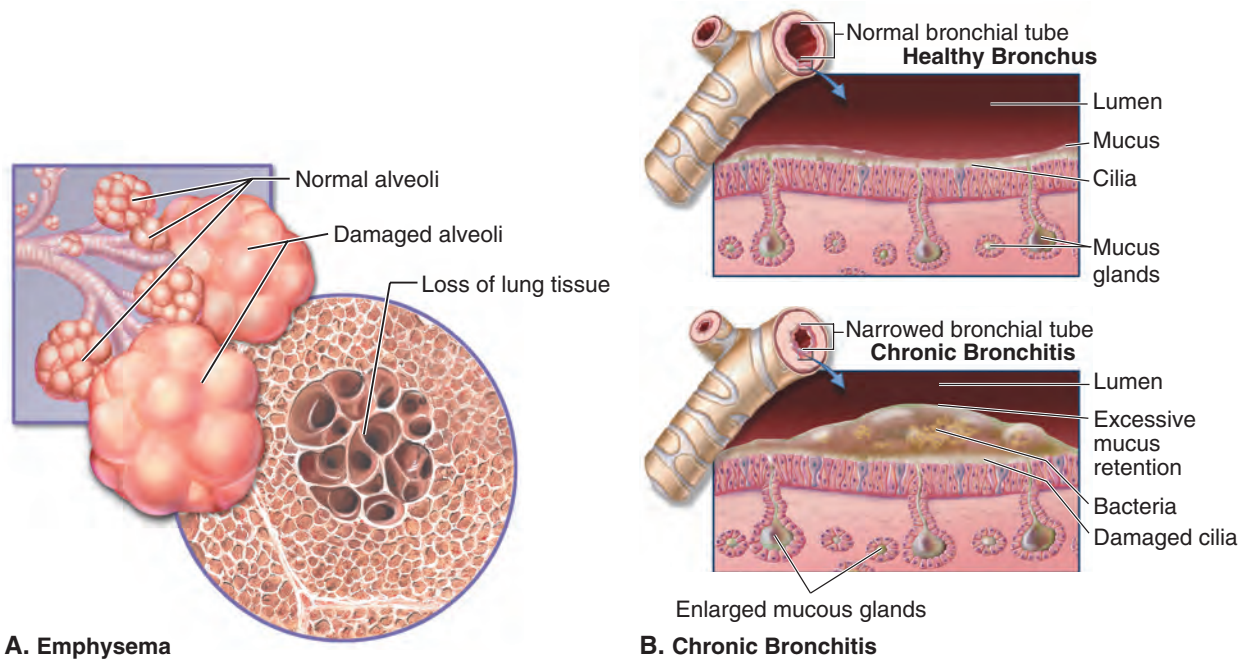

FIGURE 12-10 Types of chronic obstructive pulmonary disease (COPD). A. Emphysema results in dilation and destruction of alveoli. **B.** Chronic bronchitis involves airway inflammation, damage to cilia, and excess mucus secretion.

extern.ir

obstructive pulmonary disease (**COPD**). Other conditions included in this category are **asthma**, **bronchiectasis**, and chronic **bronchitis** (FIG. 12-10B).

ASTHMA

Asthma attacks result from narrowing of the bronchial tubes. This constriction, along with edema (swelling) of the bronchial linings, inflammation, and mucus accumulation, results in wheezing, extreme **dyspnea** (difficulty in breathing), and **cyanosis**.

Asthma is most common in children. Although its causes are uncertain, a main factor is irritation caused by allergy. Heredity may also play a role. Treatment of asthma includes:

- removal of allergens
- administration of bronchodilators to widen the airways
- administration of corticosteroids to reduce inflammation

PNEUMOCONIOSIS

Chronic irritation and inflammation caused by dust inhalation is termed **pneumoconiosis**. This is an occupational hazard seen mainly in people working in mining and stone-working industries. Different forms of pneumoconiosis are named for the specific type of dust inhaled: silicosis (silica or quartz), anthracosis (coal dust), asbestosis (asbestos fibers).

Although the term *pneumoconiosis* is limited to conditions caused by inhalation of inorganic dust, lung irritation may also result from inhalation of organic dusts, such as textile or grain dusts.

LUNG CANCER

Lung cancer is the leading cause of cancer-related deaths in both men and women. The incidence of lung cancer has increased steadily over the past 50 years, especially in women. Cigarette smoking is a major risk factor in this as well as other types of cancer. The most common form of lung cancer is squamous carcinoma, originating in the lining of the bronchi (bronchogenic). Lung cancer usually cannot be detected early, and it metastasizes rapidly. The overall long-term survival rate is low.

Methods used to diagnose lung cancer include radiographic studies, computed tomography (CT) scans, and sputum examination for cancer cells. Physicians can use a **bronchoscope** to examine the airways and to collect tissue samples for study. They may also take samples by surgical or needle biopsies.

RESPIRATORY DISTRESS SYNDROME

Respiratory distress syndrome (**RDS**) of the newborn occurs in premature infants and is the most common cause of death in this group. It results from a lack of lung surfactant, which reduces compliance. **Acute respiratory distress syndrome** (**ARDS**), also known as *shock lung*, may result from trauma, allergic reactions, infection, and other causes. It involves edema that can lead to respiratory failure and death if untreated.

CYSTIC FIBROSIS

Cystic fibrosis (**CF**) is the most common fatal hereditary disease among white children. The flawed gene that causes CF affects glandular secretions by altering chloride transport across cell membranes. Thickening of bronchial secretions leads to infection and other respiratory disorders. Other mucus-secreting glands, sweat glands, and the pancreas are also involved, causing electrolyte imbalance and digestive disturbances.

CF is diagnosed by the increased amounts of sodium and chloride in the sweat. Geneticists also can identify the gene that causes CF by DNA analysis. There is no cure at present for CF. Patients are treated to relieve their symptoms, by postural drainage, aerosol mists, bronchodilators, antibiotics, and mucolytic (mucus-dissolving) agents.

SUDDEN INFANT DEATH SYNDROME

Sudden infant death syndrome (**SIDS**), also called "crib death," is the unexplained death of a seemingly healthy infant under 1 year of age. Death usually occurs during sleep, leaving no signs of its cause. Neither autopsy nor careful investigation of family history and circumstances of death provides any clues.

Certain maternal conditions during pregnancy are associated with an increased risk of SIDS, although none is a sure predictor. These include cigarette smoking, age under 20, low weight gain, anemia, illegal drug use, and reproductive or urinary tract infections.

Some practices that have reduced the incidence of SIDS are:

- Place the baby on his or her back (supine) for sleep ("back to sleep").
- Keep the baby in a smoke-free environment.
- Use a firm, flat baby mattress.
- Don't overheat the baby.

PLEURAL DISORDERS

Pleurisy, also called pleuritis, is an inflammation of the pleura, usually associated with infection. Pain is the common symptom of pleurisy. Because this pain is intensified by breathing or coughing as the inflamed membranes move, breathing becomes rapid and shallow. Analgesics and anti-inflammatory drugs are used to treat the symptoms of pleurisy.

As a result of injury, infection, or weakness in the pleural membrane, substances may accumulate between the layers of the pleura. When air or gas collects in this space, the condition is termed **pneumothorax** (FIG. 12-11). Compression may cause collapse of the lung, termed **atelectasis**.

extern.ir

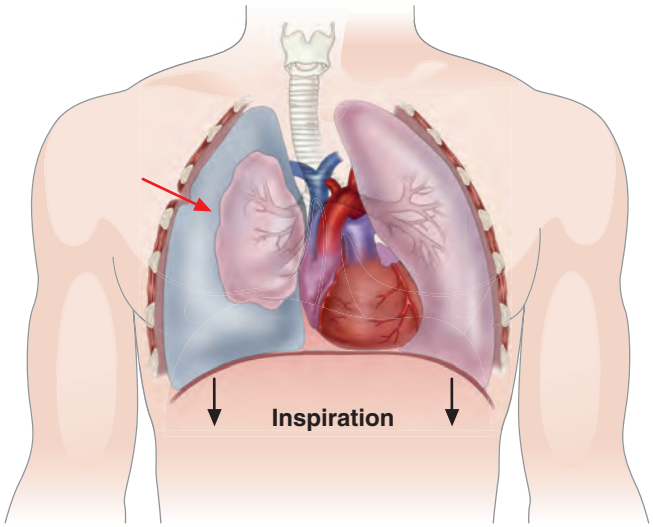

FIGURE 12-11 Pneumothorax. Injury to the chest wall or lung tissue allows air to leak into the pleural space (*red arrow*) and put pressure on the lung. This may result in partial or complete collapse of the lung.

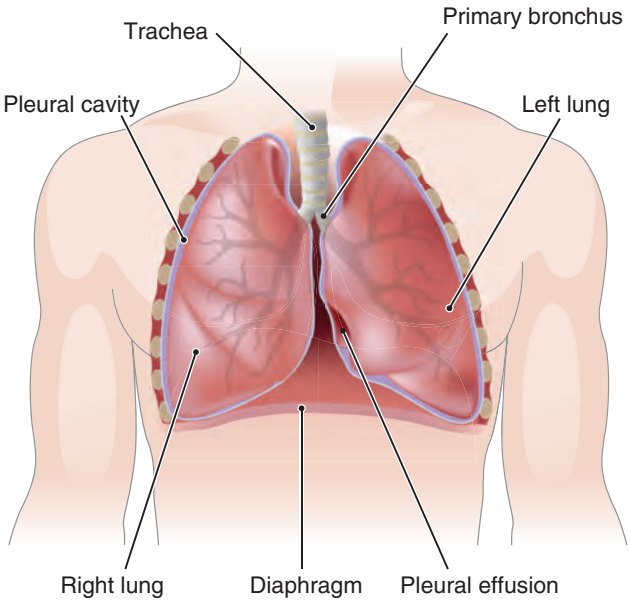

FIGURE 12-12 Pleural effusion. An abnormal volume of fluid collects in the pleural space.

In **pleural effusion,** other materials accumulate in the pleural space (FIG. 12-12). Depending on the substance involved, these are described as **empyema** (pus), also termed **pyothorax; hemothorax** (blood); or **hydrothorax** (fluid). Causes of these conditions include injury, infection, heart failure, and pulmonary embolism. **Thoracentesis,** needle puncture of the chest to remove fluids (FIG. 12-13), or fusion of the pleural membranes (pleurodesis) may be required. A chest tube may be inserted to remove air and fluid from the pleural space.

DIAGNOSIS OF RESPIRATORY DISORDERS

In addition to chest radiographs, CT scans, and magnetic resonance imaging (MRI) scans, methods for diagnosing respiratory disorders include **lung scans,** bronchoscopy, and tests of pleural fluid removed by thoracentesis. **Arterial blood gases** (ABGs) are used to evaluate gas exchange in the lungs by measuring carbon dioxide, oxygen, bicarbonate, and pH in an arterial blood sample. **Pulse oximetry** is routinely used to measure the oxygen saturation of arterial blood by means of an oximeter, a simple device placed on a thin part of the body, usually the finger or the ear (FIG. 12-14).

Pulmonary function tests are used to assess breathing, usually by means of a **spirometer.** They measure the volumes of air that can be moved into or out of the lungs with different degrees of effort. Often used to monitor treatment in cases of allergy, asthma, emphysema, and other respiratory conditions, they are also used to measure progress in smoking cessation. The main volumes and capacities measured in these tests are summarized in BOX 12-4 and illustrated in FIGURE 12-15. A capacity is the sum of two or more volumes.

See BOX 12-5 for information on respiratory therapists, who perform many of these tests.

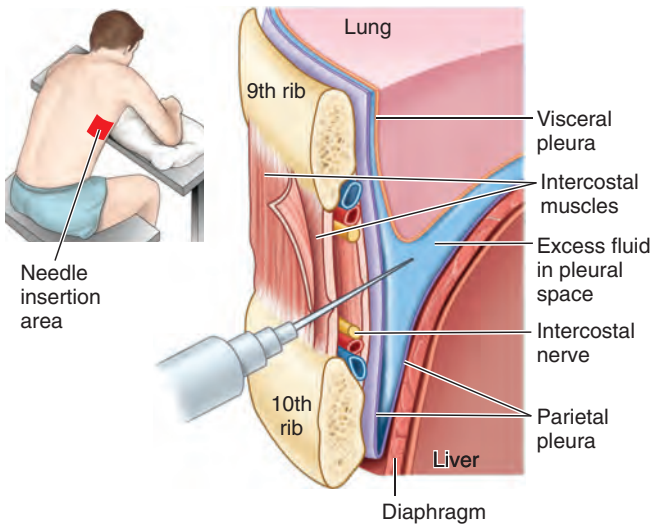

FIGURE 12-13 Thoracentesis. A needle is inserted into the pleural space to withdraw fluid.

FIGURE 12-14 Pulse oximetry. The oximeter measures the oxygen saturation of arterial blood.

extern.ir

FOR YOUR REFERENCE

BOX 12-4

Volumes and Capacities (Sums of Volumes) Used in Pulmonary Function Tests

Volume or Capacity	Definition
tidal volume (TV)	amount of air breathed into or out of the lungs in quiet, relaxed breathing
residual volume (RV)	amount of air that remains in the lungs after maximum exhalation
expiratory reserve volume (ERV)	amount of air that can be exhaled after a normal exhalation
inspiratory reserve volume (IRV)	amount of air that can be inhaled above a normal inspiration
total lung capacity (TLC)	total amount of air that can be contained in the lungs after maximum inhalation
inspiratory capacity (IC)	amount of air that can be inhaled after normal exhalation
vital capacity (VC)	amount of air that can be expelled from the lungs by maximum exhalation after maximum inhalation
functional residual capacity (FRC)	amount of air remaining in the lungs after normal exhalation
forced expiratory volume (FEV)	volume of gas exhaled with maximum force within a given interval of time; the time interval is shown as a subscript, such as FEV_1 (1 second) and FEV_3 (3 seconds)
forced vital capacity (FVC)	the volume of gas exhaled as rapidly and completely as possible after a complete inhalation

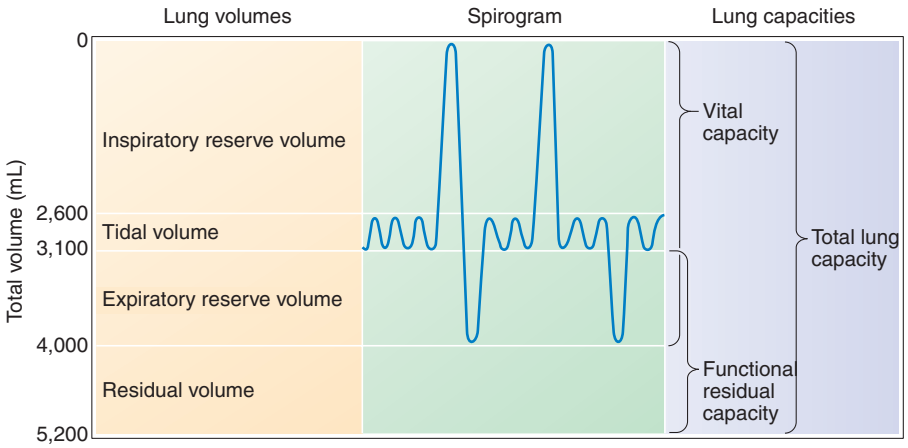

FIGURE 12-15 A spirogram. A spirometer produces a tracing of lung volumes and capacities (sums of volumes).

HEALTH PROFESSIONS

BOX 12-5

Careers in Respiratory Therapy

Respiratory therapists and respiratory therapy technicians specialize in evaluating and treating breathing disorders. Respiratory therapists evaluate the severity of their patients' conditions by taking complete histories and testing respiratory function with specialized equipment. Based on their findings, and in consultation with a physician, therapists design and implement individualized treatment plans, which may include oxygen therapy and chest physiotherapy. They also educate patients on the use of ventilators and other medical devices. Respiratory therapy technicians assist in carrying out evaluations and treatments.

To perform their duties, both types of practitioners need a thorough scientific background. Most respiratory therapists in the United States receive their training from an accredited college or university and take a national licensing exam. Respiratory therapists and technicians work in a variety of settings, such as hospitals, nursing-care facilities, and private clinics. For additional information about careers in respiratory therapy, visit the American Association for Respiratory Care at aarc.org.

extern.ir

Terminology Key Terms

The terms listed below are emphasized in this chapter. Knowing them will help you organize and prioritize your learning. These boldface terms are also found, collectively, with all chapter key terms in the Glossary.

Disorders

acidosis *as-ih-DO-sis*	Abnormal acidity of body fluids; respiratory acidosis is caused by abnormally high carbon dioxide levels
acute respiratory distress syndrome (ARDS)	Pulmonary edema that can lead rapidly to fatal respiratory failure; causes include trauma, aspiration into the lungs, viral pneumonia, and drug reactions; shock lung
acute rhinitis *ri-NI-tis*	Inflammation of the nasal mucosa with sneezing, tearing, and profuse secretion of watery mucus, as seen in the common cold
alkalosis *al-kah-LO-sis*	Abnormal alkalinity of body fluids; respiratory alkalosis is caused by abnormally low carbon dioxide levels
aspiration *as-pih-RA-shun*	The accidental inhalation of food or other foreign material into the lungs; also means the withdrawal of fluid from a cavity by suction
asthma *AZ-mah*	A disease characterized by dyspnea and wheezing caused by spasm of the bronchial tubes or swelling of their mucous membranes
atelectasis *at-eh-LEK-tah-sis*	Incomplete expansion of a lung or part of a lung; lung collapse; may be present at birth (as in respiratory distress syndrome) or may be caused by bronchial obstruction or compression of lung tissue (prefix atel/o means "imperfect")
bronchiectasis *brong-ke-EK-tah-sis*	Chronic dilatation of a bronchus or bronchi
bronchitis *brong-KI-tis*	Inflammation of a bronchus
chronic obstructive pulmonary disease (COPD)	Any of a group of chronic, progressive, and debilitating respiratory diseases, which includes emphysema, asthma, bronchitis, and bronchiectasis (see **FIG. 12-10**)
croup *krupe*	A childhood disease usually caused by a viral infection that involves upper airway inflammation and obstruction; croup is characterized by a barking cough, difficulty breathing, and laryngeal spasm
cyanosis *si-ah-NO-sis*	Bluish discoloration of the skin caused by lack of oxygen in the blood (adjective: cyanotic) (see **FIG. 1-17**)
cystic fibrosis (CF) *SIS-tik fi-BRO-sis*	An inherited disease that affects the pancreas, respiratory system, and sweat glands; characterized by mucus accumulation in the bronchi causing obstruction and leading to infection
diphtheria *dif-THERE-e-ah*	Acute infectious disease, usually limited to the upper respiratory tract, characterized by the formation of a surface pseudomembrane composed of cells and coagulated material
dyspnea *disp-NE-ah*	Difficult or labored breathing (-pnea), sometimes with pain; "air hunger"
emphysema *em-fih-SE-mah*	A chronic pulmonary disease characterized by enlargement and destruction of the alveoli
empyema *em-pi-E-mah*	Accumulation of pus in a body cavity, especially the pleural space; pyothorax
hemoptysis *he-MOP-tih-sis*	The spitting of blood from the mouth or respiratory tract (ptysis means "spitting")
hemothorax *he-mo-THOR-aks*	Presence of blood in the pleural space
hydrothorax *hi-dro-THOR-aks*	Presence of fluid in the pleural space

extern.ir

Terminology — Key Terms (Continued)

hyperventilation *hi-per-ven-tih-LA-shun*	Increase in the rate and depth of breathing to above optimal levels, with blood carbon dioxide decreasing to levels below normal
hypoventilation *hi-po-ven-tih-LA-shun*	Condition in which the amount of air entering the alveoli is insufficient to meet metabolic needs and blood carbon dioxide increases to levels above normal
influenza *in-flu-EN-zah*	An acute, contagious respiratory infection causing fever, chills, headache, and muscle pain; "flu"
pertussis *per-TUS-is*	An acute, infectious disease characterized by a cough ending in a whooping inspiration; whooping cough
pleural effusion *PLURE-al eh-FU-zhun*	Accumulation of fluid in the pleural space; the fluid may contain blood (hemothorax) or pus (pyothorax or empyema) (see **FIG. 12-12**)
pleurisy *PLURE-ih-se*	Inflammation of the pleura; pleuritis; a symptom of pleurisy is sharp pain on breathing
pneumoconiosis *nu-mo-ko-ne-O-sis*	Disease of the respiratory tract caused by inhalation of dust particles; named more specifically by the type of dust inhaled, such as silicosis, anthracosis, asbestosis
pneumonia *nu-MO-ne-ah*	Inflammation of the lungs generally caused by infection; may involve the bronchioles and alveoli (bronchopneumonia) or one or more lobes of the lung (lobar pneumonia) (see **FIG. 12-8**)
pneumonitis *nu-mo-NI-tis*	Inflammation of the lungs; may be caused by infection, asthma, allergy, or inhalation of irritants
pneumothorax *nu-mo-THOR-aks*	Accumulation of air or gas in the pleural space; may result from injury or disease or may be produced artificially to collapse a lung (see **FIG. 12-11**)
pyothorax *pi-o-THOR-aks*	Accumulation of pus in the pleural space; empyema
respiratory distress syndrome (RDS)	A respiratory disorder that affects premature infants born without enough surfactant in the lungs; it is treated with respiratory support and surfactant administration
sudden infant death syndrome (SIDS)	The sudden and unexplained death of an apparently healthy infant; crib death
tuberculosis *tu-ber-ku-LO-sis*	An infectious disease caused by the tubercle bacillus, *Mycobacterium tuberculosis;* often involves the lungs but may involve other parts of the body as well; miliary (*MIL-e-ar-e*) tuberculosis is an acute generalized form of the disease with formation of minute tubercles that resemble millet seeds (see **FIG. 12-9**)
Diagnosis	
arterial blood gases (ABGs)	The concentrations of gases, specifically oxygen and carbon dioxide, in arterial blood; reported as the partial pressure (P) of the gas in arterial (a) blood, such as PaO_2 or $PaCO_2$; these measurements are important in measuring acid–base balance
bronchoscope *BRONG-ko-skope*	An endoscope used to examine the tracheobronchial passageways. Also allows access for tissue biopsy or removal of a foreign object (**FIG. 12-16**)
lung scan	Study based on the accumulation of radioactive isotopes in lung tissue; a ventilation scan measures ventilation after inhalation of radioactive material; a perfusion scan measures blood supply to the lungs after injection of radioactive material; also called a pulmonary scintiscan
pulse oximetry *ok-SIM-eh-tre*	Determination of the oxygen saturation of arterial blood by means of a photoelectric apparatus (oximeter), usually placed on the finger or the ear; reported as SpO_2 in percent (see **FIG. 12-14**)
pulmonary function tests	Tests done to assess breathing, usually by spirometry

(continued)

extern.ir

Terminology — Key Terms (Continued)

spirometer *spi-ROM-eh-ter*	An apparatus used to measure breathing volumes and capacities; record of test is a spirogram (see **FIG. 12-15**)
thoracentesis *thor-ah-sen-TE-sis*	Surgical puncture of the chest for removal of air or fluids, such as may accumulate after surgery or as a result of injury, infection, or cardiovascular problems; also called thoracocentesis (see **FIG. 12-13**)
tuberculin test *tu-BER-ku-lin*	A skin test for tuberculosis; tuberculin (PPD), the test material made from products of the tuberculosis organism, is injected below the skin; a hard, raised lump appearing within 48 to 72 hours indicates an active or inactive TB infection; also called the Mantoux (*man-TOO*) test

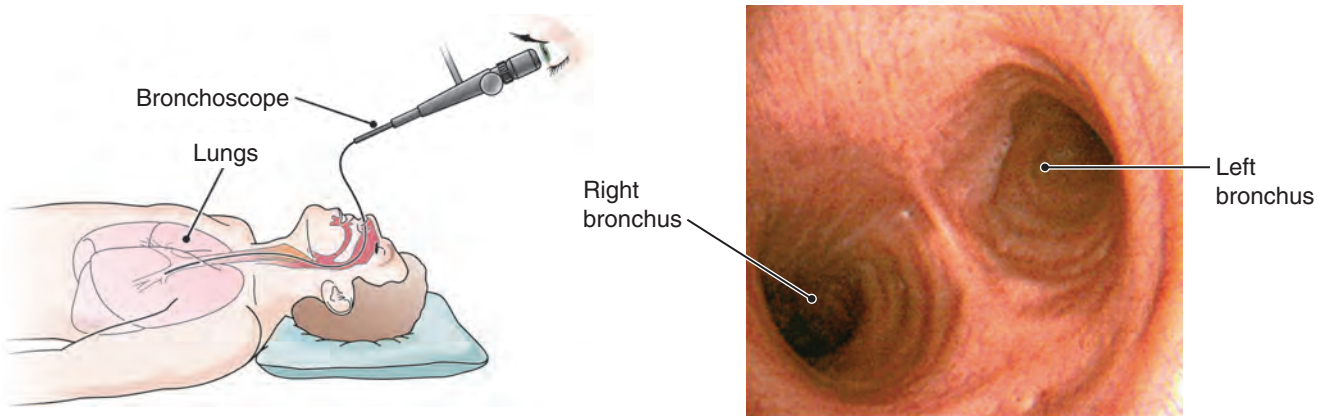

A B

FIGURE 12-16 Use of a bronchoscope. A. A bronchoscope is a lighted tube used to inspect the bronchi, remove specimens, and remove foreign objects. **B.** View of the bronchial openings through a bronchoscope. Note the larger right bronchus.

Terminology — Enrichment Terms

The terms listed below expand on the key terms to increase your knowledge of this chapter topic.

Normal Structure and Function

carina *kah-RI-nah*	A projection of the lowest tracheal cartilage that forms a ridge between the two bronchi; used as a landmark for endoscopy; any ridge or ridge-like structure (from a Latin word that means "keel")
hilum *HI-lum*	An anatomic depression in an organ where vessels and nerves enter
hyperpnea *hi-PERP-ne-ah*	Increase in the depth and rate of breathing to meet the body's needs, as in exercise
hypopnea *hi-POP-ne-ah*	Decrease in the rate and depth of breathing
nares *NA-reze*	The external openings of the nose; the nostrils (singular: naris)
nasal septum	The partition that divides the nasal cavity into two parts (root sept/o means "septum")
tachypnea *tak-IP-ne-ah*	Excessive rate of breathing, which may be normal, as in exercise

extern.ir

Terminology *Enrichment Terms (Continued)*

Symptoms and Conditions	
anoxia *an-OK-se-ah*	Lack or absence of oxygen in the tissues; often used incorrectly to mean hypoxia
asphyxia *as-FIK-se-ah*	Condition caused by inadequate intake of oxygen; suffocation (literally "lack of pulse")
Biot respirations *be-O*	Deep, fast breathing interrupted by sudden pauses; seen in spinal meningitis and other central nervous system disorders
bradypnea *brad-IP-ne-ah*	Abnormally slow rate of breathing
bronchospasm *BRONG-ko-spazm*	Narrowing of the bronchi caused by smooth muscle spasms; common in cases of asthma and bronchitis
Cheyne–Stokes respiration *chane stokes*	A repeating cycle of gradually increased and then decreased respiration followed by a period of apnea; caused by depression of the breathing centers in the brainstem; seen in cases of coma and in terminally ill patients
cor pulmonale *korpul-mo-NA-le*	Enlargement of the heart's right ventricle caused by disease of the lungs or pulmonary blood vessels
coryza *ko-RI-zah*	Acute inflammation of the nasal passages with profuse nasal discharge; acute rhinitis
deviated septum	A shifted nasal septum; may require surgical correction
epiglottitis *ep-ih-gloh-TI-tis*	Inflammation of the epiglottis that may lead to upper airway obstruction; commonly seen in croup (also spelled epiglottiditis)
epistaxis *ep-ih-STAK-sis*	Hemorrhage from the nose; nosebleed (Greek: staxis means "dripping")
fremitus *FREM-ih-tus*	A vibration, especially as felt through the chest wall on palpation
Kussmaul respiration *KOOS-mawl*	Rapid and deep gasping respiration without pause; characteristic of severe acidosis
pleural friction rub	A sound heard on auscultation that is produced by the rubbing together of the two pleural layers; a common sign of pleurisy
rales *rahlz*	Abnormal chest sounds heard when air enters small airways or alveoli containing fluid; usually heard during inspiration (singular: rale [*rahl*]); also called crackles
rhonchi *RONG-ki*	Abnormal chest sounds produced in airways with accumulated fluids; more noticeable during expiration (singular: rhonchus)
stridor *STRI-dor*	A harsh, high-pitched sound caused by obstruction of an upper air passageway
tussis *TUS-is*	A cough; an antitussive drug is one that relieves or prevents coughing
wheeze	A whistling or sighing sound caused by narrowing of a respiratory passageway
Disorders	
byssinosis *bis-ih-NO-sis*	Obstructive airway disease caused by reaction to the dust in unprocessed plant fibers

(continued)

extern.ir

Terminology — *Enrichment Terms (Continued)*

sleep apnea *AP-ne-ah*	Intermittent periods of breathing cessation during sleep; central sleep apnea arises from failure of the brainstem to stimulate breathing; obstructive sleep apnea results from airway obstruction during deep sleep, as from obesity or enlarged tonsils
small cell carcinoma	A highly malignant type of bronchial tumor involving small, undifferentiated cells; "oat cell" carcinoma
Diagnosis	
mediastinoscopy *me-de-as-tih-NOS-ko-pe*	Examination of the mediastinum by means of an endoscope inserted through an incision above the sternum
plethysmograph *pleh-THIZ-mo-graf*	An instrument that measures changes in gas volume and pressure during respiration
pneumotachometer *nu-mo-tak-OM-eh-ter*	A device for measuring air flow
thoracoscopy *thor-ah-KOS-ko-pe*	Examination of the pleural cavity through an endoscope; pleuroscopy
Treatment	
aerosol therapy	Treatment by inhalation of a drug or water in spray form
continuous positive airway pressure (CPAP)	Use of a mechanical respirator to maintain pressure throughout the respiratory cycle in a patient who is breathing spontaneously
extubation	Removal of a previously inserted tube
intermittent positive pressure breathing (IPPB)	Use of a ventilator to inflate the lungs at intervals under positive pressure during inhalation
intermittent positive pressure ventilation (IPPV)	Use of a mechanical ventilator to force air into the lungs while allowing for passive exhalation
nasal cannula *KAN-u-lah*	A two-pronged plastic device inserted into the nostrils for delivery of oxygen **(FIG. 12-17)**
orthopneic position *or-thop-NE-ik*	An upright or semi-upright position that aids breathing

FIGURE 12-17 A nasal cannula.

extern.ir

Terminology *Enrichment Terms (Continued)*

positive end-expiratory pressure (PEEP)	Use of a mechanical ventilator to increase the volume of gas in the lungs at the end of exhalation, thus improving gas exchange
postural drainage *POS-tu-ral*	Use of body position to drain secretions from the lungs by gravity; the patient is placed so that secretions will move passively into the larger airways for elimination
thoracic gas volume (TGV, V_{TG})	The volume of gas in the thoracic cavity calculated from measurements made with a body plethysmograph
Surgery	
adenoidectomy *ad-eh-noyd-EK-to-me*	Surgical removal of the adenoids
intubation *in-tu-BA-shun*	Insertion of a tube into a hollow organ, such as into the larynx or trachea for entrance of air **(FIG. 12-18)**; patients may be intubated during surgery for administration of anesthesia or to maintain an airway; endotracheal intubation may be used as an emergency measure when airways are blocked
lobectomy *lo-BEK-to-me*	Surgical removal of a lobe of the lung or of another organ
pneumoplasty *NU-mo-plas-te*	Plastic surgery of the lung; in reduction pneumoplasty, nonfunctional portions of the lung are removed, as in cases of advanced emphysema
tracheotomy *tra-ke-OT-o-me*	Incision of the trachea through the neck, usually to establish an airway in cases of tracheal obstruction
tracheostomy *tra-ke-OS-to-me*	Surgical creation of an opening into the trachea to form an airway or to prepare for the insertion of a tube for ventilation **(FIG. 12-19)**; also the opening thus created

(continued)

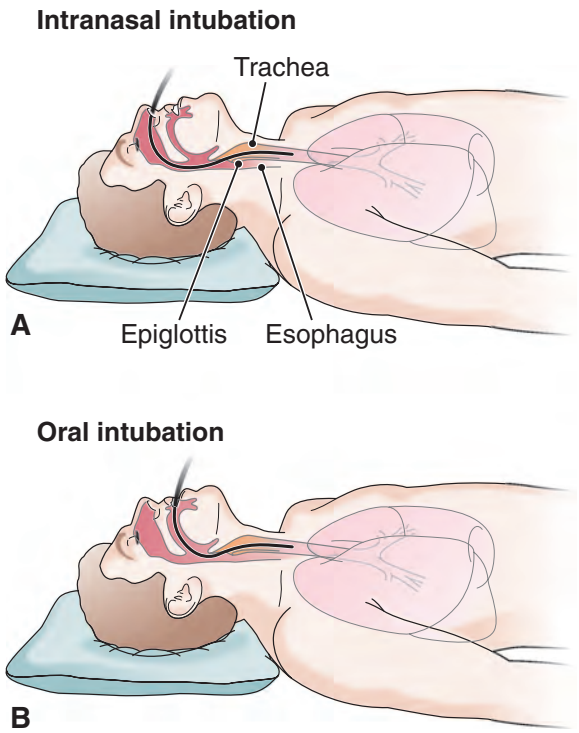

FIGURE 12-18 Endotracheal intubation. A. Nasal endotracheal catheter in proper position. **B.** Oral endotracheal intubation.

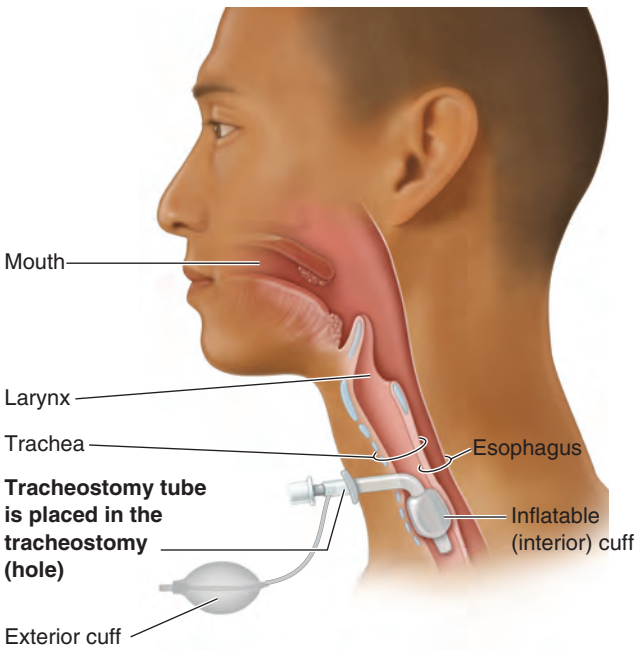

FIGURE 12-19 A tracheostomy tube in place.

extern.ir

Terminology Enrichment Terms (Continued)

Drugs	
antihistamine *an-te-HIS-tah-mene*	Agent that prevents responses mediated by histamine, such as allergic and inflammatory reactions
antitussive *an-te-TUS-iv*	Drug that prevents or relieves coughing
asthma maintenance drug	Agent used to prevent asthma attacks and for chronic treatment of asthma
bronchodilator *brong-ko-DI-la-tor*	Drug that relieves bronchial spasm and widens the bronchi
corticosteroid *kor-tih-ko-STARE-oyd*	Hormone from the adrenal cortex; used to reduce inflammation
decongestant *de-kon-JES-tant*	Agent that reduces congestion or swelling
expectorant *ek-SPEK-to-rant*	Agent that aids in removal of bronchopulmonary secretions
isoniazid (INH) *i-so-NI-ah-zid*	Drug used to treat tuberculosis
leukotriene antagonist *lu-ko-TRI-ene*	Drug that prevents or reduces inflammation by inhibiting leukotrienes, substances made in white blood cells that promote inflammation, constrict the bronchi, and increase mucus production; used in asthma treatment
mucolytic *mu-ko-LIT-ik*	Agent that loosens mucus to aid in its removal
rifampin (rifampicin) *RIF-am-pin*	Drug used to treat tuberculosis

Terminology Abbreviations

The abbreviations listed below are emphasized in this chapter. These are also found, collectively, with all chapter abbreviations in Appendix 2.

ABG(s)	Arterial blood gas(es)
AFB	Acid-fast bacillus (usually *Mycobacterium tuberculosis*)
ARDS	Acute respiratory distress syndrome; shock lung
ARF	Acute respiratory failure
BCG	Bacillus Calmette–Guérin (tuberculosis vaccine)
BS	Breath sounds
C	Compliance
CF	Cystic fibrosis
CO_2	Carbon dioxide
COPD	Chronic obstructive pulmonary disease
CPAP	Continuous positive airway pressure
CXR	Chest radiograph, chest x-ray
DTaP	Diphtheria, tetanus, pertussis (vaccine)
ERV	Expiratory reserve volume
FEV	Forced expiratory volume
FRC	Functional residual capacity

extern.ir

Terminology *Abbreviations (Continued)*

FVC	Forced vital capacity
HPS	*Hantavirus* pulmonary syndrome
IC	Inspiratory capacity
IGRA	Interferon-gamma release assay (test for TB)
INH	Isoniazid
IPPB	Intermittent positive pressure breathing
IPPV	Intermittent positive pressure ventilation
IRV	Inspiratory reserve volume
LLL	Left lower lobe (of lung)
LUL	Left upper lobe (of lung)
MEFR	Maximal expiratory flow rate
MMFR	Maximum midexpiratory flow rate
NAA	Nucleic acid amplification (test) (for TB)
O_2	Oxygen
$PaCO_2$	Arterial partial pressure of carbon dioxide
PaO_2	Arterial partial pressure of oxygen
PCP	*Pneumocystis* pneumonia
PEEP	Positive end-expiratory pressure
PEFR	Peak expiratory flow rate
PFT	Pulmonary function test(s)
PIP	Peak inspiratory pressure
PND	Paroxysmal nocturnal dyspnea
PPD	Purified protein derivative (tuberculin)
R	Respiration
RDS	Respiratory distress syndrome
RLL	Right lower lobe (of lung)
RML	Right middle lobe (of lung)
RSV	Respiratory syncytial virus
RUL	Right upper lobe (of lung)
RV	Residual volume
SARS	Severe acute respiratory syndrome
SIDS	Sudden infant death syndrome
SpO_2	Oxygen percent saturation
T & A	Tonsils and adenoids; tonsillectomy and adenoidectomy
TB	Tuberculosis
TGV	Thoracic gas volume
TLC	Total lung capacity
TV	Tidal volume
URI	Upper respiratory infection
VC	Vital capacity
V_{TG}	Thoracic gas volume

Case Study Revisited

Allison's Follow-Up to Surgery

Allison's surgery went well and there were no complications. The anesthesiologist closely monitored her respiratory status to make certain it was not compromised. He administered additional medications to maintain optimal airflow. Postoperatively, Allison's asthma was kept under control. The postoperative spirometry was adequate. Her discharge instructions were to resume preoperative medications and to follow up with her pediatrician if there were any problems.

Allison followed the postoperative instructions. After a month of physical therapy, she was able to resume normal activities which included walking her dog and playing with friends. She did notice that her asthma attacks were more frequent so her mom made an appointment with Allison's pediatrician. The pediatrician made slight adjustments to Allision's medications and scheduled a follow-up appointment. In between appointments, Allison with the help of her mom, was asked by the pediatrician to put together a daily diary. The diary includes Allison's activities and lists any medication that is used and any triggers that may cause an asthma attack.

extern.ir

CHAPTER 12

Review

This review tests your understanding of the content introduced in this chapter. Follow the instructions for each exercise and check your answers in Appendix 11.

LABELING EXERCISE

THE RESPIRATORY SYSTEM

Write the name of each numbered part on the corresponding line of the answer sheet.

Alveolar duct	Epiglottis	Left bronchus	Oral cavity	Smooth muscle
Alveoli	Esophagus	Left lung	Oropharynx	Sphenoidal sinus
Bronchioles	Frontal sinus	Mediastinum	Pharynx	Terminal bronchiole
Capillaries	Laryngopharynx	Nasal cavity	Right bronchus	Trachea
Diaphragm	Larynx	Nasopharynx	Right lung	

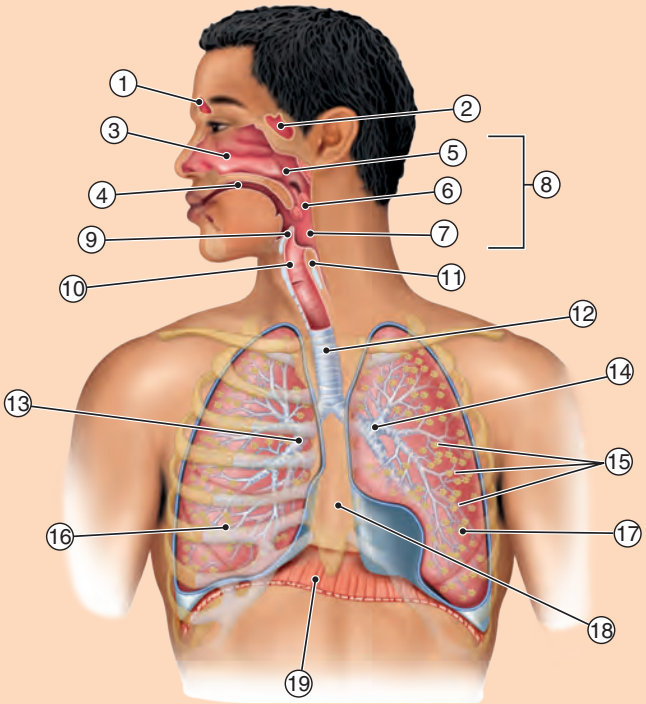

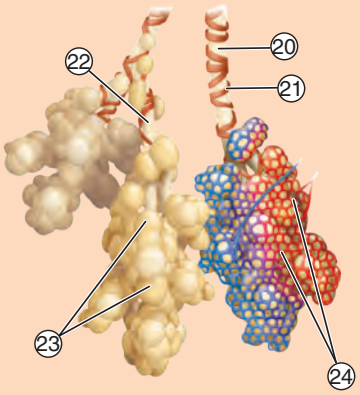

1. _____
2. _____
3. _____
4. _____
5. _____
6. _____
7. _____
8. _____
9. _____
10. _____
11. _____
12. _____
13. _____
14. _____
15. _____
16. _____
17. _____
18. _____
19. _____
20. _____
21. _____
22. _____
23. _____
24. _____

extern.ir

TERMINOLOGY

MATCHING

Match the following terms, and write the appropriate letter to the left of each number.

____ 1.	atelectasis	a. pulmonary disease with destruction of alveoli
____ 2.	emphysema	b. increased carbon dioxide in the blood
____ 3.	hypercapnemia	c. decreased rate and depth of breathing
____ 4.	hypopnea	d. whooping cough
____ 5.	pertussis	e. incomplete expansion of lung tissue

____ 6.	mediastinum	a. accidental inhalation of foreign material into the lungs
____ 7.	aspiration	b. space between the lungs
____ 8.	sputum	c. substance that reduces surface tension
____ 9.	surfactant	d. a measure of how easily the lungs expand
____ 10.	compliance	e. expectoration

____ 11.	PCP	a. childhood vaccine
____ 12.	DTaP	b. tuberculosis vaccine
____ 13.	CF	c. hereditary disease that affects respiration
____ 14.	IPPB	d. pneumonia seen in compromised patients
____ 15.	BCG	e. a form of respiratory treatment

Enrichment Terms

____ 16.	epistaxis	a. suffocation
____ 17.	intubation	b. nosebleed
____ 18.	asphyxia	c. insertion of a tube into a hollow organ
____ 19.	stridor	d. harsh, high-pitched respiratory sound
____ 20.	expectorant	e. agent that helps remove bronchial secretions

____ 21.	mucolytic	a. irregular respiration seen in terminally ill patients
____ 22.	Cheyne–Stokes	b. agent that loosens mucus to aid in its removal
____ 23.	rales	c. acute rhinitis
____ 24.	orthopneic	d. pertaining to an upright position
____ 25.	coryza	e. abnormal chest sounds

FILL IN THE BLANKS

Complete the sentence with the correct term(s).

26. The trachea divides into a right and a left primary _____ .
27. The phrenic nerve activates the _____ .
28. The gas produced in the tissues and exhaled in respiration is _____ .
29. The double membrane that covers the lungs and lines the thoracic cavity is the _____ .
30. The small air sacs in the lungs through which gases are exchanged between the atmosphere and the blood are the _____ .
31. The turbinate bones contain receptors for the sense of _____ .
32. A pneumotropic virus is one that invades the _____ .
33. The term *acid-fast bacillus* (AFB) is commonly applied to the organism that causes _____ .

extern.ir

34. The apparatus used to measure Allison's breathing volumes in the opening case study is called a(n) _____ .

35. The amount of air that Allison could expel from her lungs by maximum exhalation after maximum inhalation is termed the _____ .

Enrichment Terms

36. A thoracoscopy is an examination of the _____ through an endoscope.
37. An antitussive agent prevents _____ .
38. A mucolytic agent dissolves _____ .
39. Intermittent periods of not breathing during sleep are termed sleep _____ .
40. Allison was given a drug to widen the bronchi. This type of drug is called a(n) _____ .

TRUE–FALSE

Examine the following statements. If the statement is true, write T in the first blank. If the statement is false, write F in the first blank, and correct the statement by replacing the underlined word in the second blank.

	True or False	Correct Answer
41. The pharynx is the <u>throat</u>.	_____	_____
42. The diaphragm flattens during <u>exhalation</u>.	_____	_____
43. The vocal folds are located in the <u>pharynx</u>.	_____	_____
44. The right lung has <u>three</u> lobes.	_____	_____
45. The opening between the vocal folds is the <u>glottis</u>.	_____	_____
46. The adenoids are in the <u>nasopharynx</u>.	_____	_____

DEFINITIONS

Write words for the following definitions.

47. incision of the phrenic nerve _____
48. decrease in rate and depth of breathing _____
49. inflammation of the throat _____
50. inflammation of the bronchioles _____
51. creation of an opening into the trachea _____

The word thorax (chest) is used as an ending in compound words that mean the accumulation of substances in the pleural space. Define the following terms.

52. pneumothorax _____
53. hydrothorax _____
54. pyothorax _____
55. hemothorax _____

extern.ir

Define the following words.

56. tracheostenosis _____
57. hemoptysis _____
58. hypoxia _____
59. pneumonopathy _____
60. tachypnea _____
61. bronchiectasis _____
62. rhinoplasty _____
63. pleurodynia _____

Identify and define the root in the following words.

	Root	Meaning of Root
64. rhinoplasty	_____	_____
65. pulmonologist	_____	_____
66. respiration	_____	_____
67. phrenicotomy	_____	_____
68. pneumatic	_____	_____

OPPOSITES

Write a word that means the opposite of the following.

69. bradypnea _____
70. hypocapnia _____
71. expiration _____
72. extrapulmonary _____
73. extubation _____

ADJECTIVES

Write the adjective form of the following words.

74. larynx _____
75. alveolus _____
76. nose _____
77. trachea _____
78. pleura _____
79. bronchus _____

extern.ir

PLURALS

Write the plural form of the following words.

80. naris _____
81. pleura _____
82. alveolus _____
83. concha _____
84. bronchus _____

ELIMINATIONS

In each of the sets below, underline the word that does not fit in with the rest and explain the reason for your choice.

85. turbinates — septum — nares — tonsil — conchae

_____

86. sinus — thyroid cartilage — epiglottis — cricoid cartilage — vocal folds

_____

87. diphtheria — tuberculosis — asthma — common cold — influenza

_____

88. RUL — URI — LUL — LLL — RML

_____

89. TLC — FRC — FEV — TV — RDS

_____

WORD BUILDING

Write words for the following definitions using the word parts given. Each word part can be used more than once.

-pnea	-ia	ox/i	a-	-metry	phon/o	hyper-	dys-	capn/o	hypo-	eu-	tachy-

90. loss of voice _____
91. increased levels of carbon dioxide _____
92. difficulty in speaking _____
93. increased rate and depth of breathing _____
94. measurement of oxygen levels _____
95. difficulty in breathing _____
96. low levels of oxygen in the tissues _____
97. normal, regular breathing _____
98. rapid breathing _____
99. excessive voice production _____

extern.ir

WORD ANALYSIS

Define the following words and give the meaning of the word parts in each. Use a dictionary if necessary.

100. pneumotachometer (*nu-mo-tak-OM-eh-ter*)
    a. pneum/o _____
    b. tach/o _____
    c. -meter _____
101. atelectasis (*at-eh-LEK-tah-sis*)
    a. atel/o- _____
    b. -ectasis _____
102. pneumatocardia (*nu-mah-to-KAR-de-ah*)
    a. pneumat/o _____
    b. cardi _____
    c. -ia _____
103. pneumoconiosis (*nu-mo-ko-ne-O-sis*)
    a. pneum/o _____
    b. coni/o _____
    c. -sis _____

extern.ir

Additional Case Studies

Case Study 12-1: Giant Cell Sarcoma of the Lung

Morgan, a 68 y/o man, was admitted to the pulmonary unit with chest pain on inspiration, dyspnea, and diaphoresis. He had smoked one and a half packs of cigarettes per day for 52 years and had quit 3 months ago. Morgan retired from the advertising industry and was admitted to occasional alcohol use. He was treated for primary giant cell sarcoma of the left lung 3 years ago with a lobectomy of the left lung followed by radiation and chemotherapy.

Physical examination was unremarkable except for a thoracotomy scar in the left hemithorax, decreased breath sounds, and dullness to percussion of the left base. There was no hemoptysis. Chest and upper abdomen CT scan showed findings compatible with recurrent sarcoma of the left hemithorax. Abnormal mediastinal nodes were evident. A thoracentesis was attempted but did not yield fluid. Morgan was scheduled for a left thoracoscopy, mediastinoscopy, and biopsy.

Case Study 12-1 Questions

To check your answers go to Appendix 11.

Multiple Choice. *Select the best answer, and write the letter of your choice to the left of each number.*

_____ 1. The root *pulmon*, as in *pulmonary*, means
   a. chest
   b. air
   c. lung
   d. breath sound

_____ 2. Hemoptysis is
   a. drooping eyelids
   b. discoloration of skin
   c. blue nail beds
   d. spitting of blood

Write words from the case study with the following meanings.

3. Removal of a lobe _____
4. Profuse sweating _____
5. Surgical incision of the chest _____
6. Endoscopic examination of the chest cavity _____
7. Half of the chest _____
8. Endoscopic examination of the space between the lungs _____

extern.ir

Case Study 12-2: Terminal Dyspnea

Ella, a 76 y/o woman, was in the ICU in the terminal stage of multisystem organ failure. She had been admitted to the hospital for bacterial pneumonia, which had not resolved with antibiotic therapy. She had a 20-year history of COPD. She was not conscious and was unable to breathe on her own. Her ABGs were abnormal, and she was diagnosed with refractory ARDS. The decision was made to support her breathing with endotracheal intubation and mechanical ventilation. After 1 week and several unsuccessful attempts to wean her from the ventilator, the pulmonologist suggested a permanent tracheostomy and discussed with the family the options of continuing or withdrawing life support. Her physiologic status met the criteria of remote or no chance for recovery.

Ella's family discussed her condition and decided not to pursue aggressive life-sustaining therapies. Ella was assigned do not resuscitate (DNR) status. After the written orders were read and signed by the family, the endotracheal tube, feeding tube, pulse oximeter, and ECG electrodes were removed, and a morphine IV drip was started with prn boluses ordered to promote comfort and relieve pain. The family sat with her for many hours, providing comfort and support. After a while, they noticed that her breathing had become shallow with Cheyne–Stokes respirations. Ella died quietly in the presence of her family and the hospital chaplain.

Case Study 12-2 Questions

To check your answers go to Appendix 11.

Multiple Choice. *Select the best answer, and write the letter of your choice to the left of each number.*

_____ 1. Dyspnea could NOT be described as
- a. difficulty breathing
- b. eupnea
- c. air hunger
- d. Cheyne–Stokes respirations

_____ 2. Pulse oximetry is used to measure
- a. forced expiratory volume
- b. tidal volume
- c. positive end-expiratory pressure
- d. oxygen saturation of blood

_____ 3. An endotracheal tube is placed
- a. within the trachea
- b. beyond the carina
- c. within the bronchus
- d. under the trachea

Define the following abbreviations.

4. COPD _____
5. ABG _____
6. ARDS _____
7. DNR _____

extern.ir

CHAPTER 13

Digestive System

Pretest

Multiple Choice. **Select the best answer, and write the letter of your choice to the left of each number. To check your answers go to Appendix 11.**

_____ 1. An organic catalyst is a(n)
a. enzyme
b. sugar
c. nucleic acid
d. saliva

_____ 2. The organ that carries food from the pharynx to the stomach is the
a. trachea
b. larynx
c. esophagus
d. intestine

_____ 3. The word root for stomach is
a. hepat/o
b. ren/o
c. gastr/o
d. cardi/o

_____ 4. The word root *enter/o* refers to the
a. gallbladder
b. intestine
c. kidney
d. heart

_____ 5. The wave-like action that moves substances through an organ is called
a. pulmonary
b. peristalsis
c. parotid
d. mastication

_____ 6. The process of moving digested nutrients from the intestine into the circulation is called
a. lymphedema
b. digestion
c. egestion
d. absorption

_____ 7. The organ that secretes bile is the
a. kidney
b. spleen
c. liver
d. stomach

_____ 8. Cholecystitis is inflammation of the
a. gallbladder
b. throat
c. diaphragm
d. small intestine

extern.ir

Learning Objectives

After careful study of this chapter, you should be able to:

1. Describe the organs of the digestive tract, and give the function of each. ***P426***
2. Describe the accessory organs of digestion and explain the role of each. ***P429***
3. Identify and use the roots pertaining to the digestive system and accessory organs. ***P432***
4. Describe the major disorders of the digestive system. ***P436***
5. Define medical terms used in reference to the digestive system. ***P442***
6. Interpret abbreviations used in referring to the gastrointestinal system. ***P449***
7. Analyze the medical terms in case studies related to the digestive system. ***PP425, 456***

Case Study: Abe's Gastroesophageal Reflux Disease and Erosive Esophagitis



Chief Complaint

Abe is a 51 y/o businessman with complaints of epigastric pain. He has a 10-year history of heartburn that he notes has become worse over the last year. The heartburn occurs both after meals and at bedtime. His sleep has been interrupted by nighttime symptoms, and he feels generally fatigued. Intermittently he says he feels that things come back up into his throat, but he lacks clear signs of aspiration into the respiratory tract. He is aware that gastroesophageal reflux disease (GERD) is a chronic condition and may be associated with a risk for complications that include serious morbidity and mortality. Due to his required travel for business, he has put off making a doctor's appointment but realizes he needs to see his physician. The heartburn has increased in frequency (daily now) and severity, so he finally schedules an office visit.

Examination

Abe is seen by his primary care physician and describes his daily episodes of discomfort. Abe is 6-foot-1-inch and weighs 230 pounds. The physician reviews a colonoscopy from last year with him that was normal. His blood pressure and other physical examination findings at this visit are within normal ranges. Results of a complete blood count, chemistry profile, and lipid profile are all within normal limits. He describes his self-medication by taking over-the-counter (OTC) drugs including antacids, histamine-2 receptor antagonists (H2 blockers), and the OTC proton pump inhibitor (PPI) omeprazole. He notes the latter helped "a little bit," but he discontinued use after 2 weeks, as noted in the packaging instructions. He has no history of smoking or alcohol abuse. He has an unremarkable past medical and family history.

Clinical Course

The physician explained to Abe that he is experiencing classic esophageal symptoms that are highly specific to GERD, heartburn, and regurgitation. The physician also informed him that GERD might be associated with erosive esophagitis, which is best diagnosed on endoscopy via esophagogastroduodenoscopy (EGD). Because Abe is 51 and has been experiencing heartburn for more than 10 years with daily symptoms for the past year, he should be evaluated thoroughly. He has been referred for the endoscopy procedure, but the appointment is not for 7 weeks. He is prescribed a PPI and is instructed to return to the office in approximately 4 weeks while still on therapy for assessment of symptoms prior to his appointment.

Case Study Revisited: Once you complete this chapter, please review the case follow-up on p. 449.

Ancillaries *At-A-Glance*

Visit the web resource to access the following resources.

extern.ir

Learning Resources

- eBook
- A&P Module with Heart & Lung Sounds
- Image Bank
- TestPrep
- Animations
- Audio Pronunciation Glossary

Introduction

The function of the digestive system is to prepare food for intake by body cells. Nutrients must be broken down by mechanical and chemical means into molecules that are small enough to be absorbed into circulation. Within cells, the nutrients are used for energy and for rebuilding vital cell components. The digestive system also stores undigested waste materials and then eliminates them from the body.

Digestion

Digestion takes place in the digestive tract proper, which extends from the **mouth** to the **anus** (FIG. 13-1). **Peristalsis,** wave-like contractions of the organ walls, moves food through the digestive tract and also moves undigested waste material out of the body. Also contributing to digestion are several accessory organs that release secretions into the digestive tract.

Enzymes are needed throughout the digestive process. These compounds are organic catalysts that speed the rate of food's chemical breakdown. The names of most enzymes can be recognized by the ending *-ase*.

The Digestive Tract

The digestive tract, also known as the alimentary canal or gastrointestinal (GI) tract, is essentially a long tube modified into separate organs with special functions (see FIG. 13-1). BOX 13-1 summarizes the activities of the digestive organs

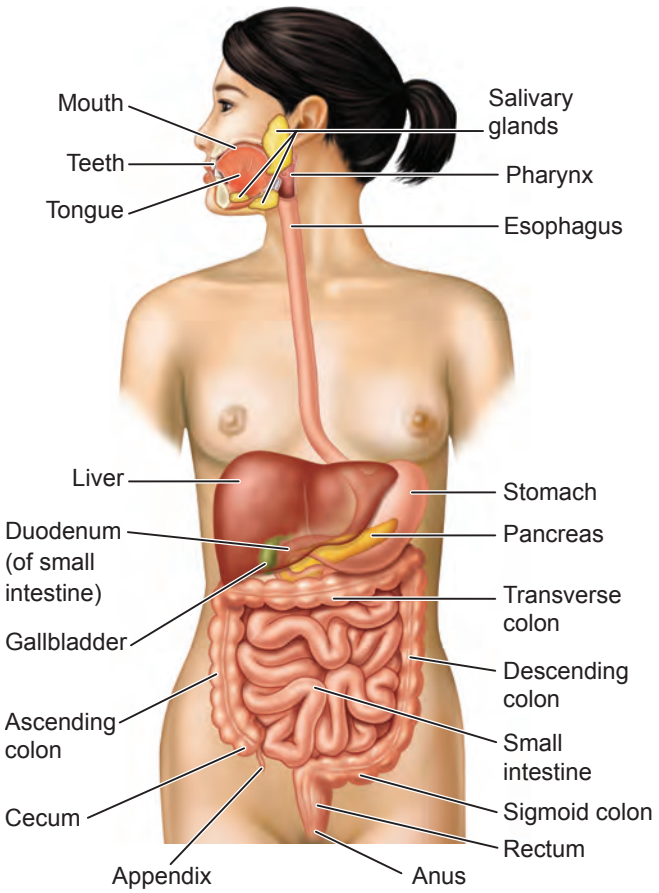

FIGURE 13-1 Digestive system. Divisions of the gastrointestinal tract are shown along with the accessory organs, the salivary glands, liver, gallbladder, and pancreas.

extern.ir

FOR YOUR REFERENCE
Organs of the Digestive Tract

BOX 13-1

Organ	Digestive Actions
mouth	Used to bite and chew food. Mixes food with saliva, which contains salivary amylase, an enzyme that begins the digestion of starch. Shapes food into small portions, which the tongue pushes into the pharynx.
pharynx	Swallows food by reflex action and moves it into the esophagus.
esophagus	Moves food into the stomach by peristalsis.
stomach	Stores food; churns to mix food with water and digestive juices. Secretes protein-digesting hydrochloric acid (HCl) and the enzyme pepsin.
small intestine	Secretes enzymes. Receives secretions from the accessory organs, which digest and neutralize food. Site of most digestion and absorption of nutrients into the circulation.
large intestine	Forms, stores, and eliminates undigested waste material.

described below. A large serous membrane, the **peritoneum** (*per-ih-to-NE-um*), covers the organs in the abdominal cavity, supporting and separating them.

THE MOUTH TO THE STOMACH

Digestion begins in the mouth (FIG. 13-2), also called the oral cavity. Here, food is chewed into small bits by the teeth. There are 32 teeth in a complete adult set, including incisors and canines to bite food and molars for grinding. The structural features of a molar tooth and its surrounding tissue are shown in FIGURE 13-3. The **palate** is the roof of the mouth; the anterior portion (hard palate) is formed by bone, and the posterior part (soft palate) is made of soft tissue. The fleshy **uvula**, used in speech production, hangs from the soft palate. Dental hygienists help in care of the mouth and teeth. BOX 13-2 has information on careers in dental hygiene.

In the process of chewing, or **mastication**, the tongue, lips, cheeks, and palate also help to break up food and mix it with **saliva**, a secretion that moistens the food and begins starch digestion. The salivary glands (see FIG. 13-1) secrete saliva into the mouth and are considered to be accessory digestive organs.

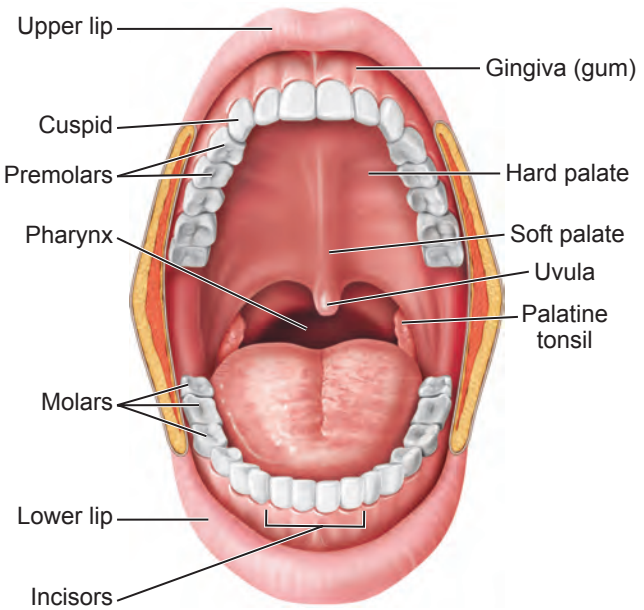

FIGURE 13-2 The mouth. The teeth, pharynx, tonsils, and other structures in the oral cavity are shown.

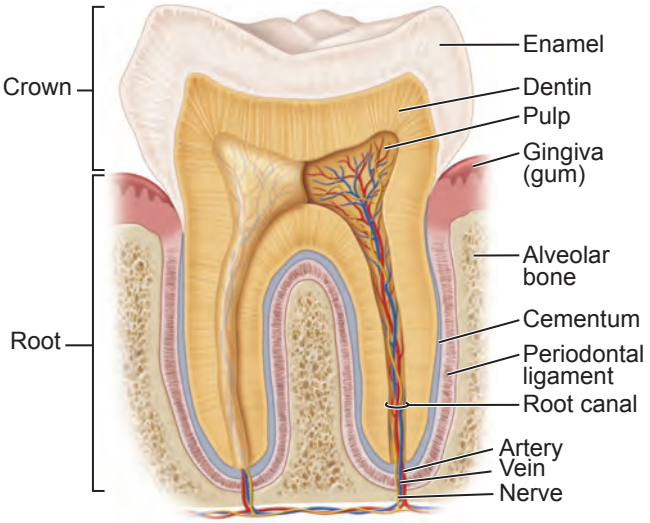

FIGURE 13-3 A molar tooth. The bony socket, gingiva, blood vessels, and nerve supply are shown as well as portions of the tooth.

extern.ir

HEALTH PROFESSIONS
Dental Hygienist

BOX 13-2

Dental hygienists focus primarily on dental health maintenance and preventive dental care. They examine patients' dentition and periodontium (supporting structures of the teeth); take radiographic images; and perform oral prophylaxis using hand and ultrasonic instruments to remove deposits, such as calculus, stains, and plaque. They may also apply fluorides to prevent caries. They work independently or along with a dentist to administer local anesthesia and nitrous oxide sedation and to do oral screenings, polish restorations, remove sutures, apply dental sealants, and perform periodontal procedures. Dental hygienists must be knowledgeable about safety concerning x-ray equipment, anesthesia, and infectious diseases. They wear safety glasses, surgical masks, and gloves to protect themselves and their patients. A major component of the dental hygienist's work is patient education for maintenance of good oral health. They may give instruction on nutrition and proper oral care, such as brushing, flossing, and the use of antimicrobial rinses.

Most dental hygiene programs award an associate degree; some offer bachelor's or master's degrees. The higher degrees are required for research, teaching, or practice in public or school health facilities. The professional program requires 1 year of college-level prerequisite courses. The curriculum includes courses in radiography, dental anatomy, pharmacology, head and neck anatomy, and other health- and dental-related sciences. Additional material on the legal and ethical aspects of dental hygiene practice and extensive clinical training are included in the program. After graduation, dental hygienists must be licensed in their states by passing clinical and written examinations administered by the American Dental Association's (ADA) Joint Commission on National Dental Examinations.

Almost all hygienists work in dental offices. One advantage of this field is scheduling flexibility and the opportunity for part-time work. Job prospects are good; dental hygiene is among the fastest growing occupations. Benefits vary with place of employment. For additional information, contact the American Dental Hygienists' Association at adha.org.

Portions of moistened food are moved toward the **pharynx** (throat), where swallowing reflexes push them into the **esophagus.** Peristalsis moves the food through the esophagus and into the stomach. At its distal end, where it joins the **stomach,** the esophagus has muscle tissue that contracts to keep stomach contents from refluxing (flowing backward). This **lower esophageal sphincter** (**LES**) is also called the "cardiac sphincter" because it lies above the cardia of the stomach, the region around its upper opening.

In the stomach, food is further broken down as it is churned and mixed with secretions containing the enzyme pepsin and powerful hydrochloric acid (HCl), both of which break down proteins. The partially digested food then passes through the stomach's lower portion, the **pylorus,** into the **intestine.**

THE SMALL INTESTINE

Food leaving the stomach enters the **duodenum,** the first portion of the **small intestine.** As the food continues through the **jejunum** and **ileum,** the small intestine's remaining sections, digestion is completed. (Ileum sounds like ilium, a large bone of the pelvis. For information on these and other homonyms, see **BOX 13-3.**) The digestive substances active in

FOCUS ON WORDS
Homonyms

BOX 13-3

Homonyms are words that sound alike but have different meanings. One must know the context in which they are used in order to understand the intended meaning. For example, the ilium is the upper portion of the pelvis, but the ileum is the last portion of the small intestine. Different adjectives are preferred for each—iliac for the first and ileal for the second. The word *meiosis* refers to the type of cell division that halves the chromosomes to form the gametes, but *miosis* means abnormal contraction of the pupil. Both words come from the Greek word that means a decrease.

Similar-sounding names lead to some funny misspellings. The large bone of the upper arm is the humerus, but this bone is often written as "humorous." The vagus nerve (cranial nerve X) is named with a root that means "wander," as in the words vague and vagabond, because this nerve branches to many of the internal organs. Students often write the name as if it had some relation to the famous gambling city in Nevada.

Homonyms may have a more serious side as well. Drug names may sound or look so similar that clinicians could confuse them, leading to dangerous, potentially fatal, complications. For example, a 50 y/o woman was hospitalized after she took Flomax, which is used to treat symptoms for an enlarged prostate instead of Volmax, which is used to relieve bronchospasm. Another example involved two drugs used to treat schizophrenia, clozapine and olanzapine; a young man was given the wrong drug and suffered severe complications. The FDA and the United States Adopted Names Council regulate sound-alike or look-alike drug names. The World Health Organization (WHO) has rejected many proposed names, and has even changed drug names after they have been marketed, when they have led to medication errors.

extern.ir

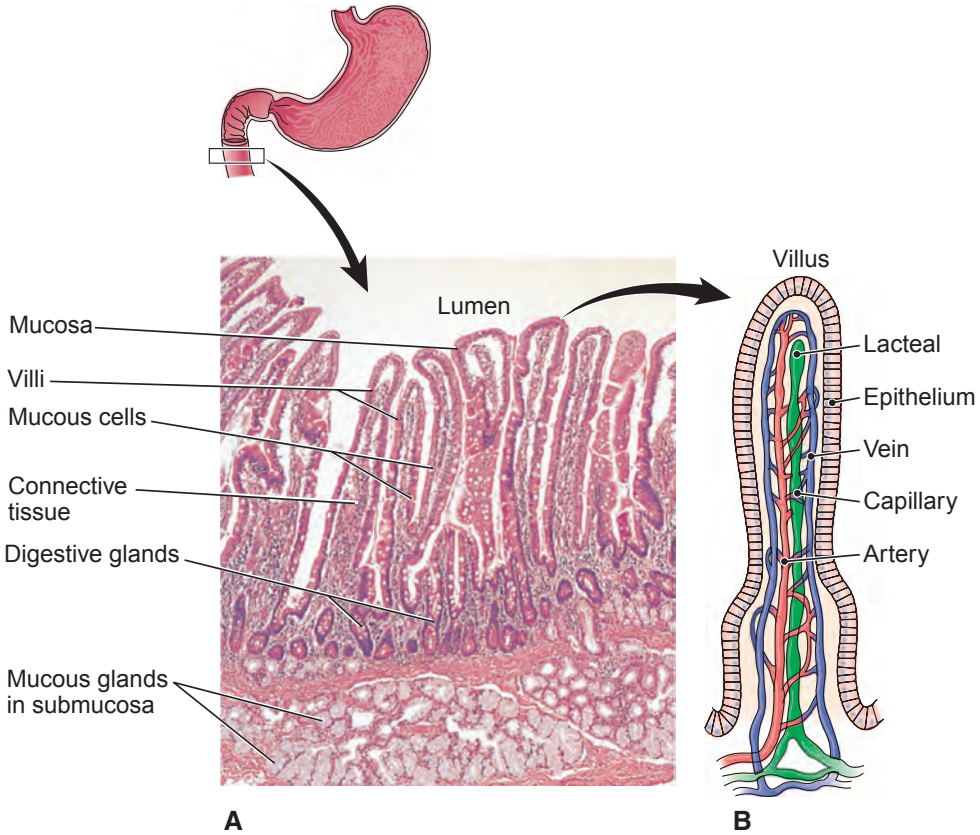

FIGURE 13-4 Intestinal villi. A. Microscopic view of the small intestine's lining showing villi and glands that secrete mucus and digestive juices. The lumen is the central opening. **B.** An intestinal villus. Each villus has blood vessels and a lacteal (lymphatic capillary) for nutrient absorption.

the small intestine include enzymes from the intestine itself and products from accessory organs that secrete into the duodenum.

The digested nutrients, including water, minerals, and vitamins, are absorbed into the circulation, aided by small projections in the intestinal lining called **villi** (FIG. 13-4). Each villus has blood capillaries to absorb nutrients into the bloodstream and lymphatic capillaries, or **lacteals**, to absorb small molecules of digested fats into the lymph. These fats join the blood when lymph flows into the bloodstream near the heart.

THE LARGE INTESTINE

Any food that has not been digested, along with water and digestive juices, passes into the **large intestine.** This part of the digestive tract begins in the lower right region of the abdomen with a small pouch, the **cecum**, to which the **appendix** is attached. (The appendix does not aid in digestion, but contains lymphatic tissue and may function in immunity.) The large intestine continues as the **colon**, a name that is often used alone to mean the large intestine, because the colon constitutes such a large portion of that organ. The colon travels upward along the right side of the abdomen as the ascending colon, crosses below the stomach as the transverse colon, and then continues down the left side of the abdomen as the descending colon. As food is pushed through the colon, water is reabsorbed, and stool or **feces** is formed. This waste material passes into the S-shaped **sigmoid colon** and is stored in the **rectum** until eliminated through the anus.

The Accessory Organs

The salivary glands, which secrete into the mouth, are the first accessory organs to act on food (FIG. 13-5). They

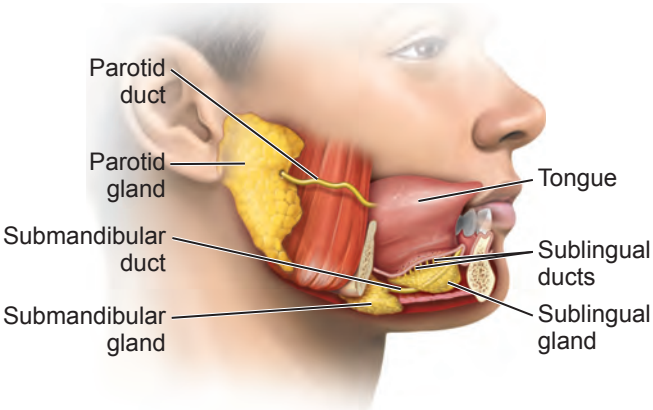

FIGURE 13-5 Salivary glands. These accessory organs of digestion secrete into the mouth.

extern.ir

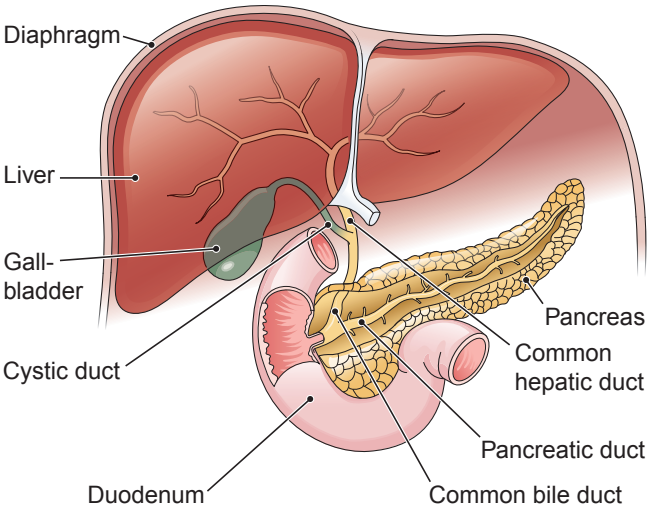

FIGURE 13-6 Accessory organs of digestion, which secrete into the small intestine. The organs and ducts are shown. The diaphragm is shown for reference.

secrete an enzyme (salivary amylase) that begins starch digestion. The remaining accessory organs are in the abdomen and secrete into the duodenum (FIG. 13-6). The **liver** is a large gland with many functions. A major activity is to process blood, removing toxins and converting nutrients into new compounds. A special circulatory pathway, the **hepatic portal system**, carries blood to the liver from the other abdominal organs. The liver functions in digestion by secreting **bile**, which emulsifies fats, that is, breaks them down into smaller units. The **gallbladder** stores bile until it is needed in digestion. The common hepatic duct from the liver and the cystic duct from the gallbladder merge to form the **common bile duct**, which empties into the duodenum.

The **pancreas** produces a mixture of digestive enzymes that is delivered into the duodenum through the pancreatic duct. It also secretes large amounts of bicarbonate, which neutralizes the strong stomach acid. BOX 13-4 summarizes the functions of the accessory organs.

FOR YOUR REFERENCE
The Accessory Organs

BOX 13-4

Organ	Digestive Actions
salivary glands	Secrete saliva, which moistens food and contains salivary amylase, an enzyme that begins the digestion of starch.
liver	Secretes bile salts that break down (emulsify) fats.
gallbladder	Stores bile and releases it into the digestive tract when needed.
pancreas	Secretes a variety of digestive enzymes. Also secretes bicarbonate to neutralize stomach acid and water to dilute food.

Terminology — *Key Terms*

The terms listed below are emphasized in this chapter. Knowing them will help you organize and prioritize your learning. These boldface terms are also found, collectively, with all chapter key terms in the Glossary.

Normal Structure and Function

anus *A-nus*	The distal opening of the digestive tract (root: an/o)
appendix *ah-PEN-diks*	An appendage; usually means the narrow tube of lymphatic tissue attached to the cecum, the vermiform (worm-like) appendix
bile	The fluid secreted by the liver that emulsifies fats and aids in their absorption (roots: chol/e, bili)
cecum *SE-kum*	A blind pouch at the beginning of the large intestine (root: cec/o)
colon *KO-lon*	The major portion of the large intestine; extends from the cecum to the rectum and is formed by ascending, transverse, and descending portions (roots: col/o, colon/o)
common bile duct	The duct that carries bile into the duodenum; formed by the union of the cystic duct and the common hepatic duct (root: choledoch/o)

extern.ir

Terminology — Key Terms (Continued)

duodenum *du-o-DE-num*	The first portion of the small intestine (root: duoden/o); also pronounced *du-OD-eh-num*
enzyme *EN-zime*	An organic catalyst; speeds the rate of chemical reactions
esophagus *e-SOF-ah-gus*	The muscular tube that carries food from the pharynx to the stomach
feces *FE-seze*	The waste material eliminated from the intestine (adjective: fecal); stool
gallbladder	A sac on the undersurface of the liver that stores bile (root: cholecyst/o)
hepatic portal system	A special circulatory pathway that brings blood directly from the abdominal organs to the liver for processing (also called simply the portal system); the vessel that enters the liver is the hepatic portal vein (portal vein)
ileum *IL-e-um*	The terminal portion of the small intestine (root: ile/o)
intestine *in-TES-tin*	The portion of the digestive tract between the stomach and the anus; it consists of the small and large intestines; it functions in digestion, absorption, and elimination of waste (root: enter/o); the bowel (*BOW-el*)
jejunum *jeh-JU-num*	The middle portion of the small intestine (root: jejun/o)
lacteal *lak-TELE*	A lymphatic capillary in a villus of the small intestine; lacteals absorb digested fats into the lymph
large intestine *in-TES-tin*	The terminal portion of the digestive tract, consisting of the cecum, colon, rectum, and anus; it stores and eliminates undigested waste material (feces)
liver *LIV-er*	The large gland in the upper right abdomen; in addition to many other functions, it secretes bile needed for digestion and absorption of fats (root: hepat/o)
lower esophageal sphincter (LES) *e-sof-ah-JE-al SFINK-ter*	Muscle tissue at the distal end of the esophagus (gastroesophageal junction) that prevents stomach contents from refluxing into the esophagus; also called the cardiac sphincter
mastication *mas-tih-KA-shun*	Chewing
mouth	The oral cavity; contains the tongue and teeth; used to take in and chew food, mix it with saliva, and move it toward the throat to be swallowed
palate *PAL-at*	The roof of the mouth; the partition between the mouth and nasal cavity; consists of an anterior portion formed by bone, the hard palate, and a posterior portion formed of tissue, the soft palate (root: palat/o)
pancreas *PAN-kre-as*	A large, elongated gland posterior to the stomach; it produces hormones that regulate sugar metabolism and also produces digestive enzymes (root: pancreat/o)
peristalsis *per-ih-STAL-sis*	Wave-like contractions of an organ's walls; moves material through an organ or duct
peritoneum *per-ih-to-NE-um*	The large serous membrane that lines the abdominal cavity and supports the abdominal organs
pharynx *FAR-inks*	The throat; a common passageway for food entering the esophagus and air entering the larynx (root: pharyng/o)
pylorus *pi-LOR-us*	The stomach's distal opening into the duodenum (root: pylor/o); the opening is controlled by a ring of muscle, the pyloric sphincter
rectum *REK-tum*	The distal portion of the large intestine; it stores and eliminates undigested waste (roots: rect/o, proct/o)

(continued)

extern.ir

Terminology — Key Terms (Continued)

saliva *sah-LI-vah*	The clear secretion released into the mouth that moistens food and contains a starch-digesting enzyme (root: sial/o); saliva is produced by three pairs of glands: the parotid, submandibular, and sublingual glands (see **FIG. 13-1**)
sigmoid colon	Distal S-shaped portion of the large intestine located between the descending colon and the rectum
small intestine *in-TES-tin*	The portion of the intestine between the stomach and the large intestine; comprised of the duodenum, jejunum, and ileum; accessory organs secrete into the small intestine, and almost all digestion and absorption occur there
stomach *STUM-ak*	A muscular sac-like organ below the diaphragm that stores food and secretes juices that digest proteins (root: gastr/o)
uvula *U-vu-lah*	The fleshy mass that hangs from the soft palate; aids in speech production (literally "little grape") (root: uvul/o)
villi *VIL-i*	Tiny projections in the lining of the small intestine that absorb digested foods into the circulation (singular: villus)

Roots Pertaining to the Digestive System

See **TABLES 13-1** to **13-3**.

Table 13-1 Roots for the Mouth

Root	Meaning	Example	Definition of Example
bucc/o	cheek	buccoversion *buk-ko-VER-zhun*	turning toward the cheek
dent/o, dent/i	tooth, teeth	edentulous *e-DEN-tu-lus*	without teeth
odont/o	tooth, teeth	periodontics *per-e-o-DON-tiks*	dental specialty that deals with the study and treatment of the tissues around the teeth
gingiv/o	gum (gingiva)	gingivectomy *jin-jih-VEK-to-me*	excision of gum tissue
gloss/o	tongue	glossoplegia *glos-o-PLE-je-ah*	paralysis (-plegia) of the tongue
lingu/o	tongue	orolingual *or-o-LING-gwal*	pertaining to the mouth and tongue
gnath/o	jaw	prognathous *PROG-nah-thus*	having a projecting jaw
labi/o	lip	labium *LA-be-um*	lip or lip-like structure
or/o	mouth	circumoral *sir-kum-OR-al*	around the mouth
stoma, stomat/o	mouth	xerostomia *ze-ro-STO-me-ah*	dryness (xero-) of the mouth
palat/o	palate	palatine *PAL-ah-tine*	pertaining to the palate (also palatal)
sial/o	saliva, salivary gland, salivary duct	sialogram *si-AL-o-gram*	radiograph of the salivary glands and ducts
uvul/o	uvula	uvulotome *U-vu-lo-tome*	instrument (-tome) for incising the uvula

extern.ir

Exercise 13-1

Complete the exercise. To check your answers go to Appendix 11.

Use the adjective suffix *-al* to write a word that has the same meaning as the following.

1. pertaining to the gums _____
2. pertaining to the tongue _____
3. pertaining to the teeth _____
4. pertaining to the cheek _____
5. pertaining to the lip _____
6. pertaining to the mouth _____

Fill in the blanks.

7. Dentistry (*DEN*-tis-tre) is the profession that studies, diagnoses, and treats the _____ .
8. Micrognathia (*mi-krog-NATH-e-ah*) is excessive smallness of the _____ .
9. An orthodontist (*or-tho-DON-tist*) specializes in straightening (ortho-) of the _____ .
10. The oropharynx is the part of the pharynx that is located behind _____ .
11. Stomatoplasty (*STO-mah-to-plas-te*) is any plastic repair of the _____ .
12. Hemiglossal (*hem-e-GLOS-al*) means pertaining to one half of the _____ .
13. A sialolith (*si-AL-o-lith*) is a stone formed in a(n) _____ gland or duct.

Define the following words.

14. buccopharyngeal (*BUK-oh-far-in-je-al*) _____
15. gingivoplasty (*jin-jih-vo-PLAS-te*) _____
16. sublingual (*sub-LING-gwal*) _____
17. labiodental (*la-be-o-DEN-tal*) _____
18. uvuloptosis (u-*vu-lop-TO-sis*) _____
19. hypoglossal (*hi-po-GLOS-al*) _____
20. palatorrhaphy (*pal-at-OR-ah-fe*) _____

13

Table 13-2 Roots for the Digestive Tract (Except the Mouth)

Root	Meaning	Example	Definition of Example
esophag/o	esophagus	esophageal[a] *e-sof-ah-JE-al*	pertaining to the esophagus
gastr/o	stomach	gastroparesis *gas-tro-pah-RE-sis*	partial paralysis (paresis) of the stomach
pylor/o	pylorus	pyloroplasty *pi-LOR-o-plas-te*	plastic repair of the pylorus
enter/o	intestine	dysentery *DIS-en-ter-e*	infectious disease of the intestine
duoden/o	duodenum	duodenostomy *du-o-deh-NOS-to-me*	surgical creation of an opening into the duodenum
jejun/o	jejunum	jejunectomy *jeh-ju-NEK-to-me*	excision of the jejunum

(continued)

extern.ir

Table 13-2 Roots for the Digestive Tract (Except the Mouth) *(Continued)*

Root	Meaning	Example	Definition of Example
ile/o	ileum	ileitis *il-e-I-tis*	inflammation of the ileum
cec/o	cecum	cecoptosis *se-kop-TO-sis*	downward displacement of the cecum
col/o, colon/o	colon	coloclysis *ko-lo-KLI-sis*	irrigation (-clysis) of the colon
sigmoid/o	sigmoid colon	sigmoidoscope *sig-MOY-do-skope*	an endoscope for examining the sigmoid colon
rect/o	rectum	rectocele *REK-to-sele*	hernia of the rectum
proct/o	rectum	proctopexy *PROK-to-pek-se*	surgical fixation of the rectum
an/o	anus	perianal *per-e-A-nal*	around the anus

[a]Note addition of e before -al.

Exercise 13-2

Complete the exercise. To check your answers go to Appendix 11.

Use the adjective suffix *-ic* to write a word for the following definitions.

1. pertaining to the pylorus _____
2. pertaining to the colon _____
3. pertaining to the stomach _____
4. pertaining to the intestine _____

Use the adjective suffix *-al* to write a word for the following definitions.

5. pertaining to the rectum _____
6. pertaining to the jejunum _____
7. pertaining to the ileum _____
8. pertaining to the cecum _____
9. pertaining to the anus _____

Write a word for the following definitions.

10. pertaining to the stomach and duodenum _____
11. inflammation of the esophagus _____
12. surgical creation of an opening in the intestine _____
13. study of the stomach and intestines _____
14. endoscopic examination of the stomach _____
15. downward displacement of the pylorus _____
16. inflammation of the jejunum and ileum _____
17. excision of the ileum _____
18. pertaining to the anus and rectum _____

extern.ir

Exercise 13-2 *(Continued)*

Use the root *col/o* to write a word for the following definitions.

19. inflammation of the colon _____
20. surgical creation of an opening into the colon _____
21. surgical fixation of the colon _____
22. surgical puncture of the colon _____

Use the root *colon/o* to write a word for the following definitions.

23. any disease of the colon _____
24. endoscopic examination of the colon _____

Two organs of the digestive tract or even two parts of the same organ may be surgically connected by a passage (anastomosis) after removal of damaged tissue. Such a procedure is named for the connected organs plus the ending *-stomy*. Use two roots plus the suffix *-stomy* to write a word for the following definitions.

25. surgical creation of a passage between the esophagus and stomach _____
26. surgical creation of a passage between the stomach and intestine _____
27. surgical creation of a passage between two portions of the jejunum _____
28. surgical creation of a passage between the duodenum and the ileum _____
29. surgical creation of a passage between the sigmoid colon and the rectum (proct/o) _____

13

Table 13-3 Roots for the Accessory Organs

Root	Meaning	Example	Definition of Example
hepat/o	liver	hepatocyte *HEP-ah-to-site*	a liver cell
bili	bile	biliary *BIL-e-ar-e*	pertaining to the bile or bile ducts
chol/e, chol/o	bile, gall	cholestasis *ko-le-STA-sis*	stoppage of bile flow
cholecyst/o	gallbladder	cholecystogram *ko-le-SIS-to-gram*	radiograph of the gallbladder
cholangi/o	bile duct	cholangioma *ko-lan-je-O-mah*	cancer of the bile ducts
choledoch/o	common bile duct	choledochal *KO-le-dok-al*	pertaining to the common bile duct
pancreat/o	pancreas	pancreatotropic *pan-kre-at-o-TROP-ik*	acting on the pancreas

extern.ir

Exercise 13-3

Complete the exercise. To check your answers go to Appendix 11.

Use the suffix *-ic* to write a word for the following definitions.

1. pertaining to the liver _____
2. pertaining to the gallbladder _____
3. pertaining to the pancreas _____

Use the suffix *-graphy* to write a word for the following definitions.

4. radiographic study of the liver _____
5. radiographic study of the gallbladder _____
6. radiographic study of the bile ducts _____
7. radiographic study of the pancreas _____

Use the suffix *-lithiasis* to write a word for the following definitions.

8. condition of having a stone in the common bile duct _____
9. condition of having a stone in the pancreas _____

Fill in the blanks.

10. Inflammation of the liver is called _____ .
11. The word biligenesis (*bil-ih-JEN-eh-sis*) means the formation of _____ .
12. A cholelith (*KO-le-lith*) is a(n) _____ .
13. Choledochotomy (*ko-led-o-KOT-o-me*) is incision of the _____ .
14. Cholecystectomy (*ko-le-sis-TEK-to-me*) is removal of the _____ .
15. Hepatomegaly (*hep-ah-to-MEG-ah-le*) is enlargement of the _____ .
16. Cholangitis (*ko-lan-JI-tis*) is inflammation of a(n) _____ .
17. Pancreatolysis (*pan-kre-ah-TOL-ih-sis*) is dissolving of the _____ .

Clinical Aspects of the Digestive System

DIGESTIVE TRACT

Infection

A variety of organisms can infect the GI tract, from viruses and bacteria to protozoa and worms. In the mouth, bacterial infection contributes to tooth decay or **caries.** It may cause a mild gum infection (gingivitis) or more extensive involvement of the deeper tissues and bony support around the tooth (periodontitis). Infections of the stomach or intestine may produce short-lived upsets with **gastroenteritis**, **nausea**, **diarrhea**, and **emesis** (vomiting). Other infectious diseases of the GI tract, such as typhoid, cholera, and dysentery, are more serious, even fatal.

Appendicitis results from infection of the appendix, often secondary to its obstruction. Surgery is necessary to avoid rupture and **peritonitis**, infection of the peritoneal cavity.

Ulcers

An ulcer is a lesion of the skin or a mucous membrane marked by inflammation and tissue damage. Ulcers caused by the damaging action of gastric juices, also called peptic juices, on the lining of the GI tract are termed **peptic ulcers.** Most peptic ulcers appear in the first portion of the duodenum. The origins of such ulcers are not completely known, although infection with a bacterium, *Helicobacter pylori*, has been identified as a major cause. Heredity and stress may be factors, as well as chronic inflammation and exposure to damaging drugs, such as aspirin and other NSAIDs, or to irritants in food and drink.

Current ulcer treatment includes the administration of antibiotics to eliminate *H. pylori* infection and use of drugs that inhibit gastric acid secretion. Ulcers may lead to hemorrhage or to perforation of the digestive tract wall.

extern.ir

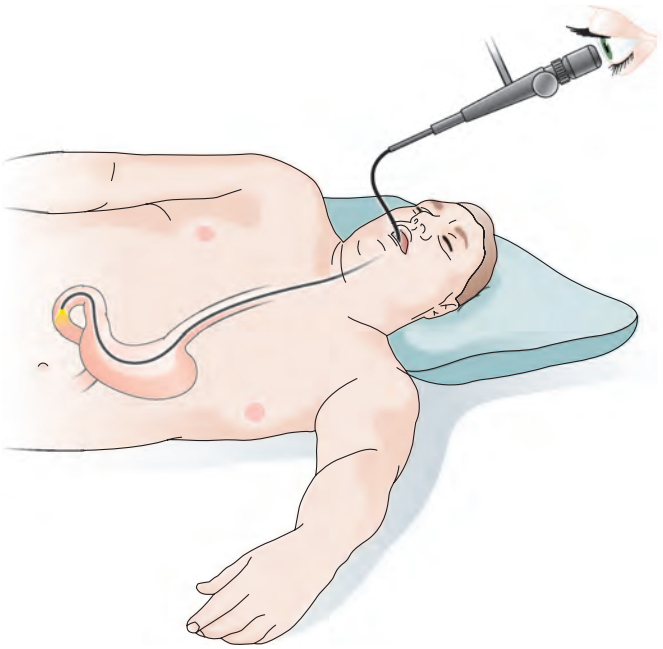

FIGURE 13-7 Endoscopy. A patient undergoing gastroscopy is shown.

Ulcers can be diagnosed by **endoscopy** (FIG. 13-7, BOX 13-5) and by radiographic study of the GI tract using a contrast medium, usually barium sulfate. A **barium study** can reveal a variety of GI disorders in addition to ulcers, including tumors and obstructions. A barium swallow is used for the study of the pharynx and esophagus; an upper GI series examines the esophagus, stomach, and small intestine.

Cancer

Cancer of the mouth generally involves the lips or tongue. Smoking is a major risk factor in these cases. **Leukoplakia,** white patches on mucous membranes, often results from smoking or other irritants and is an early sign of cancer in up to 25% of cases. The most common sites for GI tract cancer are the colon and rectum. Together, these colorectal cancers rank among the most frequent causes of cancer deaths in the United States in both men and women. A diet low in fiber and calcium and high in fat is a major risk factor in colorectal cancer. Heredity is also a factor, as is chronic inflammation of the colon (colitis). **Polyps** (growths) in the intestine often become cancerous and should be removed. Polyps can be identified and even removed by endoscopy.

One sign of colorectal cancer is bleeding into the intestine, which can be detected by testing the stool for blood. Because this blood may be present in very small amounts, it is described as **occult** ("hidden") **blood.** Colorectal cancers are staged according to **Dukes classification,** ranging from A to C according to severity.

Examiners can observe the intestine's interior with various endoscopes named for the specific area in which they

CLINICAL PERSPECTIVES
Endoscopy

BOX 13-5

Modern medicine has made great strides toward looking into the body without resorting to surgery. The endoscope, an instrument that is inserted through a body opening or small incision, has allowed the noninvasive examination of passageways, hollow organs, and body cavities. The first endoscopes were rigid, lighted telescopes that could be inserted only a short distance into the body. Today, physicians can navigate the twists and turns of the digestive tract using long fiberoptic endoscopes composed of flexible, light-transmitting bundles of glass or plastic.

Physicians can endoscopically detect structural abnormalities, ulcers, inflammation, and tumors in the GI tract. In addition, they use endoscopes to remove fluid or tissue samples for testing. Some surgery can even be done with an endoscope, such as polyp removal from the colon or sphincter expansion. Endoscopy can also be used to examine and operate on joints (arthroscopy), the bladder (cystoscopy), respiratory passages (bronchoscopy), and the abdominal cavity (laparoscopy).

A "virtual colonoscopy" uses computerized x-rays to generate detailed images of the colon. This method can provide an adequate screening for most people, although a small percentage might then need a standard colonoscopy for further assessment or surgery. Capsular endoscopy, a recent technologic advance, has made examination of the GI tract even easier. It uses a pill-sized camera that a patient can swallow! As the camera moves through the digestive tract, it transmits video images to a data recorder worn on the patient's belt.

extern.ir

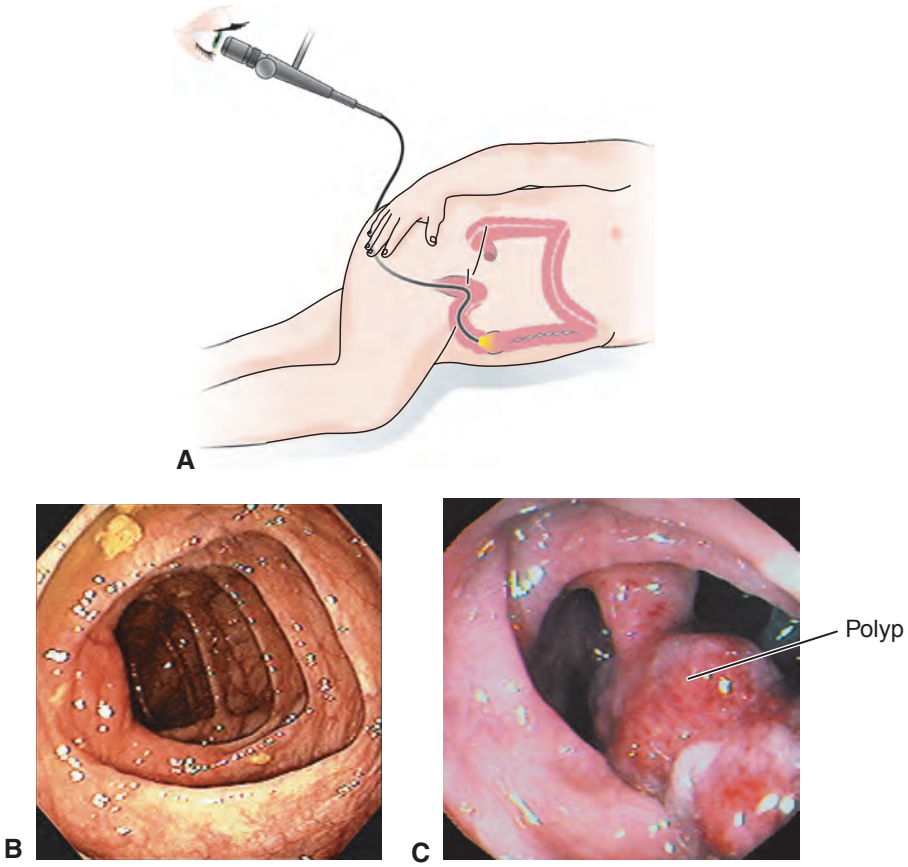

FIGURE 13-8 Colonoscopy. A. Sigmoidoscopy. The flexible fiberoptic endoscope is advanced past the proximal sigmoid colon and then into the descending colon. **B.** Endoscopic image of the cecum, the first portion of the large intestine. **C.** Endoscopic image of a colonic polyp.

are used, such as proctoscope (rectum), sigmoidoscope (sigmoid colon), and colonoscope (colon) (FIG. 13-8).

In some cases of cancer, and for other reasons as well, it may be necessary to surgically remove a portion of the GI tract and create a **stoma** (opening) on the abdominal wall for elimination of waste. Such **ostomy** surgery (FIG. 13-9) is named for the organ involved, such as ileostomy (ileum) or colostomy (colon). When an **anastomosis** (connection) is formed between two organs of the tract, both organs are included in naming, such as gastroduodenostomy

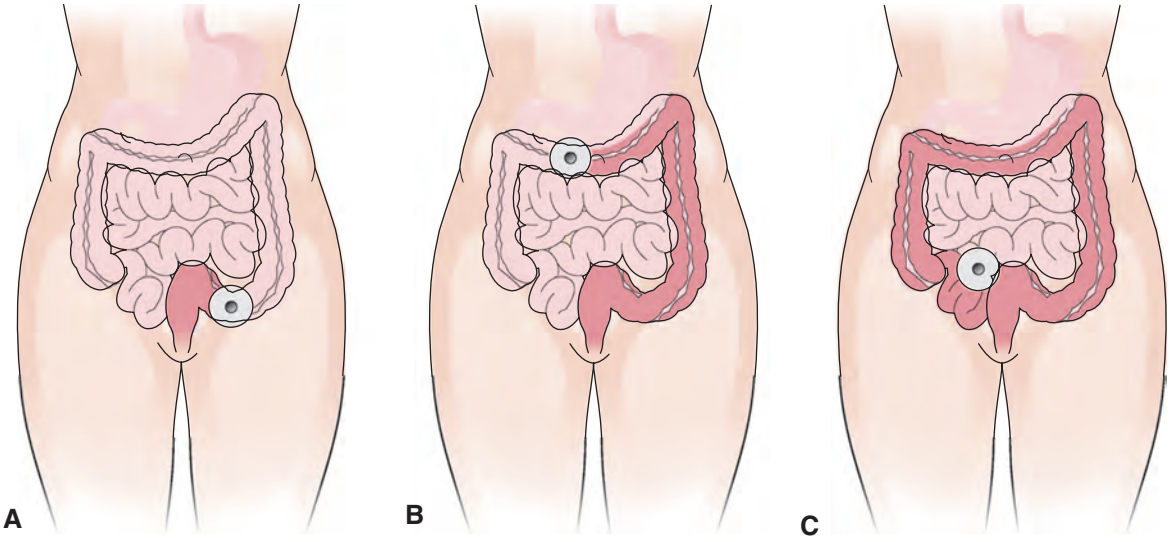

FIGURE 13-9 Ostomy surgery. Various locations are shown. The shaded portions represent the bowel sections that have been removed or are inactive. **A.** Sigmoid colostomy. **B.** Transverse colostomy. **C.** Ileostomy.

extern.ir

(stomach and duodenum) or coloproctostomy (colon and rectum).

Obstructions

A hernia is the protrusion of an organ through an abnormal opening. The most common type is an inguinal hernia, described in Chapter 15 (see FIG. 15-7). In a **hiatal hernia**, part of the stomach moves upward into the chest cavity through the space (hiatus) in the diaphragm through which the esophagus passes (see FIG. 3-4). Often this condition produces no symptoms, but it may result in chest pain, **dysphagia** (difficulty in swallowing), or reflux (backflow) of stomach contents into the esophagus.

In **pyloric stenosis**, the opening between the stomach and small intestine is too narrow. This usually occurs in infants and in boys more often than in girls. A sign of pyloric stenosis is projectile vomiting. Surgery may be needed to correct it.

Other types of obstruction include **intussusception** (FIG. 13-10), slipping of an intestinal segment into a part below it; **volvulus**, twisting of the intestine (see FIG. 13-10B); and **ileus**, intestinal obstruction often caused by lack of peristalsis.

Hemorrhoids are varicose veins in the rectum associated with pain, bleeding, and, in some cases, rectal prolapse.

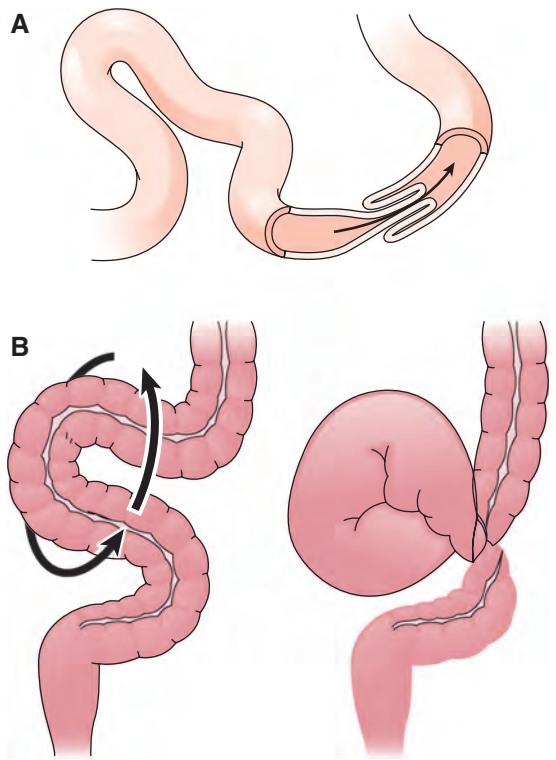

FIGURE 13-10 Intestinal obstruction. A. Intussusception. **B.** Volvulus, showing counterclockwise twist.

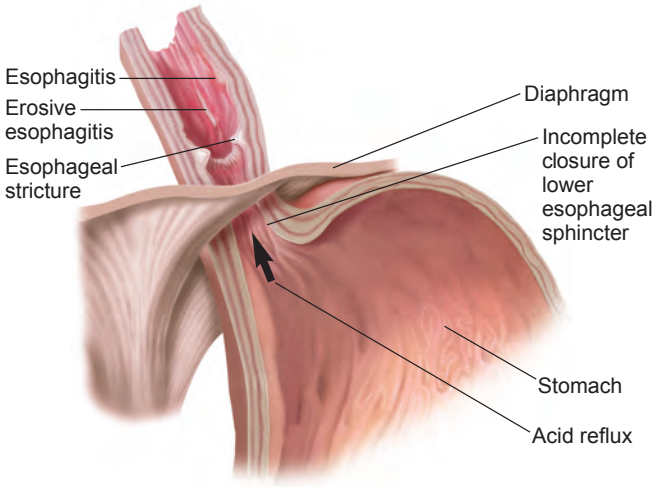

FIGURE 13-11 Gastroesophageal reflux disease (GERD). A weak LES allows acidic stomach contents to flow backward into the lower portion of the esophagus causing pain and irritation.

Gastroesophageal Reflux Disease

Gastroesophageal reflux disease (GERD) refers to reflux of gastric juices into the esophagus due to weakness at the gastroesophageal junction, specifically the LES (FIG. 13-11). These acidic secretions irritate the lining of the esophagus and even the throat and mouth if propelled upward by **regurgitation.** A GERD symptom commonly known as **heartburn**, an upward-radiating burning sensation behind the sternum, does not involve the heart, but is experienced in the area near the heart (see Abe's opening case study).

GERD symptoms are more likely to occur when there is increased pressure in the stomach, such as after meals when the stomach is full, when one is lying or bending down, and with obesity and pregnancy. Hiatal hernia can also lead to GERD. Treatment includes weight reduction if needed, elevating the head of the bed 4 to 6 in, avoidance of irritating foods, and drugs to reduce gastric acid secretion. Surgery to repair an incompetent LES might be needed.

Persistent reflux esophagitis may cause injury to the esophageal lining leading to **Barrett syndrome** or *Barrett esophagus*. In this condition, the esophageal mucosa is gradually replaced with epithelium resembling that of the stomach or intestines. Barrett esophagus frequently has no early symptoms, but possible complications include esophageal spasms, formation of scar tissue, esophageal strictures, and increased risk of cancer.

Inflammatory Intestinal Disease

Two similar diseases are included under the heading of inflammatory bowel disease (IBD):

- **Crohn disease** is a chronic inflammation of the intestinal wall, usually in the ileum and colon, causing pain, diarrhea, abscess, and often formation of an abnormal passageway, or **fistula**.
- **Ulcerative colitis** involves a continuous inflammation of the colon's lining that begins in the rectum and extends proximally (FIG. 13-12).

extern.ir

FIGURE 13-12 Ulcerative colitis. Prominent erythema and ulceration of the colon begin in the ascending colon and are most severe in the rectosigmoid area.

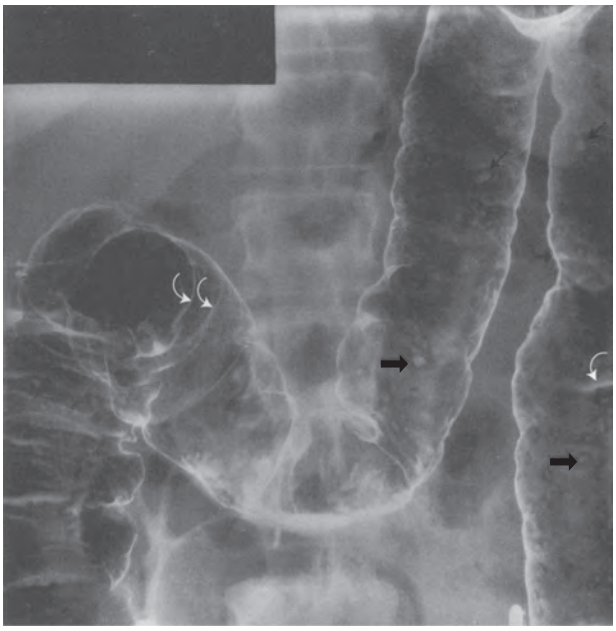

FIGURE 13-13 Lower gastrointestinal (GI) series. Barium enema shows lesions of enteritis (*straight arrows*) and thickened mucosa (*curved arrows*).

Both forms of IBD occur mainly in adolescents and young adults and show a hereditary pattern. They originate with an abnormal immunologic response, perhaps to the normal intestinal flora, along with autoimmunity. Treatment is with anti-inflammatory agents, immunosuppressants, and frequently surgery to remove damaged portions of the colon.

Celiac disease is characterized by the inability to absorb foods containing gluten, a protein found in wheat and some other grains. It affects the upper part of the small intestine and originates with an excess immune response to gluten. Mucosal inflammation diminishes the intestinal villi and interferes with absorption. Celiac disease is treated with a gluten-free diet.

Diverticulitis most commonly affects the colon. Diverticula are small pouches in the intestinal wall that commonly appear with age. The presence of these pouches is termed **diverticulosis**, which has been attributed to a diet low in fiber. Collection of waste and bacteria in these sacs leads to diverticulitis, which is accompanied by pain and sometimes bleeding. Diverticula can be seen by radiographic studies of the lower GI tract using barium as a contrast medium, a so-called barium enema **(FIG. 13-13)**. Although there is no cure, diverticulitis is treated with a high-fiber diet, stool softeners, and drugs (antispasmodics) to reduce motility. Diverticular infections are treated with antibiotics.

ACCESSORY ORGANS

Hepatitis

In the United States and other industrialized countries, **hepatitis** is most often caused by viral infection. More than five types of hepatitis viruses have now been identified. Vaccines are available for hepatitis A and hepatitis B.

- Hepatitis A virus (HAV) is the most common hepatitis virus. It is spread by fecal–oral contamination, often by food handlers, and in crowded, unsanitary conditions. It may also be acquired by eating contaminated food, especially seafood.
- Hepatitis B virus (HBV) is spread by blood and other body fluids. It may be transmitted sexually, by sharing injection needles, and by close interpersonal contact. Infected individuals may become carriers of the disease. Most patients recover, but the disease may be serious, even fatal, and may lead to liver cancer.
- Hepatitis C is spread through blood and blood products or by close contact with an infected person. Drug treatment is available to cure hepatitis C.
- Hepatitis D, the delta virus, is highly pathogenic but infects only those already infected with hepatitis B.
- Hepatitis E, like HAV, is spread by contaminated food and water. It has caused epidemics in Asia, Africa, and Mexico.

The name *hepatitis* simply means "inflammation of the liver," but this disease also causes necrosis (death) of liver cells. Other infections as well as drugs and toxins may also cause hepatitis. Liver function tests performed on blood serum are important in diagnosis.

Jaundice, or **icterus**, is a symptom of hepatitis and other diseases of the liver and biliary system **(FIG. 13-14)**. It appears as yellowness of the skin, whites of the eyes, and mucous membranes due to the presence of bile pigments, mainly **bilirubin**, in the blood.

Cirrhosis

Cirrhosis is a chronic liver disease characterized by **hepatomegaly**, edema, **ascites** (fluid in the abdomen), and jaundice.

extern.ir

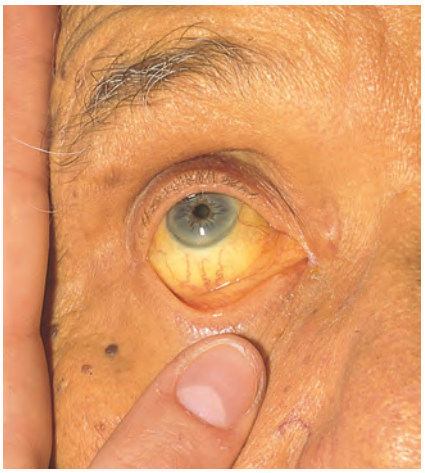

FIGURE 13-14 Jaundice. Yellowish discoloration due to bile pigments in the blood is seen in the eye.

Disease progression leads to internal bleeding and brain damage caused by changes in the blood's composition. One complication of cirrhosis is **portal hypertension**, increased pressure in the hepatic portal system, the vessels that carry blood from the other abdominal organs to the liver. Portal hypertension causes **splenomegaly** and the formation of varices (varicose veins) in the distal esophagus with possible hemorrhage. The main cause of cirrhosis is the excess consumption of alcohol.

Gallstones

Cholelithiasis refers to the presence of stones in the gallbladder (FIG. 13-15) or bile ducts, which is usually associated with **cholecystitis**, inflammation of the gallbladder. Cholelithiasis is characterized by **biliary colic** (pain) in the right upper quadrant (RUQ), nausea, and vomiting.

Most gallstones are composed of cholesterol, an ingredient of bile. They form more commonly in women than in men and are promoted by conditions that increase estrogen, as this hormone raises the cholesterol level in bile. These predisposing conditions include pregnancy, use of oral contraceptives, and obesity. Oddly, the rapid weight loss that follows stomach reduction surgery to treat morbid obesity commonly leads to gallstones because of changes in bile production and cholesterol precipitation in the bile. Drugs may dissolve gallstones, but often the cure is removal of the gallbladder in a **cholecystectomy.** Originally, this procedure required an extensive incision, but now the gallbladder is almost always removed laparoscopically through a small abdominal slit. Following gallbladder removal, bile flows directly into the duodenum through the common bile duct.

Ultrasonography, radiography, and magnetic resonance imaging are used to diagnose gallstones (see FIG. 13-14). **Endoscopic retrograde cholangiopancreatography** (ERCP) (FIG. 13-16) is a technique for visualizing and correcting biliary and pancreatic duct obstructions. Contrast medium is injected into the biliary system from the duodenum before imaging.

Pancreatitis

Pancreatitis, or inflammation of the pancreas, may result from alcohol abuse, drug toxicity, bile obstruction, infections, and other causes. Blood tests in acute pancreatitis show increased levels of the enzymes amylase and lipase. Glucose and bilirubin levels may also be elevated. Often the disease subsides with only symptomatic treatment.

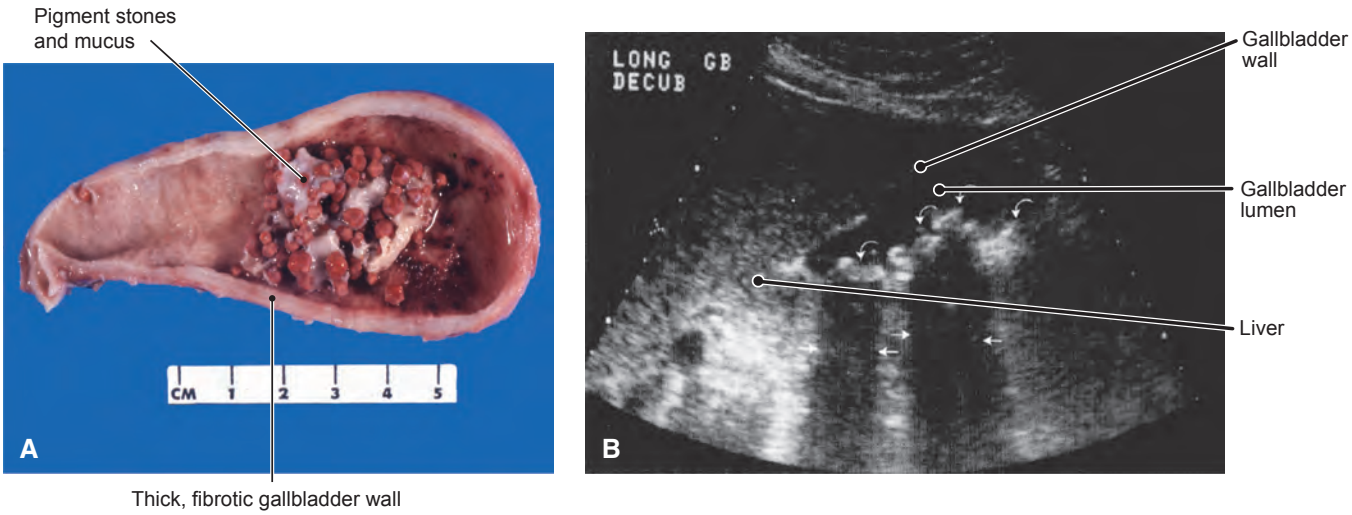

FIGURE 13-15 Cholelithiasis (gallstones). A. Formation of gallstones (cholelithiasis) causes gallbladder inflammation (cholecystitis) and bile obstruction. Numerous gallstones and a thickened gallbladder wall caused by chronic inflammation are evident in this figure. **B.** Sonogram shows dense gallstones (*curved arrows*). Shadows appear (between the *straight arrows*) because the sound waves cannot penetrate the stones (calculi).

extern.ir

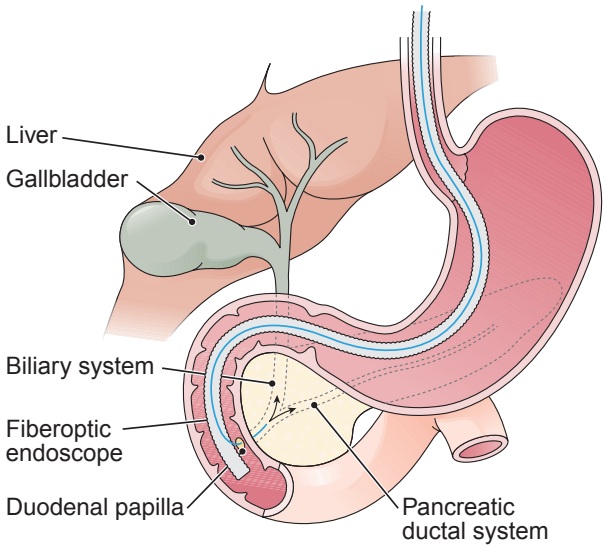

FIGURE 13-16 Endoscopic retrograde cholangiopancreatography (ERCP). A contrast medium is injected into the pancreatic and bile ducts in preparation for radiography.

Terminology *Key Terms*

The terms listed below are emphasized in this chapter. Knowing them will help you organize and prioritize your learning. These boldface terms are also found, collectively, with all chapter key terms in the Glossary.

Disorders

appendicitis *ah-pen-dih-SI-tis*	Inflammation of the appendix
ascites *ah-SI-teze*	Accumulation of fluid in the abdominal cavity; a form of edema; may be caused by heart disease, lymphatic or venous obstruction, cirrhosis, or changes in blood plasma composition
Barrett syndrome *BAH-ret*	Condition resulting from chronic esophagitis, as caused by gastroesophageal reflux disease; inflammatory injury can lead to esophageal spasms, scarring, strictures, and increased risk of cancer; also called Barrett esophagus
biliary colic *BIL-e-ar-e KOL-ik*	Acute abdominal pain caused by gallstones in the bile ducts
bilirubin *bil-ih-RU-bin*	A pigment released in the breakdown of hemoglobin from red blood cells; mainly excreted by the liver in bile
caries *KAR-eze*	Tooth decay
celiac disease *SE-le-ak*	Inability to absorb foods containing gluten, a protein found in wheat and some other grains; caused by an excess immune response to gluten
cholecystitis *ko-le-sis-TI-tis*	Inflammation of the gallbladder
cholelithiasis *ko-le-lih-THI-ah-sis*	The condition of having stones in the gallbladder; also used to refer to stones in the common bile duct
cirrhosis *sir-RO-sis*	Chronic liver disease with degeneration of liver tissue
Crohn disease *krone*	A chronic inflammatory disease of the gastrointestinal tract usually involving the ileum and colon

extern.ir

Terminology Key Terms (Continued)

diarrhea *di-ah-RE-ah*	The frequent passage of watery bowel movements
diverticulitis *di-ver-tik-u-LI-tis*	Inflammation of diverticula (small pouches) in the wall of the digestive tract, especially in the colon
diverticulosis *di-ver-tik-u-LO-sis*	The presence of diverticula, especially in the colon
dysphagia *dis-FA-je-ah*	Difficulty in swallowing
emesis *EM-eh-sis*	Vomiting
fistula *FIS-tu-lah*	An abnormal passageway between two organs such as between the rectum and anus (anorectal fistula), or from an organ to the body surface
gastroenteritis *gas-tro-en-ter-I-tis*	Inflammation of the stomach and intestine
gastroesophageal reflux disease (GERD) *gas-tro-e-sof-ah-JE-al*	Condition caused by reflux of gastric juices into the esophagus resulting in heartburn, regurgitation, inflammation, and possible damage to the esophagus; caused by weakness of the lower esophageal sphincter (LES) (see **FIG. 13-11**)
heartburn *HART-bern*	A warm or burning sensation felt behind the sternum and radiating upward; commonly associated with gastroesophageal reflux; medical name is pyrosis (pyr/o means "heat")
hemorrhoids *HEM-o-roydz*	Varicose veins in the rectum associated with pain, bleeding, and sometimes rectal prolapse; piles
hepatitis *hep-ah-TI-tis*	Inflammation of the liver; commonly caused by a viral infection
hepatomegaly *hep-ah-to-MEG-ah-le*	Enlargement of the liver
hiatal hernia *hi-A-tal*	A protrusion of the stomach through the opening (hiatus) in the diaphragm through which the esophagus passes (see **FIG. 3-4**)
icterus *IK-ter-us*	Jaundice
ileus *IL-e-us*	Intestinal obstruction; may be caused by lack of peristalsis (adynamic, paralytic ileus) or by contraction (dynamic ileus); intestinal matter and gas may be relieved by insertion of a drainage tube
intussusception *in-tuh-suh-SEP-shun*	Slipping of one intestinal segment into another part below it; occurs mainly in male infants in the ileocecal region (see **FIG. 13-10A**); may be fatal if untreated for more than 1 day
jaundice *JAWN-dis*	A yellowish color of the skin, mucous membranes, and whites of the eye caused by bile pigments in the blood (from French *jaune* meaning "yellow"); the main pigment is bilirubin, a byproduct of erythrocyte destruction (see **FIG. 13-14**)
leukoplakia *lu-ko-PLA-ke-ah*	White patches on mucous membranes, as on the tongue or cheeks, often resulting from smoking or other irritants; may be precancerous
nausea *NAW-zhah*	An unpleasant sensation in the upper abdomen that often precedes vomiting; typically occurs in digestive upset, motion sickness, and sometimes early pregnancy
occult blood *o-KULT*	Blood present in such small amounts that it can be detected only microscopically or chemically; in the feces, a sign of intestinal bleeding (*occult* means "hidden")
pancreatitis *pan-kre-ah-TI-tis*	Inflammation of the pancreas

(continued)

extern.ir

Terminology Key Terms (Continued)

peptic ulcer *PEP-tik UL-ser*	A lesion in the mucous membrane of the esophagus, stomach, or duodenum caused by the action of gastric juice
peritonitis *per-ih-to-NI-tis*	Inflammation of the peritoneum, the membrane that lines the abdominal cavity and covers the abdominal organs; may result from perforation of an ulcer, ruptured appendix, or reproductive tract infection, among other causes
polyp *POL-ip*	A tumor that grows on a stalk and bleeds easily
portal hypertension	An abnormal pressure increase in the hepatic portal system; may be caused by cirrhosis, infection, thrombosis, or a tumor
pyloric stenosis *pi-LOR-ik*	Narrowing of the opening between the stomach and the duodenum; pylorostenosis
regurgitation *re-gur-jih-TA-shun*	A backward flowing, such as the backflow of undigested food
splenomegaly *sple-no-MEG-ah-le*	Enlargement of the spleen
ulcerative colitis *UL-ser-ah-tiv ko-LI-tis*	Chronic ulceration of the rectum and colon; the cause is unknown, but may involve autoimmunity
volvulus *VOL-vu-lus*	Twisting of the intestine resulting in obstruction; usually involves the sigmoid colon and occurs most often in children and in the elderly; may be caused by congenital malformation, a foreign body, or adhesion; failure to treat immediately may result in death (see **FIG. 13-10B**)
Diagnosis and Treatment	
anastomosis *ah-nas-to-MO-sis*	A passage or communication between two vessels or organs; may be normal or pathologic or may be created surgically
barium study *BAH-re-um*	Use of barium sulfate as a liquid contrast medium for fluoroscopic or radiographic study of the digestive tract; can show obstruction, tumors, ulcers, hiatal hernia, and motility disorders, among other conditions
cholecystectomy *ko-le-sis-TEK-to-me*	Surgical removal of the gallbladder
Dukes classification	A system for staging colorectal cancer based on degree of bowel wall penetration and lymph node involvement; severity is graded from A to C
endoscopic retrograde cholangiopancreatography (ERCP) *ko-lan-je-o-pan-kre-ah-TOG-rah-fe*	A technique for viewing the pancreatic and bile ducts and for performing certain techniques to relieve obstructions; contrast medium is injected into the biliary system from the duodenum before radiographs are taken (see **FIG. 13-16**)
endoscopy *en-DOS-ko-pe*	Use of a fiberoptic endoscope for direct visual examination; GI studies include esophagogastroduodenoscopy, proctosigmoidoscopy (rectum and distal colon), and colonoscopy (all regions of the colon) (see **FIGS. 13-7** and **13-8**)
Ostomy *OS-to-me*	An opening into the body; generally refers to an opening created for elimination of body waste; also refers to the operation done to create such an opening (see stoma)
stoma *STO-mah*	A surgically created opening to the body surface or between two organs (literally "mouth") (see **FIG. 13-9**)

extern.ir

Terminology *Enrichment Terms*

The terms listed below expand on the key terms to increase your knowledge of this chapter topic.

Normal Structure and Function

bolus *BO-lus*	A mass, such as the rounded mass of food that is swallowed
cardia *KAR-de-ah*	The part of the stomach near the esophagus, named for its closeness to the heart
chyme *kime*	The semiliquid partially digested food that moves from the stomach into the small intestine
defecation *def-eh-KA-shun*	The evacuation of feces from the rectum
deglutition *deg-lu-TISH-un*	Swallowing
duodenal bulb *du-o-DE-nal*	The part of the duodenum near the pylorus; the first bend (flexure) of the duodenum
duodenal papilla *du-o-DE-nalpah-PIL-lah*	The raised area where the common bile duct and pancreatic duct enter the duodenum (see **FIG. 13-16**); papilla of Vater (*FAH-ter*)
greater omentum *o-MEN-tum*	A fold of the peritoneum that extends from the stomach over the abdominal organs
hepatic flexure *heh-PAT-ik FLEK-shur*	The right bend of the colon, forming the junction between the ascending colon and the transverse colon (see **FIG. 13-1**)
ileocecal valve *il-e-o-SE-kal*	A valve-like structure between the ileum of the small intestine and the cecum of the large intestine
mesentery *MES-en-ter-e*	The portion of the peritoneum that folds over and supports the intestine
mesocolon *mes-o-KO-lon*	The portion of the peritoneum that folds over and supports the colon
papilla of Vater	See duodenal papilla
rugae *RU-je*	The large folds in the stomach's lining seen when the stomach is empty
sphincter of Oddi *OD-e*	The muscular ring at the opening of the common bile duct into the duodenum
splenic flexure *SPLEN-ik FLEK-shur*	The left bend of the colon, forming the junction between the transverse colon and the descending colon (see **FIG. 13-1**)

Disorders

achalasia *ak-ah-LA-ze-ah*	Failure of a smooth muscle to relax, especially the lower esophageal sphincter, so that food is retained in the esophagus
achlorhydria *a-klor-HI-dre-ah*	Lack of hydrochloric acid in the stomach; opposite is hyperchlorhydria
anorexia *an-o-REK-se-ah*	Loss of appetite; anorexia nervosa is a psychologically induced refusal or inability to eat (adjectives: anorectic, anorexic)
aphagia *ah-FA-je-ah*	Inability to swallow or difficulty in swallowing; refusal or inability to eat
aphthous ulcer *AF-thus*	An ulcer in a mucous membrane, as in the mouth

(continued)

extern.ir

Terminology Enrichment Terms (Continued)

bruxism *BRUK-sizm*	Clenching and grinding of the teeth, usually during sleep
bulimia *bu-LEME-e-ah*	Excessive, insatiable appetite; a disorder characterized by overeating followed by induced vomiting, diarrhea, or fasting
cachexia *kah-KEK-se-ah*	Profound ill health, malnutrition, and wasting
cheilosis *ki-LO-sis*	Cracking at the corners of the mouth, often caused by B vitamin deficiency (root cheil/o means "lip")
cholestasis *ko-le-STA-sis*	Stoppage of bile flow; also pronounced *ko-LES-tah-sis*
constipation *con-stih-PA-shun*	Infrequency or difficulty in defecation and the passage of hard, dry feces
dyspepsia *dis-PEP-se-ah*	Poor or painful digestion
eructation *eh-ruk-TA-shun*	Belching
familial adenomatous polyposis (FAP) *fah-MIL-e-al ad-eh-NO-mah-tus pol-ih-PO-sis*	A hereditary condition in which multiple polyps form in the colon and rectum, predisposing one to colorectal cancer
flatulence *FLAT-u-lens*	Condition of having gas or air in the GI tract
flatus *FLA-tus*	Gas or air in the gastrointestinal tract; gas or air expelled through the anus
hematemesis *he-mah-TEM-eh-sis*	Vomiting of blood
irritable bowel syndrome (IBS)	A chronic stress-related disease characterized by diarrhea, constipation, and pain associated with rhythmic intestinal contractions; mucous colitis; spastic colon
megacolon *meg-ah-KO-lon*	An extremely dilated colon; usually congenital but may occur in acute ulcerative colitis
melena *MEL-e-nah*	Black tarry feces resulting from blood in the intestines; common in newborns; may also be a sign of gastrointestinal bleeding
obstipation *ob-stih-PA-shun*	Extreme constipation
pernicious anemia *per-NISH-us*	A form of anemia caused by the stomach's failure to secrete intrinsic factor, a substance needed for the absorption of vitamin B_{12}
pilonidal cyst *pi-lo-NI-dal*	A dermal cyst in the sacral region, usually at the top of the cleft between the buttocks; may become infected and begin to drain
thrush	Fungal infection of the mouth and/or throat caused by *Candida*; appears as mucosal white patches or ulcers
Vincent disease *VIN-sent*	Severe gingivitis with necrosis associated with the bacterium *Treponema vincentii*; necrotizing ulcerative gingivitis; trench mouth
Diagnosis and Treatment	
appendectomy *ap-en-DEK-to-me*	Surgical removal of the appendix

extern.ir

Terminology Enrichment Terms (Continued)

bariatrics *bar-e-AT-riks*	The branch of medicine concerned with prevention and control of obesity and associated diseases (from Greek *baros*, meaning "weight")
bariatric surgery	Surgery to reduce the size of the stomach and reduce nutrient absorption in the treatment of morbid obesity; most common is gastric bypass surgery, which involves division of the stomach and anastomosis of its upper part to the small intestine (jejunum) (**FIG. 13-17**); other methods are gastric stapling, partitioning of the stomach with rows of staples, and gastric banding, which involves laparoscopic placement of an adjustable loop (Lap-Band) that reduces stomach capacity
Billroth operation	Gastrectomy with anastomosis of the stomach to the duodenum (Billroth I) or to the jejunum (Billroth II) (**FIG. 13-18**)
gavage *gah-VAHZH*	Process of feeding through a nasogastric tube into the stomach
lavage *lah-VAJ*	Washing out of a cavity; irrigation
manometry *man-OM-eh-tre*	Measurement of pressure; pertaining to the GI tract, measurement of pressure in the portal system as a sign of obstruction
Murphy sign	Inability to take a deep breath when fingers are pressed firmly below the right arch of the ribs (below the liver); signifies gallbladder disease
nasogastric (NG) tube *na-zo-GAS-trik*	Tube that is passed through the nose into the stomach (**FIG. 13-19**); may be used for emptying the stomach, administering medication, giving liquids, or sampling stomach contents
parenteral hyperalimentation *pah-REN-ter-al*	Complete intravenous feeding for one who cannot take in food; total parenteral nutrition (TPN)
percutaneous endoscopic gastrostomy (PEG) tube	Tube inserted into the stomach for long-term feeding (**FIG. 13-20**)
vagotomy *va-GOT-o-me*	Interruption of vagal nerve impulses to reduce stomach secretions in the treatment of a gastric ulcer; originally done surgically but may also be done with drugs
Drugs	
antacid *ant-AS-id*	Agent that counteracts acidity, usually gastric acidity
antidiarrheal *an-te-di-ah-RE-al*	Drug that treats or prevents diarrhea by reducing intestinal motility or absorbing irritants and soothing the intestinal lining
antiemetic *an-te-eh-MET-ik*	Agent that relieves or prevents nausea and vomiting
antiflatulent *an-te-FLAT-u-lent*	Agent that prevents or relieves flatulence
antispasmodic *an-te-spas-MOD-ik*	Agent that relieves spasm, usually of smooth muscle
emetic *eh-MET-ik*	An agent that causes vomiting
histamine H_2 antagonist	Drug that decreases secretion of stomach acid by interfering with the action of histamine at H_2 receptors; used to treat ulcers and other gastrointestinal problems; H_2-receptor–blocking agent
laxative *LAK-sah-tiv*	Agent that promotes elimination from the large intestine; types include stimulants, substances that retain water (hyperosmotics), stool softeners, and bulk-forming agents
proton pump inhibitor (PPI)	Agent that inhibits gastric acid secretion by blocking the transport of hydrogen ions (protons) into the stomach

extern.ir

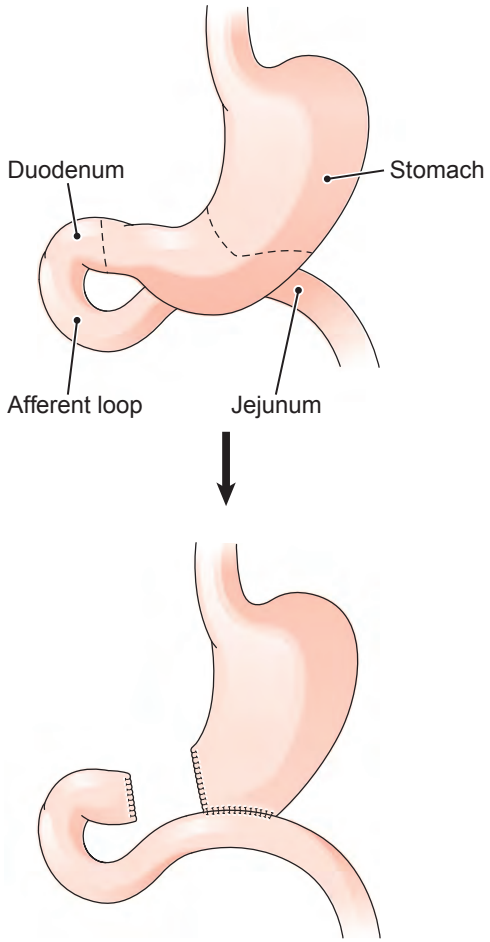

FIGURE 13-17 Gastric bypass. For treatment of morbid obesity, a small pouch is created in the stomach to limit food intake. The pouch is attached to the jejunum in a gastrojejunostomy to bypass the stomach and reduce nutrient absorption.

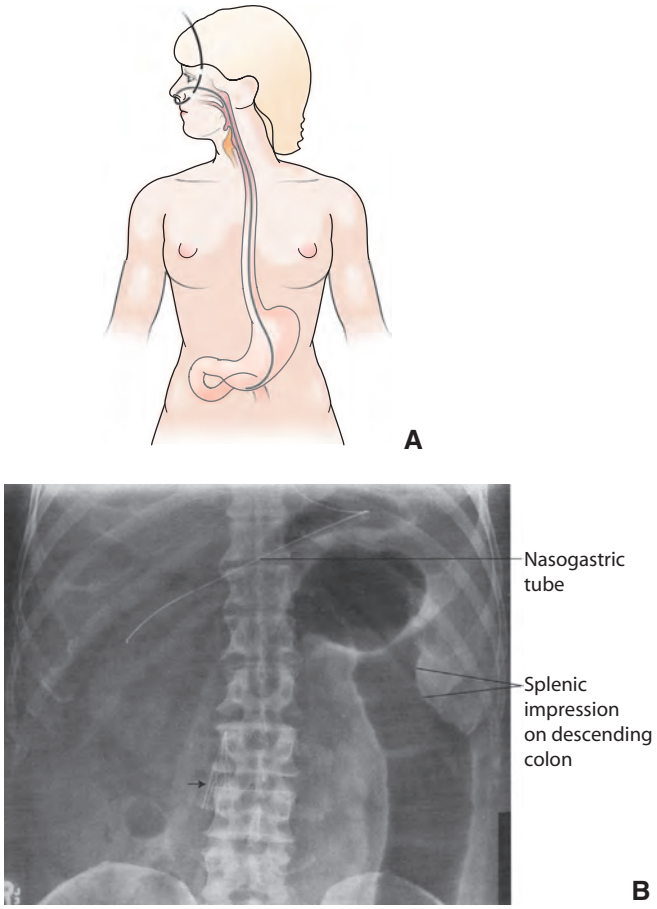

FIGURE 13-19 A nasogastric (NG) tube. A. Diagram showing an NG tube in place. **B.** Abdominal radiograph showing an NG tube. The filter (*arrow*) shown in the inferior vena cava is meant to trap emboli that might originate in the lower extremities and pelvis.

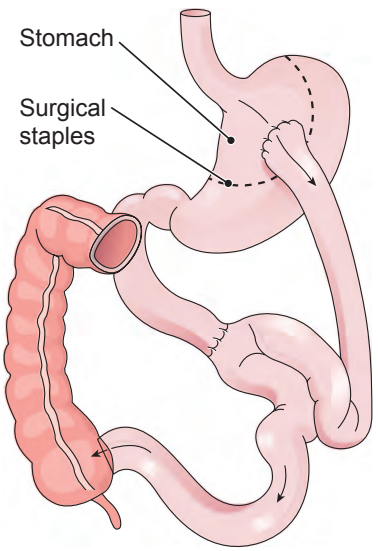

FIGURE 13-18 Gastrojejunostomy (Billroth II operation). The dotted lines show the portion removed.

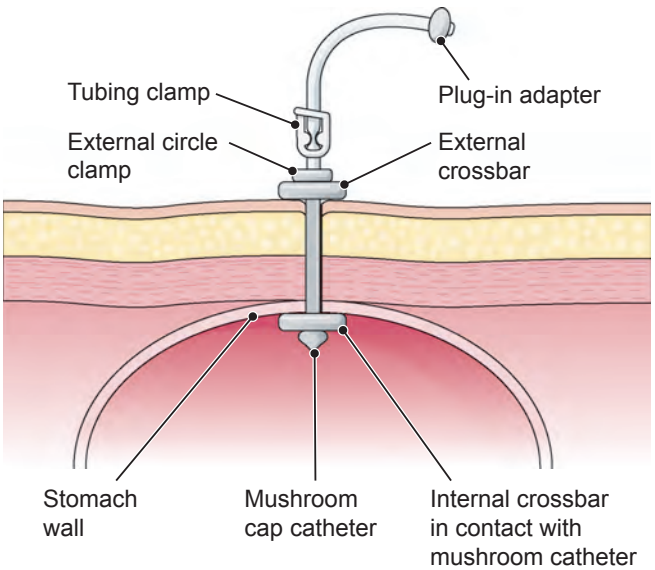

FIGURE 13-20 Percutaneous endoscopic gastrostomy (PEG) tube. The tube is shown in place in the stomach.

extern.ir

Terminology *Abbreviations*

The abbreviations listed below are emphasized in this chapter. These are also found, collectively, with all chapter abbreviations in Appendix 2.

BE	Barium enema (for radiographic study of the colon)
BM	Bowel movement
CBD	Common bile duct
EGD	Esophagogastroduodenoscopy
ERCP	Endoscopic retrograde cholangiopancreatography
FAP	Familial adenomatous polyposis
GERD	Gastroesophageal reflux disease
GI	Gastrointestinal
HAV	Hepatitis A virus
HBV	Hepatitis B virus
HCV	Hepatitis C virus
HDV	Hepatitis D virus
HEV	Hepatitis E virus
HCl	Hydrochloric acid
IBD	Inflammatory bowel disease
IBS	Irritable bowel syndrome
LES	Lower esophageal sphincter
NG	Nasogastric (tube)
N&V	Nausea and vomiting
N/V/D	Nausea, vomiting, and diarrhea
PEG	Percutaneous endoscopic gastrostomy (tube)
PONV	Postoperative nausea and vomiting
PPI	Proton pump inhibitor
TPN	Total parenteral nutrition
UGI	Upper gastrointestinal (radiograph series)

Case Study Revisited

Abe's Follow-Up Study

When Abe returns after 4 weeks for his follow-up appointment in primary care, he explains that he started feeling better, so he stopped taking the medicine after 3 weeks. Now his symptoms have returned. They are waking him up at night, and he also now reports experiencing mild dysphagia. The physician explained that he must remain on his medication. Medication nonadherence, when patients do not take their medications, is unfortunately fairly common especially among patients with chronic disease. The physician knew this and educated Abe on understanding the importance of following the directions that he was given on the prescription and from his previous appointment. Stopping a medication early, as Abe did, caused his symptoms to return.

Abe's appointment for his endoscopy is in 3 weeks. The physician emphasized that Abe continue his medication and go to his endoscopy appointment. Abe did follow the physician's instructions and the results from the endoscopy indicate that he does indeed have moderate erosive esophagitis. There is a small hiatal hernia present as well.

Following the study, Abe is prescribed a PPI, 40 mg/day and encouraged to take it on a regular basis. He is counseled to decrease the fat in his meals, avoid lying down for at least 2 hours after meals, and limit alcohol intake. He returns 6 weeks later with marked improvement in compliance and total control of his symptoms. He is instructed to continue the PPI and to return in 6 months for reassessment.

extern.ir

CHAPTER 13

Review

This review tests your understanding of the content introduced in this chapter. Follow the instructions for each exercise and check your answers in Appendix 11.

LABELING EXERCISE

THE DIGESTIVE SYSTEM

Write the name of each numbered part on the corresponding line of the answer sheet.

Anus
Appendix
Ascending colon
Cecum
Descending colon
Duodenum (of small intestine)
Esophagus
Gallbladder
Liver
Mouth
Pancreas
Pharynx
Rectum
Salivary glands
Sigmoid colon
Small intestine
Stomach
Teeth
Tongue
Transverse colon

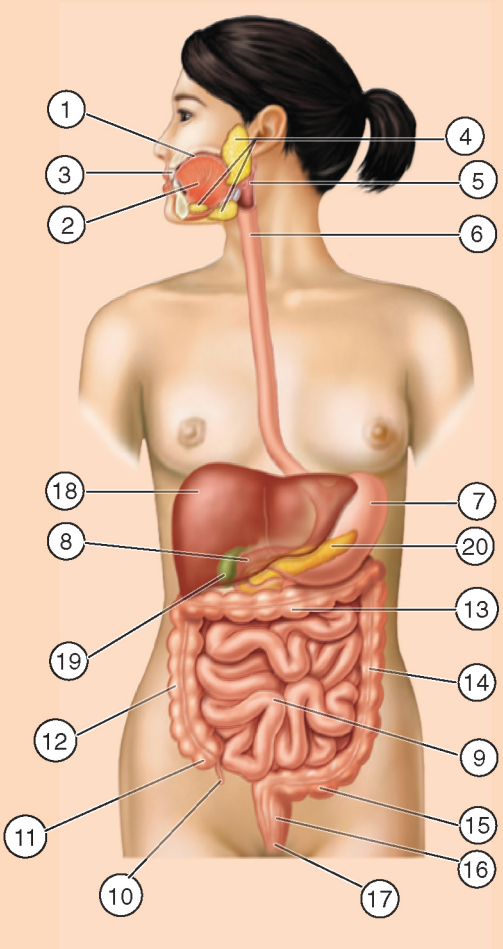

1. _____
2. _____
3. _____
4. _____
5. _____
6. _____
7. _____
8. _____
9. _____
10. _____
11. _____
12. _____
13. _____
14. _____
15. _____
16. _____
17. _____
18. _____
19. _____
20. _____

extern.ir

ACCESSORY ORGANS OF DIGESTION

Write the name of each numbered part on the corresponding line of the answer sheet.

Common bile duct
Common hepatic duct
Cystic duct
Diaphragm
Duodenum
Gallbladder
Liver
Pancreas
Pancreatic duct

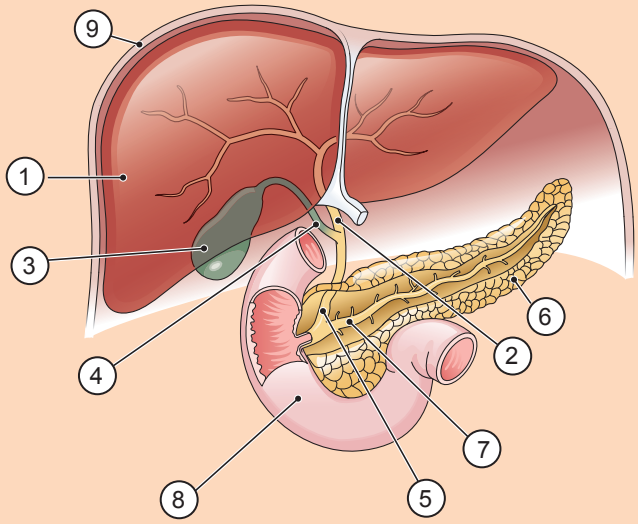

1. _____
2. _____
3. _____
4. _____
5. _____
6. _____
7. _____
8. _____
9. _____

TERMINOLOGY

MATCHING

Match the following terms, and write the appropriate letter to the left of each number.

____	1. sublingual	a. pertaining to the cheek
____	2. emetic	b. pertaining to the gum
____	3. gingival	c. substance that induces vomiting
____	4. agnathia	d. hypoglossal
____	5. buccal	e. absence of the jaw
____	6. enzyme	a. tooth decay
____	7. caries	b. wave-like muscular contractions
____	8. ileum	c. organic catalyst
____	9. peristalsis	d. terminal portion of the small intestine
____	10. icterus	e. jaundice
____	11. choledochal	a. a type of liver disease
____	12. cholelithotripsy	b. pertaining to the common bile duct
____	13. cholangiectasis	c. crushing of a biliary calculus
____	14. leukoplakia	d. dilatation of a bile duct
____	15. cirrhosis	e. white patches on a mucous membrane

Enrichment Terms

____	16. eructation	a. part of the stomach near the esophagus
____	17. cardia	b. chewing
____	18. achlorhydria	c. belching
____	19. bolus	d. lack of hydrochloric acid in the stomach
____	20. mastication	e. a mass, as of food

extern.ir

____ 21. gavage	a. swallowing
____ 22. bruxism	b. tooth grinding
____ 23. deglutition	c. malnutrition and wasting
____ 24. cachexia	d. feeding through a tube
____ 25. chyme	e. partially digested food

____ 26. antiflatulent	a. agent that controls loose watery stools
____ 27. antidiarrheal	b. agent that relieves heartburn, counteracts acidity
____ 28. antiemetic	c. agent that relieves or prevents gas
____ 29. antacid	d. agent that relieves spasm
____ 30. antispasmodic	e. agent that relieves or prevents nausea and vomiting

FILL IN THE BLANKS

Complete the sentence with the correct term(s).

31. Any surgical procedure to reduce the size of the stomach in the treatment of obesity is described as _____ .
32. The blind pouch at the beginning of the colon is the _____ .
33. The hepatic portal system carries blood to the _____ .
34. The organ that stores bile is the _____ .
35. The large serous membrane that lines the abdominal cavity and supports the abdominal organs is _____ .
36. Glossorrhaphy is suture of the _____ .
37. The palatine tonsils are located on either side of the _____ .
38. Dentin is the main substance of a(n) _____ .
39. From its name you might guess that the buccinator muscle is in the _____ .
40. An enterovirus is a virus that infects the _____ .
41. The anticoagulant heparin is found throughout the body, but it is named for its presence in the _____ .
42. The substance cholesterol is named for its chemical composition (sterol) and for its presence in the _____ .

Refer to Abe's opening case study.

43. Protrusion of the stomach through an opening in the diaphragm is termed a(n) _____ .
44. Difficulty in swallowing is technically called _____ .
45. The histamine-2 receptor antagonist used to treat Abe reduces secretion of (see Appendix 10) _____ .

DEFINITIONS

Write words for the following definitions.

46. liver enlargement _____
47. a dentist who specializes in treating the tissues around the teeth _____
48. surgical excision of the stomach _____
49. surgical repair of the palate _____
50. narrowing of the pylorus _____
51. inflammation of the pancreas _____

extern.ir

52. medical specialist who treats diseases of the stomach and intestine _____
53. surgical creation of an opening into the colon _____
54. surgical creation of a passage between the stomach and the duodenum _____
55. within (intra-) the liver _____

PLURALS

Write the plural form of the following words.

56. diverticulum _____
57. gingiva _____
58. calculus _____
59. anastomosis _____

SPELL CHECK

Write the correct spelling on the line to the right of the term.

60. hietal hernia _____
61. dypepsia _____
62. inginal herna _____
63. ikterus _____
64. pyeloric stenoses _____
65. diarryhea _____

TRUE–FALSE

Examine the following statements. If the statement is true, write T in the first blank. If the statement is false, write F in the first blank, and correct the statement by replacing the underlined word in the second blank.

	True or False	Correct Answer
66. In the opening case study, Abe is experiencing his epigastric pain in the region <u>below</u> the stomach.	_____	_____
67. The middle portion of the small intestine is the <u>duodenum</u>.	_____	_____
68. Polysialia is the excess secretion of <u>bile</u>.	_____	_____
69. The cystic duct carries bile to and from the <u>gallbladder</u>.	_____	_____
70. The appendix is attached to the <u>cecum</u>.	_____	_____
71. The common hepatic duct and the cystic duct merge to form the <u>common bile duct</u>.	_____	_____
72. An emetic is an agent that promotes <u>diarrhea</u>.	_____	_____
73. A <u>lavage</u> is an irrigation of a cavity.	_____	_____

extern.ir

ELIMINATIONS

In each of the sets below, underline the word that does not fit in with the rest, and explain the reason for your choice.

74. gingiva — villus — palate — uvula — incisor

_____

75. spleen — cecum — colon — rectum — anus

_____

76. pancreas — gallbladder — liver — pylorus — salivary glands

_____

77. diarrhea — emesis — nausea — regurgitation — amylase

_____

ABBREVIATIONS

Write the meaning of the following abbreviations.

78. N&V _____
79. NG _____
80. TPN _____
81. GERD _____
82. EGD _____
83. GI _____
84. HCl _____
85. PPI _____
86. PEG (tube) _____
87. HAV _____

WORD BUILDING

Write a word for the following definitions using the word parts given. Each word part can be used more than once.

-al	cec/o	r	-pexy	-cele	proct/o	-itis	-rhaphy	ile/o

88. inflammation of the cecum _____
89. suture of the rectum _____
90. fixation of the cecum _____
91. hernia of the rectum _____
92. pertaining to the ileum and cecum _____
93. fixation of the ileum _____
94. inflammation of the rectum _____
95. suture of the cecum _____
96. inflammation of the ileum _____

extern.ir

WORD ANALYSIS

Define each of the following words and give the meaning of the word parts in each. Use a dictionary if necessary.

97. myenteric (*mi-en-TER-ik*)
    a. my/o _____
    b. enter/o _____
    c. -ic _____
98. cholescintigraphy (*ko-le-sin-TIG-rah-fe*)
    a. chole _____
    b. scinti _____
    c. -graphy _____
99. parenteral (*pah-REN-ter-al*)
    a. par(a) _____
    b. enter/o _____
    c. -al _____
100. nasogastric
    a. nas/o _____
    b. gastr/o _____
    c. -ic _____
101. xerostomia
    a. xero- _____
    b. stoma _____
    c. -ia _____

extern.ir

Additional Case Studies

Case Study 13-1: Cholecystectomy

Heather, a 42 y/o obese woman, entered the hospital with nausea and vomiting, flatulence and eructation, a fever of 100.5°F, and continuous right upper quadrant (RUQ) and subscapular pain. Examination on admission showed rebound tenderness in the RUQ with a positive Murphy sign. Her skin, nails, and conjunctivae were yellowish, and she reported frequent clay-colored stools. Her leukocyte count was 16,000. An ERCP and ultrasound of the abdomen suggested many small stones in her gallbladder and possibly in the common bile duct. Her diagnosis was cholecystitis with cholelithiasis.

A laparoscopic cholecystectomy was attempted with an intraoperative cholangiogram and common bile duct exploration. Because of Heather's size and some unexpected bleeding, visualization was difficult, and the procedure was converted to an open approach. Small stones and granular sludge were irrigated from her common duct, and the gallbladder was removed. She had a T-tube inserted into the duct for bile drainage; this tube was removed on the second postoperative day. An NG tube in place before and during the surgery was also removed on Day 2. She was discharged on the fifth postoperative day with a prescription for prn pain medication.

Case Study 13-1 Questions

To check your answers go to Appendix 11.

Multiple Choice. *Select the best answer, and write the letter of your choice to the left of each number.*

_____ 1. Flatulence and eructation represent
- a. regurgitation of chyme
- b. sounds heard only by abdominal auscultation
- c. passage of gas or air from the GI tract
- d. muscular movement of the alimentary tract

_____ 2. Subscapular pain is experienced (see **FIG. 2-17**)
- a. above the navel
- b. below the shoulder blade
- c. below the sternum
- d. beside the shoulder blade

_____ 3. Yellowish conjunctivae indicate
- a. emesis
- b. jaundice
- c. inflammation
- d. ptosis

_____ 4. The common duct is more properly called the
- a. common bile duct
- b. common duodenal duct
- c. unified cystic duct
- d. joined bile duct

_____ 5. The Murphy sign is a test for pain
- a. under the ribs on the left
- b. near the spleen
- c. in the lower right abdomen
- d. under the ribs on the right

_____ 6. The NG tube is inserted through the _____ and terminates in the _____.
- a. nose, stomach
- b. nostril, gallbladder
- c. glottis, nephron
- d. anus, cecum

extern.ir

Write the meaning of each of the following abbreviations.

7. ERCP _____
8. RUQ _____
9. NG _____

Give the word or words in the case study with each of the following meanings.

10. presence of stones in the gallbladder _____
11. endoscopic surgery of the gallbladder _____
12. inflammation of the gallbladder _____
13. radiographic study of the gallbladder and biliary system _____

Case Study 13-2: Colonoscopy With Biopsy

Sam, a 24 y/o man, had a recent history of lower abdominal pain with frequent loose mucoid stools. He described symptoms of occasional dysphagia, dyspepsia, nausea, and aphthous ulcers of his tongue and buccal mucosa. A previous barium enema (BE) examination showed some irregularities in the sigmoid and rectal segments of his large bowel. Stool samples for culture, ova, and parasites were negative. His tentative diagnosis was irritable bowel syndrome (IBS). He followed a lactose-free, low-residue diet and took Imodium to reduce intestinal motility. His gastroenterologist recommended a colonoscopy. After a 2-day regimen of a soft to clear liquid diet, laxatives, and an enema, the morning of the procedure, he reported to the endoscopy unit. He was transported to the procedure room. ECG electrodes, a pulse oximeter sensor, and a blood pressure cuff were applied for monitoring, and an IV was inserted in Sam's right arm. An IV bolus of propofol was given, and Sam was positioned on his left side. The colonoscope was gently inserted through the anal sphincter and advanced proximally.

The physician was able to advance past the ileocecal valve, examining the entire length of the colon. Ulcerated granulomatous lesions were seen throughout the colon with a concentration in the sigmoid segment. Many biopsy specimens were taken. The mucosa of the distal ileum was normal. Pathology examination of the biopsy samples was expected to establish a diagnosis of IBD.

extern.ir

Case Study 13-2 Questions

To check your answers go to Appendix 11.

Multiple Choice. *Select the best answer, and write the letter of your choice to the left of each number.*

_____ 1. Dysphagia and dyspepsia are difficulty or pain with
a. chewing and intestinal motility
b. swallowing and digestion
c. breathing and absorption
d. swallowing and nutrition

_____ 2. The buccal mucosa is in the
a. nostril, medial side
b. mouth, inside of the cheek
c. greater curvature of the stomach
d. base of the tongue

_____ 3. A gastroenterologist is a physician who specializes in the study of
a. mouth and teeth
b. stomach, intestines, and related structures
c. musculoskeletal system
d. nutritional and weight loss diets

_____ 4. The splenic and hepatic flexures are bends in the colon near the
a. liver and splanchnic vein
b. common bile duct and biliary tree
c. spleen and appendix
d. spleen and liver

_____ 5. Intestinal motility refers to
a. peristalsis
b. chewing
c. absorption
d. ascites

_____ 6. A colonoscopy is
a. a radiograph of the small intestine
b. an endoscopic study of the esophagus
c. an upper endoscopy with biopsy
d. an endoscopic examination of the large bowel

_____ 7. The ileocecal valve is
a. part of a colonoscope
b. at the distal ileum
c. in the pylorus
d. at the proximal ileum

extern.ir

Write the meaning of each of the following abbreviations.

8. IBD _____
9. BE _____
10. IBS _____

Give the word or words in the case study with each of the following meanings.

11. ring of muscle that regulates the distal opening of the colon _____
12. surgical excision of tissue for pathology examination _____
13. difficulty in swallowing _____

extern.ir

CHAPTER 14

Urinary System

Pretest

Multiple Choice. **Select the best answer, and write the letter of your choice to the left of each number. To check your answers go to Appendix 11.**

_____ 1. The organ that forms urine is the
a. cystic duct
b. bladder
c. gallbladder
d. kidney

_____ 2. The tube that carries urine out of the body is the
a. ureter
b. pylorus
c. urethra
d. peristalsis

_____ 3. The hormone erythropoietin stimulates production of
a. leukocytes
b. saliva
c. red blood cells
d. platelets

_____ 4. Micturition is the scientific term for
a. urination
b. digestion
c. breathing
d. retention

_____ 5. With reference to the urinary system, the root *cyst/o* means
a. ureter
b. urinary stasis
c. urinary bladder
d. kidney

_____ 6. Nephritis is inflammation of the
a. liver
b. intestine
c. bladder
d. kidney

_____ 7. Separation of substances by passage through a membrane is termed
a. absorption
b. deglutition
c. centrifugation
d. dialysis

_____ 8. A substance that promotes urinary output is a(n)
a. hypertensive
b. diuretic
c. channel blocker
d. enzyme

extern.ir

Learning Objectives

After careful study of this chapter, you should be able to:

1. Describe the functions of the urinary system. ***P462***
2. Name and describe the organs of the urinary tract, and cite the functions of each. ***P462***
3. Identify the portions of the nephron. ***P462***
4. Explain the relationship between the kidney and the blood circulation. ***P463***
5. Describe the processes involved in urine formation. ***P464***
6. Explain how urine is transported and released from the body. ***P465***
7. Identify and use the roots pertaining to the urinary system. ***P466***
8. Describe six major disorders of the urinary system. ***P469***
9. Interpret abbreviations used in reference to the urinary system. ***P479***
10. Analyze medical terms in case studies pertaining to the urinary system. ***PP461, 486***

Case Study: Jade's Stress Incontinence

Chief Complaint

Jade is a 52 y/o female with a history of stress incontinence. The condition has affected her quality of life, as she is not able to be active in athletics without worrying about urinary leakage under physical strain. Jade has cut back on her sports participation and currently is involved in only two golf leagues. Although the incontinence continues to be a problem, she does not want to take medication or have corrective surgery. Jade heard about a minimally invasive clinical research study that could potentially address the incontinence. She decided to investigate to see if she could be a candidate for the study.

Examination

Jade met with the clinical research nurse who explained the study to her. She was told the study hoped to achieve around 75% improvement, which Jade found acceptable. A urologic history was taken involving questions relating to urinary frequency, urgency, and nocturia (nighttime urination). A few procedures were required at the beginning of the study that would determine eligibility. Jade was required to provide a clean-catch specimen and underwent a cystometrography (CMG) and a cystoscopy. The results indicated that she would be a good candidate for the clinical research study. She was required to maintain a urinary diary for 2 weeks and record when the stress incontinence and urgency occurred prior to the procedure. In addition, she was required to have follow-up appointments, at various intervals, over the next 3 years. Jade signed the required paperwork and proceeded with the study.

Clinical Course

The clinical research study involved taking muscle cells from Jade's thigh, growing them in a laboratory, and then reinserting cultured stem cells (myoblasts) into the area surrounding the urethra. Theoretically, these actively growing cells would repair urethral sphincter muscle deficiency and/or damage, thus improving sphincter function and providing greater control of urination. The urologist took a punch biopsy from Jade's thigh muscle to obtain the necessary cells. After laboratory processing, the active cells were injected into place. They were allowed to settle and grow for 3 months, at which time another CMG and cystoscopy were performed. A comparison was made with the original test results to see if there was any improvement in the stress incontinence. All procedures were conducted in the office with minimal discomfort.

Case Study Revisited: Once you complete this chapter, please review the case follow-up on p. 479.

extern.ir

Ancillaries *At-A-Glance*

Visit the web resource to access the following resources.

Learning Resources

- eBook
- A&P Module with Heart & Lung Sounds
- Image Bank
- TestPrep
- Animations
- Audio Pronunciation Glossary

Introduction

The urinary system excretes metabolic waste. While forming and eliminating urine, it also regulates the composition, volume, and acid–base balance (pH) of body fluids. In several ways, kidney activity affects the circulation and blood pressure. The urinary system is thus of critical importance in maintaining homeostasis, the state of internal balance. As shown in **FIGURE 14-1**, the urinary system consists of:

- Two kidneys, the organs that form urine
- Two ureters, which transport urine from the kidneys to the bladder
- The urinary bladder, which stores and eliminates urine
- The urethra, which carries urine out of the body

The Kidneys

The kidneys are the organs that form **urine** from substances filtered out of the blood. In addition to metabolic wastes, urine contains water and ions, so its formation is important in regulating the blood's volume and composition. In addition, the kidneys produce two substances that act on the circulatory system:

- **Erythropoietin** (**EPO**), a hormone that stimulates red blood cell production in the bone marrow.
- **Renin**, an enzyme that functions to raise blood pressure. It activates a blood component called **angiotensin**, which causes constriction of the blood vessels. The drugs known as ACE inhibitors (angiotensin-converting enzyme inhibitors) lower blood pressure by interfering with the production of angiotensin.

KIDNEY LOCATION AND STRUCTURE

The **kidneys** are located behind the peritoneum in the lumbar region. On the top of each kidney rests an adrenal gland. The kidney is encased in a capsule of fibrous connective tissue overlaid with fat. An outermost layer of connective tissue supports the kidney and anchors it to the body wall.

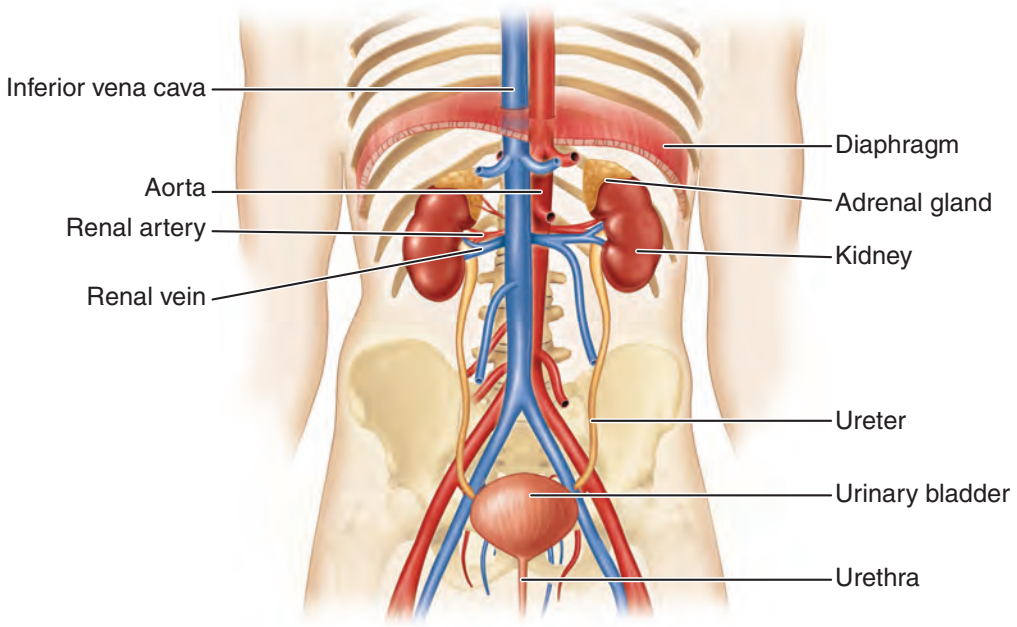

FIGURE 14-1 The urinary system. This system consists of the kidneys, ureters, urinary bladder, and urethra. It is shown here along with the diaphragm, nearby blood vessels, and the adrenal glands.

extern.ir

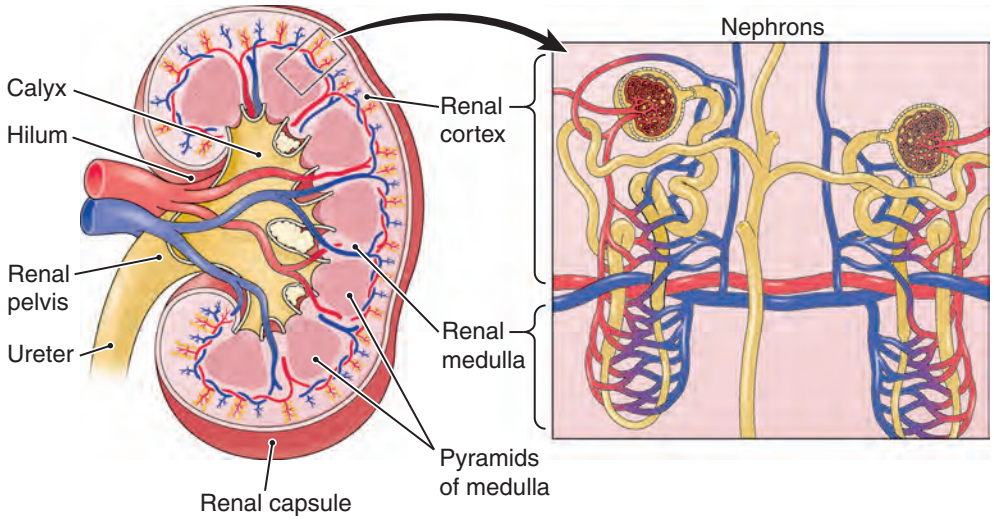

FIGURE 14-2 The kidney. A longitudinal section (*left*) through the kidney shows its internal structure. The hilum is the point where blood vessels and ducts connect with the kidney. An enlarged diagram of nephrons. Each kidney contains more than 1 million nephrons (*right*).

If you look inside the kidney (FIG. 14-2), you will see that it has an outer region, the **renal cortex**, and an inner region, the **renal medulla** (BOX 14-1). The medulla is divided into triangular sections, the **renal pyramids**. These pyramids have a lined appearance because they are made up of the loops and collecting tubules of the **nephrons**, the kidney's functional units. Each collecting tubule empties into a urine-collecting area called a **calyx** (from the Latin word meaning "cup"). Several of the smaller minor calices merge to form a major calyx. The major calices then unite to form the **renal pelvis**, the upper funnel-shaped portion of the **ureter**.

THE NEPHRONS

The tiny working units of the kidneys are the nephrons (FIG. 14-3). Each of these microscopic structures is basically a single tubule coiled and folded into various shapes. The tubule begins with a cup-shaped **glomerular** (Bowman) **capsule**, which is part of the nephron's blood-filtering device. The tubule then folds into the proximal tubule, straightens out to form the nephron loop (loop of Henle), coils again into the distal tubule, and then finally straightens out to form a collecting duct.

BLOOD SUPPLY TO THE KIDNEY

Blood enters the kidney through a renal artery, a short branch of the abdominal aorta. This vessel subdivides into smaller vessels as it branches throughout the kidney tissue, until finally blood is brought into the glomerular capsule and circulated through a cluster of capillaries, called a **glomerulus**, within the capsule.

Blood leaves the kidney by a series of vessels that finally merge to form the renal vein, which empties into the inferior vena cava.

Urine Formation

As blood flows through the glomerulus, blood pressure forces materials through the glomerular wall and through the wall of the glomerular capsule into the nephron. The fluid that enters the nephron, the **glomerular filtrate**, consists mainly

FOCUS ON WORDS
Words That Serve Double Duty

BOX 14-1

Some words appear in more than one body system to represent different structures. The medulla of the kidney is the inner portion of the organ. Other organs, such as the adrenal gland, ovary, and lymph nodes, may also be divided into a central medulla and outer cortex. But *medulla* means "marrow," and this term also applies to the bone marrow, to the spinal cord, and to the part of the brain that connects with the spinal cord, the medulla oblongata.

A ventricle is a chamber. There are ventricles in the brain and in the heart. The word *fundus* means the back part or base of an organ. The uterus has a fundus, the upper rounded portion farthest from the cervix, as does the stomach. The fundus of the eye, examined for signs of diabetes and glaucoma, is the innermost layer, where the retina is located. A macula is a spot. There is a macula in the eye, which is the point of sharpest vision. There is also a macula in the ear, which contains receptors for equilibrium.

In interpreting medical terminology, it is often important to know the context in which a word is used.

extern.ir

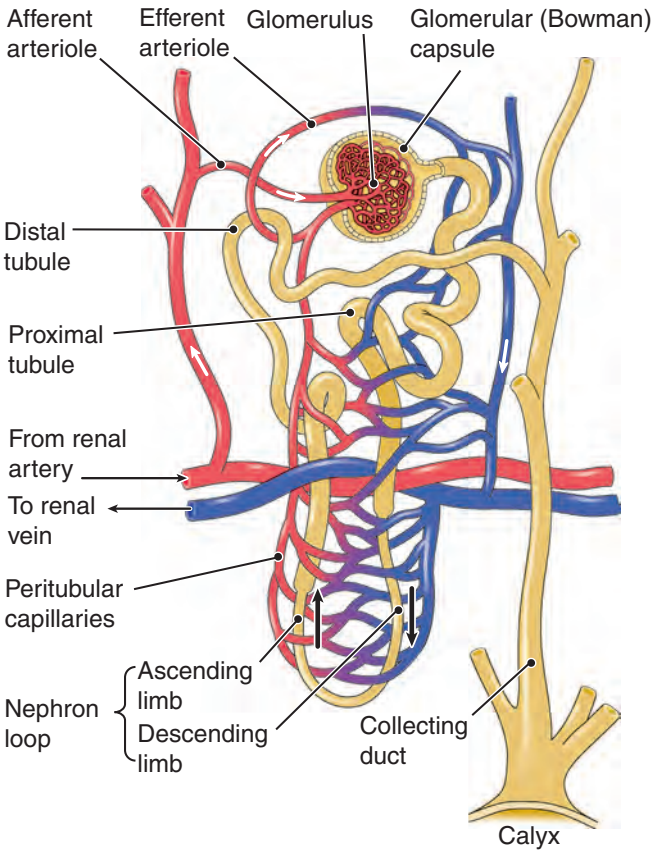

FIGURE 14-3 A nephron and its blood supply. The nephron regulates the proportion of water, waste, and other materials in urine according to the body's constantly changing needs. A nephron consists of a glomerular capsule, convoluted tubules, the nephron loop (loop of Henle), and a collecting duct. Blood filtration occurs through the glomerulus in the glomerular capsule. Materials that enter the nephron can be returned to the blood through the surrounding peritubular capillaries.

of water, electrolytes, soluble wastes, nutrients, and toxins. The main waste material is **urea**, the nitrogenous (nitrogen-containing) byproduct of protein metabolism. The filtrate should not contain any cells or proteins, such as albumin.

The waste material and the toxins must be eliminated, but most of the water, electrolytes, and nutrients must be returned to the blood, or we would rapidly starve and dehydrate. This return process, termed **tubular reabsorption**, occurs through the peritubular capillaries that surround the nephron.

As the filtrate flows through the nephron, other processes further regulate its composition and pH. For example, the nephron tubule can actively secrete substances from the blood into the urine. Hydrogen ions are moved in this manner, making the urine more acidic and raising the pH of body fluids. Certain drugs can also be removed from the blood and excreted. The filtrate's concentration is also adjusted under the effects of a pituitary hormone. **Antidiuretic hormone** (**ADH**) promotes reabsorption of water, thus concentrating the filtrate. The final filtrate, now called urine, flows into the collecting ducts to be eliminated. A **diuretic** is a substance that promotes increased urinary output or **diuresis.** Diuretic drugs are used in treating hypertension and heart failure to decrease fluid volume and reduce the heart's workload (see Chapter 10).

TRANSPORT AND REMOVAL OF URINE

Urine is drained from the renal pelvis and carried by the left and right ureters to the **urinary bladder** (FIG. 14-4), where it is stored. The bladder is located posterior to the pubic bone and below the peritoneum. As the bladder fills, it expands upward from a stable triangle at its base. This triangle, the

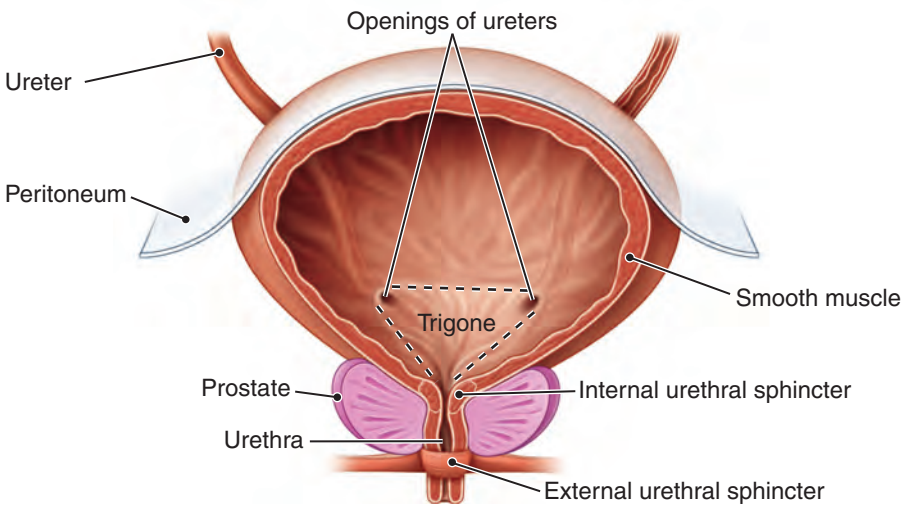

FIGURE 14-4 The urinary bladder. The interior of the male bladder is shown. The trigone is a triangular region in the bladder floor marked by the openings of the ureters and the urethra. The urethra travels through the prostate gland in the male.

extern.ir

trigone, is marked by the ureteral openings and the urethral opening below (see FIG. 14-4). The trigone's stability prevents urine from refluxing into the ureters.

Fullness stimulates a reflex contraction of the bladder muscle and expulsion of urine through the **urethra.** The female urethra is short (4 cm [1.5 in]) and carries only urine. The male urethra is longer (20 cm [8 in]) and carries both urine and semen.

The voiding (release) of urine, called **urination** or more technically, **micturition**, is regulated by two sphincters (circular muscles) that surround the urethra. The superior muscle, the internal urethral sphincter, is around the entrance to the urethra and functions involuntarily; the inferior muscle, the external urethral sphincter, is under conscious control. An inability to retain urine is termed *urinary incontinence*.

Terminology *Key Terms*

The terms listed below are emphasized in this chapter. Knowing them will help you organize and prioritize your learning. These boldface terms are also found, collectively, with all chapter key terms in the Glossary.

Normal Structure and Function

antidiuretic hormone (ADH) *an-te-di-u-RET-ik*	A hormone released from the pituitary gland that causes water reabsorption in the kidneys, thus concentrating the urine
angiotensin *an-je-o-TEN-sin*	A substance that increases blood pressure; activated in the blood by renin, an enzyme produced by the kidneys
calyx *KA-liks*	A cup-like cavity in the pelvis of the kidney; also calix (plural: calices) (roots: cali/o, calic/o)
diuresis *di-u-RE-sis*	Excretion of urine; usually meaning increased urinary excretion
diuretic *di-u-RET-ik*	A substance that increases the excretion of urine; pertaining to diuresis
erythropoietin (EPO) *eh-rith-ro-POY-eh-tin*	A hormone produced by the kidneys that stimulates red blood cell production in the bone marrow
glomerular capsule *glo-MER-u-lar KAP-sule*	The cup-shaped structure at the beginning of the nephron that surrounds the glomerulus and receives material filtered out of the blood; Bowman (*BO-man*) capsule
glomerular filtrate *glo-MER-u-lar FIL-trate*	The fluid and dissolved materials that filter out of the blood and enter the nephron through the glomerular capsule
glomerulus *glo-MER-u-lus*	The cluster of capillaries within the glomerular capsule (plural: glomeruli) (root: glomerul/o)
kidney *KID-ne*	An organ of excretion (roots: ren/o, nephr/o); the two kidneys filter the blood and form urine, which contains metabolic waste products and other substances as needed to regulate the water, electrolyte, and pH balance of body fluids
micturition *mik-tu-RISH-un*	The voiding of urine; urination
nephron *NEF-ron*	A microscopic functional unit of the kidney; working with blood vessels, the nephron filters the blood and balances the composition of urine
renal cortex *RE-nal KOR-tex*	The kidney's outer portion; contains portions of the nephrons
renal medulla *meh-DUL-lah*	The kidney's inner portion; contains portions of the nephrons and ducts that transport urine toward the renal pelvis
renal pelvis *PEL-vis*	The expanded upper end of the ureter that receives urine from the kidney (Greek root *pyel/o* means "basin")
renal pyramid *PERE-ah-mid*	A triangular structure in the renal medulla; composed of the nephrons' loops and collecting ducts

(continued)

extern.ir

Terminology — Key Terms (Continued)

renin *RE-nin*	An enzyme produced by the kidneys that activates angiotensin in the blood
trigone *TRI-gone*	A triangle at the base of the bladder formed by the openings of the two ureters and the urethra (see **FIG. 14-4**)
tubular reabsorption *TUBE-u-lar re-ab-SORP-shun*	The return of substances from the glomerular filtrate to the blood through the peritubular capillaries
urea *u-RE-ah*	The main nitrogenous (nitrogen-containing) waste product in the urine
ureter *U-re-ter*	The tube that carries urine from the kidney to the bladder (root: ureter/o)
urethra *u-RE-thrah*	The duct that carries urine out of the body and also transports semen in the male (root: urethr/o)
urinary bladder *u-rih-NAR-e BLAD-der*	The organ that stores and eliminates urine excreted by the kidneys (roots: cyst/o, vesic/o)
urination *u-rih-NA-shun*	The voiding of urine; micturition
urine *U-rin*	The fluid excreted by the kidneys; it consists of water, electrolytes, urea, other metabolic wastes, and pigments; a variety of other substances may appear in urine in cases of disease (root: ur/o)

Roots Pertaining to the Urinary System

See **TABLES 14-1** and **14-2**.

Table 14-1 Roots for the Kidney

Root	Meaning	Example	Definition of Example
ren/o	kidney	suprarenal *su-prah-RE-nal*	above the kidney
nephr/o	kidney	nephrosis *nef-RO-sis*	any noninflammatory disease condition of the kidney
glomerul/o	glomerulus	juxtaglomerular *juks-tah-glo-MER-u-lar*	near the glomerulus
pyel/o	renal pelvis	pyelectasis *pi-eh-LEK-tah-sis*	dilatation of the renal pelvis
cali/o, calic/o	calyx	caliceal *kal-ih-SE-al*	pertaining to a renal calyx (note addition of *e*); also spelled calyceal

extern.ir

Exercise 14-1

Complete the exercise. To check your answers go to Appendix 11.

Use the root *ren/o* to write a word for the following.

1. before or in front of (pre-) the kidney _____
2. behind (post-) the kidney _____
3. above the kidneys _____
4. around the kidneys _____

Use the root *nephr/o* to write a word for the following.

5. the medical specialist who studies the kidney _____
6. any disease of the kidney _____
7. poisonous or toxic to the kidney _____
8. softening of the kidney _____
9. enlargement of the kidney _____

Use the appropriate root to write a word for the following.

10. incision into the kidney _____
11. inflammation of the renal pelvis and kidney _____
12. plastic repair of the renal pelvis _____
13. radiograph of the renal pelvis _____
14. inflammation of a glomerulus _____
15. incision of a renal calyx _____
16. hardening of a glomerulus _____
17. dilatation of a renal calyx _____

Table 14-2 Roots for the Urinary Tract (Except the Kidney)

Root	Meaning	Example	Definition of Example
ur/o	urine, urinary tract	urinalysis *ur-ih-NAL-ih-sis*	laboratory study of urine
urin/o	urine	nocturia *nok-TU-re-ah*	urination during the night (noct/i)
ureter/o	ureter	ureterostenosis *u-re-ter-o-steh-NO-sis*	narrowing of the ureter
cyst/o	urinary bladder	cystocele *SIS-to-sele*	hernia of the urinary bladder
vesic/o	urinary bladder	intravesical *in-trah-VES-ih-kal*	within the urinary bladder
urethr/o	urethra	urethrotome *u-RE-thro-tome*	instrument for incising the urethra

extern.ir

Exercise 14-2

Complete the exercise. To check your answers go to Appendix 11.

Use the root *ur/o* to write a word for the following.

1. any disease of the urinary tract _____
2. radiography of the urinary tract _____
3. a urinary calculus (stone) _____
4. presence of urinary waste products in the blood _____

The root *ur/o-* is used in the suffix *-uria*, which means "condition of urine or of urination." Use *-uria* to write a word for the following.

5. lack of urine _____
6. presence of pus in the urine _____
7. urination at night _____
8. painful or difficult urination _____
9. presence of blood (hemat/o) in the urine _____

The suffix *-uresis* means "urination." Use *-uresis* to write a word for the following.

10. increased excretion of urine _____
11. lack of urination _____
12. excretion of sodium (natri-) in the urine _____
13. excretion of potassium (kali-) in the urine _____

The adjective ending for the above words is -uretic, as in diuretic (pertaining to diuresis) and natriuretic (pertaining to the excretion of sodium in the urine).

Use the appropriate root to write a word for the following.

14. surgical fixation of the urethra _____
15. surgical creation of an opening in the ureter _____
16. suture of the urethra _____
17. endoscopic examination of the urethra _____
18. herniation of the ureter _____

Use the root *cyst/o* to write a word for the following.

19. inflammation of the urinary bladder _____
20. radiography of the urinary bladder _____
21. an instrument for examining the interior of the bladder _____
22. incision of the bladder _____
23. discharge from the bladder _____

Use the root *vesic/o* to write a word for the following.

24. above the urinary bladder _____
25. pertaining to the urethra and bladder _____

extern.ir

Exercise 14-2 *(Continued)*

Define the following terms.

26. cystalgia (*sis-TAL-je-ah*) _____
27. ureterotomy (*u-re-ter-OT-o-me*) _____
28. transurethral (*trans-u-RE-thral*) _____
29. uropoiesis (*u-ro-poy-E-sis*) _____

Clinical Aspects of the Urinary System

INFECTIONS

Organisms that infect the urinary tract generally enter through the urethra and ascend toward the bladder, producing **cystitis**. Untreated, the infection can ascend even further into the urinary tract. The infecting organisms are usually colon bacteria carried in feces, particularly *Escherichia coli*. Although urinary tract infections (UTIs) do occur in men, they appear more commonly in women because the female urethra is shorter than the male urethra and its opening is closer to the anus. Poor toilet habits and **urinary stasis** are contributing factors. In hospitals, UTIs may result from procedures involving the urinary system, especially **catheterization**, in which a tube is inserted into the bladder to withdraw urine (FIG. 14-5). Less frequently, UTIs originate in the blood and descend through the urinary system.

An infection that involves the kidney and renal pelvis is termed **pyelonephritis.** As in cystitis, signs of this condition include **dysuria**, painful or difficult urination, and the presence of bacteria and pus in the urine, **bacteriuria** and **pyuria**, respectively.

Urethritis is inflammation of the urethra, generally associated with sexually transmitted infections such as gonorrhea and chlamydial infections (see Chapter 15).

GLOMERULONEPHRITIS

Although the name simply means inflammation of the glomeruli and kidney, **glomerulonephritis** is a specific disorder that follows an immunologic reaction. It is usually a response to infection in another system, commonly a streptococcal infection of the respiratory tract or a skin infection. It may also accompany autoimmune diseases such as lupus erythematosus. The symptoms are hypertension, edema, and **oliguria**, the passage of small amounts of urine. This urine is highly concentrated. Because of damage to kidney tissue, blood and proteins escape into the nephrons, causing **hematuria**, blood in the urine, and **proteinuria**, protein in the urine. Blood cells may also form into small molds of the kidney tubule, called **casts**, which can be found in the

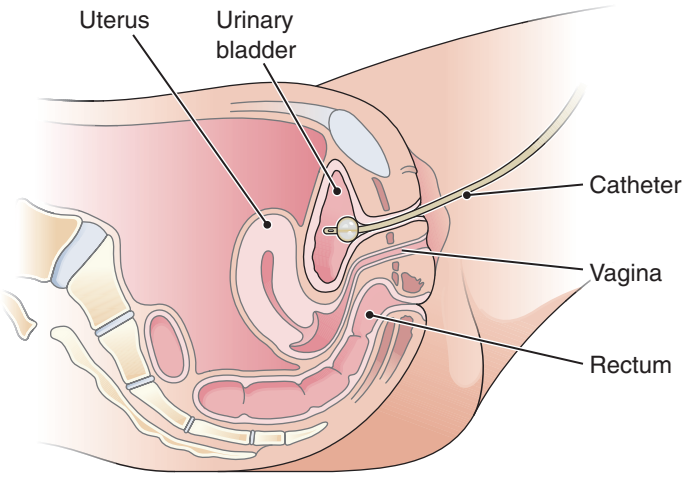

FIGURE 14-5 An indwelling (Foley) catheter. The catheter is shown in place in the female bladder.

extern.ir

urine. Most patients fully recover from glomerulonephritis, but in some cases, especially among the elderly, the disorder may lead to chronic renal failure (CRF) or end-stage renal disease (ESRD). In such cases, urea and other nitrogenous compounds accumulate in the blood, a condition termed **uremia**. These compounds affect the central nervous system, causing irritability, loss of appetite, stupor, and other symptoms. There is also electrolyte imbalance and **acidosis**.

NEPHROTIC SYNDROME

Glomerulonephritis is one cause of **nephrotic syndrome**, a disease in which the glomeruli become overly permeable and allow the loss of proteins. Other possible causes of nephrotic syndrome are renal vein thrombosis, diabetes, systemic lupus erythematosus, toxins, or any other condition that damages the glomeruli.

Nephrotic syndrome is marked by proteinuria and **hypoproteinemia**, low blood protein. The low plasma protein level affects capillary exchange and results in edema. There is also an increase in blood lipids, as the liver compensates for lost protein by releasing lipoproteins.

RENAL FAILURE

Chronic renal failure results from a gradual loss of nephrons. As more and more nephrons are destroyed, the kidneys slowly lose the ability to perform their normal functions. In many cases, there is a lesser decrease in renal function, known as *renal insufficiency*, that produces fewer symptoms. Injury, shock, exposure to toxins, infections, and other renal disorders may cause sudden damage to the nephrons, resulting in a rapid loss of kidney function, or **acute renal failure** (**ARF**). When destruction (necrosis) of kidney tubules is involved, the condition may be referred to as *acute tubular necrosis* (*ATN*).

A few of the characteristic signs and symptoms of renal failure are the following:

- **Dehydration** (*de-hi-DRA-shun*). Excessive loss of body fluid may occur early in renal failure, when the kidneys cannot concentrate the urine and large amounts of water are eliminated.
- **Edema** (*eh-DE-mah*). Accumulation of fluid in the tissue spaces may occur late in chronic renal disease, when the kidneys cannot eliminate water in adequate amounts.
- Electrolyte imbalance. The results of such disturbance, as they apply to electrolytes of sodium and potassium, are described in **BOX 14-2**.
- **Hypertension** may occur as the result of sodium and water retention.
- **Anemia** occurs when the kidneys cannot produce the hormone EPO to activate red blood cell production in bone marrow.
- **Uremia** (*u-RE-me-ah*), an excess of nitrogenous waste products in the blood. When these levels are high, urea can be changed into ammonia in the stomach and intestine and cause ulcerations and bleeding.

Renal failure may lead to a need for kidney **dialysis** or, ultimately, **renal transplantation.** Dialysis refers to the movement of substances across a semipermeable membrane; it is a method used to eliminate harmful or unnecessary substances from the body when the kidneys are impaired or have been removed **(FIG. 14-6)**. Two approaches are used:

- In **hemodialysis**, blood is cleansed by passage over a membrane surrounded by fluid (dialysate) that draws out unwanted substances. Most people on hemodialysis are treated for 4 hours three times a week in a dialysis center. Some patients are able to use simpler machines at home for daily dialysis. **BOX 14-3** has information on careers in hemodialysis treatment.
- In **peritoneal dialysis**, fluid is introduced into the peritoneal cavity. The fluid, along with waste products, is periodically withdrawn and replaced. Fluid may be exchanged at intervals throughout the day in continuous ambulatory peritoneal dialysis (CAPD) or during the night in continuous cyclic peritoneal dialysis (CCPD).

CLINICAL PERSPECTIVES

BOX 14-2

Sodium and Potassium: Causes and Consequences of Imbalance

Sodium and potassium concentrations in body fluids are important measures of water and electrolyte balance. An excess of sodium in body fluids is termed **hypernatremia**, taken from the Latin name for sodium, *natrium*. This condition accompanies dehydration and severe vomiting and may cause hypertension, edema, convulsions, and coma. **Hyponatremia**, a sodium deficiency in body fluids, can come from water intoxication (overhydration), heart failure, kidney failure, cirrhosis of the liver, pH imbalance, or endocrine disorders. It can cause muscle weakness, hypotension, confusion, shock, convulsions, and coma.

The term **hyperkalemia** is taken from the Latin name for potassium, *kalium*. It refers to excess potassium in body fluids, which may result from kidney failure, dehydration, and other causes. Its signs and symptoms include nausea, vomiting, muscular weakness, and severe cardiac arrhythmias. **Hypokalemia**, or low potassium in body fluids, may result from taking diuretics that cause potassium to be lost along with water. It may also result from pH imbalance or secretion of too much aldosterone from the adrenal cortex, resulting in potassium excretion. Hypokalemia causes muscle fatigue, paralysis, confusion, hypoventilation, and cardiac arrhythmias.

extern.ir

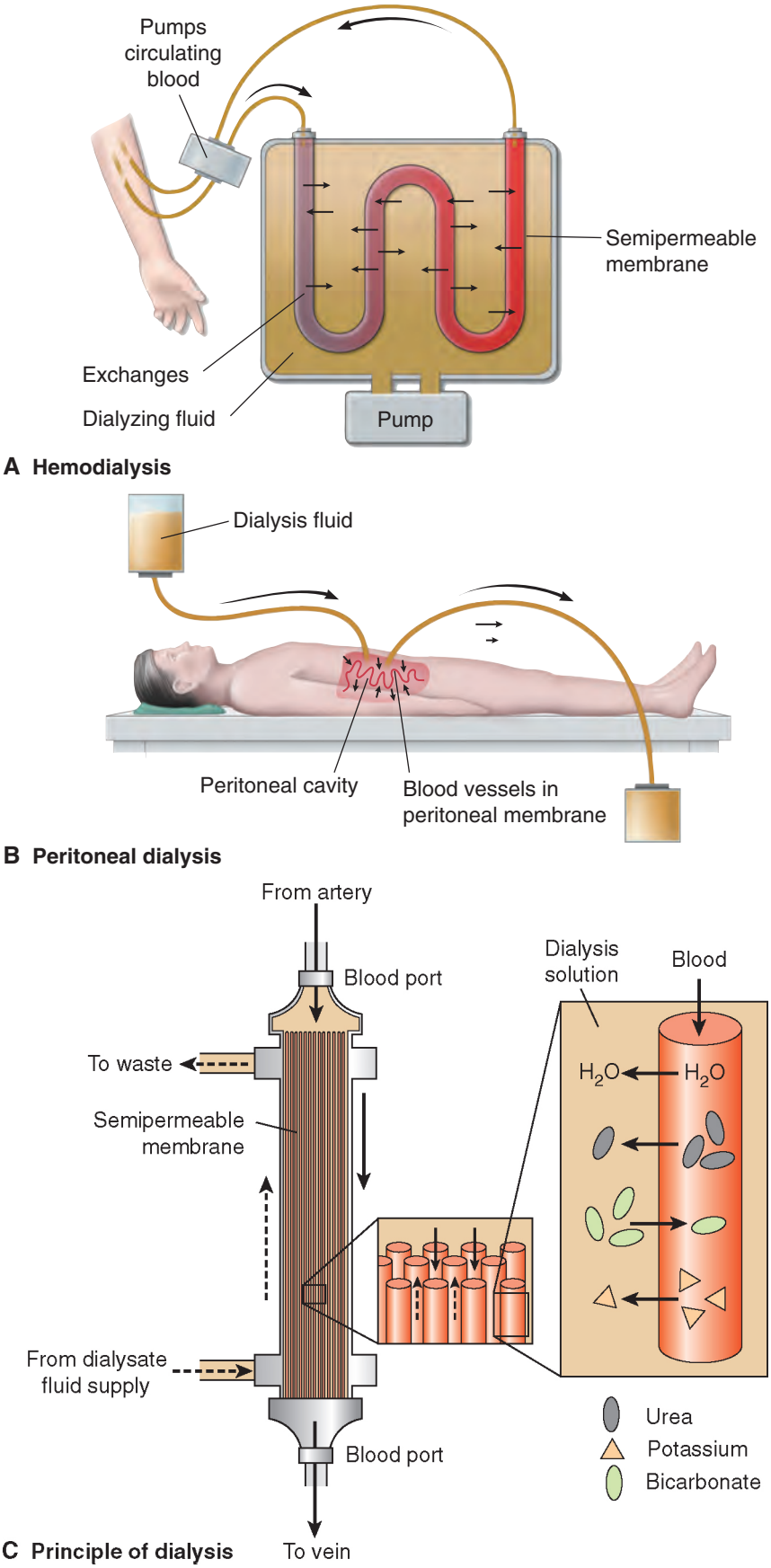

FIGURE 14-6 Dialysis. A dialyzing fluid (dialysate) draws materials out of the blood through a semipermeable membrane. **A.** Hemodialysis. The patient's blood flows through a dialysis machine. **B.** Peritoneal dialysis. The dialysate is introduced into the peritoneal cavity. The peritoneum acts as the dialysis membrane. **C.** The principle of dialysis. Materials, such as water, electrolytes, and dissolved waste, flow through a semipermeable membrane based on their concentration on either side of the membrane. When kidneys fail, dialysis can restore the blood's proper composition.

extern.ir

HEALTH PROFESSIONS
Hemodialysis Technician

BOX 14-3

A hemodialysis technician, also called a renal technician or a nephrology technician, specializes in the safe and effective delivery of renal dialysis therapy to patients suffering from kidney failure. Before treatment begins, the technician prepares the dialysis solutions and ensures that the dialysis machine is clean, sterile, and in proper working order. The technician measures and records the patient's weight, temperature, and vital signs; inserts a catheter into the patient's arm; and connects the dialysis machine to it. During dialysis, the technician monitors the patient for adverse reactions and guards against any equipment malfunction. After the treatment is completed, the technician again measures and records the patient's weight, temperature, and vital signs. To perform these duties, hemodialysis technicians need thorough scientific and clinical training. Most technicians in the United States receive their training from colleges or technical schools, and many states require that the technician be certified.

Hemodialysis technicians work in a variety of settings, such as hospitals, clinics, and patients' homes. As populations age, the incidence of kidney disease is expected to rise, as will the need for hemodialysis. For more information about this career, contact the American Nephrology Nurses Association (ANNA) at annanurse.org.

URINARY STONES

Urinary lithiasis (presence of stones) may be related to infection, irritation, diet, or hormone imbalances that lead to increased calcium in the blood. Most urinary calculi (stones) are made up of calcium salts, but they may be composed of other materials as well. Causes of stone formation include dehydration, infection, abnormal pH of urine, urinary stasis, and metabolic imbalances. The stones generally form in the kidney and may move to the bladder). This results in great pain, termed **renal colic**, and obstruction that can promote infection and cause **hydronephrosis**, collection of urine in the renal pelvis.

Because they are radiopaque, stones can usually be seen on simple radiographs of the abdomen. Stones may dissolve and pass out of the body on their own. If not, they may be removed surgically, in a **lithotomy**, or by endoscopy. External shock waves are used to crush stones in the urinary tract in a procedure called extracorporeal (outside the body) shock-wave **lithotripsy** (crushing of stones) **(FIG. 14-7)**.

CANCER

Carcinoma of the bladder has been linked to occupational exposure to chemicals, parasitic infections, and cigarette smoking. A key symptom is sudden, painless hematuria. Often, the cancer can be seen by viewing the bladder lining with a **cystoscope** **(FIG. 14-8)**. This instrument can also be used to biopsy tissue for study.

If treatment is not effective in permanently removing the tumor, a **cystectomy** (removal of the bladder) may be necessary. In this case, the ureters must be vented elsewhere, such as directly to the body surface through the ileum in an **ileal conduit** **(FIG. 14-9)**, or to some other portion of the intestine.

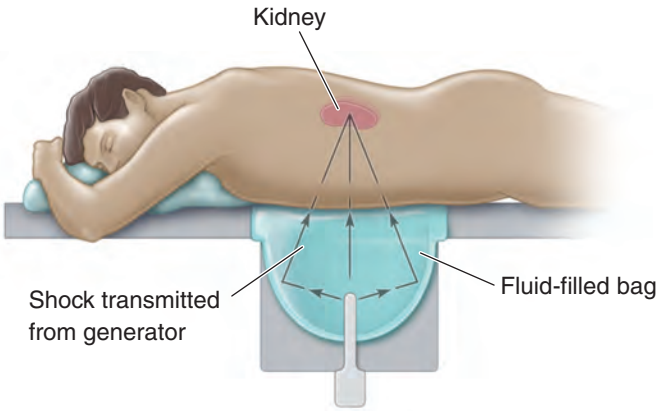

FIGURE 14-7 Lithotripsy. Shock waves are used to break kidney stones and allow for their passage. The procedure is called extracorporeal shock-wave lithotripsy (ESWL).

extern.ir

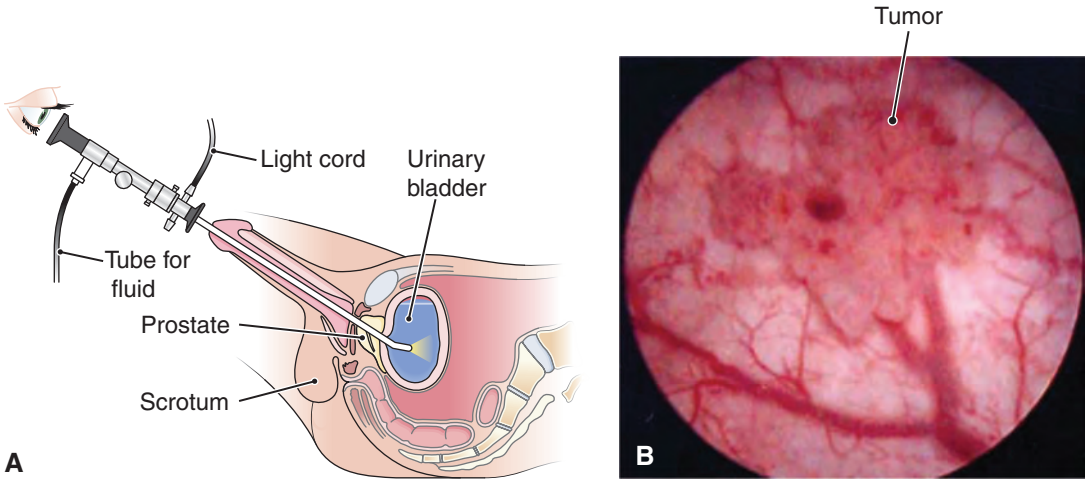

FIGURE 14-8 Cystoscopy. A. A lighted cystoscope is introduced through the urethra into the bladder of a male subject. Sterile fluid is used to inflate the bladder. Cystoscopes are used to examine the bladder, take biopsy specimens, and remove tumors. **B.** A cancer of the bladder, as viewed through a cystoscope.

Cancer may also involve the kidney and renal pelvis. Additional means for diagnosing cancer and other urinary tract disorders include ultrasound, computed tomography scans, and radiographic studies such as **intravenous urography** (IVU) (FIG. 14-10), also called **intravenous pyelography** (IVP), and **retrograde pyelography.**

URINALYSIS

Urinalysis (UA) is a simple and widely used method for diagnosing urinary tract disorders. It may also reveal disturbances in other systems when abnormal byproducts are eliminated in the urine. In a routine UA, the urine is grossly examined for color and turbidity (a sign that bacteria are present); **specific gravity** (SG) (a measure of concentration) and pH are recorded; tests are performed for chemical components such as glucose, ketones, and hemoglobin; and the urine is examined microscopically for cells, crystals, and casts. In more detailed tests, drugs, enzymes, hormones, and other metabolites may be analyzed, and bacterial cultures may be performed.

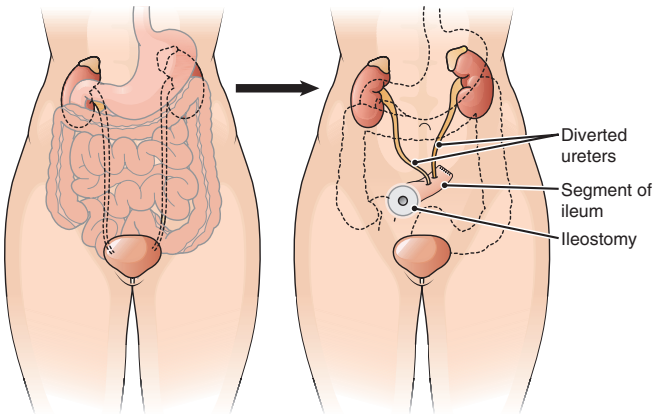

FIGURE 14-9 Ileal conduit. In this surgery, the ureters are vented to the body surface through the ileum when the bladder is removed or nonfunctional.

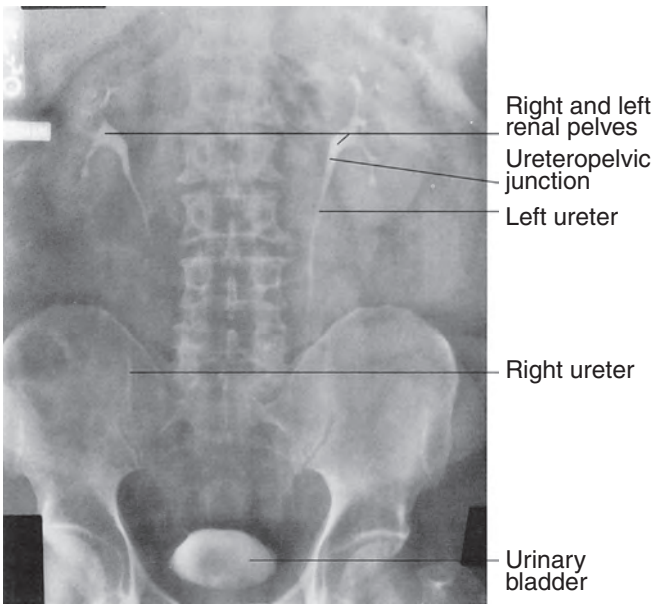

FIGURE 14-10 Intravenous urogram. The image shows the renal pelvis, ureters, and urinary bladder.

extern.ir

Terminology *Key Terms*

The terms listed below are emphasized in this chapter. Knowing them will help you organize and prioritize your learning. These boldface terms are also found, collectively, with all chapter key terms in the Glossary.

Disorders

acidosis *as-ih-DO-sis*	Excessive acidity of body fluids
bacteriuria *bak-te-re-U-re-ah*	Presence of bacteria in the urine
cast	A solid mold of a renal tubule found in the urine
cystitis *sis-TI-tis*	Inflammation of the urinary bladder, usually as a result of infection
dysuria *dis-U-re-ah*	Painful or difficult urination
glomerulonephritis *glo-mer-u-lo-nef-RI-tis*	Inflammation of the kidney, primarily involving the glomeruli; the acute form usually occurs after an infection elsewhere in the body; the chronic form varies in cause and usually leads to renal failure
hematuria *he-mat-U-re-ah*	Presence of blood in the urine
hydronephrosis *hi-dro-nef-RO-sis*	Collection of urine in the renal pelvis caused by obstruction; results in distention and renal atrophy
hypokalemia *hi-po-kah-LE-me-ah*	Deficiency of potassium in the blood
hyponatremia *hi-po-nah-TRE-me-ah*	Deficiency of sodium in the blood
hypoproteinemia *hi-po-pro-te-NE-me-ah*	Decreased amount of protein in the blood; may be caused by kidney damage resulting in protein loss
hyperkalemia *hi-per-kah-LE-me-ah*	Excess amount of potassium in the blood
hypernatremia *hi-per-nah-TRE-me-ah*	Excess amount of sodium in the blood
nephrotic syndrome *nef-ROT-ik*	Condition that results from glomerular damage leading to loss of protein in the urine (proteinuria); there is low plasma protein (hypoproteinemia), edema, and increased blood lipids as the liver releases lipoproteins; also called nephrosis
oliguria *ol-ig-U-re-ah*	Elimination of small amounts of urine
proteinuria *pro-te-NU-re-ah*	Presence of protein, mainly albumin, in the urine
pyelonephritis *pi-eh-lo-neh-FRI-tis*	Inflammation of the renal pelvis and kidney, usually caused by infection
pyuria *pi-U-re-ah*	Presence of pus in the urine
renal colic *KOL-ik*	Radiating pain in the region of the kidney associated with the passage of a stone
renal failure	Loss of kidney function resulting from loss or damage to the kidney nephrons. May be chronic, developing over time, or acute, as a result of sudden damage, as by injury, shock, or toxins

extern.ir

Terminology *Key Terms (Continued)*

uremia *u-RE-me-ah*	Presence of toxic levels of urea and other nitrogenous substances in the blood as a result of renal insufficiency
urethritis *u-re-THRI-tis*	Inflammation of the urethra, usually due to infection
urinary stasis *STA-sis*	Stoppage of urine flow; urinary stagnation
Diagnosis and Treatment	
catheterization *kath-eh-ter-ih-ZA-shun*	Introduction of a tube into a passage, such as through the urethra into the bladder for withdrawal of urine (see **FIG. 14-5**)
cystoscope *SIS-to-skope*	An instrument for examining the interior of the urinary bladder; also used for removing foreign objects, for surgery, and for other forms of treatment
dialysis *di-AL-ih-sis*	Separation of substances by passage through a semipermeable membrane; dialysis is used to rid the body of unwanted substances when the kidneys are impaired or missing; the two forms of dialysis are hemodialysis and peritoneal dialysis
hemodialysis *he-mo-di-AL-ih-sis*	Removal of unwanted substances from the blood by passage through a semipermeable membrane (see **FIG. 14-6**)
intravenous pyelography (IVP) *in-trah-VE-nus pi-eh-LOG-rah-fe*	Intravenous urography (see **FIG. 14-10**)
intravenous urography (IVU) *in-trah-VE-nus u-ROG-rah-fe*	Radiographic visualization of the urinary tract after intravenous administration of a contrast medium that is excreted in the urine; also called excretory urography or intravenous pyelography, although the latter is less accurate because the procedure shows more than just the renal pelvis
lithotripsy *LITH-o-trip-se*	Crushing of a stone (see **FIG. 14-7**)
peritoneal dialysis *per-ih-to-NE-al di-AL-ih-sis*	Removal of unwanted substances from the body by introduction of a dialyzing fluid into the peritoneal cavity followed by removal of the fluid (see **FIG. 14-6**)
retrograde pyelography *RET-ro-grade pi-eh-LOG-rah-fe*	Pyelography in which the contrast medium is injected into the kidneys from below by way of the ureters
specific gravity (SG)	The weight of a substance compared with the weight of an equal volume of water; the specific gravity of normal urine ranges from 1.015 to 1.025; this value may increase or decrease with disease
urinalysis (UA) *u-rih-NAL-ih-sis*	Laboratory study of the urine; physical and chemical properties and microscopic appearance are included
Surgery	
cystectomy *sis-TEK-to-me*	Surgical removal of all or part of the urinary bladder
ileal conduit *IL-e-al KON-du-it*	Diversion of urine by connection of the ureters to an isolated segment of the ileum; one end of the segment is sealed, and the other drains through an opening in the abdominal wall (see **FIG. 14-9**); a procedure used when the bladder is removed or nonfunctional; also called ileal bladder
lithotomy *lith-OT-o-me*	Incision of an organ to remove a stone (calculus)
renal transplantation	Surgical implantation of a donor kidney into a patient

extern.ir

Terminology *Enrichment Terms*

The terms listed below expand on the key terms to increase your knowledge of this chapter topic.

Normal Structure and Function	
aldosterone *al-DOS-ter-one*	A hormone secreted by the adrenal gland that regulates electrolyte excretion by the kidneys
clearance	The volume of plasma that the kidneys can clear of a substance per unit of time; renal plasma clearance
creatinine *kre-AT-in-in*	A nitrogenous byproduct of muscle metabolism; an increase in blood creatinine is a sign of renal failure
detrusor muscle *de-TRU-sor*	The muscle in the bladder wall
glomerular filtration rate (GFR)	The amount of filtrate formed per minute by both kidneys
maximal transport capacity (Tm)	The maximum rate at which a given substance can be transported across the renal tubule; tubular maximum
renal corpuscle *KOR-pus-l*	The glomerular capsule and the glomerulus considered as a unit; the filtration device of the kidney
Symptoms and Conditions	
anuresis *an-u-RE-sis*	Lack of urination
anuria *an-U-re-ah*	Lack of urine formation
azotemia *az-o-TE-me-ah*	Presence of increased nitrogenous waste, especially urea, in the blood
azoturia *az-o-TU-re-ah*	Presence of increased nitrogenous compounds, especially urea, in the urine
cystocele *SIS-to-sele*	Herniation of the bladder into the vagina (see **FIG. 16-12**); vesicocele
dehydration *de-hi-DRA-shun*	Excessive loss of body fluids
diabetes insipidus *di-ah-BE-teze in-SIP-id-us*	A condition caused by inadequate production of antidiuretic hormone, resulting in excessive excretion of dilute urine and extreme thirst
enuresis *en-u-RE-sis*	Involuntary urination, usually at night; bed-wetting
epispadias *ep-ih-SPA-de-as*	A congenital condition in which the urethra opens on the dorsal surface of the penis as a groove or cleft; anaspadias
glycosuria *gli-ko-SU-re-ah*	Presence of glucose in the urine, as in cases of diabetes mellitus
horseshoe kidney	A congenital union of the lower poles of the kidneys, resulting in a horseshoe-shaped organ **(FIG. 14-11)**
hydroureter *hi-dro-u-RE-ter*	Distention of the ureter with urine due to obstruction
hypospadias *hi-po-SPA-de-as*	A congenital condition in which the urethra opens on the undersurface of the penis or into the vagina **(FIG. 14-12)**
hypovolemia *hi-po-vo-LE-me-ah*	A decrease in blood volume
neurogenic bladder *nu-ro-JEN-ik*	Any bladder dysfunction that results from a central nervous system lesion

extern.ir

Terminology *Enrichment Terms (Continued)*

nocturia *nok-TU-re-ah*	Excessive urination at night (root: noct/o means "night")
polycystic kidney disease *pol-e-SIS-tik*	A hereditary condition in which the kidneys are enlarged and contain many cysts **(FIG. 14-13)**
polydipsia *pol-e-DIP-se-ah*	Excessive thirst
polyuria *pol-e-U-re-ah*	Elimination of large amounts of urine, as in diabetes mellitus
retention of urine	Accumulation of urine in the bladder because of an inability to urinate
staghorn calculus	A kidney stone that fills the renal pelvis and calices to give a "staghorn" appearance **(FIG. 14-14)**
ureterocele *u-RE-ter-o-sele*	A cyst-like dilatation of the ureter near its opening into the bladder; usually results from a congenital narrowing of the ureteral opening **(FIG. 14-15)**
urinary frequency	A need to urinate often without an increase in average output
urinary incontinence *in-KON-tin-ens*	Inability to retain urine; may originate with a neurologic disorder, trauma to the spinal cord, weakness of the pelvic muscles, urinary retention, or impaired bladder function; in urgency incontinence, an urge causes sudden urination before one has enough time to reach a bathroom; in stress incontinence, urine leaks during a forceful activity such as coughing, sneezing, or exercise
urinary urgency	Sudden need to urinate
water intoxication *in-tok-sih-KA-shun*	Excess intake or retention of water with decrease in sodium concentration; may result from excess drinking, excess ADH, or replacement of a large amount of body fluid with pure water; causes an imbalance in the cellular environment, with edema and other disturbances; also called hyponatremia
Wilms tumor	A malignant kidney tumor that usually appears in children before the age of 5 years
Diagnosis	
anion gap *AN-i-on*	A measure of electrolyte imbalance
blood urea nitrogen (BUN)	Nitrogen in the blood in the form of urea; an increase in BUN indicates an increase in nitrogenous waste products in the blood and renal failure
clean-catch specimen	A urine sample obtained after thorough cleansing of the urethral opening and collection in midstream to minimize the chance of contamination
cystometrography *sis-to-meh-TROG-rah-fe*	A study of bladder function in which the bladder is filled with fluid or air and the pressure exerted by the bladder muscle at varying degrees of filling is measured; the tracing recorded is a cystometrogram
protein electrophoresis (PEP)	Laboratory study of urinary proteins; used to diagnose multiple myeloma, systemic lupus erythematosus, and lymphoid tumor
urinometer *u-rih-NOM-eh-ter*	Device for measuring the specific gravity of urine
Treatment	
indwelling Foley catheter	A urinary tract catheter with a balloon at one end that prevents the catheter from leaving the bladder (see **FIG. 14-5**)
lithotrite *LITH-o-trite*	Instrument for crushing a bladder stone

extern.ir

FIGURE 14-11 Horseshoe kidney. The photograph shows the kidneys fused at the poles.

FIGURE 14-13 Adult polycystic disease. The kidney is enlarged, and the active tissue is almost entirely replaced by cysts of varying size. (*Left*) Surface view. (*Right*) Longitudinal section.

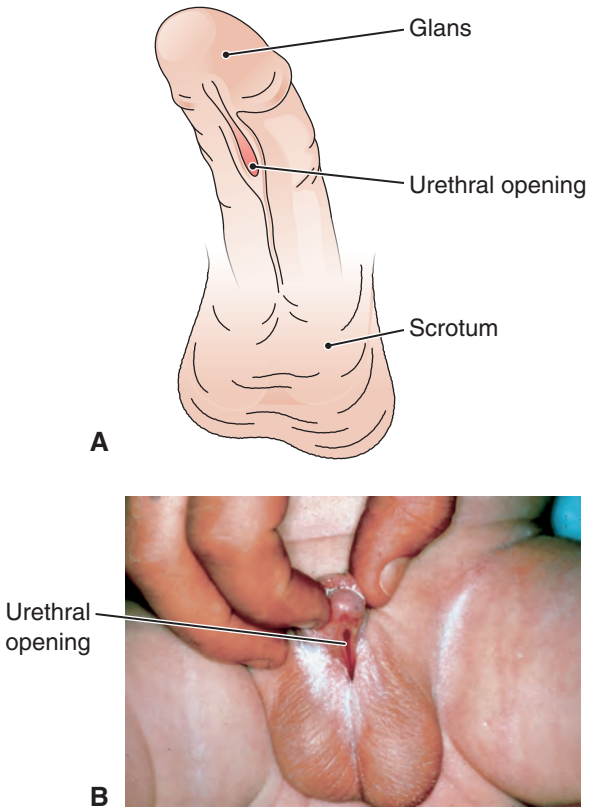

FIGURE 14-12 Hypospadias. A. The urethra is shown opening on the ventral surface of the penis. **B.** In this photo of a baby with hypospadias, the urethral opening is on the scrotum.

FIGURE 14-14 Staghorn calculus. The kidney shows hydronephrosis and stones that are casts of the dilated calices.

extern.ir

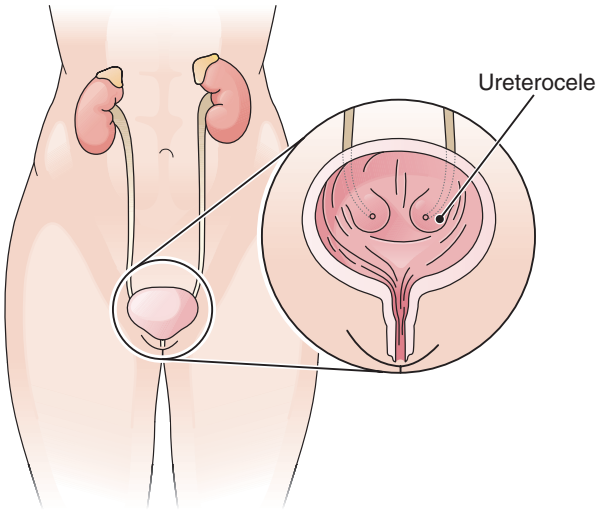

FIGURE 14-15 Ureterocele. The ureter bulges into the bladder. The resulting obstruction causes urine to reflux into the ureter (hydroureter) and renal pelvis (hydronephrosis).

Terminology *Abbreviations*

The abbreviations listed below are emphasized in this chapter. These are also found, collectively, with all chapter abbreviations in Appendix 2.

ACE	Angiotensin-converting enzyme	**GFR**	Glomerular filtration rate
ADH	Antidiuretic hormone	**GU**	Genitourinary
ARF	Acute renal failure	**IVP**	Intravenous pyelography
ATN	Acute tubular necrosis	**IVU**	Intravenous urography
BUN	Blood urea nitrogen	**K**	Potassium
CAPD	Continuous ambulatory peritoneal dialysis	**KUB**	Kidney–ureter–bladder (radiography)
CCPD	Continuous cyclic peritoneal dialysis	**Na**	Sodium
CMG	Cystometrography; cystometrogram	**PEP**	Protein electrophoresis
CRF	Chronic renal failure	**SG**	Specific gravity
EPO	Erythropoietin	**Tm**	Maximal transport capacity
ESRD	End-stage renal disease	**UA**	Urinalysis
ESWL	Extracorporeal shock-wave lithotripsy	**UTI**	Urinary tract infection

Case Study Revisited

Jade's Follow-Up Study

At her 3-month follow-up appointment Jade had excellent results from the implanted autograft of her skeletal muscle stem cells. There was no retention of urine, and the incontinence and urgency had all but disappeared. Jade's urologist explained that the use of stem cells in the field of regenerative medicine has emerged in the last few years due to their capacity to restore and maintain normal function via direct effects on injured or dysfunctional tissues (as in Jade's case). The urologist further explained that the procedure that Jade received via the clinical study was proving to be a viable option for improving issues surrounding urethral sphincter muscle deficiency and damage.

After a year, Jade continues to experience 95% success rate from her stress incontinence and her quality of life has improved. She regularly participates in her favorite athletic activities without the worry of stress incontinence. She continues to schedule her follow-up appointments with her urologist and follows the strict guidelines for her participation in the clinical research study.

extern.ir

CHAPTER 14 Review

This review tests your understanding of the content introduced in this chapter. Follow the instructions for each exercise and check your answers in Appendix 11.

LABELING EXERCISE

THE URINARY SYSTEM

Write the name of each numbered part on the corresponding line.

Adrenal gland
Aorta
Diaphragm
Inferior vena cava
Kidney
Renal artery
Renal vein
Ureter
Urethra
Urinary bladder

1. _____
2. _____
3. _____
4. _____
5. _____
6. _____
7. _____
8. _____
9. _____
10. _____

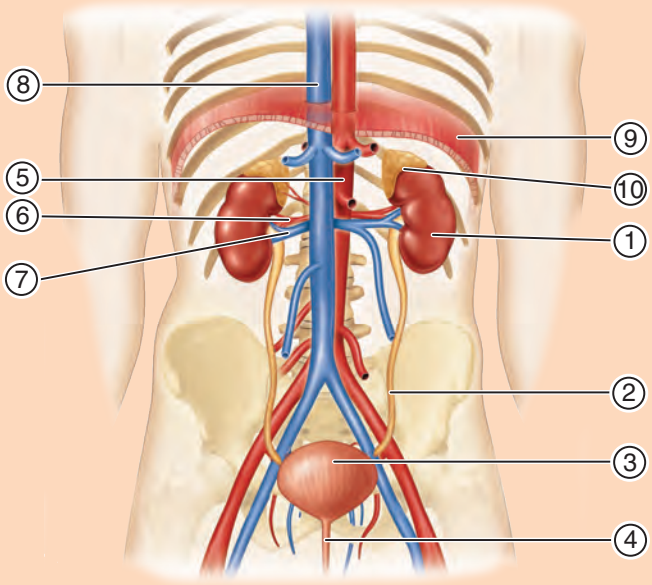

extern.ir

KIDNEY

Write the name of each numbered part on the corresponding line.

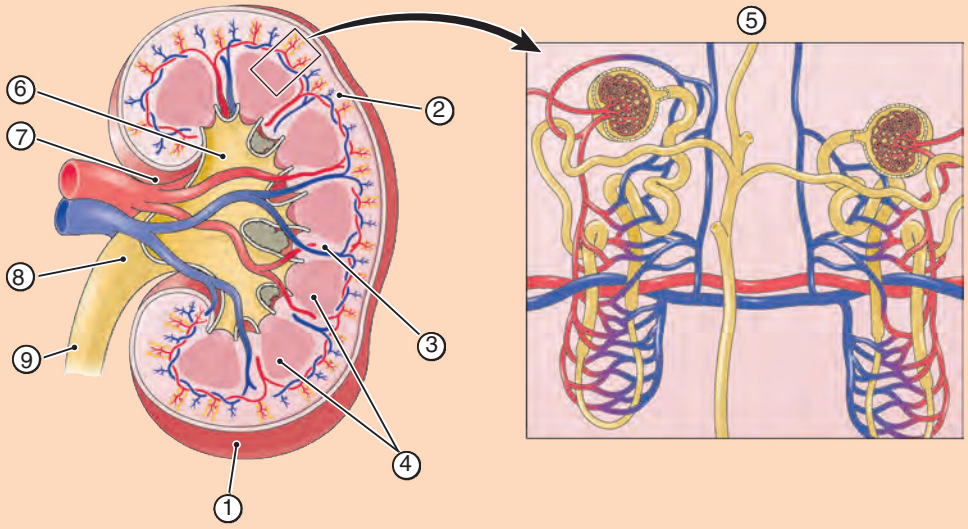

Calyx	Pyramids of medulla	Renal pelvis
Hilum	Renal capsule	Renal cortex
Nephrons	Renal medulla	Ureter

1. _____
2. _____
3. _____
4. _____
5. _____
6. _____
7. _____
8. _____
9. _____

URINARY BLADDER

Write the name of each numbered part on the corresponding line.

External urethral sphincter	Smooth muscle
Internal urethral sphincter	Trigone
Openings of ureters	Ureter
Peritoneum	Urethra
Prostate	

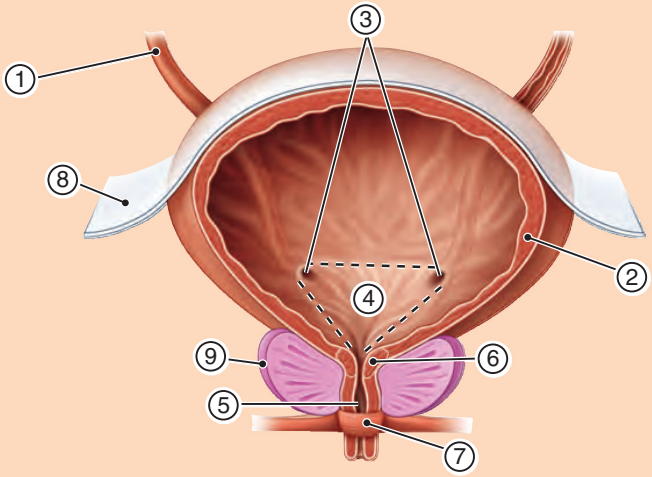

1. _____
2. _____
3. _____
4. _____
5. _____
6. _____
7. _____
8. _____
9. _____

extern.ir

TERMINOLOGY

MATCHING

Match the following terms, and write the appropriate letter to the left of each number.

____ 1. hematuria	a. blood in the urine
____ 2. oliguria	b. proteinuria
____ 3. chromaturia	c. elimination of small amounts of urine
____ 4. albuminuria	d. abnormal color of urine
____ 5. pyuria	e. pus in the urine

____ 6. renal cortex	a. absence of a bladder
____ 7. nephron	b. stagnation, as of urine
____ 8. stasis	c. deficiency of urine
____ 9. acystia	d. kidney's outer portion
____ 10. uropenia	e. microscopic functional unit of the kidney

Enrichment Terms

____ 11. aldosterone	a. amount of filtrate formed per minute by the kidney
____ 12. diabetes insipidus	b. condition caused by lack of ADH
____ 13. incontinence	c. nitrogenous metabolic waste
____ 14. glomerular filtration rate	d. hormone that regulates electrolytes
____ 15. creatinine	e. inability to retain urine

____ 16. polydipsia	a. excessive thirst
____ 17. enuresis	b. bed-wetting
____ 18. azoturia	c. presence of excess nitrogenous waste in the urine
____ 19. anuresis	d. congenital misplacement of the ureteral opening
____ 20. hypospadias	e. lack of urination

FILL IN THE BLANKS

Complete the sentence with the correct term(s).

21. Collection of urine in the renal pelvis is a result of obstruction _____ .
22. The cluster of capillaries within the glomerular capsule is the _____ .
23. An enzyme released by the kidneys that acts to increase blood pressure is _____ .
24. Micturition is the scientific term for _____ .
25. Laboratory study of the urine is a(n) _____ .
26. The main nitrogenous waste product in urine is _____ .

Refer to Jade's opening case study.

27. Jade's inability to retain urine is termed urinary _____ .
28. A midstream urine sample collected after thorough cleansing of the urethral opening is called a(n) _____ .
29. Endoscopic examination of the urinary bladder is termed _____ .

extern.ir

TRUE–FALSE

Examine the following statements. If the statement is true, write T in the first blank. If the statement is false, write F in the first blank, and correct the statement by replacing the underlined word in the second blank.

	True or False	Correct Answer
30. A reniform structure is shaped like the bladder.	_____	_____
31. Pyelitis is inflammation of the renal pelvis.	_____	_____
32. A nephrotropic substance acts on the kidney.	_____	_____
33. The inner portion of the kidney is the cortex.	_____	_____
34. The tube that carries urine out of the body is the ureter.	_____	_____
35. EPO stimulates the production of red blood cells.	_____	_____
36. A lithotomy is an incision to remove a calculus.	_____	_____
37. Natriuresis refers to the excretion of potassium in the urine.	_____	_____

DEFINITIONS

Define the following words.

38. urethrostenosis (*u-re-thro-steh-NO-sis*) _____
39. polyuria (*pol-e-U-re-ah*) _____
40. nephrotoxic (*nef-ro-TOK-sik*) _____
41. juxtaglomerular (*juks-tah-glo-MER-u-lar*) _____
42. calicectomy (*kal-ih-SEK-to-me*) _____
43. pararenal (*par-ah-RE-nal*) _____

Write a word for the following definitions.

44. Physician who specializes in the kidney (nephr/o) _____
45. Dilatation of the renal pelvis and calices _____
46. Softening of a kidney (nephr/o) _____
47. Incision of the bladder (cyst/o) _____
48. Any disease of the kidney (nephr/o) _____
49. Radiograph of the bladder (cyst/o) and urethra _____
50. Plastic repair of a ureter and renal pelvis _____
51. Inflammation of the renal pelvis and the kidney _____
52. Surgical creation of an opening between a ureter and the sigmoid colon _____

extern.ir

ELIMINATIONS

In each of the sets below, underline the word that does not fit in with the rest and explain the reason for your choice.

53. capsule — cast — pyramid — nephron — cortex

_____

54. nephron loop — distal convoluted tubule — glomerular capsule — calyx — proximal convoluted tubule

_____

55. ileal conduit — specific gravity — dialysis — cystoscopy — lithotripsy

_____

OPPOSITES

Write a word that means the opposite of the following.

56. dehydration _____
57. hypovolemia _____
58. diuretic _____
59. hyponatremia _____
60. uresis _____

ADJECTIVES

Write the adjective form of the following.

61. ureter _____
62. nephrology _____
63. uremia _____
64. diuresis _____
65. nephrosis _____
66. calyx _____
67. urethra _____

PLURALS

Write the plural form of the following.

68. pelvis _____
69. calyx _____
70. glomerulus _____

FOLLOW THE FLOW

Describing the pathway of urine flow, put the following steps in the correct order by placing the letters "A" through "G" in the space provided.

____ 71. Fluid or glomerular filtrate enters the nephron
____ 72. Urine flows into the collecting ducts to be eliminated
____ 73. Urine flows from the ureters to the bladder
____ 74. Tubular reabsorption, or return process of nutrients, water, and electrolytes, occurs
____ 75. Blood flows through the glomerulus
____ 76. Urine is drained from the renal pelvis to the ureters
____ 77. Urine flows from the bladder to the urethra

extern.ir

WORD BUILDING

Write a word for the following definitions using the word parts given. Each word part can be used more than once.

graph-	ren/o	-al	intra-	vesic/o	-y	ur/o	inter-	lith	log	supra-

78. radiographic study of the urinary tract _____
79. pertaining to the kidney _____
80. within the kidney _____
81. radiographic study of the kidney _____
82. within the bladder _____
83. above the kidney _____
84. study of the urinary tract _____
85. between the kidneys _____
86. pertaining to the bladder _____
87. a urinary tract stone _____

ABBREVIATIONS

Write the meaning of the following abbreviations.

88. SG _____
89. ADH _____
90. EPO _____
91. IVP _____
92. Na _____
93. GFR _____
94. UA _____

WORD ANALYSIS

Define the following words, and give the meaning of the word parts in each. Use a dictionary if necessary.

95. hemodialysis (*he-mo-di-AL-ih-sis*)
    a. hem/o _____
    b. dia- _____
    c. lysis _____
96. cystometrography (*sis-to-meh-TROG-rah-fe*)
    a. cyst/o _____
    b. metr/o _____
    c. -graphy _____
97. ureteroneocystostomy (*u-re-ter-o-ne-o-sis-TOS-to-me*)
    a. ureter/o _____
    b. neo- _____
    c. cyst/o _____
    d. -stomy _____

extern.ir

Additional Case Studies

Case Study 14-1: Renal Calculi

Helen, a 48 y/o woman, was admitted to the inpatient unit from the ED with severe right flank pain unresponsive to analgesics. Her pain did not decrease with administration of 100 mg of IV meperidine. She had a 3-month history of chronic UTI. She had been prescribed calcium supplements for low bone density 6 months ago. Her gynecologist warned her that calcium could be a problem for people who are "stone formers." Helen was unaware that she might be at risk. An IV urogram showed a right staghorn calculus. The diagnosis was further confirmed by a renal ultrasound. A renal flow scan showed normal perfusion and no obstruction. Kidney function was 37% on the right and 63% on the left. The pain became intermittent, and Helen had no hematuria, dysuria, frequency, urgency, or nocturia. Urinalysis revealed no albumin, glucose, bacteria, or blood; there was evidence of cells, crystals, and casts.

Helen was transferred to surgery for a cystoscopic ureteral laser lithotripsy, insertion of a right retrograde ureteral catheter, and right percutaneous nephrolithotomy. A ureteral calculus was fragmented with a pulsed-dye laser. Most of the staghorn was removed from the renal pelvis with no remaining stone in the renal calices. She was discharged 2 days later and ordered to strain her urine for the next week for evidence of stones.

Case Study 14-1 Questions

Multiple Choice. *Select the best answer, and write the letter of your choice to the left of each number.*

_____ 1. The term *perfusion* means
   a. metabolism
   b. size
   c. passage of fluid
   d. surrounding tissue

_____ 2. The term *percutaneous* means
   a. under the skin
   b. on the surface
   c. with a catheter
   d. through the skin

Write a term from the case study with the following meanings.

3. Intravenous injection of contrast dye and radiographic study of the urinary tract _____
4. Presence of blood in the urine _____
5. Referring to endoscopy of the urinary bladder _____
6. Surgical incision for removal of a kidney stone _____
7. Getting up to go to the bathroom at night _____
8. Crushing a stone _____

extern.ir

Case Study 14-2: End-Stage Renal Disease

Adrien, a 20 y/o part-time college student, has had chronic glomerulonephritis since age 7. He has been treated at home with CAPD for the past 16 months as he awaits kidney transplantation. His doctor advised him to go immediately to the ED when he reported chest pain, shortness of breath, and oliguria. On admission, Adrien was placed on oxygen and given a panel of blood tests and an ECG to rule out an acute cardiac episode. His hemoglobin was 8.2, and his hematocrit was 26%. He had bilateral lung rales. ABGs were: pH, 7.0; Pa_{CO_2}, 28; Pa_{O_2}, 50; HCO_3, 21. His BUN, serum creatinine, and BUN/creatinine ratio were abnormally high. His ECG and liver enzyme studies were normal. His admission diagnosis was ESRD, fluid overload, and metabolic acidosis. He was typed and crossed for blood; tested for HIV, hepatitis B antigen, and sexually transmitted disease; and sent for hemodialysis. A bed was reserved for him on the transplant unit.

Case Study 14-2 Questions

Multiple Choice. *Select the best answer, and write the letter of your choice to the left of each number.*

_____ 1. Adrien's chronic glomerulonephritis means that he has had
   a. long-term kidney stones
   b. an acute bout of kidney infection
   c. short-term bladder inflammation
   d. a long-term kidney infection

_____ 2. Renal dialysis can be performed by shunting venous blood through a dialysis machine and returning the blood to the patient's arterial system. This procedure is called
   a. hemodialysis
   b. arteriovenous transplant
   c. CAPD
   d. glomerular filtration rate

Write a term from the case study with the following meanings.

3. Production of a reduced amount of urine _____
4. Kidney replacement _____

Define the following abbreviations.

5. CAPD _____
6. BUN _____
7. ESRD _____
8. HIV _____

extern.ir

CHAPTER 15

Male Reproductive System

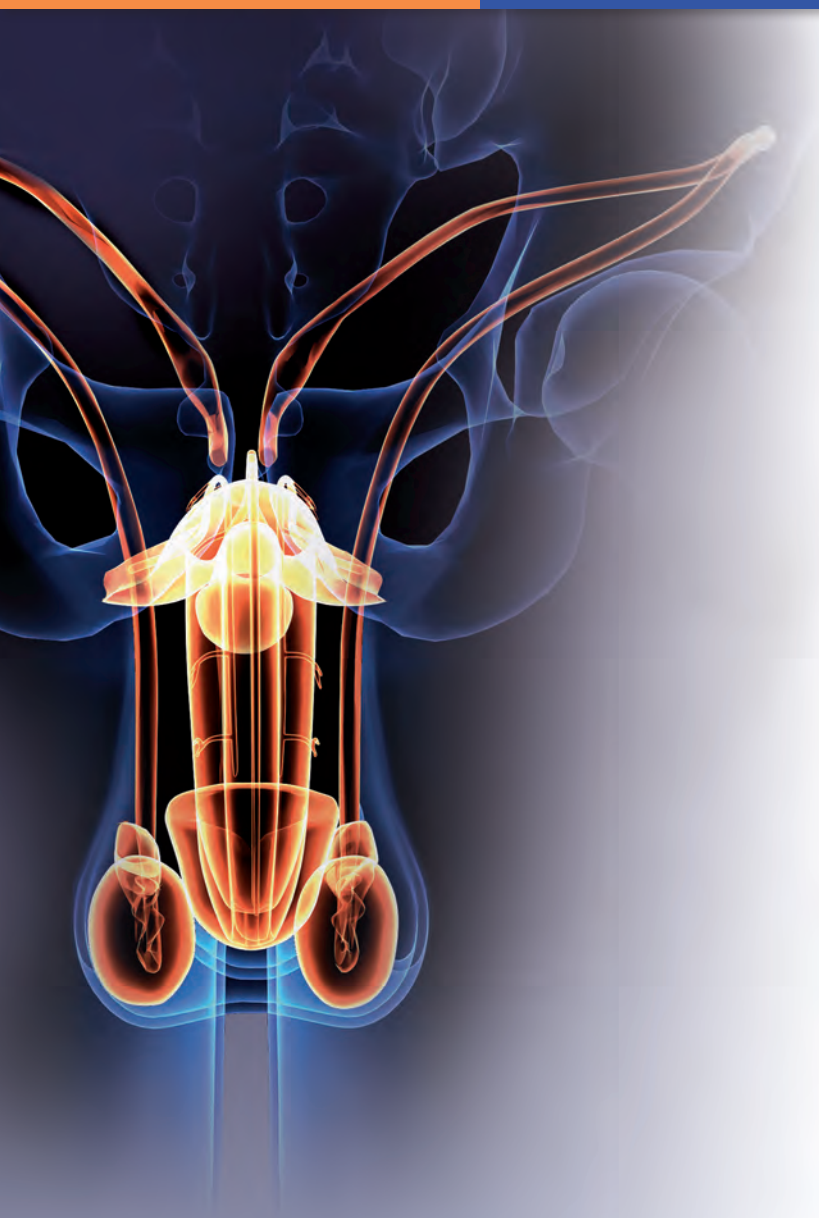

Pretest

Multiple Choice. **Select the best answer, and write the letter of your choice to the left of each number. To check your answers go to Appendix 11.**

_____ 1. The male germ cell, or gamete, is the
a. ovum
b. testis
c. spermatozoon
d. semen

_____ 2. Gametes develop in a gonad, which in males is called the
a. vas deferens
b. seminal vesicle
c. penis
d. testis

_____ 3. The main male sex hormone is
a. testosterone
b. renin
c. estrogen
d. amylase

_____ 4. The secretion that transports gametes in males is
a. bile
b. semen
c. urine
d. pepsin

_____ 5. The gland below the bladder in males is the
a. scrotum
b. prostate
c. adrenal
d. parotid

_____ 6. Orchitis is inflammation of the
a. bladder
b. kidney
c. penis
d. testis

extern.ir

Learning Objectives

After careful study of this chapter, you should be able to:

1. Describe the organs of the male reproductive tract, and give the function of each part. ***P490***
2. Follow spermatozoa from their development in the testis to their release. ***P490***
3. Describe the contents and functions of semen. ***P492***
4. Identify and use roots pertaining to the male reproductive system. ***P494***
5. Describe six main disorders of the male reproductive system. ***P496***
6. Interpret abbreviations used in referring to the male reproductive system. ***P502***
7. Analyze medical terms in several case studies concerning the male reproductive system. ***PP489, 508***

Case Study: Dexter's Benign Prostatic Hyperplasia and TURP

Chief Complaint

Dexter, a 60 y/o teacher, was having a decreased force of his urine stream and ejaculation, hesitancy, and sensation of incomplete bladder emptying. He had tried using prostate-health herbal supplements without any real benefit for 2 years. He decided to make an appointment with a urologist.

Examination

The urologist took a history and examined the patient. Dexter reported no dysuria, hematuria, or flank pain. He had no history of UTI, epididymitis, prostatitis, renal disease, or renal calculi. His medical history was otherwise not significant to his urologic complaint.

Rectal examination revealed a 50-g prostate with slight firmness in the right prostatic lobe. The physician ordered a bladder ultrasound, which was performed later that week. The results indicated no intravesical lesions or prostate protrusion into the bladder base.

A transabdominal ultrasound was ordered and showed a residual urine volume of 120 mL. A urinalysis revealed normal values except for the following: WBC = 8; RBC = 10; bacteria = trace.

Dexter was diagnosed with benign prostatic hyperplasia (BPH) with bladder neck obstruction and was scheduled for a transurethral resection of the prostate (TURP). His urologist explained the procedure and what to expect pre- and postoperatively. The office staff notified the hospital to schedule the surgery. The next day, the hospital admissions department called Dexter, went through normal admissions procedures, and scheduled a surgery date.

Clinical Course

Dexter was NPO the night before the surgery. He was taken to the operating room and was given a spinal anesthetic for the procedure. It had already been explained to him that the surgery would take about an hour and that he would be awake during the procedure but would not feel any pain. A resectoscope was used to trim the enlarged prostatic tissue. At the end of the surgery, a Foley catheter was inserted into the bladder and left in place to drain the urine and permit irrigation of the bladder to remove any clots. Dexter tolerated the procedure well and was transferred to the recovery room and later to his hospital room. He was encouraged to drink plenty of fluids postoperatively.

Case Study Revisited: Once you complete this chapter, please review the case follow-up on p. 502.

Ancillaries *At-A-Glance*

Visit the web resource to access the following resources.

extern.ir

Learning Resources

- eBook
- A&P Module with Heart & Lung Sounds
- Image Bank
- TestPrep
- Animations
- Audio Pronunciation Glossary

Introduction

The function of the **gonads** (sex glands) in both males and females is to produce the reproductive cells, the **gametes**, and to produce hormones. The gametes are generated by **meiosis**, a process of cell division that halves the chromosome number from 46 to 23. When male and female gametes unite in fertilization, the original chromosome number is restored.

Sex hormones aid in the manufacture of gametes, function in pregnancy and lactation, and also produce the secondary sex characteristics such as the typical size, shape, body hair, and voice that we associate with the male and female genders.

The reproductive tract develops in close association with the urinary tract. In females, the two systems become completely separate, whereas the male reproductive and urinary tracts share a common passage, the **urethra.** Thus, the two systems are referred together as the genitourinary (GU) or urogenital (UG) tract, and urologists are called on to treat disorders of the male reproductive system as well as those of the urinary system.

The Testes

The male germ cells, the sperm cells or **spermatozoa** (singular: spermatozoon), are produced in the paired **testes** (singular: testis) that are suspended outside of the body in the **scrotum** (FIG. 15-1). Although the testes develop in the abdominal cavity, they normally descend through the **inguinal canal** into the scrotum before birth or shortly thereafter (FIG. 15-2).

From the start of sexual maturation, or **puberty**, spermatozoa form continuously within the testes in coiled seminiferous tubules (FIG. 15-3). Their development requires the aid of special **Sertoli cells** and male sex hormones, or **androgens**, mainly **testosterone.** These hormones are manufactured in **interstitial cells** located between the tubules. In both males and females, the gonads are stimulated by **follicle-stimulating hormone** (FSH) and **luteinizing hormone** (LH), released from the anterior **pituitary gland** beneath the brain. These hormones are chemically the same in males and females, although they are named for their actions in female reproduction. In males, FSH stimulates the Sertoli cells and promotes the formation of spermatozoa. LH stimulates the interstitial cells to produce testosterone.

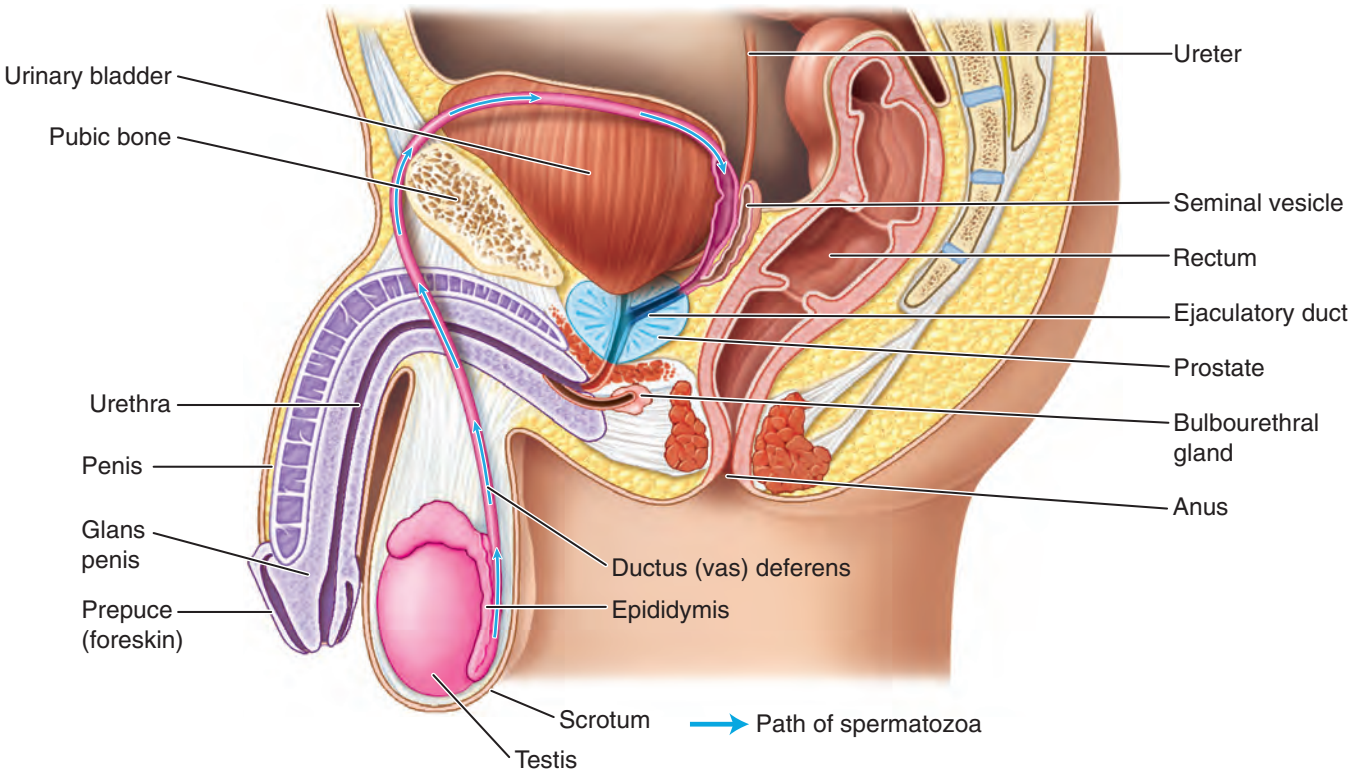

FIGURE 15-1 Male reproductive system. *Arrows* show the path of spermatozoa. Parts of the urinary system and digestive system are also shown.

extern.ir

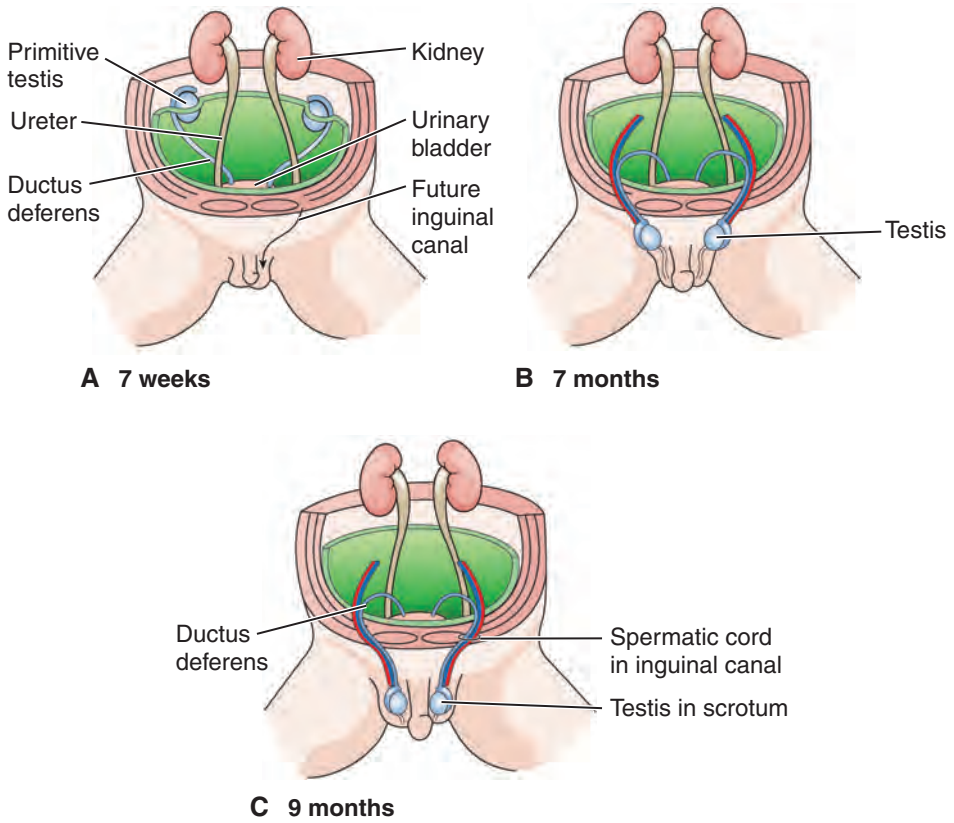

FIGURE 15-2 Descent of the testes. Drawings show formation of the inguinal canals and descent of the testes at three different times during fetal development. **A.** At 7 weeks, the testis is in the dorsal abdominal wall. **B.** At 7 months, the testis is passing through the inguinal canal. **C.** At 9 months, the testis is in the scrotum, suspended by the spermatic cord.

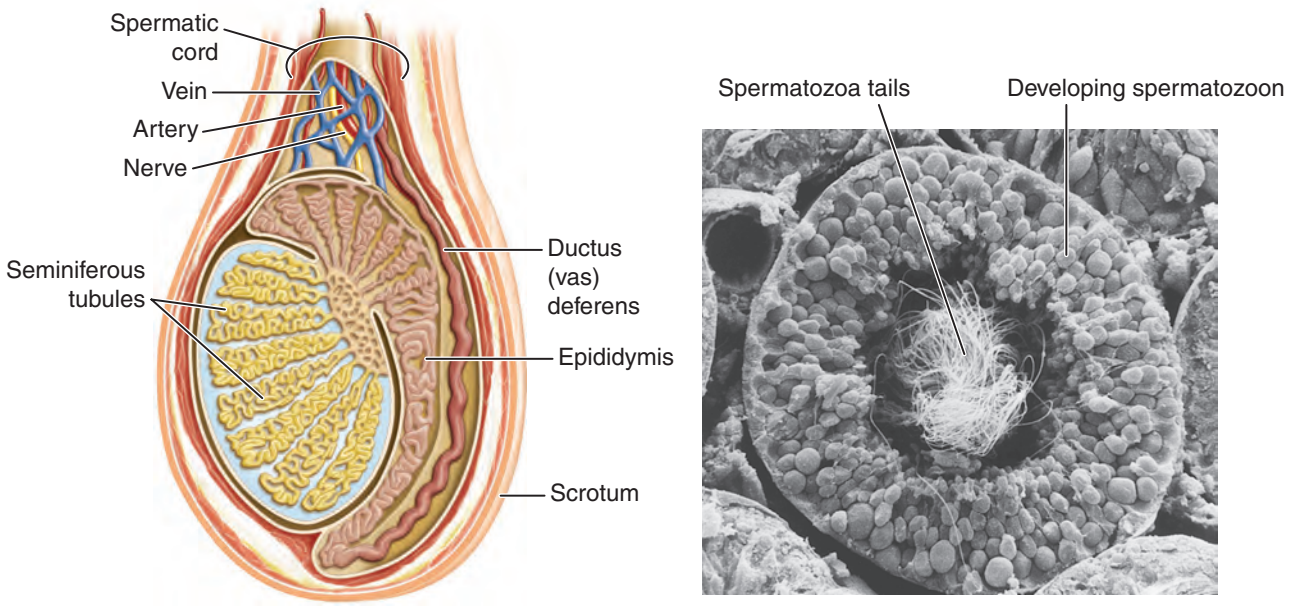

FIGURE 15-3 The testis. A. The testis in position in the scrotum showing the structure of the seminiferous tubules. The epididymis and spermatic cord are also shown. **B.** Spermatozoa develop within the seminiferous tubules in the testis.

extern.ir

FOCUS ON WORDS
Which Is It?

BOX 15-1

Some of the work of learning medical terminology is made more difficult by the fact that many structures and processes are known by two or even more names. This duplication may occur because different names have been assigned at different times or places or because the name is in a state of transition to another name, and the new one has not been universally accepted.

The tube that leads from the testis to the urethra in males was originally called the vas deferens, *vas* being a general term for *vessel.* To distinguish this tube from a blood vessel, efforts have been made to change the name to ductus deferens. However, the original name has lingered because the surgical procedure used to sterilize a man is still called a vasectomy and not a "ductusectomy."

Similar inconsistencies appear in other systems. Dorsal is also posterior; ventral could be anterior. Human growth hormone is also called somatotropin. ADH, a hormone that increases blood pressure, is also known as vasopressin.

In the nervous system, the little swellings at the ends of axons that contain neurotransmitters are variously called end-feet, end-bulbs, terminal knobs, terminal feet, and even other names. In a woman, the tube that carries the ovum from the ovary to the uterus is referred to as the uterine tube, or maybe the Fallopian tube … or the oviduct … or …

Transport of Spermatozoa

After their manufacture, sperm cells are stored in a much-coiled tube on the surface of each testis, the **epididymis** (see FIGS. 15-1 and 15-3). Here, they remain until **ejaculation** propels them into a series of ducts that lead out of the body. The first of these is the **ductus (vas) deferens**, which is contained in the **spermatic cord** along with nerves and blood vessels that supply the testis (see FIGS. 15-2 and 15-3). The spermatic cord ascends through the inguinal canal into the abdominal cavity, where the ductus deferens leaves the cord and travels behind the bladder. (See BOX 15-1, which discusses how alternative names can be a challenge to learning medical terminology.)

A short continuation of the ductus deferens, the **ejaculatory duct**, delivers spermatozoa to the urethra as it passes through the **prostate gland** below the bladder. Finally, the cells, now mixed with other secretions, travel in the urethra through the penis to be released (see FIG. 15-1).

The Penis

The penile urethra transports both urine and **semen.** The **penis** is the male organ of sexual intercourse, or **coitus.** It is composed of three segments of spongy tissue, which become engorged with blood to produce an **erection**, a stiffening of the penis. As shown in FIGURE 15-4, the two corpora cavernosa are lateral bodies; the corpus spongiosum, through which the urethra travels, is in the center. The corpus spongiosum enlarges at the tip to form the **glans penis**, which is covered by loose skin—the **prepuce**, or foreskin. Surgery to remove the foreskin is **circumcision**. This may be performed for medical reasons but is most often performed electively in male infants for reasons of hygiene, cultural preferences, or religion.

Formation of Semen

Semen is the thick, whitish fluid that transports spermatozoa. It contains, in addition to sperm cells, secretions from three types of accessory glands (see FIG. 15-1). Following the sequence of sperm transport, these are:

1. The paired **seminal vesicles**, which release their secretions into the ejaculatory duct on each side.
2. The prostate gland, which secretes into the first part of the urethra beneath the bladder. As men age, prostatic enlargement may compress the urethra and cause urinary problems.
3. The two **bulbourethral** (Cowper) **glands**, which secrete into the urethra just below the prostate gland.

Together, these glands produce a slightly alkaline mixture that nourishes and transports the sperm cells and also protects them by neutralizing the acidity of the female vaginal tract.

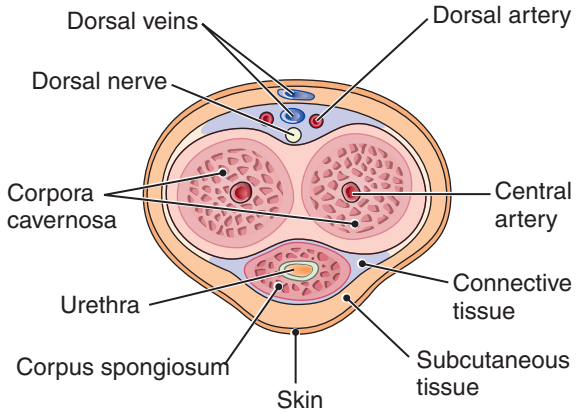

FIGURE 15-4 The penis. This cross-section shows the erectile bodies of the penis (corpora cavernosa and corpus spongiosum), the centrally located urethra, as well as blood vessels and a nerve.

extern.ir

Terminology *Key Terms*

The terms listed below are emphasized in this chapter. Knowing them will help you organize and prioritize your learning. These boldface terms are also found, collectively, with all chapter key terms in the Glossary.

androgen *AN-dro-jen*	Any hormone that produces male characteristics (root andr/o means "male")
bulbourethral gland *bul-bo-u-RE-thral*	A small gland beside the urethra below the prostate that secretes part of the seminal fluid; also called Cowper gland
circumcision *ser-kum-SIH-zhun*	Surgical removal of the end of the prepuce (foreskin)
coitus *KO-ih-tus*	Sexual intercourse
ductus deferens *DUK-tus DEF-er-enz*	The duct that conveys spermatozoa from the epididymis to the ejaculatory duct; also called vas deferens
ejaculation *e-jak-u-LA-shun*	Ejection of semen from the male urethra
ejaculatory duct *e-JAK-u-lah-tor-e*	The duct formed by union of the ductus deferens and the duct of the seminal vesicle; it carries spermatozoa and seminal fluid into the urethra
epididymis *ep-ih-DID-ih-mis*	A coiled tube on the surface of the testis that stores sperm until ejaculation (root: epididym/o)
erection *e-REK-shun*	The stiffening or hardening of the penis or the clitoris, usually because of sexual excitement
follicle-stimulating hormone (FSH)	A hormone secreted by the anterior pituitary that acts on the gonads; in males, FSH stimulates Sertoli cells and promotes sperm cell development; in females, it stimulates ripening of ova in the ovary
gamete *GAM-ete*	A mature reproductive cell, the spermatozoon in the male and the ovum in the female
glans penis *glanz PE-nis*	The bulbous end of the penis
gonad *GO-nad*	A sex gland; testis or ovary
inguinal canal *ING-gwin-al*	The channel through which the testis descends into the scrotum in the male
interstitial cells *in-ter-STISH-al*	Cells located between the seminiferous tubules of the testes that produce hormones, mainly testosterone; also called cells of Leydig (*LI-dig*)
luteinizing hormone (LH) *LU-te-in-i-zing*	A hormone secreted by the anterior pituitary that acts on the gonads; in males, it stimulates the interstitial cells to produce testosterone; in females, it stimulates ovulation and corpus luteum formation.
meiosis *mi-O-sis*	The type of cell division that forms the gametes; it results in cells with 23 chromosomes, half the number found in other body cells (from the Greek word *meiosis* meaning "diminution")
penis *PE-nis*	The male organ of copulation and urination (adjective: penile)
pituitary gland *pih-TU-ih-tar-e*	An endocrine gland at the base of the brain
prepuce *PRE-pus*	The fold of skin over the glans penis; the foreskin
prostate gland *PROS-tate*	A gland that surrounds the urethra below the bladder in males and contributes secretions to the semen (root: prostat/o)
puberty *PU-ber-te*	Period during which the ability for sexual reproduction is attained and secondary sex characteristics begin to develop

(continued)

extern.ir

Terminology — Key Terms (Continued)

scrotum *SKRO-tum*	A double pouch that contains the testes (root: osche/o)
semen	The thick secretion that transports spermatozoa (roots: semin, sperm/i, spermat/o)
seminal vesicle *SEM-ih-nal VES-ih-kl*	A sac-like gland behind the bladder that contributes secretions to the semen (root: vesicul/o)
Sertoli cell *ser-TO-le*	Cell in a seminiferous tubule that aids in the development of spermatozoa; sustentacular (*sus-ten-TAK-u-lar*) cell
spermatic cord *sper-MAT-ik*	Cord attached to the testis that contains the ductus deferens, blood vessels, and nerves enclosed within a fibrous sheath (see **FIG. 15-3**)
spermatozoon *sper-mah-to-ZO-on*	Mature male sex cell (plural: spermatozoa) (roots: sperm/i, spermat/o)
testis *TES-tis*	The male reproductive gland (roots: test/o, orchi/o, orchid/o); plural is testes (*TES-teze*); also called testicle
testosterone *tes-TOS-ter-one*	The main male sex hormone
urethra *u-RE-thrah*	The duct that carries urine out of the body and also transports semen in the male
vas deferens *DEF-er-enz*	The duct that conveys spermatozoa from the epididymis to the ejaculatory duct; also called ductus deferens

Word Parts Pertaining to the Male Reproductive System

See **TABLE 15-1**.

Table 15-1 Roots for Male Reproduction

Root	Meaning	Example	Definition of Example
test/o	testis, testicle	testosterone *tes-TOS-teh-rone*	hormone produced in the testis
orchi/o, orchid/o	testis	anorchism *an-OR-kizm*	absence of a testis
osche/o	scrotum	oscheal *OS-ke-al*	pertaining to the scrotum
semin	semen	inseminate *in-SEM-ih-nate*	to introduce semen into a vagina
sperm/i, spermat/o	semen, spermatozoa	polyspermia *pol-e-SPER-me-ah*	secretion of excess semen
epididym/o	epididymis	epididymitis *ep-ih-did-ih-MI-tis*	inflammation of the epididymis
vas/o	vas deferens, ductus deferens; also vessel	vasostomy *vas-OS-to-me*	surgical creation of an opening in the ductus deferens
vesicul/o	seminal vesicle	vesiculogram *veh-SIK-u-lo-gram*	radiograph of a seminal vesicle
prostat/o	prostate	prostatometer *pros-tah-TOM-eh-ter*	instrument for measuring the prostate

extern.ir

Exercise 15-1

Complete the exercise. To check your answers go to Appendix 11.

Define the following words.

1. spermatogenesis (*sper-mah-to-JEN-eh-sis*) _____
2. prostatodynia (*pros-tah-to-DIN-e-ah*) _____
3. oscheoplasty (*os-ke-o-PLAS-te*) _____
4. epididymectomy (*ep-ih-did-ih-MEK-to-me*) _____
5. orchialgia (*or-ke-AL-je-ah*) _____
6. testopathy (*tes-TOP-ah-the*) _____
7. orchiepididymitis (*or-ke-ep-ih-did-ih-MI-tis*) _____

Use the root *orchi/o* to write a word for the following definitions. Each is also written with the root *orchid/o*.

8. surgical fixation of a testis _____
9. plastic repair of a testis _____
10. surgical removal of a testis _____

Use the root *spermat/o* to write a word for the following definitions.

11. Condition of having sperm in the urine (-uria) _____
12. Destruction (-lysis) of sperm _____
13. Excessive discharge (-rhea) of semen _____
14. Subnormal concentration of sperm in semen _____
15. A sperm-forming cell _____

The ending *-spermia* means "condition of sperm or semen." Add a prefix to *-spermia* to form a word for the following definitions.

16. presence of blood in the semen _____
17. lack of semen _____
18. secretion of excess (poly-) semen _____
19. presence of pus in the semen _____

Write a word for the following definitions.

20. excision of the ductus deferens _____
21. tumor of the scrotum _____
22. suture of the vas deferens _____
23. excision of the prostate gland _____
24. radiographic study of a seminal vesicle _____
25. inflammation of a seminal vesicle _____
26. incision of the epididymis _____

extern.ir

Clinical Aspects of the Male Reproductive System

INFECTION

Most infections of the male reproductive tract are **sexually transmitted infections** (**STIs**), listed in **BOX 15-2**. The most common STI in the United States is caused by the bacterium *Chlamydia trachomatis*, which mainly causes **urethritis** in males. This same organism also causes lymphogranuloma venereum, an STI associated with lymphadenopathy, which occurs most commonly in tropical regions. Both forms of these chlamydial infections respond to treatment with antibiotics.

Gonorrhea is caused by *Neisseria gonorrhoeae*, the gonococcus (GC). Infection usually centers in the urethra, causing urethritis with burning, a purulent discharge, and dysuria. Untreated, the disease can spread through the reproductive system. Gonorrhea is treated with antibiotics, but gonococci can rapidly develop resistance to these drugs.

Another common STI is herpes infection, caused by a virus. Other STIs are discussed in Chapter 16. Sexually transmitted infections are some of the most common infectious diseases in the United States, affecting up to 20 million men and women each year. Anyone who is sexually active and not in a monogamous sexual relationship with an uninfected partner should have regular checkups for STIs.

Mumps is a nonsexually transmitted viral disease that can infect the testes and lead to **sterility.** Other microorganisms can infect the reproductive tract as well, causing urethritis, **prostatitis**, **orchitis**, or **epididymitis.**

FOR YOUR REFERENCE BOX 15-2

Sexually Transmitted Infections

Disease	Organism	Description
BACTERIAL		
chlamydial infection	*Chlamydia trachomatis* types D to K	Ascending infection of reproductive and urinary tracts; may spread to pelvis in women, causing pelvic inflammatory disease (PID)
lymphogranuloma venereum	*Chlamydia trachomatis* type L	General infection with swelling of inguinal lymph nodes; scarring of genital tissue
gonorrhea	*Neisseria gonorrhoeae*; gonococcus (GC)	Inflammation of reproductive and urinary tracts; urethritis in men; vaginal discharge and cervical inflammation (cervicitis) in women, leading to pelvic inflammatory disease (PID); possible systemic infection; may spread to newborns; treated with antibiotics
bacterial vaginosis	*Gardnerella vaginalis*	Vaginal infection with foul-smelling discharge
syphilis	*Treponema pallidum* (a spirochete)	Primary stage: chancre (lesion); secondary stage: systemic infection and syphilitic warts; tertiary stage: degeneration of other systems; cause of spontaneous abortions, stillbirths, and fetal deformities; treated with antibiotics
VIRAL		
AIDS (acquired immunodeficiency syndrome)	HIV (human immunodeficiency virus)	A disease that infects T cells of the immune system, weakening the host and leading to other diseases: usually fatal if untreated
genital herpes	herpes simplex virus (HSV)	Painful genital lesions; in women, may be a risk factor in cervical carcinoma; often fatal infections of newborns; no cure at present
hepatitis B	hepatitis B virus (HBV)	Causes liver inflammation, which may be acute or may develop into a chronic carrier state; linked to liver cancer
condyloma acuminatum (genital warts)	human papillomavirus (HPV)	Benign genital warts; in women, predisposes to cervical dysplasia and carcinoma; a vaccine against the most prevalent strains is available
PROTOZOAL		
trichomoniasis	*Trichomonas vaginalis*	Vaginitis; green, frothy discharge with itching, pain on intercourse (dyspareunia), and painful urination (dysuria)

extern.ir

BENIGN PROSTATIC HYPERPLASIA

As men age, the prostate gland commonly enlarges, a condition known as **benign prostatic hyperplasia (BPH)**, as noted in Dexter's opening case study. Although not cancerous, this overgrown tissue can press on the urethra near the bladder and interfere with urination. Urinary retention, infection, and other complications may follow if an obstruction is not corrected.

Medications to relax smooth muscle in the prostate and bladder neck are used to treat the symptoms of BPH. Alpha-adrenergic blocking agents interfere with sympathetic nervous stimulation in these regions to improve urinary flow rate. One example is tamsulosin (Flomax). Because testosterone stimulates enlargement of the prostate, drugs that interfere with prostatic testosterone activity may slow the disorder's progress. One example is finasteride (Proscar). A herbal remedy that seems to act in this same manner is an extract of the berries of the saw palmetto, a low-growing palm tree. Saw palmetto has been found to delay the need for surgery in some cases of BPH.

In advanced cases of BPH, removal of the prostate, or **prostatectomy**, may be required. When this is performed through the urethra, the procedure is called a transurethral resection of the prostate (TURP) **(FIG. 15-5A)**. The prostate may also be cut in a transurethral incision of the prostate (TUIP) to reduce pressure on the urethra **(FIG. 15-5B)**. Surgeons also use a laser beam or heat to destroy prostatic tissue. BPH is diagnosed by digital rectal examination (DRE) or imaging studies.

CANCER

Cancer of the Prostate

Prostatic cancer is the most common malignancy among men in the United States. Only lung cancer and colon cancer cause more cancer-related deaths in men who are past middle age. Physicians can often detect prostatic cancer by DRE. Blood tests for prostate-specific antigen (PSA) may also help in early detection. This protein is produced in increased amounts in cases of prostatic cancer, although it may increase in other prostatic disorders as well.

The TNM system for staging prostate cancer includes the following categories:

- T_1: tumor not palpable by rectal examination; detected by biopsy or abnormal PSA
- T_2: tumor palpable and confined to the prostate
- T_3: tumor has spread locally beyond the prostate
- M: distant metastases

Treatment methods include surgery (prostatectomy); radiation; inhibition of male hormones (androgens), which stimulate prostatic growth; and chemotherapy. Radiation is usually delivered by implantation of radioactive seeds. Another approach is termed "watchful waiting" or deferred therapy, which consists of monitoring without therapy. Choice of this option is based on a man's age, tumor invasiveness, and the probability that an untreated tumor will result in harm to a patient during his lifetime. A genetic test for tumor aggressiveness can help to evaluate risk and determine treatment decisions.

Testicular Cancer

Cancer of the testis represents less than 1 percent of cancer in adult males. It usually appears between the ages of 25 and 45 years and shows no sign of genetic inheritance. This cancer typically originates in germ cells and can spread to abdominal lymph nodes. More than half of testicular tumors release markers that can be detected in the blood. Treatment may include removal of the testis (orchiectomy), radiation, and chemotherapy.

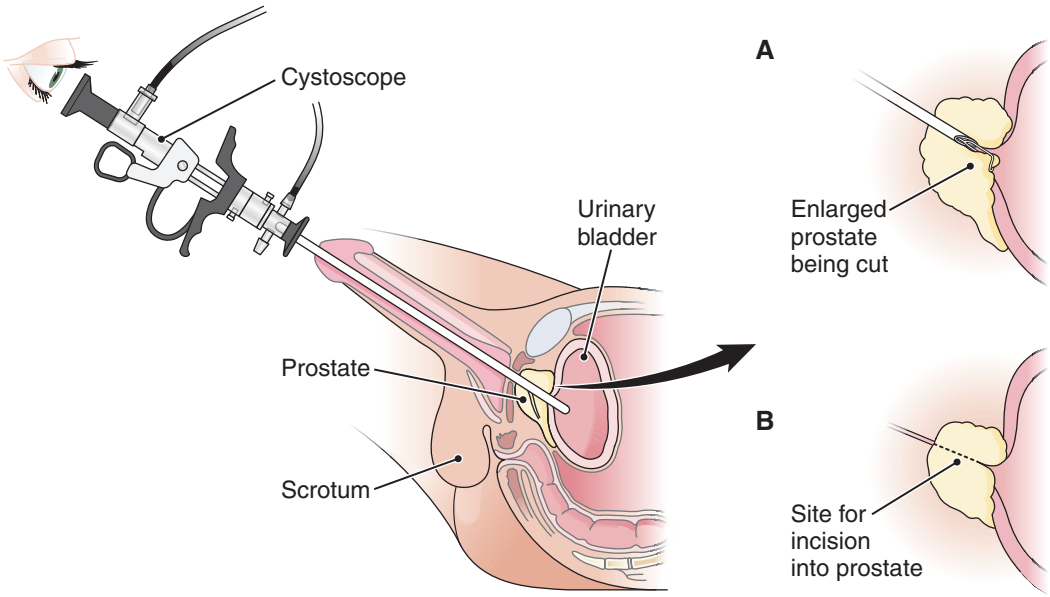

FIGURE 15-5 Prostate surgery procedures. A. Transurethral resection of the prostate (TURP). Portions of the prostate are removed at the bladder opening. **B.** Transurethral incision of the prostate (TUIP). One or two incisions are made in the prostate to reduce pressure on the urethra.

extern.ir

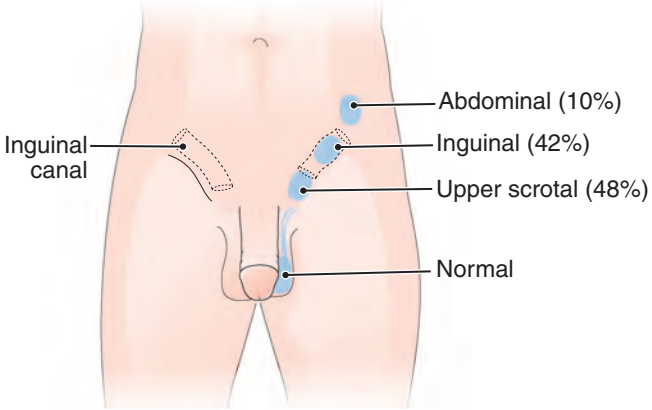

FIGURE 15-6 Cryptorchidism. The testis fails to descend into the scrotum. In most cases, the testis is retained in the upper part of the scrotal sac or in the inguinal canal. The percentages of different locations are shown.

CRYPTORCHIDISM

It is fairly common that one or both testes will fail to descend into the scrotum by the time of birth (FIG. 15-6). This condition is termed **cryptorchidism**, literally hidden (crypt/o) testis (orchid/o). The condition usually corrects itself within the first year of life. If not, it must be corrected surgically to avoid sterility and an increased risk of cancer.

INFERTILITY

An inability or a diminished ability to reproduce is termed **infertility.** Its causes may be hereditary, hormonal, disease-related, or the result of exposure to chemical or physical agents. The most common causes of infertility are STIs. A total inability to produce offspring may be termed sterility. Men may be voluntarily sterilized by cutting and sealing the vas deferens on both sides in a **vasectomy** (see FIG. 16-5 in Chapter 16).

Erectile Dysfunction

Erectile dysfunction (ED), also called **impotence**, is the inability of the male to perform intercourse because of failure to initiate or maintain an erection until ejaculation. About 10 to 20 percent of such cases are psychogenic, that is, caused by emotional factors, such as stress, depression, or emotional trauma. More often, ED has a physical cause, which may be:

- A vascular disorder such as arteriosclerosis, varicose veins, or damage caused by diabetes.
- A neurologic problem, as caused by a tumor, trauma, the effects of diabetes, or damage caused by radiation or surgery.
- A side effect of a drug, such as an antihypertensive agent, antiulcer medication, or appetite suppressant.

Drugs that are used to treat ED work by dilating arteries in the penis to increase blood flow to that organ. Nondrug approaches include corrective surgery; vacuum pumps to draw blood into the penis; penile injections to dilate blood vessels; and penile prostheses. BOX 15-3 has more information on ED.

Physician assistants aid in patient examination and care in urology and many other medical and surgical fields. BOX 15-4 describes careers in this specialty.

INGUINAL HERNIA

The inguinal canal, through which the testis descends, may constitute a weakness in the abdominal wall that can lead to a hernia. In the most common form of **inguinal hernia** (FIG. 15-7), an abdominal organ, usually the intestine, enters the inguinal canal and may extend into the scrotum. This is an indirect, or external, inguinal hernia. In a direct, or internal, inguinal hernia, the organ protrudes through the abdominal wall into the scrotum. If blood supply to the organ is cut off, the hernia is said to be *strangulated*. Surgery to correct a hernia is a **herniorrhaphy**.

CLINICAL PERSPECTIVES
Treating Erectile Dysfunction

BOX 15-3

Approximately 25 million American men and their partners are affected by ED, the inability to achieve or maintain an erection. Although ED is more common in men over the age of 65, it can occur at any age and can have many causes.

Erection results from an interaction between the autonomic nervous system and penile blood vessels. Sexual arousal stimulates parasympathetic nerves in the penis to release a compound called nitric oxide (NO). This substance activates an enzyme in vascular smooth muscle that promotes vasodilation, increasing blood flow into the penis and causing erection. Physical factors that cause ED prevent these physiologic changes.

Drugs that target the physiologic mechanisms of erection are helping men who suffer from ED. These include sildenafil (trade name, Viagra), vardenafil (Levitra), and tadalafil (Cialis). These drugs prevent the breakdown of vasodilators, thus prolonging the effects of NO. Although effective in about 80 percent of ED cases, these drugs can cause some relatively minor side effects, including headache, nasal congestion, stomach upset, and blue-tinged vision. They should never be used by men who are taking nitrate drugs to treat angina. Because nitrates elevate NO levels, taking them with drugs for ED and prolonging the effects of NO can cause life-threatening hypotension. They are also contraindicated in men with low blood pressure and heart failure.

extern.ir

HEALTH PROFESSIONS
Physician Assistant

BOX 15-4

Physician assistants (PAs) practice medicine under the supervision of physicians and surgeons. They are trained in diagnosis, therapy, and preventive health care. They are also licensed to treat minor injuries. In almost all states, they are permitted to prescribe medications. Depending on the work setting, they may also manage a practice and supervise other medical personnel. In medically underserved areas, they may work under their own direction and confer with physicians as needed. Many PAs work in general, pediatric, or family medicine practices. If they specialize in surgery, they may provide patient care before and after an operation or assist in surgery.

A PA must complete a formal 6-year educational program: 4 years of undergraduate work and a 2-year master's degree. The majority of PA programs require candidates to enter with a bachelor's degree, core science courses, and clinical experience either in the military or some other allied health field. After successful completion of a didactic year and a year of clinical rotations, PAs must be licensed by passing a national examination. They may also become certified (PA-C) through the National Commission on Certification of Physician Assistants (NCCPA) and maintain that certification by continuing education. The job outlook is very good, especially as hospitals are required to compensate for shorter medical residents' shifts by increasing staffing with PAs. Also, medical personnel can consult with ease via telecommunication, allowing for physical independence at certain practices. For additional information, contact the American Academy of Physician Assistants at aapa.org.

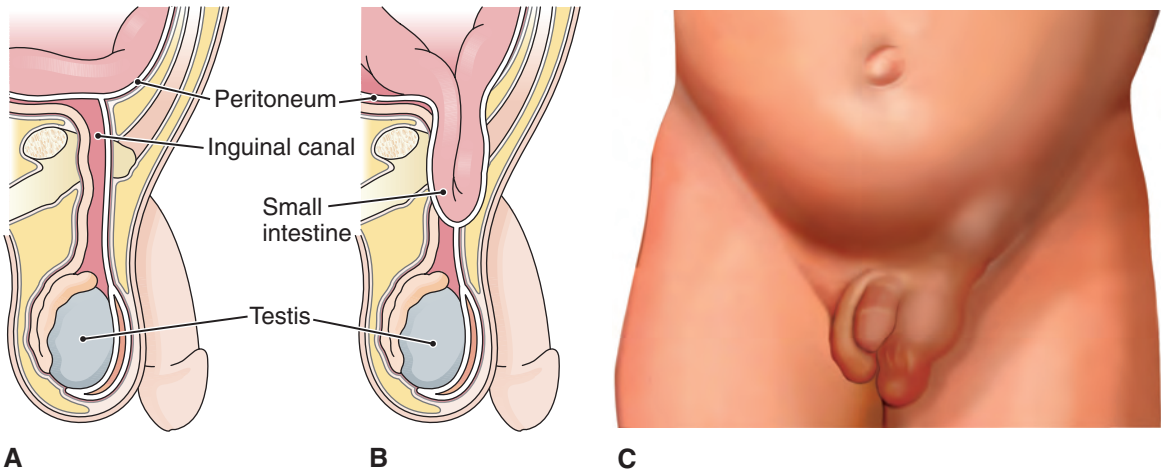

FIGURE 15-7 Inguinal hernia. A. Normal. **B.** Weakness in the abdominal wall allows the intestine or other abdominal contents to protrude into the inguinal canal. The hernial sac is a continuation of the peritoneum. **C.** An inguinal hernia can cause a visible bulge in the inguinal area and scrotum.

Terminology *Key Terms*

The terms listed below are emphasized in this chapter. Knowing them will help you organize and prioritize your learning. These boldface terms are also found, collectively, with all chapter key terms in the Glossary.

Disorders

benign prostatic hyperplasia (BPH) *be-NINE pros-TAT-ik hi-per-PLA-ze-ah*	Nonmalignant enlargement of the prostate; frequently develops with age
cryptorchidism *krip-TOR-kid-izm*	Failure of the testis to descend into the scrotum (see **FIG. 15-6**)
epididymitis *ep-ih-did-ih-MI-tis*	Inflammation of the epididymis; common causes are UTIs and STIs
erectile dysfunction (ED) *eh-REK-tile dis-FUNK-shun*	Inability of the male to perform intercourse because of failure to initiate or maintain an erection until ejaculation; impotence

(continued)

extern.ir

Terminology Key Terms (Continued)

impotence *IM-po-tens*	Erectile dysfunction
infertility *in-fer-TIL-ih-te*	Decreased capacity to produce offspring
inguinal hernia *ING-gwin-al*	Protrusion of the intestine or other abdominal organ through the inguinal canal (see **FIG. 15-7**) or through the wall of the abdomen into the scrotum
orchitis *or-KI-tis*	Inflammation of a testis; may be caused by injury, mumps virus, or other infections
prostatitis *pros-tah-TI-tis*	Inflammation of the prostate gland; often appears with UTI, STI, and a variety of other stresses
sexually transmitted infection (STI)	Infection spread through sexual activity (see **BOX 15-2**); also called sexually transmitted disease (STD) and formerly venereal (*veh-NE-re-al*) disease (VD) (from Venus, the goddess of love)
sterility *steh-RIL-ih-te*	Complete inability to produce offspring
urethritis *u-re-THRI-tis*	Inflammation of the urethra; often caused by gonorrhea and chlamydia infections
Surgery	
herniorrhaphy *her-ne-OR-ah-fe*	Surgical repair of a hernia
prostatectomy *pros-tah-TEK-to-me*	Surgical removal of the prostate
vasectomy *vah-SEK-to-me*	Excision of the vas deferens; usually done bilaterally to produce sterility (see **FIG. 16-5**); may be accomplished through the urethra (transurethral resection)

Terminology Enrichment Terms

The terms listed below expand on the key terms to increase your knowledge of this chapter topic.

Normal Structure and Function	
emission *e-MISH-un*	The discharge of semen
genitalia *jen-ih-TA-le-ah*	The organs concerned with reproduction, divided into internal and external components
insemination *in-sem-ih-NA-shun*	Introduction of semen into a woman's vagina
orgasm *OR-gazm*	A state of physical and emotional excitement, especially that which occurs at the climax of sexual intercourse
phallus *FAL-us*	The penis (adjective: phallic)
Disorders	
balanitis *bal-ah-NI-tis*	Inflammation of the glans penis and mucous membrane beneath it (root balan/o means "glans penis")

extern.ir

Terminology Enrichment Terms (Continued)

bladder neck obstruction (BNO)	Blockage of urine flow at the outlet of the bladder; the common cause is benign prostatic hyperplasia
hydrocele *HI-dro-sele*	The accumulation of fluid in a sac-like cavity, especially within the covering of the testis or spermatic cord **(FIG. 15-8)**
phimosis *fi-MO-sis*	Narrowing of the prepuce's opening so that the foreskin cannot be pushed back over the glans penis
priapism *PRI-ah-pizm*	Abnormal, painful, continuous erection of the penis, as may be caused by drugs or specific damage to the spinal cord
seminoma *sem-ih-NO-mah*	A tumor of the testis
spermatocele *SPER-mah-to-sele*	An epididymal cyst containing spermatozoa (see **FIG. 15-8**)
varicocele *VAR-ih-ko-sele*	Enlargement of the veins of the spermatic cord (see **FIG. 15-8**)
Diagnosis and Treatment	
brachytherapy *brak-e-THER-ah-pe*	Radiation therapy by placement of encapsulated radiation sources, such as seeds, directly into a tumor or nearby tissue (from Greek *brachy*, meaning "short")
castration *kas-TRA-shun*	Surgical removal of the testes or ovaries; hormones and drugs can inhibit the gonads to produce functional castration
Gleason tumor grade *GLE-son*	A system for assessing the severity of cancerous changes in the prostate; reported as a Gleason score
resectoscope *re-SEK-to-skope*	Endoscopic instrument for transurethral removal of tissue from the urinary bladder, prostate gland, uterus, or urethra
Whitmore–Jewett staging *WIT-more JEW-et*	A method for staging prostatic tumors; an alternate to TNM staging

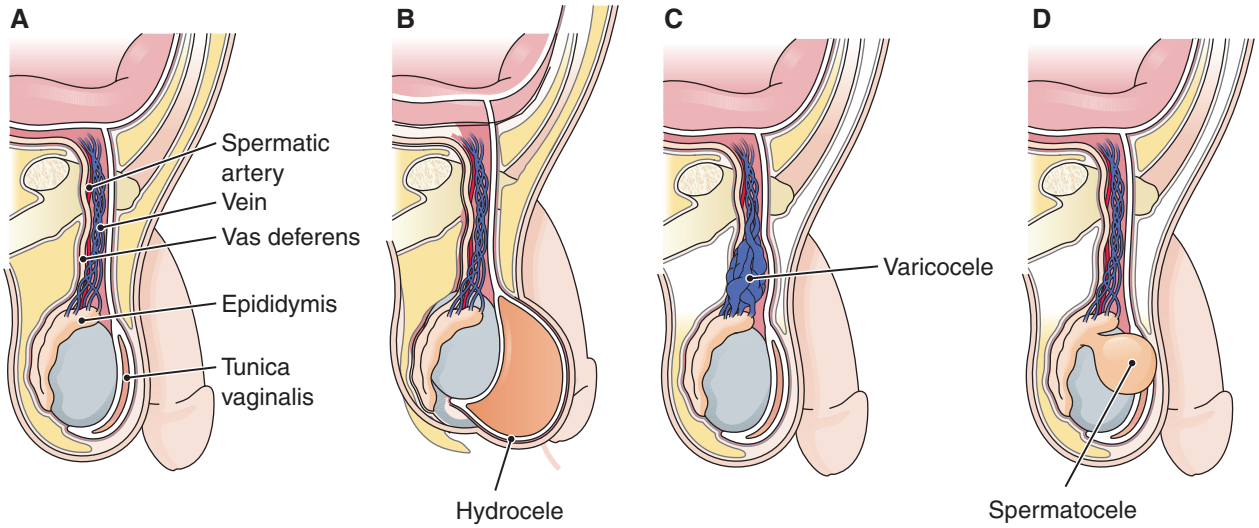

FIGURE 15-8 Scrotal abnormalities. A. Normal. **B.** Hydrocele. **C.** Varicocele. **D.** Spermatocele.

extern.ir

Terminology *Abbreviations*

The abbreviations listed below are emphasized in this chapter. These are also found, collectively, with all chapter abbreviations in Appendix 2.

AIDS	Acquired immunodeficiency syndrome
BNO	Bladder neck obstruction
BPH	Benign prostatic hyperplasia
DRE	Digital rectal examination
ED	Erectile dysfunction
FSH	Follicle-stimulating hormone
GC	Gonococcus
GU	Genitourinary
HBV	Hepatitis B virus
HIV	Human immunodeficiency virus
HSV	Herpes simplex virus
LH	Luteinizing hormone
NGU	Nongonococcal urethritis
PSA	Prostate-specific antigen
STD	Sexually transmitted disease
STI	Sexually transmitted infection
TPUR	Transperineal urethral resection
TSE	Testicular self-examination
TUIP	Transurethral incision of prostate
TURP	Transurethral resection of prostate
UG	Urogenital
UTI	Urinary tract infection
VD	Venereal disease (sexually transmitted infection)
VDRL	Venereal Disease Research Laboratory (test for syphilis)

Case Study Revisited

Dexter's Follow-Up

On the morning of the second postoperative day, the Foley catheter was removed, and Dexter was able to void on his own. He experienced dysuria and some burning when urinating, but otherwise did not have any postoperative complications. The urologist informed Dexter that it is normal to find urinating uncomfortable and difficult for at least a few days after the catheter is removed. He also explained that removing the extra prostate tissue help urination be easier and less frequent. Most men who have this surgery are back to their regular activities in 4 to 6 weeks.

Dexter remained in the hospital through the second day and was discharged home with specific instructions. The nurse explained that during recovery there may be an urgent need to urinate, trouble controlling urination, pain during urination, problems getting and keeping an erection, and some small amounts of blood in the urine. The nurse said these surgery side effects should subside in time. Dexter was informed that he should call his urologist if these problems are still present several weeks after surgery.

At his 4-week follow-up appointment with the urologist, Dexter was cleared to continue with his normal activities such as playing tennis and lifting weights at his community gym.

extern.ir

CHAPTER 15 Review

This review tests your understanding of the content introduced in this chapter. Follow the instructions for each exercise and check your answers in Appendix 11.

LABELING EXERCISE

MALE REPRODUCTIVE SYSTEM

Write the name of each numbered part on the corresponding line.

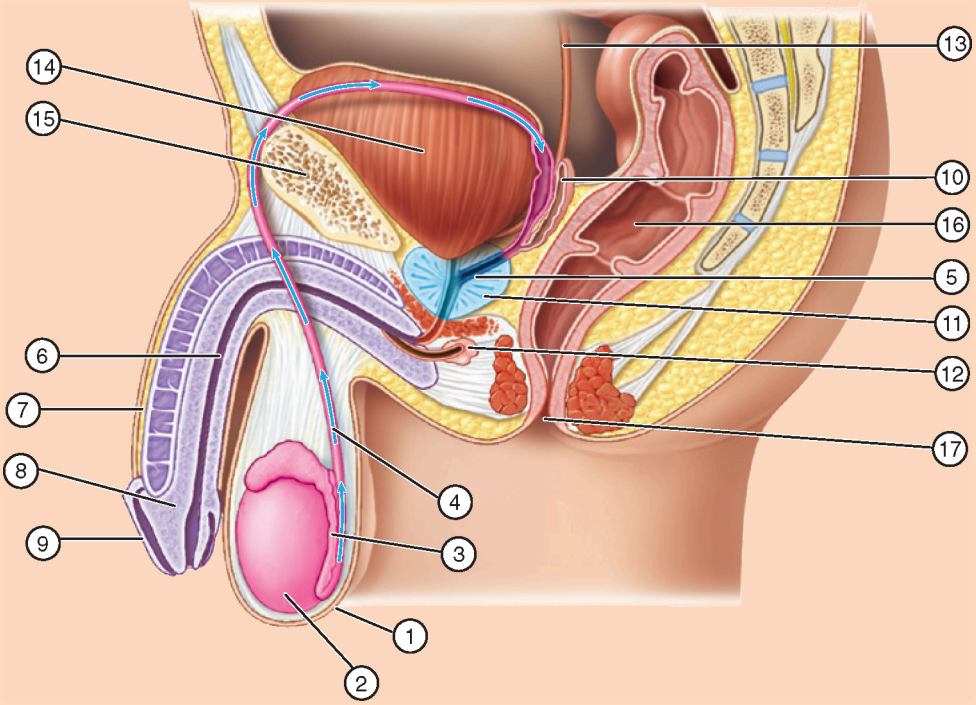

Anus	Glans penis	Rectum	Ureter
Bulbourethral gland	Penis	Scrotum	Urethra
Ductus (vas) deferens	Prepuce (foreskin)	Seminal vesicle	Urinary bladder
Ejaculatory duct	Prostate	Testis	
Epididymis	Pubic bone		

1. _____
2. _____
3. _____
4. _____
5. _____
6. _____
7. _____
8. _____
9. _____
10. _____
11. _____
12. _____
13. _____
14. _____
15. _____
16. _____
17. _____

extern.ir

TERMINOLOGY

MATCHING

Match the following terms, and write the appropriate letter to the left of each number.

____ 1.	gamete	a. reproductive cell
____ 2.	androgen	b. start of sexual maturity
____ 3.	gonad	c. hormone that produces male characteristics
____ 4.	puberty	d. cell division that forms the gametes
____ 5.	meiosis	e. sex gland

____ 6.	vasectomy	a. excision of the ductus deferens
____ 7.	circumcision	b. erectile dysfunction
____ 8.	impotence	c. surgical removal of the foreskin
____ 9.	glans	d. end of the penis
____ 10.	coitus	e. sexual intercourse

Enrichment Terms

____ 11.	priapism	a. narrowing of the foreskin opening
____ 12.	phallic	b. prolonged erection of the penis
____ 13.	genitalia	c. tumor of the testis
____ 14.	phimosis	d. reproductive organs
____ 15.	seminoma	e. pertaining to the penis

____ 16.	spermatocele	a. inflammation of the glans penis
____ 17.	balanitis	b. a form of radiation treatment
____ 18.	castration	c. discharge of semen
____ 19.	emission	d. removal of the testes
____ 20.	brachytherapy	e. epididymal cyst

FILL IN THE BLANKS

Complete the sentence with the correct term(s).

21. The main male sex hormone is _____ .
22. The two glands that secrete into the urethra just below the prostate gland are the _____ .
23. The thick fluid that transports spermatozoa is _____ .
24. The male gonad is the _____ .
25. The channel through which the testis descends is the _____ .
26. The sac that holds the testis is the _____ .

DEFINITIONS

Define the following terms.

27. vasorrhaphy (*vas-OR-ah-fe*) _____
28. anorchism (*an-OR-kizm*) _____
29. oscheoma (*os-ke-O-mah*) _____
30. vesiculography (*veh-sik-u-LOG-rah-fe*) _____
31. prostatometer (*pros-tah-TOM-eh-ter*) _____
32. hemospermia (*he-mo-SPER-me-ah*) _____

extern.ir

Write words for the following definitions.

33. surgical fixation of the testis _____
34. stone in the scrotum _____
35. surgical incision of the epididymis _____
36. plastic repair of the scrotum _____
37. surgical creation of an opening between two parts of a cut ductus deferens (done to reverse a vasectomy) _____

Find a word in Dexter's opening case study for each of the following definitions (see also Chapter 14).

38. blood in the urine _____
39. painful urination _____
40. within the urinary bladder _____
41. overdevelopment of tissue _____
42. instrument for excising tissue _____

TRUE–FALSE

Examine the following statements. If the statement is true, write T in the first blank. If the statement is false, write F in the first blank, and correct the statement by replacing the underlined word in the second blank.

	True or False	Correct Answer
43. Any male sex hormone is an <u>androgen</u>.	_____	_____
44. The adjective *seminal* refers to the <u>seminal vesicle</u>.	_____	_____
45. The spirochete *Treponema pallidum* causes <u>syphilis</u>.	_____	_____
46. Herpes simplex is a <u>virus</u>.	_____	_____
47. The <u>ureter</u> carries both urine and semen in males.	_____	_____
48. FSH and LH are produced by the <u>pituitary gland</u>.	_____	_____
49. Spermatogenesis begins at <u>puberty</u>.	_____	_____

ELIMINATIONS

In each of the sets below, underline the word that does not fit in with the rest, and explain the reason for your choice.

50. bulbourethral gland — prostate — testis — spermatic cord — seminal vesicle

_____

51. FSH — semen — testosterone — androgen — LH

_____

52. condyloma acuminatum — gonorrhea — hernia — AIDS — herpes

_____

extern.ir

ADJECTIVES

Write the adjective form of the following words.

53. semen _____
54. prostate _____
55. penis _____
56. urethra _____
57. scrotum _____

ABBREVIATIONS

Write the meaning of the following abbreviations.

58. BPH _____
59. STI _____
60. ED _____
61. GC _____
62. PSA _____
63. GU _____
64. TURP _____

FOLLOW THE FLOW

Describing the pathway of semen flow, put the following steps in the correct order by placing the letters "A" through "F" in the spaces provided.

____ 65. ejaculatory duct delivers sperm to the urethra

____ 66. sperm cells, mixed with other secretions, travel through the prostate gland

____ 67. sperm cells mix with secretions from the seminal vesicle

____ 68. sperm is propelled through ductus deferens

____ 69. sperm cells are manufactured and stored in the epididymis

____ 70. cells travel in the urethra through the penis to be released

WORD BUILDING

Write a word for the following definitions using the word parts given. Each word part can be used more than once.

-ar	-tomy	-graphy	-genesis	spermat/o	vas/o	-plasty	-itis	-ic	-cyte	-lysis	vesicul/o

71. plastic repair of the ductus deferens _____
72. destruction of sperm cells _____
73. pertaining to the seminal vesicle _____
74. x-ray study of the vas deferens _____
75. inflammation of the seminal vesicle _____
76. pertaining to spermatozoa _____
77. cell that develops into a sperm cell _____
78. incision of the ductus deferens _____
79. formation of spermatozoa _____
80. radiographic study of the seminal vesicle _____

extern.ir

WORD ANALYSIS

Define the following words, and give the meaning of the word parts in each. Use a dictionary if necessary.

81. hydrocelectomy (*hi-dro-se-LEK-to-me*)
    a. hydr/o _____
    b. -cele _____
    c. ecto- _____
    d. tom/o _____
    e. -y _____
82. spermicidal (*sper-mih-SI-dal*)
    a. sperm/i _____
    b. -cide _____
    c. -al _____
83. cryptorchidism (*krip-TOR-kid-izm*)
    a. crypt- _____
    b. orchid/o _____
    c. -ism _____
84. vasovesiculitis (*vas-o-veh-sik-u-LI-tis*)
    a. vas/o _____
    b. vesicul/o _____
    c. -itis _____
85. polyspermia
    a. poly- _____
    b. sperm/o _____
    c. -ia _____

extern.ir

Additional Case Studies

Case Study 15-1: Herniorrhaphy and Vasectomy

Derek, a 48 y/o married dock worker with three children, had inguinal bulging and pain on exertion when he lifted heavy objects. An occupational health service advised a surgical referral. The surgeon diagnosed Derek with bilateral direct inguinal hernias and suggested that he not delay surgery, although he was not at high risk for a strangulated hernia. Derek asked the surgeon if he could also be sterilized at the same time. He was scheduled for bilateral inguinal herniorrhaphy and elective vasectomy.

During the herniorrhaphy procedure, an oblique incision was made in each groin. The incision continued through the muscle layers by either resecting or splitting the muscle fibers. The spermatic vessels and vas deferens were identified, separated, and gently retracted. The spermatic cord was examined for an indirect hernia. Repair began with suturing the defect in the rectus abdominis muscles, transverse fascia, cremaster muscle, external oblique aponeurosis, and Scarpa fascia with heavy-gauge synthetic nonabsorbable suture material.

The vasectomy began with the identification of the vas deferens through the scrotal skin. An incision was made, and the vas was gently dissected and retracted through the opening. Each vas was clamped with a small hemostat, and a 1-cm length was resected. Both cut ends were coagulated with electrosurgery and tied independently with a fine-gauge absorbable suture material. The testicles were examined, and the scrotal incision was closed with an absorbable suture material.

Case Study 15-1 Questions

Multiple Choice. *Select the best answer, and write the letter of your choice to the left of each number.*

_____ 1. The term for male sterilization surgery is
   a. herniorrhaphy
   b. circumcision
   c. vagotomy
   d. vasectomy

_____ 2. An oblique surgical incision follows which direction?
   a. slanted or angled
   b. superior to inferior
   c. lateral
   d. circumferential

_____ 3. When the ends of the vas were coagulated with electrosurgery, they were
   a. dilated
   b. sealed
   c. sutured
   d. clamped

Write a term from the case study with the following meanings.

4. surgical repair of a weak abdominal muscle in the groin area on both sides _____
5. entrapment of a bowel loop in a hernia _____
6. inflammation of the glans penis _____
7. narrowing of the distal opening of the foreskin _____

extern.ir

Case Study 15-2: Erectile Dysfunction

Diego, a 67 y/o attorney, was at his annual appointment with his internist when he decided to discuss what he considered an embarrassing subject, erectile dysfunction (ED). Diego was happily married with four grown children and had continued to enjoy an active sexual relationship with his wife, until recently. He was having difficulty sustaining an erection. He had seen so much media publicity on this subject that he decided to bring it up with his physician. At the conclusion of the appointment, the internist ruled out any psychogenic causes or adverse effects of medications, such as an antidepressant or an antihypertensive, that could predispose to ED. He recommended that Diego schedule a follow-up visit to his urologist to make certain there were no underlying physical factors that would contribute to his impotence.

Diego made an appointment with the urologist whom he had seen about 10 years ago when he was diagnosed with BPH. At that time, the physician had reviewed various therapies with Diego, so Diego felt comfortable discussing his present concerns.

The urologist's examination ruled out trauma, vascular disorders, or tumors. It was decided to have Diego try an ED medication. The physician explained that the impotence agents work by targeting the physiologic mechanisms of erection. They promote vasodilation to increase blood flow to the penis. Side effects of the medications were also discussed. Diego was relieved that he had no tumor or other disease condition. He understood the therapy plan and left with follow-up instructions.

Case Study 15-2 Questions

Multiple Choice. *Select the best answer, and write the letter of your choice to the left of each number.*

_____ 1. A urologist is a physician who treats health and disease conditions of the
   a. male reproductive system
   b. urinary system
   c. digestive system
   d. a and b

_____ 2. Impotence is a condition that
   a. precedes a vasectomy
   b. is synonymous with ED
   c. refers to the inability to maintain penile erection
   d. b and c

_____ 3. BPH is a condition of the prostate gland that
   a. is cancerous
   b. causes impotence
   c. requires vasodilation agents as treatment
   d. may cause urinary retention and infection

_____ 4. The ED drugs Viagra and Cialis target the physiologic mechanisms of erection by
   a. increasing urinary and semen flow
   b. dilating arteries in the penis to increase blood flow
   c. increasing neurotransmitters to treat underlying psychogenic causes
   d. b and c

Write a term from the case study with the following meanings.

5. originating in the mind _____
6. widening of blood vessels _____
7. drug for treatment of high blood pressure _____

extern.ir

CHAPTER 16

Female Reproductive System; Pregnancy and Birth

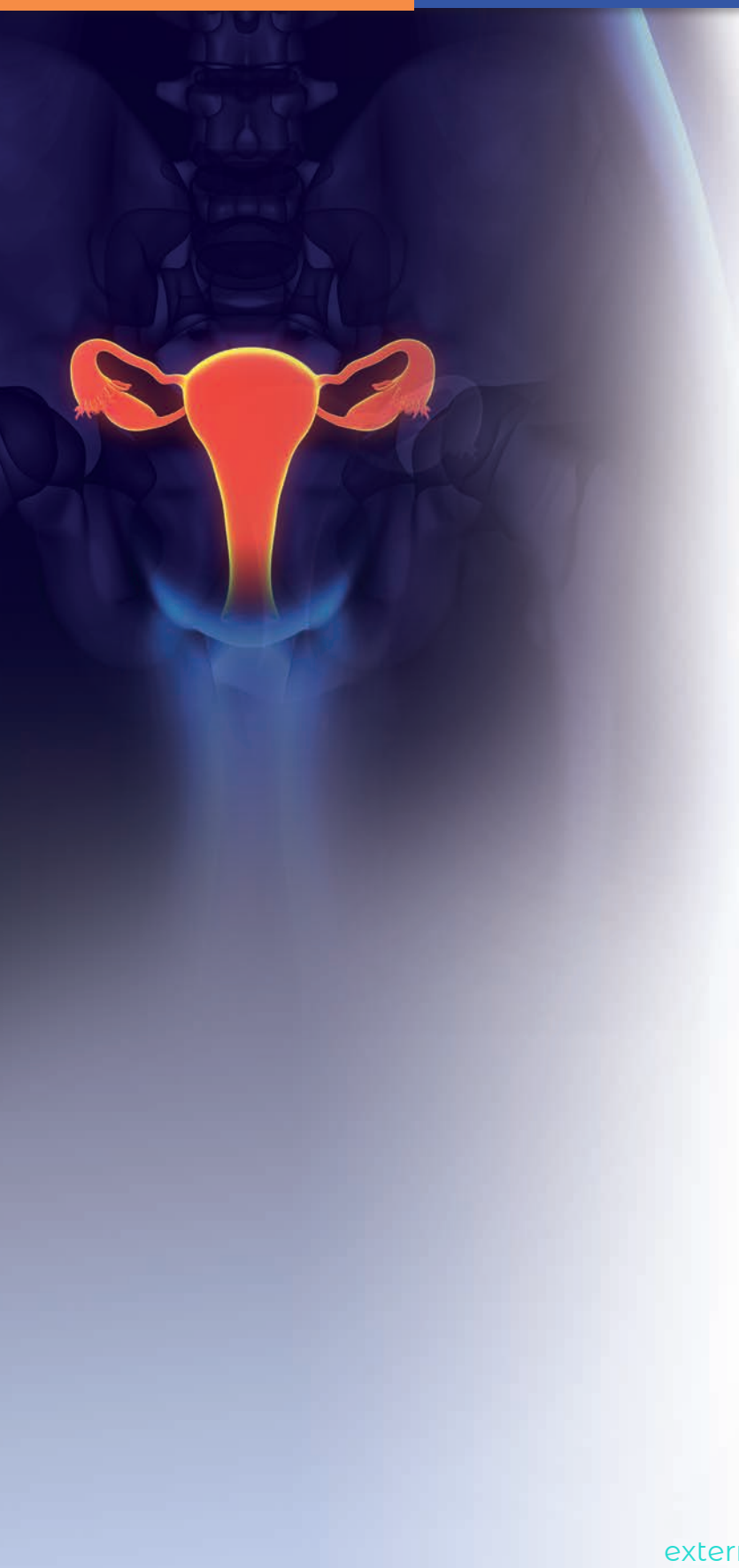

Pretest

Multiple Choice. **Select the best answer, and write the letter of your choice to the left of each number. To check your answers go to Appendix 11.**

_____ 1. The female gonad is the
a. uterus
b. cervix
c. ovary
d. testis

_____ 2. The two ovarian hormones are
a. testosterone and estrogen
b. estrogen and progesterone
c. thyroxine and progesterone
d. progesterone and testosterone

_____ 3. Use of artificial methods to prevent fertilization is termed
a. conception
b. coitus
c. contraception
d. gestation

_____ 4. During the first 2 months of growth, the developing offspring is called a(n)
a. neonate
b. embryo
c. zygote
d. fetus

_____ 5. The structure that nourishes the developing fetus is the
a. mammary gland
b. cervix
c. placenta
d. follicle

_____ 6. Production of milk is technically called
a. ovulation
b. lactation
c. corpus luteum
d. parturition

_____ 7. The roots *metr/o* and *hyster/o* mean
a. uterus
b. vagina
c. follicle
d. ovary

_____ 8. Any disorder present at birth is described as
a. hereditary
b. genetic
c. congenital
d. familial

extern.ir

Learning Objectives

After careful study of this chapter, you should be able to:

1. Describe the female reproductive tract, and give the function of each part. ***P512***
2. Describe the structure and function of the mammary glands. ***P514***
3. Outline the events in the menstrual cycle. ***P514***
4. List three categories of contraception with examples of each. ***P515***
5. Describe seven disorders of the female reproductive system. ***P521***
6. Outline the major events that occur in the first 2 months after fertilization. ***P528***
7. Describe the structure and function of the placenta. ***P528***
8. Describe two adaptations in fetal circulation, and cite their purposes. ***P530***
9. Describe the three stages of childbirth. ***P531***
10. List the hormonal and nervous controls over lactation. ***P532***
11. Identify and use roots pertaining to the female reproductive system, pregnancy, and birth. ***PP518, 534***
12. Describe six disorders of pregnancy and birth. ***P535***
13. Define two types of congenital disorders and give examples each. ***P536***
14. Interpret abbreviations used in referring to reproduction. ***PP528, 543***
15. Analyze the medical terms in several case studies concerning the female reproductive system, pregnancy, and birth. ***PP511, 552***

Case Study: Abigail's Cesarean Section

Chief Complaint

Abigail is a 29 y/o gravida 2, para 1, at 39 weeks of gestation. Her first pregnancy resulted in a cesarean section. She had had an uneventful pregnancy with good health, moderate weight gain, good fetal heart sounds, and no signs or symptoms of pregnancy-induced hypertension. Abigail went to the hospital when she realized she was going into labor.

Examination

Abigail had been in active labor for several hours, fully effaced and dilated, yet unable to progress. Her obstetrician ordered an x-ray pelvimetry test that revealed cephalopelvic disproportion (CPD) with the fetus in the right occiput posterior position. Changes in fetal heart rate indicated fetal distress. Abigail was transported to the OR for an emergency C-section under spinal anesthesia.

Clinical Course

After being placed in the supine position, Abigail had a urethral catheter inserted, and her abdomen was prepped with antimicrobial solution. After draping, a transverse suprapubic incision was made. Dissection was continued through the muscle layers to the uterus, with care not to nick the bladder. The uterus was incised through the lower segment, 2 cm from the bladder. The fetal head was gently elevated through the incision while the assistant put gentle pressure on the fundus. The baby's mouth and nose were suctioned with a bulb syringe, and the umbilical cord was clamped and cut. The baby was handed off to an attending pediatrician and OB nurse and placed in a radiant neonate warmer bed. The Apgar score was 9/9. The placenta was gently delivered from the uterus, and the scrub nurse checked for three vessels and filled two sterile test tubes with cord blood for laboratory analysis. Abigail was given an injection of Pitocin to stimulate uterine contraction. The uterus and abdomen were closed, and Abigail was transported to the postanesthesia care unit (PACU).

Case Study Revisited: Once you complete this chapter, please review the case follow-up on p. 544.

extern.ir

Ancillaries *At-A-Glance*

Visit the web resource to access the following resources.

Learning Resources

- eBook
- A&P Module with Heart & Lung Sounds
- Image Bank
- TestPrep
- Animations
- Audio Pronunciation Glossary

Introduction

As in males, the female reproductive tract consists of internal organs and external genitalia. The breasts, or mammary glands, although not part of the reproductive system, are usually included with a discussion of this system, as their purpose is to nourish an infant.

In contrast to the continuous gametogenesis in males, formation of the female gamete is cyclic, with an egg released midway in the menstrual cycle. Each month, the **uterus** is prepared to receive a fertilized egg. If fertilization occurs, the developing offspring is nourished and protected by the placenta and surrounding fluids until birth. If the released egg is not fertilized, the lining of the uterus is sloughed off in menstruation.

The Female Reproductive System

THE OVARIES

The female gonads are the paired **ovaries** (singular: ovary) that are held by ligaments in the pelvic cavity on either side of the uterus). These ligaments, as well as the ovaries and uterine tubes, are contained within the broad ligaments, folds of the peritoneum that anchor the uterus to the lateral body wall **(FIG. 16-1)**. It is within the ovaries that the female gametes, the eggs or **ova** (singular: ovum), develop. Every month, several ova ripen, each within a cluster of cells called an **ovarian follicle.** At the time of **ovulation**, usually only one ovum is released from an ovary, and the remainder of the ripening ova degenerate. The follicle remains behind and continues to function for about 2 weeks if the ovum is not fertilized and for about 2 months if the ovum is fertilized.

THE UTERINE TUBES, UTERUS, AND VAGINA

After ovulation, the ovum travels into a **uterine tube**, also called the **fallopian tube**, attached to the upper lateral portion of the uterus (see **FIG. 16-1**). This tube arches above the ovary and has finger-like projections called **fimbriae** that sweep the released ovum into the uterine tube. If fertilization takes place, it typically occurs in a uterine tube.

The uterus is the organ that nourishes the developing offspring. It is pear-shaped, with an upper rounded fundus, a triangular cavity, and a lower narrow **cervix** that projects into the **vagina.** The recess around the cervix in the superior vagina is the **fornix.** At the posterior cervix, the peritoneum dips downward to form a blind pouch, the **rectouterine pouch,** the lowest point of the peritoneal cavity. This region is also called the *cul-de-sac,* from French, meaning "bottom of the bag." The innermost layer of the uterine wall, the **endometrium**, has a rich blood supply. It receives the fertilized ovum and becomes part of the placenta during pregnancy. The endometrium is shed during the menstrual period if no fertilization occurs. The muscle layer of the uterine wall is the **myometrium.**

The vagina is a muscular tube that receives the penis during intercourse, functions as a birth canal, and transports the menstrual flow out of the body (see **FIG. 16-1**).

THE EXTERNAL GENITAL ORGANS

All of the external female genitalia together are called the **vulva (FIG. 16-2)**. This includes the large outer **labia majora** (singular: labium majus) and small inner **labia minora** (singular: labium minus) that enclose the vaginal and urethral openings. The **clitoris**, anterior to the urethral opening, is similar in developmental origin to the penis and responds to sexual stimulation. The vulva also includes the openings of ducts from two small glands on either side of the vagina that secrete mucus for lubrication during intercourse. These are the **greater vestibular glands** or *Bartholin glands*.

In both males and females, the region between the thighs from the external genital organs to the anus is the **perineum.** During childbirth, an incision may be made between the vagina and the anus to facilitate birth and prevent the tearing of tissue, a procedure called an *episiotomy.* (This procedure is actually a perineotomy, as the root episi/o means "vulva.")

The Mammary Glands

The **mammary glands,** or breasts, are not a part of the female reproductive system itself, but are included in this chapter as they function in providing infant nourishment after birth, as

extern.ir

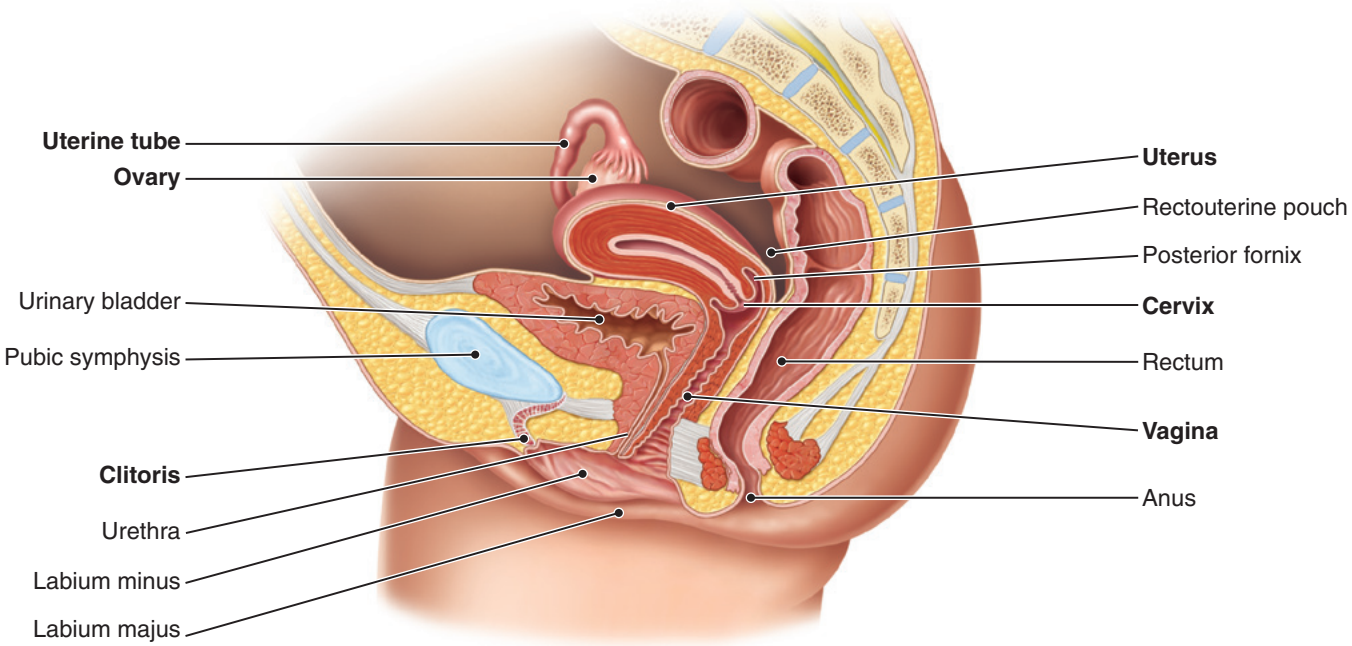

A Sagittal view

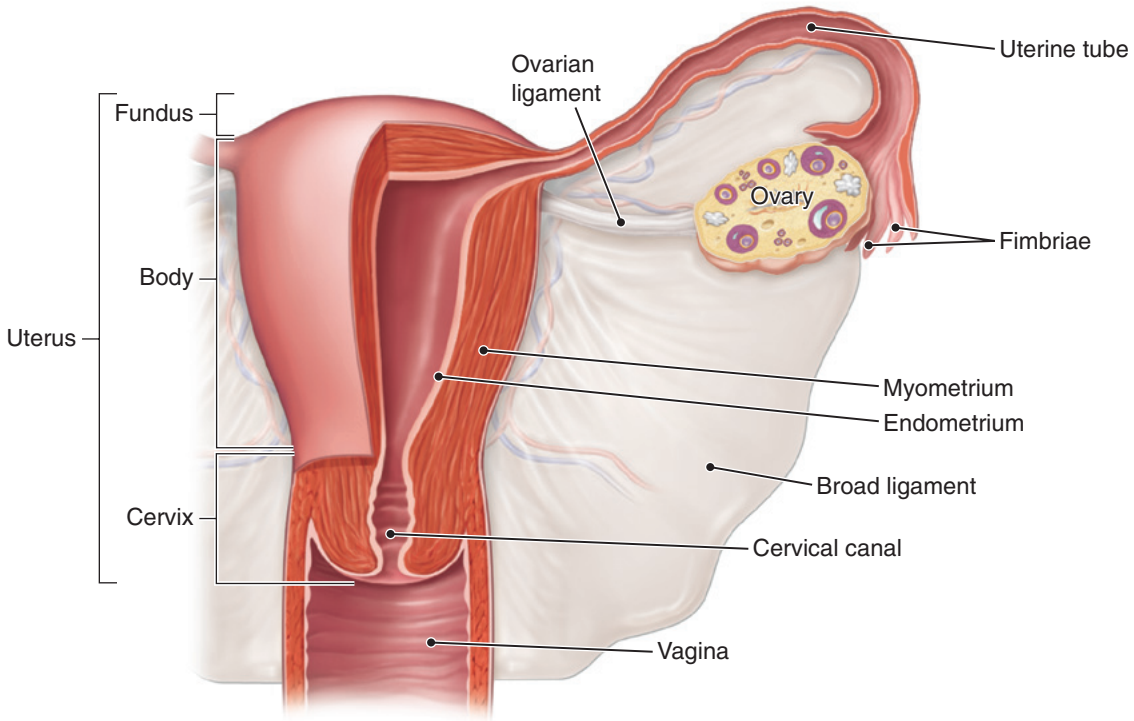

B Frontal view

FIGURE 16-1 Female reproductive system. A. As seen in sagittal section, the internal female genitalia are located between structures of the urinary and gastrointestinal systems, which are also shown. The reproductive structures are labeled in bold type. **B.** Ligaments hold the uterus and ovaries in place.

extern.ir

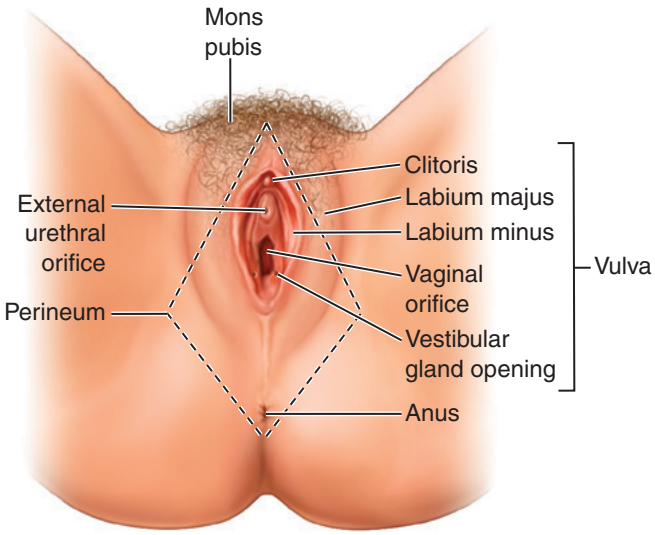

FIGURE 16-2 The external female genitalia. The vulva is shown along with nearby structures and the outlines of the perineum. The obstetrical perineum extends from the vagina to the anus.

discussed later. The breasts are composed mainly of glandular tissue and fat (FIG. 16-3). The milk secreted by the lactiferous glands is carried in ducts to the nipple.

The Menstrual Cycle

Female reproductive activity normally begins during puberty with **menarche**, the first menstrual period. Each month, the menstrual cycle is controlled, as is male reproductive activity, by hormones from the anterior pituitary gland.

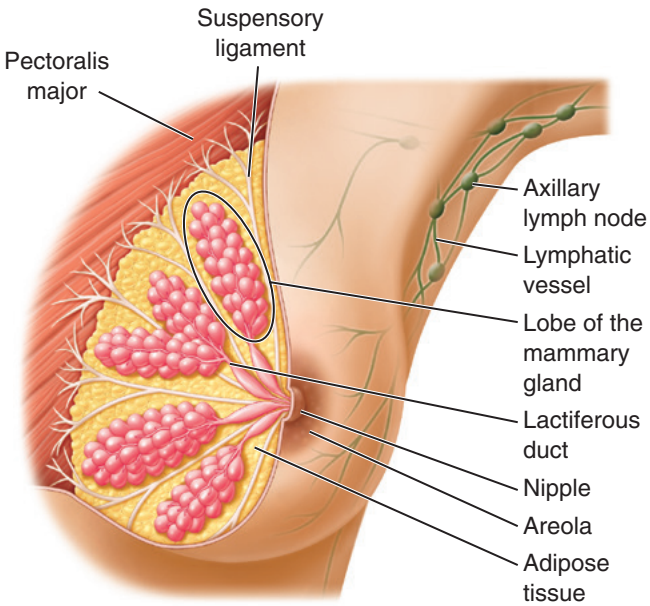

FIGURE 16-3 Section of the breast (mammary gland). The lactiferous glands are divided into lobes containing milk ducts that converge at the nipple.

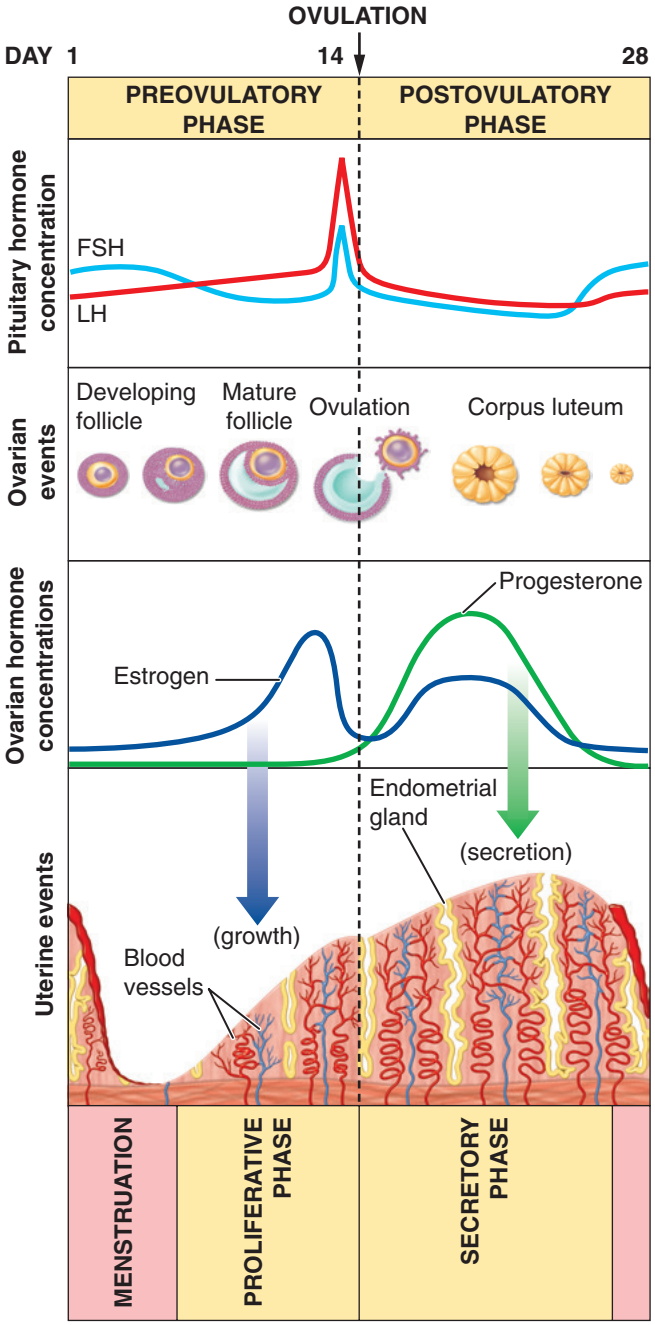

FIGURE 16-4 The menstrual cycle. Changes in pituitary and ovarian hormones, the ovary, and the uterus are shown during an average 28-day menstrual cycle with ovulation on day 14. Phases in the ovary are named for follicular development and formation of the corpus luteum. Phases in the uterus are named for changes in the endometrium.

Follicle-stimulating hormone (FSH) begins the cycle by causing the ovum to ripen in the ovarian follicle (FIG. 16-4). The follicle secretes **estrogen**, a hormone that starts endometrial development in preparation for the fertilized egg.

A second pituitary hormone, **luteinizing hormone** (LH), triggers ovulation and conversion of the follicle to the **corpus luteum.** This structure, left behind in the ovary,

extern.ir

secretes **progesterone** and estrogen, which further the endometrial growth. If no fertilization occurs, hormone levels decline, and the endometrium sloughs off in the process of **menstruation**.

The average menstrual cycle lasts 28 days, with the first day of menstruation taken as day 1 and ovulation typically occurring on about day 14. Throughout the cycle, estrogen and progesterone feed back to the pituitary to regulate the production of FSH and LH. Hormonal birth control methods act by supplying estrogen and progesterone, which inhibit FSH and LH release from the pituitary and prevent ovulation while not interfering with menstruation. The menstrual period that follows withdrawal of the hormones is anovulatory (*an-OV-u-lah-tor-e*); that is, it is not preceded by ovulation.

FIGURE 16-4 shows changes occurring simultaneously in the ovary and uterus during the course of one menstrual cycle under the effects of pituitary and ovarian hormones. The time before ovulation is described as the follicular phase in the ovary, because it encompasses development of the ovarian follicle. The uterus during this time is in the proliferative phase, marked by endometrial growth. After ovulation, the ovary is in the luteal phase with conversion of the follicle to the corpus luteum. The uterus is then in a secretory phase, as its glands are actively preparing the endometrium for possible implantation of a fertilized egg.

MENOPAUSE

Menopause is the cessation of monthly menstrual cycles. This change generally occurs between the ages of 45 and 55 years. Reproductive hormone levels decline, and ovarian ova gradually degenerate. Some women experience unpleasant symptoms, such as hot flashes, headaches, insomnia, mood swings, and urinary problems. There is also some atrophy of the reproductive tract with vaginal dryness. Most importantly, the decline in estrogen levels is associated with bone weakening (osteoporosis).

Physicians may prescribe hormone replacement therapy (HRT) to alleviate menopausal symptoms. This treatment, also called menopausal hormone therapy (MHT), usually consists of administering estrogen in combination with progestin (*pro-JES-tin*), a synthetic progesterone, given to minimize the risk of endometrial cancer. Estrogen replacement reduces bone loss associated with aging. However, concerns about HRT safety have caused reconsideration of this therapy beyond the early postmenopausal years. Studies with the most widely used form of HRT showed an increased risk of endometrial cancer and breast cancer and an increased risk of thrombosis and embolism, especially in women who smoke. All these risks increase with the duration of therapy, so HRT should be given at the lowest effective dose for the shortest possible time. Women with a history or a family history of breast cancer or circulatory problems should not take HRT. Studies are ongoing on HRT safety and the use of estrogen alone for women who have no uterus.

Aside from HRT, antidepressants and vitamin E may help to relieve menopausal symptoms; locally applied estrogen and moisturizers relieve vaginal dryness. Nonhormonal drugs that increase bone density are also available if needed. As always, exercise and a balanced diet with adequate calcium are important in maintaining health throughout life.

Contraception

Contraception is the use of artificial methods to prevent fertilization of the ovum or its implantation in the uterus. It is the most common method of birth control. Temporary contraceptive methods function to:

- Block sperm penetration of the uterus (e.g., condom, diaphragm).
- Prevent implantation of the fertilized egg (e.g., intrauterine device or IUD).
- Prevent ovulation (e.g., hormones). Hormonal methods differ in dosage and route of delivery, such as oral intake (the birth control pill), injection, skin patch, and vaginal ring.

The so-called "morning-after pill" is intended for emergency contraception. It considerably reduces the chance of pregnancy if taken within 72 hours after unprotected sexual intercourse. One such product, Plan B, consists of two progestin doses taken 12 hours apart.

Surgical sterilization provides the most effective and usually permanent contraception. In males, this procedure is a vasectomy; in females, surgical sterilization is a **tubal ligation**, in which uterine tubes are cut and tied on both sides **(FIG. 16-5)**. Laparoscopic surgery through the abdominal

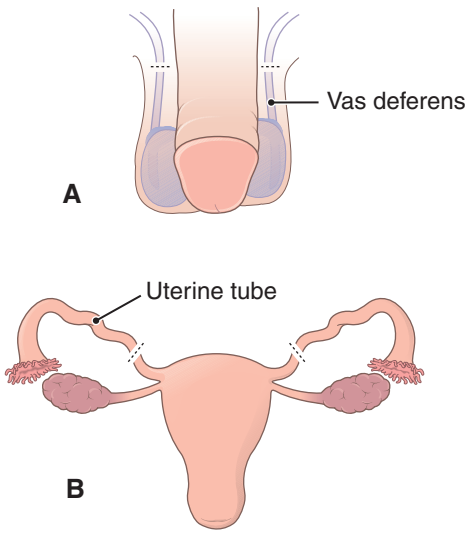

FIGURE 16-5 Sterilization. A. Vasectomy. **B.** Tubal ligation.

extern.ir

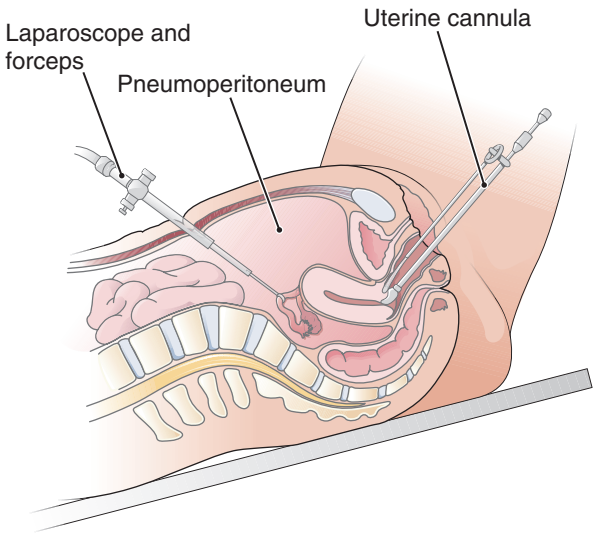

FIGURE 16-6 Laparoscopic sterilization. The peritoneal cavity is inflated (pneumoperitoneum), and the uterine tubes are cut laparoscopically through a small incision.

wall is the preferred method for performing the procedure (FIG. 16-6).

RU486 (mifepristone) is more widely used for birth control in other countries than in the United States. It terminates an early pregnancy by blocking progesterone, causing the endometrium to break down. Technically, RU486 is an abortion-causing agent (abortifacient), not a contraceptive.

BOX 16-1 describes the main contraceptive methods currently in use. Each has advantages and disadvantages over other methods, but they are listed roughly in order of decreasing effectiveness. Note that only male and female condoms protect against the spread of STIs.

FOR YOUR REFERENCE

BOX 16-1

Main Methods of Birth Control Currently in Use

Method	Description
SURGICAL	
vasectomy/tubal ligation	cutting and tying the tubes that carry the gametes
HORMONAL	
birth control pills	estrogen and progestin or progestin alone taken orally to prevent ovulation
birth control shot	injection of synthetic progesterone every 3 months to prevent ovulation
birth control patch	adhesive patch placed on body that administers estrogen and progestin through the skin; left on for 3 weeks and removed for a fourth week
birth control ring	flexible ring inserted into vagina that releases hormones internally; left in place for 3 weeks and removed for a fourth week
BARRIER	
condom	sheath that prevents sperm cells from contacting an ovum; a male condom fits over an erect penis; a female condom fits into the vagina and covers the cervix
diaphragm (with spermicide)	rubber cap that fits over cervix and prevents sperm entrance
contraceptive sponge (with spermicide)	soft, disposable foam disk containing spermicide, which is moistened with water and inserted into vagina
intrauterine device (IUD)	metal or plastic device inserted into uterus through vagina; prevents fertilization and implantation by release of copper or birth control hormones
OTHER	
spermicide	chemicals used to kill sperm; best when used in combination with a barrier method
fertility awareness	abstinence during fertile part of cycle as determined by menstrual history, basal body temperature, or quality of cervical mucus

extern.ir

Terminology *Key Terms*

The terms listed below are emphasized in this chapter. Knowing them will help you organize and prioritize your learning. These boldface terms are also found, collectively, with all chapter key terms in the Glossary.

Female Reproductive System

Normal Structure and Function

cervix *SER-viks*	Neck; usually means the lower narrow portion (neck) of the uterus (root: cervic/o); also called the cervix uteri (*U-ter-i*)
clitoris *KLIT-o-ris*	A small erectile body anterior to the urethral opening that is similar in developmental origin to the penis (roots: clitor/o, clitorid/o)
contraception *kon-trah-SEP-shun*	The prevention of pregnancy
corpus luteum *KOR-pus LU-te-um*	The small yellow structure that develops from the ovarian follicle after ovulation and secretes progesterone and estrogen
endometrium *en-do-ME-tre-um*	The inner lining of the uterus
estrogen *ES-tro-jen*	A group of hormones that produce female characteristics and prepare the uterus for the fertilized egg; the most active of these is estradiol
fallopian tube *fah-LO-pe-an*	See uterine tube
fimbriae *FIM-bre-e*	The long finger-like extensions of the uterine tube that wave to capture the released ovum (see **FIG. 16-1**) (singular: fimbria)
follicle-stimulating hormone (FSH)	A hormone secreted by the anterior pituitary that acts on the gonads; in males, FSH stimulates Sertoli cells and promotes sperm development; in females, it stimulates ripening of ova in the ovary
fornix *FOR-niks*	An arch-like space, such as the space between the uppermost wall of the vagina and the cervix (see **FIG. 16-1**); from Latin meaning "arch"
greater vestibular gland *ves-TIB-u-lar*	A small gland that secretes mucus through a duct that opens near the vaginal orifice; also called Bartholin (*BAR-to-lin*) gland (see **FIG. 16-2**)
labia majora *LA-be-ah mah-JOR-ah*	The two large folds of skin that form the sides of the vulva (root labi/o means "lip") (singular: labium majus)
labia minora *LA-be-ah mi-NOR-ah*	The two small folds of skin within the labia majora (singular: labium minus)
luteinizing hormone (LH) *LU-te-in-i-zing*	A hormone secreted by the anterior pituitary that acts on the gonads; in males, it stimulates the interstitial cells to produce testosterone; in females, it stimulates ovulation and corpus luteum formation
mammary gland *MAM-ah-re*	A specialized gland capable of secreting milk in the female (roots: mamm/o, mast/o); the breast
menarche *men-AR-ke*	The first menstrual period, which normally occurs during puberty
menopause *MEN-o-pawz*	Cessation of menstrual cycles in the female
menstruation *men-stru-A-shun*	The cyclic discharge of blood and mucosal tissues from the lining of the nonpregnant uterus (roots: men/o, mens); menstrual period, menses (*MEN-seze*)
myometrium *mi-o-ME-tre-um*	The muscular wall of the uterus
ovarian follicle *o-VAR-e-an FOL-ih-kl*	The cluster of cells in which the ovum ripens in the ovary

(continued)

extern.ir

Terminology Key Terms (Continued)

ovary *O-vah-re*	A female gonad (roots: ovari/o, oophor/o)
ovulation *ov-u-LA-shun*	The release of a mature ovum from the ovary (from *ovule*, meaning "little egg")
ovum *O-vum*	The female gamete or reproductive cell (roots: oo, ov/o) (plural: ova)
perineum *per-ih-NE-um*	The region between the thighs from the external genitalia to the anus (root: perine/o)
progesterone *pro-JES-ter-one*	A hormone produced by the corpus luteum and the placenta that maintains the endometrium for pregnancy
rectouterine pouch *rek-to-U-ter-in*	A blind pouch, such as the recess between the rectum and the uterus; the cul-de-sac or pouch of Douglas (see **FIG. 16-1**)
tubal ligation *TU-bal li-GA-shun*	Surgical constriction of the uterine tubes to produce sterilization (see **FIGS. 16-5** and **16-6**)
uterine tube *U-ter-in*	A tube extending from the upper lateral portion of the uterus that carries the ovum to the uterus (root: salping/o); also called fallopian (*fah-LO-pe-an*) tube
uterus *U-ter-us*	The organ that receives the fertilized egg and maintains the developing offspring during pregnancy (roots: uter/o, metr, hyster/o) (**BOX 16-2**)
vagina *vah-JI-nah*	The muscular tube between the cervix and the vulva (roots: vagin/o, colp/o)
vulva *VUL-va*	The external female genital organs (roots: vulv/o, episi/o)

FOCUS ON WORDS
Crazy Ideas

BOX 16-2

Most women would be surprised to learn the origin of the root hyster/o, used for the uterus. It comes from the same root as the words hysterical and hysterics and was based on the very old belief that the womb was the source of mental disturbances in women.

A similar history lies at the origin of the word hypochondriac, a term for someone who has imaginary illnesses. The hypochondriac regions are in the upper portions of the abdomen, an area that the ancients believed was the seat of mental disorders.

Roots Pertaining to the Female Reproductive System

See **TABLES 16-1** to **16-3**.

Table 16-1 Roots for Female Reproduction and the Ovaries

Root	Meaning	Example	Definition of Example
gyn/o, gynec/o[a]	woman	gynecology *gi-neh-KOL-o-je*	study of women's diseases
men/o, mens	month, menstruation	premenstrual *pre-MEN-stru-al*	before a menstrual period

extern.ir

Table 16-1 Roots for Female Reproduction and the Ovaries *(Continued)*

Root	Meaning	Example	Definition of Example
oo	ovum, egg cell	oocyte *O-o-site*	cell that gives rise to an ovum
ov/o, ovul/o	ovum, egg cell	anovulatory *an-OV-u-lah-tore-e*	absence of egg ripening or of ovulation
ovari/o	ovary	ovariopexy *o-var-e-o-PEK-se*	surgical fixation of an ovary
oophor/o	ovary	oophorectomy *o-of-o-REK-to-me*	excision of an ovary

[a]Although the correct pronunciation of this root is *jine* (with a soft *g* and long *i*), it is commonly pronounced with a hard *g* as in *gine* and may also have a short *i*, as in *jin* or *gin*.

Exercise 16-1

Complete the exercise. To check your answers go to Appendix 11.

Define the following words.

1. gynecopathy (*gi-neh-KOP-ah-the*) _____
2. intermenstrual (*in-ter-MEN-stru-al*) _____
3. oogenesis (*o-o-JEN-eh-sis*) _____
4. ovulation (*ov-u-LA-shun*) _____
5. ovarian (*o-VAR-e-an*) _____
6. oophoritis (*o-of-o-RI-tis*) _____

Write a word for the following definitions.

7. rupture (-rhexis) of an ovary _____
8. pertaining to ovulation _____
9. profuse bleeding (-hagia) at the time of menstruation _____

The word menorrhea means "menstruation." Add a prefix to menorrhea to form words for the following definitions.

10. scanty menstrual flow _____
11. absence of menstruation _____
12. painful or difficult menstruation _____

Use the root *ovari/o* to write words for the following.

13. incision into an ovary _____
14. surgical puncture of an ovary _____
15. hernia of an ovary _____

Use the root *oophor/o* to write words for the following.

16. surgical repair of an ovary _____
17. malignant tumor of the ovary _____

extern.ir

Table 16-2 Roots for the Uterine Tubes, Uterus, and Vagina

Root	Meaning	Example	Definition of Example
salping/o	uterine tube, tube	salpingoplasty *sal-PING-o-plas-te*	plastic repair of a uterine tube
uter/o	uterus	intrauterine *in-trah-U-ter-in*	within the uterus
metr/o, metr/i	uterus	metrorrhea *me-tro-RE-ah*	abnormal uterine discharge
hyster/o	uterus	hysterotomy *his-ter-OT-o-me*	incision of the uterus
cervic/o	cervix, neck	endocervical *en-do-SER-vih-kal*	pertaining to the lining of the cervix
vagin/o	vagina	vaginometer *vaj-ih-NOM-eh-ter*	instrument for measuring the vagina
colp/o	vagina	colpostenosis *kol-po-sten-O-sis*	narrowing of the vagina

Exercise 16-2

Complete the exercise. To check your answers go to Appendix 11.

Define the following terms.

1. hysterography (*his-ter-OG-rah-fe*) _____
2. metromalacia (*me-tro-mah-LA-she-ah*) _____
3. vaginoplasty (*vaj-ih-no-PLAS-te*) _____
4. colpodynia (*kol-po-DIN-e-ah*) _____
5. salpingectomy (*sal-pin-JEK-to-me*) _____
6. uterovesical (*u-ter-o-VES-ih-kal*) _____
7. intracervical (*in-trah-SER-vih-kal*) _____

Write words for the following.

8. surgical fixation of a uterine tube _____
9. radiographic study of the uterine tube _____

The root *salping/o* is taken from the word salpinx, which means "tube." Add a prefix to salpinx to write a word for the following.

10. collection of fluid in a uterine tube _____
11. presence of pus in a uterine tube _____

Note how the roots *salping/o* and *oophor/o* are combined to form salpingo-oophoritis (inflammation of a uterine tube and ovary). Write a word for the following.

12. surgical removal of a uterine tube and ovary _____

Use the roots indicated to write words for the following.

13. surgical fixation of the uterus (hyster/o) _____
14. pertaining to the uterus (uter/o) _____
15. narrowing of the uterus (metr/o) _____

extern.ir

Exercise 16-2 *(Continued)*

16. radiograph of the uterus (hyster/o) and uterine tubes _____
17. through the cervix _____
18. prolapse of the uterus (metr/o) _____
19. hernia of the vagina (colp/o) _____
20. inflammation of the vagina (vagin/o) _____

Table 16-3 Roots for the Female Accessory Structures

Root	Meaning	Example	Definition of Example
vulv/o	vulva	vulvar *VUL-var*	pertaining to the vulva
episi/o	vulva	episiotomy *eh-piz-e-OT-o-me*	incision of the vulva
perine/o	perineum	perineal *per-ih-NE-al*	pertaining to the perineum
clitor/o, clitorid/o	clitoris	clitorectomy *klih-to-REK-to-me*	excision of the clitoris
mamm/o	breast, mammary gland	mammoplasty *mam-o-PLAS-te*	plastic surgery of the breast
mast/o	breast, mammary gland	amastia *ah-MAS-te-ah*	absence of the breasts

Exercise 16-3

Complete the exercise. To check your answers go to Appendix 11.

Write a word for the following.

1. excision of the vulva (vulv/o) _____
2. suture of the vulva (episi/o) _____
3. pertaining to the vagina (vagin/o) and perineum _____
4. enlargement of the clitoris _____
5. radiographic record of the breast (mamm/o) _____
6. inflammation of the breast (mast/o) _____
7. excision of the breast _____

Clinical Aspects of Female Reproduction

INFECTION

The major organisms that cause sexually transmitted infections in both men and women are given in **BOX 16-2**.

Genital herpes is a presently incurable viral infection that affects over 25% of adults in the United States. Once infection occurs, the virus lives in the nervous system, causing intermittent outbreaks that may include genital sores, itching, burning, and urinary problems. The virus is easily spread to sexual partners even if there are no active signs of the disease. Pregnant women can pass the virus to their babies during delivery, resulting in possible disabilities and even death. Some basic hygiene measures and condom use can reduce viral spread.

A fungus that infects the vulva and vagina is *Candida albicans*, causing **candidiasis.** The resultant **vaginitis**, inflammation of the vagina, causes itching and release of a thick, white, cheesy discharge. Pregnancy, diabetes mellitus, and use of antibiotics, steroids, or birth control pills predispose

extern.ir

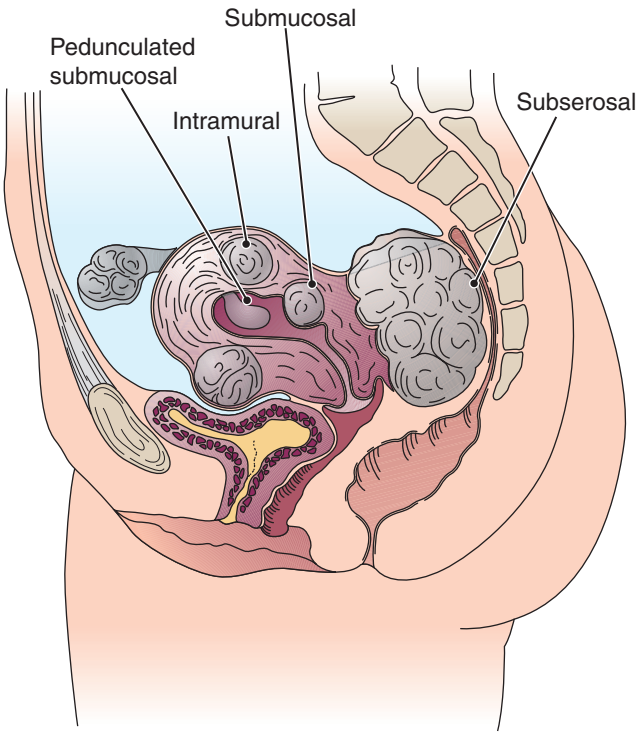

FIGURE 16-7 Uterine leiomyomas (fibroids). Various possible locations are shown. They may be within the uterine wall (intramural), below the mucous membrane (submucosal), on a stalk (pedunculated), or below the outer serous membrane (subserosal). One tumor is shown compressing the urinary bladder and another the rectum.

to this infection. Antifungal agents (mycostatics) are used in treatment.

Pelvic inflammatory disease (PID) is the spread of infection from the reproductive organs into the pelvic cavity. It is most often caused by the gonorrhea organism or by *Chlamydia*, although bacteria normally living in the reproductive tract may also be responsible when conditions allow. PID is a serious disorder that may result in septicemia or shock. Inflammation of the uterine tubes, called **salpingitis**, may close off these tubes and cause infertility.

FIBROIDS

A **fibroid** is a benign smooth muscle tumor usually occurring in the uterine wall, the myometrium (FIG. 16-7). This type of growth, technically called a **leiomyoma**, is one of the most common uterine disorders, but it usually causes no symptoms and requires no treatment. However, fibroids may cause heavy menstrual bleeding (menorrhagia) and rectal or bladder pressure. Treatments include:

- Suppression of hormones that stimulate fibroid growth.
- Surgical removal of the fibroids (myomectomy).
- Surgical removal of the uterus, or **hysterectomy.**
- Uterine fibroid embolization (UFE), a method that has reduced the need for hysterectomies. A specially trained radiologist uses a catheter to inject small synthetic particles into a uterine artery. These particles then block blood supply to the fibroid, causing it to shrink.

ENDOMETRIOSIS

Growth of endometrial tissue outside the uterus is termed **endometriosis.** Commonly, the ovaries, uterine tubes, peritoneum, and other pelvic organs are involved (FIG. 16-8). Stimulated by normal hormones, the endometrial tissue causes inflammation, fibrosis, and adhesions in surrounding areas. The results may be pain, menstrual disorders, and infertility. Laparoscopy is used to diagnose endometriosis and also to remove the abnormal tissue.

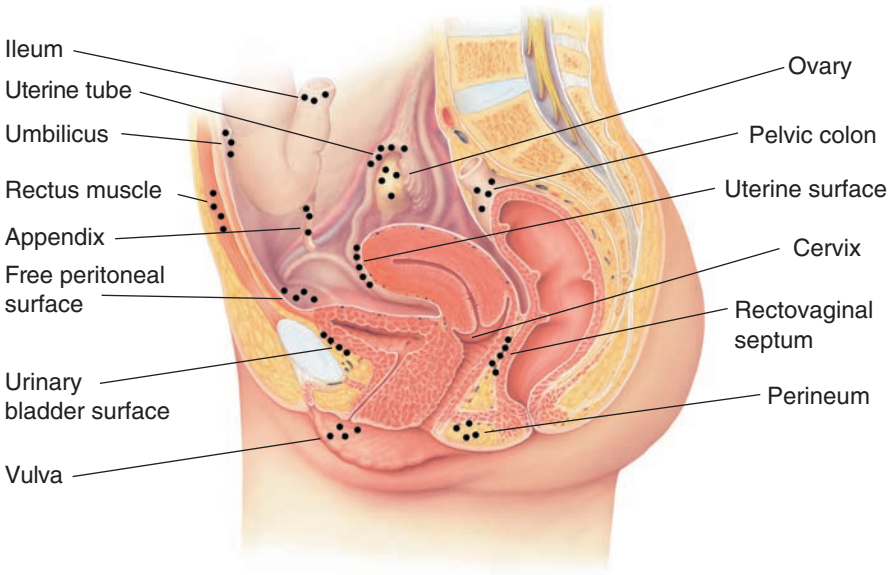

FIGURE 16-8 Endometriosis. Endometrial tissue can grow outside the uterus almost anywhere in the peritoneal cavity, causing inflammation and other complications.

extern.ir

DYSFUNCTIONAL UTERINE BLEEDING

Menstrual bleeding abnormalities include flow that is too scanty (oligomenorrhea) or too heavy (menorrhagia) and the absence of monthly periods (amenorrhea). **Dysmenorrhea**, painful or difficult menstruation, when it occurs, usually begins at the start of menstruation and lasts 1 to 2 days. **Metrorrhagia**, or intermenstrual bleeding, refers to uterine bleeding between normal menstrual periods, which may indicate a tumor. Together, these disorders are classified as dysfunctional uterine bleeding (DUB). These responses may be caused by hormone imbalances, systemic disorders, or uterine problems. They are most common in adolescence or near menopause. At other times, they are often related to life changes and emotional upset.

PREMENSTRUAL SYNDROME

Premenstrual syndrome (PMS) describes symptoms that appear during the menstrual cycle's second half and includes emotional changes, fatigue, bloating, headaches, and appetite changes. Possible causes of PMS have been under study. Symptoms may be relieved by hormone therapy, antidepressants, or antianxiety medications. Exercise, dietary control, rest, and relaxation strategies may also be helpful. Avoiding caffeine and taking vitamin E supplements may relieve breast tenderness; one should also drink adequate water and limit salt intake.

POLYCYSTIC OVARIAN SYNDROME

Polycystic ovarian syndrome (PCOS) is discussed here because the first-described symptoms of this disorder were enlarged ovaries with multiple cysts. These signs are not always present in PCOS, although the ovaries do show abnormalities. PCOS is an endocrine disorder involving increased androgen and estrogen secretion that interferes with normal secretion of pituitary FSH and LH. Some effects include:

- Anovulation and infertility
- Scant or absent menses (oligomenorrhea or amenorrhea)
- Excessive hair growth (hirsutism), caused by excess androgen (male hormone)
- Resistance to insulin, a hormone that lowers blood sugar, resulting in symptoms of diabetes mellitus
- Obesity

PCOS is treated with hormones to regulate hormonal imbalance, drugs to increase responsiveness to insulin, weight reduction (estrogen is produced in adipose tissue), and sometimes partial removal of the ovaries.

CANCER OF THE FEMALE REPRODUCTIVE TRACT

Endometrial Cancer

Cancer of the endometrium is the most common cancer of the female reproductive tract. Women at risk should have biopsies taken regularly because endometrial cancer is not always detected by **Pap** (Papanicolaou) **smear**, a simple histologic test. Treatment consists of hysterectomy (removal of the uterus) and sometimes radiation therapy. A small percentage of cases occur after endometrial overgrowth (hyperplasia). This tissue can be removed by **dilation and curettage (D&C)**, in which the cervix is widened and the lining of the uterus is scraped with a curette.

Cervical Cancer

Almost all patients with cervical cancer have been infected with human papillomavirus (HPV), a virus that causes genital warts. Incidence is also related to high sexual activity and other sexually transmitted viral infections, such as herpes. A vaccine against the most prevalent HPV strains is available and is recommended for females at 11 to 12 years of age.

In the 1940s and 1950s, the synthetic steroid DES (diethylstilbestrol) was given to prevent miscarriages. A small percentage of daughters born to women treated with this drug have shown an increased risk for cancer of the cervix and vagina. These women need to be examined regularly.

Cervical carcinoma is often preceded by abnormal growth (dysplasia) of the epithelial cells lining the cervix. Growth is graded as CIN I, II, or III, depending on the depth of tissue involved. CIN stands for cervical intraepithelial neoplasia. Diagnosis of cervical cancer is by a Pap smear, examination with a **colposcope**, and biopsy. In a **cone biopsy**, a cone-shaped piece of tissue is removed from the lining of the cervix for study. Often in the procedure, all of the abnormal cells are removed as well. A newer procedure that can supplement or replace the Pap smear involves testing a cervical cell sample for the DNA of cancer-causing HPV strains.

Ovarian Cancer

Cancer of the ovary has a high mortality rate because it usually causes no distinct early symptoms and there is no accurate routine screening test yet available. Women may overlook the vague possible signs of ovarian cancer, such as bloating, change in bowel habits, backache, urinary changes, abnormal bleeding, weight loss, and fatigue. Often by the time of diagnosis, the tumor has invaded the pelvis and abdomen. Removal of the ovaries, an **oophorectomy**, and uterine tubes, a **salpingectomy**, along with the uterus is required, in addition to chemotherapy and radiation therapy.

BREAST CANCER

Carcinoma of the breast is second only to lung cancer in causing cancer-related deaths among women in the United States. This cancer metastasizes readily through the lymph nodes and blood to other sites such as the lung, liver, bones, and ovaries.

Diagnosis

Palpation is a simple first step in breast cancer diagnosis. Regular breast self-examination (BSE) is of utmost importance, because many breast cancers are discovered by women themselves.

Mammography, which provides two-dimensional x-ray images of the breast, is still the standard diagnostic procedure for breast cancer **(FIG. 16-9)**. Some health organizations recommend annual mammograms after the age of 40 years.

extern.ir

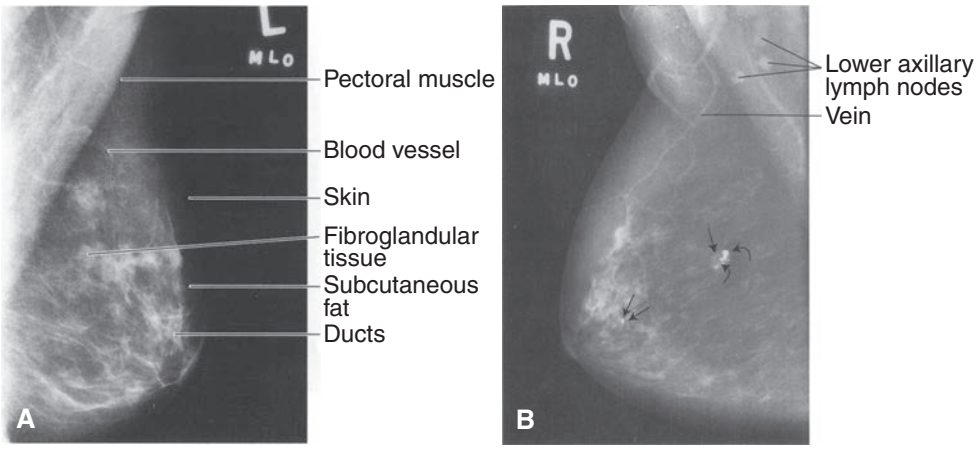

FIGURE 16-9 Mammograms. A. Normal mammogram, left breast. **B.** Mammogram of right breast showing lesions (*arrows*). In mammograms, fat tissue appears gray; breast tissue, calcium deposits, and benign or cancerous tumors appear white.

Other health professionals recommend waiting until age 50 unless a woman is in a high-risk group, such as having a family history of breast cancer. In digital mammography, x-ray images are stored on computers instead of on film. These images can be manipulated electronically to aid interpretation. They are more easily stored and retrieved or sent to other medical facilities.

While mammography remains the most commonly recommended choice in breast cancer screening, medical researchers are currently testing new technologies. These are aimed at addressing one of the major weaknesses of mammography, which is the detection of cancer in women with radiographically dense breasts. Current procedures in these women result in many false positives and frequent recalls for additional imaging. Improvements in screening have been recognized with the three-dimensional technique called digital **tomosynthesis.** This procedure is approved by the U.S. Food and Drug Administration to be used in conjunction with mammography but is not yet considered the standard of care for breast cancer screening.

Ultrasound and MRI studies are adjuncts to mammography. Ultrasound can show whether a lump seen on mammography is simply a benign cyst. MRI with a contrast medium can show abnormal blood vessel formation signifying a tumor.

Any suspicious breast tissue must be biopsied by needle aspiration or surgical excision for further study. In a **stereotactic biopsy**, a physician uses a computer-guided imaging system to locate suspicious tissue and remove samples with a needle. This method is less invasive than surgical biopsy.

Ductal carcinoma in situ (DCIS) is an abnormality of breast tissue that arises from an overgrowth of the cells lining a milk duct. It is initially confined to the duct, that is, it does not invade nearby tissue or metastasize, and it can usually be detected by mammography in its early stages. DCIS may unpredictably become metastatic, and treatment depends on tumor pathology as well as a patient's age and family history.

Treatment

Treatment of breast cancer is usually some form of **mastectomy**, or removal of breast tissue:

- In a radical mastectomy, the entire breast is removed. Underlying muscle and axillary lymph nodes (in the armpit) are also removed.
- In a modified radical mastectomy, the breast and lymph nodes are removed, but muscles are left in place.
- In a segmental mastectomy, or "lumpectomy," just the tumor itself is removed. When the tumor is small and surgery is followed by additional treatment, this procedure gives survival rates as high as those with more radical surgeries.

Surgeons can assess the extent of tumor spread and conserve lymphatic tissue using a **sentinel node biopsy.** A dye or radioactive tracer identifies the first lymph nodes that receive lymph from a tumor. Study of possible tumor spread to these "sentinel nodes" guides further treatment.

Often after breast surgery, a patient receives chemotherapy and/or radiation therapy. It is now possible in some cases to deliver radiation to just the tumor area (brachytherapy) instead of irradiating the whole breast. A radiation source is delivered through catheters or implanted in the breast tissue for a short time.

Progress in breast cancer treatment involves genetic studies and tumor analysis that allows therapy more specific to each particular case. About 8% of these cancers are linked to a defective gene (*BRCA1* or *BRCA2*) that is transmitted within families. Women with these genetic predispositions can be screened more carefully or treated prophylactically.

Some types of specific drug treatments for breast cancer, which may be given in combination, are:

- Drugs that block estrogen production or block estrogen receptors in breast tissue if a tumor responds to this hormone
- Drugs that inhibit tumor growth factors
- Drugs that inhibit growth of blood vessels that supply the tumor (antiangiogenesis agents)

These and other anticancer drugs are described in more detail in the list of enrichment terms.

extern.ir

Terminology *Key Terms*

The terms listed below are emphasized in this chapter. Knowing them will help you organize and prioritize your learning. These boldface terms are also found, collectively, with all chapter key terms in the Glossary.

Female Reproductive System

Disorders	
candidiasis *kan-dih-DI-ah-sis*	Infection with the fungus *Candida*, a common cause of vaginitis
dysmenorrhea *DIS-men-o-re-ah*	Painful or difficult menstruation; a common disorder that may be caused by infection, use of an intrauterine device, endometriosis, overproduction of prostaglandins, or other factors
endometriosis *en-do-me-tre-O-sis*	Growth of endometrial tissue outside the uterus, usually in the pelvic cavity (see **FIG. 16-8**)
fibroid *FI-broyd*	Benign tumor of smooth muscle (see leiomyoma)
leiomyoma *li-o-mi-O-mah*	Benign tumor of smooth muscle, usually in the uterine wall (myometrium); in the uterus, may cause bleeding and pressure on the bladder or rectum; also called fibroid or myoma (see **FIG. 16-7**)
metrorrhagia *me-tro-RA-je-ah*	Uterine bleeding between normal menstrual periods
pelvic inflammatory disease (PID)	Condition caused by the spread of infection from the reproductive tract into the pelvic cavity; commonly caused by sexually transmitted gonorrhea and *Chlamydia* infections
salpingitis *sal-pin-JI-tis*	Inflammation of a uterine tube, typically caused by urinary tract infection or sexually transmitted infection; chronic salpingitis may lead to infertility or ectopic pregnancy (development of the fertilized egg outside of the uterus)
vaginitis *vaj-ih-NI-tis*	Inflammation of the vagina
Diagnosis and Treatment	
colposcope *KOL-po-skope*	Instrument for examining the vagina and cervix
cone biopsy	Removal of a cone of tissue from the cervical lining for cytologic examination; also called conization
dilation and curettage (D&C) *ku-reh-TAJ*	Procedure in which the cervix is dilated (widened) and the uterine lining is scraped with a curette
hysterectomy *his-ter-EK-to-me*	Surgical removal of the uterus; most commonly done because of tumors; often the uterine tubes and ovaries are removed as well
mammography *mam-OG-rah-fe*	Radiographic study of the breast for the detection of breast cancer; the image obtained is a mammogram (see **FIG. 16-9**)
mastectomy *mas-TEK-to-me*	Excision of breast tissue to eliminate malignancy
oophorectomy *o-of-o-REK-to-me*	Excision of an ovary
Pap smear	Study of cells collected from the cervix and vagina for early detection of cancer; also called Papanicolaou smear or Pap test
salpingectomy *sal-pin-JEK-to-e*	Surgical removal of the uterine tube
sentinel node biopsy *SEN-tih-nel*	Biopsy of the first lymph nodes to receive drainage from a tumor; used to determine spread of cancer in planning treatment
stereotactic biopsy *ster-e-o-TAK-tik BI-op-se*	Needle biopsy using a computer-guided imaging system to locate suspicious tissue and remove samples for study
tomosynthesis *toh-mo-SIN-theh-sis*	Three-dimensional x-ray imaging technique for detection of breast cancer; digital tomosynthesis

extern.ir

Terminology *Enrichment Terms*

The terms listed below expand on the key terms to increase your knowledge of this chapter topic.

Female Reproductive System

Normal Structure and Function	
adnexa *ad-NEK-sah*	Appendages, such as the adnexa uteri—the ovaries, uterine tubes, and uterine ligaments
areola *ah-RE-o-lah*	A pigmented ring, such as the dark area around the nipple of the breast
Graafian follicle *GRAF-e-an*	A mature ovarian follicle
hymen *HI-men*	A fold of mucous membrane that partially covers the entrance of the vagina
mons pubis *monz PU-bis*	The rounded, fleshy elevation anterior to the pubic joint that is covered with hair after puberty (see **FIG. 16-2**)
oocyte *O-o-site*	An immature ovum
perimenopause *per-ih-MEN-o-pawz*	The period immediately before menopause; begins at the time of irregular menstrual cycles and ends 1 year after the last menstrual period; averages 3 to 4 years
vestibule *VES-tih-bule*	The space between the labia minora that contains the openings of the urethra, vagina, and ducts of the greater vestibular glands
Disorders	
cystocele *SIS-to-sele*	Herniation of the urinary bladder into the wall of the vagina **(FIG. 16-10)**
dyspareunia *dis-par-U-ne-ah*	Pain during sexual intercourse
fibrocystic disease of the breast *fi-bro-SIS-tik*	A condition in which there are palpable lumps in the breasts, usually associated with pain and tenderness; these lumps or "thickenings" change with the menstrual cycle and must be distinguished from malignant tumors by diagnostic methods
hirsutism *HIR-su-tizm*	Excess hair growth
leukorrhea *lu-ko-RE-ah*	White or yellowish discharge from the vagina; infection and other disorders may change the amount, color, or odor of the discharge
microcalcification *mi-kro-kal-sih-fih-KA-shun*	Small deposit of calcium that appears as a white spot on mammograms; most microcalcifications are harmless, but some might indicate breast cancer
prolapse of the uterus	Downward displacement of the uterus with the cervix sometimes protruding from the vagina
rectocele *REK-to-sele*	Herniation of the rectum into the wall of the vagina; also called proctocele (see **FIG. 16-10**)
Diagnosis and Treatment	
culdocentesis *kul-do-sen-TE-sis*	Puncture of the vaginal wall to sample fluid from the rectouterine space for diagnosis
episiorrhaphy *eh-pis-e-OR-ah-fe*	Suture of the vulva or suture of the perineum cut in an episiotomy (incision to ease childbirth)
laparoscopy *lap-ah-ROS-ko-pe*	Endoscopic examination of the abdomen; may include surgical procedures, such as tubal ligation (see **FIG. 16-6**)

extern.ir

Terminology *Enrichment Terms (Continued)*

myomectomy *mi-o-MEK-to-me*	Surgical removal of a uterine leiomyoma (fibroid, myoma)
speculum *SPEK-u-lum*	An instrument used to enlarge the opening of a passage or cavity to allow examination (see **FIG. 3-18**)
teletherapy *tel-eh-THER-ah-pe*	Delivery of radiation to a tumor from an external beam source, as compared to implantation of radioactive material (brachytherapy) or systemic administration of radionuclide
Drugs	
aromatase inhibitor (AI) *ah-RO-mah-tase*	Agent that inhibits estrogen production; used for postmenopausal treatment of breast cancers that respond to estrogen; examples are exemestane (Aromasin), anastrozole (Arimidex), and letrozole (Femara)
bisphosphonate *bis-FOS-fo-nate*	Agent used to prevent and treat osteoporosis; increases bone mass by decreasing bone turnover; examples are alendronate (Fosamax) and risedronate (Actonel)
HER2 inhibitor	Drug used to treat breast cancers that show excess receptors (HER2) for human epidermal growth factor; example is trastuzumab (Herceptin)
paclitaxel *pak-lih-TAKS-el*	Antineoplastic agent derived from yew trees used mainly in treatment of breast and ovarian cancer; Taxol
selective estrogen receptor modulator (SERM)	Drug that acts on estrogen receptors; examples are tamoxifen (Nolvadex) and raloxifene (Evista), which is also used to prevent bone loss after menopause

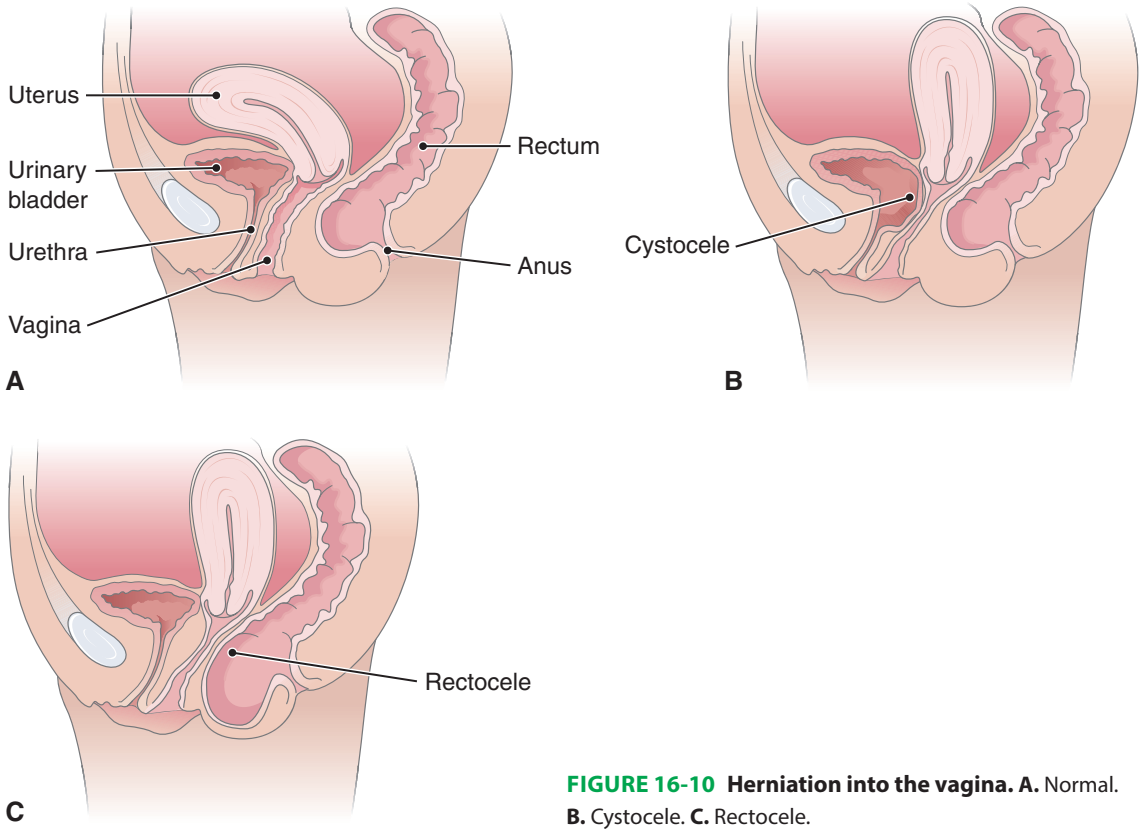

FIGURE 16-10 Herniation into the vagina. A. Normal. **B.** Cystocele. **C.** Rectocele.

extern.ir

Terminology *Abbreviations*

The abbreviations listed below are emphasized in this chapter. These are also found, collectively, with all chapter abbreviations in Appendix 2.

AI	Aromatase inhibitor	**HRT**	Hormone replacement therapy
BRCA1	Breast cancer gene 1	**IUD**	Intrauterine device
BRCA2	Breast cancer gene 2	**LH**	Luteinizing hormone
BSE	Breast self-examination	**MHT**	Menopausal hormone therapy
BSO	Bilateral salpingo-oophorectomy	**NGU**	Nongonococcal urethritis
BV	Bacterial vaginosis	**PCOS**	Polycystic ovarian syndrome
CIN	Cervical intraepithelial neoplasia	**PID**	Pelvic inflammatory disease
D&C	Dilation and curettage	**PMS**	Premenstrual syndrome
DCIS	Ductal carcinoma in situ	**SERM**	Selective estrogen receptor modulator
DES	Diethylstilbestrol	**STD**	Sexually transmitted disease
DUB	Dysfunctional uterine bleeding	**STI**	Sexually transmitted infection
FSH	Follicle-stimulating hormone	**TAH**	Total abdominal hysterectomy
GC	Gonococcus (cause of gonorrhea)	**TSS**	Toxic shock syndrome
GYN	Gynecology; Gynecologist	**UFE**	Uterine fibroid embolization
HPV	Human papillomavirus	**VD**	Venereal disease (sexually transmitted disease)

Pregnancy and Birth

FERTILIZATION AND EARLY DEVELOPMENT

Penetration of an ovulated egg cell by a spermatozoon results in **fertilization** (FIG. 16-11). This union normally occurs in the uterine tube. The nuclei of the sperm and ovum fuse, restoring the chromosome number to 46 and forming a **zygote.** As the zygote travels through the uterine tube toward the uterus, it divides rapidly. Within 6 to 7 days, the fertilized egg reaches the uterus and implants into the endometrium, and the **embryo** begins to develop.

During the first 8 weeks of growth, all of the major body systems are established. Embryonic tissue produces **human chorionic gonadotropin** (**hCG**), a hormone that keeps the corpus luteum functional in the ovary to maintain the endometrium. (The presence of hCG in urine is the basis for the most commonly used tests for pregnancy.) After 2 months, placental hormones take over this function, and the corpus luteum degenerates. At this time, the embryo becomes a **fetus** (FIG. 16-12).

THE PLACENTA

During development, the fetus is nourished by the **placenta**, an organ formed from the embryo's outermost layer, the **chorion**, and the endometrium, the innermost layer of the uterus (FIG. 16-13). Here, exchanges take place between the bloodstreams of the mother and the fetus through fetal capillaries.

The **umbilical cord** contains the blood vessels that link the fetus to the placenta. Fetal blood is carried to the placenta in two umbilical arteries. While traveling through the placenta, the blood picks up nutrients and oxygen and gives up carbon dioxide and metabolic waste. Replenished blood is carried from the placenta to the fetus in a single umbilical vein.

Although the bloodstreams of the mother and the fetus do not mix and all exchanges take place through capillaries, some materials do manage to get through the placenta in both directions. For example, some viruses, such as HIV and rubella (German measles), as well as drugs, alcohol, and other harmful substances are known to pass from the mother to the fetus; fetal proteins can enter the mother's blood and cause immunologic reactions.

The placenta also produces hormones that promote fetal growth. One of these, chemically similar to pituitary growth hormone, is named placental growth hormone.

extern.ir

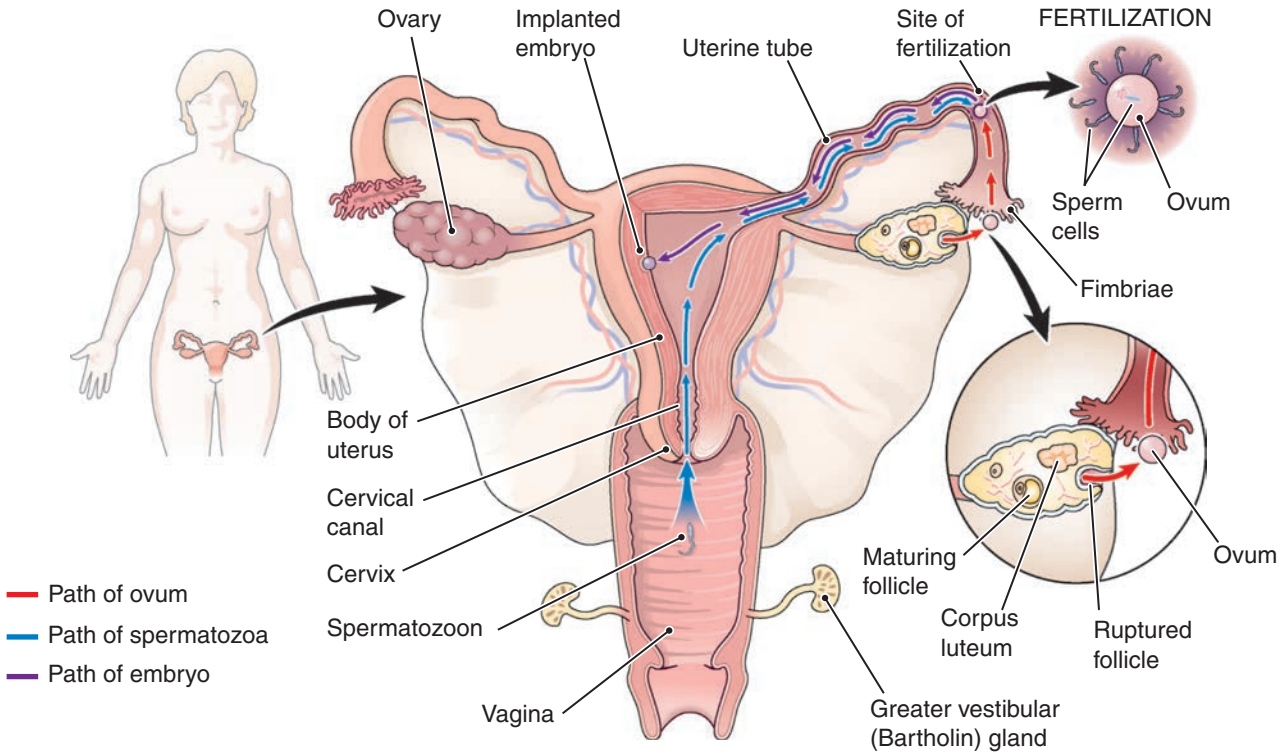

FIGURE 16-11 Ovulation and fertilization. *Arrows* show the pathway of spermatozoa and ovum. Fertilization occurs in the uterine tube, after which the zygote implants in the uterine lining.

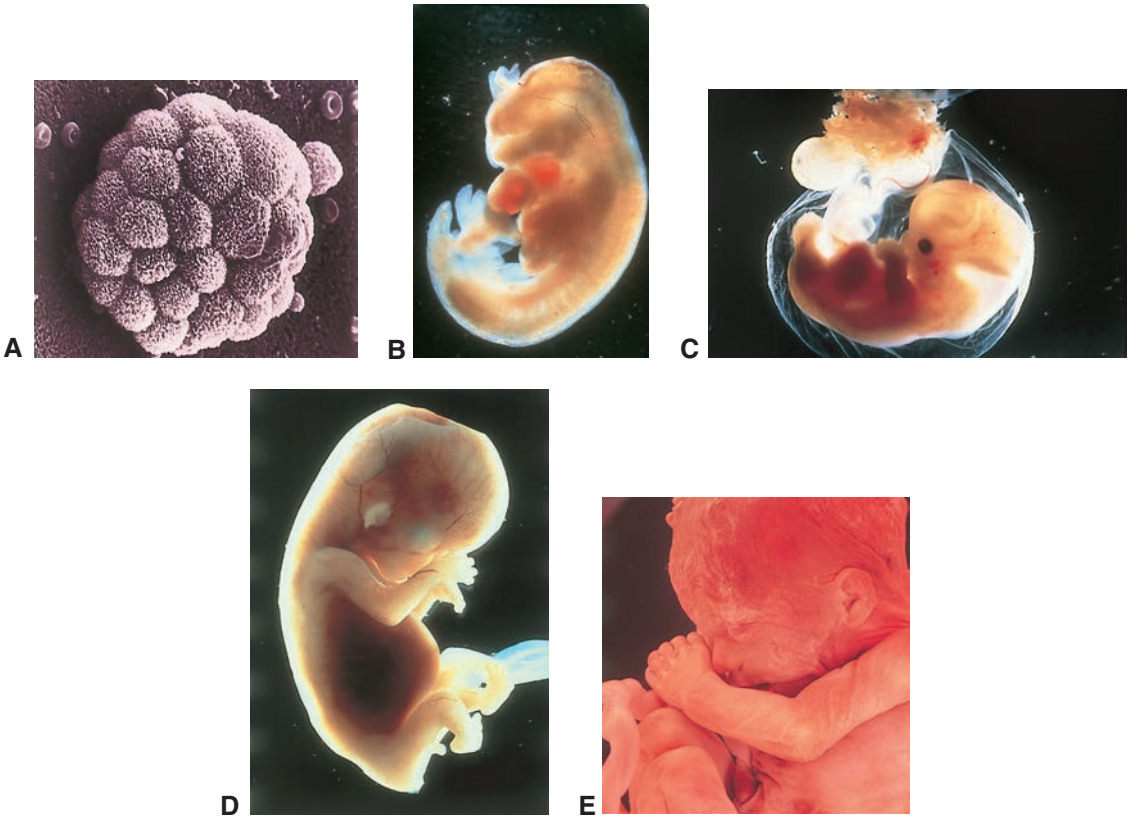

FIGURE 16-12 Human development. Human embryos and an early fetus are shown. **A.** Implantation in the uterus 7 to 8 days after conception. **B.** Embryo at 32 days. **C.** At 37 days. **D.** At 41 days. **E.** Fetus at 12 to 15 weeks.

extern.ir

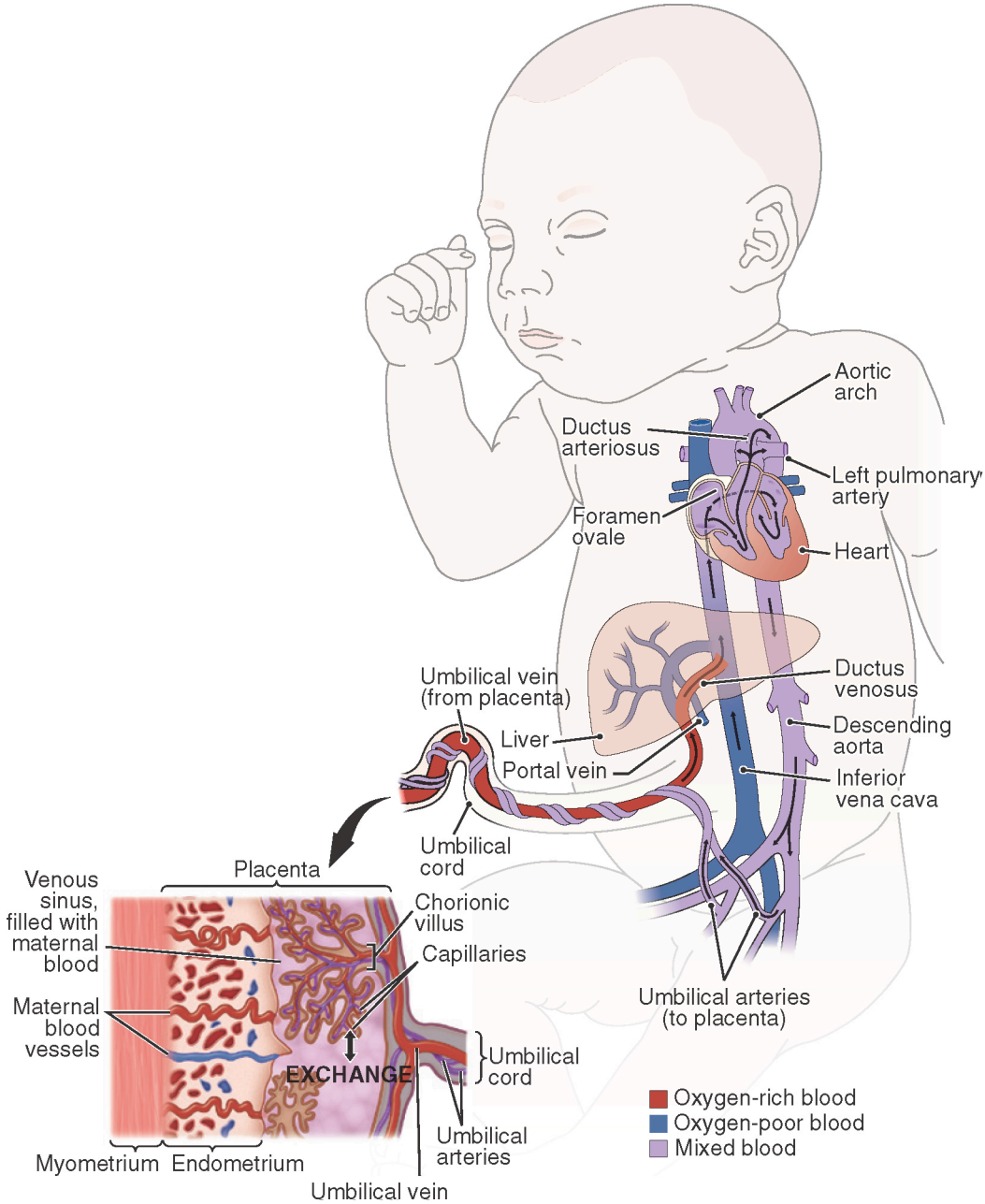

FIGURE 16-13 Fetal circulation. Colors show relative oxygen content of blood in the various vessels. Gases, waste products, and nutrients are exchanged between the fetus and the mother through capillaries in the placenta.

Another is human chorionic somatomammotropin (hCS). These hormones increase fatty acids and glucose availability for the fetus by modifying maternal metabolism.

During **gestation** (the period of development), the fetus is cushioned and protected by fluid contained in the **amniotic sac** (amnion) (FIG. 16-14), commonly called the "bag of waters." This sac ruptures at birth.

FETAL CIRCULATION

The fetus has several adaptations that serve to bypass the lungs, which are not needed to oxygenate the blood. When blood coming from the placenta enters the right atrium, the **foramen ovale**, a small hole in the septum between the atria, allows some of the blood to go directly into the left atrium, thus bypassing the pulmonary artery. Further, blood pumped out of the right ventricle can shunt directly into the aorta through a short vessel, the **ductus arteriosus**, which connects the pulmonary artery with the descending aorta (see FIG. 16-13). Both of these passages close off at birth when the pulmonary circuit is established. Their failure to close taxes the heart and may require medical attention.

extern.ir

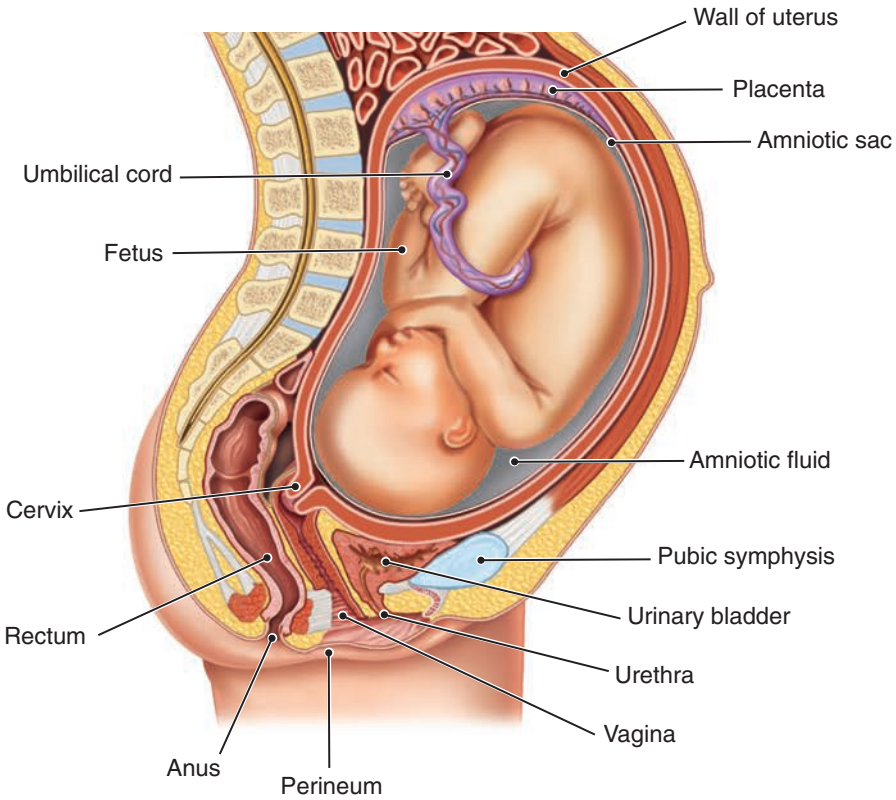

FIGURE 16-14 Midsagittal section of a pregnant uterus with intact fetus.

CHILDBIRTH

The length of pregnancy, from fertilization of the ovum to birth, is about 38 weeks, or 266 days. In practice, it is calculated as approximately 280 days or 40 weeks from the first day of the last menstrual period (LMP). For study purposes, pregnancy is divided into 3-month periods (trimesters), during which defined changes can be observed in the fetus.

Childbirth, or **parturition**, occurs in three stages **(FIG. 16-15)**:

1. Onset of regular uterine contractions and dilation of the cervix
2. Expulsion of the fetus
3. Delivery of the placenta and fetal membranes

The third stage of childbirth is followed by contraction of the uterus and control of bleeding. The factors that start labor are not completely understood, but it is clear that the hormone **oxytocin** from the posterior pituitary gland and other hormones called

16

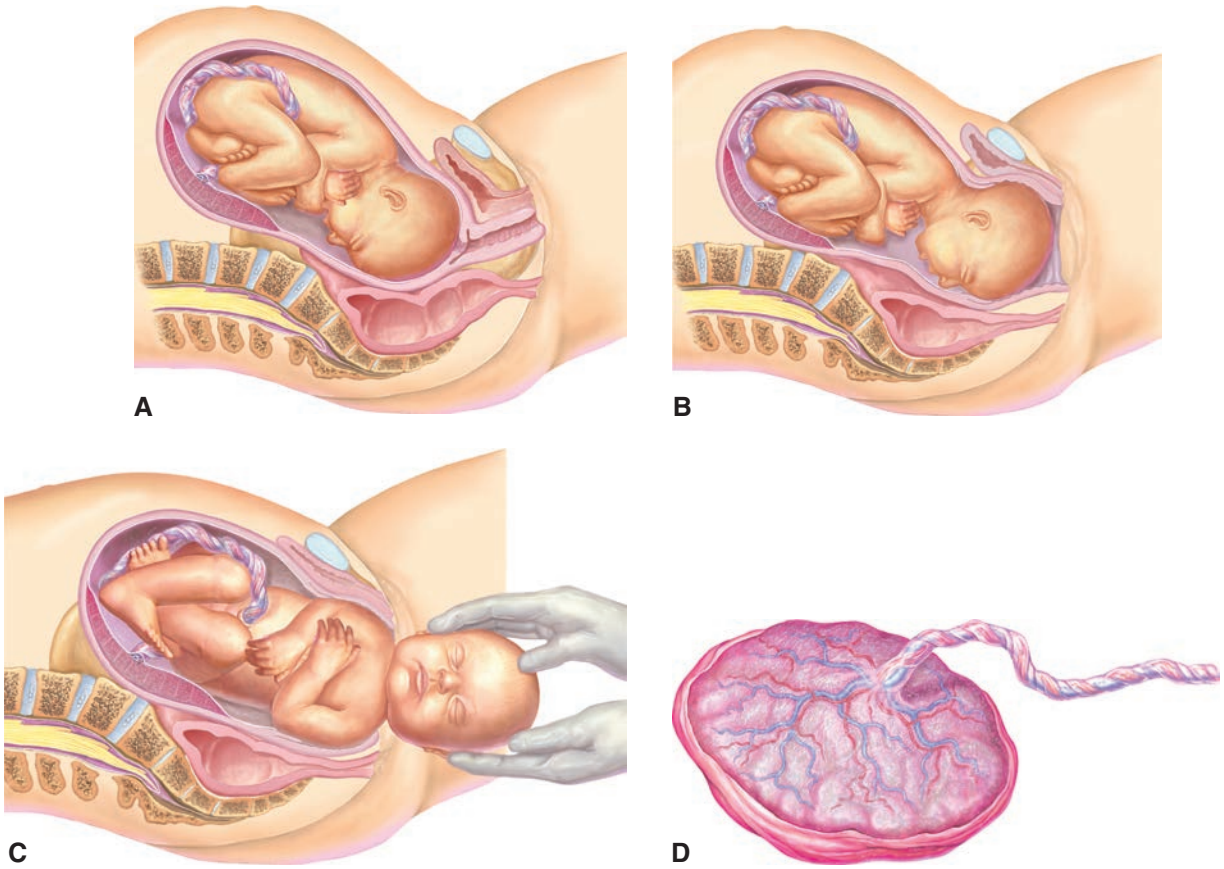

FIGURE 16-15 Stages of labor. The first stage (**A**) begins with the onset of uterine contractions. The second stage begins when the cervix is completely dilated (**B**) and ends with the birth of the baby (**C**). The third stage (**D**) ends with expulsion of the afterbirth.

extern.ir

HEALTH PROFESSIONS
Nurse-Midwives and Doulas

BOX 16-3

There are various titles associated with the term *midwife*, each having different academic preparation and certification. The name *midwife* literally means "with woman," and the practice is termed midwifery (*mid-WIF-re* or *mid-WIF-er-e*). The role of a midwife in the United States varies based on education, credentials, and licensure.

A certified nurse-midwife (CNM) is educated in the disciplines of both nursing and midwifery. A certified midwife (CM) is educated solely in the discipline of midwifery. A master's degree is required for both titles in order to take the American Midwifery Certification Board (AMCB) examination. Recertification is required every 5 years. CNMs and CMs provide primary health care to women from adolescence to beyond menopause. This includes routine gynecologic and reproductive health care, pregnancy, birth, and postpartum care, as well as perimenopause and menopause management. CNMs are licensed in all 50 U.S. states, Washington, D.C., and U.S. territories, and they have prescriptive authority in all U.S. jurisdictions. CMs are licensed in New York, New Jersey, and Rhode Island, and they may practice in Delaware and Missouri. They have prescriptive authority in New York. Most private insurances and Medicaid reimburse for CNM/CM services. The majority of CNM/CMs attend births in hospitals, but they may also attend home births and work in birth centers, clinics, and health departments. The American College of Nurse-Midwives at acnm.org has information on these careers.

A Certified Professional Midwife (CPM) is an independent midwifery provider who has met the standards for certification set by the North American Registry of Midwives (NARM). No college degree is required for this specialty. CPMs are regulated in 26 states, which vary in certification, licensure, and registration requirements. CPMs have no prescriptive authority. Private insurance in some states and Medicaid in 10 states reimburse CPMs for home and birth center births. CPMs provide care for women during pregnancy, birth, and the postpartum period and also provide newborn care. The professional associations for CPMs are the Midwives Alliance of North America (MANA) and National Association of Certified Professional Midwives (NACPM). Information is available at mana.org.

A doula (birth assistant) is someone who works with families during pregnancy, through labor, and after childbirth. Doulas provide emotional and physical support and education. They may help with prenatal preparation and early labor at home and continue with support throughout the hospital stay. Some doulas are trained in postpartum care and can give the family support at home after the birth. The name *doula* comes from Greek and refers to the most important female servant in the household, who probably assisted the lady of the house in childbearing. Doulas have a professional association that sets standards for training and certification. For more information visit dona.org.

prostaglandins are involved. BOX 16-3 has career information on midwives and other birth assistants.

Hospitals use the **Apgar score** to assess a newborn's health. Five features—heart rate, respiration, muscle tone, reaction to a nasal catheter, and skin color—are rated as 0, 1, or 2 at 1 and 5 minutes after birth. The maximum score in the test is 10. Infants with low scores require medical attention. (Although this test is named for a person, Virginia Apgar, an anesthesiologist, the title is often used as an acronym for the test components: appearance, pulse, grimace, activity, respiration.)

The term **gravida** refers to a pregnant woman. The term **para** refers to a woman who has given birth. This means the production of a viable infant (500 g or more or over 20 weeks of gestation) regardless of whether the infant is alive at birth or whether the birth is single or multiple. Prefixes are added to both terms to indicate the number of pregnancies or births, such as:

- nulli—none
- primi—one
- secondi—two
- tri or terti—three
- quadri—four
- multi—two or more

Alternatively, a number can be added after the term to indicate events, such as gravida 1, para 3, and so forth.

LACTATION

The hormone prolactin from the anterior pituitary gland, as well as hormones from the placenta, start the secretion of milk from the breasts, called **lactation.** The baby's suckling then stimulates milk release. The pituitary hormone oxytocin is needed for this release or "letdown" of milk. For the first few days after delivery, only **colostrum** is produced. This has a slightly different composition than milk, but like the milk, it has protective antibodies.

extern.ir

Terminology *Key Terms*

The terms listed below are emphasized in this chapter. Knowing them will help you organize and prioritize your learning. These boldface terms are also found, collectively, with all chapter key terms in the Glossary.

Pregnancy and Birth

Normal Structure and Function

amniotic sac *am-ne-OT-ik*	The membranous sac filled with fluid that holds the fetus; also called amnion (root: amnio)
Apgar score *AP-gar*	A system of rating an infant's physical condition immediately after birth; five features are rated as 0, 1, or 2 at 1 and 5 minutes after delivery and sometimes thereafter; the maximum possible score at each test interval is 10; infants with low scores require medical attention
chorion *KOR-e-on*	The outermost layer of the embryo that, with the endometrium, forms the placenta (adjective: chorionic)
colostrum *ko-LOS-trum*	Breast fluid that is secreted in the first few days after giving birth before milk is produced
ductus arteriosus *DUK-tusar-tere-e-O-sus*	A fetal blood vessel that connects the pulmonary artery with the descending aorta, thus allowing blood to bypass the lungs
embryo *EM-bre-o*	The stage in development between the zygote and the fetus, extending from the second through the eighth week of growth in the uterus (root: embry/o) (adjective: embryonic)
fertilization *fer-tih-lih-ZA-shun*	The union of an ovum and a spermatozoon
fetus *FE-tus*	The developing child in the uterus from the third month to birth (root: fet/o) (adjective: fetal)
foramen ovale *fo-RA-men o-VA-le*	A small hole in the interatrial septum in the fetal heart that allows blood to pass directly from the right to the left side of the heart
gestation *jes-TA-shun*	The period of development from conception to birth
gravida *GRAV-ih-da*	Pregnant woman
human chorionic gonadotropin (hCG) *kor-e-ON-ik GO-nah-do-tro-pin*	A hormone secreted by the embryo early in pregnancy that maintains the corpus luteum so that it will continue to secrete hormones
lactation *lak-TA-shun*	The secretion of milk from the mammary glands
oxytocin *ok-se-TO-sin*	A pituitary hormone that stimulates contractions of the uterus; it also stimulates release ("letdown") of milk from the breasts
para	Woman who has produced a viable infant; multiple births are considered as single pregnancies
parturition *par-tu-RIH-shun*	Childbirth (root: nat/i); labor (root: toc/o)
placenta *plah-SEN-tah*	The organ composed of fetal and maternal tissues that nourishes and maintains the developing fetus
prostaglandins *PROS-tah-glan-dinz*	A group of hormones produced throughout the body that have a variety of effects, including stimulation of uterine contractions and regulation of blood pressure, blood clotting, and inflammation
umbilical cord *um-BIL-ih-kal*	The structure that connects the fetus to the placenta; it contains vessels that carry blood between the mother and the fetus
zygote *ZI-gote*	The fertilized ovum

extern.ir

Roots Pertaining to Pregnancy and Birth

See **TABLE 16-4**.

Table 16-4 Roots for Pregnancy and Birth

Root	Meaning	Example	Definition of Example
amnio	amnion, amniotic sac	diamniotic *di-am-ne-OT-ik*	showing two amniotic sacs
embry/o	embryo	embryonic *em-bre-ON-ik*	pertaining to the embryo
fet/o	fetus	fetometry *fe-TOM-eh-tre*	measurement of a fetus
toc/o	labor	dystocia *dis-TO-se-ah*	difficult labor
nat/i	birth	neonate *NE–o-nate*	newborn
lact/o	milk	lactose *LAK-tose*	sugar (-ose) found in milk
galact/o	milk	galactagogue *gah-LAK-to-gog*	agent that promotes (-agogue) the flow of milk
gravida	pregnant woman	nulligravida *nul-ih-GRAV-ih-dah*	woman who has never (nulli-) been pregnant
para	woman who has given birth	multipara *mul-TIP-ah-rah*	woman who has given birth two or more times

Exercise 16-4

Complete the exercise. To check your answers go to Appendix 11.

Define the following words.

1. prenatal (*pre-NA-tal*) _____
2. embryogenesis (*em-bre-o-JEN-eh-sis*) _____
3. neonatal (*ne-o-NA-tal*) _____
4. fetoscopy (*fe-TOS-ko-pe*) _____
5. monoamniotic (*mon-o-am-ne-OT-ik*) _____
6. agalactia (*a-gah-LAK-she-ah*) _____
7. hypolactation (*hi-po-lak-TA-shun*) _____

Use the appropriate roots to write words for the following.

8. study of an embryo _____
9. after birth _____
10. incision of the amnion (to induce labor) _____
11. cell (-cyte) found in amniotic fluid _____
12. any disease of an embryo _____
13. instrument for endoscopic examination of the fetus _____
14. rupture of the amniotic sac _____
15. study of the newborn _____

extern.ir

Exercise 16-4 *(Continued)*

16. woman who is pregnant for the first time _____
17. woman who has been pregnant two or more times _____
18. woman who has never given birth _____
19. woman who has given birth to one child _____

Use the suffix *-tocia*, meaning "condition of labor," to write words for the following.

20. dry labor _____
21. slow labor _____

Use the root *galact/o* to write words for the following.

22. discharge of milk _____
23. cystic enlargement (-cele) of a milk duct _____

Clinical Aspects of Pregnancy and Birth

INFERTILITY

About 10% to 15% of couples who want children are unable to conceive or to sustain a pregnancy. Some of the possible causes of infertility are discussed in Chapter 15 and in this section. In men, these causes include low sperm count, low sperm motility, blockage of the ducts that transport the sperm cells, and erectile dysfunction. In women they include:

- Lack of ovulation
- Blockage in the uterine tubes, as caused by infection or excess growth of tissue
- Uterine problems, such as tumors or abnormal growth of endometrial tissue
- Cervical scarring or infection
- Excess vaginal acidity, which harms spermatozoa, or antibodies to sperm cells
- Drugs, including temporary or permanent infertility following cessation of birth control pills

BOX 16-4 describes some clinical approaches to helping infertile couples have children when all other diagnostic and therapeutic methods have failed.

ECTOPIC PREGNANCY

Development of a fertilized egg outside of its normal position in the uterine cavity is termed an **ectopic pregnancy**

CLINICAL PERSPECTIVES — BOX 16-4

Assisted Reproductive Technology: The "Art" of Conception

At least 1 in 10 American couples is affected by infertility. Assisted reproductive technologies such as in vitro fertilization (IVF), gamete intrafallopian transfer (GIFT), and zygote intrafallopian transfer (ZIFT) can help these couples have children.

In vitro *fertilization* refers to fertilization of an egg outside the mother's body in a laboratory dish, and it is often used when a woman's fallopian tubes are blocked or when a man has a low sperm count. The woman participating in IVF is given hormones to cause ovulation of several eggs. These are then withdrawn with a needle and fertilized with the father's sperm. After a few divisions, some of the fertilized eggs are placed in the uterus, thus bypassing the fallopian tubes. Additional fertilized eggs can be frozen to repeat the procedure in case of failure or for later pregnancies.

GIFT can be used when the woman has at least one normal fallopian tube and the man has an adequate sperm count. As in IVF, the woman is given hormones to cause ovulation of several eggs, which are collected. Then, the eggs and the father's sperm are placed into the fallopian tube using a catheter. Thus, in GIFT, fertilization occurs inside the woman, not in a laboratory dish.

ZIFT is a combination of IVF and GIFT. Fertilization takes place in a laboratory dish, and then the zygote is placed into the fallopian tube.

Because of a lack of guidelines or restrictions in the United States in the field of assisted reproductive technology, some problems have arisen. These issues concern the use of stored embryos and gametes, use of embryos without consent, and improper screening for disease among donors. In addition, the implantation of more than one fertilized egg has resulted in a high incidence of multiple births, even up to seven or eight offspring in a single pregnancy, a situation that imperils the survival and health of the babies.

extern.ir

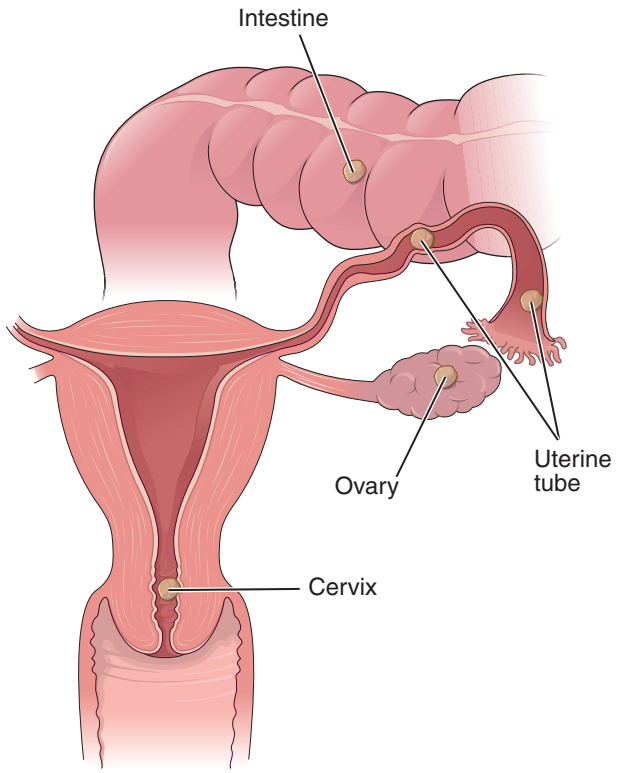

FIGURE 16-16 Ectopic pregnancy. Possible sites where a fertilized ovum might develop outside the body of the uterus.

(FIG. 16-16). Although it may occur elsewhere in the abdominal cavity, an ectopic pregnancy usually occurs in the uterine tube, resulting in a tubal pregnancy. Salpingitis, endometriosis, and PID may lead to ectopic pregnancy by blocking the ovum's passage into the uterus. Continued growth will rupture the tube, causing dangerous hemorrhage. Symptoms of ectopic pregnancy are pain, tenderness, swelling, and shock. Diagnosis is by measurement of the hormone hCG and **ultrasonography**, confirmed by laparoscopic examination. Prompt surgery is required, sometimes including removal of the tube.

PREECLAMPSIA

Preeclampsia is a serious disorder involving new-onset hypertension (high blood pressure) and proteinuria (protein in the urine) that develops after 20 weeks of pregnancy. Additional signs include general edema and sudden weight gain. Hypertension with proteinuria is known as **pregnancy-induced hypertension (PIH).** Whereas PIH is not associated with adverse outcomes, it should be monitored to ensure that it does not develop into preeclampsia.

The cause of preeclampsia is not completely understood. Researchers currently believe that it results from a hormone imbalance the leads to constriction of placental blood vessels. The condition is most often seen in first pregnancies and in women whose nutritional state is poor, who are obese, and who have received little or no health care during pregnancy. If preeclampsia remains untreated, it may lead to **eclampsia** with onset of kidney failure, convulsions, and coma during pregnancy or after birth. The result may be the death of both the mother and the infant.

ABORTION

For a variety of reasons, a pregnancy may terminate before the fetus is capable of surviving outside the uterus. An **abortion** is loss of an embryo or fetus before the 20th week of pregnancy or before a weight of 500 g (1.1 lb). When this occurs spontaneously, it is commonly referred to as a miscarriage. Most spontaneous abortions occur within the first 3 months of pregnancy. Causes include poor maternal health, hormonal imbalance, cervical incompetence (weakness), immune reactions, tumors, and, most commonly, fetal abnormalities. If all gestational tissues are not eliminated, the abortion is described as incomplete, and a physician must remove the remaining tissue.

An induced abortion is the intentional termination of a pregnancy. A common method for inducing an abortion is **dilatation and evacuation** (D&E), in which the cervix is dilated and the fetal tissue is removed by suction.

Rh INCOMPATIBILITY

Incompatibility between the blood of a mother and her fetus is a problem in certain pregnancies. If a mother lacks the Rh blood antigen (see Chapter 11) and her baby is positive for that factor (inherited from the father), the mother's body may make Rh antibodies as her baby's blood crosses the placenta during pregnancy or enters the maternal bloodstream during childbirth. In a subsequent pregnancy with an Rh-positive fetus, the antibodies may enter the fetus and destroy its red cells. **Hemolytic disease of the newborn (HDN)** is prevented by giving the mother preformed Rh antibodies during pregnancy and shortly after delivery to remove these proteins from her blood.

PLACENTAL ABNORMALITIES

If the placenta attaches near or over the cervix instead of in the upper portion of the uterus, the condition is termed **placenta previa** (FIG. 16-17). This disorder may cause bleeding later in the pregnancy. If bleeding is heavy, it may be necessary to terminate the pregnancy.

Placental abruption (abruptio placentae) describes premature separation of the placenta from its point of attachment. The separation causes hemorrhage, which, if extensive, may result in fetal or maternal death or a need to end the pregnancy. Causative factors include injury, maternal hypertension, and advanced maternal age.

MASTITIS

Inflammation of the breast, or **mastitis**, may occur at any time but usually occurs in the early weeks of breast-feeding. It is commonly caused by staphylococcal or streptococcal bacteria that enter through cracks in the nipple. The breast becomes red, swollen, and tender, and the patient may experience chills, fever, and general discomfort.

extern.ir

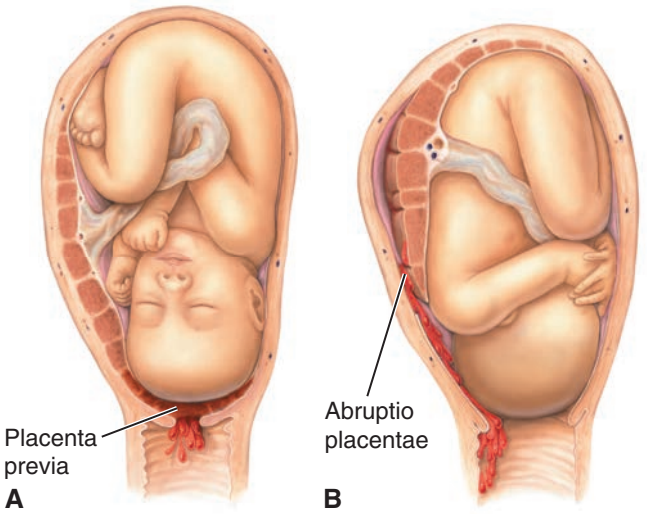

FIGURE 16-17 Placental abnormalities. If the placenta develops out of position or separates prematurely, bleeding and possible termination of pregnancy may occur. **A.** In placenta previa, the placenta attaches near the cervix instead of at the superior part of the uterus. **B.** In abruptio placentae, the placenta separates prematurely from the uterine wall.

Congenital Disorders

Congenital disorders are those present at birth (birth defects). They fall into two categories:

- Developmental disorders that occur during fetal growth
- Hereditary (familial) disorders that can be passed from parents to children through the germ cells

A genetic disorder is caused by a **mutation** (change) in the genes or chromosomes of cells. Mutations may involve changes in the number or structure of the chromosomes or changes in single or multiple genes. The appearance and severity of genetic disorders may also involve abnormal genes interacting with environmental factors. Examples are the diseases that "run in families," such as diabetes mellitus, heart disease, hypertension, and certain forms of cancer. **BOX 16-5** describes some of the most common genetic disorders.

A **carrier** of a genetic disorder is an individual who has a genetic defect that does not appear but that can be passed to offspring. Laboratory tests can identify carriers of some genetic disorders.

FOR YOUR REFERENCE

BOX 16-5

Genetic Disorders[a]

Disease	Cause	Description
albinism *AL-bih-nizm*	recessive gene mutation	lack of pigmentation
cystic fibrosis *sis-tik fi-BRO-sis*	recessive gene mutation	affects respiratory system, pancreas, and sweat glands; most common hereditary disease in white populations (see Chapter 12)
Down syndrome	extra chromosome 21	slanted eyes, short stature, mental retardation, and others (FIG. 16-18); incidence increases with increasing maternal age; trisomy 21 syndrome
fragile X chromosome	defect in an X (sex-determining) chromosome	reduced intellectual abilities, autism, hyperactivity; enlarged head and ears; passed from mothers to sons with the X chromosome (sex-linked)
hemophilia *he-mo-FIL-e-ah*	recessive gene mutation on the X chromosome	bleeding disease inherited with an X chromosome and usually passed from mothers to sons
Huntington disease	dominant gene mutation	altered metabolism destroys specific nerve cells; appears in adulthood and is fatal within about 10 years; causes motor and mental disorders
Klinefelter syndrome	extra X chromosome	lack of sexual development, lowered intelligence
Marfan syndrome	dominant gene mutation	disease of connective tissue with weakness of the aorta
neurofibromatosis *nu-ro-fi-bro-mah-TO-sis*	dominant gene mutation	multiple skin tumors containing nerve tissue

(continued)

extern.ir

FOR YOUR REFERENCE *(Continued)*

BOX 16-5

Genetic Disorders[a]

Disease	Cause	Description
phenylketonuria (PKU) *fen-il-ke-to-NU-re-ah*	recessive gene mutation	lack of enzyme to metabolize an amino acid (phenylalanine); neurologic signs, mental retardation, lack of pigment; tested for at birth; special diet can prevent retardation
sickle cell anemia	recessive gene mutation	abnormally shaped red cells block blood vessels; mainly affects black populations
Tay–Sachs disease *ta-saks*	recessive gene mutation	an enzyme deficiency causes lipid to accumulate in nerve cells and other tissues; causes death in early childhood; carried in eastern European Jewish populations
Turner syndrome	single X chromosome	sexual immaturity, short stature, possible lowered intelligence

[a]A dominant gene is one for a trait that always appears if the gene is present; that is, it will affect the offspring even if inherited from only one parent. A recessive gene is one for a trait that will appear only if the gene is inherited from both parents.

Teratogens are factors that cause malformations in the developing fetus. These include infections—such as rubella, herpes simplex, and syphilis—alcohol, drugs, chemicals, and radiation. The fetus is most susceptible to teratogenic effects during the first 3 months of pregnancy.

Examples of developmental disorders are **atresia** (absence or closure of a normal body opening), **anencephaly** (absence of a brain), **cleft lip**, **cleft palate**, and congenital heart disease. **Spina bifida** is incomplete closure of the spine, through which the spinal cord and its membranes may project (FIG. 16-19). This usually occurs in the lumbar region. If there is no herniation of tissue, the condition is spina bifida occulta. Protrusion of the meninges through the opening is a meningocele; in a myelomeningocele, both the spinal cord and membranes herniate through the defect, as seen in FIGURES 16-19D and 16-20. Note that folic acid or folate, a B vitamin, can prevent embryonic spinal malformations, known as neural tube defects. This vitamin is found in vegetables, liver, legumes, and seeds, but it is now added to some commercial foods, including cereals and breads, to provide young women with this vitamin early on in case they become pregnant.

FIGURE 16-18 Child with Down syndrome (trisomy 21). The typical facial features are visible in this photo.

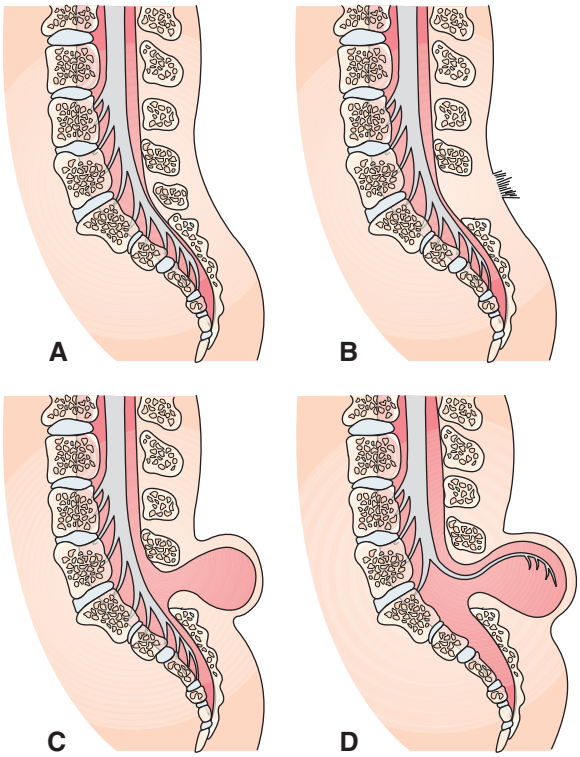

FIGURE 16-19 Spinal defects. A. Normal spinal cord. **B.** Spina bifida occulta. **C.** Meningocele. **D.** Myelomeningocele.

extern.ir

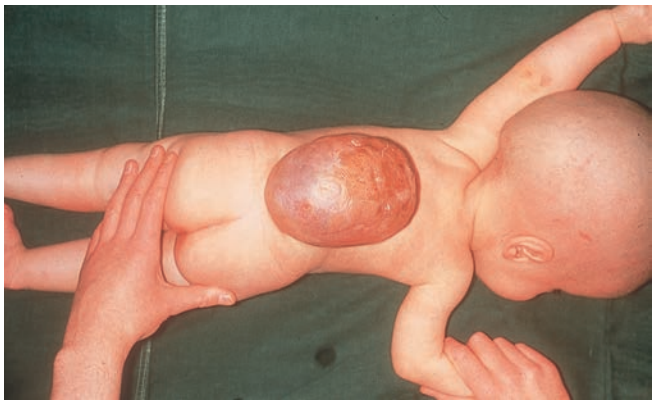

FIGURE 16-20 A myelomeningocele.

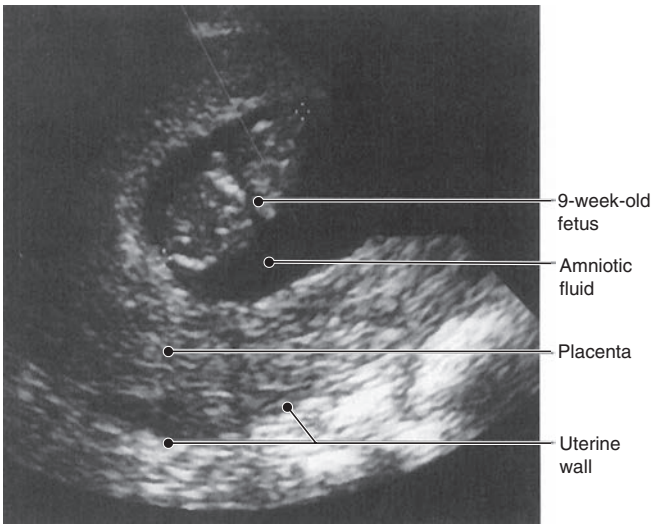

FIGURE 16-21 Sonogram. This transvaginal sonogram shows a 9-week-old fetus.

DIAGNOSIS OF CONGENITAL DISORDERS

Many congenital disorders can now be detected before birth. Ultrasonography (FIG. 16-21), in addition to its use for monitoring pregnancies and determining fetal sex, can also reveal certain fetal abnormalities. In **amniocentesis** (FIG. 16-22), a sample is withdrawn from the amniotic cavity with a needle. The fluid obtained is analyzed for chemical abnormalities. The cells are grown in the laboratory and tested for biochemical disorders. A **karyotype** is prepared to study the genetic material (see FIG. 2-10).

In **chorionic villus sampling** (CVS), biopsies of the membrane around the fetus are obtained through the cervix for analysis (see FIG. 16-22). This can be done at 8 to 10 weeks of pregnancy, in comparison with 14 to 16 weeks for amniocentesis.

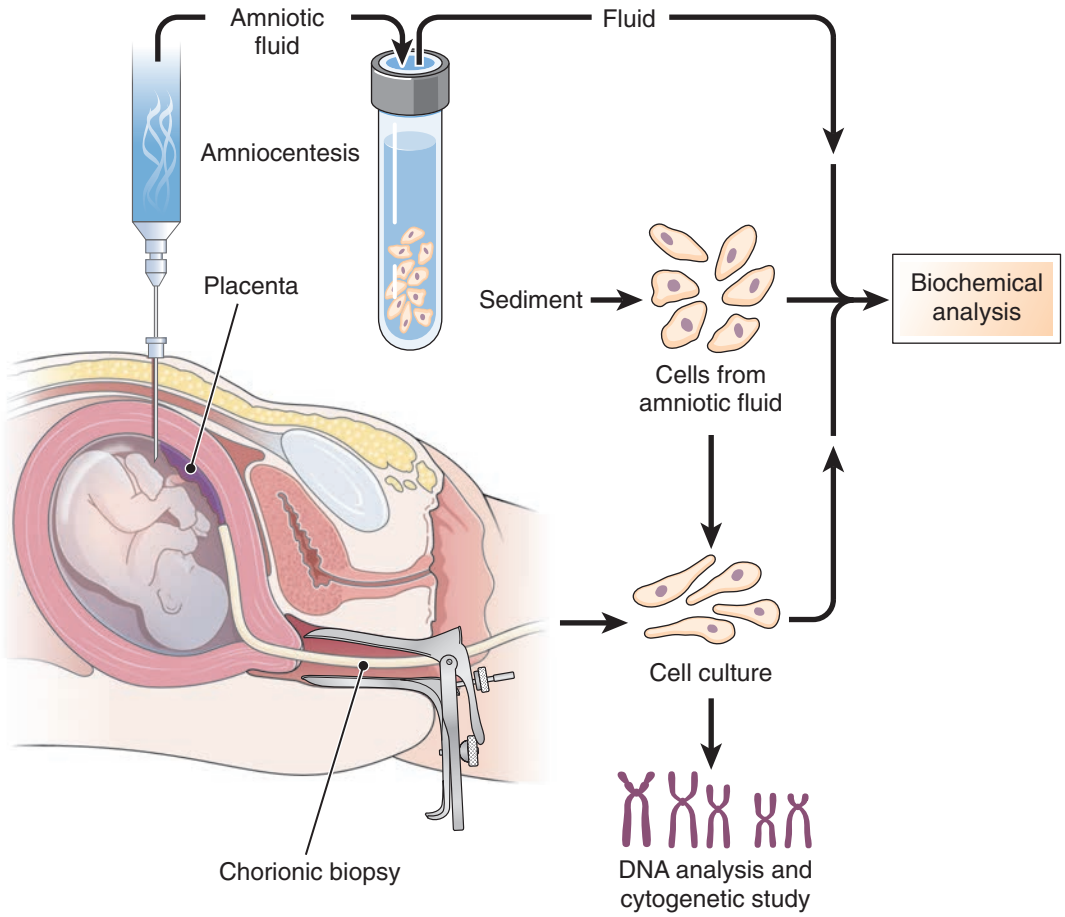

FIGURE 16-22 Prenatal testing. Specimens obtained by amniocentesis or chorionic villus sampling can be analyzed chemically and cells can be cultured for DNA analysis.

extern.ir

Terminology Key Terms

The terms listed below are emphasized in this chapter. Knowing them will help you organize and prioritize your learning. These boldface terms are also found, collectively, with all chapter key terms in the Glossary.

Pregnancy and Birth

Disorders

abortion *ah-BOR-shun*	Termination of a pregnancy before the fetus is capable of surviving outside the uterus, usually at 20 weeks or 500 g; may be spontaneous or induced; a spontaneous abortion is commonly called a miscarriage
anencephaly *an-en-SEF-ah-le*	Congenital absence of a brain
atresia *ah-TRE-ze-ah*	Congenital absence or closure of a normal body opening
carrier *KAH-re-er*	An individual who has an unexpressed genetic defect that can be passed to his or her children
cleft lip	A congenital separation of the upper lip
cleft palate	A congenital split in the roof of the mouth
congenital disorder *kon-JEN-ih-tal*	A disorder that is present at birth; may be developmental or hereditary (familial)
eclampsia *eh-KLAMP-se-ah*	Convulsions and coma occurring during pregnancy or after delivery and associated with preeclampsia (see below) (adjective: eclamptic)
ectopic pregnancy *ek-TOP-ik*	Development of the fertilized ovum outside the body of the uterus; usually occurs in the uterine tube (tubal pregnancy) but may occur in other parts of the reproductive tract or abdominal cavity (see **FIG. 16-16**)
hemolytic disease of the newborn (HDN)	Disease that results from Rh incompatibility between the blood of a mother and her fetus; an Rh-negative mother produces antibody to Rh-positive fetal red cells that enter her circulation; these antibodies can destroy Rh-positive fetal red cells in a later pregnancy unless the mother is treated with antibodies to remove the Rh antigen; formerly called erythroblastosis fetalis
mastitis *mas-TI-tis*	Inflammation of the breast, usually associated with the early weeks of breast-feeding
mutation *mu-TA-shun*	A change in the genetic material of the cell; most mutations are harmful; if the change appears in the sex cells, it can be passed to future generations
placental abruption *ab-RUP-shun*	Premature separation of the placenta; abruptio placentae
placenta previa *PRE-ve-ah*	Placental attachment in the lower portion of the uterus instead of the upper portion, as is normal; may result in hemorrhage late in pregnancy
preeclampsia *pre-eh-KLAMP-se-ah*	A serious disorder involving new-onset hypertension and proteinuria that develops after 20 weeks of pregnancy. If untreated, may lead to eclampsia
pregnancy-induced hypertension (PIH)	New-onset hypertension without proteinuria that develops during pregnancy
spina bifida *SPI-nah BIF-ih-dah*	A congenital defect in the closure of the spinal column through which the spinal cord and its membranes may project (see **FIG. 16-19**)
teratogen *ter-AT-o-jen*	A factor that causes developmental abnormalities in the fetus (root terat/o means "malformed fetus") (adjective: teratogenic)

extern.ir

Terminology *Key Terms (Continued)*

Diagnosis and Treatment	
amniocentesis *am-ne-o-sen-TE-sis*	Transabdominal puncture of the amniotic sac to remove amniotic fluid for testing; tests on the cells and fluid obtained can reveal congenital abnormalities, blood incompatibility, and sex of the fetus (see **FIG. 16-22**)
chorionic villus sampling (CVS)	Removal of chorionic cells through the cervix for prenatal testing; can be done earlier in pregnancy than amniocentesis
dilatation and evacuation (D&E)	Widening of the cervix and removal of conception products by suction
karyotype *KAR-e-o-tipe*	A picture of cellular chromosomes arranged in the order of decreasing size; can reveal abnormalities in the chromosomes themselves or in their number or arrangement (root kary/o means "nucleus") (see **FIG. 2-10**)
ultrasonography *ul-trah-so-NOG-rah-fe*	The use of high-frequency sound waves to produce a photograph of an organ or tissue (see **FIG. 16-21**); used in obstetrics to diagnose pregnancy, multiple births, and abnormalities and also to study and measure the fetus; the image obtained is a sonogram or ultrasonogram

Terminology *Enrichment Terms*

The terms listed below expand on the key terms to increase your knowledge of this chapter topic.

Pregnancy and Birth

Normal Structure and Function	
afterbirth	The placenta and membranes delivered after birth of a child
antepartum *an-te-PAR-tum*	Before childbirth, with reference to the mother
Braxton Hicks contractions	Light uterine contractions that occur during pregnancy and increase in frequency and intensity during the third trimester; they strengthen the uterus for delivery
chloasma *klo-AZ-mah*	Brownish pigmentation that appears on the face during pregnancy; melasma
fontanel *fon-tan-EL*	A membrane-covered space between cranial bones in the fetus that later becomes ossified; a soft spot; also spelled fontanelle
intrapartum *in-trah-PAR-tum*	Occurring during childbirth
linea nigra *LIN-e-ah NI-grah*	A dark line on the abdomen from the umbilicus to the pubic region that may appear late in pregnancy
lochia *LO-ke-ah*	The mixture of blood, mucus, and tissue discharged from the uterus after childbirth
meconium *meh-KO-ne-um*	The first feces of the newborn
peripartum *per-ih-PAR-tum*	Occurring during the end of pregnancy or the first few months after delivery, with reference to the mother
postpartum	After childbirth, with reference to the mother
premature	Describing an infant born before the organ systems are fully developed; immature

(continued)

extern.ir

Terminology Enrichment Terms (Continued)

preterm	Occurring before the 37th week of gestation; describing an infant born before the 37th week of gestation
puerperium *pu-er-PERE-e-um*	The first 42 days after childbirth, during which the mother's reproductive organs usually return to normal (root puer means "child")
striae atrophicae *STRI-e ah-TRO-fih-ke*	Pinkish or gray lines that appear where skin has been stretched, as in pregnancy; stretch marks, striae gravidarum
umbilicus *um-bih-LI-kus*	The scar in the middle of the abdomen that marks the attachment point of the umbilical cord to the fetus; the navel; also pronounced *um-BIL-ih-kus*
vernix caseosa *VER-niks ka-se-O-sah*	The cheese-like deposit that covers and protects the fetus (literally "cheesy varnish")
Disorders	
cephalopelvic disproportion *sef-ah-lo-PEL-vik*	The condition in which the head of the fetus is larger than the mother's pelvic outlet; also called fetopelvic disproportion
choriocarcinoma *kor-e-o-kar-sih-NO-mah*	A rare malignant neoplasm composed of placental tissue
galactorrhea *gah-lak-to-RE-ah*	Excessive secretion of milk or continued milk production after breast-feeding has ceased; often results from excess prolactin secretion and may signal a pituitary tumor
hydatidiform mole *hi-dah-TID-ih-form*	A benign overgrowth of placental tissue; the placenta dilates and resembles grape-like cysts; the neoplasm may invade the uterine wall, causing rupture; also called hydatid mole
hydramnios *hi-DRAM-ne-os*	An excess of amniotic fluid; also called polyhydramnios
oligohydramnios *ol-ih-go-hi-DRAM-ne-os*	A deficiency of amniotic fluid
patent ductus arteriosus (PDA) *PA-tent DUK-tusar-te-re-O-sus*	Persistence of the ductus arteriosus after birth so that blood continues to shunt from the pulmonary artery to the aorta
puerperal infection *pu-ER-per-al*	Infection of the genital tract after delivery
Diagnosis and Treatment	
abortifacient *a-bor-tih-FA-shent*	Agent that induces abortion
alpha-fetoprotein (AFP) *AL-fah-fe-to-PRO-tene*	A fetal protein that may be elevated in amniotic fluid and maternal serum in cases of certain fetal disorders
artificial insemination (AI)	Placement of active semen into the vagina or cervix for the purpose of impregnation; the semen can be from a husband, partner, or donor
cesarean section *seh-ZAR-e-an*	Incision of the abdominal wall and uterus for delivery of a fetus; also called cesarean birth
endometrial ablation *ab-LA-shun*	Selective destruction of the endometrium for therapeutic purpose; done to relieve excessive menstrual bleeding (menorrhagia)
extracorporeal membrane oxygenation (ECMO) *eks-trah-kor-PO-re-al*	A technique for pulmonary bypass in which deoxygenated blood is removed, passed through a circuit that oxygenates the blood, and then returned; used for selected newborn and pediatric patients in respiratory failure with an otherwise good prognosis

extern.ir

Terminology Enrichment Terms (Continued)

in vitro fertilization (IVF)	Clinical procedure for achieving fertilization when it cannot be accomplished naturally; an oocyte (immature ovum) is removed, fertilized in the laboratory, and placed as a zygote into the uterus or fallopian tube (ZIFT, zygote intrafallopian transfer); alternatively, an ovum can be removed and placed along with sperm cells into the fallopian tube (GIFT, gamete intrafallopian transfer) (see **BOX 16-4**)
obstetrics *ob-STET-riks*	The branch of medicine that treats women during pregnancy, childbirth, and the puerperium; usually combined with the practice of gynecology
pediatrics *pe-de-AT-riks*	The branch of medicine that treats children and diseases of children (root ped/o means "child")
pelvimetry *pel-VIM-eh-tre*	Measurement of the pelvis by manual examination or radiographic study to determine whether delivery of a fetus through the vagina will be possible
Pitocin *pih-TO-sin*	Trade name for oxytocin; used to induce and hasten labor
presentation	Term describing the part of the fetus that can be felt by vaginal or rectal examination; normally the head presents first (vertex presentation), but sometimes the buttocks (breech presentation), face, or other part presents first
RhoGAM *RO-gam*	Trade name for a preparation of antibody to the Rh(D) antigen; used to prevent hemolytic disease of the newborn in cases of Rh incompatibility

Terminology Abbreviations

The abbreviations listed below are emphasized in this chapter. These are also found, collectively, with all chapter abbreviations in Appendix 2.

Pregnancy and Birth

AB	Abortion
AFP	Alpha-fetoprotein
AGA	Appropriate for gestational age
AI	Artificial insemination
ART	Assisted reproductive technology
C-section	Cesarean section
CPD	Cephalopelvic disproportion
CVS	Chorionic villus sampling
D&E	Dilatation and evacuation
ECMO	Extracorporeal membrane oxygenation
EDC	Estimated date of confinement
FHR	Fetal heart rate
FHT	Fetal heart tone
FTND	Full-term normal delivery
FTP	Full-term pregnancy
GA	Gestational age
GIFT	Gamete intrafallopian transfer
hCG	Human chorionic gonadotropin
HDN	Hemolytic disease of the newborn
IVF	In vitro fertilization
LMP	Last menstrual period
NB	Newborn
NICU	Neonatal intensive care unit
OB	Obstetrics, obstetrician
PDA	Patent ductus arteriosus
PIH	Pregnancy-induced hypertension
PKU	Phenylketonuria
SVD	Spontaneous vaginal delivery
UC	Uterine contractions
UTP	Uterine term pregnancy
VBAC	Vaginal birth after cesarean section
ZIFT	Zygote intrafallopian transfer

extern.ir

Case Study Revisited

Abigail's Follow-Up Study

After a short stay in the PACU, Abigail was alert and oriented when she arrived at her private postpartum hospital room. Her healthy newborn daughter was immediately brought into the room and placed by Abigail's face, neck, and chest. Skin to skin contact is an important aspect to initial bonding with a newborn. Both parents held, stroked, kissed, and talked to their new daughter. The nurse explained that talking is important, as a newborn already knows its parents' voices and is soothed by the familiar sounds.

Abigail was fortunate that her hospital had "family-centered" care. The private postpartum room included a fold out bed for her husband. The healthy newborn was also able to stay in the room with mom and dad. Rooming-in, or having a baby with the parents at all times, is increasingly popular in hospitals. Both mom and newborn had frequent nurse checks around the clock.

Abigail was encouraged to get up and walk the next day. Her incision was healing well, and there were no signs of infection. She was able to tolerate a regular diet and required minimal medication for pain. Abigail experienced minor discomfort with breast-feeding initially, but she and the baby began to get into a routine, and the feeding progressed well. The nurse explained to Abigail that if she needed rest it was okay for her newborn to spend a few hours in the nursery while Abigail slept. Abigail would just need to tell the nurses whether they could give her newborn baby formula or would like her returned to Abigail for breast-feeding.

Abigail's husband offered needed support and encouragement and was very helpful with their 3 y/o son, who missed his mom. Both baby and mom were doing well and were discharged home. Abigail's mother was stopping by the house every day to take care of the "big brother," help with meals, and do some light housekeeping so Abigail could get some important rest.

extern.ir

CHAPTER 16

Review

This review tests your understanding of the content introduced in this chapter. Follow the instructions for each exercise and check your answers in Appendix 11.

LABELING EXERCISE

THE FEMALE REPRODUCTIVE SYSTEM

Write the name of each numbered part on the corresponding line.

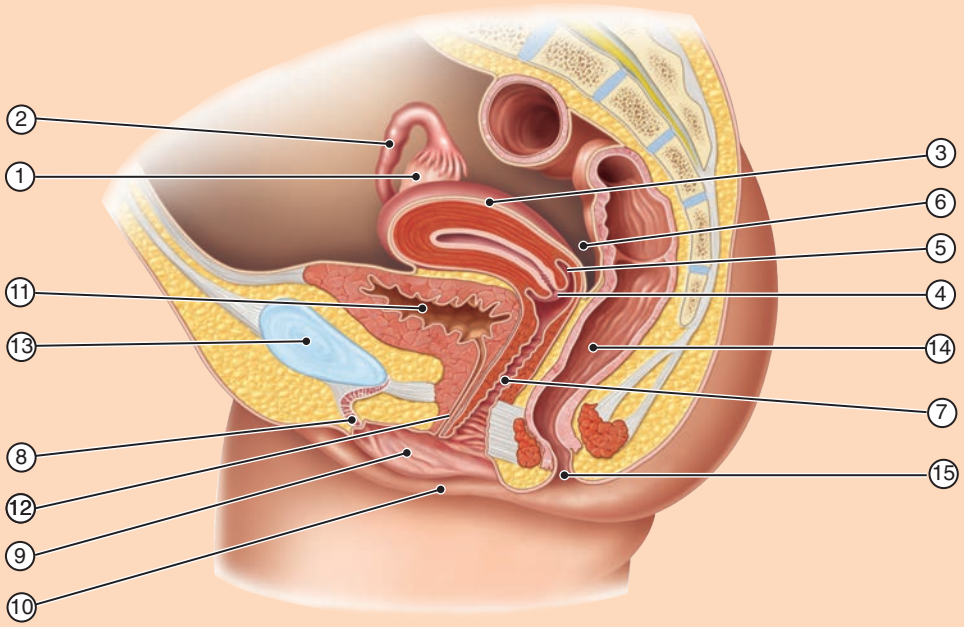

Anus
Cervix
Clitoris
Labium majus
Labium minus
Ovary
Posterior fornix
Pubic symphysis
Rectouterine pouch
Rectum
Urethra
Urinary bladder
Uterine tube
Uterus
Vagina

1. _____
2. _____
3. _____
4. _____
5. _____
6. _____
7. _____
8. _____
9. _____
10. _____
11. _____
12. _____
13. _____
14. _____
15. _____

extern.ir

OVULATION AND FERTILIZATION

Write the name of each numbered part on the corresponding line.

Body of uterus
Cervix
Fimbriae
Greater vestibular (Bartholin) gland
Implanted embryo
Ovary
Ovum
Sperm cells (spermatozoa)
Uterine tube
Vagina

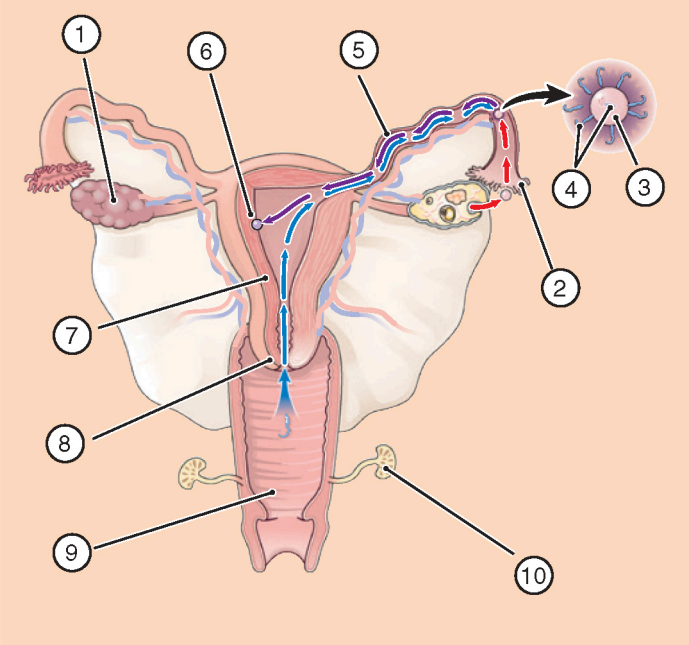

1. _____
2. _____
3. _____
4. _____
5. _____
6. _____
7. _____
8. _____
9. _____
10. _____

TERMINOLOGY

MATCHING

Match the following terms, and write the appropriate letter to the left of each number.

____	1. vulva	a. fertilized egg
____	2. gestation	b. female erectile tissue
____	3. oxytocin	c. external female genitalia
____	4. zygote	d. period of development in the uterus
____	5. clitoris	e. hormone that stimulates labor

____	6. menostasis	a. first menstrual period
____	7. metrorrhagia	b. excess uterine bleeding
____	8. menarche	c. suppression of menstruation
____	9. gynecogenic	d. wasting of uterine tissue
____	10. metratrophia	e. producing female characteristics

____	11. eclampsia	a. fibroid
____	12. mutation	b. absence of a normal body opening
____	13. teratogen	c. genetic change
____	14. atresia	d. convulsions and coma associated with pregnancy
____	15. leiomyoma	e. cause of fetal abnormality

extern.ir

Enrichment Terms

____ 16. puerperium
____ 17. linea nigra
____ 18. meconium
____ 19. hymen
____ 20. lochia

a. uterine discharge after childbirth
b. period after childbirth
c. first feces of the newborn
d. membrane that covers the vaginal opening
e. dark line on the abdomen from umbilicus to pubic region

____ 21. hirsutism
____ 22. dyspareunia
____ 23. vernix caseosa
____ 24. leukorrhea
____ 25. polyhydramnios

a. excess of amniotic fluid
b. pain during intercourse
c. whitish vaginal discharge
d. excess hair growth
e. fetal protective covering

FILL IN THE BLANKS

Complete the sentence with the correct term(s).

26. The instrument for examining the vagina and cervix is the _____ .
27. The female gonad is the _____ .
28. The herniation of the rectum into the vaginal wall is called _____ .
29. The ovarian follicle encloses a developing _____ .
30. The organ that nourishes and maintains the developing fetus is the _____ .
31. The secretion of milk from the mammary glands is called _____ .
32. Loss of an embryo or fetus before 20 weeks or 500 g is termed a(n) _____ .
33. Parametritis (*par-ah-me-TRI-tis*) means inflammation of the tissue near the _____ .
34. Polymastia (*pol-e-MAS-te-ah*) means the presence of more than one pair of _____ .

TRUE–FALSE

Examine the following statements. If the statement is true, write T in the first blank. If the statement is false, write F in the first blank, and correct the statement by replacing the underlined word in the second blank.

	True or False	Correct Answer
35. Agalactia is the lack of <u>milk</u> production.	_____	_____
36. For the first 2 months, the developing offspring is called a <u>fetus</u>.	_____	_____
37. The muscular wall of the uterus is the <u>endometrium</u>.	_____	_____
38. After ovulation, the ovarian follicle becomes a <u>fimbriae</u>.	_____	
39. Fertilization of an ovum occurs in the <u>uterus</u>.	_____	_____
40. The Pap smear is a test for <u>cervical</u> cancer.	_____	_____
41. Parturition is <u>childbirth</u>.	_____	_____
42. The fallopian tube is the <u>uterine tube</u>.	_____	_____
43. A fontanel is the soft spot between the <u>cranial bones</u>.	_____	_____

extern.ir

DEFINITIONS

Define the following terms.

44. retrouterine (*reh-tro-U-ter-in*) _____
45. hysteropathy (*his-teh-ROP-ah-the*) _____
46. metromalacia (*me-tro-mah-LA-she-ah*) _____
47. pyosalpinx (*pi-o-SAL-pinx*) _____
48. colpostenosis (*kol-po-steh-NO-sis*) _____
49. vulvodynia (*vul-vo-DIN-e-ah*) _____
50. postnatal (*post-NA-tal*) _____
51. inframammary (*in-frah-MAM-ah-re*) _____
52. extraembryonic (*eks-trah-em-bre-ON-ik*) _____
53. tripara (*TRIP-ah-rah*) _____
54. teratogenic (*TER-at-o-jen-ik*) _____

Write words for the following definitions.

55. hernia of a uterine tube _____
56. suture of the vulva (episi/o) _____
57. narrowing of the uterus (metr/o) _____
58. surgical removal of the uterus (hyster/o) and uterine tubes _____
59. radiograph of the breast (mamm/o) _____
60. abnormal or difficult labor _____
61. rupture of the amniotic sac _____
62. study of the embryo _____
63. measurement of a fetus _____

In Abigail's opening case study, find words for the following.

64. term that refers to a pregnant woman _____
65. upper rounded portion of the uterus _____
66. measurement of the pelvis _____
67. above the pubic bone _____
68. test to measure the health of a newborn _____
69. newborn _____

OPPOSITES

Write a word that means the opposite of the following.

70. oligohydramnios _____
71. postnatal _____
72. dystocia _____
73. ovulatory _____
74. extrauterine _____

extern.ir

ADJECTIVES

Write the adjective form of the following.

75. cervix _____
76. uterus _____
77. perineum _____
78. vagina _____
79. embryo _____
80. amnion _____

PLURALS

Write the plural form of the following.

81. ovum _____
82. cervix _____
83. fimbria _____
84. labium _____

ELIMINATIONS

In each of the sets below, underline the word that does not fit in with the rest, and explain the reason for your choice.

85. amniocentesis — chorionic villus sampling — karyotype — ultrasonography — candidiasis

_____

86. hemophilia — albinism — measles — PKU — cystic fibrosis

_____

87. colostrum — progesterone — LH — estrogen — FSH

_____

88. umbilical cord — labia majora — amniotic fluid — chorion — placenta

_____

89. placental abruption — spina bifida — pregnancy-induced hypertension — placenta previa — eclampsia

_____

FOLLOW THE PATH

Follow the path of an ovum from production to implantation. Place the letters "A" through "D" next to the terms on the space provided to put the terms in proper order.

90. uterine tube _____
91. fimbriae _____
92. ovary _____
93. uterus _____

extern.ir

WORD BUILDING

Write a word for the following definitions using the word parts given. Each word part can be used more than once.

-graphy	episi/o	-plasty	intra-	cervic/o	mamm/o	-itis	-al	-tomy	trans-

94. plastic repair of the vulva _____
95. inflammation of the cervix _____
96. radiographic study of the breast _____
97. plastic repair of the breast _____
98. radiographic study of the cervix _____
99. incision of the vulva _____
100. within the cervix _____
101. plastic repair of the cervix _____
102. incision of the cervix _____
103. through the cervix _____

ABBREVIATIONS

Write the meaning of the following abbreviations.

104. hCG _____
105. DUB _____
106. LMP _____
107. FHR _____
108. GA _____
109. VBAC _____

WORD ANALYSIS

Define the following words, and give the meaning of the word parts in each. Use a dictionary if necessary.

110. antiangiogenesis (*an-te-an-je-o-JEN-eh-sis*)
    a. anti- _____
    b. angi/o _____
    c. gen _____
    d. e/sis _____
111. gynecomastia (*gi-neh-ko-MAS-te-ah*)
    a. gynec/o _____
    b. mast/o _____
    c. -ia _____
112. oxytocia (*ok-se-TO-se-ah*)
    a. oxy _____
    b. toc _____
    c. -ia _____

extern.ir

113. oligohydramnios (*ol-ih-go-hi-DRAM-ne-os*)

a. oligo- _____

b. hydr/o _____

c. amnio(s) _____

114. galactorrhea (*gah-LAK-tor-e-ah*)

a. galact/o _____

b. (r)rhea _____

115. anencephaly (*an-en-SEF-ah-le*)

a. an- _____

b. encephal/o _____

c. -y _____

extern.ir

Additional Case Studies

Case Study 16-1: Total Abdominal Hysterectomy With Bilateral Salpingo-oophorectomy

Naomi, a 60 y/o gravida 2, para 2, had spent 3 months under the care of her gynecologist (GYN) for treatment of postmenopausal bleeding and cervical dysplasia. She had had several vaginal examinations with Pap smears, a uterine ultrasound, colposcopy with endocervical biopsies, and a D&C with cone biopsy. She wanted to take hormone replacement therapy (HRT), but her doctor thought she was at too much risk with the abnormal cells on her cervix and the excessive bleeding.

She had a TAH and BSO under general anesthesia with no complications and an uneventful recovery. Her uterus had been prolapsed on abdominal examination, but there was no sign of malignancy or PID. The pathology report revealed several uterine leiomyomas and stenosis of the right uterine tube. She was discharged on the second postoperative day with few activity restrictions.

Case Study 16-1 Questions

Follow the instructions for each question and check your answers in Appendix 11.

Multiple Choice. *Select the best answer, and write the letter of your choice to the left of each number.*

_____ 1. Naomi is a gravida 2, para 2. This means
- a. she has four children from two pregnancies
- b. she has had two pregnancies and two births
- c. she has had four pregnancies and two births
- d. she has one set of twins

_____ 2. An endocervical biopsy is
- a. a cone-shaped tissue sample from the uterine fundus
- b. a tissue sample from within the neck
- c. a tissue sample from the lining of the cervix
- d. a scraping of tissue cells from the vaginal wall

_____ 3. A curettage is a(n)
- a. suturing
- b. scraping
- c. incision
- d. examination

_____ 4. A colposcopy is an endoscopic examination of the
- a. vagina
- b. fundus
- c. intraperitoneal pelvic floor
- d. uterus and uterine tubes

_____ 5. Another name for a leiomyoma is a(n)
- a. ectopic pregnancy
- b. uterine fibroid
- c. myoma
- d. b and c

Define each of the following abbreviations.

6. D&C _____
7. BSO _____
8. HRT _____
9. TAH _____
10. GYN _____

extern.ir

Case Study 16-2: In Vitro Fertilization

Ruth had worked as a technologist in the in vitro fertilization (IVF) laboratory at University Medical Center for 4 years. Her department was the advanced reproductive technology program. Although her work was primarily in the laboratory, she followed each patient through all five phases of the IVF and embryo transfer treatment cycle: follicular development, aspiration of the preovulatory follicles, sperm preparation, IVF, and embryo transfer. Her department does both gamete intrafallopian transfer (GIFT) and zygote intrafallopian transfer (ZIFT).

While the female patient is in surgery having an ultrasound-guided transvaginal oocyte retrieval, Ruth examines the recently donated sperm for motility and quantity. She prepares to inoculate the sample into the cytoplasm of the ova as soon as she receives the cells from the OR. After inoculation, she places the sterile petri dish with the fertilized oocytes into an incubator until they are ready to be introduced into the female patient.

Case Study 16-2 Questions

Follow the instructions for each question and check your answers in Appendix 11.

Write a term from the case study with each of the following meanings.

1. cell produced by fertilization _____
2. an immature egg cell _____
3. pertaining to the structure in which an egg ripens _____

Define each of the following abbreviations.

4. IVF _____
5. ZIFT _____
6. GIFT _____

extern.ir

Appendix 1
Commonly Used Symbols

Commonly Used Symbols

Symbol	Meaning	Chapter
1°	primary	3
2°	secondary (to)	3
Δ	change (Greek delta)	3
Ⓛ	left	3
Ⓡ	right	3
↑	increase(d)	3
↓	decrease(d)	3
♂	male	3
♀	female	3
°	degree	3
∧	above	3
∨	below	3
=	equal to	3
≠	not equal to	3
±	doubtful, slight	3
~	approximately	3
×	times	3
#	number, pound	3

extern.ir

Appendix 2
Abbreviations and Their Meanings

Abbreviations and Their Meanings

Abbreviation	Meaning	Chapter
ā	before	3
A, Acc	accommodation	8
$\overline{aa}$	of each	3
A1c	glycated hemoglobin	9
Ab	antibody	11
AB	abortion	16
ABC	aspiration biopsy cytology	3
ABCDE	asymmetry, uneven borders, different colors, diameter of more than 6 mm, and evolution (change)	4
ABG(s)	arterial blood gas(es)	12
ABR	auditory brainstem response	8
ac	before meals	3
AC	air conduction	8
ACE	angiotensin-converting enzyme	10, 14
ACh	acetylcholine	6, 7
ACL	anterior cruciate ligament	5
ACTH	adrenocorticotropic hormone	9
ad lib	as desired	3
AD	Alzheimer disease	7
ADH	antidiuretic hormone	9, 14
ADHD	attention-deficit/hyperactivity disorder	7
ADL	activities of daily living	3
AE	above the elbow	5
AED	automated external defibrillator	10
AF	acid fast; atrial fibrillation	3, 10
AFB	acid-fast bacillus	12
AFP	alpha-fetoprotein	3, 16
Ag	antigen; also silver	11
AGA	appropriate for gestational age	16
AI	artificial insemination; aromatase inhibitor	16
AIDS	acquired immunodeficiency syndrome	11, 15
AK	above the knee	5
ALL	acute lymphoblastic (lymphocytic) leukemia	11
ALS	amyotrophic lateral sclerosis	6, 7
AMA	against medical advice	3
AMB	ambulatory	3
AMD	age-related macular degeneration	8
AMI	acute myocardial infarction	10
AML	acute myeloblastic (myelogenous) leukemia	11
ANS	autonomic nervous system	7
AP	anteroposterior	3
APAP	acetaminophen	3
APC	atrial premature complex; antigen-presenting cell	10, 11
APTT	activated partial thromboplastin time	11
aq	water (Latin, *aqua*)	3
AR	aortic regurgitation	10
ARB	angiotensin receptor blocker	10
ARC	abnormal retinal correspondence	8
ARDS	acute respiratory distress syndrome	12
ARF	acute respiratory failure, shock lung; acute renal failure	12, 14
ART	assisted reproductive technology	16
ASA	acetylsalicylic acid (aspirin)	3
As, AST	astigmatism	8
AS	atrial stenosis; arteriosclerosis	10
ASCVD	arteriosclerotic cardiovascular disease	10
ASD	autism spectrum disorder; atrial septal defect	7, 10
ASF	anterior spinal fusion	5
ASHD	arteriosclerotic heart disease	10

(*continued*)

extern.ir

Abbreviations and Their Meanings (*Continued*)

Abbreviation	Meaning	Chapter
ASHP	American Society of Health System Pharmacists	3
AT	atrial tachycardia	10
ATN	acute tubular necrosis	14
AV	atrioventricular	10
BAEP	brainstem auditory evoked potentials	7, 8
BBB	bundle branch block	10
BC	bone conduction	8
BCG	bacille Calmette–Guérin (tuberculosis vaccine)	12
BE	below the elbow; barium enema (for radiographic study of the colon)	5, 13
bid, b.i.d.	twice a day (Latin, *bis in die)*	3
BK	below the knee	5
BM	bowel movement	13
BMD	bone mineral density	5
BNO	bladder neck obstruction	15
BP	blood pressure	3, 10
BPH	benign prostatic hyperplasia (hypertrophy)	15
bpm	beats per minute	3, 10
BRCA1	breast cancer gene 1	16
BRCA2	breast cancer gene 2	16
BRP	bathroom privileges	3
BS	bowel sounds; breath sounds; blood sugar	3, 9, 12
BSA	body surface area	4
BSE	breast self-examination	16
BSO	bilateral salpingo-oophorectomy	16
BT	bleeding time	11
BUN	blood urea nitrogen	14
BV	bacterial vaginosis	16
bx	biopsy	3
c̄	with	3
C	Celsius (centigrade); compliance; cervical vertebra	3, 5, 12
C-section	cesarean section	16
CA, Ca	cancer	3
CABG	coronary artery bypass graft	10
CAD	coronary artery disease	10
CAM	complementary and alternative medicine	3
cap	capsule	3
CAPD	continuous ambulatory peritoneal dialysis	14
CBC	complete blood count	11
CBD	common bile duct	13
CBF	cerebral blood flow	7
CBR	complete bed rest	3
cc	with correction	8
CC	chief complaint	3
CCPD	continuous cyclic peritoneal dialysis	14
CCU	coronary/cardiac care unit	10
CF	cystic fibrosis	12
CFS	chronic fatigue syndrome	6
CGL	chronic granulocytic leukemia	11
CHD	coronary heart disease	10
CHF	congestive heart failure	10
Ci	Curie (unit of radioactivity)	3
CIN	cervical intraepithelial neoplasia	16
CIS	carcinoma in situ	3
CJD	Creutzfeldt–Jakob disease	7
CK	creatine kinase	6
CK-MB	creatine kinase MB	10
CLL	chronic lymphocytic leukemia	11
cm	centimeter	Appendix 8
CMG	cystometrography, cystometrogram	14
CML	chronic myelogenous leukemia	11
CNS	central nervous system; clinical nurse specialist	7
c/o, CO	complains (complaining) of	3
Co	coccyx; coccygeal	5
CO_2	carbon dioxide	12
COPD	chronic obstructive pulmonary disease	12
CP	cerebral palsy	7
CPAP	continuous positive airway pressure	12
CPD	cephalopelvic disproportion	16
CPR	cardiopulmonary resuscitation	10
CRF	chronic renal failure	14
crit	hematocrit	11
CRP	C-reactive protein	10
C&S	culture and (drug) sensitivity (of bacteria)	3

extern.ir

Abbreviations and Their Meanings (*Continued*)

Abbreviation	Meaning	Chapter
CSF	cerebrospinal fluid	7
CSII	continuous subcutaneous insulin infusion	9
CT	computed tomography	3
CTA	computed tomography angiography	10
CTE	chronic traumatic encephalopathy	7
CTS	carpal tunnel syndrome	6
CVA	cerebrovascular accident	7, 10
CVD	cardiovascular disease; cerebrovascular disease	10
CVI	chronic venous insufficiency	10
CVP	central venous pressure	10
CVS	chorionic villus sampling	16
CXR	chest x-ray	12
D&C	dilatation and curettage	16
DAW	dispense as written	3
dB	decibel	8
dc, D/C	discontinue	3
DCIS	ductal carcinoma in situ	16
D&E	dilation and evacuation	16
DES	diethylstilbestrol	16
DEXA	dual-energy x-ray absorptiometry (scan)	5
DIC	disseminated intravascular coagulation	11
DIFF	differential count	11
DIP	distal interphalangeal	5
DJD	degenerative joint disease	5
dL	deciliter	Appendix 8
DLE	discoid lupus erythematosus	4
DM	diabetes mellitus	9
DNR	do not resuscitate	3
DOE	dyspnea on exertion	10
DTaP	diphtheria, tetanus, acellular pertussis (vaccine)	12
DRE	digital rectal examination	15
DS	double strength	3
DSM	*Diagnostic and Statistical Manual of Mental Disorders*	7
DTR	deep tendon reflexes	7
DUB	dysfunctional uterine bleeding	16
DVT	deep vein thrombosis	10
Dx	diagnosis	3
EBL	estimated blood loss	3
EBV	Epstein–Barr virus	11
ECG (EKG)	electrocardiogram, electrocardiography	10
ECMO	extracorporeal membrane oxygenation	16
ED	emergency department; erectile dysfunction	3, 15
EDC	estimated date of confinement	16
EEG	electroencephalogram; electroencephalograph(y)	7
EGD	esophagogastroduodenoscopy	13
ELISA	enzyme-linked immunosorbent assay	11
elix	elixir	3
Em	emmetropia	8
EMG	electromyography, electromyogram	6
ENG	electronystagmography	8
ENT	ear(s), nose, and throat	8
EOM	extraocular movement, muscles	8
EOMI	extraocular muscles intact	3
EPO, EP	erythropoietin	11, 14
ERCP	endoscopic retrograde cholangiopancreatography	13
ERG	electroretinography	8
ERV	expiratory reserve volume	12
ESR	erythrocyte sedimentation rate	11
ESRD	end-stage renal disease	14
ESWL	extracorporeal shock-wave lithotripsy	14
ET	esotropia	8
ETOH	alcohol, ethyl alcohol	3
F	Fahrenheit	3
FAP	familial adenomatous polyposis	13
FBG	fasting blood glucose	9
FBS	fasting blood sugar	9
FC	finger counting	8
FDA	Food and Drug Administration	3
FEV	forced expiratory volume	12
FFP	fresh frozen plasma	11
FHR	fetal heart rate	16
FHT	fetal heart tone	16
FMS	fibromyalgia syndrome	6
FPG	fasting plasma glucose	9

(*continued*)

extern.ir

Abbreviations and Their Meanings (*Continued*)

Abbreviation	Meaning	Chapter
FRC	functional residual capacity	12
FSH	follicle-stimulating hormone	9, 15, 16
FTI	free thyroxine index	9
FTND	full-term normal delivery	16
FTP	full-term pregnancy	16
FTSG	full-thickness skin graft	4
FUO	fever of unknown origin	3
FVC	forced vital capacity	12
Fx	fracture	5
g	gram	Appendix 8
GA	gestational age	16
GAD	generalized anxiety disorder	7
GC	gonococcus	15, 16
GDM	gestational diabetes mellitus	9
GERD	gastroesophageal reflux disease	13
GFR	glomerular filtration rate	14
GH	growth hormone	9
GI	gastrointestinal	13
GIFT	gamete intrafallopian transfer	16
Gm^+	Gram positive	3
Gm^-	Gram negative	3
GU	genitourinary	14, 15
GYN	gynecology	16
H&P	history and physical examination	3
HAV	hepatitis A virus	13
Hb, Hgb	hemoglobin	11
HbA1c	hemoglobin A1c; glycated hemoglobin	9
HBV	hepatitis B virus	13, 15
hCG	human chorionic gonadotropin	16
HCl	hydrochloric acid	13
Hct, Ht	hematocrit	11
HCV	hepatitis C virus	13
HDL	high-density lipoprotein	10
HDN	hemolytic disease of the newborn	11, 16
HDV	hepatitis D virus	13
HEV	hepatitis E virus	13
HEENT	head, eyes, ears, nose, and throat	3
HIPAA	Health Insurance Portability and Accountability Act	3
HIV	human immunodeficiency virus	11, 15
HL	hearing level	8
HM	hand movements	8
HNP	herniated nucleus pulposus	5
h/o	history of	3
HPI	history of present illness	3
HPS	*Hantavirus* pulmonary syndrome	12
HPV	human papillomavirus	16
HR	heart rate	3
HRT	hormone replacement therapy	16
hs	at bedtime	3
hs-CRP	high sensitivity C-reactive protein (test)	10
HSV	herpes simplex virus	15
Ht, Hct	hematocrit	11
HTN	hypertension	10
Hx	history	3
Hz	Hertz	8
^{131}I	iodine-131 (radioactive iodine)	9
I&D	incision and drainage	3
I&O	intake and output	3
IABP	intra-aortic balloon pump	10
IBD	inflammatory bowel disease	13
IBS	irritable bowel syndrome	13
IC	inspiratory capacity	12
ICD	implantable cardioverter defibrillator	10
ICP	intracranial pressure	7
ICU	intensive care unit	3
ID	intradermal	3
IF	intrinsic factor	11
IFG	impaired fasting blood glucose	9
Ig	immunoglobulin	11
IGRA	interferon gamma release assay (test for TB)	12
IGT	impaired glucose tolerance	9
IM	intramuscular(ly); intramedullary	3, 5
INH	isoniazid (antituberculosis drug)	3, 12
IOL	intraocular lens	8
IOP	intraocular pressure	8
IPPA	inspection, palpation, percussion, auscultation	3, 12
IPPB	intermittent positive pressure breathing	12

extern.ir

Abbreviations and Their Meanings (*Continued*)

Abbreviation	Meaning	Chapter
IPPV	intermittent positive pressure ventilation	12
IRV	inspiratory reserve volume	12
ITP	idiopathic thrombocytopenic purpura	11
IU	international unit	3
IUD	intrauterine device	16
IV	intravenous(ly)	3
IVCD	intraventricular conduction delay	10
IVDA	intravenous drug abuse	3
IVF	in vitro fertilization	16
IVP	intravenous pyelography	14
IVU	intravenous urography	14
JVP	jugular venous pulse	10
K	potassium	14
kg	kilogram	Appendix 8
km	kilometer	Appendix 8
KUB	kidney–ureter–bladder	14
KVO	keep vein open	3
L	lumbar vertebra (numbered L1 to L5); liter	5, Appendix 8
LA	long-acting	3
LAD	left anterior descending (coronary artery)	10
LAHB	left anterior hemiblock	10
LDL	low-density lipoprotein	10
LE	lupus erythematosus	4
LES	lower esophageal sphincter	13
LH	luteinizing hormone	9, 15, 16
LL	left lateral	3
LLE	left lower extremity	6
LLL	left lower lobe (of lung)	12
LLQ	left lower quadrant	2
LMN	lower motor neuron	7
LMP	last menstrual period	16
LOC	level of consciousness	7
LP	lumbar puncture	7
LUE	left upper extremity	6
LUL	left upper lobe (of lung)	12
LUQ	left upper quadrant	2
LV	left ventricle	10
LVAD	left ventricular assist device	10
LVEDP	left ventricular end-diastolic pressure	10
LVH	left ventricular hypertrophy	10
lytes	electrolytes	11
m	meter	Appendix 8
MAOI	monoamine oxidase inhibitor	7
mcg	microgram	3, Appendix 8
MCH	mean corpuscular hemoglobin	11
MCHC	mean corpuscular hemoglobin concentration	11
mcL	microliter	11, Appendix 8
mcm	micrometer (μm)	11, Appendix 8
MCP	metacarpophalangeal	5
MCV	mean corpuscular volume	11
MDR	multidrug resistant	3
MDS	myelodysplastic syndrome	11
MED(s)	medicine(s), medication(s)	3
MEFR	maximal expiratory flow rate	12
MEN	multiple endocrine neoplasia	9
mEq	milliequivalent	11
MET	metastasis	3
mg	milligram	3, Appendix 8
MG	myasthenia gravis	6
MHT	menopausal hormone therapy	16
MI	myocardial infarction	10
MID	multi-infarct dementia	7
mL	milliliter	3, Appendix 8
mm	millimeter	Appendix 8
MMFR	maximum midexpiratory flow rate	12
mm Hg	millimeters of mercury	10
MMT	manual muscle test(ing)	6
MR	mitral regurgitation, reflux	10
MRI	magnetic resonance imaging	3
MRSA	methicillin-resistant *Staphylococcus aureus*	3
MS	multiple sclerosis; mitral stenosis	7, 10
MTP	metatarsophalangeal	5
MTBI	mild traumatic brain injury	7
MUGA	multigated acquisition (scan)	10
MVP	mitral valve prolapse	10
MVR	mitral valve replacement	10

(*continued*)

extern.ir

Abbreviations and Their Meanings (*Continued*)

Abbreviation	Meaning	Chapter
Na	sodium	14
NAA	nucleic acid amplification (test) (for TB)	12
NAD	no apparent distress	3
NB	newborn	16
NCCAM	National Center for Complementary and Alternative Medicine	3
NG	nasogastric	13
NGU	nongonococcal urethritis	15, 16
NHL	non-Hodgkin lymphoma	11
NICU	neonatal intensive care unit; neurologic intensive care unit	7, 16
NKDA	no known drug allergies	3
NMJ	neuromuscular junction	6
NPH	normal pressure hydrocephalus; neutral protamine Hagedorn (insulin)	7, 9
NPO	nothing by mouth (Latin, *non per os*)	3
NRC	normal retinal correspondence	8
NREM	nonrapid eye movement (sleep)	7
NS, N/S	normal saline	3
NSAID(s)	nonsteroidal anti-inflammatory drug(s)	3, 5
NSR	normal sinus rhythm	10
NV	near vision	8
N&V	nausea and vomiting	13
N/V/D	nausea, vomiting, diarrhea	13
O_2	oxygen	12
OA	osteoarthritis	5
OB	obstetrics, obstetrician	16
OCD	obsessive–compulsive disorder	7
ODS	Office of Dietary Supplements	3
OGTT	oral glucose-tolerance test	9
OI	osteogenesis imperfecta	5
OL	otolaryngology	8
OOB	out of bed	3
OM	otitis media	8
OR	operating room	3
ORIF	open reduction internal fixation	5
ORL	otorhinolaryngology	8
ortho, ORTH	orthopedics	5
OT	occupational therapy/therapist	6
OTC	over-the-counter	3
p	after, post	3
P	pulse	3, 10
PA	posteroanterior; physician assistant	3
PAC	premature atrial contraction	10
$PaCO_2$	arterial partial pressure of carbon dioxide	12
PACU	postanesthesia care unit	3
PaO_2	arterial partial pressure of oxygen	12
PAP	pulmonary arterial pressure	10
pc	after meals (Latin, *post cibum*)	3
PCA	patient-controlled analgesia	3
PCI	percutaneous coronary intervention	10
PCL	posterior cruciate ligament	5
PCOS	polycystic ovarian syndrome	16
PCP	*Pneumocystis* pneumonia	12
PCV	packed cell volume	11
PCWP	pulmonary capillary wedge pressure	10
PDA	patent ductus arteriosus	16
PDD	pervasive developmental disorder	7
PDR	*Physicians' Desk Reference*	3
PE	physical examination	3
PEEP	positive end-expiratory pressure	12
PEFR	peak expiratory flow rate	12
PEG	percutaneous endoscopic gastrostomy (tube)	13
PEP	protein electrophoresis	14
PE(R)RLA	pupils equal, (regular) react to light and accommodation	3
PET	positron emission tomography	3, 7
PFT	pulmonary function test(s)	12
pH	scale for measuring hydrogen ion concentration (acidity or alkalinity)	11
Ph	Philadelphia chromosome	11
PICC	peripherally inserted central catheter	3
PID	pelvic inflammatory disease	16
PIH	pregnancy-induced hypertension	16
PIP	proximal interphalangeal (joint); peak inspiratory pressure	5, 12

extern.ir

Abbreviations and Their Meanings (*Continued*)

Abbreviation	Meaning	Chapter
PKU	phenylketonuria	16
PMH	past medical history	3
PMI	point of maximal impulse	10
PMN	polymorphonuclear (neutrophil)	11
PMS	premenstrual syndrome	16
PND	paroxysmal nocturnal dyspnea	12
PNS	peripheral nervous system	7
po, PO	by mouth (Latin, *per os*)	3
poly, polymorph	neutrophil	11
PONV	postoperative nausea and vomiting	13
postop, post-op	postoperative	3
pp	postprandial (after a meal)	3
PPD	purified protein derivative (tuberculin)	12
PPI	proton pump inhibitor	13
preop, pre-op	preoperative	3
PRL	prolactin	9
prn	as needed	3
PSA	prostate-specific antigen	15
PSF	posterior spinal fusion	5
PSS	physiologic saline solution; progressive systemic sclerosis	3, 4
PSVT	paroxysmal supraventricular tachycardia	10
pt	patient	3
PT	physical therapy/therapist	5
PT, ProTime	prothrombin time; pro time	11
PTCA	percutaneous transluminal coronary angioplasty	10
PTH	parathyroid hormone	9
PTSD	posttraumatic stress disorder	7
PTT	partial thromboplastin time	11
PUVA	psoralen ultraviolet A	4
PVC	premature ventricular contraction	10
PVD	peripheral vascular disease	10
PYP	pyrophosphate (scan)	10
qam	every morning (Latin, *quaque ante meridiem*)	3
qh	every hour (Latin, *quaque hora*)	3
q __ h	every __ hours	3
qid, q.i.d.	four times a day (Latin, *quater in die*)	3
QNS	quantity not sufficient	3
QS	quantity sufficient	3
R	respiration	3, 12
RA	rheumatoid arthritis	5
RAIU	radioactive iodine uptake	9
RAS	reticular activating system	7
RATx	radiation therapy	3
RBC	red blood cell; red blood (cell) count	11
RDS	respiratory distress syndrome	12
REM	rapid eye movement (sleep)	7
RIA	radioimmunoassay	9
RICE	rest, ice, compression, elevation	6
RL	right lateral	3
RLE	right lower extremity	6
RLL	right lower lobe (of lung)	12
RLQ	right lower quadrant	2
RLS	restless legs syndrome	6
RML	right middle lobe (of lung)	12
R/O	rule out	3
ROM	range of motion	6
ROS	review of systems	3
RSI	repetitive strain injury	6
RSV	respiratory syncytial virus	12
RTC	rotator cuff	6
RUE	right upper extremity	6
RUL	right upper lobe (of lung)	12
RUQ	right upper quadrant	2
RV	residual volume	12
Rx	drug, prescription, therapy	3
s̄	without	3
S	sacrum; sacral	5
S_1	first heart sound	10
S_2	second heart sound	10
SA	sustained action; sinoatrial	3, 10
SARS	severe acute respiratory syndrome	12
SBE	subacute bacterial endocarditis	10
sc	without correction	8
SC, SQ, subcut.	subcutaneous(ly)	3
SCLE	subacute cutaneous lupus erythematosus	4
seg	neutrophil	11
SERM	selective estrogen receptor modulator	5, 16

(*continued*)

extern.ir

Abbreviations and Their Meanings (*Continued*)

Abbreviation	Meaning	Chapter
SG	specific gravity	14
SIADH	syndrome of inappropriate antidiuretic hormone (secretion)	9
SIDS	sudden infant death syndrome	12
SITS	supraspinatus, infraspinatus, teres minor, subscapularis (muscles)	6
SK	streptokinase	10
SL	sublingual	3
SLE	systemic lupus erythematosus	4, 11
SPECT	single-photon emission computed tomography	3
SPF	sun protection factor	4
SpO_2	oxygen percent saturation	12
SR	sustained release	3
$\overline{ss}$	half (Latin, *semis*)	3
SSEP	somatosensory evoked potentials	7
SSRI	selective serotonin reuptake inhibitor	7
ST	speech threshold	8
staph	staphylococcus	3
STAT	immediately	3
STD	sexually transmitted disease	15, 16
STI	sexually transmitted infection	15, 16
strep	streptococcus	3
STSG	split-thickness skin graft	4
supp	suppository	3
susp	suspension	3
SVD	spontaneous vaginal delivery	16
SVT	supraventricular tachycardia	10
T	temperature; thoracic vertebra (numbered T1 to T12)	3, 5
T1DM	type 1 diabetes mellitus	9
T2DM	type 2 diabetes mellitus	9
T_3	triiodothyronine	9
T_4	thyroxine; tetraiodothyronine	9
T_7	free thyroxine index	9
T&A	tonsils and adenoids; tonsillectomy and adenoidectomy	12
tab	tablet	3
TAH	total abdominal hysterectomy	16
TB	tuberculosis	12
TBG	thyroxine-binding globulin	9
TBI	traumatic brain injury; thrombolytic brain infarction	7
^{99m}Tc	technetium-99m	10
TCA	tricyclic antidepressant	7
TEE	transesophageal echocardiography	10
TGV	thoracic gas volume	12
THA	total hip arthroplasty	5
THP	total hip precautions	5
THR	total hip replacement	5
TIA	transient ischemic attack	7
tid, t.i.d.	three times per day (Latin, *ter in die*)	3
tinct	tincture	3
TKA	total knee arthroplasty	5
TKO	to keep open	3
TLC	total lung capacity	12
Tm	maximal transport capacity; tubular maximum	14
TM	tympanic membrane	8
Tn	troponin	10
TNM	(primary) tumor, (regional lymph) nodes, (distant) metastases	3
TMJ	temporomandibular joint	5
tPA	tissue plasminogen activator	10
TPN	total parenteral nutrition	13
TPR	temperature, pulse, respiration	3
TPUR	transperineal urethral resection	15
TSE	testicular self-examination	15
TSH	thyroid-stimulating hormone	9
TSS	toxic shock syndrome	16
T(C)T	thrombin (clotting) time	11
TTP	thrombotic thrombocytopenic purpura	11
TTS	temporary threshold shift	8
TUIP	transurethral incision of prostate	15
TURP	transurethral resection of prostate	15
TV	tidal volume	12
Tx	traction	5
U	units	3
UA	urinalysis	14
UC	uterine contractions	16
UFE	uterine fibroid embolization	16

extern.ir

Abbreviations and Their Meanings (*Continued*)

Abbreviation	Meaning	Chapter
UG	urogenital	15
UGI	upper gastrointestinal	13
UMN	upper motor neuron	7
ung	ointment	3
URI	upper respiratory infection	12
USP	*United States Pharmacopeia*	3
UTI	urinary tract infection	14, 15
UTP	uterine term pregnancy	16
UV	ultraviolet	3, 4
UVA	ultraviolet A	4
UVB	ultraviolet B	4
VA	visual acuity	8
VAC	vacuum-assisted closure	4
VAD	ventricular assist device	10
VBAC	vaginal birth after cesarean section	16
VC	vital capacity	12
VD	venereal disease	15, 16
VDRL	Venereal Disease Research Laboratory	15
VEP	visual evoked potentials	7
VF	visual field	8
VF, v fib	ventricular fibrillation	10
VLDL	very low density lipoprotein	10
VPC	ventricular premature complex	10
VRSA	vancomycin-resistant *Staphylococcus aureus*	3
VS	vital signs	3
VSD	ventricular septal defect	10
VT	ventricular tachycardia	10
VTE	venous thromboembolism	10
V_{TG}	thoracic gas volume	12
vWF	von Willebrand factor	11
WBC	white blood cell; white blood (cell) count	11
WD	well developed	3
WNL	within normal limits	3
w/o	without	3
WPW	Wolff–Parkinson–White syndrome	10
x	times	3
XT	exotropia	8
y/o, YO	years old, year-old	3
ZIFT	zygote intrafallopian transfer	16

extern.ir

Appendix 3
Word Parts and Their Meanings

Word Parts and Their Meanings

Word Part	Meaning	Reference Page
a-	not, without, lack of, absence	21
ab-	away from	22
abdomin/o	abdomen	52
-ac	pertaining to	13
acous, acus	sound, hearing	264
acro-	extremity, end	58
ad-	toward, near	22
aden/o	gland	47
adip/o	fat	50
adren/o	adrenal gland, epinephrine	299
adrenal/o	adrenal gland	299
adrenocortic/o	adrenal cortex	299
aer/o	air, gas	98
-agogue	promoter, stimulator	534
-al	pertaining to	13
alg/o, algi/o, algesi/o	pain	82, 112
-algesia	pain	84, 261
-algia	pain	84
ambly-	dim	280
amnio	amnion	534
amyl/o	starch	50
an-	not, without, lack of, absence	21
andr/o	male	493
angi/o	vessel	326
an/o	anus	430
ante-	before	25
anti-	against	21, 112
aort/o	aorta	327
-ar	pertaining to	13
arter/o, arteri/o	artery	327
arteriol/o	arteriole	327
arthr/o	joint	158
-ary	pertaining to	13

Word Part	Meaning	Reference Page
-ase	enzyme	50
atel/o	imperfect	408
atlant/o	atlas	156
atri/o	atrium	324
audi/o	hearing	264
auto-	self	239
azot/o	nitrogenous compounds	369
bacill/i, bacill/o	bacillus	86
bacteri/o	bacterium	86
balan/o	glans penis	500
bar/o	pressure	98
bi-	two, twice	18
bili	bile	435
bio	life	45
blast/o, -blast	immature cell, productive cell, embryonic cell	49
blephar/o	eyelid	273
brachi/o	arm	58
brachy-	short	501
brady-	slow	83
bronch/o, bronch/i	bronchus	399
bronchiol	bronchiole	399
bucc/o	cheek	432
burs/o	bursa	158
calc/i	calcium	369
cali/o, calic/o	calyx	466
-capnia	carbon dioxide (level of)	398
carcin/o	cancer, carcinoma	82
cardi/o	heart	326
cec/o	cecum	434
-cele	hernia, localized dilation	84
celi/o	abdomen	57
centesis	puncture, tap	100
cephal/o	head	57
cerebell/o	cerebellum	228

extern.ir

Word Parts and Their Meanings (*Continued*)

Word Part	Meaning	Reference Page
cerebr/o	cerebrum	228
cervic/o	neck, cervix	57, 520
chem/o	chemical	112
cheil/o	lip	446
chir/o	hand	97
cholangi/o	bile duct	435
chol/e, chol/o	bile, gall	435
cholecyst/o	gallbladder	435
choledoch/o	common bile duct	435
chondr/o	cartilage	158
chori/o, choroid/o	choroid	274
chrom/o, chromat/o	color, stain	98
chron/o	time	98
circum-	around	59
clasis, -clasia	breaking	84
clitor/o, clitorid/o	clitoris	521
coccy, coccyg/o	coccyx	159
cochle/o	cochlea (of inner ear)	265
col/o, colon/o	colon	434
colp/o	vagina	520
contra-	against, opposite, opposed	21, 112
copro	feces	230
cor/o, cor/e	pupil	280
corne/o	cornea	274
cortic/o	outer portion, cerebral cortex	228
cost/o	rib	159
counter-	against, opposite, opposed	112
crani/o	skull, cranium	159
cry/o	cold	98
crypt/o	hidden	498
cus	sound, hearing	264
cyan/o-	blue	20
cycl/o	ciliary body, ciliary muscle (of eye)	274
cyst/o	filled sac or pouch, cyst, bladder, urinary bladder	82
-cyte, cyt/o	cell	47
dacry/o	tear, lacrimal apparatus	273
dacryocyst/o	lacrimal sac	273
dactyl/o	finger, toe	58
de-	down, without, removal, loss	21
dent/o, dent/i	tooth, teeth	432
derm/o, dermat/o	skin	129
-desis	binding, fusion	100
dextr/o-	right	26
di-	two, twice	18
dia-	through	22
dilation, dilatation	expansion, widening	85
dipl/o-	double	18
dis-	absence, removal, separation	21
duoden/o	duodenum	433
dynam/o	force, energy	203
dys-	abnormal, painful, difficult	83
ec-	out, outside	26
ectasia, ectasis	dilation, dilatation, distention	85
ecto-	out, outside	26
-ectomy	excision, surgical removal	100
edema	accumulation of fluid, swelling	85
electr/o	electricity	98
embry/o	embryo	534
emesis	vomiting	443
-emia	condition of blood	367
encephal/o	brain	228
end/o-	in, within	26
endocrin/o	endocrine	299
enter/o	intestine	433
epi-	on, over	59
epididym/o	epididymis	494
episi/o	vulva	521
equi-	equal, same	24
erg/o	work	98, 197
erythr/o-	red, red blood cell	20
erythrocyt/o	red blood cell	368
esophag/o	esophagus	433
-esthesia, -esthesi/o	sensation	261, 271
eu-	true, good, easy, normal	24
ex/o-	away from, outside	26
extra-	outside	59
fasci/o	fascia	197
fer	to carry	225
ferr/i, ferr/o	iron	369

(*continued*)

extern.ir

Word Parts and Their Meanings (*Continued*)

Word Part	Meaning	Reference Page
fet/o	fetus	534
fibr/o	fiber	47
-form	like, resembling	13
galact/o	milk	534
gangli/o, ganglion/o	ganglion	227
gastr/o	stomach	433
gen, genesis	origin, formation	49
ger/e, ger/o	old age	12
-geusia	sense of taste	261
gingiv/o	gum, gingiva	432
gli/o	neuroglia	227
glomerul/o	glomerulus	466
gloss/o	tongue	432
gluc/o	glucose	50
glyc/o	sugar, glucose	50
gnath/o	jaw	50
goni/o	angle	172, 281
-gram	record of data	99
-graph	instrument for recording data	99
-graphy	act of recording data	99
gravida	pregnant woman	534
gyn/o, gynec/o	woman	518
hem/o, hemat/o	blood	368
hemi-	half, one side	18
-hemia	condition of blood	367
hepat/o	liver	435
hetero-	other, different, unequal	24
hidr/o	sweat, perspiration	129
hist/o, histi/o	tissue	47
homo-, homeo-	same, unchanging	24
hydr/o	water, fluid	50
hyper-	over, excess, increased, abnormally high	23
hypn/o	sleep	112
hypo-	under, below, decreased, abnormally low	23
hypophysi/o	pituitary, hypophysis	299
hyster/o	uterus	520
-ia	condition of	10
-ian	specialist	11
-ia/sis	condition of	10
-iatrics	medical specialty	11
-iatr/o	physician	9
-iatry	medical specialty	11
-ic	pertaining to	13
-ical	pertaining to	13
-ics	medical specialty	11
-ile	pertaining to	13
ile/o	ileum	434
ili/o	ilium	159
im-	not	21
immun/o	immunity, immune system	368
in-	not	21
infra-	below	59
in/o	fiber, muscle fiber	197
insul/o	pancreatic islets	299
inter-	between	59
intra-	in, within	59
ir, irit/o, irid/o	iris	274
-ism	condition of	10
iso-	equal, same	24
-ist	specialist	11
-itis	inflammation	84
jejun/o	jejunum	433
juxta-	near, beside	59
kali	potassium	369
kary/o	nucleus	47
kerat/o	cornea, keratin, horny layer of skin	129, 274
kin/o, kine, kinesi/o, kinet/o	movement	197
labi/o	lip	432
labyrinth/o	labyrinth (inner ear)	465
lacrim/o	tear, lacrimal apparatus	273
lact/o	milk	534
-lalia	speech, babble	230
lapar/o	abdominal wall	57
laryng/o	larynx	399
lent/i	lens	274
-lepsy	seizure	230
leuk/o-	white, colorless, white blood cell	20
leukocyt/o	white blood cell	368
-lexia	reading	230

extern.ir

Word Parts and Their Meanings (*Continued*)

Word Part	Meaning	Reference Page
lingu/o	tongue	432
lip/o	fat, lipid	50
-listhesis	slipping	169
lith	calculus, stone	82
-logy	study of	11
lumb/o	lumbar region, lower back	57
lymphaden/o	lymph node	340
lymphangi/o	lymphatic vessel	340
lymph/o	lymph, lymphatic system, lymphocyte	340
lymphocyt/o	lymphocyte	368
-lysis	separation, loosening, dissolving, destruction	85
-lytic	dissolving, reducing, loosening	112
macro-	large, abnormally large	24
mal-	bad, poor	83
malacia	softening	85
mamm/o	breast, mammary gland	521
-mania	excited state, obsession	230
mast/o	breast, mammary gland	521
medull/o	inner part, medulla oblongata, spinal cord	228
mega-, megal/o-	large, abnormally large	24
-megaly	enlargement	84
melan/o-	black, dark, melanin	20
mening/o, meninge/o	meninges	227
men/o, mens	month, menstruation	518
mes/o-	middle	26
met/a	change, after, beyond	81
-meter	instrument for measuring	99
metr/o	measure	99, 276
metr/o, metr/i	uterus	520
-metry	measurement of	99
micro-	small, one millionth	24
-mimetic	mimicking, simulating	112
mon/o-	one	18
morph/o	form, structure	47
muc/o	mucus, mucous membrane	47
multi-	many	18
muscul/o	muscle	197
myc/o	fungus, mold	86
myel/o	bone marrow, spinal cord	158, 227, 368
my/o	muscle	197
myring/o	tympanic membrane	264
myx/o	mucus	47
narc/o	stupor, unconsciousness	112, 228
nas/o	nose	399
nat/i	birth	534
natri	sodium	369
necrosis	death of tissue	85
neo-	new	24
nephr/o	kidney	466
neur/o, neur/i	nervous system, nerve	227
noct/i	night	102
non-	not	21
normo-	normal	24
nucle/o	nucleus	47
nulli-	never	534
nyct/o	night, darkness	280
ocul/o	eye	274
odont/o	tooth, teeth	432
-odynia	pain	84
-oid	like, resembling	13
olig/o-	few, scanty, deficiency of	23
-oma	tumor	84
onc/o	tumor	82
onych/o	nail	129
oo	ovum	518
oophor/o	ovary	518
ophthalm/o	eye	274
-opia	condition of the eye, vision	276
-opsia	condition of vision	276
opt/o	eye, vision	274
orchid/o, orchi/o	testis	494
or/o	mouth	432
ortho-	straight, correct, upright	24
-ory	pertaining to	13
osche/o	scrotum	494
-ose	sugar	50
-o/sis	condition of	10
osm/o	smell	261
-osmia	sense of smell	261

(*continued*)

extern.ir

Word Parts and Their Meanings (*Continued*)

Word Part	Meaning	Reference Page
oste/o	bone	158
ot/o	ear	264
-ous	pertaining to	13
ovari/o	ovary	519
ov/o, ovul/o	ovum	519
-oxia	oxygen (level of)	398
ox/y	oxygen, sharp, acute	369
pachy-	thick	83
palat/o	palate	432
palpebr/o	eyelid	273
pan-	all	23
pancreat/o	pancreas	435
papill/o	nipple	47
para-	near, beside, abnormal	59
para	woman who has given birth	534
parathyr/o, parathyroid/o	parathyroid	299
-paresis	partial paralysis, weakness	230
path/o, -pathy	disease, any disease of	82, 84
ped/o	foot, child	58
pelvi/o	pelvis	159
-penia	decrease in, deficiency of	367
per-	through	22
peri-	around	59
perine/o	perineum	521
periton, peritone/o	peritoneum	57
-pexy	surgical fixation	100
phac/o, phak/o	lens	274
phag/o	eat, ingest	49
pharm, pharmac/o	drug, medicine	112
pharyng/o	pharynx	399
-phasia	speech	230
phil, -philic	attracting, absorbing	49
phleb/o	vein	327
-phobia	fear	230
phon/o	sound, voice	98
-phonia	voice	398
phot/o	light	98
phren/o	diaphragm	400
phrenic/o	phrenic nerve	400
phyt/o	plant	107, 137
pituitar/i	pituitary, hypophysis	299
plas, -plasia	formation, molding, development	49
-plasty	plastic repair, plastic surgery, reconstruction	100
-plegia	paralysis	230
pleur/o	pleura	400
-pnea	breathing	398
pneum/o, pneumat/o	air, gas, lung, respiration	400
pneumon/o	lung	400
pod/o	foot	58
-poiesis	formation, production	367
poikilo-	varied, irregular	24
poly-	many, much	18
post-	after, behind	25
pre-	before, in front of	25
presby-	old	271
prim/i-	first	18
pro-	before, in front of	25
proct/o	rectum	434
prostat/o	prostate	494
prote/o	protein	50
pseudo-	false	24
psych/o	mind	228
ptosis	dropping, downward displacement, prolapse	85
ptysis	spitting	408
puer	child	542
pulm/o, pulmon/o	lung	400
pupill/o	pupil	274
pyel/o	renal pelvis	466
pylor/o	pylorus	433
py/o	pus	82
pyr/o, pyret/o	fever, fire	82
quadr/i-	four	18
rachi/o	spine	159
radicul/o	root of spinal nerve	227
radi/o	radiation, x-ray	98
re-	again, back	24
rect/o	rectum	434
ren/o	kidney	466
reticul/o	network	47
retin/o	retina	274

extern.ir

Word Parts and Their Meanings (*Continued*)

Word Part	Meaning	Reference Page
retro-	behind, backward	59
rhabd/o	rod, muscle cell	203
-rhage, -rhagia	bursting forth, profuse flow, hemorrhage	84
-rhaphy	surgical repair, suture	100
-rhea	flow, discharge	84
-rhexis	rupture	84
rhin/o	nose	399
sacchar/o	sugar	50
sacr/o	sacrum	159
salping/o	tube, uterine tube, auditory (eustachian) tube	264, 520
-schisis	fissure, splitting	84
scler/o	hard, sclera (of eye)	82, 274
sclerosis	hardening	85
-scope	instrument for viewing or examining	99
-scopy	examination of	99
seb/o	sebum, sebaceous gland	129
semi-	half, partial	18
semin	semen	494
sept/o	septum, dividing wall, partition	410
sial/o	saliva, salivary gland, salivary duct	432
sider/o	iron	369
sigmoid/o	sigmoid colon	434
sinistr/o	left	26
-sis	condition of	10
skelet/o	skeleton	157
somat/o	body	47
-some	body, small body	47
somn/i, somn/o	sleep	228
son/o	sound, ultrasound	98
spasm	sudden contraction, cramp	85
sperm/i	semen, spermatozoa	494
spermat/o	semen, spermatozoa	494
-spermia	condition of semen	495
sphygm/o	pulse	325
spir/o	breathing	400
splen/o	spleen	340
spondyl/o	vertebra	159
staped/o, stapedi/o	stapes	264
staphyl/o	grape-like cluster, *Staphylococcus*	86
stasis	suppression, stoppage	85
steat/o	fatty	50
stenosis	narrowing, constriction	85
steth/o	chest	97
sthen/o	strength	202
stoma, stomat/o	mouth	432
-stomy	surgical creation of an opening	100
strept/o-	twisted chain, *Streptococcus*	86
sub-	below, under	59
super-	above, excess	23
supra-	above	59
syn-, sym-	together	26
synov/i	synovial joint, synovial membrane	158
tachy-	rapid	83
tax/o	order, arrangement	202
tel/e-, tel/o-	end, far, at a distance	26
ten/o, tendin/o	tendon	197
terat/o	malformed fetus	540
test/o	testis, testicle	494
tetra-	four	18
thalam/o	thalamus	428
therm/o	heat, temperature	98
thorac/o	chest, thorax	58
thromb/o	blood clot	368
thrombocyt/o	platelet, thrombocyte	368
thym/o	thymus gland	340
thyr/o, thyroid/o	thyroid	299
toc/o	labor	534
-tome	instrument for incising (cutting)	100
-tomy	incision, cutting	100
ton/o	tone	197
tonsil/o	tonsil	340
tox/o, toxic/o	poison, toxin	82, 112
toxin	poison	85
trache/o	trachea	399
trans-	through	22
tri-	three	18

(*continued*)

extern.ir

Word Parts and Their Meanings (*Continued*)

Word Part	Meaning	Reference Page
trich/o	hair	129
-tripsy	crushing	100
trop/o	turning	281
trop, -tropic	act(ing) on, affect(ing)	49, 112
troph/o, -trophy, -trophia	feeding, growth, nourishment	49
tympan/o	tympanic cavity (middle ear), tympanic membrane	264
un-	not	21
uni-	one	18
-uresis	urination	468
ureter/o	ureter	467
urethr/o	urethra	467
-uria	condition of urine, urination	468
ur/o	urine, urinary tract	467
urin/o	urine	467
uter/o	uterus	520
uve/o	uvea (of eye)	274
uvul/o	uvula	432
vagin/o	sheath, vagina	520
valv/o, valvul/o	valve	326
varic/o	twisted and swollen vein, varix	336
vascul/o	vessel	327
vas/o	vessel, duct, vas deferens	85, 112, 327, 494
ven/o, ven/i	vein	327
ventricul/o	cavity, ventricle	228, 326
vertebr/o	vertebra, spinal column	159
vesic/o	urinary bladder	467
vesicul/o	seminal vesicle	494
vestibul/o	vestibule, vestibular apparatus (of ear)	467
vir/o	virus	86
vulv/o	vulva	521
xanth/o-	yellow	20
xen/o	foreign, strange	235
xer/o-	dry	83
-y	condition of	10

extern.ir

Appendix 4
Meanings and Their Corresponding Word Parts

Meanings and Their Corresponding Word Parts

Meaning	Word Part(s)	Reference Page
abdomen	abdomin/o, celi/o	57
abdominal wall	lapar/o	57
abnormal	dys-, para-	59, 83
abnormally high	hyper-	23
abnormally large	macro-, mega-, megal/o-	24
abnormally low	hypo-	23
above	super-, supra-	23, 59
absence	a-, an-, dis-	21
absorb(ing)	phil, -philic	49
accumulation of fluid	edema	85
act of recording data	-graphy	99
act(ing) on	trop, -tropic	112
acute	ox/y	369
adrenal gland	adren/o, adrenal/o	299
adrenaline	adren/o	299
adrenal	adren/o	299
adrenal cortex	adrenocortic/o	299
affect(ing)	trop, -tropic	49
after	post-, met/a	26, 81
again	re-	24
against	anti-, contra-, counter-	112
air	aer/o, pneumat/o	98, 400
all	pan-	23
amnion, amniotic sac	amnio	534
angle	goni/o	172
anus	an/o	434
any disease of	-pathy	84
aorta	aort/o	327
arm	brachi/o	58
around	circum-, peri-	59
arrangement	tax/o	202
arteriole	arteriol/o	327
artery	arter/o, arteri/o	327
at a distance	tel/e, tel/o	26
atlas	atlant/o	156
atrium	atri/o	326
attract(ing)	phil, -philic	49
auditory (eustachian) tube	salping/o	264, 520
away from	ab-, ex/o-	22, 26
babble	-lalia	230
bacillus	bacill/i, bacill/o	86
back	re-	24
backward	retro-	59
bacterium	bacteri/o	86
bad	mal-	83
before	ante-, pre-, pro-	25
behind	post-, retro-	25, 49
below	hypo-, infra-, sub-	23, 59
beside	para-, juxta-	59
between	inter-	59
beyond	met/a	81
bile	bili, chol/e, chol/o	435
bile duct	cholangi/o	435
binding	-desis	100
birth	nat/i	534
black	melan/o-	20
bladder	cyst/o	82
bladder (urinary)	cyst/o, vesic/o	82, 467
blood	hem/o, hemat/o	368
blood (condition of)	-emia, -hemia	367
blood clot	thromb/o	368
blue	cyan/o-	20
body	somat/o, -some	47
bone	oste/o	158

(*continued*)

extern.ir

Meanings and Their Corresponding Word Parts (*Continued*)

Meaning	Word Part(s)	Reference Page
bone marrow	myel/o	158, 227, 368
brain	encephal/o	228
breaking	-clasis, -clasia	84
breast	mamm/o, mast/o	521
breathing	-pnea, spir/o	398, 400
bronchiole	bronchiol	399
bronchus	bronch/i, bronch/o	399
bursa	burs/o	158
bursting forth	-rhage, -rhagia	84
calcium	calc/i	369
calculus	lith	82
calyx	cali/o, calic/o	466
cancer	carcin/o	82
carbon dioxide	-capnia	398
carcinoma	carcin/o	82
carry	fer	225
cartilage	chondr/o	158
cavity	ventricul/o	228, 326
cecum	cec/o	434
cell	-cyte, cyt/o	47
cerebellum	cerebell/o	228
cerebral cortex	cortic/o	228
cerebrum	cerebr/o	228
cervix	cervic/o	520
chain (twisted)	strept/o	86
change	met/a	81
cheek	bucc/o	432
chemical	chem/o	112
chest	thorac/o, steth/o	57, 271
child	ped/o, puer	542
choroid	chori/o, choroid/o	274
ciliary body	cycl/o	274
ciliary muscle	cycl/o	274
clitoris	clitor/o, clitorid/o	521
clot	thromb/o	368
coccyx	coccy, coccyg/o	159
cochlea	cochle/o	265
cold	cry/o	98
colon	col/o, colon/o	434
color	chrom/o, chromat/o	98
colorless	leuk/o-	20
common bile duct	choledoch/o	435
condition of	-ia, -ia/sis, -ism, -o/sis, -sis, -y	10
condition of blood	-emia, -hemia	367
condition of the eye	-opia	276
condition of urine, urination	-uria	468
condition of vision	-opia, -opsia	476
condition of semen	-spermia	495
constriction	stenosis	85
contraction (sudden)	spasm	85
cornea	corne/o, kerat/o	274
correct	ortho-	24
cramp	spasm	85
cranium	crani/o	159
crushing	-tripsy	100
cutting	-tomy	100
cutting instrument	-tome	100
cyst	cyst/o	82
dark	melan/o-	20
darkness	nyct/o	102
data	-gram	99
death of tissue	necrosis	85
decreased, decrease in	hypo-, -penia	23, 367
deficiency of	oligo-, -penia	23, 367
destruction	lysis	85
development	plas, -plasia	49
diaphragm	phren/o	400
different	hetero-	24
difficult	dys-	83
dilatation, dilation	ectasia, ectasis	85
dim	ambly-	280
discharge	-rhea	84
disease	path/o, -pathy	82
dissolving	lysis, -lytic	85, 112
distance (at a)	tel/e, tel/o	26
distention	ectasia, ectasis	85
double	dipl/o-	18
down	de-	21
dropping, downward displacement	ptosis	85

extern.ir

Meanings and Their Corresponding Word Parts (*Continued*)

Meaning	Word Part(s)	Reference Page
drug	pharm, pharmac/o	112
dry	xer/o-	83
duct	vas/o	112
ductus deferens	vas/o	494
duodenum	duoden/o	433
ear	ot/o	264
easy	eu-	24
eat	phag/o	49
egg cell	oo, ov/o, ovul/o	519
electricity	electr/o	98
embryo	embry/o	534
embryonic cell	-blast, blast/o	49
end	tel/e, tel/o, acro	26, 58
endocrine	endocrin/o	299
energy	dynam/o	203
enlargement	-megaly, megal/o	84
enzyme	-ase	50
epididymis	epididym/o	494
epinephrine	adren/o	299
equal	iso-, equi-	24
erythrocyte	erythr/o, erythrocyt/o	368
esophagus	esophag/o	433
eustachian (auditory) tube	salping/o	264, 520
examination of	-scopy	99
excess	hyper-, super-	23
excision	-ectomy	100
excited state	mania	230
expansion	dilation, dilatation, ectasia, ectasis	85
extremity	acro	58
eye	ocul/o, ophthalm/o, opt/o, -opia	274, 276
eyelid	blephar/o, palpebr/o	273
fallopian tube	salping/o	264, 520
false	pseudo-	24
far	tel/e, tel/o	26
fascia	fasci/o	197
fat	adip/o, lip/o	50
fatty	steat/o	50
fear	-phobia	230
feces	copro	230
feeding	troph/o, -trophy, -trophia	49
fetus	fet/o	534
fetus (malformed)	terat/o	540
fever	pyr/o, pyret/o	82, 112
few	oligo-	23
fiber	fibr/o, in/o	47, 197
filled sac or pouch	cyst/o	82
finger	dactyl/o	58
fire	pyr/o, pyret/o	82
first	prim/i-	18
fissure	-schisis	84
fixation (surgical)	-pexy	100
flow	-rhea	84
fluid	hydr/o	50
foot	ped/o, pod/o	58
foreign	xen/o	235
form	morph/o	47
formation	gen, genesis, plas, -plasia, -poiesis	49, 367
force	dynam/o	203
four	quadr/i, tetra-	18
fungus	myc/o	86
fusion	-desis	100
gall	chol/e, chol/o	435
gallbladder	cholecyst/o	435
ganglion	gangli/o, ganglion/o	227
gas	aer/o, pneum/o, pneumon/o, pneumat/o	98, 400
gingiva (gum)	gingiv/o	432
gland	aden/o	47
glans penis	balan/o	500
glomerulus	glomerul/o	466
glucose	gluc/o, glyc/o	50
good	eu-	24
grape-like cluster	staphyl/o	86
growth	troph/o, -trophy, -trophia	49
gum, gingiva	gingiv/o	432
hair	trich/o	129
half	hemi-, semi-	18
hand	chir/o	97
hard	scler/o	82
hardening	sclerosis	85
head	cephal/o	57

(*continued*)

extern.ir

Meanings and Their Corresponding Word Parts (*Continued*)

Meaning	Word Part(s)	Reference Page
hearing	acous, acus, audi/o, cus	264
heart	cardi/o	326
heat	therm/o	98
hemorrhage	-rhage, -rhagia	84
hernia	-cele	84
hidden	crypt/o	498
horny layer of skin	kerat/o	129
hypophysis	hypophysi/o, pituitar/i	299
islets (pancreatic)	insul/o	299
ileum	ile/o	434
ilium	ili/o	159
immature cell	blast/o, -blast	49
immune system	immun/o	368
immunity	immun/o	368
imperfect	atel/o	408
in	end/o-, intra-	26, 59
in front of	pre-, pro-	25
incision of	-tomy	100
increased	hyper-	23
inflammation	-itis	84
ingest	phag/o	49
inner ear	labyrinth/o	265
instrument for incising (cutting)	-tome	100
instrument for measuring	-meter	99
instrument for recording data	-graph	99
instrument for viewing or examining	-scope	99
intestine	enter/o	433
iris	ir, irid/o, irit/o	274
iron	ferr/i, ferr/o, sider/o	369
irregular	poikilo-	24
jaw	gnath/o	432
jejunum	jejun/o	433
joint	arthr/o	158
keratin	kerat/o	129
kidney	nephr/o, ren/o	466
labor	toc/o	534
labyrinth	labyrinth/o	265
lack of	a-, an-	21
lacrimal apparatus	dacry/o, lacrim/o	273
lacrimal sac	dacryocyst/o	273
large	macro-, mega-, megal/o-	24
larynx	laryng/o	399
left	sinistr/o	26
lens	lent/i, phac/o, phak/o	274
leukocyte	leuk/o, leukocyt/o	368
level of carbon dioxide	-capnia	398
level of oxygen	-oxia	398
life	bio	45
light	phot/o	98
like	-form, -oid	13
lip	labi/o, cheil/o	432, 446
lipid	lip/o	50
liver	hepat/o	435
localized dilation	-cele	84
loosening	lysis, -lytic	85, 112
loss	de-	21
lumbar region, lower back	lumb/o	57
lung, lungs	pneum/o, pneumat/o, pneumon/o, pulm/o, pulmon/o	400
lymph, lymphatic system	lymph/o	340
lymph node	lymphaden/o	340
lymphatic vessel	lymphangi/o	340
lymphocyte	lymph/o, lymphocyt/o	368
male	andr/o	493
malformed fetus	terat/o	540
mammary gland	mamm/o, mast/o	521
many	multi-, poly-	18
marrow	myel/o	158, 227, 368
measure	metr/o	99, 520
measuring instrument	-meter	99
measurement of	-metry	99
medical specialty	-ics, -iatrics, iatry	11
medicine	pharm, pharmac/o	112
medulla oblongata	medull/o	228
melanin	melan/o	20
meninges	mening/o, meninge/o	227
menstruation	men/o, mens	518

extern.ir

Meanings and Their Corresponding Word Parts (*Continued*)

Meaning	Word Part(s)	Reference Page
middle	meso-	26
middle ear	tympan/o	264
milk	galact/o, lact/o	534
mimicking	-mimetic	112
mind	psych/o	228
mold	myc/o	86
molding	plas, -plasia	49
month	men/o, mens	518
mouth	or/o, stoma, stomat/o	432
movement	kin/o, kine, -kinesi/o, kinet/o	197
much	poly-	18
mucus	muc/o, myx/o	47
mucous membrane	muc/o	47
muscle	my/o, muscul/o	197
muscle cell	rhabd/o	203
muscle fiber	in/o	197
nail	onych/o	129
narrowing	stenosis	85
near	ad-, juxta-, para-	22, 59
neck	cervic/o	57, 520
nerve, nervous system, nervous tissue	neur/o, neur/i	227
network	reticul/o	47
neuroglia	gli/o	227
never	nulli-	534
new	neo-	24
night	noct/i, nyct/o	102
nipple	papill/o	47
nitrogenous compounds	azot/o	369
normal	eu-, normo-	24
nose	nas/o, rhin/o	399
not	a-, an-, in-, im-, non-, un-	21
nourishment	troph/o, -trophy, -trophia	49
nucleus	kary/o, nucle/o	47
obsession	mania	230
old	presby-	276
old age	ger/e, ger/o	12
on	epi-	59
one	mon/o-, uni-	18
one side	hemi-	18
opening (created surgically)	-stomy	101
opposed	contra-, counter	112
opposite	contra-, counter-	112
order	tax/o	202
origin	gen, genesis	49
other	hetero-	24
out, outside	ec-, ecto-, ex/o, extra-	26, 59
outer portion	cortic/o	228
ovary	ovari/o, oophor/o	519
over	hyper-, epi-	23, 59
ovum	oo, ov/o, ovul/o	519
oxygen	ox/y, -oxia	369, 398
pain	-algia, -odynia	84
pain	-algesia, alg/o, algi/o, algesi/o	84, 12
painful	dys-	83
palate	palat/o	432
pancreas	pancreat/o	435
pancreatic islets	insul/o	299
paralysis	-plegia	230
paralysis (partial)	-paresis	230
parathyroid	parathyr/o, parathyroid/o	299
partial	semi-	18
partial paralysis	-paresis	230
partition	sept/o	410
pelvis	pelvi/o	159
perineum	perine/o	521
peritoneum	periton, peritone/o	57
perspiration	hidr/o	129
pertaining to	-ac, -al, -ar, -ary, -ic, -ical, -ile, -ory, -ous	13
pharynx	pharyng/o	399
phrenic nerve	phrenic/o	400
physician	iatr/o	9
pituitary	pituitar/i, hypophysi/o	299
plant	phyt/o	107, 137
plastic repair, plastic surgery	-plasty	100
platelet	thrombocyt/o	368
pleura	pleur/o	400
poison	tox/o, toxic/o, toxin	82, 112
poor	mal-	83

(*continued*)

extern.ir

Meanings and Their Corresponding Word Parts (*Continued*)

Meaning	Word Part(s)	Reference Page
potassium	kali	369
pouch (filled)	cyst/o, cyst/i	82
pregnant woman	gravida	534
pressure	bar/o	98
production	-poiesis	367
productive cell	blast/o, -blast	49
profuse flow	-rhage, -rhagia	84
prolapse	ptosis	85
promotor	-agogue	534
prostate	prostat/o	494
protein	prote/o	50
pulse	sphygm/o	271
puncture	centesis	100
pupil	pupill/o, cor/o, cor/e	274, 280
pus	py/o	82
pylorus	pylor/o	433
radiation	radi/o	98
rapid	tachy-	83
reading	-lexia	230
reconstruction	-plasty	100
record of data	-gram	99
recording data (act of)	-graphy	99
rectum	rect/o, proct/o	434
red	erythr/o-	20
red blood cell	erythr/o, erythrocyt/o	368
reducing	-lytic	112
removal	de-, dis-	21
removal (surgical)	-ectomy	100
renal pelvis	pyel/o	466
repair (plastic)	-plasty	100
repair (surgical)	-rhaphy	100
respiration	pneum/o, pneumat/o	400
resembling	-form, -oid	13
retina	retin/o	274
rib	cost/o	159
right	dextr/o-	26
rod	rhabd/o	203
root of spinal nerve	radicul/o	227
rupture	-rhexis	84
sac (filled)	cyst/o, cyst/i	82
sacrum	sacr/o	159
saliva, salivary gland, salivary duct	sial/o	432
same	equi-, homo-, homeo-, iso-	24
sclera (of eye)	scler/o	274
scanty	oligo-	23
scrotum	osche/o	494
sebum, sebaceous gland	seb/o	129
seizure	-lepsy	230
self	auto-	239
semen	semin, sperm/i, spermat/o	494
semen, condition of	-spermia	495
seminal vesicle	vesicul/o	494
sensation	-esthesia, esthesi/o	261
sense of smell	-osmia	261
sense of taste	-geusia	261
separation	dis-, -lysis	21, 85
septum	sept/o	410
sharp	ox/y	369
short	brachy-	501
sigmoid colon	sigmoid/o	434
simulating	-mimetic	112
skeleton	skelet/o	157
skin	derm/o, dermat/o	129
skull	crani/o	159
sleep	hypn/o, somn/o, somn/i	112, 228
slipping	-listhesis	169
slow	brady-	83
small	micro-	24
small body	-some	47
smell	osm/o	261
smell (sense of)	-osmia	261
sodium	natri	369
softening	malacia	85
sound	phon/o, son/o, acous, acus, cus	98, 264
specialist	-ian, -ist, -logist	11
specialty	-ics, -iatrics, -iatry	11
speech	-phasia, -lalia	230
sperm, spermatozoa	sperm/i, spermat/o	494

extern.ir

Meanings and Their Corresponding Word Parts (*Continued*)

Meaning	Word Part(s)	Reference Page
spinal column	vertebr/o	159
spinal cord	myel/o, medull/o	158, 228, 368
spinal nerve root	radicul/o	227
spine	rachi/o	159
spitting	-ptysis	408
spleen	splen/o	340
splitting	-schisis	84
stain	chrom/o, chromat/o	98
stapes	staped/o, stapedi/o	264
staphylococcus	staphyl/o	86
starch	amyl/o	50
stimulator	-agogue	534
stomach	gastr/o	433
stone	lith	82
stoppage	stasis	85
straight	ortho-	24
strange	xen/o	235
strength	sthen/o	202
Streptococcus	strept/o	86
structure	morph/o	47
study of	-logy	11
stupor	narc/o	112, 228
sugar	glyc/o, sacchar/o, -ose	50
sudden contraction	spasm	85
suppression	stasis	85
surgery (plastic)	-plasty	100
surgical creation of an opening	-stomy	100
surgical fixation	-pexy	100
surgical removal	-ectomy	100
surgical repair	-rhaphy	100
suture	-rhaphy	100
sweat	hidr/o	129
swelling	edema	85
synovial fluid, joint, membrane	synov/i	158
tap	centesis	100
taste (sense of)	-geusia	261
tear	dacry/o, lacrim/o	273
teeth	dent/o, dent/i, odont/o	432
temperature	therm/o	98
tendon	ten/o, tendin/o	197
testicle	test/o	494
testis	test/o, orchid/o, orchi/o	494
thalamus	thalam/o	228
thick	pachy-	83
thorax	thorac/o	57
three	tri-	18
thrombocyte	thrombocyt/o	368
through	dia-, per-, trans-	22
thymus gland	thym/o	340
thyroid	thyr/o, thyroid/o	299
time	chron/o	98
tissue	hist/o, histi/o	47
tissue death	necrosis	85
toe	dactyl/o	58
together	syn-, sym-	26
tone	ton/o	197
tongue	gloss/o, lingu/o	432
tonsil	tonsil/o	340
tooth	-dent/o, dent/i, odont/o	432
toward	ad-	22
toxin	tox/o, toxic/o	82, 112
trachea	trache/o	399
true	eu-	24
tube	salping/o	264, 520
tumor	onc/o, -oma	82, 84
turning	trop/o	281
twice	bi-, di-	18
twisted chain	strept/o	86
twisted and swollen vein	varic/o	336
two	bi-, di-, dipl/o-	18
tympanic cavity	tympan/o	264
tympanic membrane	myring/o, tympan/o	264
ultrasound	son/o	98
unchanging	homo-, homeo-	24
unconsciousness	narc/o	228
under	hypo-, sub-	23, 59
unequal	hetero-	24
upright	ortho-	24
ureter	ureter/o	467
urethra	urethr/o	467

(*continued*)

extern.ir

Meanings and Their Corresponding Word Parts (*Continued*)

Meaning	Word Part(s)	Reference Page
urinary bladder	cyst/o, vesic/o	467
urination	-uresis	468
urine, urinary tract, urination	ur/o, -uria	467
urine	urin/o	467
uterine tube	salping/o	264, 520
uterus	hyster/o, metr/o, metr/i, uter/o	520
uvea	uve/o	274
uvula	uvul/o	432
vagina	colp/o, vagin/o	520
valve	valv/o, valvul/o	326
varicose vein, varix	varic/o	336
varied	poikilo-	24
vas deferens	vas/o	112
vein	ven/o, ven/i, phleb/o	327
vein (twisted, swollen)	varic/o	336
ventricle	ventricul/o	228, 326
vertebra	spondyl/o, vertebr/o	159
vessel	angi/o, vas/o, vascul/o	326, 327
vestibular apparatus, vestibule	vestibul/o	265
virus	vir/o	86
vision	opt/o, -opia, -opsia	274, 276
voice	phon/o, -phonia	98, 398
vomiting	emesis	112
vulva	episi/o, vulv/o	521
wall, dividing wall	sept/o	410
water	hydr/o	50
weakness	paresis	230
white	leuk/o-	20
white blood cell	leuk/o, leukocyt/o	368
widening	ectasia, ectasis, dilation, dilatation	85
within	end/o-, intra-	26, 59
without	a-, an-, de-	21
woman	gyn/o, gynec/o	518
woman who has given birth	para	534
work	erg/o	98, 197
x-ray	radi/o	98
yellow	xanth/o-	20

extern.ir

Appendix 5
Word Roots

Word Roots

Root	Meaning	Reference Page
abdomin/o	abdomen	57
acous, acus	sound, hearing	264
acro	extremity, end	58
aden/o	gland	47
adip/o	fat	50
adren/o	adrenal gland, epinephrine	299
adrenal/o	adrenal gland	299
adrenocortic/o	adrenal cortex	299
aer/o	air, gas	98
alg/o, algi/o, algesi/o	pain	82, 112
amnio	amnion	534
amyl/o	starch	50
andr/o	male	493
angi/o	vessel	327
an/o	anus	434
aort/o	aorta	327
arter/o, arteri/o	artery	327
arteriol/o	arteriole	327
arthr/o	joint	158
atel/o	incomplete, imperfect	408
atlant/o	atlas	156
atri/o	atrium	326
audi/o	hearing	264
azot/o	nitrogenous compounds	369
bacill/i, bacill/o	bacillus	86
bacteri/o	bacterium	86
balan/o	glans penis	500
bar/o	pressure	98
bili	bile	435
bio	life	45
blast/o	immature cell, productive cell, embryonic cell	49
blephar/o	eyelid	273
brachi/o	arm	58
bronch/i, bronch/o	bronchus	399
bronchiol	bronchiole	399
bucc/o	cheek	432
burs/o	bursa	158
calc/i	calcium	369
cali/o, calic/o	calyx	466
carcin/o	cancer, carcinoma	82
cardi/o	heart	326
cec/o	cecum	434
celi/o	abdomen	57
centesis	puncture, tap	100
cephal/o	head	57
cerebell/o	cerebellum	228
cerebr/o	cerebrum	228
cervic/o	neck, cervix	57, 520
cheil/o	lip	446
chem/o	chemical	112
chir/o	hand	97
cholangi/o	bile duct	435
chol/e, chol/o	bile, gall	435
cholecyst/o	gallbladder	435
choledoch/o	common bile duct	435
chondr/o	cartilage	152
chori/o, choroid/o	choroid	274
chrom/o, chromat/o	color, stain	98
chron/o	time	98
clasis	breaking	84
clitor/o, clitorid/o	clitoris	521
coccy, coccyg/o	coccyx	159
cochle/o	cochlea (of inner ear)	265
col/o, colon/o	colon	434
colp/o	vagina	520

(*continued*)

extern.ir

Word Roots (*Continued*)

Root	Meaning	Reference Page
copro	feces	230
cor/o, cor/e	pupil	280
corne/o	cornea	274
cortic/o	outer portion, cerebral cortex	228
cost/o	rib	159
crani/o	skull, cranium	159
cry/o	cold	98
crypt/o	hidden	498
cus	sound, hearing	264
cycl/o	ciliary body, ciliary muscle (of eye)	274
cyst/o	filled sac or pouch, cyst, bladder, urinary bladder	82, 467
cyt/o	cell	47
dacry/o	tear, lacrimal apparatus	273
dacryocyst/o	lacrimal sac	273
dactyl/o	finger, toe	58
dent/o, dent/i	tooth, teeth	432
derm/o, dermat/o	skin	129
dilation, dilatation	expansion, widening	85
duoden/o	duodenum	433
dynam/o	force, energy	203
ectasia, ectasis	dilation, dilatation, distention	85
edema	accumulation of fluid, swelling	85
electr/o	electricity	98
embry/o	embryo	534
emesis	vomiting	443
encephal/o	brain	228
endocrin/o	endocrine	299
enter/o	intestine	433
epididym/o	epididymis	494
episi/o	vulva	521
erg/o	work	98, 197
erythr/o-	red, red blood cell	20
erythrocyt/o	red blood cell	368
esophag/o	esophagus	433
fasci/o	fascia	197
fer	carry	225
ferr/i, ferr/o	iron	369
fet/o	fetus	534
fibr/o	fiber	47
galact/o	milk	534
gangli/o, ganglion/o	ganglion	227
gastr/o	stomach	433
gen	origin, formation	49
ger/e, ger/o	old age	12
gingiv/o	gum, gingiva	432
gli/o	neuroglia	227
glomerul/o	glomerulus	466
gloss/o	tongue	432
gluc/o	glucose	50
glyc/o	sugar, glucose	50
gnath/o	jaw	432
goni/o	angle	172, 281
gravida	pregnant woman	534
gyn/o, gynec/o	woman	518
hem/o, hemat/o	blood	368
hepat/o	liver	435
hidr/o	sweat, perspiration	129
hist/o, histi/o	tissue	47
hydr/o	water, fluid	50
hypn/o	sleep	112
hypophysi/o	pituitary, hypophysis	299
hyster/o	uterus	520
iatr/o	physician	9
ile/o	ileum	434
ili/o	ilium	159
immun/o	immunity, immune system	368
in/o	fiber, muscle fiber	197
insul/o	pancreatic islets	299
ir, irit/o, irid/o	iris	274
jejun/o	jejunum	433
kali	potassium	369
kary/o	nucleus	47
kerat/o	cornea, keratin, horny layer of skin	129, 274
kin/o, kine, kinesi/o, kinet/o	movement	197
labi/o	lip	432
labyrinth/o	labyrinth (inner ear)	265
lacrim/o	tear, lacrimal apparatus	273
lact/o	milk	534
lapar/o	abdominal wall	57

extern.ir

Word Roots (*Continued*)

Root	Meaning	Reference Page
laryng/o	larynx	399
lent/i	lens	274
leuk/o	white, colorless, white blood cell	20
leukocyt/o	white blood cell	368
lingu/o	tongue	432
lip/o	fat, lipid	50
listhesis	slipping	169
lith	calculus, stone	82
lumb/o	lumbar region, lower back	57
lymphaden/o	lymph node	340
lymphangi/o	lymphatic vessel	340
lymph/o	lymph, lymphatic system, lymphocyte	340
lymph/o, lymphocyt/o	lymphocyte	368
lysis	separation, loosening, dissolving, destruction	85
malacia	softening	85
mamm/o	breast, mammary gland	521
mania	excited state, obsession	230
mast/o	breast, mammary gland	521
medull/o	inner part, medulla oblongata, spinal cord	228
melan/o	dark, black, melanin	20
mening/o, meninge/o	meninges	227
men/o, mens	month, menstruation	518
metr/o	measure	99, 520
metr/o, metr/i	uterus	520
morph/o	form, structure	47
muc/o	mucus, mucous membrane	47
muscul/o	muscle	197
myc/o	fungus, mold	86
myel/o	bone marrow, spinal cord	158, 227, 368
my/o	muscle	197
myring/o	tympanic membrane	264
myx/o	mucus	47
narc/o	stupor, unconsciousness	112, 228
nas/o	nose	399
nat/i	birth	534
natri	sodium	369
necrosis	death of tissue	85
nephr/o	kidney	466
neur/o, neur/i	nervous system, nerve	227
noct/i	night	102
nucle/o	nucleus	47
nyct/o	night, darkness	280
ocul/o	eye	274
odont/o	tooth, teeth	432
onc/o	tumor	82
onych/o	nail	129
oo	ovum	519
oophor/o	ovary	519
ophthalm/o	eye	274
opt/o	eye, vision	274
orchid/o, orchi/o	testis	494
or/o	mouth	432
osche/o	scrotum	494
osm/o	smell	261
oste/o	bone	158
ot/o	ear	264
ovari/o	ovary	519
ov/o, ovul/o	ovum	519
ox/y	oxygen, sharp, acute	369
palat/o	palate	432
palpebr/o	eyelid	273
pancreat/o	pancreas	435
papill/o	nipple	47
para	woman who has given birth	534
parathyr/o, parathyroid/o	parathyroid	299
paresis	partial paralysis, weakness	230
path/o	disease, any disease of	82
ped/o	foot, child	58, 543
pelvi/o	pelvis	159
perine/o	perineum	521
periton, peritone/o	peritoneum	57
phac/o, phak/o	lens	274
phag/o	eat, ingest	49
pharm, pharmac/o	drug, medicine	112
pharyng/o	pharynx	399
phil	attracting, absorbing	49
phleb/o	vein	327
phobia	fear	230

(*continued*)

extern.ir

Word Roots (*Continued*)

Root	Meaning	Reference Page
phon/o	sound, voice	98
phot/o	light	98
phren/o	diaphragm	400
phrenic/o	phrenic nerve	400
phyt/o	plant	107, 137
pituitar/i	pituitary, hypophysis	299
plas	formation, molding, development	49
pleur/o	pleura	400
pneum/o, pneumat/o	air, gas, lung, respiration	400
pneumon/o	lung	400
pod/o	foot	58
proct/o	rectum	434
prostat/o	prostate	494
prote/o	protein	50
psych/o	mind	228
ptosis	dropping, downward displacement, prolapse	85
ptysis	spitting	408
puer	child	542
pulm/o, pulmon/o	lung	400
pupill/o	pupil	274
pyel/o	renal pelvis	466
pylor/o	pylorus	433
py/o	pus	82
pyr/o, pyret/o	fever, fire	82
rachi/o	spine	159
radicul/o	root of spinal nerve	227
radi/o	radiation, x-ray	98
rect/o	rectum	434
ren/o	kidney	466
reticul/o	network	47
retin/o	retina	274
rhabd/o	rod, muscle cell	203
rhin/o	nose	399
sacchar/o	sugar	50
sacr/o	sacrum	159
salping/o	tube, uterine tube, auditory (eustachian) tube	264, 520
schisis	fissure	84
scler/o	hard, sclera (of eye)	82, 274
sclerosis	hardening	85
seb/o	sebum, sebaceous gland	129
semin	semen	494
sept/o	septum, partition, dividing wall	410
sial/o	saliva, salivary gland, salivary duct	432
sider/o	iron	369
sigmoid/o	sigmoid colon	434
skelet/o	skeleton	157
somat/o	body	47
somn/i, somn/o	sleep	228
son/o	sound, ultrasound	98
spasm	sudden contraction, cramp	85
sperm/i	semen, spermatozoa	494
spermat/o	semen, spermatozoa	494
sphygm/o	pulse	325
spir/o	breathing	400
splen/o	spleen	340
spondyl/o	vertebra	159
staped/o, stapedi/o	stapes	264
stasis	suppression, stoppage	85
steat/o	fatty	50
stenosis	narrowing, constriction	85
steth/o	chest	97
sthen/o	strength	202
stoma, stomat/o	mouth	432
synov/i	synovial joint, synovial membrane	158
tax/o	order, arrangement	202
ten/o, tendin/o	tendon	197
terat/o	malformed fetus	540
test/o	testis, testicle	494
thalam/o	thalamus	228
therm/o	heat, temperature	99
thorac/o	chest, thorax	57
thromb/o	blood clot	368
thrombocyt/o	platelet, thrombocyte	368
thym/o	thymus gland	340
thyr/o, thyroid/o	thyroid	299
toc/o	labor	534
ton/o	tone	197
tonsil/o	tonsil	340

extern.ir

Word Roots (*Continued*)

Root	Meaning	Reference Page
tox/o, toxic/o	poison, toxin	82, 112
trache/o	trachea	399
trich/o	hair	129
trop/o	turning	281
trop	act(ing) on, affect(ing)	49
troph/o	feeding, growth, nourishment	49
tympan/o	tympanic cavity (middle ear), tympanic membrane	264
ureter/o	ureter	467
urethr/o	urethra	467
ur/o	urine, urinary tract	467
urin/o	urine	467
uter/o	uterus	520
uve/o	uvea (of eye)	274
uvul/o	uvula	432
vagin/o	sheath, vagina	520
valv/o, valvul/o	valve	326
varic/o	twisted and swollen vein, varix	336
vascul/o	vessel	327
vas/o	vessel, duct, vas deferens	112, 327
ven/o, ven/i	vein	327
ventricul/o	cavity, ventricle	228, 326
vertebr/o	vertebra, spinal column	159
vesic/o	urinary bladder	467
vesicul/o	seminal vesicle	494
vestibul/o	vestibule, vestibular apparatus (of ear)	265
vir/o	virus	86
vulv/o	vulva	521
xen/o	foreign, strange	235

extern.ir

Appendix 6
Suffixes

Suffixes

Suffix	Meaning	Reference Page
-ac	pertaining to	13
-agogue	promoter, stimulator	534
-al	pertaining to	13
-algesia	pain	84, 261
-algia	pain	84
-ar	pertaining to	13
-ary	pertaining to	13
-ase	enzyme	50
-blast	immature cell, productive cell, embryonic cell	49
-capnia	carbon dioxide (level of)	398
-cele	hernia, localized dilation	84
-centesis	puncture, tap	100
-clasis, -clasia	breaking	84
-cyte	cell	47
-desis	binding, fusion	100
-dilation, -dilatation	expansion, widening	85
-ectasia, -ectasis	dilation, dilatation, distention	85
-ectomy	excision, surgical removal	100
-edema	accumulation of fluid, swelling	85
-emia	condition of blood	367
-esthesia, -esthesi/o	sensation	261
-form	like, resembling	13
-gen, -genesis	origin, formation	49
-geusia	sense of taste	261
-gram	record of data	99
-graph	instrument for recording data	99
-graphy	act of recording data	99
-hemi	half, one side	18
-hemia	condition of blood	367
-ia	condition of	10
-ian	specialist	11
-ia/sis	condition of	10
-iatrics	medical specialty	11
-iatry	medical specialty	11
-ic	pertaining to	13
-ical	pertaining to	13
-ics	medical specialty	11
-ile	pertaining to	13
-ism	condition of	10
-ist	specialist	11
-itis	inflammation	84
-lalia	speech, babble	230
-lepsy	seizure	230
-lexia	reading	230
-listhesis	slipping	169
-logy	study of	11
-lysis	separation, loosening, dissolving, destruction	85
-lytic	dissolving, reducing, loosening	112
-malacia	softening	85
-mania	excited state, obsession	230
-megaly	enlargement	84
-meter	instrument for measuring	99
-metry	measurement of	99
-mimetic	mimicking, simulating	112
-necrosis	death of tissue	85
-odynia	pain	84
-oid	like, resembling	13
-oma	tumor	84
-opia	condition of the eye, vision	276
-opsia	condition of vision	276
-ory	pertaining to	13
-ose	sugar	50
-o/sis	condition of	10

extern.ir

Suffixes (*Continued*)

Suffix	Meaning	Reference Page
-osmia	sense of smell	261
-ous	pertaining to	13
-oxia	oxygen (level of)	398
-paresis	partial paralysis, weakness	230
-pathy	disease, any disease of	84
-penia	decrease in, deficiency of	367
-pexy	surgical fixation	100
-phasia	speech	230
-philic	attracting, absorbing	49
-phobia	fear	230
-phonia	voice	398
-plasia	formation, molding, development	49
-plasty	plastic repair, plastic surgery, reconstruction	100
-plegia	paralysis	230
-pnea	breathing	398
-poiesis	formation, production	367
-ptosis	dropping, downward displacement, prolapse	85
-rhage, -rhagia	bursting forth, profuse flow, hemorrhage	84
-rhaphy	surgical repair, suture	100
-rhea	flow, discharge	84
-rhexis	rupture	84
-schisis	fissure, splitting	84
-sclerosis	hardening	85
-scope	instrument for viewing or examining	99
-scopy	examination of	99
-sis	condition of	10
-some	body, small body	47
-spasm	sudden contraction, cramp	85
-stasis	suppression, stoppage	85
-spermia	condition of semen	494
-stenosis	narrowing, constriction	85
-stomy	surgical creation of an opening	100
-tome	instrument for incising (cutting)	100
-tomy	incision, cutting	100
-toxin	poison	85
-tripsy	crushing	100
-tropic	act(ing) on, affect(ing)	112
-trophy, -trophia	feeding, growth, nourishment	49
-uresis	urination	468
-uria	condition of urine, urination	468
-y	condition of	10

extern.ir

Appendix 7
Prefixes

Prefixes

Prefix	Meaning	Reference Page
a-	not, without, lack of, absence	21
ab-	away from	22
acro-	extremity, end	58
ad-	toward, near	22
ambly-	dim	280
an-	not, without, lack of, absence	21
ante-	before	25
anti-	against	21, 112
atel/o-	incomplete	408
auto-	self	375
bi-	two, twice	18
brachy-	short	501
brady-	slow	83
circum-	around	59
contra-	against, opposite, opposed	21, 112
counter-	against, opposite, opposed	112
cyan/o-	blue	20
de-	down, without, removal, loss	21
dextr/o-	right	26
di-	two, twice	18
dia-	through	22
dipl/o-	double	18
dis-	absence, removal, separation	21
dys-	abnormal, painful, difficult	83
ec-	out, outside	26
ecto-	out, outside	26
end/o-	in, within	26
epi-	on, over	59
equi-	equal, same	24
erythr/o-	red	20
eu-	true, good, easy, normal	24
ex/o-	away from, outside	26
extra-	outside	59
hemi-	half, one side	18
hetero-	other, different, unequal	24
homo-, homeo-	same, unchanging	24
hyper-	over, excess, increased, abnormally high	23
hypo-	under, below, decreased, abnormally low	23
im-	not	21
in-	not	21
infra-	below	59
inter-	between	59
intra-	in, within	59
iso-	equal, same	24
juxta-	near, beside	59
leuk/o-	white, colorless, white blood cell	20
macro-	large, abnormally large	24
mal-	bad, poor	83
mega-, megal/o-	large, abnormally large	24
melan/o-	black, dark, melanin	20
mes/o-	middle	26
met/a-	change, after, beyond	81
micro-	small, one millionth	24
mon/o-	one	18
multi-	many	18
neo-	new	24
non-	not	21
normo-	normal	24
nulli-	never	534
olig/o-	few, scanty, deficiency of	23
ortho-	straight, correct, upright	24
pachy-	thick	83
pan-	all	23
para-	near, beside, abnormal	59
per-	through	22

extern.ir

Prefixes (*Continued*)

Prefix	Meaning	Reference Page
peri-	around	59
poikilo-	varied, irregular	24
poly-	many, much	18
post-	after, behind	25
pre-	before, in front of	25
presby-	old	276
prim/i-	first	18
pro-	before, in front of	25
pseudo-	false	24
quadr/i-	four	18
re-	again, back	24
retro-	behind, backward	59
semi-	half, partial	18
sinistr/o-	left	26
staphyl/o-	grape-like cluster, Staphylococcus	86
strept/o-	twisted chain, Streptococcus	86
sub-	below, under	59
super-	above, excess	23
supra-	above	59
syn-, sym-	together	26
tachy-	rapid	83
tel/e-, tel/o-	end, far, at a distance	26
tetra-	four	18
trans-	through	22
tri-	three	18
un-	not	21
uni-	one	18
xanth/o-	yellow	20
xer/o-	dry	83

extern.ir

Appendix 8
Metric Measurements

Appendix 8-1 Metric Measurements

Unit	Abbreviation	Metric Equivalent	U.S. Equivalent
Units of Length			
kilometer	km	1,000 m	0.62 mi; 1.6 km/mi
meter*	m	100 cm; 1,000 mm	39.4 in; 1.1 yards
centimeter	cm	1/100 m; 0.01 m	0.39 in; 2.5 cm/in
millimeter	mm	1/1,000 m; 0.001 m	0.039 in; 25 mm/in
micrometer	µm (mcm)	1/1,000 mm; 0.001 mm	
Units of Weight			
kilogram	kg	1,000 g	2.2 lb
gram*	g	1,000 mg	0.035 oz; 28.5 g/oz
milligram	mg	1/1,000 g; 0.001 g	
microgram	mcg	1/1,000 mg; 0.001 mg	
Units of Volume			
liter*	L	1,000 mL	1.06 qt
deciliter	dL	1/10 L; 0.1 L	
milliliter	mL	1/1,000 L; 0.001 L	0.034 oz; 29.4 mL/oz
microliter	µL (mcL)	1/1,000 mL; 0.001 mL	

*Basic unit.

Appendix 8-2 Metric Prefixes

Prefix	Meaning of Prefix
kilo-	1,000
deci-	1/10; one tenth
centi-	1/100; one hundredth
milli-	1/1,000; one thousandth
micro-	1/1,000,000; one millionth

extern.ir

Appendix 9
Stedman's Medical Dictionary at a Glance

an·ti·bod·y (an′tē-bod′e) *Avoid the jargonsitic use of the plural antibodies when the reference is to a single antibody species.* An immunoglobulin molecule produced by B-lymphoid cells that combine specifically with an immunogen or antigen. A.'s may be present naturally, their specificity is determined through gene rearrangement or somatic replacement or may be synthesized in response to stimulus provided by the introduction of an antigen; a.'s are found in the blood and body fluids, although the basic structure of the molecule consists of two light and two heavy chains, a.'s may also be found as dimers, trimers, or pentamers. After binding antigen, some a.'s may fix, complement, bind to surface receptors on immune cells, and in some cases may neutralize microorganisms, SEE ALSO immunoglobulin. SYN immune protein, protective protein, sensitizer (2).

Usage notes appear in italics before definition

Pronunciation

Main entry

Large header for entries with numerous subentries

ANTIGEN

Indicates term is illustrated

an·ti·gen (Ag) (an′ti-jen). Any substance that, as a result of coming in contact with appropriate cells, induces a state of sensitivity or immune responsiveness and that reacts in a demonstrable way with antibodies or immune cells of the sensitized subject in vivo or in vitro. Modern usage tends to retain the broad meaning of a., employing the terms "antigenic determinant" or "determinant group" for the particular chemical group of a molecule that confers antigenic specificity. SEE ALSO hapten, SYN immunogen. [anti-body) + G, *-gen,* producing.]

Subentry

Etymologies appear in brackets

Australia a. [MIM*209800], an a. so called because first recognized in an Australian aborigine, but now known to be a subunit of the hepatitis B virus surface antigen. SYN Au a. (2), Aus a.

Abbreviation

carcinoembryonic a. (CEA), a glycoprotein constituent of the glycocalyx of embryonic endodermal epithelium, which may be elevated in the serum of some patients with colon cancer and certain other cancers and in serum of long-term tobacco smokers.

Main word is abbreviated in subentries

conjugated a., SYN conjugated *hapten.*

Cross-references in blue indicate where to find the defined / preferred term. In multi-word terms, the italicized term indicates the main entry under which the term can be found.

High-profile terms (entries) with broad significance to the practice of medicine and to the world appear in blue boxes

prostate-specific a. (PSA), a single-chain, 31-kD glycoprotein with 240 amino acid residues and 4 carbohydrate side-chains; a kallikrein protease produced by prostatic epithelial cells and normally found in seminal fluid and circulating blood. Elevations of serum PSA are highly organ-specific but occur in both cancer (adenocarcinoma) and benign disease (e.g., benign prostatic hyperplasia, prostatitis). A significant number of patients with organ-confined cancer have normal PSA values. SEE carcinoma of the prostate. SYN human glandular kallikrein 3.

Cross-references

KEY

♻	Combining Forms
🛈	Indicates term is illustrated, *see Illustration Index*
SYN	Synonym
Cf.	Compare
[NA]	Nomina Anatomica
[TA]	Terminologia Anatomica
★	Official alternate Terminologia Anatomica term
[MIM]	Mendelian Inheritance in Man
C.I.	*Color Index*

extern.ir

Appendix 10
Drugs

Appendix 10-1 Commercial Drugs and Their Actions

Category	Actions; Applications	Generic Name	Brand Name(s)
adrenergics *ad-ren-ER-jiks* (sympathomimetics [*sim-pah-tho-mih-MET-iks*])	Mimic the action of the sympathetic nervous system, which responds to stress; used to treat bronchospasms, allergic reactions, hypotension	epinephrine phenylephrine pseudoephedrine dopamine	Bronkaid Neo-Synephrine Sudafed Intropin
analgesics *an-al-JE-siks*	Alleviate pain by altering the perception of nociceptive stimuli without producing anesthesia or loss of consciousness		
narcotics *nar-KOH-tiks*	Decrease pain sensation in central nervous system; chronic use may lead to physical dependence	codeine morphine meperidine oxycodone hydrocodone	 Demerol OxyContin, Percocet Vicodin, Lortab
nonnarcotics *non-nar-KOH-tiks*	Act peripherally to inhibit prostaglandins (local hormones); they may also be anti-inflammatory and antipyretic (reduce fever); Cox-2 inhibitors limit an enzyme that causes inflammation without affecting a related enzyme that protects the stomach lining	aspirin (acetylsalicylic acid; ASA) acetaminophen (APAP) ibuprofen celecoxib (Cox-2 inhibitor)	 Tylenol Motrin, Advil Celebrex
anesthetics *an-es-THET-iks*	Reduce or eliminate sensation (esthesi/o). Compounds that reversibly depress neuronal function, which produces loss of ability to perceive pain and other sensations	local: lidocaine bupivacaine general: nitrous oxide midazolam thiopental	 Xylocaine Marcaine Versed Pentothal
anticoagulants *an-te-ko-AG-u-lants*	Prevent coagulation and formation of blood clots by blocking various steps in the blood clotting process	heparin warfarin apixaban dabigatran rivaroxaban	 Coumadin Eliquis Pradaxa Xarelto
anticonvulsants *an-te-kon-VUL-sants*	Suppress or reduce the number and/or intensity of seizures	phenobarbital phenytoin carbamazepine valproic acid	 Dilantin Tegretol Depakene
antidiabetics *an-te-di-ah-BET-iks*	Counteract diabetes by decreasing blood sugar. Prevent or alleviate diabetes	insulin glyburide linagliptin glipizide metformin	Humulin (injected) Diabeta Tradjenta Glucotrol Glucophage
antiemetics *an-te-eh-MET-iks*	Relieve symptoms of nausea and prevent vomiting (emesis)	ondansetron dimenhydrinate prochlorperazine scopolamine promethazine	Zofran Dramamine Compazine TRANSDERM-SCOP Phenergan

extern.ir

Appendix 10-1 Commercial Drugs and Their Actions (*Continued*)

Category	Actions; Applications	Generic Name	Brand Name(s)
antihistamines *an-te-HIS-tah-menes*	Prevent responses mediated by histamine on either H_1 or H_2 receptors: counteract allergic and inflammatory reactions	diphenhydramine fexofenadine loratadine cetirizine	Benadryl Allegra Claritin Zyrtec
antihypertensives *an-te-hi-per-TEN-sivs*	Lower blood pressure by reducing cardiac output, dilating vessels, or promoting excretion of water by the kidneys. ACE inhibitors block production of a substance that raises blood pressure; ARBs interfere with the action of that substance. See also calcium-channel blockers and beta-blockers under cardiac drugs; diuretics	amlodipine atenolol clonidine prazosin minoxidil captopril enalapril lisinopril losartan valsartan	Norvasc Tenormin Catapres Minipress Loniten Capoten Vasotec Zestril, Prinivil Cozaar Diovan
anti-inflammatory drugs *an-te-in-FLAM-ah-to-re*	Reduce inflammation and swelling by acting on body responses, without directly antagonizing the causative agent		
corticosteroids *kor-tih-ko-STER-oyds*	Hormones from the cortex of the adrenal gland (adrenal corticoid). A corticoid containing a steroid; used for allergy, respiratory and blood diseases, injury, and malignancy; suppress the immune system	dexamethasone cortisone prednisone hydrocortisone fluticasone	Decadron Cortone Deltasone Hydrocortone, Cortef, Solu-Cortef Flonase
nonsteroidal anti-inflammatory drugs (NSAIDs) *non-ster-OYD-al*	Reduce inflammation and pain by interfering with synthesis of prostaglandins; also antipyretic	aspirin ibuprofen indomethacin naproxen celecoxib	 Motrin, Advil Indocin Naprosyn, Aleve Celebrex
anti-infective agents *an-te-in-FEK-tiv*	Kill or prevent the growth of infectious organisms		
antibacterials *an-te-bak-TE-re-als;* antibiotics *an-te-bi-OT-iks*	Effective against bacteria	amoxicillin penicillin V erythromycin vancomycin gentamicin cephalexin tetracycline ciprofloxacin (for ulcer-causing *Helicobacter pylori*) isoniazid (INH) (tuberculosis)	Polymox Pen-Vee K Erythrocin Vancocin Garamycin Keflex Achromycin Cipro
antifungals *an-te-FUNG-gals*	Effective against fungi	amphotericin B miconazole nystatin	Fungizone Monistat Nilstat
antiparasitics *an-te-par-ah-SIT-iks*	Effective against parasites—protozoa, worms	iodoquinol (amebae) quinacrine	Yodoxin Atabrine
antivirals *an-te-VI-rals*	Effective against viruses	acyclovir zanamivir (influenza) zidovudine (HIV) indinavir (HIV protease inhibitor)	Zovirax Relenza Retrovir Crixivan
antineoplastics *an-te-ne-o-PLAS-tiks*	Destroy cancer cells; they are toxic for all cells but have greater effect on cells that are actively growing and dividing; hormones and hormone inhibitors also are used to slow tumor growth	cyclophosphamide doxorubicin methotrexate vincristine tamoxifen (estrogen inhibitor)	Cytoxan Adriamycin Oncovin Nolvadex

(*continued*)

extern.ir

Appendix 10-1 Commercial Drugs and Their Actions (*Continued*)

Category	Actions; Applications	Generic Name	Brand Name(s)
cardiac drugs *KAR-de-ak*	Act on the heart		
antiarrhythmics *an-te-ah-RITH-miks*	Correct or prevent abnormalities of heart rhythm	quinidine lidocaine digoxin	Quinidex Xylocaine Lanoxin
beta-adrenergic blockers (beta-blockers) *ba-tah-ad-ren-ER-jik*	Inhibit sympathetic nervous system; reduce rate and force of heart contractions	propranolol metoprolol atenolol	Inderal Toprol-XL Tenormin
calcium-channel blockers *KAL-se-um*	Dilate coronary arteries, slow heart rate, reduce contractions	diltiazem nifedipine verapamil	Cardizem Procardia Verelan, Calan
hypolipidemics *hi-po-lip-ih-DE-miks*	Lower cholesterol in patients with high serum levels that cannot be controlled with diet alone; hypocholesterolemics, statins	lovastatin pravastatin atorvastatin simvastatin	Mevacor Pravachol Lipitor Zocor
nitrates *NI-trates;* antianginal agents *an-tih-AN-ji-nal*	Dilate coronary arteries and reduce heart's workload by lowering blood pressure and reducing venous return	nitroglycerin isosorbide	Nitrostat Isordil
CNS stimulants	Stimulate the central nervous system	methylphenidate amphetamine (chronic use may lead to drug dependence)	Ritalin Adderall, Dexedrine
diuretics *di-u-RET-iks*	Promote excretion of water, sodium, and other electrolytes by the kidneys; used to reduce edema and blood pressure; loop diuretics act on the kidney tubules (see Chapters 10 and 14)	furosemide ethacrynic acid mannitol hydrochlorothiazide (HCTZ) triamterene + HCTZ	Lasix Edecrin Osmitrol HydroDIURIL Dyazide
gastrointestinal drugs *gas-tro-in-TES-tin-al*	Act on the digestive tract		
antidiarrheals *an-te-di-ah-RE-als*	Treat or prevent diarrhea by reducing intestinal motility or absorbing irritants and soothing the intestinal lining	diphenoxylate+ atropine loperamide attapulgite	Lomotil Imodium Kaopectate
histamine H_2 antagonists *HIS-tah-mene*	Decrease stomach acid secretion by interfering with the action of histamine at H_2 receptors; used to treat ulcers and other gastrointestinal problems	famotidine ranitidine	Pepcid Zantac
laxatives *LAK-sah-tivs*	Promote elimination from the large intestine; types include:		
	stimulants	bisacodyl	Dulcolax
	hyperosmotics (retain water)	lactulose	Constilac, Chronulac
	stool softeners	docusate	Colace, Surfak
	bulk-forming agents	psyllium	Metamucil
proton pump inhibitors *PRO-ton*	Reduce stomach acidity by blocking transport of hydrogen ions (protons) into the stomach	esomeprazole lansoprazole omeprazole	Nexium Prevacid Prilosec
muscle relaxants *re-LAK-sants*	Depress nervous system stimulation of skeletal muscles; used to control muscle spasms and pain	baclofen carisoprodol methocarbamol	Lioresal Soma Robaxin

extern.ir

Appendix 10-1 Commercial Drugs and Their Actions (*Continued*)

Category	Actions; Applications	Generic Name	Brand Name(s)
psychotropics *si-ko-TROP-iks*	Affect the mind, altering mental activity, mental state, or behavior		
antianxiety agents *an-te-ang-ZI-eh-te*	Reduce or dispel anxiety; tranquilizers; anxiolytic agents	lorazepam chlordiazepoxide diazepam hydroxyzine alprazolam buspirone	Ativan Librium Valium Atarax Xanax BuSpar
antidepressants *an-te-de-PRES-sants*	Relieve depression by raising brain levels of neurotransmitters (chemicals active in the nervous system)	amitriptyline imipramine fluoxetine paroxetine sertraline	Elavil Tofranil Prozac Paxil Zoloft
antipsychotics *an-te-si-KOT-iks*	Act on nervous system to relieve symptoms of psychoses	chlorpromazine haloperidol risperidone olanzapine	Thorazine Haldol Risperdal Zyprexa
respiratory drugs	Act on the respiratory system		
antitussives *an-te-TUS-sivs*	Suppress coughing	dextromethorphan	Benylin DM
asthma maintenance drugs; bronchodilators *brong-ko-di-LA-tors*	Used for prevention of asthma attacks and chronic treatment of asthma; prevent or eliminate spasm of the bronchi (breathing tubes) by relaxing bronchial smooth muscle; used to treat asthma attacks and bronchitis	fluticasone montelukast albuterol metaproterenol tiotropium	Flovent Singulair Proventil Alupent Spiriva
expectorants *ek-SPEK-to-rants*	Induce productive coughing to eliminate respiratory secretions	guaifenesin	Robitussin
mucolytics *mu-ko-LIT-iks*	Loosen mucus to promote its elimination	acetylcysteine	Mucomyst
sedatives/hypnotics *SED-ah-tivs/hip-NOT-iks*	Induce relaxation and sleep; lower (sedative) doses promote relaxation leading to sleep; higher (hypnotic) doses induce sleep; antianxiety agents also used	phenobarbital zolpidem	 Ambien

extern.ir

Appendix 10-2 Therapeutic Uses of Herbal Medicines

Name	Part Used	Therapeutic Uses
aloe *AL-o*	leaf	treatment of burns and minor skin irritations
black cohosh *KO-hosh*	root	reduction of menopausal hot flashes
chamomile *KAM-o-mile*	flower	anti-inflammatory, gastrointestinal antispasmodic, sedative
echinacea *eh-kih-NA-she-ah*	all	may reduce severity and duration of colds, may stimulate the immune system, used topically for wound healing
evening primrose oil *PRIM-roze*	seed	source of essential fatty acids important for the health of the cardiovascular system; treatment of premenstrual syndrome (PMS), rheumatoid arthritis, skin disorders
flax	seed	source of fatty acids important in maintaining proper lipids (e.g., cholesterol) in the blood
ginger *JIN-jer*	root	relief of nausea and motion sickness, treatment of colds and sore throat
ginkgo *GING-ko*	leaf	improves blood circulation in and function of the brain, improves memory, used to treat dementia, antianxiety agent, protects the nervous system
ginseng *JIN-seng*	root	stress reduction, lowers blood cholesterol and blood sugar
green tea	leaf	antioxidant, acts against cancer of the gastrointestinal tract and skin, oral antimicrobial agent, reduces dental caries
kava *KAH-vah*	root	antianxiety agent, sedative
milk thistle *thisl*	seeds	protects the liver against toxins, antioxidant
saw palmetto *pal-MET-o*	berries	used to treat benign prostatic hyperplasia (BPH)
slippery elm	bark	as lozenge for throat irritation, for gastrointestinal irritation and upset, protects irritated skin
soy	bean	rich source of nutrients; protective estrogenic effects in menopausal symptoms, osteoporosis, cardiovascular disease, cancer prevention
St. John's wort	flower	treatment of anxiety and depression, has antibacterial and antiviral properties (note: this product can interact with a variety of drugs)
tea tree oil	leaf	antimicrobial; used to heal cuts, skin infections, burns
valerian *vah-LE-re-an*	root	sedative, sleep aid

extern.ir

Appendix 11
Answer Key

Chapter 1
PRETEST

1. c
2. d
3. c
4. a
5. a
6. c
7. c
8. b

CHAPTER EXERCISES

Exercise 1-1

1. -ia
2. -sis, -iasis
3. -ism
4. -y
5. -ia
6. -ism
7. -sis, -osis
8. -y
9. -sis, -esis

Exercise 1-2

1. -ist
2. -logy
3. -iatrics
4. -logy
5. -ian
6. -ist
7. anatomist
8. pediatrician
9. radiologist
10. psychologist
11. technologist; also, technician
12. obstetrician

Exercise 1-3

1. -ary
2. -al
3. -ic
4. -ous
5. -form
6. -oid
7. -al, -ical
8. -ile
9. -ic
10. -al, -ical
11. -ar
12. -ary
13. -ory
14. -ic
15. -ar

Exercise 1-4

1. patellae (*pah-TEL-e*)
2. phenomena (*feh-NOM-eh-nah*)
3. omenta (*o-MEN-tah*)
4. prognoses (*prog-NO-seze*)
5. apices (*AP-ih-seze*)
6. ova (*O-vah*)
7. spermatozoa (*sper-mah-to-ZO-ah*)
8. meninges (*meh-NIN-jeze*)
9. emboli (*EM-bo-li*)
10. protozoon (*pro-to-ZO-on*)
11. appendix (*ah-PEN-diks*)
12. adenoma (*ad-eh-NO-mah*)
13. fungus (*FUN-gus*)
14. pelvis (*PEL-vis*)
15. foramen (*fo-RA-men*)
16. curriculum (*kur-RIK-u-lum*)
17. index (*IN-deks*)
18. alveolus (*al-VE-o-lus*)

Exercise 1-5

1. uni-; bi-; tri-; tetra-
2. two
3. four
4. one
5. half
6. two
7. four
8. three
9. one
10. bi-
11. multi-
12. semi-
13. uni-

Exercise 1-6

1. d
2. c
3. a
4. b
5. e

Exercise 1-7

1. a-; not, without, lack of, absence
2. anti-; against
3. a-; not, without (root *mnem/o* means "memory")
4. dis-; absence, removal, separation
5. contra-; against, opposite, opposed
6. in-; not
7. de-; down, without, removal, loss
8. non-; not
9. unconscious
10. insignificant
11. disinfect
12. unusual
13. nonspecific
14. decongestant
15. incompatible

Exercise 1-8

1. dia-; through
2. per-; through
3. ad-; toward, near
4. ab-; away from
5. dia-; through
6. trans-; through

Exercise 1-9

1. c
2. e
3. d
4. b
5. a

Exercise 1-10

1. d
2. e
3. c
4. b
5. a
6. homeo-; same, unchanging
7. equi-; equal, same
8. ortho-; straight, correct, upright
9. re-; again, back
10. eu-; true, good, easy, normal
11. neo-; new
12. mega-; large, abnormally large
13. iso-; equal, same
14. normo-; normal

extern.ir

15. heterogeneous (*het-er-o-JE-ne-us*)
16. microscopic (*mi-kro-SKOP-ik*)

Exercise 1-11

1. e
2. a
3. b
4. c
5. d
6. pre-; before, in front of
7. post-; after, behind
8. pro-; before, in front of
9. pre-; before, in front of
10. ante-; before

Exercise 1-12

1. e
2. c
3. a
4. b
5. d
6. sym-; together
7. ex-; away from, outside
8. ecto-; out, outside
9. syn-; together
10. endo-; in, within
11. endogenous (*en-DOJ-eh-nus*)
12. sinistromanual (*sin-is-tro-MAN-u-al*)
13. endoderm (*EN-do-derm*)

CHAPTER REVIEW

1. b
2. d
3. d
4. b
5. c
6. b
7. a
8. combining form
9. diarrhea
10. alcohol, ethyl alcohol
11. examination of
12. cardiology
13. pertaining to
14. increase(d)
15. one
16. three
17. left
18. two
19. opposite
20. four
21. -ism
22. -ia
23. -sis, -osis
24. -y
25. -sis, -osis
26. -ia
27. -iatry
28. -ics
29. -ist
30. -ian
31. -ian
32. dermatologist
33. pediatrician
34. physiologist
35. gynecologist
36. -ous
37. -oid
38. -al
39. -ic
40. -ary
41. -al
42. -oid
43. -ile
44. -ar
45. -ory
46. gingivae (*JIN-jih-ve*)
47. testes (*TES-teze*)
48. criteria (*kri-TIR-e-ah*)
49. lumina (*LU-mih-nah*)
50. loci (*LO-si*)
51. ganglia (*GANG-le-ah*)
52. larynges (*lah-RIN-jeze*)
53. nuclei (*NU-kle-i*)
54. thrombus (*THROM-bus*)
55. vertebra (*VER-teh-bra*)
56. bacterium (*bak-TE-re-um*)
57. alveolus (*al-VE-o-lus*)
58. apex (*A-peks*)
59. foramen (*fo-RA-men*)
60. diagnosis (*di-ag-NO-sis*)
61. carcinoma (*kar-sih-NO-mah*)
62. hyper-; over, excess, abnormally high, increased
63. trans-; through
64. post-; after
65. re-; again, back
66. ex-; away from, outside
67. ad-; toward, near
68. un-; not
69. de-; removal, without
70. semi-; half, partial
71. pre-; before, in front of
72. per-; through
73. dia-; through
74. anti-; against
75. micro-; small
76. dis-; absence, removal, separation
77. endo-; in, within
78. sym-; together
79. pro-; before, in front of
80. in-; not
81. dehumidify
82. impermeable
83. homogeneous
84. endotoxin
85. macroscopic
86. hypoventilation
87. presynaptic
88. aseptic
89. hypersensitivity
90. macrocyte
91. prenatal
92. equilateral
93. T
94. F; one cell
95. T
96. F; four
97. F; right
98. F; three
99. T
100. *dis-LEK-se-ah*
101. *RU-mah-tizm*
102. *nu-MAT-ik*
103. *KEM-ist*
104. *FAR-mah-se*
105. cardiac
106. hydrogen
107. ocular
108. rheumatic
109. e
110. d
111. c
112. b
113. a
114. d
115. c
116. a
117. b
118. e
119. e
120. a
121. b
122. c
123. d
124. gastritis (*gas-TRI-tis*)
125. neurology (*nu-ROL-o-je*)
126. nephroptosis (*nef-rop-TO-sis*)
127. nephrology (*nef-ROL-o-je*)
128. neuritis (*nu-RI-tis*)
129. cardioptosis (*kar-de-op-TO-sis*)
130. microcytic
131. ectocardia
132. monocytic
133. dextrocardia
134. endocardial
135. macrocytic
136. microcardia

extern.ir

137. pertaining to the kidney and stomach
    a. kidney
    b. stomach
    c. pertaining to
138. Specialist in care of the aged:
    a. old, old age
    b. physician
    c. pertaining to
    d. specialist
139. of equal dimensions
    a. equal, same
    b. measure
    c. pertaining to
140. association of two or more organisms
    a. together
    b. life
    c. condition of

CASE STUDY QUESTIONS

Case Study 1-1

1. c
2. d
3. a
4. b
5. anterior cruciate ligament
6. complains (complaining) of
7. over, excess, abnormally high, increased
8. as needed
9. a. excess
    b. fat
    c. condition of blood
10. a. straight
    b. foot/child
11. between

Case Study 1-2

1. c
2. b
3. b
4. c
5. a
6. (in any order)
    1. pulmonologist
    2. stylist
    3. manicurist
    4. therapist
7. (in any order)
    1. -ic: bronchoscopic, antibiotic
    2. -ory: respiratory
    3. -ile: febrile
    4. -ary: pulmonary
    5. -ical, -al: chemical

Case Study 1-3

1. pre-; before, in front of
2. an-; not, without, lack of, absence
3. dis-; absence, removal, separation
4. re-; again, back
5. bi-; two, twice
6. hemi-; half, one side
7. de-; down, without, removal, loss
8. condition of
9. pertaining to
10. preoperative
11. postoperative
12. abduction

Chapter 2

PRETEST

1. c
2. c
3. b
4. a
5. d
6. d
7. d
8. a

CHAPTER EXERCISES

Exercise 2-1

1. cells
2. fiber
3. tissues
4. forms
5. nucleus
6. nucleus
7. gland
8. nipple
9. mucus
10. network
11. mucus
12. body
13. morphology (*mor-FOL-o-je*)
14. cytology (*si-TOL-o-je*)
15. histology (*his-TOL-o-je*)

Exercise 2-2

1. d
2. c
3. e
4. b
5. a
6. d
7. c
8. e
9. b
10. a
11. gen; origin, formation
12. phag/o; eat, ingest
13. blast; immature cell, productive cell, embryonic cell
14. plas; formation, molding, development
15. troph; feeding, growth, nourishment

Exercise 2-3

1. sugars
2. sugar
3. water
4. starch
5. lipid, fat
6. glucose
7. fat, lipid
8. steat/o; fatty
9. lip/o; lipid, fat
10. glyc/o; sugar, glucose
11. gluc/o; glucose

Exercise 2-4

1. thoracic (*tho-RAS-ik*)
2. cephalic (*seh-FAL-ik*)
3. cervical (*SER-vih-kal*)
4. abdominal (*ab-DOM-ih-nal*)
5. lumbar (*LUM-bar*)
6. peritoneum
7. abdomen
8. abdominal wall

Exercise 2-5

1. extremities (hands and feet)
2. arms
3. finger or toe
4. arm and head
5. foot

Exercise 2-6

1. circumoral
2. subscapular
3. circumvascular
4. infracostal
5. periorbital
6. infrapatellar
7. intracellular
8. suprascapular
9. extrathoracic
10. near the nose
11. behind the peritoneum
12. above the abdomen
13. within the uterus
14. around the navel (umbilicus)
15. between the buttocks
16. above the ankle
17. within the eye
18. near the sacrum

extern.ir

CHAPTER REVIEW

Labeling Exercise

Directional Terms

1. superior (cranial)
2. inferior (caudal)
3. anterior (ventral)
4. posterior (dorsal)
5. medial
6. lateral
7. proximal
8. distal

Planes of Division

1. frontal (coronal) plane
2. sagittal plane
3. transverse (horizontal) plane

Body Cavities, Lateral View

1. dorsal cavity
2. cranial cavity
3. spinal cavity (canal)
4. ventral cavity
5. thoracic cavity
6. diaphragm
7. abdominopelvic cavity
8. abdominal cavity
9. pelvic cavity

The Nine Regions of the Abdomen

1. epigastric (*ep-i-GAS-trik*) region
2. umbilical (*um-BIL-i-kal*) region
3. hypogastric (*hi-po-GAS-trik*) region
4. right hypochondriac (*hi-po-KON-dre-ak*) region
5. left hypochondriac region
6. right lumbar (*LUM-bar*) region
7. left lumbar region
8. right iliac (*IL-e-ak*) region; also inguinal (*ING-gwi-nal*) region
9. left iliac region; also, inguinal region

Terminology

1. c
2. d
3. e
4. a
5. b
6. a
7. c
8. b
9. e
10. d
11. d
12. a
13. b
14. c
15. e
16. e
17. a
18. b
19. c
20. d
21. a
22. e
23. b
24. d
25. c
26. b
27. c
28. d
29. e
30. a
31. e
32. c
33. a
34. d
35. b
36. d
37. a
38. c
39. b
40. e
41. histology
42. epithelial, connective, muscle, and nervous tissue
43. metabolism
44. lymphatic system
45. glucose
46. mucus
47. enzyme
48. water
49. morphology
50. abdomen
51. finger or toe
52. base of skull
53. wrist
54. neck
55. arm
56. instrument for viewing the peritoneal cavity through the abdominal wall
57. above the pubis
58. below the umbilicus (navel)
59. under the tongue
60. behind the peritoneum
61. having two feet
62. dorsal
63. periocular
64. inframammary
65. anterior
66. megacephaly, macrocephaly
67. superficial
68. distal
69. suprascapular
70. intracellular
71. inferior
72. cervical region; *Cervical* refers to the neck; the others are abdominal regions.
73. transverse; *Transverse* refers to a plane of division; the others are body positions.
74. spinal cavity; The *spinal cavity* is a dorsal cavity; the others are ventral cavities.
75. T
76. F; lipid, fat
77. T
78. F; dorsal
79. T
80. F; distal
81. F; frontal, coronal
82. T
83. T
84. adenoid
85. leukoblast
86. lipase
87. mucoid
88. histioblast
89. amylase
90. amyloid
91. dactylospasm
92. infrathoracic
93. intrathoracic
94. polydactyly
95. syndactyly
96. cephalothoracic
97. adactyly
98. intracephalic
99. acephaly
100. a state of internal balance
    a. same, unchanging
    b. standing still, unchanging
    c. condition of
101. destruction and disposal of damaged organelles in the cell
    a. self
    b. to eat
    c. condition of
102. bluish discoloration of the hands or feet
    a. extremity
    b. blue
    c. condition of
103. pertaining to the forearm
    a. before
    b. arm
    c. pertaining to

extern.ir

CASE STUDY QUESTIONS

Case Study 2-1

1. a
2. d
3. a-; not, without, lack of, absence
4. bi-; two
5. meta-; change, after, beyond
6. morphologic
7. histologic
8. cytoplasm, lymphocytes, lymphocytic

Case Study 2-2

1. b
2. b
3. d
4. c
5. a

6–15. See diagrams.

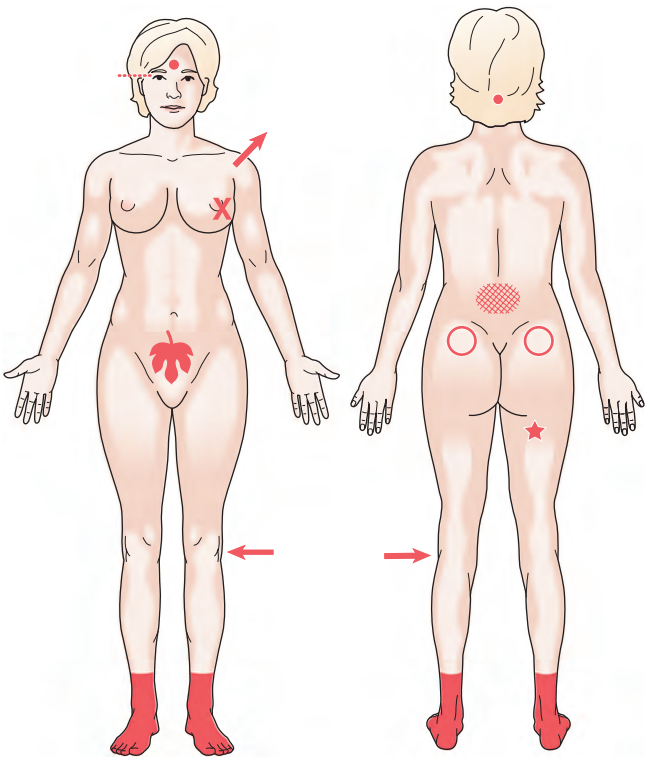

Chapter 3

PRETEST

1. c
2. b
3. a
4. d
5. b
6. b
7. c
8. d

CHAPTER EXERCISES

Exercise 3-1

1. toxic/o; poison
2. py/o; pus
3. lith/o; stone
4. path/o; disease
5. hardening
6. calculus, stone
7. bladder
8. disease
9. cancer, carcinoma
10. toxin, poison
11. pus
12. pain
13. tumor
14. fever

Exercise 3-2

1. e
2. a
3. d
4. b
5. c
6. xero-; dry
7. dys-; abnormal, painful, difficult
8. mal-; bad, poor

Exercise 3-3

1. a
2. d
3. b
4. e
5. c
6. b
7. d
8. a
9. c
10. e
11. pain in a muscle
12. any disease of muscle
13. rupture of a muscle
14. pain in a muscle
15. tumor of muscle

Exercise 3-4

1. e
2. d
3. b
4. a
5. c
6. softening of the spleen
7. dropping or prolapse of the spleen
8. substance poisonous or harmful to the spleen

Exercise 3-5

1. bacteria
2. fungus
3. bacilli
4. chain
5. cluster
6. mycology (*mi-KOL-o-je*)
7. virology (*vi-ROL-o-je*)
8. bacteriology (*bak-tere-e-OL-o-je*)

Exercise 3-6

1. a
2. c
3. d
4. e
5. b
6. son/o; sound
7. chron/o; time
8. therm/o; heat, temperature
9. erg/o; work
10. aer/o; air (oxygen)
11. chrom/o; color
12. electricity
13. light
14. cold
15. pressure
16. sound

Exercise 3-7

1. e
2. c
3. d
4. a

extern.ir

5. b
6. c
7. e
8. d
9. a
10. b

Exercise 3-8

1. b
2. e
3. a
4. d
5. c
6. cystotomy (*sis-TOT-o-me*)
7. cystopexy (*SIS-to-pek-e*)
8. cystoplasty (*SIS-to-plas-te*)
9. cystorrhaphy (*sis-TOR-ah-fe*)
10. cystostomy (*sis-TOS-to-me*)
11. arthroplasty (*AR-thro-plas-te*)
12. arthrotome (*AR-thro-tome*)
13. arthrotomy (*ar-THROT-o-me*)
14. arthrocentesis (*ar-thro-sen-TE-sis*)
15. arthrodesis (*ar-THROD-eh-sis*)
16. tracheotomy (*tra-ke-OT-o-me*)
17. gastrorrhaphy (*gas-TROR-ah-fe*)
18. colostomy (*ko-LOS-to-me*)

Exercise 3-9

1. -lytic; dissolving, reducing, loosening
2. -tropic; acting on
3. -mimetic; mimicking, simulating
4. antibacterial (*an-te-bak-TERE-e-al*)
5. contralateral (*kon-trah-LAT-er-al*)
6. antiseptic (*an-te-SEP-tik*)
7. counteract (*COWN-ter-act*)
8. antiemetic (*an-te-eh-MET-ik*)
9. antipyretic (*an-te-pi-RET-ik*)
10. narc/o; stupor
11. chem/o; chemical
12. algesi/o; pain
13. toxic/o; poison
14. hypn/o; sleep
15. dilation (widening) of a vessel
16. study of drugs
17. dissolving mucus
18. acting on the gonads (sex glands)

CHAPTER REVIEW

1. d
2. c
3. b
4. e
5. a
6. e
7. c
8. d
9. b
10. a
11. c
12. b
13. d
14. a
15. e
16. a
17. c
18. b
19. d
20. e
21. c
22. d
23. b
24. e
25. a
26. e
27. d
28. c
29. a
30. b
31. d
32. e
33. a
34. c
35. b
36. d
37. b
38. e
39. c
40. a
41. a
42. c
43. e
44. b
45. d
46. inflammation
47. neoplasm
48. metastasis
49. hernia
50. necrosis
51. tumor
52. worm
53. palpation
54. prognosis (*prog-NO-sis*)
55. edematous (*eh-DEM-ah-tus*)
56. therapy (*THER-ah-pe*)
57. light
58. gastroplasty (*GAS-tro-plas-te*)
59. arthrodesis (*ar-THROD-eh-sis*)
60. colostomy (*ko-LOS-to-me*)
61. skin
62. tolerance
63. vein
64. potentiation
65. diuretic
66. antiemetic
67. pain
68. psychotropic
69. fatty acids
70. leaf
71. hepatotomy (*hep-ah-TOT-o-me*)
72. hepatectomy (*hep-ah-TEK-to-me*)
73. hepatopexy (*HEP-ah-to-pek-se*)
74. hepatorrhaphy (*hep-ah-TOR-ah-fe*)
75. carcinogenesis (*kar-sin-o-JEN-e-sis*)
76. pathogenesis (*path-o-JEN-eh-sis*)
77. pyogenesis (*pi-o-JEN-eh-sis*)
78. oncogenesis (*ong-ko-JEN-eh-sis*)
79. bronchorrhea (*brong-ko-RE-ah*)
80. bronchitis (*brong-KI-tis*)
81. bronchostenosis (*brong-ko-steno-sis*)
82. bronchospasm (*BRONG-kospazm*)
83. osteodynia, ostealgia (*os-te-o-DIN-e-ah*, *os-te-AL-je-ah*)
84. osteonecrosis (*os-te-o-ne-KRO-sis*)
85. osteoma (*os-te-O-mah*)
86. osteoclasis (*os-te-OK-la-sis*)
87. osteomalacia (*os-te-o-mah-LA-she-ah*)
88. F; fungus
89. T
90. F; acute
91. T
92. F; bradycardia
93. F; ear
94. F; radiograph
95. T
96. helminths; *Helminths* are worms, the others are types of bacteria.
97. metastatic; *Metastatic* refers to the spread of cancer; the others are terms describing infections.
98. remission; *Remission* is the lessening of disease symptoms; the others are examining methods.
99. syncope; *Syncope* is fainting; the others are examination instruments.
100. tablet; A *tablet* is a solid dosage form, a pill; the others are forms of liquid solutions.
101. nephrotoxic (*nef-ro-TOKS-ik*)
102. pyogenic (*pi-o-JEN-ik*)
103. nephroma (*nef-RO-mah*)
104. pathology (*pa-THOL-o-je*)

extern.ir

105. pyrogenic (*pi-ro-JEN-ik*)
106. nephrology (*nef-ROL-o-je*)
107. pathogenic (*path-o-JEN-ik*)
108. nephropathy (*nef-ROP-a-the*)
109. nephrogenic (*nef-ro-JEN-ik*)
110. neurotripsy (*nu-ro-TRIP-se*)
111. cystorrhaphy (*sis-TOR-ah-fe*)
112. cystopexy (*SIS-to-pek-se*)
113. neurorrhaphy (*nu-ROR-ah-fe*)
114. lithotripsy (*LITH-o-trip-se*)
115. cystolith (*SIS-to-lith*)
116. cystoscopy (*sis-TOS-ko-pe*)
117. neurotome (*NU-ro-tome*)
118. cystotome (*SIS-to-tome*)
119. ingestion of organisms or small particles by a cell
    a. to eat
    b. cell
    c. condition of
120. counteracting fever
    a. against
    b. fever
    c. pertaining to
121. hardening of the arteries
    a. artery
    b. hard
    c. condition of
122. uneven, not symmetrical or of the same measurement
    a. not
    b. together
    c. measure
    d. pertaining to

CASE STUDY QUESTIONS

Case Study 3-1

1. b
2. a
3. d
4. c
5. electrocardiogram
6. transesophageal echocardiogram
7. subacute bacterial endocarditis
8. idiopathic hypertrophic subaortic stenosis

Case Study 3-2

1. b
2. a
3. c
4. c
5. d
6. a
7. by mouth
8. milligram
9. microgram
10. intravenous(ly)

Chapter 4

PRETEST

1. c
2. b
3. a
4. b
5. d
6. c

CHAPTER EXERCISES

Exercise 4-1

1. derm/o; skin
2. seb/o; sebum
3. melan/o; melanin
4. kerat/o; keratin, horny layer of the skin
5. hidr/o; sweat
6. trich/o; hair
7. onych/o; nail
8. skin
9. horny (keratinous) layer
10. melanin
11. hair
12. nail
13. sweat, perspiration
14. skin
15. dermatolysis (*der-mah-TOL-ih-sis*); dermolysis (*der-MOL-ih-sis*)
16. dermatology (*der-mah-TOL-o-je*)
17. onychomalacia (*on-ih-ko-mah-LA-she-ah*)
18. hyperhidrosis (*hi-per-hi-DRO-sis*)
19. trichology (*trik-OL-o-je*)
20. dermatome (*DER-mah-tome*)
21. keratogenesis (*ker-ah-to-JEN-eh-sis*)
22. melanoma (*mel-ah-NO-mah*)
23. scleroderma (*skle-ro-DER-mah*)
24. pyoderma (*pi-o-DER-mah*)

CHAPTER REVIEW

Labeling Exercise

Cross-Section of the Skin

1. epidermis
2. stratum basale (growing layer)
3. stratum corneum
4. dermis
5. skin
6. subcutaneous layer
7. adipose tissue
8. hair follicle
9. hair
10. arrector pili muscle
11. artery
12. vein
13. nerve
14. nerve endings
15. sweat gland
16. pore (opening of sweat gland)
17. sebaceous (oil) gland
18. touch receptor
19. pressure receptor

Terminology

1. e
2. a
3. d
4. b
5. c
6. d
7. c
8. a
9. e
10. b
11. e
12. b
13. c
14. a
15. d
16. a
17. b
18. e
19. d
20. c
21. melanin
22. sebaceous glands
23. sweat, perspiration
24. skin
25. skin
26. keratin
27. nail
28. decubitus ulcer, bed sore, pressure sore
29. touch
30. débridement
31. skin graft, full-thickness skin graft
32. ischemia
33. plastic surgeon
34. dryness of the skin
35. abnormal keratin production
36. excess flow of sebum
37. thickening of the skin
38. infection of a nail and nail bed
39. excess melanin production
40. through the skin
41. producing keratin
42. seborrheic (*seb-o-RE-ik*)
43. hyperkeratosis (*hi-per-ker-ah-TO-sis*)
44. dermatome (*DER-mah-tome*)
45. melanoma (*mel-ah-NO-mah*)
46. melanocyte (*MEL-ah-no-site*)
47. scleroderma; dermatosclerosis (*skle-ro-DER-mah; der-mah-to-skle-RO-sis*)

extern.ir

48. anhidrosis (*an-hi-DRO-sis*)
49. hyperhidrosis (*hi-per-hi-DRO-sis*)
50. chromhidrosis (*krome-hi-DRO-sis*)
51. bullae
52. ecchymoses
53. fungi
54. comedones
55. staphylococci
56. T
57. T
58. T
59. T
60. F; hair
61. dermatolysis (*der-mah-TOL-ih-sis*)
62. onychomycosis (*on-ih-ko-my-KO-sis*)
63. trichoid (*TRIK-oyd*)
64. trichology (*tri-KOL-o-je*)
65. onycholysis (*on-ih-KOL-ih-sis*)
66. dermatoid (*DER-mah-toyd*)
67. onychopathy (*on-ih-KOP-ah-the*)
68. trichomycosis (*trik-o-mi-KO-sis*)
69. dermatopathy (*der-mah-TOP-ah-the*)
70. dermatology (*der-mah-TOL-o-je*)
71. keloid; A *keloid* is a raised, thickened scar; the others are types of skin lesions.
72. escharotomy; *Escharotomy* is removal of scab tissue; the others are types of skin diseases.
73. BSA; *BSA* is an abbreviation for body surface area; the others are abbreviations for skin diseases.
74. fungal infection of the skin
    a. skin
    b. plant
    c. condition of
75. benign tumor of a sweat gland
    a. sweat
    b. gland
    c. tumor
76. ingrown toenail
    a. nail
    b. hidden
    c. condition of
77. lack of color or graying of the hair
    a. lack of
    b. color
    c. hair
    d. condition of

CASE STUDY QUESTIONS

Case Study 4-1

1. b
2. c
3. d
4. d
5. dermabrasion
6. nodule
7. dermatologist
8. subcutaneous tissue
9. full-thickness skin graft
10. sun protection factor

Case Study 4-2

1. a
2. c
3. b
4. c
5. a
6. erythroderma
7. hyperkeratosis
8. at bedtime
9. twice per day
10. as needed

Chapter 5

PRETEST

1. d
2. a
3. d
4. b
5. c
6. d
7. a
8. c

CHAPTER EXERCISES

Exercise-5-1

1. joint
2. bone marrow
3. bone, bone tissue
4. cartilage
5. bursa
6. surgical puncture of a joint
7. formation of bone marrow
8. pain in cartilage
9. pertaining to or resembling bone
10. inflammation of a bursa
11. pertaining to synovial fluid, joint, or membrane
12. osteomyelitis (*os-te-o-mi-eh-LI-tis*)
13. osteoblast (*OS-te-o-blast*)
14. chondroid (*KON-droyd*); also chondral, cartilaginous
15. arthropathy (*ar-THROP-ah-the*)
16. synovitis (*sih-no-VI-tis*)
17. myelography (*mi-eh-LOG-rah-fe*)
18. bursotomy (*bur-SOT-o-me*)
19. myeloma (*mi-eh-LO-mah*)
20. arthroscope (*AR-thro-skope*)
21. hyperostosis (*hi-per-os-TO-sis*)
22. dysostosis (*dis-os-TO-sis*)

Exercise 5-2

1. cranial
2. costal
3. pelvic
4. iliac
5. vertebral
6. sacral
7. incision of the cranium (skull)
8. before or in front of the spinal column or vertebra
9. pain in a vertebra
10. measurement of the pelvis
11. cranioschisis (*kra-ne-OS-kih-sis*)
12. suprapelvic (*su-prah-PEL-vik*)
13. craniosacral (*kra-ne-o-SA-kral*)
14. sacroiliac (*sa-kro-IL-e-ak*)
15. rachiocentesis (*ra-ke-o-sen-TE-sis*); also, rachicentesis (*ra-ke-sen-TE-sis*)
16. costectomy (*kos-TEK-to-me*)
17. vertebroplasty (*ver-teh-bro-PLAS-te*)
18. spondylitis (*spon-dih-LI-tis*)
19. perisacral (*per-ih-SA-kral*)
20. infracostal (*in-frah-KOS-tal*); subcostal (*sub-KOS-tal*)
21. iliococcygeal (*il-e-o-kok-SIJ-e-al*)
22. coccygectomy (*kok-sih-JEK-to-me*)

CHAPTER REVIEW

Labeling Exercise

The Skeleton

1. cranium
2. facial bones
3. mandible
4. vertebral column
5. sacrum
6. sternum
7. ribs
8. clavicle
9. scapula
10. humerus
11. radius
12. ulna
13. carpals
14. metacarpals
15. phalanges
16. pelvis
17. ilium
18. femur
19. patella

extern.ir

20. fibula
21. tibia
22. tarsals
23. calcaneus
24. metatarsals

Skull from the Left

1. frontal
2. parietal
3. occipital
4. temporal
5. sphenoid
6. lacrimal
7. nasal
8. zygomatic
9. maxilla
10. mandible
11. hyoid

Vertebral Column

1. cervical vertebrae
2. thoracic vertebrae
3. lumbar vertebrae
4. sacrum
5. coccyx
6. intervertebral disk
7. body of vertebra

The Pelvic Bones

1. ilium
2. ischium
3. pubis
4. pubic symphysis
5. acetabulum
6. sacrum

Structure of a Long Bone

1. proximal epiphysis (*eh-PIF-ih-sis*)
2. diaphysis (*di-AF-ih-sis*)
3. distal epiphysis
4. cartilage
5. epiphyseal line (growth line)
6. spongy bone (containing red marrow)
7. compact bone
8. medullary (marrow) cavity
9. artery and vein
10. yellow marrow
11. periosteum (*per-e-OS-te-um*)

Terminology

1. d
2. e
3. a
4. c
5. b
6. e
7. a
8. d
9. c
10. b
11. c
12. b
13. e
14. a
15. d
16. d
17. b
18. a
19. c
20. e
21. tendon
22. cartilage
23. orthopedics
24. sacrum
25. cartilage
26. synovial fluid; synovia
27. bursa
28. bone marrow
29. joint, joint cavity
30. vertebrae
31. spine
32. inflammation of the bone marrow
33. formation of bone tissue
34. fusion of a joint
35. excision of a synovial membrane
36. cartilage cell
37. below a rib
38. pain in the coccyx
39. inflammation of a vertebra
40. pertaining to many joints
41. within bone
42. around a bursa
43. chondrogenesis (*kon-dro-JEN-eh-sis*)
44. arthrodesis (*ar-THROD-eh-sis*)
45. pelvimetry (*pel-VIM-eh-tre*)
46. osteochondroma (*os-te-o-kon-DRO-mah*)
47. arthrostenosis (*ar-thro-steh-NO-sis*)
48. osteonecrosis (*os-te-o-neh-KRO-sis*)
49. bursolith (*BUR-so-lith*)
50. craniotomy (*kra-ne-OT-o-me*)
51. parasacral (*par-ah-SA-kral*)
52. sacroiliac (*sak-ro-IL-e-ak*)
53. coccygectomy (*kok-sih-JEK-to-me*)
54. arthroscopy (*ar-THROS-ko-pe*)
55. idiopathic
56. scapula
57. ilium
58. thorax
59. osteotomies
60. scoliosis
61. sacral
62. vertebral
63. coccygeal
64. pelvic
65. iliac
66. F; metaphysis
67. T
68. T
69. F; appendicular
70. T
71. T
72. F; red
73. F; lordosis
74. T
75. hyoid; The *hyoid* is the bone below the mandible (lower jaw); the others are bone markings.
76. lambdoid; *Lambdoid* refers to a skull suture; the others are bones of the skull.
77. cost/o; *Cost/o* refers to a rib; the others are roots pertaining to the spine.
78. sciatic; *Sciatic* refers to the sciatic nerve that travels through the leg; the others are types of bone fractures.
79. OA; *OA* is an abbreviation for osteoarthritis; the others are abbreviations for spinal regions.
80. arthrodynia
81. spondylolysis
82. spondylodynia
83. arthrolysis
84. osteotome
85. arthroplasty
86. osteodynia
87. arthrotome
88. osteolysis
89. osteoplasty
90. disease of the (cartilaginous) growth center in children
    a. bone
    b. cartilage
    c. condition of
91. surgical fusion (ankylosis) between vertebrae
    a. vertebra
    b. together
    c. fusion, binding
92. bony outgrowth from a bone
    a. out
    b. bone
    c. condition of
93. decreased growth of cartilage in the growth plate of long bones resulting in dwarfism
    a. lack of

extern.ir

b. cartilage
c. formation, molding
d. condition of

94. reduction in bone density
a. bone
b. pore(s)
c. condition of

CASE STUDY QUESTIONS

Case Study 5-1

1. b
2. b
3. c
4. zygomatic
5. periosteum
6. meniscus
7. arthroplasty
8. degenerative joint disease
9. normal saline
10. temporomandibular joint
11. estimated blood loss

Case Study 5-2

1. d
2. c
3. osteogenesis
4. fracture
5. congenital
6. femur
7. osteogenesis imperfecta
8. open reduction internal fixation
9. operating room
10. intramedullary
11. postanesthesia care unit

Chapter 6

PRETEST

1. b
2. c
3. d
4. d
5. a
6. b
7. c
8. a

CHAPTER EXERCISES

Exercise 6-1

1. pertaining to muscle
2. pertaining to fascia
3. pertaining to movement
4. pertaining to a tendon
5. pertaining to tone
6. myotomy (*mi-OT-o-me*)
7. myotenositis (*mi-o-ten-o-SI-tis*)
8. kinesiology (*ki-ne-se-OL-o-je*)
9. fasciectomy (*fash-e-EK-to-me*)
10. tenalgia, tenodynia (*teh-NAL-je-ah, ten-o-DIN-e-ah*)
11. muscle
12. fibers
13. fascia
14. tone
15. work
16. movement, motion
17. muscle
18. muscle, smooth muscle
19. excess muscle tone
20. suture of fascia
21. inflammation of a tendon
22. pertaining to a muscle and tendon
23. binding or fusion of a tendon
24. pain in a muscle
25. treatment using movement
26. abnormality of movement
27. lack of muscle tone
28. producing or generating work
29. pertaining to muscle and fascia
30. inflammation of a muscle and a tendon

CHAPTER REVIEW

Labeling Exercise

Superficial Muscles, Anterior View

1. frontalis
2. temporalis
3. orbicularis oculi
4. orbicularis oris
5. masseter
6. sternocleidomastoid
7. trapezius
8. deltoid
9. pectoralis major
10. serratus anterior
11. brachialis
12. biceps brachii
13. brachioradialis
14. flexor carpi
15. extensor carpi
16. external oblique
17. internal oblique
18. rectus abdominis
19. intercostals
20. sartorius
21. adductors of thigh
22. quadriceps femoris
23. gastrocnemius
24. soleus
25. fibularis longus
26. tibialis anterior

Superficial Muscles, Posterior View

1. sternocleidomastoid
2. trapezius
3. deltoid
4. teres minor
5. teres major
6. latissimus dorsi
7. triceps brachii
8. gluteus medius
9. gluteus maximus
10. hamstring group
11. gastrocnemius
12. fibularis longus

Terminology

1. a
2. c
3. b
4. d
5. e
6. b
7. c
8. d
9. e
10. a
11. e
12. b
13. c
14. a
15. d
16. c
17. e
18. d
19. b
20. a
21. e
22. c
23. d
24. a
25. b
26. b
27. e
28. a
29. c
30. d
31. tendon
32. muscle, muscle tissue
33. three
34. extensor
35. acetylcholine
36. Achilles tendon
37. adduction
38. fascia
39. arm
40. supraspinatus
41. neck
42. pertaining to muscle and fascia
43. plastic repair of a tendon

extern.ir

44. decreased muscle tone
45. abnormally increased movement
46. acting on (muscle) fibers
47. inflammation of muscle
48. fasciorrhaphy
49. myonecrosis
50. kinesiology
51. atony
52. tenotomy
53. myology
54. fasciectomy
55. tendinous
56. antagonist
57. insertion
58. adduction
59. supination
60. flexion
61. ataxic
62. athetotic
63. spastic, spasmodic
64. clonic
65. F; axon
66. F; voluntary
67. F; four
68. T
69. F; posterior
70. T
71. F; insertion
72. T
73. osteoblast; An *osteoblast* is a bone cell; the others are related to muscle structure.
74. soleus; The *soleus* is a calf muscle; the others are muscles of the arm.
75. intercostals; The *intercostals* are between the ribs; the others are quadriceps muscles in the anterior thigh.
76. actin; *Actin* is a type of muscle filament involved in contraction; the others are types of movement.
77. EMG; *EMG* is electromyography, a method for studying the electric energy in muscles; the others are diseases that involve muscles.
78. rest, ice, compression, elevation
79. rotator cuff
80. carpal tunnel syndrome
81. neuromuscular junction
82. electromyogram
83. fasciitis
84. tenodesis
85. tenalgia
86. myolysis
87. fasciodesis
88. myoblast
89. tenolysis
90. fascial
91. myalgia
92. nonspecific term or pain, tenderness, and stiffness in muscles and joints
    a. fiber
    b. muscle
    c. inflammation
93. muscular weakness
    a. muscle
    b. lack of
    c. strength
    d. condition of
94. lack of smooth or accurate muscle movement because coordination between muscle components is lacking
    a. abnormal
    b. together
    c. work
    d. condition of
95. pertaining to muscle wasting, atrophy
    a. lack of
    b. muscle
    c. nourishment
    d. pertaining to

CASE STUDY QUESTIONS

Case Study 6-1

1. b
2. c
3. d
4. a
5. b
6. d
7. orthopedic
8. laxity
9. physical therapy
10. range of motion

Case Study 6-2

1. b
2. d
3. c
4. c
5. d
6. flexion
7. plantar flexion
8. somatosensory evoked potentials
9. postanesthesia care unit

Chapter 7

PRETEST

1. b
2. a
3. d
4. c
5. a
6. c
7. b
8. d

CHAPTER EXERCISES

Exercise 7-1

1. pertaining to a nerve or the nervous system
2. pertaining to neuroglia, glial cells
3. pertaining to a spinal nerve root
4. pertaining to the meninges
5. pertaining to a ganglion
6. meninges
7. nervous system, nervous tissue
8. meninges
9. spinal cord
10. surgical removal of a ganglion
11. inflammation of many spinal nerve roots
12. destruction of a nerve or nervous tissue
13. nerve pain due to irritation of the sensory nerve root
14. radiographic study of the spinal cord
15. glioma (*gli-O-mah*)
16. myelogram (*MI-eh-lo-gram*)
17. neuralgia (*nu-RAL-je-ah*)
18. myelitis (*mi-eh-LI-tis*)
19. neuropathy (*nu-ROP-ah-the*)

Exercise 7-2

1. sleep
2. cerebrum, brain
3. thalamus
4. mind
5. stupor, unconsciousness
6. brain
7. cerebrum, brain
8. psychic (*SI-kik*)
9. cortical (*KOR-tih-kal*)
10. thalamic (*thah-LAM-ik*)
11. cerebral (*SER-eh-bral*)
12. ventricular (*ven-TRIK-u-lar*)
13. any disease of the brain
14. lack of sleep, inability to sleep
15. study of the mind
16. pertaining to the brain and spinal cord
17. outside the medulla
18. incision of a ventricle
19. ventriculogram (*ven-TRIK-u-lo-gram*)
20. corticothalamic (*kor-tih-ko-thah-LAM-ik*)

extern.ir

21. intracerebellar (*in-trah-ser-eh-BEL-ar*)
22. encephalitis (*en-sef-ah-LI-tis*)
23. supracerebral (*su-prah-SER-eh-bral*)

Exercise 7-3

1. seizures
2. read
3. speech
4. tetraplegia (*tet-rah-PLE-je-ah*)
5. partial paralysis, weakness
6. paralysis of the heart
7. lack of speech communication
8. inability to comprehend the written or printed word
9. obsession with fire
10. fear of women
11. partial paralysis or weakness of all four limbs
12. photophobia (*fo-to-FO-be-ah*)
13. noctiphobia (*nok-tih-FO-be-ah*); also, nyctophobia (*nik-to-FO-be-ah*)
14. hemiplegia (*hem-ih-PLE-je-ah*)
15. bradylalia (*brad-e-LA-le-ah*)

CHAPTER REVIEW

Labeling Exercise

Anatomic Divisions of the Nervous System

1. central nervous system
2. brain
3. spinal cord
4. peripheral nervous system
5. cranial nerves
6. spinal nerves

Motor Neuron

1. cell body
2. nucleus
3. dendrites
4. axon covered with myelin sheath
5. node
6. myelin
7. axon branch
8. muscle

External Surface of the Brain

1. sulci
2. gyri
3. frontal lobe
4. parietal lobe
5. occipital lobe
6. temporal lobe
7. pons
8. medulla oblongata
9. cerebellum
10. spinal cord

Spinal Cord, Lateral View

1. brain
2. brainstem
3. spinal cord
4. cervical enlargement
5. lumbar enlargement
6. cervical nerves
7. thoracic nerves
8. lumbar nerves
9. sacral nerves
10. coccygeal nerve

Spinal Cord, Cross-Section

1. white matter
2. gray matter
3. dorsal horn
4. ventral horn
5. central canal
6. dorsal root
7. dorsal root ganglion
8. sensory (afferent) signals
9. ventral root
10. motor (efferent) signals
11. spinal nerve

Reflex Pathway

1. receptor
2. sensory neuron
3. spinal cord (CNS)
4. motor neuron
5. effector

Terminology

1. e
2. a
3. d
4. c
5. b
6. e
7. c
8. d
9. a
10. b
11. b
12. a
13. e
14. c
15. d
16. e
17. d
18. c
19. b
20. a
21. c
22. e
23. a
24. d
25. b
26. b
27. a
28. e
29. c
30. d
31. cerebrum
32. cerebrospinal fluid (CSF)
33. neuroglia, glial cells
34. synapse
35. neuron
36. meninges
37. reflex
38. autonomic nervous system (ANS)
39. neurotransmitter
40. cerebellum
41. dura mater
42. pertaining to the cerebral cortex and thalamus
43. inflammation of many nerves
44. absence of a brain
45. partial paralysis of half the body
46. pertaining to a spinal nerve root
47. treatment of mental disorders
48. total paralysis
49. softening of the brain
50. sleep disorder
51. neurology
52. meningomyelitis
53. ganglionectomy; gangliectomy
54. neuropathy
55. ventriculostomy
56. hemiplegia
57. intracerebellar
58. dyslexia
59. hydrophobia
60. monoplegia
61. T
62. F; peripheral
63. T
64. F; white
65. T
66. F; dendrite
67. T
68. T
69. T
70. intramedullary
71. contralateral
72. preganglionic
73. bradylalia
74. sensory
75. ventral
76. efferent
77. ganglionic
78. thalamic
79. dural

extern.ir

80. meningeal
81. psychotic
82. ganglia
83. ventricles
84. meninges
85. emboli
86. lumbar puncture; *Lumbar puncture* is a diagnostic procedure for sampling CSF; the others are vascular disorders.
87. hematoma; *Hematoma* is a local collection of clotted blood; the others are neoplasms.
88. mania; *Mania* is a state of elation; the others are parts of the brain.
89. CNS; *CNS* is the central nervous system; the others are behavioral disorders.
90. myeloplegia
91. aphasia
92. hemiparesis
93. myoparesis
94. dysphasia
95. ganglioplegia
96. tetraplegia
97. myelitis
98. bradyphasia
99. hemiplegia
100. gangliitis
101. hemorrhage into the spinal cord
    a. blood
    b. spinal cord
    c. condition of
102. abnormal development of the spinal cord
    a. spinal cord
    b. abnormal
    c. development
    d. condition of
103. inflammation of many nerves and nerve roots
    a. many
    b. nerve
    c. spinal nerve root
    d. inflammation of
104. disturbance of muscle coordination
    a. abnormal, difficult
    b. together
    c. work
    d. condition of

CASE STUDY QUESTIONS

Case Study 7-1

1. c
2. d
3. a
4. ischemic
5. meningitis
6. subdural hematoma
7. aphasia
8. hemiparesis
9. Glasgow Coma Scale
10. computed tomography
11. neurological intensive care unit (also means neonatal intensive care unit)
12. cerebrovascular accident
13. transient ischemic attack

Case Study 7-2

1. d
2. b
3. lethargic
4. psychiatrist
5. neuroleptics
6. paranoia
7. antispasmodic
8. diaphoresis

Chapter 8

PRETEST

1. b
2. a
3. d
4. c
5. c
6. b
7. a
8. d

CHAPTER EXERCISES

Exercise 8-1

1. loss of pain
2. abnormal sense of smell
3. lack of taste sensation
4. myesthesia (*mi-es-THE-ze-ah*)
5. pseudogeusia (*su-do-GU-ze-ah*)
6. thermesthesia (*ther-mes-THE-ze-ah*)
7. hyperalgesia (*hi-per-al-JE-ze-ah*)
8. dysgeusia (*dis-GU-ze-ah*)
9. anesthesia (*an-es-THE-ze-ah*)

Exercise 8-2

1. hearing
2. sound
3. ear
4. pertaining to the stapes
5. pertaining to the cochlea
6. pertaining to the vestibule or vestibular apparatus
7. pertaining to hearing
8. pertaining to the labyrinth (inner ear)
9. pertaining to the ear
10. otalgia (*o-TAL-je-ah*); otodynia (*o-to-DIN-e-ah*)
11. labyrinthotomy (*lab-ih-rin-THOT-o-me*)
12. salpingoscope (*sal-PING-go-skope*)
13. otoscope (*O-to-skope*)
14. endocochlear (*en-do-KOK-le-ar*); intracochlear (*in-trah-KOK-le-ar*)
15. vestibulocochlear (*ves-tib-u-lo-KOK-le-ar*)
16. audiometry (*aw-de-OM-eh-tre*)
17. tympanoplasty (*tim-PAN-o-plas-te*)
18. stapedectomy (*sta-pe-DEK-to-me*)
19. inflammation of the eardrum (tympanic membrane)
20. instrument used to measure hearing
21. any disease of the vestibule or vestibular apparatus
22. pertaining to the auditory tube and pharynx
23. procedure to surgically fix the tympanic membrane (eardrum) to the stapes

Exercise 8-3

1. pertaining to the nose and lacrimal apparatus
2. between the eyelids
3. surgical repair of the eyelid
4. excision of a lacrimal sac
5. blepharoplegia (*blef-ah-ro-PLE-je-ah*)
6. dacryolith (*DAK-re-o-lith*)
7. dacryocystitis (*dak-re-o-sis-TI-tis*)

Exercise 8-4

1. ophthalmologist
2. lens
3. eye
4. vision
5. lens
6. cornea
7. opt/o; eye, vision
8. ophthalm/o; eye
9. pupill/o; pupil
10. lent/i; lens
11. irid/o; iris
12. uve/o; uvea
13. phac/o; lens
14. uveoscleritis (*u-ve-o-skleh-RI-tis*)

extern.ir

15. phacosclerosis (*fak-o-skle-RO-sis*)
16. corneal (*KOR-ne-al*)
17. retinopexy (*ret-ih-no-PEK-se*)
18. cyclitis (*si-KLI-tis*)
19. ophthalmoscope (*of-THAL-mo-skope*)
20. ophthalmology (*of-thal-MOL-o-je*)
21. iridectomy (*ir-ih-DEK-to-me*)
22. iridoplegia (*ir-id-o-PLE-je-ah*)
23. pertaining to the right eye
24. pertaining to the lens
25. inflammation of the iris and ciliary body
26. pertaining to the choroid and retina
27. inflammation of the cornea
28. incision of the ciliary muscle
29. pertaining to the eye or vision
30. instrument used to incise the sclera
31. splitting of the retina

Exercise 8-5

1. macropsia (*mah-KROP-se-ah*)
2. achromatopsia (*ah-kro-mah-TOP-se-ah*)
3. diplopia (*dip-LO-pe-ah*)
4. presbyopia (*pres-be-O-pe-ah*)
5. amblyopia (*am-ble-O-pe-ah*)
6. ametropia (*am-eh-TRO-pe-ah*)
7. heterometropia (*het-er-o-meh-TRO-pe-ah*); also, anisometropia (*an-i-so-meh-TRO-pe-ah*)

CHAPTER REVIEW

Labeling Exercise

The Ear

1. outer ear
2. pinna
3. external auditory canal
4. tympanic membrane
5. middle ear
6. malleus
7. incus
8. stapes
9. inner ear
10. semicircular canals
11. vestibule
12. cochlea
13. vestibular nerve
14. cochlear nerve
15. vestibulocochlear nerve (VIII)
16. auditory tube
17. pharynx
18. cerumen
19. temporal bone

The Eye

1. retina
2. choroid
3. sclera
4. ciliary body
5. suspensory ligaments
6. cornea
7. iris
8. pupil
9. lens
10. aqueous humor
11. vitreous body
12. fovea
13. optic disc
14. blood vessels
15. optic nerve

Terminology

1. c
2. a
3. e
4. d
5. b
6. d
7. e
8. a
9. c
10. b
11. e
12. c
13. d
14. b
15. a
16. e
17. c
18. b
19. a
20. d
21. d
22. c
23. a
24. b
25. e
26. d
27. e
28. a
29. c
30. b
31. tympanic membrane
32. sensorineural
33. stapes
34. sclera
35. refraction
36. retina
37. cornea
38. proprioception
39. specialist in the study and treatment of hearing disorders
40. instrument for measuring the eye
41. absence of a lens
42. below the sclera
43. incision of the iris
44. instrument used to examine the tympanic membrane (eardrum)
45. around the lens
46. excess flow of tears
47. loss of hearing caused by aging
48. inflammation of the cornea and iris
49. phacomalacia
50. pupillometry
51. stapedectomy
52. blepharoptosis
53. otoplasty
54. vestibulocochlear
55. retinopathy
56. analgesia
57. lacrimal
58. cyclectomy
59. salpingoscopy
60. hyperopia
61. cochlear
62. palpebral
63. choroidal
64. uveal
65. corneal
66. scleral
67. pupillary
68. hypoesthesia, hypesthesia
69. hyperalgesia
70. sc
71. myopia
72. miosis
73. exotropia
74. pseudosmia
75. myringoplasty
76. retinoscopy
77. salpingoscopy
78. anosmia
79. retinoschisis
80. myringoscopy
81. subretinal
82. retinopexy
83. keratoscopy
84. F; cochlea
85. T
86. T
87. T
88. F; taste
89. F; constrict
90. F; tympanic membrane
91. F; tears
92. smell; *Smell* is a special sense; the others are general senses.
93. pinna; The *pinna* is part of the outer ear; the others are parts of the inner ear.

extern.ir

94. incus; The *incus* is an ossicle of the ear; the others are structures that protect the eye.
95. presbycusis; *Presbycusis* is loss of hearing due to age; the others are disorders of the eye.
96. weakness or tiring of the eyes
    a. lack of
    b. strength
    c. eye
    d. condition of
97. condition in which a cataractous lens has been removed and replaced with a plastic lens implant
    a. false
    b. lens
    c. condition of
98. a cyst-like mass containing cholesterol
    a. bile (here, cholesterol, found in bile)
    b. fat
    c. tumor, neoplasm
99. a type of strabismus (squint) in which the eye deviates outward
    a. out
    b. turning
    c. condition of
100. unequal refractive power in the two eyes, heterometropia
    a. not, without
    b. equal, same
    c. measure
    d. eye
    e. condition of

CASE STUDY QUESTIONS

Case Study 8-1

1. c
2. b
3. d
4. b
5. suprathreshold
6. aural
7. tympanogram
8. acoustic
9. tinnitus
10. hertz
11. brainstem auditory evoked potentials

Case Study 8-2

1. b
2. d
3. ophthalmologist
4. conjunctival peritomy
5. intraocular
6. miosis
7. subconjunctival
8. intraocular lens

Chapter 9

PRETEST

1. d
2. b
3. a
4. c
5. d
6. d
7. b
8. c

CHAPTER EXERCISES

Exercise 9-1

1. condition of underactivity of the adrenal gland
2. acting on the thyroid gland
3. excision of the pituitary gland (hypophysis)
4. study of the endocrine glands or hormones
5. tumor of the pancreatic islets
6. hyperthyroidism (*hi-per-THI-royd-izm*)
7. hypoparathyroidism (*hi-po-par-ah-THI-royd-izm*)
8. hyperadrenalism (*hi-per-ah-DRE-nal-izm*)
9. hyperadrenocorticism (*hi-per-ah-dre-no-KOR-tih-sizm*)
10. hypopituitarism (*hi-po-pih-TU-ih-tah-rizm*)
11. adrenomegaly (*ah-dre-no-MEG-ah-le*)
12. thyroidectomy (*thi-roy-DEK-to-me*)
13. adrenalopathy (*ah-dre-nah-LOP-ah-the*); also, adrenopathy (*ah-dre-NOP-ah-the*)
14. endocrinologist (*en-do-krih-NOL-o-jist*)
15. insulitis (*in-su-LI-tis*)

CHAPTER REVIEW

Labeling Exercise

Glands of the Endocrine System

1. pineal
2. hypothalamus
3. pituitary (hypophysis)
4. thyroid
5. parathyroids
6. adrenals
7. pancreatic islets
8. ovaries
9. testes

Terminology

1. b
2. e
3. c
4. d
5. a
6. d
7. b
8. a
9. c
10. e
11. b
12. d
13. e
14. c
15. a
16. c
17. e
18. d
19. a
20. b
21. b
22. a
23. e
24. c
25. d
26. pituitary (hypophysis)
27. thyroid
28. adrenals
29. diabetes mellitus
30. hyperglycemia
31. incision into the thyroid gland
32. condition caused by underactivity of the pituitary gland
33. acting on the hypophysis (pituitary)
34. any disease of the adrenal gland
35. enlargement of the adrenal gland
36. physician who specializes in the study and treatment of endocrine disorders
37. insuloma
38. thyrolytic
39. adrenocortical
40. thyroiditis
41. hemithyroidectomy
42. parathyroidectomy
43. hyperadrenalism
44. thyrotropic
45. thyroptosis
46. thyropathy
47. F; ADH, antidiuretic hormone
48. T

extern.ir

49. F; cortex
50. F; calcium
51. F; thyroid
52. T
53. T
54. T
55. T
56. T
57. PTH; *PTH* is a parathyroid hormone from the parathyroid gland; the others are hormones produced by the anterior pituitary.
58. dwarfism; *Dwarfism* is caused by hyposecretion of growth hormone: the others are caused by hypersecretion of hormones.
59. TBG; *TBG* is a test of thyroid function; the others are abbreviations associated with diabetes mellitus.
60. spleen; The *spleen* is part of the immune system; the others are endocrine glands.
61. thyropathy
62. adrenotropic
63. thyromegaly
64. adrenal
65. adrenomegaly
66. insuloma
67. thyrolytic
68. adrenopathy
69. thyrotropic
70. insular
71. benign tumor of the pituitary gland
    a. cranium
    b. pharynx (the tumor arises from tissue that forms the roof of the mouth)
    c. tumor, neoplasm
72. condition of complete underactivity of the pituitary gland
    a. all
    b. under, abnormally low
    c. pituitary gland
    d. condition of
73. usually benign tumor of the adrenal medulla or any cells that stain with chromium salts (chromaffin cells)
    a. dark, dusky
    b. color
    c. cell
    d. tumor, neoplasm
74. a toxic condition caused by hyperactivity of the thyroid gland
    a. thyroid
    b. poisonous
    c. condition of
75. condition marked by enlargement of the extremities
    a. extremity
    b. enlargement
    c. condition of
76. pancreas (pancreatic islets)
77. adrenal cortex
78. thyroid
79. parathyroid
80. anterior pituitary

CASE STUDY QUESTIONS

Case Study 9-1

1. a
2. c
3. d
4. nephrectomy
5. adenoma
6. ampule
7. hypertension
8. within normal limits

Case Study 9-2

1. a
2. b
3. c
4. a
5. hyperglycemia
6. bolus
7. neutral protamine Hagedorn
8. continuous subcutaneous insulin infusion

Chapter 10

PRETEST

1. c
2. c
3. b
4. d
5. d
6. b
7. c
8. a

CHAPTER EXERCISES

Exercise 10-1

1. valve
2. atrium
3. ventricles
4. heart
5. atrial (*A-tre-al*)
6. myocardial (*mi-o-KAR-de-al*)
7. cardiac (*KAR-de-ak*)
8. valvular (*VAL-vu-lar*); also valvar (*VAL-var*)
9. ventricular (*ven-TRIK-u-lar*)
10. pericardial (*per-ih-KAR-de-al*)
11. pericarditis (*per-ih-kar-DI-tis*)
12. endocarditis (*en-do-kar-DI-tis*)
13. myocarditis (*mi-o-kar-DI-tis*)
14. cardiogenic (*kar-de-o-JEN-ik*)
15. valvotomy (*val-VOT-o-me*); also, valvulotomy (*val-vu-LOT-o-me*)
16. atrioventricular (*a-tre-o-ven-TRIK-u-lar*)
17. interatrial (*in-ter-A-tre-al*)
18. cardiology (*kar-de-OL-o-je*)

Exercise 10-2

1. vessels
2. vessel
3. aorta
4. artery
5. arteriole
6. vein
7. vessels
8. rupture of an artery
9. within the aorta
10. inflammation of a vessel or vessels
11. inflammation of a vein
12. pertaining to the heart and vessels
13. angiogram
14. aortogram
15. phlebogram; venogram
16. angioplasty (*AN-je-o-plas-te*)
17. angiopathy (*an-je-OP-ah-the*)
18. angiectasis (*an-je-EK-tah-sis*); also, hemangiectasis (*he-man-je-EK-tah-sis*)
19. angiogenesis (*an-je-o-JEN-eh-sis*)
20. phlebectomy (*fleh-BEK-to-me*); venectomy (*ve-NEK-to-me*)
21. aortosclerosis (*a-or-to-skleh-RO-sis*)
22. intravenous (*in-trah-VE-nus*)
23. arteriotomy (*ar-tere-e-OT-o-me*)

Exercise 10-3

1. tonsil
2. thymus
3. lymph node
4. lymph
5. lymphatic vessels
6. spleen
7. lymphangi/o; lymphatic vessel
8. splen/o; spleen
9. lymphaden/o; lymph node
10. tonsill/o; tonsil
11. thym/o; thymus
12. splenomegaly (*sple-no-MEG-ah-le*)
13. tonsillitis (*ton-sih-LI-tis*)

extern.ir

14. lymphadenopathy (*lim-fad-eh-NOP-ah-the*)
15. lymphangitis (*lim-fan-JI-tis*); also, lymphangiitis (*lim-fan-je-I-tis*)
16. thymic (*THI-mik*)
17. lymphoma (*lim-FO-mah*)

CHAPTER REVIEW

Labeling Exercise

The Cardiovascular System

1. right atrium
2. right ventricle
3. left pulmonary artery
4. left lung
5. right lung
6. left pulmonary vein
7. left atrium
8. left ventricle
9. aorta
10. head and arms
11. superior vena cava
12. internal organs
13. legs
14. inferior vena cava

The Heart and Great Vessels

1. superior vena cava
2. inferior vena cava
3. right atrium
4. right atrioventricular (tricuspid) valve
5. right ventricle
6. pulmonary valve
7. pulmonary trunk
8. right pulmonary artery
9. left pulmonary artery
10. left pulmonary veins
11. left atrium
12. left atrioventricular (bicuspid) valve
13. left ventricle
14. aortic valve
15. ascending aorta
16. aortic arch
17. apex
18. interventricular septum
19. endocardium
20. myocardium
21. epicardium

Location of Lymphoid Organs and Tissue

1. tonsils
2. thymus
3. spleen
4. Peyer patches
5. appendix

Terminology

1. e
2. a
3. b
4. d
5. c
6. b
7. c
8. e
9. a
10. d
11. d
12. b
13. e
14. a
15. c
16. b
17. d
18. c
19. a
20. e
21. b
22. e
23. d
24. a
25. c
26. myocardium
27. capillary
28. atrium
29. sinoatrial (SA) node
30. aorta
31. vein
32. varicose vein, varix
33. thymus
34. right atrium
35. common iliac (*IL-e-ak*) arteries
36. common carotid (*kah-ROT-id*) artery
37. inferior vena cava
38. subclavian veins
39. Holter monitor
40. atrial fibrillation
41. ablation
42. F; mitral (bicuspid)
43. F; heart
44. F; arm
45. T
46. T
47. T
48. F; pulmonary circuit
49. F; vein
50. T
51. T
52. T
53. apex; The *apex* is the pointed lower region of the heart; the others are part of the heart's conduction system.
54. murmur; A *murmur* is an abnormal heart sound; the others are terms associated with blood pressure.
55. S_1; S_1 symbolizes the first heart sound; the others are waves of the ECG.
56. cusp; A *cusp* is a flap of a heart valve; the others are lymphoid tissue.
57. without vessels
58. incision of an atrium
59. surgical removal of the spleen
60. above a ventricle
61. dilatation of a vein
62. valvotome; valvulotome (*VAL-vo-tome; VAL-vu-lo-tome*)
63. aortorrhaphy (*a-or-TOR-ah-fe*)
64. lymphadenectomy (*lim-fad-eh-NEK-to-me*)
65. cardiologist (*kar-de-OL-o-jist*)
66. lymphostasis (*lim-FOS-tah-sis*)
67. splenopexy (*SPLE-no-pek-se*)
68. aortostenosis (*a-or-to-steh-NO-sis*)
69. aortoptosis (*a-or-top-TO-sis*)
70. aortogram (*a-OR-to-gram*)
71. preaortic (*pre-a-OR-tik*)
72. ventricular
73. septal
74. valvular, valvar
75. thymic
76. sclerotic
77. splenic; splenetic
78. thrombi
79. varices
80. stenoses
81. septa
82. automated external defibrillator
83. left ventricular assist device
84. deep vein thrombosis
85. ventricular fibrillation
86. bundle branch block
87. percutaneous transluminal coronary angioplasty
88. phlebitis
89. lymphadenopathy
90. lymphoma
91. angioplasty
92. lymphangiitis; lymphangitis
93. angiopathy
94. lymphadenitis
95. phleboplasty
96. lymphadenoma
97. angioma
98. recording of the heart's sounds
    a. sound
    b. heart
    c. act of recording

extern.ir

99. excision of the inner layer of an artery thickened by atherosclerosis
    a. within
    b. artery
    c. out
    d. to cut
100. permanent dilation of small blood vessels causing small, local red lesions
    a. end
    b. vessel
    c. dilation
101. inflammation of lymphatic vessels and veins
    a. lymphatic system
    b. vessel
    c. vein
    d. inflammation

CASE STUDY QUESTIONS

Case Studies 10-1A and 10-1B

1. d
2. b
3. c
4. d
5. a
6. c
7. a
8. dyspnea
9. murmur
10. stress test
11. cardiovascular
12. endarterectomies
13. sublingual
14. cyanosis
15. diaphoresis
16. interatrial
17. substernal
18. electrocardiogram
19. acute myocardial infarction
20. coronary artery disease
21. left anterior descending
22. congestive heart failure
23. transesophageal echocardiogram
24. mitral valve replacement
25. coronary/cardiac care unit

Chapter 11

PRETEST

1. c
2. d
3. b
4. b
5. c
6. a

CHAPTER EXERCISES

Exercise 11-1

1. a decreased number of platelets in the blood
2. presence of bacteria in the blood
3. deficiency of leukocytes (white blood cells)
4. production of erythrocytes (red blood cells)
5. presence of toxins (poisons) in the blood
6. decreased protein in the blood
7. excess albumin in the blood
8. viremia (*vi-RE-me-ah*)
9. leukemia (*lu-KE-me-ah*)
10. pyemia (*pi-E-me-ah*)

Exercise 11-2

1. leuk/o; leukocytes; white blood cells
2. hem/o; blood
3. immun/o; immunity
4. hemat/o; blood
5. thromb/o; blood clot
6. myel/o; bone marrow
7. lymphocytes
8. blood
9. blood
10. bone marrow
11. erythrocytes; red blood cells
12. immunity
13. platelets; thrombocytes
14. leukocytes; white blood cells
15. leukopenia (*lu-ko-PE-ne-ah*)
16. myeloma (*mi-eh-LO-mah*)
17. lymphoblast (*LIM-fo-blast*)
18. thrombolysis (*throm-BOL-ih-sis*)
19. myelopoiesis (*mi-eh-lo-poy-E-sis*)
20. granulocytosis (*gran-u-lo-si-TO-sis*)
21. lymphocytosis (*lim-fo-si-TO-sis*)
22. erythrocytosis (*eh-rith-ro-si-TO-sis*)
23. monocytosis (*mon-o-si-TO-sis*)
24. thrombocytosis (*throm-bo-si-TO-sis*)

Exercise 11-3

1. iron
2. potassium
3. nitrogenous compounds
4. oxygen
5. iron
6. calcium
7. natremia (*na-TRE-me-ah*)
8. azotemia (*az-o-TE-me-ah*)
9. kalemia (*kah-LE-me-ah*)
10. calcemia (*kal-SE-me-ah*)

CHAPTER REVIEW

Labeling Exercise

Blood Cells

1. platelet
2. leukocyte
3. erythrocyte

Leukocytes (White Blood Cells)

1. neutrophil
2. eosinophil
3. basophil
4. lymphocyte
5. monocyte

Terminology

1. c
2. d
3. e
4. b
5. a
6. b
7. c
8. e
9. a
10. d
11. d
12. c
13. a
14. b
15. e
16. e
17. d
18. b
19. c
20. a
21. b
22. c
23. a
24. e
25. d
26. phagocytosis
27. hemoglobin
28. electrolyte
29. platelets (thrombocytes)
30. blood cells
31. oxygen
32. blood
33. anemia
34. bone marrow
35. immunoglobulin
36. c
37. a
38. c
39. b
40. b
41. F; white blood cell

extern.ir

42. T
43. T
44. T
45. F; neutrophil
46. T
47. increase in leukocytes (white blood cells) in the blood
48. increase in eosinophils in the blood
49. increase in erythrocytes (red blood cells) in the blood
50. increase in thrombocytes (platelets) in the blood
51. increase in neutrophils in the blood
52. increase in monocytes in the blood
53. erythroblast; erythrocytoblast
54. thrombocytopenia; thrombopenia
55. pyemia
56. immunologist
57. hemorrhage
58. destruction of red blood cells
59. deficiency of neutrophils
60. substance that is toxic (poisonous) to bone marrow
61. immunity to one's own tissue
62. presence of viruses in the blood
63. hemolytic (*he-mo-LIT-ik*)
64. leukemic (*lu-KE-mik*)
65. basophilic (*ba-so-FIL-ik*)
66. septicemic (*sep-tih-SE-mik*)
67. thrombotic (*throm-BOT-ik*)
68. lymphocytic (*lim-fo-SIT-ik*)
69. thrombolysis; *Thrombolysis* is destruction of a blood clot; the others pertain to formation of a blood clot.
70. EPO; *EPO* is erythropoietin, a hormone that stimulates red cell production in the bone marrow; the others are abbreviations for blood tests.
71. reticulocyte; A *reticulocyte* is an immature red blood cell; the others are types of leukocytes.
72. gamma globulin; *Gamma globulin* is the fraction of the blood plasma that contains antibodies; the others are terms associated with exaggerated immune responses.
73. erythrocytic
74. leukoblast
75. myeloid
76. myelogenic
77. myeloblast
78. leukemia
79. leukopenia; leukocytopenia
80. myeloma
81. erythropoiesis; erythrocytopoiesis
82. myelocytic
83. overall decrease in blood cells
    a. all
    b. cell
    c. deficiency
84. increase in the number of red cells in the blood; erythremia, erythrocythemia
    a. many
    b. cell
    c. blood
    d. condition of
85. unequal distribution of hemoglobin in red cells
    a. without
    b. same, equal
    c. color
    d. condition of
86. pertaining to dysfunctional bone marrow
    a. bone marrow
    b. abnormal
    c. formation
    d. condition of

CASE STUDY QUESTIONS

Case Study 11-1

1. d
2. d
3. c
4. a
5. c
6. d
7. prothrombin time
8. partial thromboplastin time
9. fresh frozen plasma
10. disseminated intravascular coagulation

Case Study 11-2

1. b
2. b
3. c
4. d
5. d
6. b
7. a
8. hemoglobin
9. hematocrit
10. red blood cell

Chapter 12

PRETEST

1. c
2. b
3. d
4. a
5. d
6. c
7. c
8. b

CHAPTER EXERCISES

Exercise 12-1

1. orthopnea (*or-THOP-ne-ah*)
2. bradypnea (*brad-ip-NE-ah*)
3. eupnea (*upe-NE-ah*)
4. dyspnea (*disp-NE-ah*)
5. orthopneic (*or-THOP-NE-ik*)
6. bradypneic (*brad-ip-NE-ik*)
7. eupneic (*upe-NE-ik*)
8. dyspneic (*disp-NE-ik*)
9. dysphonia (*dis-FO-ne-ah*)
10. hypocapnia (*hi-po-KAP-ne-ah*)
11. anoxia (*an-OK-se-ah*)
12. hypercapnia (*hi-per-KAP-ne-ah*)

Exercise 12-2

1. rhinorrhea (*ri-no-RE-ah*)
2. laryngeal (*lah-RIN-je-al*)
3. bronchitis (*brong-KI-tis*)
4. pharyngoscopy (*far-ing-GOS-ko-pe*)
5. laryngoplasty (*lah-RING-go-plas-te*)
6. tracheotomy (*tra-ke-OT-o-me*)
7. tracheostenosis (*tra-ke-o-steh-NO-sis*)
8. bronchiolitis (*brong-ke-o-LI-tis*)
9. pertaining to the bronchioles
10. near the nose
11. around a bronchus
12. within the trachea
13. pertaining to the nose and pharynx
14. dilatation of a bronchus

Exercise 12-3

1. pain in the pleura
2. within the lungs
3. surgical removal of a lung or lung tissue
4. plastic repair of a lung
5. study of the lungs
6. absence of a lung
7. surgical incision of the phrenic nerve
8. intrapleural (*in-trah-PLU-ral*)
9. supraphrenic (*su-prah-FREN-ik*)
10. pleurocentesis (*plu-ro-sen-TE-sis*)
11. pneumonopathy (*nu-mo-NOP-ah-the*)

extern.ir

12. phrenicotripsy (*fren-ih-ko-TRIP-se*)
13. spirogram (*SPI-ro-gram*)

CHAPTER REVIEW

Labeling Exercise

The Respiratory System

1. frontal sinus
2. sphenoidal sinus
3. nasal cavity
4. oral cavity
5. nasopharynx
6. oropharynx
7. laryngopharynx
8. pharynx
9. epiglottis
10. larynx
11. esophagus
12. trachea
13. right bronchus
14. left bronchus
15. bronchioles
16. right lung
17. left lung
18. mediastinum
19. diaphragm
20. terminal bronchiole
21. smooth muscle
22. alveolar duct
23. alveoli
24. capillaries

Terminology

1. e
2. a
3. b
4. c
5. d
6. b
7. a
8. e
9. c
10. d
11. d
12. a
13. c
14. e
15. b
16. b
17. c
18. a
19. d
20. e
21. b
22. a
23. e
24. d
25. c
26. bronchus
27. diaphragm
28. carbon dioxide
29. pleura
30. alveoli
31. smell, olfaction
32. lungs
33. tuberculosis
34. spirometer
35. vital capacity
36. pleural cavity
37. coughing
38. mucus
39. apnea
40. bronchodilator
41. T
42. F; inhalation
43. F; larynx
44. T
45. T
46. T
47. phrenicotomy (*fren-ih-KOT-o-me*)
48. hypopnea (*hi-POP-ne-ah*)
49. pharyngitis (*far-in-JI-tis*)
50. bronchiolitis (*brong-ke-o-LI-tis*)
51. tracheostomy (*tra-ke-OS-to-me*)
52. accumulation of air or gas in the pleural space
53. accumulation of fluid in the pleural space
54. accumulation of pus in the pleural space
55. accumulation of blood in the pleural space
56. narrowing of the trachea
57. spitting of blood
58. deficiency of oxygen in the tissues
59. any disease of the lungs
60. rapid rate of respiration
61. dilatation of a bronchus
62. plastic repair of the nose
63. pain in the pleura
64. rhin/o; nose
65. pulmon/o; lung
66. spir/o; breathing
67. phrenic/o; phrenic nerve
68. pneum/o; pertaining to air or gas
69. tachypnea
70. hypercapnia
71. inspiration
72. intrapulmonary
73. intubation
74. laryngeal
75. alveolar
76. nasal
77. tracheal
78. pleural
79. bronchial
80. nares
81. pleurae
82. alveoli
83. conchae
84. bronchi
85. tonsil; A *tonsil* is lymphatic tissue in the pharynx; the others are parts of the nose.
86. sinus; A *sinus* is a cavity or channel; the others are parts of the larynx.
87. asthma; *Asthma* is a chronic breathing problem caused by allergy and other factors; the others are infectious diseases.
88. URI; *URI* is an abbreviation for upper respiratory infection; the others are abbreviations for lobes of the lung.
89. RDS; *RDS* is respiratory distress syndrome; the others are breathing volumes or capacities.
90. aphonia
91. hypercapnia
92. dysphonia
93. hyperpnea
94. oximetry
95. dyspnea
96. hypoxia
97. eupnea
98. tachypnea
99. hyperphonia
100. device for measuring air flow
    a. air
    b. rapid, swift
    c. measure
101. incomplete expansion of the alveoli
    a. incomplete
    b. expansion, dilation
102. presence of air or gas in a blood vessel of the heart
    a. air, gas
    b. heart
    c. condition of
103. respiratory disease caused by inhalation of dust particles
    a. lung
    b. dust
    c. condition of

CASE STUDY QUESTIONS

Case Study 12-1

1. c
2. d

extern.ir

3. lobectomy
4. diaphoresis
5. thoracotomy
6. thoracoscopy
7. hemithorax
8. mediastinoscopy

Case Study 12-2

1. b
2. d
3. d
4. chronic obstructive pulmonary disease
5. arterial blood gas
6. acute respiratory distress syndrome
7. do not resuscitate

Chapter 13

PRETEST

1. a
2. c
3. c
4. b
5. b
6. d
7. c
8. a

CHAPTER EXERCISES

Exercise 13-1

1. gingival (*JIN-jih-val*)
2. lingual (*LING-gwal*); glossal (*GLOS-sal*)
3. dental (*DEN-tal*)
4. buccal (*BUK-al*)
5. labial (*LA-be-al*)
6. oral (*OR-al*); stomal (*STO-mal*)
7. teeth
8. jaw
9. teeth
10. mouth
11. mouth
12. tongue
13. salivary
14. pertaining to the cheek and pharynx
15. plastic repair or reconstruction of the gingiva
16. under the tongue
17. pertaining to the lip and teeth
18. dropping of the uvula
19. under the tongue
20. suture of the palate

Exercise 13-2

1. pyloric (*pi-LOR-ik*)
2. colic (*KOL-ik*); also colonic (*ko-LON-ik*)
3. gastric (*GAS-trik*)
4. enteric (*en-TER-ik*)
5. rectal (*REK-tal*)
6. jejunal (*jeh-JUN-al*)
7. ileal (*IL-e-al*)
8. cecal (*SE-kal*)
9. anal (*A-nal*)
10. gastroduodenal (*gas-tro-du-o-DE-nal*)
11. esophagitis (*e-sof-ah-JI-tis*)
12. enterostomy (*en-ter-OS-to-me*)
13. gastroenterology (*gas-tro-en-ter-OL-o-je*)
14. gastroscopy (*gas-TROS-ko-pe*)
15. pyloroptosis (*pi-lor-o-TO-sis*)
16. jejunoileitis (*jeh-ju-no-il-e-I-tis*)
17. ileectomy (*il-e-EK-to-me*)
18. anorectal (*a-no-REK-tal*)
19. colitis (*ko-LI-tis*)
20. colostomy (*ko-LOS-to-me*)
21. colopexy (*KO-lo-pek-se*)
22. colocentesis (*ko-lo-sen-TE-sis*)
23. colonopathy (*ko-lo-NOP-ah-the*)
24. colonoscopy (*ko-lon-OS-ko-pe*)
25. esophagogastrostomy (*e-sof-ah-go-gas-TROS-to-me*)
26. gastroenterostomy (*gas-tro-en-ter-OS-to-me*)
27. jejunojejunostomy (*jeh-ju-no-jeh-ju-NOS-to-me*)
28. duodenoileostomy (*du-o-de-no-il-e-OS-to-me*)
29. sigmoidoproctostomy (*sig-moy-do-prok-TOS-to-me*)

Exercise 13-3

1. hepatic (*heh-PAT-ik*)
2. cholecystic (*ko-le-SIS-tik*)
3. pancreatic (*pan-kre-AT-ik*)
4. hepatography (*hep-ah-TOG-rah-fe*)
5. cholecystography (*ko-le-sis-TOG-rah-fe*)
6. cholangiography (*ko-lan-je-OG-rah-fe*)
7. pancreatography (*pan-kre-ah-TOG-rah-fe*)
8. choledocholithiasis (*ko-led-o-ko-lih-THI-ah-sis*)
9. pancreatolithiasis (*pan-kre-ah-to-lih-THI-ah-sis*)
10. hepatitis (*hep-ah-TI-tis*)
11. bile
12. gallstone; biliary calculus
13. common bile duct
14. gallbladder
15. liver
16. bile duct
17. pancreas

CHAPTER REVIEW

Labeling Exercise

The Digestive System

1. mouth
2. tongue
3. teeth
4. salivary glands
5. pharynx
6. esophagus
7. stomach
8. duodenum (of small intestine)
9. small intestine
10. appendix
11. cecum
12. ascending colon
13. transverse colon
14. descending colon
15. sigmoid colon
16. rectum
17. anus
18. liver
19. gallbladder
20. pancreas

Accessory Organs of Digestion

1. liver
2. common hepatic duct
3. gallbladder
4. cystic duct
5. common bile duct
6. pancreas
7. pancreatic duct
8. duodenum
9. diaphragm

Terminology

1. d
2. c
3. b
4. e
5. a
6. c
7. a
8. d
9. b
10. e
11. b
12. c
13. d
14. e
15. a

extern.ir

16. c
17. a
18. d
19. e
20. b
21. d
22. b
23. a
24. c
25. e
26. c
27. a
28. e
29. b
30. d
31. bariatric surgery
32. cecum
33. liver
34. gallbladder
35. peritoneum
36. tongue
37. palate
38. tooth
39. cheek
40. intestine
41. liver
42. bile
43. hiatal hernia
44. dysphagia
45. stomach acid
46. hepatomegaly
47. periodontist
48. gastrectomy
49. palatorrhaphy
50. pylorostenosis
51. pancreatitis
52. gastroenterologist
53. colostomy
54. gastroduodenostomy
55. intrahepatic
56. diverticula
57. gingivae
58. calculi
59. anastomoses
60. hiatal hernia
61. dyspepsia
62. inguinal hernia
63. icterus
64. pyloric stenosis
65. diarrhea
66. F; above
67. F; jejunum
68. F; saliva
69. T
70. T
71. T
72. F; vomiting
73. T
74. villus; A *villus* is a tiny projection in the lining of the small intestine that aids in absorption of nutrients; the others are parts of the mouth.
75. spleen; The *spleen* is a lymphoid organ; the others are parts of the large intestine.
76. pylorus; The *pylorus* is the distal portion of the stomach; the others are accessory digestive organs.
77. amylase; *Amylase* is a starch-digesting enzyme; the others are disorders of the digestive tract.
78. nausea and vomiting
79. nasogastric
80. total parenteral nutrition
81. gastroesophageal reflux disease
82. esophagogastroduodenoscopy
83. gastrointestinal
84. hydrochloric acid
85. proton pump inhibitor
86. percutaneous endoscopic gastrostomy (tube)
87. hepatitis A virus
88. cecitis
89. proctorrhaphy
90. cecopexy
91. proctocele
92. ileocecal
93. ileopexy
94. proctitis
95. cecorrhaphy
96. ileitis
97. pertaining to the muscular layer of the intestine
    a. muscle
    b. intestine
    c. pertaining to
98. radiography of the biliary tract and gallbladder using radionuclides
    a. bile
    b. spark (radiation)
    c. act of recording data
99. referring to any route other than the alimentary canal
    a. beside
    b. intestine
    c. pertaining to
100. pertaining to the nose and stomach
    a. nose
    b. stomach
    c. pertaining to
101. pertaining to a dry mouth
    a. dry
    b. mouth
    c. pertaining to

CASE STUDY QUESTIONS

Case Study 13-1

1. c
2. b
3. b
4. a
5. d
6. a
7. endoscopic retrograde cholangiopancreatography
8. right upper quadrant
9. nasogastric
10. cholelithiasis
11. laparoscopic cholecystectomy
12. cholecystitis
13. cholangiogram

Case Study 13-2

1. b
2. b
3. b
4. d
5. a
6. d
7. b
8. inflammatory bowel disease
9. barium enema
10. irritable bowel syndrome
11. anal sphincter
12. biopsy
13. dysphagia

Chapter 14

PRETEST

1. d
2. c
3. c
4. a
5. c
6. d
7. d
8. b

CHAPTER EXERCISES

Exercise 14-1

1. prerenal (*pre-RE-nal*)
2. postrenal (*post-RE-nal*)
3. suprarenal (*su-prah-RE-nal*)
4. perirenal (*per-ih-RE-nal*); circumrenal (*sir-kum-RE-nal*)
5. nephrologist (*neh-FROL-o-jist*)

extern.ir

6. nephropathy (*neh-FROP-ah-the*)
7. nephrotoxic (*nef-ro-TOK-sik*)
8. nephromalacia (*nef-ro-mah-LA-she-ah*)
9. nephromegaly (*neh-fro-MEG-ah-le*)
10. nephrotomy (*neh-FROT-o-me*)
11. pyelonephritis (*pi-eh-lo-nef-RI-tis*)
12. pyeloplasty (*pi-eh-lo-PLAS-te*)
13. pyelogram (*PI-eh-lo-gram*)
14. glomerulitis (*glo-mer-u-LI-tis*)
15. calicotomy (*kal-ih-KOT-o-me*); caliotomy (*ka-le-OT-o-me*)
16. glomerulosclerosis (*glo-mer-u-lo-skleh-RO-sis*)
17. caliectasis (*ka-le-EK-tah-sis*); calicectasis (*kal-ih-SEK-tah-sis*)

Exercise 14-2

1. uropathy (*u-ROP-ah-the*)
2. urography (*u-ROG-rah-fe*)
3. urolith (*U-ro-lith*)
4. uremia (*u-RE-me-ah*)
5. anuria (*an-U-re-ah*)
6. pyuria (*pi-U-re-ah*)
7. nocturia (*nokt-U-re-ah*)
8. dysuria (*dis-U-re-ah*)
9. hematuria (*he-mah-TU-re-ah*)
10. diuresis (*di-u-RE-sis*)
11. anuresis (*an-u-RE-sis*)
12. natriuresis (*na-tre-u-RE-sis*)
13. kaliuresis (*ka-le-u-RE-sis*)
14. urethropexy (*u-RE-thro-pek-se*)
15. ureterostomy (*u-re-ter-OS-to-me*)
16. urethrorrhaphy (*u-re-THROR-ah-fe*)
17. urethroscopy (*u-re-THROS-ko-pe*)
18. ureterocele (*u-RE-ter-o-sele*)
19. cystitis (*sis-TI-tis*)
20. cystography (*sis-TOG-rah-fe*)
21. cystoscope (*SIS-to-skope*)
22. cystotomy (*sis-TOT-o-me*)
23. cystorrhea (*sis-to-RE-ah*)
24. supravesical (*su-prah-VES-ih-kal*)
25. urethrovesical (*u-re-thro-VES-ih-kal*)
26. pain in the urinary bladder
27. surgical incision of the ureter
28. through the urethra
29. formation of urine

CHAPTER REVIEW

Labeling Exercise

The Urinary System

1. kidney
2. ureter
3. urinary bladder
4. urethra
5. aorta
6. renal artery
7. renal vein
8. inferior vena cava
9. diaphragm
10. adrenal gland

Kidney

1. renal capsule
2. renal cortex
3. renal medulla
4. pyramids of medulla
5. nephrons
6. calyx
7. hilum
8. renal pelvis
9. ureter

Urinary Bladder

1. ureter
2. smooth muscle
3. openings of ureters
4. trigone
5. urethra
6. internal urethral sphincter
7. external urethral sphincter
8. peritoneum
9. prostate

Terminology

1. a
2. c
3. d
4. b
5. e
6. d
7. e
8. b
9. a
10. c
11. d
12. b
13. e
14. a
15. c
16. a
17. b
18. c
19. e
20. d
21. hydronephrosis
22. glomerulus
23. renin
24. urination; voiding of urine
25. urinalysis
26. urea
27. incontinence; stress incontinence
28. clean-catch specimen
29. cystoscopy
30. F; kidney
31. T
32. T
33. F; medulla
34. F; urethra
35. T
36. T
37. F; sodium
38. narrowing of the urethra
39. elimination of large amounts of urine
40. toxic or poisonous to the kidney
41. near the glomerulus
42. surgical removal of a calyx
43. near the kidney
44. nephrologist
45. pyelocaliectasis; pyelocalicectasis
46. nephromalacia
47. cystectomy
48. nephropathy
49. cystourethrogram
50. ureteropyeloplasty
51. pyelonephritis
52. ureterosigmoidostomy
53. cast; A *cast* is a solid mold of a renal nephron; the others are parts of the kidney.
54. calyx; A *calyx* is a collecting region for urine in the kidney; the others are parts of a nephron.
55. specific gravity; *Specific gravity* is a measure of density; the others are treatment procedures for the urinary system.
56. hydration
57. hypervolemia
58. antidiuretic
59. hypernatremia
60. anuresis
61. ureteral
62. nephrologic
63. uremic
64. diuretic
65. nephrotic
66. caliceal; calyceal
67. urethral
68. pelves
69. calyces
70. glomeruli
71. b
72. d
73. f
74. c
75. a
76. e

extern.ir

77. g
78. urography
79. renal
80. intrarenal
81. renography
82. intravesical
83. suprarenal
84. urology
85. interrenal
86. vesical
87. urolith
88. specific gravity
89. antidiuretic hormone
90. erythropoietin
91. intravenous pyelography
92. sodium
93. glomerular filtration rate
94. urinalysis
95. removal of substances from the blood by passage through a semipermeable membrane
    a. blood
    b. through
    c. separation
96. test that measures and records bladder function
    a. urinary bladder
    b. measure
    c. act of recording data
97. surgical creation of a new passage between a ureter and the bladder
    a. ureter
    b. new
    c. bladder
    d. surgical creation of an opening

CASE STUDY QUESTIONS

Case Study 14-1

1. c
2. d
3. IV urogram
4. hematuria
5. cystoscopic
6. nephrolithotomy
7. nocturia
8. lithotripsy

Case Study 14-2

1. d
2. a
3. oliguria
4. kidney transplantation
5. continuous ambulatory peritoneal dialysis
6. blood urea nitrogen
7. end-stage renal disease
8. human immunodeficiency virus

Chapter 15

PRETEST

1. c
2. d
3. a
4. b
5. b
6. d

CHAPTER EXERCISES

Exercise 15-1

1. formation (-genesis) of spermatozoa
2. pain in the prostate
3. plastic repair of the scrotum
4. excision of the epididymis
5. pain in the testis
6. any disease of a testis
7. inflammation of the testis and epididymis
8. orchiopexy (*or-ke-o-PEK-se*); also, orchidopexy (*or-kih-do-PEK-se*)
9. orchioplasty (*OR-ke-o-plas-te*); also, orchidoplasty (*OR-kih-do-plas-te*)
10. orchiectomy (*or-ke-EK-to-me*); also, orchidectomy (*or-kih-DEK-to-me*)
11. spermaturia (*sper-mah-TU-re-ah*)
12. spermatolysis (*sper-mah-TOL-ih-sis*)
13. spermatorrhea (*sper-mah-to-RE-ah*)
14. oligospermia (*ol-ih-go-SPER-me-ah*)
15. spermatocyte (*sper-MAH-to-site*)
16. hemospermia (*he-mo-SPER-me-ah*); also, hematospermia (*he-mah-to-SPER-me-ah*)
17. aspermia (*ah-SPER-me-ah*)
18. polyspermia (*pol-e-SPER-me-ah*)
19. pyospermia (*pi-o-SPER-me-ah*)
20. vasectomy (*vah-SEK-to-me*)
21. oscheoma (*os-ke-O-mah*)
22. vasorrhaphy (*vas-OR-ah-fe*)
23. prostatectomy (*pros-tah-TEK-to-me*)
24. vesiculography (*veh-sik-u-LOG-rah-fe*)
25. vesiculitis (*veh-sik-u-LI-tis*)
26. epididymotomy (*ep-ih-did-ih-MOT-o-me*)

CHAPTER REVIEW

Labeling Exercise

Male Reproductive System

1. scrotum
2. testis
3. epididymis
4. ductus (vas) deferens
5. ejaculatory duct
6. urethra
7. penis
8. glans penis
9. prepuce (foreskin)
10. seminal vesicle
11. prostate
12. bulbourethral gland
13. ureter
14. urinary bladder
15. pubic bone
16. rectum
17. anus

Terminology

1. a
2. c
3. e
4. b
5. d
6. a
7. c
8. b
9. d
10. e
11. b
12. e
13. d
14. a
15. c
16. e
17. a
18. d
19. c
20. b
21. testosterone
22. bulbourethral glands
23. semen
24. testis
25. inguinal canal
26. scrotum
27. suture of the vas (ductus) deferens
28. absence of a testis
29. tumor of the scrotum
30. radiographic study of the seminal vesicles
31. instrument for measuring the prostate
32. presence of blood in the semen
33. orchiopexy; orchidopexy

extern.ir

34. oscheolith
35. epididymotomy
36. oscheoplasty
37. vasovasostomy
38. hematuria
39. dysuria
40. intravesical
41. hyperplasia
42. resectoscope
43. T
44. F; semen
45. T
46. T
47. F; urethra
48. T
49. T
50. spermatic cord; The *spermatic cord* suspends the testis in the scrotum and contains the ductus deferens, nerves, and vessels; the others are the glands that contribute to semen.
51. semen; *Semen* is the secretion that transports spermatozoa; the others are hormones active in reproduction.
52. hernia; A *hernia* is a protrusion of tissue through an abnormal body opening; the others are sexually transmitted infections.
53. seminal
54. prostatic
55. penile
56. urethral
57. scrotal
58. benign prostatic hyperplasia
59. sexually transmitted infection
60. erectile dysfunction
61. gonococcus
62. prostate-specific antigen
63. genitourinary
64. transurethral resection of prostate
65. d
66. e
67. c
68. b
69. a
70. f
71. vasoplasty
72. spermatolysis
73. vesicular
74. vasography
75. vesiculitis
76. spermatic
77. spermatocyte
78. vasotomy
79. spermatogenesis
80. vesiculography
81. removal of a hydrocele by fluid drainage or partial excision
    a. fluid, water
    b. hernia, localized dilatation
    c. out
    d. cut
    e. condition of
82. destructive to sperm cells
    a. sperm
    b. agent that kills
    c. pertaining to
83. undescended testis
    a. hidden
    b. testis
    c. condition of
84. inflammation of the ductus deferens and seminal vesicle
    a. vas (ductus) deferens
    b. seminal vesicle
    c. inflammation
85. abnormally profuse spermatic secretion
    a. many
    b. sperm
    c. condition of

CASE STUDY QUESTIONS

Case Study 15-1

1. d
2. a
3. b
4. bilateral inguinal herniorrhaphy
5. strangulated hernia
6. balanitis
7. phimosis

Case Study 15-2

1. d
2. d
3. d
4. b
5. psychogenic
6. vasodilation
7. antihypertensive

Chapter 16

PRETEST

1. c
2. b
3. c
4. b
5. c
6. b
7. a
8. c

CHAPTER EXERCISES

Exercise 16-1

1. any disease of women
2. between menstruation periods
3. formation of an ovum
4. release of an ovum from the ovary
5. pertaining to an ovary
6. inflammation of an ovary
7. ovariorrhexis (*o-var-e-o-REK-sis*)
8. ovulatory (*OV-u-lah-to-re*)
9. menorrhagia (*men-o-RA-je-ah*)
10. oligomenorrhea (*ol-ih-go-men-o-RE-ah*)
11. amenorrhea (*ah-men-o-RE-ah*)
12. dysmenorrhea (*DIS-men-o-re-ah*)
13. ovariotomy (*o-var-e-OT-o-me*)
14. ovariocentesis (*o-var-e-o-sen-TE-sis*)
15. ovariocele (*o-VAR-e-o-sele*)
16. oophoroplasty (*o-of-or-o-PLAS-te*)
17. oophoroma (*o-of-o-RO-mah*)

Exercise 16-2

1. radiographic examination of the uterus
2. softening of the uterus
3. plastic repair of the vagina
4. pain in the vagina
5. excision of a uterine tube, fallopian tube
6. pertaining to the uterus and urinary bladder
7. within the cervix
8. salpingopexy (*sal-PING-go-pek-se*)
9. salpingography (*sal-ping-GOG-rah-fe*)
10. hydrosalpinx (*hi-dro-SAL-pinx*)
11. pyosalpinx (*pi-o-SAL-pinx*)
12. salpingo-oophorectomy (*sal-ping-go-o-of-o-REK-to-me*); also, salpingo-ovariectomy (*sal-ping-go-o-var-e-EK-to-me*)
13. hysteropexy (*his-ter-o-PEK-se*)
14. uterine (*U-ter-in*)
15. metrostenosis (*me-tro-steh-NO-sis*)
16. hysterosalpingogram (*his-ter-o-sal-PING-go-gram*)
17. transcervical (*trans-SER-vih-kal*)
18. metroptosis (*me-trop-TO-sis*)
19. colpocele (*KOL-po-sele*)
20. vaginitis (*vaj-ih-NI-tis*)

Exercise 16-3

1. vulvectomy (*vul-VEK-to-me*)
2. episiorrhaphy (*eh-piz-e-OR-ah-fe*)

extern.ir

3. vaginoperineal (*vaj-ih-no-per-ih-NE-al*)
4. clitoromegaly (*klit-or-o-MEG-ah-le*)
5. mammogram (*MAM-o-gram*)
6. mastitis (*mas-TI-tis*)
7. mastectomy (*mas-TEK-to-me*); also, mammectomy (*mah-MEK-to-me*)

Exercise 16-4

1. before birth
2. formation of an embryo
3. pertaining to a newborn
4. endoscopic examination of the fetus
5. developing in, or pertaining to, one amniotic sac
6. lack of milk production
7. decreased secretion of milk
8. embryology (*em-bre-OL-o-je*)
9. postnatal (*post-NA-tal*)
10. amniotomy (*am-ne-OT-o-me*)
11. amniocyte (*AM-ne-o-site*)
12. embryopathy (*em-bre-OP-ah-the*)
13. fetoscope (*FE-to-skope*)
14. amniorrhexis (*am-ne-o-REK-sis*)
15. neonatology (*ne-o-na-TOL-o-je*)
16. primigravida (*prih-mih-GRAV-ih-dah*)
17. multigravida (*mul-tih-GRAV-ih-dah*)
18. nullipara (*nul-IP-ah-rah*)
19. primipara (*prih-MIP-ah-rah*)
20. xerotocia (*ze-ro-TO-se-ah*)
21. bradytocia (*brad-e-TO-se-ah*)
22. galactorrhea (*gah-lak-to-RE-ah*); also, lactorrhea (*lak-to-RE-ah*)
23. galactocele (*ga-hLAK-to-sele*); also, lactocele (*LAK-to-sele*)

CHAPTER REVIEW

Labeling Exercise

The Female Reproductive System

1. ovary
2. uterine tube
3. uterus
4. cervix
5. posterior fornix
6. rectouterine pouch
7. vagina
8. clitoris
9. labium minus
10. labium majus
11. urinary bladder
12. urethra
13. pubic symphysis
14. rectum
15. anus

Ovulation and Fertilization

1. ovary
2. fimbriae
3. ovum
4. sperm cells (spermatozoa)
5. uterine tube
6. implanted embryo
7. body of uterus
8. cervix
9. vagina
10. greater vestibular (Bartholin) gland

Terminology

1. c
2. d
3. e
4. a
5. b
6. c
7. b
8. a
9. e
10. d
11. d
12. c
13. e
14. b
15. a
16. b
17. e
18. c
19. d
20. a
21. d
22. b
23. e
24. c
25. a
26. colposcope
27. ovary
28. rectocele
29. ovum (egg cell)
30. placenta
31. lactation
32. abortion
33. uterus
34. breasts (mammary glands)
35. T
36. F; embryo
37. F; myometrium
38. F; corpus luteum
39. F; uterine tube
40. T
41. T
42. T
43. T
44. behind the uterus
45. any disease of the uterus
46. softening of the uterus
47. pus in the uterine tube (fallopian tube)
48. narrowing of the vagina
49. pain in the vulva
50. after birth
51. below the mammary gland (breast)
52. outside the embryo
53. woman who has given birth three times
54. causing fetal abnormalities
55. salpingocele
56. episiorrhaphy
57. metrostenosis
58. hysterosalpingectomy
59. mammogram
60. dystocia
61. amniorrhexis
62. embryology
63. fetometry
64. gravida
65. fundus
66. pelvimetry
67. suprapubic
68. Apgar score
69. neonate
70. polyhydramnios
71. prenatal
72. eutocia
73. anovulatory
74. intrauterine
75. cervical
76. uterine
77. perineal
78. vaginal
79. embryonic
80. amniotic
81. ova
82. cervices
83. fimbriae
84. labia
85. candidiasis; *Candidiasis* is a fungal infection; the others are procedures used to diagnose fetal abnormalities.
86. measles; *Measles* is an infectious disease; the others are hereditary disorders.
87. colostrum; *Colostrum* is the breast fluid released before milk is produced; the others are hormones involved in reproduction.

extern.ir

88. labia majora; The *labia majora* are part of the vulva; the others are associated with pregnancy.
89. spina bifida; *Spina bifida* is a congenital spinal defect; the others are disorders of pregnancy.
90. c
91. b
92. a
93. d
94. episioplasty
95. cervicitis
96. mammography
97. mammoplasty
98. cervicography
99. episiotomy
100. intracervical
101. cervicoplasty
102. cervicotomy
103. transcervical
104. human chorionic gonadotropin
105. dysfunctional uterine bleeding
106. last menstrual period
107. fetal heart rate
108. gestational age
109. vaginal birth after cesarean section
110. prevention of blood vessel formation
    a. against
    b. vessel
    c. origin, formation
    d. condition of
111. excessive development of the mammary glands in the male, even to the secretion of milk
    a. woman
    b. breast
    c. condition of
112. extreme rapidity of labor
    a. sharp, acute
    b. labor
    c. condition of
113. a deficiency of amniotic fluid
    a. few, scanty
    b. fluid
    c. amnion
114. flow of milk from the breast other than normal lactation
    a. milk
    b. flow or discharge
115. congenital absence of a brain
    a. without
    b. brain
    c. pertaining to

CASE STUDY QUESTIONS

Case Study 16-1

1. b
2. c
3. b
4. a
5. b
6. dilatation and curettage
7. bilateral salpingo-oophorectomy
8. hormone replacement therapy
9. total abdominal hysterectomy
10. gynecologist

Case Study 16-2

1. zygote
2. oocyte
3. follicular
4. in vitro fertilization
5. zygote intrafallopian transfer
6. gamete intrafallopian transfer

extern.ir

Glossary

A

abdominal cavity (ab-DOM-ih-nal) The large ventral cavity below the diaphragm and above the pelvic cavity

abdominopelvic cavity (ab-dom-ih-no-PEL-vik) The large ventral cavity between the diaphragm and pelvis that includes the abdominal and pelvic cavities

ablation (ab-LA-shun) Removal or destruction. In cardiac ablation, a catheter is used to destroy a portion of the heart's conduction pathway to correct an arrhythmia

abortion (ah-BOR-shun) Termination of a pregnancy before the fetus is capable of surviving outside the uterus, usually at 20 weeks or 500 g; may be spontaneous or induced; a spontaneous abortion is commonly called a miscarriage

accommodation (ah-kom-o-DA-shun) Adjustment of the lens's curvature to allow for vision at various distances

acetabulum (as-eh-TAB-u-lum) The bony socket in the hip bone that holds the head of the femur (from the Latin word for vinegar because it resembles the base of a vinegar cruet)

acetylcholine (ACh) (as-eh-til-KO-lene) A neurotransmitter that stimulates contraction of skeletal muscles

acidosis (as-ih-DO-sis) Excessive acidity of body fluids

acoustic neuroma (ah-KU-stik nu-RO-mah) A tumor of the eighth cranial nerve sheath; although benign, it can press on surrounding tissue and produce symptoms; also called an acoustic or vestibular schwannoma or acoustic neurilemmoma

acquired immunodeficiency syndrome (AIDS) (ah-KWI-erd im-u-no-de-FISH-en-se SIN-drome) Immune system failure caused by infection with HIV (human immunodeficiency virus); the virus infects certain T cells and thus interferes with immunity

acromegaly (ak-ro-MEG-ah-le) Overgrowth of bone and soft tissue, especially in the hands, feet, and face, caused by excess growth hormone in an adult; the name comes from acro meaning "extremity" and megal/o meaning "enlargement"

acronym (AK-ro-nim) An abbreviation formed from the first letter of each word in a phrase

actin (AK-tin) One of the two contractile proteins in muscle cells; the other is myosin

acupuncture (AK-u-punk-chur) An ancient Chinese method of inserting thin needles into the body at specific points to relieve pain, induce anesthesia, or promote healing; similar effects can be obtained by using firm finger pressure at the surface of the body in the technique of acupressure

acute (ah-KUTE) Sudden, severe; having a short course

acute respiratory distress syndrome (ARDS) Pulmonary edema that can lead rapidly to fatal respiratory failure; causes include trauma, aspiration into the lungs, viral pneumonia, and drug reactions; shock lung

acute rhinitis (ri-NI-tis) Inflammation of the nasal mucosa with sneezing, tearing, and profuse secretion of watery mucus, as seen in the common cold

Addison disease A disease resulting from deficiency of adrenocortical hormones; it is marked by darkening of the skin, weakness, and alterations in salt and water balance

adenoids (AD-eh-noyds) Lymphoid tissue located in the nasopharynx; the pharyngeal tonsils

adenoma (ad-eh-NO-mah) A neoplasm of a gland

adenosine triphosphate (ATP) (ah-DEN-o-sene tri-FOS-fate) The energy compound of the cell that stores energy needed for cell activities

adrenal gland (ah-DRE-nal) A gland on the superior surface of the kidney; the outer region (cortex) secretes steroid hormones; the inner region (medulla) secretes epinephrine (adrenaline) in response to stress (root: adren/o)

adrenaline (ah-DREN-ah-lin) See epinephrine

adult hypothyroidism (hi-po-THI-royd-izm) A condition caused by hypothyroidism in an adult; there is dry, waxy swelling, most notable in the face; formerly called myxedema (miks-eh-DE-mah)

afferent (AF-er-ent) Carrying toward a given point, such as the sensory neurons and nerves that carry impulses toward the CNS (root fer means "to carry")

age-related macular degeneration (AMD) (MAK-u-lar de-jen-er-A-shun) Deterioration of the macula associated with aging; macular degeneration impairs central vision

agonist A muscle that carries out a given movement (from Greek agon meaning "contest," "struggle")

agranulocyte (A-gran-u-lo-site) A white blood cell that does not have visible granules in its cytoplasm; agranulocytes include lymphocytes and monocytes

albumin (al-BU-min) A simple protein found in blood plasma

alkaline phosphatase (AL-kah-lin FOS-fah-tase) An enzyme needed in the formation of bone; serum activity of this enzyme is useful in diagnosis

alkalosis (al-kah-LO-sis) Abnormal alkalinity of body fluids; respiratory alkalosis is caused by abnormally low carbon dioxide levels

allergen (AL-er-jen) A substance that causes an allergic response

allergy (AL-er-je) Hypersensitivity

alveoli (al-VE-o-li) The tiny air sacs in the lungs through which gases are exchanged between the atmosphere

extern.ir

and the blood in respiration (singular: alveolus); an alveolus, in general, is a small hollow or cavity; the term also applies to the bony socket for a tooth

Alzheimer disease (AD) (ALTS-hi-mer) A form of dementia caused by atrophy of the cerebral cortex; presenile dementia

amniocentesis (am-ne-o-sen-TE-sis) Transabdominal puncture of the amniotic sac to remove amniotic fluid for testing; tests on the cells and fluid obtained can reveal congenital abnormalities, blood incompatibility, and sex of the fetus

amniotic sac (am-ne-OT-ik) The membranous sac filled with fluid that holds the fetus; also called amnion (root: amnio)

amyloid (AM-ih-loyd) A starch-like substance of unknown composition that accumulates in the brain in Alzheimer and other diseases

amyotrophic lateral sclerosis (ALS) (ah-mi-o-TROF-ik) A disease caused by motor neuron degeneration resulting in muscular weakness and atrophy; Lou Gehrig disease

anaphylactic reaction (an-ah-fih-LAK-tik) An exaggerated allergic reaction to a foreign substance; it may lead to death caused by circulatory collapse and respiratory distress if untreated; also called anaphylaxis (from Greek phylaxis, meaning "protection")

anaphylaxis (an-ah-fih-LAK-sis) An extreme allergic reaction that can lead to respiratory distress, circulatory collapse, and death

anastomosis (ah-nas-to-MO-sis) A passage or communication between two vessels or organs; may be normal or pathologic or may be created surgically

anatomic position (an-ah-TOM-ik) Standard position for anatomic studies, in which the body is erect and facing forward, the arms are at the sides with palms forward, and the feet are parallel

androgen (AN-dro-jen) Any hormone that produces male characteristics (root andr/o means "male")

anemia (ah-NE-me-ah) A deficiency in the amount of hemoglobin in the blood; may result from blood loss, malnutrition, a hereditary defect, environmental factors, and other causes

anencephaly (an-en-SEF-ah-le) Congenital absence of a brain

anesthesia (an-es-THE-ze-ah) Loss of the ability to feel pain, as by administration of a drug

aneurysm (AN-u-rizm) A localized abnormal dilation of a blood vessel that results from weakness of the vessel wall, usually of an artery; may eventually burst

angina pectoris (an-JI-nah PEK-to-ris) A feeling of constriction around the heart or pain that may radiate to the left arm or shoulder, usually brought on by exertion; caused by insufficient blood supply to the heart

angioedema (an-je-o-eh-DE-mah) A localized edema with large hives (wheals) similar to urticaria but involving deeper layers of the skin and subcutaneous tissue

angioplasty (AN-je-o-plas-te) A procedure that reopens a narrowed vessel and restores blood flow; commonly accomplished by surgically removing plaque, inflating a balloon within the vessel, or installing a device (stent) to keep the vessel open

angiotensin (an-je-o-TEN-sin) A substance that increases blood pressure; activated in the blood by renin, an enzyme produced by the kidneys

ankylosing spondylitis (ang-kih-LO-sing spon-dih-LI-tis) A chronic, progressive inflammatory disease involving the spinal joints and surrounding soft tissue, most common in young males; also called rheumatoid spondylitis

ankylosis (ang-kih-LO-sis) Immobility and fixation of a joint

antagonist (an-TAG-o-nist) The muscle that opposes an agonist; it must relax when the agonist contracts; also a substance that interferes with or opposes the action of a drug

antibody (AN-tih-bod-e) A protein produced in response to and interacting specifically with an antigen

antidiuretic hormone (ADH) (an-te-di-u-RET-ik) A hormone released from the pituitary gland that causes water reabsorption in the kidneys, thus concentrating the urine

antigen (AN-tih-jen) A substance that induces the formation of an antibody

antigen-presenting cell (APC) Immune cell that takes in a foreign antigen, processes it, and presents it on the cell surface in combination with the body's own proteins, thus activating a T cell; examples are dendritic cells and macrophages, which are descendants of monocytes

antiinflammatory agent Drug that reduces inflammation; includes steroids, such as hydrocortisone, and nonsteroidal antiinflammatory drugs (NSAIDs)

anus (A-nus) The distal opening of the digestive tract (root: an/o)

anxiety (ang-ZI-eh-te) A feeling of fear, worry, uneasiness, or dread

aorta (a-OR-tah) The largest artery; it receives blood from the left ventricle and branches to all parts of the body (root: aort/o)

aortic valve (a-OR-tik) The valve at the entrance to the aorta

apex (A-peks) The point of a cone-shaped structure (adjective: apical); the apex of the heart is formed by the left ventricle and is pointed toward the inferior and left

Apgar score (AP-gar) A system of rating an infant's physical condition immediately after birth; five features are rated as 0, 1, or 2 at 1 and 5 minutes after delivery and sometimes thereafter; the maximum possible score at each test interval is 10; infants with low scores require medical attention

aphasia (ah-FA-ze-ah) Specifically, loss or defect in speech communication (from Greek phasis, meaning "speech"); in practice, the term is applied more broadly to a range of language disorders, both spoken and written, that may affect the ability to understand speech (receptive aphasia) or the ability to produce speech (expressive aphasia); both forms are combined in global aphasia

aplastic anemia (a-PLAS-tik) Anemia caused by bone marrow failure resulting in deficient blood cell production, especially of red cells; pancytopenia

appendicitis (ah-pen-dih-SI-tis) Inflammation of the appendix

appendix (ah-PEN-diks) An appendage; usually means the narrow tube of lymphatic tissue attached to the cecum, the vermiform (worm-like) appendix

extern.ir

aqueous humor (AK-we-us) Fluid that fills the eye anterior to the lens

arachnoid mater (ah-RAK-noyd) The middle layer of the meninges (from the Greek word for spider, because this tissue resembles a spider web)

arrhythmia (ah-RITH-me-ah) Any abnormality in the rate or rhythm of the heartbeat (literally "without rhythm"; note doubled r); also called dysrhythmia

arterial blood gases (ABGs) The concentrations of gases, specifically oxygen and carbon dioxide, in arterial blood; reported as the partial pressure (P) of the gas in arterial (a) blood, such as PaO_2 or $PaCO_2$; these measurements are important in measuring the acid–base balance

arteriole (ar-TE-re-ole) A small vessel that carries blood from the arteries into the capillaries (root: arteriol/o)

arteriosclerosis (ar-tere-e-o-skler-O-sis) Hardening (sclerosis) of the arteries, with loss of capacity and loss of elasticity, as from fatty deposits (plaque), deposit of calcium salts, or scar tissue formation

artery (AR-teh-re) A vessel that carries blood away from the heart; all except the pulmonary and umbilical arteries carry oxygenated blood (roots: arter, arteri/o)

arthritis (ar-THRI-tis) Inflammation of a joint

arthrocentesis (ar-thro-sen-TE-sis) Aspiration of fluid from a joint by needle puncture

arthrodesis (ar-THROD-eh-sis) Surgical immobilization (fusion) of a joint; artificial ankylosis

arthroplasty (AR-thro-plas-te) Partial or total replacement of a joint with a prosthesis

arthroscopy (ar-THROS-ko-pe) Use of an endoscope to examine the interior of a joint or to perform surgery on the joint; the instrument used is an arthroscope

articulation (ar-tik-u-LA-shun) A joint (adjective: articular)

artificial pacemaker A battery-operated device that generates electrical impulses to regulate the heartbeat; it may be external or implanted, may be designed to respond to need, and may have the capacity to prevent tachycardia

ascites (ah-SI-teze) Accumulation of fluid in the abdominal cavity; a form of edema; may be caused by heart disease, lymphatic or venous obstruction, cirrhosis, or changes in blood plasma composition

aspiration (as-pih-RA-shun) The accidental inhalation of food or other foreign material into the lungs; also means the withdrawal of fluid from a cavity by suction

asthma (AZ-mah) A disease characterized by dyspnea and wheezing caused by spasm of the bronchial tubes or swelling of their mucous membranes

astigmatism (ah-STIG-mah-tizm) An error of refraction caused by irregularity in the curvature of the cornea or lens

astrocytoma (as-tro-si-TO-mah) A neuroglial tumor composed of astrocytes

atelectasis (at-eh-LEK-tah-sis) Incomplete expansion of a lung or part of a lung; lung collapse; may be present at birth (as in respiratory distress syndrome) or be caused by bronchial obstruction or compression of lung tissue (prefix atel/o means "imperfect")

atherosclerosis (ath-er-o-skler-O-sis) The development of fatty, fibrous patches (plaques) in the lining of arteries, causing narrowing of the lumen and hardening of the vessel wall; the most common form of arteriosclerosis (hardening of the arteries) (root ather/o means "porridge" or "gruel")

atlas (AT-las) The first cervical vertebra (root: atlant/o)

atopic dermatitis (ah-TOP-ik der-mah-TI-tis) Hereditary, allergic, chronic skin inflammation with pruritus (itching); eczema

atresia (ah-TRE-ze-ah) Congenital absence or closure of a normal body opening

atrioventricular (AV) node (a-tre-o-ven-TRIK-u-lar) A small mass in the lower septum of the right atrium that passes impulses from the sinoatrial (SA) node toward the ventricles

atrioventricular (AV) valve A valve between the atrium and ventricle on the right and left sides of the heart; the right AV valve is the tricuspid valve; the left is the mitral valve

atrium (A-tre-um) An entrance chamber, one of the two upper receiving chambers of the heart (root: atri/o)

attention deficit hyperactivity disorder (ADHD) A condition that begins in childhood and is characterized by attention problems, easy boredom, impulsive behavior, and hyperactivity

auditory tube (aw-dih-TO-re) The tube that connects the middle ear with the nasopharynx and serves to equalize pressure between the outer and middle ear (root: salping/o); pharyngotympanic tube; originally called the eustachian (u-STA-shen) tube

auscultation (aws-kul-TA-shun) Listening for sounds within the body, usually within the chest or abdomen

autism (AW-tizm) A disorder of unknown cause consisting of self-absorption, lack of response to social contact and affection, preoccupations, stereotyped behavior, and resistance to change (from auto-, "self," and -ism, "condition of")

autism spectrum disorder (ASD) A disability that falls within a range of neurodevelopmental impairments that appears early in life and affects social interactions and communications skills

autoimmune disease (aw-to-ih-MUNE) A condition in which the immune system produces antibodies against an individual's own tissues (prefix auto means "self")

autonomic nervous system (ANS) (aw-to-NOM-ik) The division of the nervous system that regulates involuntary activities, controlling smooth muscles, cardiac muscle, and glands; the visceral nervous system

AV bundle A band of fibers that transmits impulses from the atrioventricular (AV) node to the top of the interventricular septum; it divides into the right and left bundle branches, which descend along the two sides of the septum; the bundle of His

axis (AK-sis) The second cervical vertebra

axon (AK-son) The fiber of a neuron that conducts impulses away from the cell body

B

B cell A lymphocyte that matures in bone marrow and is active in producing antibodies; B lymphocyte (LIM-fo-site)

extern.ir

bacteriuria (bak-te-re-U-re-ah) Presence of bacteria in the urine

band cell An immature neutrophil with a nucleus in the shape of a band; also called a stab cell; band cell counts are used to trace infections and other diseases

barium study (BAH-re-um) Use of barium sulfate as a liquid contrast medium for fluoroscopic or radiographic study of the digestive tract; can show obstruction, tumors, ulcers, hiatal hernia, and motility disorders, among other conditions

Barrett syndrome (BAH-ret) Condition resulting from chronic esophagitis, as caused by gastroesophageal reflux disease; inflammatory injury can lead to esophageal spasms, scarring, strictures, and increased risk of cancer; also called Barrett esophagus

basal cell carcinoma (BA-sal) An epithelial tumor that rarely metastasizes and has a high cure rate with surgical removal

basophil (BA-so-fil) A granular leukocyte that stains strongly with basic dyes; active in allergic reactions

benign (be-NINE) Not recurrent or malignant, favorable for recovery, describing a tumor that does not spread (metastasize) to other tissues

benign prostatic hyperplasia (BPH) (be-NINE pros-TAT-ik hi-per-PLA-ze-ah) Nonmalignant enlargement of the prostate; frequently develops with age

bile The fluid secreted by the liver that emulsifies fats and aids in their absorption (roots: chol/e, bili)

biliary colic (BIL-e-ar-e KOL-ik) Acute abdominal pain caused by gallstones in the bile ducts

bilirubin (bil-ih-RU-bin) A pigment released in the breakdown of hemoglobin from red blood cells; mainly excreted by the liver in bile

biofeedback (bi-o-FEDE-bak) A method for learning control of involuntary physiologic responses by using electronic devices to monitor bodily changes and feeding this information back to a person

biopsy (BI-op-se) Removal of a small amount of tissue for microscopic examination

bipolar disorder (bi-PO-lar) A form of depression with episodes of mania (a state of elation); manic depressive illness

bisphosphonate (bis-FOS-fo-nate) Agent used to prevent and treat osteoporosis; increases bone mass by decreasing bone turnover; examples are alendronate (Fosamax), risedronate (Actonel), and ibandronate (Boniva)

blood (blud) The fluid that circulates in the cardiovascular system (roots: hem/o, hemat/o)

blood pressure The force exerted by blood against the wall of a vessel

B lymphocyte See B cell

bone A calcified form of dense connective tissue; osseous tissue; also an individual unit of the skeleton made of such tissue (root: oste/o)

bone marrow The soft material that fills bone cavities; yellow marrow fills the central cavity of the long bones; blood cells are formed in red bone marrow, which is located in spongy bone tissue (root: myel/o)

bradycardia (brad-e-KAR-de-ah) A slow heart rate of less than 60 bpm

brain (brane) The nervous tissue contained within the cranium; consists of the cerebrum, diencephalon, brainstem, and cerebellum (root: encephal/o)

brainstem The part of the brain that consists of the midbrain, pons, and medulla oblongata

brand name The trade or proprietary name of a drug, a registered trademark of the manufacturer; written with an initial capital letter

bronchiectasis (brong-ke-EK-tah-sis) Chronic dilatation of a bronchus or bronchi

bronchiole (BRONG-ke-ole) One of the smaller subdivisions of the bronchial tubes (root: bronchiol/o)

bronchitis (brong-KI-tis) Inflammation of a bronchus

bronchoscope (BRONG-ko-skope) An endoscope used to examine the tracheobronchial passageways. Also allows access for tissue biopsy or removal of a foreign object

bronchus (BRONG-kus) One of the larger air passageways in the lungs; the bronchi begin as two branches of the trachea and then subdivide within the lungs (plural: bronchi) (root: bronch/o)

bulbourethral gland (bul-bo-u-RE-thral) A small gland beside the urethra below the prostate that secretes part of the seminal fluid; also called Cowper gland

bundle branches Branches of the AV bundle that divide to the right and left sides of the interventricular septum

bursa (BUR-sah) A fluid-filled sac that reduces friction near a joint (root: burs/o)

C

calyx (KA-liks) A cup-like cavity in the pelvis of the kidney; also calix (plural: calices) (roots: cali/o, calic/o)

candidiasis (kan-dih-DI-ah-sis) Infection with the fungus Candida, a common cause of vaginitis

capillary (KAP-ih-lar-e) A microscopic blood vessel through which materials are exchanged between the blood and the tissues

carbohydrates (kar-bo-HI-drates) The category of organic compounds that includes sugars and starches

carbon dioxide (CO_2) (KAR-bon di-OK-side) A gas produced by energy metabolism in cells and eliminated through the lungs

carbonic acid (kar-BON-ik) An acid formed when carbon dioxide dissolves in water; H_2CO_3

carcinoma (kar-sih-NO-mah) A malignant neoplasm composed of epithelial cells (from Greek root carcino, meaning "crab") (adjective: carcinomatous)

cardiac muscle (KAR-de-ak) Involuntary muscle that makes up the heart wall

cardiopulmonary resuscitation (CPR) (kar-de-o-PUL-mo-nar-e re-sus-ih-TA-shun) Restoration of cardiac output and pulmonary ventilation after cardiac arrest using artificial respiration and chest compression or cardiac massage

cardiovascular system (kar-de-o-VAS-ku-lar) The part of the circulatory system that consists of the heart and the blood vessels

cardioversion (KAR-de-o-ver-zhun) Correction of an abnormal cardiac rhythm; may be accomplished pharmacologically, with antiarrhythmic drugs, or by application of electric current (see defibrillation)

extern.ir

caries (KAR-eze) Tooth decay

carotid endarterectomy (end-ar-ter-EK-to-me) Surgical removal of the lining of the carotid artery, the large artery in the neck that supplies blood to the brain

carrier (KAH-re-er) An individual who has an unexpressed genetic defect that can be passed to his or her children

cartilage (KAR-tih-lij) A type of dense connective tissue that is found in the skeleton, larynx, trachea, and bronchi; it is the precursor to most bone tissue (root: chondr/o)

cast A solid mold of a renal tubule found in the urine

cataract (KAT-ah-rakt) Opacity of the lens of the eye

catheterization (kath-eh-ter-ih-ZA-shun) Introduction of a tube into a passage, such as through the urethra into the bladder for withdrawal of urine

cautery (KAW-ter-e) Destruction of tissue by a damaging agent, such as a harmful chemical, heat, or electric current (electrocautery); cauterization

CD4+ T lymphocyte count A count of the T cells that have the CD4 receptors for the AIDS virus (HIV); a count of less than 200/mcL of blood signifies severe immunodeficiency

cecum (SE-kum) A blind pouch at the beginning of the large intestine (root: cec/o)

celiac disease (SE-le-ak) Inability to absorb foods containing gluten, a protein found in wheat and some other grains; caused by an excess immune response to gluten

cell (sel) The basic structural and functional unit of the living organism, a microscopic unit that combines with other cells to form tissues (root: cyt/o)

central nervous system (CNS) The brain and spinal cord

cerebellum (ser-eh-BEL-um) The posterior portion of the brain dorsal to the pons and medulla; helps to coordinate movement and to maintain balance and posture (cerebellum means "little brain") (root: cerebell/o)

cerebral angiography (SER-eh-bral an-je-OG-rah-fe) Radiographic study of the brain's blood vessels after injection of a contrast medium

cerebral contusion (kon-TU-zhun) A bruise to the surface of the brain following a blow to the head

cerebral cortex (SER-eh-bral) The cerebrum's thin surface layer of gray matter (the cortex is the outer region of an organ) (root: cortic/o)

cerebrospinal fluid (CSF) (ser-eh-bro-SPI-nal) The watery fluid that circulates in and around the brain and spinal cord for protection

cerebrovascular accident (CVA) (ser-eh-bro-VAS-ku-lar) Sudden damage to the brain resulting from reduction of cerebral blood flow; possible causes are atherosclerosis, thrombosis, or a ruptured aneurysm; commonly called stroke

cerebrum (SER-eh-brum) The large upper portion of the brain; it is divided into two hemispheres by the longitudinal fissure (root: cerebr/o)

cerumen (seh-RU-men) The brownish, wax-like secretion formed in the external ear canal to protect the ear and prevent infection (adjective: ceruminous [seh-RU-mih-nus])

cervix (SER-viks) Neck; usually means the lower narrow portion (neck) of the uterus (root: cervic/o); also called the cervix uteri (U-ter-i)

chemotherapy (ke-mo-THER-ah-pe) Use of chemicals to treat disease; the term is often applied specifically to the treatment of cancer with chemicals

chiropractic (ki-ro-PRAK-tik) A science that stresses the condition of the nervous system in diagnosis and treatment of disease; often, the spine is manipulated to correct misalignment; most patients consult for musculoskeletal pain and headaches (from Greek cheir, meaning "hand")

cholecystectomy (ko-le-sis-TEK-to-me) Surgical removal of the gallbladder

cholecystitis (ko-le-sis-TI-tis) Inflammation of the gallbladder

cholelithiasis (ko-le-lih-THI-ah-sis) The condition of having stones in the gallbladder; also used to refer to stones in the common bile duct

chondrosarcoma (kon-dro-sar-KO-mah) A malignant tumor of cartilage

chorion (KOR-e-on) The outermost layer of the embryo that, with the endometrium, forms the placenta (adjective: chorionic)

chorionic villus sampling (CVS) Removal of chorionic cells through the cervix for prenatal testing; can be done earlier in pregnancy than amniocentesis

choroid (KOR-oyd) The dark, vascular, middle layer of the eye (roots: chori/o, choroid/o); part of the uvea

chromosome (KRO-mo-some) A thread-like body in a cell's nucleus that contains genetic information

chronic (KRON-ik) Of long duration, progressing slowly

chronic fatigue syndrome (CFS) (KRON-ik fah-TEGE SIN-drome) A disease of unknown cause that involves persistent fatigue along with muscle and joint pain and other symptoms; may be virally induced

chronic obstructive pulmonary disease (COPD) Any of a group of chronic, progressive, and debilitating respiratory diseases, which includes emphysema, asthma, bronchitis, and bronchiectasis

cicatrization (sik-ah-trih-ZA-shun) The process of scar formation; a scar is a cicatrix (SIK-ah-triks)

ciliary body (SIL-e-ar-e) The muscular portion of the uvea that surrounds the lens and adjusts its shape for near and far vision (root: cycl/o)

circumcision (ser-kum-SIH-zhun) Surgical removal of the end of the prepuce (foreskin)

cirrhosis (sir-RO-sis) Chronic liver disease with degeneration of liver tissue

cleft lip A congenital separation of the upper lip

cleft palate A congenital split in the roof of the mouth

clitoris (KLIT-o-ris) A small erectile body anterior to the urethral opening that is similar in developmental origin to the penis (roots: clitor/o, clitorid/o)

clubbing (KLUB-ing) Enlargement of the ends of the fingers and toes caused by growth of the soft tissue around the nails; seen in a variety of diseases in which there is poor peripheral circulation

extern.ir

coagulation (ko-ag-u-LA-shun) Blood clotting
coarctation of the aorta (ko-ark-TA-shun) Localized narrowing of the aorta with restriction of blood flow
cochlea (KOK-le-ah) The coiled portion of the inner ear that contains the receptors for hearing (root: cochle/o)
coitus (KO-ih-tus) Sexual intercourse
colon (KO-lon) The major portion of the large intestine; extends from the cecum to the rectum and is formed by ascending, transverse, and descending portions (roots: col/o, colon/o)
colostrum (ko-LOS-trum) Breast fluid that is secreted in the first few days after giving birth before milk is produced
colposcope (KOL-po-skope) Instrument for examining the vagina and cervix
coma (KO-mah) State of deep unconsciousness from which one cannot be roused
combining forms (kom-BI-ning) A word root combined with a vowel that links the root with another word part, such as a suffix or another root; combining forms are shown with a slash between the root and the vowel, as in neur/o
common bile duct The duct that carries bile into the duodenum; formed by the union of the cystic duct and the common hepatic duct (root: choledoch/o)
compliance (kom-PLI-ans) A measure of how easily the lungs expand under pressure; compliance is reduced in many types of respiratory disorders
compound word (KOM-pownd) A word that contains more than one root
concussion (kon-KUSH-un) Injury resulting from a violent blow or shock; a brain concussion usually results in loss of consciousness
conductive hearing loss Hearing impairment that results from blockage of sound transmission to the inner ear
cone A specialized cell in the retina that responds to light; cones have high visual acuity, function in bright light, and respond to colors
cone biopsy Removal of a cone of tissue from the cervical lining for cytologic examination; also called conization
confusion (kon-FU-zhun) A state of reduced comprehension, coherence, and reasoning ability resulting in inappropriate responses to environmental stimuli
congenital disorder (kon-JEN-ih-tal) A disorder that is present at birth; may be developmental or hereditary (familial)
congenital hypothyroidism (kon-JEN-ih-tal hi-po-THI-royd-izm) A condition caused by lack of thyroid secretion during development and marked by arrested physical and mental growth; also called infantile hypothyroidism
conjunctiva (kon-junk-TI-vah) The mucous membrane that lines the eyelids and covers the eyeball's anterior surface
conjunctivitis (kon-junk-tih-VI-tis) Inflammation of the conjunctiva; pink eye
contraception (kon-trah-SEP-shun) The prevention of pregnancy
contraindication (kon-trah-in-dih-KA-shun) A factor that makes the use of a drug undesirable or dangerous
contrecoup injury (kon-treh-KU) Damage to the brain on the side opposite the point of a blow as a result of the brain hitting the skull (from French, meaning "counterblow")
convergence (kon-VER-jens) Coordinated movement of the eyes toward fixation on the same point
convulsion (kon-VUL-shun) A series of violent, involuntary muscle contractions; a tonic convulsion involves prolonged muscle contraction; in a clonic convulsion, there is alternation of contraction and relaxation; both forms appear in grand mal epilepsy
Cooley anemia A form of thalassemia (hereditary anemia) that affects production of the β (beta)-hemoglobin chain; thalassemia major
cornea (KOR-ne-ah) The clear, anterior portion of the sclera (roots: corne/o, kerat/o)
coronary angiography (KOR-o-na-re an-je-OG-rah-fe) Radiographic study of the coronary arteries after introduction of an opaque dye by means of a catheter threaded through blood vessels into the heart
coronary artery bypass graft (CABG) Surgical creation of a shunt to bypass a blocked coronary artery; the aorta is connected to a point past the obstruction with another vessel or a piece of another vessel, usually the left internal mammary artery or part of the leg's saphenous vein
coronary calcium scan Method for visualizing vessel-narrowing calcium deposits in coronary arteries; useful for diagnosing coronary artery disease in people at moderate risk or those who have undiagnosed chest pain; also known as a heart scan
coronary circulation (KOR-o-na-re) The blood vessels in the heart that provide oxygen and nourishment and remove waste products from the myocardium
corpus luteum (KOR-pus LU-te-um) The small yellow structure that develops from the ovarian follicle after ovulation and secretes progesterone and estrogen
cranial cavity (KRA-ne-al) The dorsal cavity that contains the brain
cranial nerves The 12 pairs of nerves that are connected to the brain
C-reactive protein (CRP) Protein produced during systemic inflammation, which may contribute to atherosclerosis; high CRP levels can indicate cardiovascular disease and its prognosis
creatine kinase (CK) (KRE-ah-tin KI-nase) An enzyme found in muscle tissue; the serum CK level increases in cases of muscle damage; creatine phosphokinase (CPK)
creatine kinase MB (CK-MB) (KRE-ah-tin KI-naze) Enzyme released in increased amounts from cardiac muscle cells following myocardial infarction (MI); serum assays help diagnose MI and determine the extent of muscle damage
Crohn disease (krone) A chronic inflammatory disease of the gastrointestinal tract usually involving the ileum and colon
cross-matching Testing the compatibility of donor and recipient blood in preparation for a transfusion; donor red cells are mixed with recipient serum to look for an

extern.ir

immunologic reaction; similar tests are done on tissues before transplantation

croup (krupe) A childhood disease usually caused by a viral infection that involves upper airway inflammation and obstruction; croup is characterized by a barking cough, difficulty breathing, and laryngeal spasm

cryptorchidism (krip-TOR-kid-izm) Failure of the testis to descend into the scrotum

CT angiography (CTA) (an-je-OG-rah-fe) Computed tomography scan used to visualize vessels in the heart and other organs; requires only a small amount of dye injected into the arm; can rule out blocked coronary arteries that may cause a myocardial infarction (heart attack) in people with chest pain or abnormal stress tests

curvature of the spine (KER-vah-chure) An exaggerated spinal curve, such as scoliosis, lordosis, or kyphosis

Cushing disease Overactivity of the adrenal cortex resulting from excess production of ACTH by the pituitary

Cushing syndrome A condition resulting from an excess of hormones from the adrenal cortex; it is associated with obesity, weakness, hyperglycemia, hypertension, and hirsutism (excess hair growth)

cutaneous (ku-TA-ne-us) Pertaining to the skin (from Latin cutis, meaning "skin")

cyanosis (si-ah-NO-sis) Bluish discoloration of the skin caused by lack of oxygen in the blood (adjective: cyanotic)

cyst (sist) An abnormal filled sac or pouch; used as a root meaning a normal bladder or sac, such as the urinary bladder or gallbladder (root: cyst/o)

cystectomy (sis-TEK-to-me) Surgical removal of all or part of the urinary bladder

cystic fibrosis (CF) (SIS-tik fi-BRO-sis) An inherited disease that affects the pancreas, respiratory system, and sweat glands; characterized by mucus accumulation in the bronchi causing obstruction and leading to infection

cystitis (sis-TI-tis) Inflammation of the urinary bladder, usually as a result of infection

cystoscope (SIS-to-skope) An instrument for examining the interior of the urinary bladder; also used for removing foreign objects, for surgery, and for other forms of treatment

cytology (si-TOL-o-je) Study of cells

cytoplasm (SI-to-plazm) The fluid that fills a cell and holds the organelles

D

debridement (da-brede-MON) Removal of dead or damaged tissue, as from a wound

deep vein thrombosis (DVT) (throm-BO-sis) Thrombophlebitis involving the deep veins

defibrillation (de-fib-rih-LA-shun) Use of an electronic device (defibrillator) to stop fibrillation by delivering a brief electric shock to the heart; the shock may be delivered to the surface of the chest, as by an automated external defibrillator (AED), or directly into the heart through wire leads, using an implantable cardioverter defibrillator (ICD)

degenerative joint disease (DJD) Osteoarthritis

dehiscence (de-HIS-ens) Splitting or bursting, as when the layers of a wound separate

delayed hypersensitivity reaction An allergic reaction involving T cells that takes at least 12 hours to develop; examples are various types of contact dermatitis, such as poison ivy or poison oak; the tuberculin reaction (test for TB); and rejections of transplanted tissue

delusion (de-LU-zhun) A false belief inconsistent with knowledge and experience

dementia (de-MEN-she-ah) A gradual and usually irreversible loss of intellectual function

dendrite (DEN-drite) A fiber of a neuron that conducts impulses toward the cell body

deoxyribonucleic acid (DNA) (de-ok-se-ri-bo-nu-KLE-ik) The genetic compound of the cell, makes up the genes

depolarization (de-po-lar-ih-ZA-shun) A change in electrical charge from the resting state in nerves or muscles

depression (de-PRESH-un) A mental state characterized by profound feelings of sadness, emptiness, hopelessness, and lack of interest or pleasure in activities

derma (DER-mah) Skin (from Greek)

dermatitis (der-mah-TI-tis) Inflammation of the skin, often associated with redness and itching; may be caused by allergy, irritants (contact dermatitis), or a variety of diseases

dermatology (der-mah-TOL-o-je) Study of the skin and diseases of the skin

dermatome (DER-mah-tome) Instrument for cutting thin skin sections for grafting

dermatomyositis (der-mah-to-mi-o-SI-tis) A disease of unknown origin involving muscular inflammation as well as dermatitis and skin rashes

dermis (DER-mis) The layer of the skin between the epidermis and the subcutaneous tissue; the true skin or corium

diabetes insipidus (di-ah-BE-teze in-SIP-ih-dus) A disorder caused by insufficient release of ADH from the posterior pituitary; it results in excessive thirst and production of large amounts of very dilute urine; insipidus means "tasteless," referring to the dilution of the urine

diabetes mellitus (DM) (MEL-ih-tus) A disorder of glucose metabolism caused by deficiency of insulin production or inadequate tissue response to insulin; type 1 results from autoimmune destruction of pancreatic islet cells; it generally appears in children and requires insulin administration; type 2 generally occurs in obese adults; it is treated with diet, exercise, and drugs to improve insulin production or activity, and sometimes insulin; mellitus comes from the Latin root for honey, referring to the urine's glucose content

diabetic retinopathy (ret-ih-NOP-ah-the) Degenerative changes in the retina associated with diabetes mellitus

diagnosis (di-ag-NO-sis) The process of determining the cause and nature of an illness

dialysis (di-AL-ih-sis) Separation of substances by passage through a semipermeable membrane; dialysis is used to rid the body of unwanted substances when the kidneys

extern.ir

are impaired or missing; the two forms of dialysis are hemodialysis and peritoneal dialysis

diaphoresis (di-ah-fo-RE-sis) Profuse sweating

diaphragm (DI-ah-fram) The dome-shaped muscle under the lungs that flattens during inspiration (root: phren/o)

diaphragm (DI-ah-fram) The muscle that separates the thoracic from the abdominal cavity

diaphysis (di-AF-ih-sis) The shaft of a long bone

diarrhea (di-ah-RE-ah) The frequent passage of watery bowel movements

diarthrosis (di-ar-THRO-sis) A freely movable joint; also called a synovial joint (adjective: diarthrotic)

diastole (di-AS-to-le) The relaxation phase of the heartbeat cycle (adjective: diastolic)

diencephalon (di-en-SEF-ah-lon) The part of the brain that contains the thalamus, hypothalamus, and pituitary gland; located between the cerebrum and the brainstem

dilatation and evacuation (D&E) Widening of the cervix and removal of conception products by suction

dilation and curettage (D&C) (ku-reh-TAJ) Procedure in which the cervix is dilated (widened) and the uterine lining is scraped with a curette

diphtheria (dif-THERE-e-ah) Acute infectious disease, usually limited to the upper respiratory tract, characterized by the formation of a surface pseudomembrane composed of cells and coagulated material

discectomy (dis-KEK-to-me) Surgical removal of a herniated intervertebral disk; also spelled discectomy

dissecting aneurysm An aneurysm in which blood enters the arterial wall and separates the layers; usually involves the aorta

disseminated intravascular coagulation (DIC) Widespread clot formation in the microscopic vessels; may be followed by bleeding caused by depletion of clotting factors

diuresis (di-u-RE-sis) Excretion of urine; usually meaning increased urinary excretion

diuretic (di-u-RET-ik) A substance that increases the excretion of urine; pertaining to diuresis

diverticulitis (di-ver-tik-u-LI-tis) Inflammation of diverticula (small pouches) in the wall of the digestive tract, especially in the colon

diverticulosis (di-ver-tik-u-LO-sis) The presence of diverticula, especially in the colon

drug A substance that alters body function

ductus arteriosus (DUK-tus ar-tere-e-O-sus) A fetal blood vessel that connects the pulmonary artery with the descending aorta, thus allowing blood to bypass the lungs

ductus deferens (DUK-tus DEF-er-enz) The duct that conveys spermatozoa from the epididymis to the ejaculatory duct; also called vas deferens

Dukes classification A system for staging colorectal cancer based on degree of bowel wall penetration and lymph node involvement; severity is graded from A to C

duodenum (du-o-DE-num) The first portion of the small intestine (root: duoden/o); also pronounced du-OD-eh-num

dura mater (DU-rah MA-ter) The strong, fibrous outermost layer of the meninges

dyslipidemia (dis-lip-ih-DE-me-ah) Disorder in serum lipid levels, which is an important factor in the development of atherosclerosis; includes hyperlipidemia (high lipids), hypercholesterolemia (high cholesterol), and hypertriglyceridemia (high triglycerides)

dysmenorrhea (DIS-men-o-re-ah) Painful or difficult menstruation; a common disorder that may be caused by infection, use of an intrauterine device, endometriosis, overproduction of prostaglandins, or other factors

dysphagia (dis-FA-je-ah) Difficulty in swallowing

dyspnea (disp-NE-ah) Difficult or labored breathing (-pnea), sometimes with pain; "air hunger"

dysthymia (dis-THI-me-ah) A mild form of depression that usually develops in response to a serious life event (from dys- and Greek thymos, meaning "mind, emotion")

dysuria (dis-U-re-ah) Painful or difficult urination

E

ecchymosis (ek-ih-MO-sis) A collection of blood under the skin caused by leakage from small vessels (root chym means "juice")

echocardiography (ek-o-kar-de-OG-rah-fe) A noninvasive method that uses ultrasound to visualize internal cardiac structures

eclampsia (eh-KLAMP-se-ah) Convulsions and coma occurring during pregnancy or after delivery and associated with preeclampsia (see below) (adjective: eclamptic)

ectopic pregnancy (ek-TOP-ik) Development of the fertilized ovum outside the body of the uterus; usually occurs in the uterine tube (tubal pregnancy) but may occur in other parts of the reproductive tract or abdominal cavity

eczema (EK-ze-mah) A general term for skin inflammation with redness, lesions, and itching; atopic dermatitis

edema (eh-DE-mah) Accumulation of fluid in the tissues, swelling; adjective: edematous (eh-DE-mah-tus)

edema (eh-DE-mah) Swelling of body tissues caused by the presence of excess fluid; causes include cardiovascular disturbances, kidney failure, inflammation, and malnutrition

efferent (EF-er-ent) Carrying away from a given point, such as the motor neurons and nerves that carry impulses away from the CNS (root fer means "to carry")

efficacy (EF-ih-kah-se) The power to produce a specific result; effectiveness

ejaculation (e-jak-u-LA-shun) Ejection of semen from the male urethra

ejaculatory duct (e-JAK-u-lah-tor-e) The duct formed by union of the ductus deferens and the duct of the seminal vesicle; it carries spermatozoa and seminal fluid into the urethra

electrocardiography (ECG) (e-lek-tro-kar-de-OG-rah-fe) Study of the electrical activity of the heart as detected by electrodes (leads) placed on the surface of the body; also abbreviated EKG from the German electrocardiography

electroencephalography (EEG) (e-lek-tro-en-sef-ah-LOG-rah-fe) Amplification, recording, and interpretation of the brain's electric activity

electrolyte (e-LEK-tro-lite) A substance that separates into charged particles (ions) in solution; a salt; term also applied to ions in body fluids

extern.ir

electromyography (EMG) (e-lek-tro-mi-OG-rah-fe) Study of the electrical activity of muscles during contraction

embolism (EM-bo-lizm) Obstruction of a blood vessel by a blood clot or other matter carried in the circulation

embolus (EM-bo-lus) A mass carried in the circulation; usually a blood clot, but also may be air, fat, bacteria, or other solid matter from within or from outside the body

embryo (EM-bre-o) The stage in development between the zygote and the fetus, extending from the second through the eighth week of growth in the uterus (root: embry/o) (adjective: embryonic)

emesis (EM-eh-sis) Vomiting

emphysema (em-fih-SE-mah) A chronic pulmonary disease characterized by enlargement and destruction of the alveoli

empyema (em-pi-E-mah) Accumulation of pus in a body cavity, especially the pleural space; pyothorax

encephalitis (en-sef-ah-LI-tis) Inflammation of the brain

endocardium (en-do-KAR-de-um) The thin membrane that lines the chambers of the heart and covers the valves

endocrine (EN-do-krin) Pertaining to a ductless gland that secretes hormones into the blood

endometriosis (en-do-me-tre-O-sis) Growth of endometrial tissue outside the uterus, usually in the pelvic cavity

endometrium (en-do-ME-tre-um) The inner lining of the uterus

endoscope (EN-do-skope) An instrument for examining the inside of an organ or cavity through a body opening or small incision; most endoscopes use fiber optics for viewing

endoscopic retrograde cholangiopancreatography (ERCP) (ko-lan-je-o-pan-kre-ah-TOG-rah-fe) A technique for viewing the pancreatic and bile ducts and for performing certain techniques to relieve obstructions; contrast medium is injected into the biliary system from the duodenum before radiographs are taken

endoscopy (en-DOS-ko-pe) Use of a fiberoptic endoscope for direct visual examination; GI studies include esophagogastroduodenoscopy, proctosigmoidoscopy (rectum and distal colon), and colonoscopy (all regions of the colon)

enzyme (EN-zime) An organic substance that speeds the rate of a chemical reaction

eosinophil (e-o-SIN-o-fil) A granular leukocyte that stains strongly with acidic dyes; active in allergic reactions and defense against parasites

epicardium (ep-ih-KAR-de-um) The thin outermost layer of the heart wall

epidermis (ep-ih-DER-mis) The outermost layer of the skin (from epi-, meaning "upon or over" and derm, meaning "skin")

epididymis (ep-ih-DID-ih-mis) A coiled tube on the surface of the testis that stores sperm until ejaculation (root: epididym/o)

epididymitis (ep-ih-did-ih-MI-tis) Inflammation of the epididymis; common causes are UTIs and STIs

epidural hematoma (he-mah-TO-mah) Accumulation of blood in the epidural space (between the dura mater and the skull)

epiglottis (ep-ih-GLOT-is) A leaf-shaped cartilage that covers the larynx during swallowing to prevent food from entering the trachea

epilepsy (EP-ih-lep-se) A chronic disease involving periodic sudden bursts of electric activity from the brain, resulting in seizures

epinephrine (ep-ih-NEF-rin) A powerful stimulant produced by the adrenal gland and sympathetic nervous system; activates the cardiovascular, respiratory, and other systems needed to meet stress; used as a drug to treat severe allergic reactions and shock; also called adrenaline

epiphyseal plate (ep-ih-FIZ-e-al) The growth region of a long bone; located in the metaphysis, between the diaphysis and epiphysis; when bone growth ceases, this area appears as the epiphyseal line; also spelled epiphysial

epiphysis (eh-PIF-ih-sis) The irregularly shaped end of a long bone

equilibrium (e-kwih-LIB-re-um) The sense of balance

erectile dysfunction (ED) (eh-REK-tile dis-FUNK-shun) Inability of the male to perform intercourse because of failure to initiate or maintain an erection until ejaculation; impotence

erection (e-REK-shun) The stiffening or hardening of the penis or the clitoris, usually because of sexual excitement

erythema (er-ih-THE-mah) Diffuse redness of the skin

erythrocyte (eh-RITH-ro-site) A red blood cell (roots: erythr/o, erythrocyt/o)

erythropoietin (EPO) (eh-rith-ro-POY-eh-tin) A hormone produced in the kidneys that stimulates red blood cell production in the bone marrow; this hormone is now made by genetic engineering for clinical use

escharotomy (es-kar-OT-o-me) Removal of scab tissue resulting from burns or other skin injuries; a scab or crust is an eschar (ES-kar)

esophagus (e-SOF-ah-gus) The muscular tube that carries food from the pharynx to the stomach

estrogen (ES-tro-jen) A group of hormones that produce female characteristics and prepare the uterus for the fertilized egg; the most active of these is estradiol

etiology (e-te-OL-o-je) The cause of a disease

evisceration (e-vis-er-A-shun) Protrusion of internal organs (viscera) through an opening, as through a wound

excision (ek-SIZH-un) Removal by cutting (suffix: -ectomy)

exophthalmos (ek-sof-THAL-mos) Protrusion of the eyeballs, as seen in Graves disease

expectoration (ek-spek-to-RA-shun) The act of coughing up material from the respiratory tract; also the material thus released; sputum

expiration (ek-spih-RA-shun) The act of breathing out or expelling air from the lungs; exhalation

external auditory canal (aw-dih-TO-re) Tube that extends from the pinna of the ear to the tympanic membrane; external auditory meatus

exudate (EKS-u-date) Material, which may include fluid, cells, pus, or blood, that escapes from damaged tissue

extern.ir

F

fallopian tube (fah-LO-pe-an) See uterine tube

fascia (FASH-e-ah) The fibrous sheath of connective tissue that covers a muscle; called deep fascia to differentiate it from the superficial fascia that underlies the skin (root: fasci/o) (plural: fasciae)

fascicle (FAS-ih-kl) A small bundle, as of muscle or nerve fibers

feces (FE-seze) The waste material eliminated from the intestine (adjective: fecal); stool

fertilization (fer-tih-lih-ZA-shun) The union of an ovum and a spermatozoon

fetus (FE-tus) The developing child in the uterus from the third month to birth (root: fet/o) (adjective: fetal)

fibrillation (fih-brih-LA-shun) Spontaneous, quivering, and ineffectual contraction of muscle fibers, as in the atria or the ventricles

fibrin (FI-brin) The protein that forms a clot in the blood coagulation process

fibrinogen (fi-BRIN-o-jen) The inactive precursor of fibrin

fibroid (FI-broyd) Benign tumor of smooth muscle (see leiomyoma)

fibromyalgia syndrome (FMS) (fi-bro-mi-AL-je-ah) A disorder associated with widespread muscular aches and stiffness and having no known cause

fimbriae (FIM-bre-e) The long finger-like extensions of the uterine tube that wave to capture the released ovum (singular: fimbria)

fistula (FIS-tu-lah) An abnormal passageway between two organs such as between the rectum and anus (anorectal fistula), or from an organ to the body surface

fixation (fik-SA-shun) Holding or fastening a structure in a firm position (suffix: -pexy)

follicle-stimulating hormone (FSH) A hormone secreted by the anterior pituitary that acts on the gonads; in males, FSH stimulates Sertoli cells and promotes sperm cell development; in females, it stimulates ripening of ova in the ovary

foramen ovale (fo-RA-men o-VA-le) A small hole in the interatrial septum in the fetal heart that allows blood to pass directly from the right to the left side of the heart

formed elements The cellular components of blood

fornix (FOR-niks) An arch-like space, such as the space between the uppermost wall of the vagina and the cervix; from Latin meaning "arch"

fovea (FO-ve-ah) The tiny depression in the retina that is the point of sharpest vision; fovea centralis, central fovea

fracture (FRAK-chure) A break in a bone; in a closed or simple fracture, the broken bone does not penetrate the skin; in an open fracture, there is an accompanying wound in the skin

frontal (coronal) plane (FRUHN-tal) Plane of section that separates the body into anterior (front) and posterior (back) portions

functional murmur Any sound produced as the heart functions normally

G

gallbladder A sac on the undersurface of the liver that stores bile (root: cholecyst/o)

gamete (GAM-ete) A mature reproductive cell, the spermatozoon in the male and the ovum in the female

gamma globulin (GLOB-u-lin) The fraction of the blood plasma that contains antibodies; given for passive transfer of immunity

ganglion (GANG-gle-on) A collection of neuron cell bodies outside the CNS (plural: ganglia) (roots: gangli/o, ganglion/o)

gastroenteritis (gas-tro-en-ter-I-tis) Inflammation of the stomach and intestine

gastroesophageal reflux disease (GERD) (gas-tro-e-sof-ah-JE-al) Condition caused by reflux of gastric juices into the esophagus resulting in heartburn, regurgitation, inflammation, and possible damage to the esophagus; caused by weakness of the lower esophageal sphincter (LES)

gene (jene) A hereditary unit composed of DNA and combined with other genes to form the chromosomes

generic name (jeh-NER-ik) The nonproprietary name of a drug; that is, a name that is not privately owned or trademarked; usually a simplified version of the chemical name; not capitalized

gestation (jes-TA-shun) The period of development from conception to birth

gigantism (JI-gan-tizm) Overgrowth caused by excess growth hormone from the pituitary during childhood; also called gigantism

glans penis (glanz PE-nis) The bulbous end of the penis

glaucoma (glaw-KO-mah) An eye disease caused by increased intraocular pressure that damages the optic disk and causes vision loss; usually results from faulty fluid drainage from the anterior eye

glioma (gli-O-mah) A tumor of neuroglial cells

glomerular capsule (glo-MER-u-lar KAP-sule) The cup-shaped structure at the beginning of the nephron that surrounds the glomerulus and receives material filtered out of the blood; Bowman (BO-man) capsule

glomerular filtrate (glo-MER-u-lar FIL-trate) The fluid and dissolved materials that filter out of the blood and enter the nephron through the glomerular capsule

glomerulonephritis (glo-mer-u-lo-nef-RI-tis) Inflammation of the kidney, primarily involving the glomeruli; the acute form usually occurs after an infection elsewhere in the body; the chronic form varies in cause and usually leads to renal failure

glomerulus (glo-MER-u-lus) The cluster of capillaries within the glomerular capsule (plural: glomeruli) (root: glomerul/o)

glottis (GLOT-is) The opening between the vocal folds

glucose (GLU-kose) A simple sugar that circulates in the blood, the main energy source for metabolism (roots: gluc/o, glyc/o)

glycated hemoglobin (HbA1c) test (GLI-ka-ted) A test that measures the binding of glucose to hemoglobin during the lifespan of a red blood cell; it reflects the average

extern.ir

blood glucose level over 2 to 3 months and is useful in evaluating long-term therapy for diabetes mellitus; also called A1c test

glycosuria (gli-ko-SU-re-ah) Excess glucose in the urine

goiter (GOY-ter) Enlargement of the thyroid gland; a simple (nontoxic) goiter is caused by iodine deficiency

gonad (GO-nad) A sex gland; testis or ovary

gout (gowt) A form of acute arthritis, usually beginning in the knee or foot, caused by deposit of uric acid salts in the joints

grading (GRA-ding) A method for evaluating a tumor based on microscopic examination of the cells

Gram stain A laboratory staining procedure that divides bacteria into two groups: Gram-positive, which stain purple, and Gram-negative, which stain red

granulocyte (GRAN-u-lo-site) A white blood cell that has visible granules in its cytoplasm; granulocytes include neutrophils, basophils, and eosinophils

Graves disease An autoimmune disease resulting in hyperthyroidism; a prominent symptom is exophthalmos (protrusion of the eyeballs); also called diffuse toxic goiter

gravida (GRAV-ih-da) Pregnant woman

gray matter Unmyelinated tissue of the nervous system

greater vestibular gland (ves-TIB-u-lar) A small gland that secretes mucus through a duct that opens near the vaginal orifice; also called Bartholin (BAR-to-lin) gland

gustation (gus-TA-shun) The sense of taste (Latin geusis means "taste")

gyrus (JI-rus) A raised convolution of the surface of the cerebrum (plural: gyri)

H

hair (har) A thread-like keratinized outgrowth from the skin (root: trich/o)

hair follicle (FOL-ih-kl) The sheath in which a hair develops

hallucination (hah-lu-sih-NA-shun) A false perception unrelated to reality or external stimuli

hearing (HERE-ing) The sense or perception of sound

heart (hart) The muscular organ with four chambers that contracts rhythmically to propel blood through vessels to all parts of the body (root: cardi/o)

heart block An interference in the electrical conduction system of the heart resulting in arrhythmia

heart failure A condition caused by the inability of the heart to maintain adequate blood circulation

heart rate The number of times the heart contracts per minute; recorded as beats per minute (bpm)

heart sounds Sounds produced as the heart functions: the two loudest sounds are produced by alternate closing of the valves and are designated S1 and S2

heartburn (HART-bern) A warm or burning sensation felt behind the sternum and radiating upward; commonly associated with gastroesophageal reflux; medical name is pyrosis (pyr/o means "heat")

hematuria (he-mat-U-re-ah) Presence of blood in the urine

hemiparesis (hem-ih-pah-RE-sis) Partial paralysis or weakness of one side of the body

hemiplegia (hem-ih-PLE-je-ah) Paralysis of one side of the body

hemodialysis (he-mo-di-AL-ih-sis) Removal of unwanted substances from the blood by passage through a semipermeable membrane

hemoglobin (Hb, Hgb) (HE-mo-glo-bin) The iron-containing pigment in red blood cells that transports oxygen

hemolysis (he-MOL-ih-sis) The rupture of red blood cells and the release of hemoglobin (adjective: hemolytic)

hemolytic disease of the newborn (HDN) Disease that results from Rh incompatibility between the blood of a mother and her fetus; an Rh-negative mother produces antibody to Rh-positive fetal red cells that enter her circulation; these antibodies can destroy Rh-positive fetal red cells in a later pregnancy unless the mother is treated with antibodies to remove the Rh antigen; formerly called erythroblastosis fetalis

hemophilia (he-mo-FIL-e-ah) A hereditary blood disease caused by lack of a clotting factor resulting in abnormal bleeding

hemoptysis (he-MOP-tih-sis) The spitting of blood from the mouth or respiratory tract (ptysis means "spitting")

hemorrhagic anemia (hem-o-RAJ-ik) Anemia that results from blood loss, as from an injury or internal bleeding

hemorrhoids (HEM-o-roydz) Varicose veins in the rectum associated with pain, bleeding, and sometimes rectal prolapse; piles

hemostasis (he-mo-STA-sis) The stoppage of bleeding

hemothorax (he-mo-THOR-aks) Presence of blood in the pleural space

hepatic portal system A special circulatory pathway that brings blood directly from the abdominal organs to the liver for processing (also called simply the portal system); the vessel that enters the liver is the hepatic portal vein (portal vein)

hepatitis (hep-ah-TI-tis) Inflammation of the liver; commonly caused by a viral infection

hepatomegaly (hep-ah-to-MEG-ah-le) Enlargement of the liver

hernia (HER-ne-ah) Protrusion of an organ through an abnormal opening; commonly called a rupture

herniated disk (HER-ne-a-ted) Protrusion of the center (nucleus pulposus) of an intervertebral disk into the spinal canal; ruptured or "slipped" disk

herniorrhaphy (her-ne-OR-ah-fe) Surgical repair of a hernia

hiatal hernia (hi-A-tal) A protrusion of the stomach through the opening (hiatus) in the diaphragm through which the esophagus passes

histology (his-TOL-o-je) Study of tissues

Hodgkin lymphoma A neoplastic disease of B cells that involves the lymph nodes, spleen, liver, and other tissues; characterized by the presence of giant Reed–Sternberg cells

holistic health care (ho-LIS-tik) Practice of treating a person as a whole entity with physical, emotional, social, and spiritual needs; it stresses comprehensive care, involvement in one's own care, and the maintenance of good health rather than the treatment of disease

homeopathy (ho-me-OP-ah-the) A philosophy of treating disease by administering drugs in highly diluted form

extern.ir

along with promoting healthy life habits and a healthy environment (from home/o, meaning "same," and path/o, meaning "disease")

homeostasis (ho-me-o-STA-sis) A steady state, a condition of internal stability and constancy

hormone (HOR-mone) A secretion of an endocrine gland; a substance that travels in the blood and has a regulatory effect on tissues, organs, or glands

human chorionic gonadotropin (hCG) (kor-e-ON-ik GO-nah-do-tro-pin) A hormone secreted by the embryo early in pregnancy that maintains the corpus luteum so that it will continue to secrete hormones

human immunodeficiency virus (HIV) The virus that causes AIDS

hydrocephalus (hi-dro-SEF-ah-lus) Increased accumulation of CSF in or around the brain as a result of obstructed flow; may be caused by tumor, inflammation, hemorrhage, or congenital abnormality

hydronephrosis (hi-dro-nef-RO-sis) Collection of urine in the renal pelvis caused by obstruction; results in distention and renal atrophy

hydrothorax (hi-dro-THOR-aks) Presence of fluid in the pleural space

hyperglycemia (hi-per-gli-SE-me-ah) Excess glucose in the blood

hyperkalemia (hi-per-kah-LE-me-ah) Excess amount of potassium in the blood

hypernatremia (hi-per-nah-TRE-me-ah) Excess amount of sodium in the blood

hyperopia (hi-per-O-pe-ah) A refractive error in which light rays focus behind the retina and objects can be seen clearly only when far from the eye; farsightedness; also called hypermetropia

hypersensitivity (hi-per-sen-sih-TIV-ih-te) An immunologic reaction to a substance that is harmless to most people; allergy

hypertension (hi-per-TEN-shun) A condition of higher-than-normal blood pressure; essential (primary, idiopathic) hypertension has no known cause

hyperventilation (hi-per-ven-tih-LA-shun) Increase in the rate and depth of breathing to above optimal levels, with blood carbon dioxide decreasing to levels below normal

hypoglycemia (hi-po-gli-SE-me-ah) Abnormally low level of glucose in the blood

hypokalemia (hi-po-kah-LE-me-ah) Deficiency of potassium in the blood

hyponatremia (hi-po-nah-TRE-me-ah) Deficiency of sodium in the blood

hypophysis (hi-POF-ih-sis) The pituitary gland; named from hypo, meaning "below," and physis, meaning "growing," because the gland develops below the hypothalamus (root: hypophysi/o)

hypoproteinemia (hi-po-pro-te-NE-me-ah) Decreased amount of protein in the blood; may be caused by kidney damage resulting in protein loss

hypothalamus (hi-po-THAL-ah-mus) A portion of the brain that controls the pituitary gland, produces hormones, and is active in maintaining homeostasis

hypothalamus (hi-po-THAL-ah-mus) The part of the brain that controls the pituitary gland and maintains homeostasis

hypoventilation (hi-po-ven-tih-LA-shun) Condition in which the amount of air entering the alveoli is insufficient to meet metabolic needs and blood carbon dioxide increases to levels above normal

hysterectomy (his-ter-EK-to-me) Surgical removal of the uterus; most commonly done because of tumors; often the uterine tubes and ovaries are removed as well

I

icterus (IK-ter-us) Jaundice

ileal conduit (IL-e-al KON-du-it) Diversion of urine by connection of the ureters to an isolated segment of the ileum; one end of the segment is sealed, and the other drains through an opening in the abdominal wall; a procedure used when the bladder is removed or nonfunctional; also called ileal bladder

ileum (IL-e-um) The terminal portion of the small intestine (root: ile/o)

ileus (IL-e-us) Intestinal obstruction; may be caused by lack of peristalsis (adynamic, paralytic ileus) or by contraction (dynamic ileus); intestinal matter and gas may be relieved by insertion of a drainage tube

ilium (IL-e-um) The large, flared, superior portion of the pelvic bone (root: ili/o) (adjective: iliac)

immunity (ih-MU-nih-te) The state of being protected against a disease (root: immun/o)

immunodeficiency (im-u-no-de-FISH-en-se) A congenital or acquired failure of the immune system to protect against disease

immunoglobulin (Ig) (im-u-no-GLOB-u-lin) An antibody; immunoglobulins fall into five classes, each abbreviated with a capital letter: IgG, IgM, IgA, IgD, IgE

immunotherapy (im-u-no-THER-ah-pe) Treatment that involves stimulation or suppression of the immune system, either specifically or nonspecifically

impotence (IM-po-tens) Erectile dysfunction

incision (in-SIZH-un) A cut, as for surgery; also the act of cutting (suffix: -tomy)

incus (ING-kus) The middle ossicle of the ear

infarct (in-FARKT) An area of localized tissue necrosis (death) resulting from a blockage or a narrowing of the artery that supplies the area

inferior vena cava (VE-nah KA-vah) The large inferior vein that brings blood low in oxygen back to the right atrium of the heart from the lower body

infertility (in-fer-TIL-ih-te) Decreased capacity to produce offspring

inflammation (in-flah-MA-shun) A localized response to tissue injury characterized by heat, pain, redness, and swelling

influenza (in-flu-EN-zah) An acute, contagious respiratory infection causing fever, chills, headache, and muscle pain; "flu"

inguinal canal (ING-gwin-al) The channel through which the testis descends into the scrotum in the male

extern.ir

inguinal hernia (ING-gwin-al) Protrusion of the intestine or other abdominal organ through the inguinal canal or through the wall of the abdomen into the scrotum

insertion (in-SER-shun) In a given movement, the point where a muscle is attached to a moving part of the skeleton

insomnia (in-SOM-nee-ah) Insufficient or nonrestorative sleep despite ample opportunity to sleep

inspection (in-SPEK-shun) Visual examination of the body

inspiration (in-spih-RA-shun) The act of drawing air into the lungs; inhalation

insulin shock A condition resulting from an overdose of insulin, causing hypoglycemia

integumentary system (in-teg-u-MEN-tah-re) The skin and its associated glands, hair, and nails

interneuron (in-ter-NU-ron) Any neuron located between a sensory and a motor neuron in a neural pathway, such as the neurons that transmit impulses within the CNS

interstitial cells (in-ter-STISH-al) Cells located between the seminiferous tubules of the testes that produce hormones, mainly testosterone; also called cells of Leydig (LI-dig)

intestine (in-TES-tin) The portion of the digestive tract between the stomach and the anus; it consists of the small and large intestines; it functions in digestion, absorption, and elimination of waste (root: enter/o); the bowel (BOW-el)

intravenous pyelography (IVP) (in-trah-VE-nus pi-eh-LOG-rah-fe) Intravenous urography

intravenous urography (IVU) (in-trah-VE-nus u-ROG-rah-fe) Radiographic visualization of the urinary tract after intravenous administration of a contrast medium that is excreted in the urine; also called excretory urography or intravenous pyelography, although the latter is less accurate because the procedure shows more than just the renal pelvis

intrinsic factor (in-TRIN-sik) A substance produced in the stomach that aids in the intestinal absorption of vitamin B_{12}, necessary for the manufacture of red blood cells; lack of intrinsic factor causes pernicious anemia

intussusception (in-tuh-suh-SEP-shun) Slipping of one intestinal segment into another part below it; occurs mainly in male infants in the ileocecal region; may be fatal if untreated for more than 1 day

iris (I-ris) The muscular colored ring between the lens and the cornea; regulates the amount of light that enters the eye by altering the size of the pupil at its center (roots: ir, irid/o, irit/o) (plural: irides [IR-ih-deze])

ischemia (is-KE-me-ah) Local deficiency of blood supply caused by circulatory obstruction (root: hem/o)

J

jaundice (JAWN-dis) A yellowish color of the skin, mucous membranes, and whites of the eye caused by bile pigments in the blood (from French jaune meaning "yellow"); the main pigment is bilirubin, a byproduct of erythrocyte destruction

jejunum (jeh-JU-num) The middle portion of the small intestine (root: jejun/o)

joint The junction between two bones; articulation (root: arthr/o)

K

Kaposi sarcoma (KAP-o-se) Cancerous lesion of the skin and other tissues, seen most often in patients with AIDS

karyotype (KAR-e-o-tipe) A picture of cellular chromosomes arranged in the order of decreasing size; can reveal abnormalities in the chromosomes themselves or in their number or arrangement (root kary/o means "nucleus")

keloid (KE-loyd) A raised, thickened scar caused by tissue overgrowth during scar formation

keratin (KER-ah-tin) A protein that thickens and toughens the skin and makes up hair and nails (root: kerat/o)

ketoacidosis (ke-to-as-ih-DO-sis) Acidosis (increased acidity of body fluids) caused by excess ketone bodies, as in diabetes mellitus; diabetic acidosis

kidney (KID-ne) An organ of excretion (roots: ren/o, nephr/o); the two kidneys filter the blood and form urine, which contains metabolic waste products and other substances as needed to regulate the water, electrolyte, and pH balance of body fluids

kyphosis (ki-FO-sis) An exaggerated curve of the spine in the thoracic region; hunchback, humpback

L

labia majora (LA-be-ah mah-JOR-ah) The two large folds of skin that form the sides of the vulva (root labi/o means "lip") (singular: labium majus)

labia minora (LA-be-ah mi-NOR-ah) The two small folds of skin within the labia majora (singular: labium minus)

labyrinth (LAB-ih-rinth) The inner ear, named for its complex structure, which resembles a maze

lacrimal gland (LAK-rih-mal) A gland above the eye that produces tears (roots: lacrim/o, dacry/o)

lactation (lak-TA-shun) The secretion of milk from the mammary glands

lacteal (lak-TELE) A lymphatic capillary in a villus of the small intestine; lacteals absorb digested fats into the lymph

large intestine (in-TES-tin) The terminal portion of the digestive tract, consisting of the cecum, colon, rectum, and anus; it stores and eliminates undigested waste material (feces)

larynx (LAR-inks) The enlarged, superior portion of the trachea that contains the vocal folds (root: laryng/o)

laser (LA-zer) A device that transforms light into a beam of intense heat and power; used for surgery and diagnosis

L-dopa (DO-pah) A drug used in the treatment of parkinsonism; levodopa

left AV valve The valve between the left atrium and the left ventricle; the mitral valve or bicuspid valve

leiomyoma (li-o-mi-O-mah) Benign tumor of smooth muscle, usually in the uterine wall (myometrium); in the uterus, may cause bleeding and pressure on the bladder or rectum; also called fibroid or myoma

extern.ir

lens (lenz) The transparent, biconvex structure in the anterior portion of the eye that refracts light and functions in accommodation (roots: lent/i, phak/o)

lesion (LE-zhun) A distinct area of damaged tissue, an injury, or wound

leukemia (lu-KE-me-ah) Malignant overgrowth of immature white blood cells; may be chronic or acute; may affect bone marrow (myelogenous leukemia) or lymphoid tissue (lymphocytic leukemia)

leukocyte (LU-ko-site) A white blood cell (roots: leuk/o, leukocyt/o)

leukoplakia (lu-ko-PLA-ke-ah) White patches on mucous membranes, as on the tongue or cheeks, often resulting from smoking or other irritants; may be precancerous

levodopa See L-dopa

ligament (LIG-ah-ment) A strong band of connective tissue that joins one bone to another

lingual tonsils (LING-gwal) Small mounds of lymphoid tissue at the posterior of the tongue

lipid (LIP-id) A category of organic compounds that includes fats (root: lip/o)

lipoprotein (lip-o-PRO-tene) A compound of protein with lipid; lipoproteins are classified according to density as very low-density (VLDL), low-density (LDL), and high-density (HDL); relatively higher levels of HDLs have been correlated with cardiovascular health

lithotomy (lith-OT-o-me) Incision of an organ to remove a stone (calculus)

lithotripsy (LITH-o-trip-se) Crushing of a stone

liver (LIV-er) The large gland in the upper right abdomen; in addition to many other functions, it secretes bile needed for digestion and absorption of fats (root: hepat/o)

lordosis (lor-DO-sis) An exaggerated curve of the spine in the lumbar region; swayback

lower esophageal sphincter (LES) (e-sof-ah-JE-al SFINK-ter) Muscle tissue at the distal end of the esophagus (gastroesophageal junction) that prevents stomach contents from refluxing into the esophagus; also called the cardiac sphincter

lumbar puncture Puncture of the subarachnoid space in the lumbar region of the spinal cord to remove spinal fluid for diagnosis or to inject anesthesia; spinal tap

lung A cone-shaped, spongy respiratory organ contained within the thorax (roots: pneum/o, pulm/o)

lung scan Study based on the accumulation of radioactive isotopes in lung tissue; a ventilation scan measures ventilation after inhalation of radioactive material; a perfusion scan measures blood supply to the lungs after injection of radioactive material; also called a pulmonary scintiscan

lupus erythematosus (LE) (LU-pus er-ih-the-mah-TO-sis) A chronic, inflammatory, autoimmune disease of connective tissue that often involves the skin; types include the more widespread systemic lupus erythematosus (SLE) and a discoid form (DLE) that involves only the skin

luteinizing hormone (LH) (LU-te-in-i-zing) A hormone secreted by the anterior pituitary that acts on the gonads; in males, it stimulates the interstitial cells to produce testosterone; in females, it stimulates ovulation and corpus luteum formation

lymph (limf) The thin, plasma-like fluid that drains from the tissues and is transported in lymphatic vessels (root: lymph/o)

lymph node A small mass of lymphoid tissue along the path of a lymphatic vessel that filters lymph (root: lymphaden/o)

lymphadenitis (lim-fad-eh-NI-tis) Inflammation and enlargement of lymph nodes, usually as a result of infection

lymphadenopathy (lim-fad-eh-NOP-ah-the) Any disease of the lymph nodes

lymphangitis (lim-fan-JI-tis) Inflammation of lymphatic vessels as a result of bacterial infection; appears as painful red streaks under the skin

lymphatic system (lim-FAT-ik) The system that drains fluid and proteins from the tissues and returns them to the bloodstream; this system also participates in immunity and aids in absorption of fats from the digestive tract

lymphedema (lim-feh-DE-mah) Swelling of tissues with lymph caused by obstruction or excision of lymphatic vessels

lymphocyte (LIM-fo-site) An agranular leukocyte active in immunity (T and B cells); found in both the blood and in lymphoid tissue (roots: lymph/o, lymphocyt/o)

lymphoma (lim-FO-mah) Any neoplastic disease of lymphoid tissue

M

macula (MAK-u-lah) A small spot or colored area; used alone to mean the yellowish spot in the retina that contains the fovea

malignant (mah-LIG-nant) Growing worse, harmful, tending to cause death, describing an invasive tumor that can spread (metastasize) to other tissues

malleus (MAL-e-us) The ossicle of the middle ear that is in contact with the tympanic membrane and the incus

mammary gland (MAM-ah-re) Specialized gland capable of secreting milk in the female (roots: mamm/o, mast/o); the breast

mammography (mam-OG-rah-fe) Radiographic study of the breast for the detection of breast cancer; the image obtained is a mammogram

mania (MA-ne-ah) A state of elation, which may include agitation, hyperexcitability, or hyperactivity (adjective: manic)

massage (ma-SAHJ) Manipulation of the body or portion of the body to calm, relieve tension, increase circulation, and stimulate muscles

mastectomy (mas-TEK-to-me) Excision of breast tissue to eliminate malignancy

mastication (mas-tih-KA-shun) Chewing

mastitis (mas-TI-tis) Inflammation of the breast, usually associated with the early weeks of breast-feeding

mediastinum (me-de-as-TI-num) The space between the lungs together with the organs contained in this space

meditation (med-ih-TA-shun) Process of clearing the mind by concentrating on the inner self while controlling

extern.ir

breathing and perhaps repeating a word or phrase (mantra)

medulla oblongata (meh-DUL-lahob-long-GAH-tah) The portion of the brain that connects with the spinal cord; it has vital centers for control of respiration, heart rate, and blood pressure (root: medull/o); often called simply medulla

megakaryocyte (meg-ah-KAR-e-o-site) A large bone marrow cell that fragments to release platelets

meiosis (mi-O-sis) The type of cell division that forms the gametes; it results in cells with 23 chromosomes, half the number found in other body cells (from the Greek word meiosis meaning "diminution")

melanin (MEL-ah-nin) A dark pigment that gives color to the hair and skin and protects the skin against the sun's radiation (root: melan/o)

melanoma (mel-ah-NO-mah) A metastasizing pigmented skin tumor that arises from melanocytes; malignant melanoma

membrane (MEM-brane) A simple, very thin, and pliable sheet of tissue that might cover an organ, line a cavity, or separate structures

menarche (men-AR-ke) The first menstrual period, which normally occurs during puberty

Ménière disease (men-NYARE) A disease associated with increased fluid pressure in the inner ear and characterized by hearing loss, vertigo, and tinnitus

meninges (men-IN-jeze) The three membranes that cover the brain and spinal cord (singular: meninx) (roots: mening/o, meninge/o)

meningioma (men-nin-je-O-mah) Tumor of the meninges

meningitis (men-in-JI-tis) Inflammation of the meninges

menopause (MEN-o-pawz) Cessation of menstrual cycles in the female

menstruation (men-stru-A-shun) The cyclic discharge of blood and mucosal tissues from the lining of the nonpregnant uterus (roots: men/o, mens); menstrual period, menses (MEN-seze)

metabolic syndrome A state of hyperglycemia caused by cellular resistance to insulin, as seen in type 2 diabetes, in association with other metabolic disorders; also called syndrome X or insulin resistance syndrome

metabolism (meh-TAB-o-lizm) The sum of all the physical and chemical reactions that occur within an organism

metaphysis (meh-TAF-ih-sis) The region of a long bone between the diaphysis (shaft) and epiphysis (end); during development, the growing region of a long bone

metastasis (meh-TAS-tah-sis) Spread from one part of the body to another, characteristic of cancer; verb is metastasize (meh-TAS-tah-size), adjective: metastatic (met-ah-STAT-ik); from Greek met/a (beyond, change) + stasis (stand)

metrorrhagia (me-tro-RA-je-ah) Uterine bleeding between normal menstrual periods

microorganism (mi-kro-OR-gan-izm) An organism too small to be seen without the aid of a microscope

micturition (mik-tu-RISH-un) The voiding of urine; urination

midbrain The part of the brainstem between the diencephalon and the pons; contains centers for coordination of reflexes for vision and hearing

mitosis (mi-TO-sis) Cell division

mitral valve (MI-tral) The valve between the left atrium and the left ventricle; the left AV valve or bicuspid valve

monocyte (MON-o-site) An agranular phagocytic leukocyte

motor Producing movement; describes efferent neurons and nerves that carry impulses away from the CNS

mouth The oral cavity; contains the tongue and teeth; used to take in and chew food, mix it with saliva, and move it toward the throat to be swallowed

mucus (MU-kus) A thick fluid secreted by cells in membranes and glands that lubricates and protects tissues (roots: muc/o, myx/o); the adjective is mucous

multi-infarct dementia (MID) Dementia caused by chronic cerebral ischemia (lack of blood supply) as a result of multiple small strokes; there is progressive loss of cognitive function, memory, and judgment as well as altered motor and sensory function

multiple myeloma (mi-eh-LO-mah) A tumor of the blood-forming tissue in bone marrow

multiple sclerosis (MS) A chronic, progressive disease involving loss of myelin in the CNS

murmur An abnormal heart sound

muscle (MUS-el) An organ that produces movement by contracting; also the tissue that composes such organs (roots: my/o, muscul/o)

muscular dystrophy (DIS-tro-fe) A group of hereditary muscular disorders marked by progressive weakness and muscular atrophy

mutation (mu-TA-shun) A change in the genetic material of the cell; most mutations are harmful; if the change appears in the sex cells, it can be passed to future generations

myasthenia gravis (MG) (mi-as-THE-ne-ah GRAH-vis) A disease characterized by progressive muscular weakness; an autoimmune disease affecting the neuromuscular junction

myelin (MI-eh-lin) A whitish, fatty substance that surrounds certain axons of the nervous system

myocardial infarction (MI) (mi-o-KAR-de-al in-FARK-shun) Localized necrosis (death) of cardiac muscle tissue resulting from blockage or narrowing of the coronary artery that supplies that area; myocardial infarction is usually caused by formation of a thrombus (clot) in a vessel

myocardium (mi-o-KAR-de-um) The thick middle layer of the heart wall composed of cardiac muscle

myometrium (mi-o-ME-tre-um) The muscular wall of the uterus

myopia (mi-O-pe-ah) A refractive error in which light rays focus in front of the retina and objects can be seen clearly only when very close to the eye; nearsightedness

myosin (MI-o-sin) One of the two contractile proteins in muscle cells; the other is actin

myringotomy (mir-in-GOT-o-me) Surgical incision of the tympanic membrane; performed to drain the middle ear

extern.ir

cavity or to insert a tube into the tympanic membrane for drainage

N

nail (nale) A plate-like keratinized outgrowth of the skin that covers the dorsal surface of the terminal phalanges (root: onych/o)

narcolepsy (NAR-ko-lep-se) Brief, uncontrollable episodes of sleep during the day

naturopathy (na-chur-OP-ah-the) A therapeutic philosophy of helping people heal themselves by developing healthy lifestyles; naturopaths may use some of the methods of conventional medicine (from nature and path/o, meaning "disease")

nausea (NAW-zhah) An unpleasant sensation in the upper abdomen that often precedes vomiting; typically occurs in digestive upset, motion sickness, and sometimes early pregnancy

necrosis (neh-KRO-sis) Death of tissue (root necr/o means "death"); adjective: necrotic (neh-KROT-ik)

neoplasia (ne-o-PLA-ze-ah) An abnormal and uncontrolled growth of tissue; from prefix neo- meaning "new" and root plasm meaning "formation"

neoplasm (NE-o-plazm) A tumor, or abnormal growth, which may be benign or malignant (root onc/o and suffix -oma refer to neoplasms)

nephron (NEF-ron) A microscopic functional unit of the kidney; working with blood vessels, the nephron filters the blood and balances the composition of urine

nephrotic syndrome (nef-ROT-ik) Condition that results from glomerular damage leading to loss of protein in the urine (proteinuria); there is low plasma protein (hypoproteinemia), edema, and increased blood lipids as the liver releases lipoproteins; also called nephrosis

nerve A bundle of neuron fibers outside the CNS (root: neur/o)

neurilemmoma (nu-rih-lem-O-mah) A tumor of a peripheral nerve sheath (neurilemma); schwannoma

neuroglia (nu-ROG-le-ah) The support cells of the nervous system; also called glial cells (from glia meaning "glue") (root: gli/o)

neuromuscular junction (NMJ) (nu-ro-MUS-ku-lar JUNK-shun) The point of contact, or synapse, between a branch of a motor neuron and a muscle cell

neuron (NU-ron) The basic unit of the nervous system; a nerve cell

neurotransmitter (nu-ro-TRANS-mit-er) A chemical that transmits energy across a synapse; examples are norepinephrine (nor-ep-ih-NEF-rin), acetylcholine (ah-se-til-KO-lene), serotonin (ser-o-TO-nin), and dopamine (DO-pah-mene)

neutrophil (NU-tro-fil) A granular leukocyte that stains weakly with both acidic and basic dyes; the most numerous of the white blood cells; a type of phagocyte

non-Hodgkin lymphoma (NHL) A widespread malignant disease of lymph nodes that involves lymphocytes; it differs from Hodgkin disease in that giant Reed–Sternberg cells are absent

nonsteroidal antiinflammatory drug (NSAID) Drug that reduces inflammation but is not a steroid; examples include aspirin and ibuprofen and other inhibitors of prostaglandins, naturally produced substances that promote inflammation

nose The organ of the face used for breathing and housing receptors for the sense of smell; includes an external portion and an internal nasal cavity (roots: nas/o, rhin/o)

nucleus (NU-kle-us) The cell's control center; directs all cellular activities based on the information contained in its chromosomes (roots: nucle/o, kary/o)

nutritional anemia (nu-TRISH-un-al) Anemia resulting from a dietary deficiency, usually of iron, vitamin B_{12}, or folate

O

obsessive–compulsive disorder (OCD) (ob-SES-iv kom-PUL-siv) A condition associated with recurrent and intrusive thoughts, images, and repetitive behaviors performed to relieve anxiety

occlusion (o-KLU-zhun) A closing off or obstruction, as of a vessel

occult blood (o-KULT) Blood present in such small amounts that it can be detected only microscopically or chemically; in the feces, a sign of intestinal bleeding (occult means "hidden")

olfaction (ol-FAK-shun) The sense of smell (root osm/o means "smell")

oliguria (ol-ig-U-re-ah) Elimination of small amounts of urine

oophorectomy (o-of-o-REK-to-me) Excision of an ovary

ophthalmia neonatorum (of-THAL-me-ah ne-o-na-TOR-um) Severe conjunctivitis usually caused by infection with gonococcus during birth

ophthalmoscope (of-THAL-mo-skope) An instrument for examining the interior of the eye

optic disk The point where the optic nerve joins the retina; at this point, there are no rods or cones; also called the blind spot or optic papilla

orbit (OR-bit) The bony cavity that contains the eyeball

orchitis (or-KI-tis) Inflammation of a testis; may be caused by injury, mumps virus, or other infections

organ (OR-gan) A part of the body with a specific function, a component of a body system

organelle (OR-gah-nel) A specialized structure in the cytoplasm of a cell

origin (OR-ih-jin) In a given movement, the point where a muscle is attached to a stable part of the skeleton

orthopedics The study and treatment of disorders of the skeleton, muscles, and associated structures; literally "straight" (ortho) "child" (ped); also spelled orthopaedics

ossicles (OS-ih-klz) The small bones of the middle ear; the malleus, incus, and stapes

ossification (os-ih-fih-KA-shun) The formation of bone tissue (from Latin os, meaning "bone")

osteoarthritis (OA) (os-te-o-ar-THRI-tis) Progressive deterioration of joint cartilage with growth of new bone and soft tissue in and around the joint; the most common form of arthritis; results from wear and tear,

extern.ir

injury, or disease; also called degenerative joint disease (DJD)

osteoblast (OS-te-o-blast) A cell that produces bone tissue

osteoclast (OS-te-o-clast) A cell that destroys bone tissue

osteocyte (OS-te-o-site) A mature bone cell that nourishes and maintains bone tissue

osteogenic sarcoma (os-te-o-JEN-ik) A malignant bone tumor; osteosarcoma

osteomalacia (os-te-o-mah-LA-she-ah) A softening and weakening of the bones due to vitamin-D deficiency or other disease

osteomyelitis (os-te-o-mi-eh-LI-tis) Inflammation of bone and bone marrow caused by infection, usually bacterial

osteopathy (os-te-OP-ah-the) A system of therapy based on the theory that the body can overcome disease when it has normal structure, a favorable environment, and proper nutrition; osteopaths use standard medical practices for diagnosis and treatment but stress the identification and correction of faulty body structure (from oste/o, meaning "bone," and path/o, meaning "disease")

osteopenia (os-te-o-PE-ne-ah) A lower-than-average bone density, which may foreshadow osteoporosis

osteoporosis (os-te-o-po-RO-sis) A condition characterized by reduction in bone density, most common in white women past menopause; predisposing factors include poor diet, inactivity, and low estrogen levels

ostomy (OS-to-me) An opening into the body; generally refers to an opening created for elimination of body waste; also refers to the operation done to create such an opening (see stoma)

otitis externa (o-TI-tis ex-TER-nah) Inflammation of the external auditory canal; swimmer's ear

otitis media (o-TI-tis ME-de-ah) Inflammation of the middle ear with accumulation of serous (watery) or mucoid fluid

otosclerosis (o-to-skleh-RO-sis) Formation of abnormal and sometimes hardened bony tissue in the ear; it usually occurs around the oval window and the footplate (base) of the stapes, causing immobilization of the stapes and progressive hearing loss

otoscope (O-to-skope) Instrument used to examine the ears

ovarian follicle (o-VAR-e-an FOL-ih-kl) The cluster of cells in which the ovum ripens in the ovary

ovary (O-vah-re) A female gonad (roots: ovari/o, oophor/o)

ovulation (ov-u-LA-shun) The release of a mature ovum from the ovary (from ovule, meaning "little egg")

ovum (O-vum) The female gamete or reproductive cell (roots: oo, ov/o) (plural: ova)

oxygen (O_2) (OK-sih-jen) The gas needed by cells to release energy from food during metabolism

oxytocin (ok-se-TO-sin) A pituitary hormone that stimulates contractions of the uterus; it also stimulates release ("letdown") of milk from the breasts

P

Paget disease (PAJ-et) Skeletal disease of the elderly characterized by bone thickening and distortion with bowing of long bones; osteitis deformans

palate (PAL-at) The roof of the mouth; the partition between the mouth and nasal cavity; consists of an anterior portion formed by bone, the hard palate, and a posterior portion formed of tissue, the soft palate (root: palat/o)

palatine tonsils (PAL-ah-tine) The paired masses of lymphoid tissue located on either side of the oropharynx; usually meant when the term tonsils is used alone

palliative therapy (PAL-e-ah-tiv) Providing relief but not cure; a treatment that provides such relief

palpation (pal-PA-shun) Examining by placing the hands or fingers on the surface of the body to determine characteristics such as texture, temperature, movement, and consistency

palpebra (PAL-peh-brah) An eyelid; a protective fold (upper or lower) that closes over the anterior surface of the eye (roots: palpebr/o, blephar/o) (adjective: palpebral) (plural: palpebrae [pal-PE-bre])

pancreas (PAN-kre-as) A large, elongated gland posterior to the stomach; it produces hormones that regulate sugar metabolism and also produces digestive enzymes (root: pancreat/o)

pancreatic islet (I-let) Cluster of endocrine cells in the pancreas that secretes hormones to regulate glucose metabolism; also called islet of Langerhans or islet cells (root insul/o means "island")

pancreatitis (pan-kre-ah-TI-tis) Inflammation of the pancreas

panhypopituitarism (pan-hi-po-pih-TU-ih-tah-rism) Underactivity of the entire pituitary gland

panic disorder A form of anxiety disorder marked by episodes of intense fear

Pap smear Study of cells collected from the cervix and vagina for early detection of cancer; also called Papanicolaou smear or Pap test

para Woman who has produced a viable infant; multiple births are considered as single pregnancies

paralysis (pah-RAL-ih-sis) Temporary or permanent loss of function; flaccid paralysis involves loss of muscle tone and reflexes and muscular degeneration; spastic paralysis involves excess muscle tone and reflexes but no degeneration

paranoia (par-ah-NOY-ah) A mental state characterized by jealousy, delusions of persecution, or perceptions of threat or harm

parasite (PAR-ah-site) An organism that grows on or in another organism (the host), causing damage to it

parasympathetic nervous system (par-ah-sim-pah-THET-ik) The part of the autonomic nervous system that reverses the response to stress and restores homeostasis; it slows heart rate and respiration rate and stimulates digestive, urinary, and reproductive activities

parathyroid gland (par-ah-THI-royd) A small endocrine gland on the posterior thyroid that acts to increase blood calcium levels; there are usually four to six parathyroid glands (roots: parathyr/o, parathyroid/o); the name literally means "near the thyroid"

parkinsonism (PAR-kin-son-izm) A disorder originating in the brain's basal ganglia (nuclei) and characterized by

extern.ir

slow movements, tremor, rigidity, and mask-like face; also called Parkinson disease

parturition (par-tu-RIH-shun) Childbirth (root: nat/i); labor (root: toc/o)

patent ductus arteriosus (PA-tent DUK-tus ar-tere-e-O-sus) Persistence of the ductus arteriosus after birth; the ductus arteriosus is a vessel that connects the pulmonary artery to the descending aorta in the fetus to bypass the lungs

pathogen (PATH-o-jen) An organism capable of causing disease (root path/o means "disease")

pelvic cavity (PEL-vik) The ventral cavity that is below the abdominal cavity

pelvic inflammatory disease (PID) Condition caused by the spread of infection from the reproductive tract into the pelvic cavity; commonly caused by sexually transmitted gonorrhea and Chlamydia infections

pelvis (PEL-vis) The large ring of bone at the inferior trunk formed of the two hip bones (ossa coxae) joined to the sacrum and coccyx; each os coxae is formed of three bones: the superior, flared ilium (IL-e-um); ischium (IS-ke-um); and pubis (PU-bis) (plural: pelves [PEL-veze])

pemphigus (PEM-fih-gus) An autoimmune disease of the skin characterized by sudden, intermittent formation of bullae (blisters); may be fatal if untreated

penis (PE-nis) The male organ of copulation and urination (adjective: penile)

peptic ulcer (PEP-tik UL-ser) A lesion in the mucous membrane of the esophagus, stomach, or duodenum caused by the action of gastric juice

percussion (per-KUSH-un) Tapping the body lightly but sharply to assess the condition of the underlying tissue by the sounds obtained

percutaneous transluminal coronary angioplasty (PTCA) Dilatation of a sclerotic blood vessel by means of a balloon catheter inserted into the vessel and then inflated to flatten plaque against the arterial wall

pericardium (per-ih-KAR-de-um) The fibrous sac that surrounds the heart

perineum (per-ih-NE-um) The region between the thighs from the external genitalia to the anus (root: perine/o)

periosteum (per-e-OS-te-um) The fibrous membrane that covers a bone's surface

peripheral nervous system (PNS) (per-IF-er-al) The portion of the nervous system outside the CNS

peristalsis (per-ih-STAL-sis) Wave-like contractions of an organ's walls; moves material through an organ or duct

peritoneal dialysis (per-ih-to-NE-al di-AL-ih-sis) Removal of unwanted substances from the body by introduction of a dialyzing fluid into the peritoneal cavity followed by removal of the fluid

peritoneum (per-ih-to-NE-um) The large serous membrane that lines the abdominal cavity and supports the abdominal organs

peritonitis (per-ih-to-NI-tis) Inflammation of the peritoneum, the membrane that lines the abdominal cavity and covers the abdominal organs; may result from perforation of an ulcer, ruptured appendix, or reproductive tract infection, among other causes

pernicious anemia (per-NISH-us) Anemia caused by failure of the stomach to produce intrinsic factor, a substance needed for the absorption of vitamin B_{12}; this vitamin is required for the formation of erythrocytes

pertussis (per-TUS-is) An acute, infectious disease characterized by a cough ending in a whooping inspiration; whooping cough

petechiae (pe-E-ke-e) Pinpoint, flat, purplish-red spots caused by bleeding within the skin or mucous membrane (singular: petechia)

Peyer patches (PI-er) Aggregates of lymphoid tissue in the lining of the intestine

phacoemulsification (fak-o-e-MUL-sih-fih-ka-shun) Removal of a cataract by ultrasonic destruction and extraction of the lens

phagocytosis (fag-o-si-TO-sis) The ingestion of organisms, such as invading bacteria or small particles of waste material by a cell (root phag/o means "to eat"); the phagocytic cell, or phagocyte, then destroys the ingested material

pharynx (FAR-inks) The throat; a common passageway for food entering the esophagus and air entering the larynx (root: pharyng/o)

Philadelphia chromosome (Ph) An abnormal chromosome found in the cells of most individuals with chronic granulocytic (myelogenous) leukemia

phlebitis (fleh-BI-tis) Inflammation of a vein

phobia (FO-be-ah) An extreme, persistent fear of a specific object or situation

phrenic nerve (FREN-ik) The nerve that activates the diaphragm (root: phrenic/o)

phytomedicine (fi-to-MED-ih-sin) Another name for herbal medicine (root phyt/o meaning "plant")

pia mater (PE-ah MA-ter) The innermost layer of the meninges

pineal gland (PIN-e-al) A small gland in the brain; appears to regulate mood, daily rhythms, and sexual development in response to environmental light; secretes the hormone melatonin

pinna (PIN-ah) The projecting part of the outer ear; auricle (AW-rih-kl)

pituitary gland (pih-TU-ih-tar-e) A small endocrine gland at the base of the brain; the anterior lobe secretes growth hormone and hormones that stimulate other glands; the posterior lobe releases ADH and oxytocin manufactured in the hypothalamus (root: pituitar/i); hypophysis

pituitary gland (pih-TU-ih-tar-e) An endocrine gland at the base of the brain

placenta (plah-SEN-tah) The organ composed of fetal and maternal tissues that nourishes and maintains the developing fetus

placenta previa (PRE-ve-ah) Placental attachment in the lower portion of the uterus instead of the upper portion, as is normal; may result in hemorrhage late in pregnancy

placental abruption (ab-RUP-shun) Premature separation of the placenta; abruptio placentae

extern.ir

plaque (plak) A patch; with regard to the cardiovascular system, a deposit of fatty material and other substances on a vessel wall that impedes blood flow and may block the vessel; atheromatous plaque

plasma (PLAZ-mah) The liquid portion of the blood

plasma cell A mature form of a B cell that produces antibodies

platelet (PLATE-let) A formed element of the blood that is active in hemostasis; a thrombocyte (root: thrombocyt/o)

pleura (PLURE-ah) A double-layered membrane that lines the thoracic cavity (parietal pleura) and covers the lungs (visceral pleura) (root: pleur/o)

pleural effusion (PLURE-al eh-FU-zhun) Accumulation of fluid in the pleural space; the fluid may contain blood (hemothorax) or pus (pyothorax or empyema)

pleural space The thin, fluid-filled space between the two layers of the pleura; pleural cavity

pleurisy (PLURE-ih-se) Inflammation of the pleura; pleuritis; a symptom of pleurisy is sharp pain on breathing

pneumoconiosis (nu-mo-ko-ne-O-sis) Disease of the respiratory tract caused by inhalation of dust particles; named more specifically by the type of dust inhaled, such as silicosis, anthracosis, asbestosis

pneumonia (nu-MO-ne-ah) Inflammation of the lungs generally caused by infection; may involve the bronchioles and alveoli (bronchopneumonia) or one or more lobes of the lung (lobar pneumonia)

pneumonitis (nu-mo-NI-tis) Inflammation of the lungs; may be caused by infection, asthma, allergy, or inhalation of irritants

pneumothorax (nu-mo-THOR-aks) Accumulation of air or gas in the pleural space; may result from injury or disease or may be produced artificially to collapse a lung

polymyositis (pol-e-mi-o-SI-tis) A disease of unknown cause involving muscular inflammation and weakness

polyp (POL-ip) A tumor that grows on a stalk and bleeds easily

polysomnography (pol-e-som-NOG-rah-fe) Simultaneous monitoring of a variety of physiologic functions during sleep to diagnose sleep disorders

pons (ponz) A rounded area on the ventral surface of the brainstem; contains fibers that connect brain regions (adjective: pontine [PON-tene])

portal hypertension An abnormal pressure increase in the hepatic portal system; may be caused by cirrhosis, infection, thrombosis, or a tumor

posttraumatic stress disorder (PTSD) Persistent emotional disturbances that follow exposure to life-threatening, catastrophic events, such as trauma, abuse, natural disasters, and warfare

potentiation (po-ten-she-A-shun) Increased potency created by two drugs acting together

Pott disease Inflammation of the vertebrae, usually caused by tuberculosis

preeclampsia (pre-eh-KLAMP-se-ah) A serious disorder involving new-onset hypertension and proteinuria that develops after 20 weeks of pregnancy. If untreated, may lead to eclampsia

prefix (PRE-fix) A word part added before a root to modify its meaning

pregnancy-induced hypertension (PIH) New-onset hypertension without proteinuria that develops during pregnancy

prepuce (PRE-pus) The fold of skin over the glans penis; the foreskin

presbyopia (prez-be-O-pe-ah) Changes in the eye that occur with age; the lens loses elasticity and the ability to accommodate for near vision

prescription (Rx) (pre-SKRIP-shun) Written and signed order for a drug with directions for its administration

pressure ulcer An ulcer caused by pressure to an area of the body, as from a bed or chair; decubitus (de-KU-bih-tus) ulcer, bedsore, pressure sore

prime mover The main muscle involved in a given movement

progesterone (pro-JES-ter-one) A hormone produced by the corpus luteum and the placenta that maintains the endometrium for pregnancy

prognosis (prog-NO-sis) Prediction of a disease's course and outcome

prolapse (PRO-laps) A dropping or downward displacement of an organ or part, ptosis

proprioception (pro-pre-o-SEP-shun) The awareness of posture, movement, and changes in equilibrium; receptors are located in muscles, tendons, and joints

prostaglandins (pros-tah-GLAN-dinz) A group of hormones produced throughout the body that have a variety of effects, including stimulation of uterine contractions and regulation of blood pressure, blood clotting, and inflammation

prostate gland (PROS-tate) A gland that surrounds the urethra below the bladder in males and contributes secretions to the semen (root: prostat/o)

prostatectomy (pros-tah-TEK-to-me) Surgical removal of the prostate

prostatitis (pros-tah-TI-tis) Inflammation of the prostate gland; often appears with UTI, STI, and a variety of other stresses

protein (PRO-tene) A category of organic compounds that includes structural materials, enzymes, and some hormones

proteinuria (pro-te-NU-re-ah) Presence of protein, mainly albumin, in the urine

pruritus (pru-RI-tus) Severe itching

psoriasis (so-RI-ah-sis) A chronic hereditary dermatitis with red lesions covered by silvery scales

psychosis (si-KO-sis) A mental disorder extreme enough to cause gross misperception of reality with delusions and hallucinations

puberty (PU-ber-te) Period during which the ability for sexual reproduction is attained and secondary sex characteristics begin to develop

pulmonary artery (PUL-mo-nar-e) The vessel that carries blood from the right side of the heart to the lungs

pulmonary circuit (SER-kit) The system of vessels that carries blood from the right side of the heart to the lungs to be oxygenated and then back to the left side of the heart

extern.ir

pulmonary function tests Tests done to assess breathing, usually by spirometry

pulmonary valve The valve at the entrance to the pulmonary artery

pulmonary veins The vessels that carry blood from the lungs to the left side of the heart

pulmonary ventilation (PUL-mo-nare-e ven-tih-LA-shun) The movement of air into and out of the lungs

pulse (puls) The wave of increased pressure produced in the vessels each time the ventricles contract

pulse oximetry (ok-SIM-eh-tre) Determination of the oxygen saturation of arterial blood by means of a photoelectric apparatus (oximeter), usually placed on the finger or the ear; reported as SpO_2 in percent

pupil (PU-pil) The opening at the center of the iris (root: pupil/o)

Purkinje fibers (pur-KIN-je) The terminal fibers of the cardiac conducting system; they carry impulses through the walls of the ventricles

purpura (PUR-pu-rah) A condition characterized by hemorrhages into the skin, mucous membranes, internal organs, and other tissues (from Greek word meaning "purple"); thrombocytopenic purpura is caused by a deficiency of platelets

pus A product of inflammation consisting of fluid and white blood cells (root: py/o)

pyelonephritis (pi-eh-lo-neh-FRI-tis) Inflammation of the renal pelvis and kidney, usually caused by infection

pyloric stenosis (pi-LOR-ik) Narrowing of the opening between the stomach and the duodenum; pylorostenosis

pylorus (pi-LOR-us) The stomach's distal opening into the duodenum (root: pylor/o); the opening is controlled by a ring of muscle, the pyloric sphincter

pyothorax (pi-o-THOR-aks) Accumulation of pus in the pleural space; empyema

pyuria (pi-U-re-ah) Presence of pus in the urine

R

radiography (ra-de-OG-rah-fe) Use of x-rays passed through the body to make a visual record (radiograph) of internal structures either on specially sensitized film or digitally; roentgenography (rent-geh-NOG-rah-fe)

receptor (re-SEP-tor) A site on the cell membrane or within the cell to which a substance, such as a hormone, attaches

rectouterine pouch (rek-to-U-ter-in) A blind pouch, such as the recess between the rectum and the uterus; the cul-de-sac or pouch of Douglas

rectum (REK-tum) The distal portion of the large intestine; it stores and eliminates undigested waste (roots: rect/o, proct/o)

reduction of a fracture Return of a fractured bone to a normal position; may be closed (not requiring surgery) or open (requiring surgery)

Reed–Sternberg cells (rede SHTERN-berg) Giant cells that are characteristic of Hodgkin disease; they usually have two large nuclei and are surrounded by a halo

reflex (RE-fleks) A simple, rapid, and automatic response to a stimulus

refraction (re-FRAK-shun) The bending of light rays as they pass through the eye to focus on a specific point on the retina; also the determination and correction of ocular refractive errors

regurgitation (re-gur-jih-TA-shun) A backward flowing, such as the backflow of undigested food

remission (re-MISH-un) Lessening of disease symptoms; the period during which this decrease occurs or the period when no sign of a disease exists

renal colic (KOL-ik) Radiating pain in the region of the kidney associated with the passage of a stone

renal cortex (RE-nal KOR-tex) The kidney's outer portion; contains portions of the nephrons

renal failure Loss of kidney function resulting from loss or damage to the kidney nephrons. May be chronic, developing over time, or acute, as a result of sudden damage, as by injury, shock, or toxins

renal medulla (meh-DUL-lah) The kidney's inner portion; contains portions of the nephrons and ducts that transport urine toward the renal pelvis

renal pelvis (PEL-vis) The expanded upper end of the ureter that receives urine from the kidney (Greek root pyel/o means "basin")

renal pyramid (PERE-ah-mid) A triangular structure in the renal medulla; composed of the nephrons' loops and collecting ducts

renal transplantation Surgical implantation of a donor kidney into a patient

renin (RE-nin) An enzyme produced by the kidneys that activates angiotensin in the blood

repetitive strain injury (RSI) Tissue damage caused by repeated motion, usually overuse of the arm or hand in occupational activities such as writing, typing, painting, or using hand tools; also called repetitive motion injury, cumulative trauma injury, overuse syndrome

repolarization (re-po-lar-ih-ZA-shun) A return of electrical charge to the resting state in nerves or muscles

resorption (re-SORP-shun) Removal of bone by breakdown and absorption into the circulation

respiratory distress syndrome (RDS) A respiratory disorder that affects premature infants born without enough surfactant in the lungs; it is treated with respiratory support and surfactant administration

reticulocyte counts (re-TIK-u-lo-site) Blood counts of reticulocytes, a type of immature red blood cell; reticulocyte counts are useful in diagnosis to indicate the rate of erythrocyte formation

retina (RET-ih-nah) The innermost, light-sensitive layer of the eye; contains the rods and cones, the specialized receptor cells for vision (root: retin/o)

retinal detachment Separation of the retina from its underlying layer

retrograde pyelography (RET-ro-grade pi-eh-LOG-rah-fe) Pyelography in which the contrast medium is injected into the kidneys from below by way of the ureters

rheumatic heart disease (ru-MAT-ik) Damage to heart valves after infection with a type of Streptococcus (group A hemolytic Streptococcus); the antibodies produced in

extern.ir

response to the infection produce valvular scarring usually involving the mitral valve

rheumatoid arthritis (RA) (RU-mah-toyd) A chronic autoimmune disease of unknown origin resulting in inflammation of peripheral joints and related structures; more common in women than in men

rheumatoid factor A group of antibodies found in the blood in cases of rheumatoid arthritis and other systemic diseases

ribonucleic acid (RNA) (ri-bo-nu-KLE-ik) An organic compound involved in the manufacture of proteins within cells

rickets (RIK-ets) Faulty bone formation in children, usually caused by a deficiency of vitamin D

right AV valve The valve between the right atrium and right ventricle; the tricuspid valve

right lymphatic duct The lymphatic duct that drains fluid from the body's upper right side

rod A specialized cell in the retina that responds to light; rods have low visual acuity, function in dim light, and do not respond to color

root (rute) The fundamental unit of a word. A branch of a spinal nerve that connects with the spinal cord; the dorsal (posterior) root joins the spinal cord's dorsal gray horn; the ventral (anterior) root joins the spinal cord's ventral gray horn (root: radicul/o)

rule of nines A method for estimating the extent of body surface area involved in a burn by assigning percentages in multiples of nine to various body regions

S

sagittal plane (SAJ-ih-tal) Plane that divides the body into right and left portions

saliva (sah-LI-vah) The clear secretion released into the mouth that moistens food and contains a starch-digesting enzyme (root: sial/o); saliva is produced by three pairs of glands: the parotid, submandibular, and sublingual glands

salpingectomy (sal-pin-JEK-to-e) Surgical removal of the uterine tube

salpingitis (sal-pin-JI-tis) Inflammation of a uterine tube, typically caused by urinary tract infection or sexually transmitted infection; chronic salpingitis may lead to infertility or ectopic pregnancy (development of the fertilized egg outside of the uterus)

sarcoma (sar-KO-mah) A malignant neoplasm arising from connective tissue (from Greek root sarco, meaning "flesh"); adjective: sarcomatous

schizophrenia (skiz-o-FRE-ne-ah) A poorly understood group of severe mental disorders with features of psychosis, delusions, hallucinations, and withdrawn or bizarre behavior (schizo means "split," and phren/o means "mind")

sciatica (si-AT-ih-kah) Severe pain in the leg along the course of the sciatic nerve, usually related to spinal nerve root irritation

sclera (SKLE-rah) The tough, white, fibrous outermost layer of the eye; the white of the eye (root: scler/o)

scleroderma (sklere-o-DER-mah) A chronic disease that is characterized by thickening and tightening of the skin and that often involves internal organs in a form called progressive systemic sclerosis (PSS)

scoliosis (sko-le-O-sis) A sideways curvature of the spine in any region

scrotum (SKRO-tum) A double pouch that contains the testes (root: osche/o)

sebaceous gland (se-BA-shus) A skin gland that produces sebum; usually associated with a hair follicle (root: seb/o)

sebum (SE-bum) A fatty secretion of the sebaceous glands that lubricates the hair and skin (root: seb/o)

seizure (SE-zhur) A sudden attack, as seen in epilepsy; the most common forms of seizure are tonic–clonic, or grand mal (gran mal) (from French, meaning "great illness"); absence seizure, or petit mal (pet-E mal), meaning "small illness"; and psychomotor seizure

selective estrogen receptor modulator (SERM) Drug that acts on estrogen receptors; raloxifene (Evista) is used to prevent bone loss after menopause; other SERMs are used to prevent and treat estrogen-sensitive breast cancer

semen The thick secretion that transports spermatozoa (roots: semin, sperm/i, spermat/o)

semicircular canals The three curved channels of the inner ear that hold receptors for equilibrium

seminal vesicle (SEM-ih-nal VES-ih-kl) A sac-like gland behind the bladder that contributes secretions to the semen (root: vesicul/o)

sensorineural hearing loss (sen-so-re-NU-ral) Hearing impairment that results from damage to the inner ear, eighth cranial nerve, or auditory pathways in the brain

sensory (SEN-so-re) Pertaining to the senses or sensation; describing afferent neurons and nerves that carry impulses toward the CNS

sensory receptor (re-SEP-tor) A sensory nerve ending or a specialized structure associated with a sensory nerve that responds to a stimulus

sentinel node biopsy (SEN-tih-nel) Biopsy of the first lymph nodes to receive drainage from a tumor; used to determine spread of cancer in planning treatment

sepsis (SEP-sis) The presence of harmful microorganisms or their toxins in the blood or other tissues; adjective: septic

septal defect (SEP-tal) An opening in the septum between the atria or ventricles; a common cause is persistence of the foramen ovale (for-A-men o-VAL-e), an opening between the atria that bypasses the lungs in fetal circulation

septum (SEP-tum) A wall dividing two cavities, such as two chambers of the heart

Sertoli cell (ser-TO-le) Cell in a seminiferous tubule that aids in the development of spermatozoa; sustentacular (sus-ten-TAK-u-lar) cell

serum (SERE-um) The fraction of the plasma that remains after blood coagulation; it is the equivalent of plasma without its clotting factors (plural: sera, serums)

sexually transmitted infection (STI) Infection spread through sexual activity; also called sexually transmitted disease (STD) and formerly venereal (veh-NE-re-al) disease (VD) (from Venus, the goddess of love)

extern.ir

shingles An acute viral infection that follows nerve pathways causing small lesions on the skin; caused by reactivation of the virus that also causes chickenpox (varicella-zoster virus); also called herpes zoster (HER-peze ZOS-ter)

shock Circulatory failure resulting in an inadequate blood supply to the tissues; cardiogenic shock is caused by heart failure; hypovolemic shock is caused by a loss of blood volume; septic shock is caused by bacterial infection

sickle cell anemia (SIK-l) A hereditary anemia caused by the presence of abnormal hemoglobin; red blood cells become sickle-shaped when they give up oxygen and interfere with normal blood flow to the tissues; most common in black populations of West African descent

side effect A result of drug therapy or other therapy that is unrelated to or an extension of its intended effect; usually applies to an undesirable effect of treatment

sideroblastic anemia (sid-eh-ro-BLAS-tik) Anemia caused by inability to use available iron to manufacture hemoglobin; the excess iron precipitates in normoblasts (developing red blood cells)

sigmoid colon Distal S-shaped portion of the large intestine located between the descending colon and the rectum

sign (sine) Objective evidence of disease that can be observed or tested; examples are fever, rash, high blood pressure, and blood or urine abnormalities; an objective symptom

sinoatrial (SA) node (si-no-A-tre-al) A small mass in the upper part of the right atrium that initiates the impulse for each heartbeat; the pacemaker

sinus (SI-nus) A cavity or channel; the paranasal sinuses are located near the nose and drain into the nasal cavity

sinus rhythm (SI-nus RITH-um) Normal heart rhythm

Sjögren syndrome (SHO-gren) An autoimmune disease involving dysfunction of the exocrine glands and affecting secretion of tears, saliva, and other body fluids; deficiency leads to dry mouth, tooth decay, corneal damage, eye infections, and difficulty in swallowing

skeletal muscle (SKEL-eh-tal) Voluntary muscle that moves the skeleton and maintains posture

skeleton (SKEL-eh-ton) The body's bony framework, consisting of 206 bones; the axial portion (80 bones) is composed of the skull, spinal column, ribs, and sternum; the appendicular skeleton (126 bones) contains the bones of the arms and legs, shoulder girdle, and pelvis (root: skelet/o)

skin The tissue that covers the body; the integument (roots: derm/o, dermat/o)

sleep apnea (ap-NE-ah) Brief periods of breathing cessation during sleep

small intestine (in-TES-tin) The portion of the intestine between the stomach and the large intestine; comprised of the duodenum, jejunum, and ileum; accessory organs secrete into the small intestine, and almost all digestion and absorption occur there

smooth muscle Involuntary muscle that makes up the wall of hollow organs, vessels, and ducts; visceral muscle

somatic nervous system (so-MAT-ik) The division of the nervous system that controls skeletal (voluntary) muscles

specific gravity (SG) The weight of a substance compared with the weight of an equal volume of water; the specific gravity of normal urine ranges from 1.015 to 1.025; this value may increase or decrease in disease

spermatic cord (sper-MAT-ik) Cord attached to the testis that contains the ductus deferens, blood vessels, and nerves enclosed within a fibrous sheath

spermatozoon (sper-mah-to-ZO-on) Mature male sex cell (plural: spermatozoa) (roots: sperm/i, spermat/o)

sphygmomanometer (sfig-mo-mah-NOM-eh-ter) Instrument for determining arterial blood pressure; pressure is read in millimeters of mercury (mm Hg) when the heart is contracting (systolic pressure) and when the heart is relaxing (diastolic pressure) and is reported as systolic/diastolic; (root sphygm/o means "pulse"). Blood pressure apparatus or blood pressure cuff

spina bifida (SPI-nah BIF-ih-dah) A congenital defect in the closure of the spinal column through which the spinal cord and its membranes may project

spinal cavity (canal) (SPI-nal) Dorsal cavity that contains the spinal cord

spinal cord The nervous tissue contained within the spinal column; extends from the medulla oblongata to the second lumbar vertebra (root: myel/o)

spinal nerves The 31 pairs of nerves that connect with the spinal cord

spiral organ (SPI-ral) The hearing receptor, which is located in the cochlea of the inner ear; organ of Corti (KOR-te)

spirometer (spi-ROM-eh-ter) An apparatus used to measure breathing volumes and capacities; record of test is a spirogram

spleen A large reddish-brown organ in the upper left region of the abdomen; it filters blood and destroys old red blood cells (root: splen/o)

splenomegaly (sple-no-MEG-ah-le) Enlargement of the spleen

spondylolisthesis (spon-dih-lo-lis-THE-sis) A forward displacement of one vertebra over another (-listhesis means "a slipping"); also pronounced spon-dih-lo-LIS-theh-sis

spondylolysis (spon-dih-LOL-ih-sis) Degeneration of the articulating portions of a vertebra allowing for spinal distortion, specifically in the lumbar region

sprain (sprane) Injury to a ligament caused by abnormal or excessive force at a joint, but without bone dislocation or fracture

sputum (SPU-tum) The substance released by coughing or clearing the throat; expectoration; it may contain a variety of materials from the respiratory tract

squamous cell carcinoma (SKWA-mus) An epidermal cancer that may invade deeper tissues but tends not to metastasize

staging (STA-jing) The process of classifying malignant tumors for diagnosis, treatment, and prognosis

stapedectomy (sta-pe-DEK-to-me) Surgical removal of the stapes; it may be combined with insertion of a prosthesis to correct otosclerosis

stapes (STA-peze) The ossicle that is in contact with the inner ear (roots: staped/o, stapedi/o)

extern.ir

stenosis (steh-NO-sis) Constriction or narrowing of an opening

stent A small metal device in the shape of a coil or slotted tube that is placed inside an artery to keep the vessel open, for example, after balloon angioplasty

stereotactic biopsy (ster-e-o-TAK-tik BI-op-se) Needle biopsy using a computer-guided imaging system to locate suspicious tissue and remove samples for study

sterility (steh-RIL-ih-te) Complete inability to produce offspring

steroid hormone (STER-oyd) A hormone made from lipids; includes the sex hormones and the hormones of the adrenal cortex

stethoscope (STETH-o-skope) An instrument used for listening to sounds produced within the body (from the Greek root steth/o, meaning "chest")

stoma (STO-mah) A surgically created opening to the body surface or between two organs (literally "mouth")

stomach (STUM-ak) A muscular sac-like organ below the diaphragm that stores food and secretes juices that digest proteins (root: gastr/o)

strain (strane) Trauma to a muscle because of overuse or excessive stretch; if severe, may involve muscular tearing, bleeding, separation of a muscle from its tendon, or tendon separation from a bone

stress test Evaluation of physical fitness by continuous ECG monitoring during exercise; in a thallium stress test, a radioactive isotope of thallium is administered to trace blood flow through the heart during exercise

stroke Sudden interference with blood flow in one or more cerebral vessels leading to oxygen deprivation and necrosis of brain tissue; caused by a blood clot in a vessel (ischemic stroke) or rupture of a vessel (hemorrhagic stroke); cerebrovascular accident (CVA)

subcutaneous layer (sub-ku-TA-ne-us) The layer of tissue beneath the skin; also called the hypodermis

subdural hematoma (sub-DU-ral he-mah-TO-mah) Accumulation of blood beneath the dura mater

substance dependence A condition that may result from chronic use of a drug, in which a person has a chronic or compulsive need for a drug regardless of its adverse effects; dependence may be psychological or physical

sudden infant death syndrome (SIDS) The sudden and unexplained death of an apparently healthy infant; crib death

suffix (SUH-fix) A word part added to the end of a root to modify its meaning

sulcus (SUL-kus) A shallow furrow or groove, as on the surface of the cerebrum (plural: sulci)

superior vena cava (VE-nah KA-vah) The large superior vein that brings blood low in oxygen back to the right atrium from the upper body

surfactant (sur-FAK-tant) A substance that decreases surface tension within the alveoli and eases lung expansion

surgery (SUR-jer-e) A method for treating disease or injury by manual operations

suture (SU-chur) To unite parts by stitching them together; also the thread or other material used in that process or the seam formed by surgical stitching (suffix: -rhaphy). In the skeletal system, an immovable joint, such as a joint between skull bones

sweat gland (swet) A gland that releases a watery fluid (perspiration) to the skin surface in order to cool the body. Certain sweat glands, located mainly in the armpits and groin area, release secretions with some cellular material in response to stress. A sudoriferous (sudor-IF-er-us) gland (root: hidr/o)

sympathetic nervous system (sim-pah-THET-ik) The part of the autonomic nervous system that mobilizes a response to stress, increases heart rate and respiration rate, and delivers more blood to skeletal muscles

symphysis (SIM-fih-sis) A slightly movable joint

symptom (SIMP-tum) Any evidence of disease; sometimes limited to subjective evidence of disease as experienced by the individual, such as pain, dizziness, and weakness

synapse (SIN-aps) The junction between two neurons; also the junction between a motor neuron and a muscle or gland

syncope (SIN-ko-pe) A temporary loss of consciousness caused by inadequate blood flow to the brain; fainting

synergist (SIN-er-jist) A muscle that assists a prime mover to produce a given movement

synergy (SIN-er-je) Combined action of two or more drugs working together to produce an effect greater than any of the drugs could produce when acting alone; also called synergism (SIN-er-jizm); adjective: synergistic (sin-er-JIS-tik)

synovial fluid (sih-NO-ve-al) The fluid contained in a freely movable (diarthrotic) joint; synovia (root: synov/i)

synovial joint A freely movable joint; has a joint cavity containing synovial fluid; a diarthrosis

systemic circuit (sis-TEM-ik SER-kit) The system of vessels that carries oxygenated blood from the left side of the heart to all tissues except the lungs and returns deoxygenated blood to the right side of the heart

systemic lupus erythematosus (LU-pus er-ih-the-mah-TO-sus) Inflammatory connective tissue disease affecting the skin and multiple organs; patients are sensitive to light and may have a red butterfly-shaped rash over the nose and cheeks

systemic sclerosis A diffuse connective tissue disease that may involve any system causing inflammation, degeneration, and fibrosis; also called scleroderma because it causes thickening of the skin

systole (SIS-to-le) The contraction phase of the heartbeat cycle (adjective: systolic)

T

T cell A lymphocyte that matures in the thymus and attacks foreign cells directly; T lymphocyte

tachycardia (tak-ih-KAR-de-ah) An abnormally rapid heart rate, usually over 100 bpm

tactile (TAK-til) Pertaining to the sense of touch

target tissue The specific tissue on which a hormone acts; may also be called the target organ

extern.ir

tendinitis (ten-dih-NI-tis) Inflammation of a tendon, usually caused by injury or overuse; the shoulder, elbow, and hip are common sites; also spelled tendonitis

tendon (TEN-dun) A fibrous band of connective tissue that attaches a muscle to a bone (roots: ten/o, tendin/o)

tenosynovitis (ten-o-sin-o-VI-tis) Inflammation of a tendon and its sheath

teratogen (ter-AT-o-jen) A factor that causes developmental abnormalities in the fetus (root terat/o means "malformed fetus") (adjective: teratogenic)

testis (TES-tis) The male reproductive gland (roots: test/o, orchi/o, orchid/o); plural is testes (TES-teze); also called testicle

testosterone (tes-TOS-ter-one) The main male sex hormone

tetany (TET-ah-ne) Irritability and spasms of muscles; may be caused by low blood calcium and other factors

thalamus (THAL-ah-mus) The part of the brain that receives all sensory impulses, except those for the sense of smell, and directs them to the proper portion of the cerebral cortex (root: thalam/o)

thalassemia (thal-ah-SE-me-ah) A group of hereditary anemias mostly found in populations of Mediterranean descent (the name comes from the Greek word for "sea")

therapy (THER-ah-pe) Treatment, intervention

thoracentesis (thor-ah-sen-TE-sis) Surgical puncture of the chest for removal of air or fluids, such as may accumulate after surgery or as a result of injury, infection, or cardiovascular problems; also called thoracocentesis

thoracic cavity (tho-RAS-ik) The ventral cavity above the diaphragm, the chest cavity

thoracic duct The lymphatic duct that drains fluid from the upper left side of the body and all of the lower body; left lymphatic duct

thorax (THO-raks) The upper part of the trunk between the neck and the abdomen; formed by the 12 pairs of ribs and sternum

thrombocyte (THROM-bo-site) A blood platelet (root: thrombocyt/o)

thrombocytopenia (throm-bo-si-to-PE-ne-ah) A deficiency of thrombocytes (platelets) in the blood

thrombophlebitis (throm-bo-fleh-BI-tis) Inflammation of a vein associated with formation of a blood clot

thrombosis (throm-BO-sis) Development of a blood clot within a vessel

thrombus (THROM-bus) A blood clot that forms within a blood vessel (root: thromb/o)

thymus (THI-mus) A lymphoid organ in the upper part of the chest beneath the sternum; it functions in immunity (root: thym/o)

thyroid gland An endocrine gland on either side of the larynx and upper trachea; it secretes hormones that affect metabolism and growth (roots: thyr/o, thyroid/o)

tinnitus (TIN-ih-tus) A sensation of noises, such as ringing or tinkling, in the ear; also pronounced tih-NI-tus

tissue (TISH-u) A group of cells that acts together for a specific purpose (roots: hist/o, histi/o); types include epithelial tissue, connective tissue, muscle tissue, and nervous tissue

tolerance A condition in which chronic use of a drug results in loss of effectiveness and the dose must be increased to produce the original response

tomosynthesis (toh-mo-SIN-theh-sis) Three-dimensional x-ray imaging technique for detection of breast cancer; digital tomosynthesis

tonsil (TON-sil) Small mass of lymphoid tissue located in region of the throat (pharynx)

tonus (TO-nus) A state of steady, partial muscle contraction that maintains firmness; muscle tone (root: ton/o)

toxin (TOKS-in) A poison; adjective: toxic (roots: tox/o, toxic/o)

trachea (TRA-ke-ah) The air passageway that extends from the larynx to the bronchi (root: trache/o)

trachoma (trah-KO-mah) An infection caused by *Chlamydia trachomatis* leading to inflammation and scarring of the cornea and conjunctiva; a common cause of blindness in underdeveloped countries

tract (trakt) A bundle of neuron fibers within the CNS

traction (TRAK-shun) The process of drawing or pulling, such as traction of the head in the treatment of injuries to the cervical vertebrae

transverse (horizontal) plane (trans-VERS) Plane that divides the body into superior (upper) and inferior (lower) portions

trauma (TRAW-mah) A physical or psychological wound or injury

tremor (TREM-or) A shaking or involuntary movement

trigone (TRI-gone) A triangle at the base of the bladder formed by the openings of the two ureters and the urethra

troponin (Tn) (tro-PO-nin) A protein in muscle cells that regulates contraction; increased serum levels, primarily in the forms TnT and TnI, indicate recent myocardial infarction (MI)

tubal ligation (TU-bal li-GA-shun) Surgical constriction of the uterine tubes to produce sterilization

tuberculin test (tu-BER-ku-lin) A skin test for tuberculosis; tuberculin (PPD), the test material made from products of the tuberculosis organism, is injected below the skin; a hard, raised lump appearing within 48 to 72 hours indicates an active or inactive TB infection; also called the Mantoux (man-TOO) test

tuberculosis (tu-ber-ku-LO-sis) An infectious disease caused by the tubercle bacillus, *Mycobacterium tuberculosis*; often involves the lungs but may involve other parts of the body as well; miliary (MIL-e-ar-e) tuberculosis is an acute generalized form of the disease with formation of minute tubercles that resemble millet seeds

tubular reabsorption (TUBE-u-lar re-ab-SORP-shun) The return of substances from the glomerular filtrate to the blood through the peritubular capillaries

turbinate bones (TUR-bih-nate) The bony projections in the nasal cavity that contain receptors for the sense of smell; also called conchae (KON-ke) (singular: concha [KON-kah])

extern.ir

tympanic membrane (tim-PAN-ik) The membrane between the external auditory canal and the middle ear (tympanic cavity); the eardrum; it serves to transmit sound waves to the ossicles of the middle ear (roots: myring/o, tympan/o)

U

ulcerative colitis (UL-ser-ah-tiv ko-LI-tis) Chronic ulceration of the rectum and colon; the cause is unknown, but may involve autoimmunity

ultrasonography (ul-trah-so-NOG-rah-fe) The use of high-frequency sound waves to produce a photograph of an organ or tissue; used in obstetrics to diagnose pregnancy, multiple births, and abnormalities and also to study and measure the fetus; the image obtained is a sonogram or ultrasonogram

umbilical cord (um-BIL-ih-kal) The structure that connects the fetus to the placenta; it contains vessels that carry blood between the mother and the fetus

urea (u-RE-ah) The main nitrogenous (nitrogen-containing) waste product in the urine

uremia (u-RE-me-ah) Presence of toxic levels of urea and other nitrogenous substances in the blood as a result of renal insufficiency

ureter (U-re-ter) The tube that carries urine from the kidney to the bladder (root: ureter/o)

urethra (u-RE-thrah) The duct that carries urine out of the body and also transports semen in the male (root: urethr/o)

urethritis (u-re-THRI-tis) Inflammation of the urethra; often caused by gonorrhea and chlamydia infections

urinalysis (UA) (u-rih-NAL-ih-sis) Laboratory study of the urine; physical and chemical properties and microscopic appearance are included

urinary bladder (u-rih-NAR-e BLAD-der) The organ that stores and eliminates urine excreted by the kidneys (roots: cyst/o, vesic/o)

urinary stasis (STA-sis) Stoppage of urine flow; urinary stagnation

urination (u-rih-NA-shun) The voiding of urine; micturition

urine (U-rin) The fluid excreted by the kidneys; it consists of water, electrolytes, urea, other metabolic wastes, and pigments; a variety of other substances may appear in urine in cases of disease (root: ur/o)

urticaria (ur-tih-KAR-e-ah) A skin reaction consisting of round, raised eruptions (wheals) with itching; hives

uterine tube (U-ter-in) A tube extending from the upper lateral portion of the uterus that carries the ovum to the uterus (root: salping/o); also called fallopian (fah-LO-pe-an) tube

uterus (U-ter-us) The organ that receives the fertilized egg and maintains the developing offspring during pregnancy (roots: uter/o, metr, hyster/o)

uvea (U-ve-ah) The middle, vascular layer of the eye (root: uve/o); consists of the choroid, ciliary body, and iris

uvula (U-vu-lah) The fleshy mass that hangs from the soft palate; aids in speech production (literally "little grape") (root: uvul/o)

V

vagina (vah-JI-nah) The muscular tube between the cervix and the vulva (roots: vagin/o, colp/o)

vaginitis (vaj-ih-NI-tis) Inflammation of the vagina

valve (valv) A structure that keeps fluid flowing in a forward direction (roots: valv/o, valvul/o)

varicose vein (VAR-ih-kose) A twisted and swollen vein resulting from breakdown of the valves, pooling of blood, and chronic dilatation of the vessel (root: varic/o); also called varix (VAR-iks) or varicosity (var-ih-KOS-ih-te)

vas deferens (DEF-er-enz) The duct that conveys spermatozoa from the epididymis to the ejaculatory duct; also called ductus deferens

vasectomy (vah-SEK-to-me) Excision of the vas deferens; usually done bilaterally to produce sterility; may be accomplished through the urethra (transurethral resection)

vein (vane) A vessel that carries blood back to the heart. All except the pulmonary and umbilical veins carry blood low in oxygen (roots: ven/o, phleb/o)

ventricle (VEN-trik-l) A small cavity, such as one of the cavities in the brain in which CSF is formed. One of the two lower pumping chambers of the heart (root: ventricul/o)

venule (VEN-ule) A small vessel that carries blood from the capillaries to the veins

vertigo (VER-tih-go) An illusion of movement, as of the body moving in space or the environment moving about the body; usually caused by disturbances in the vestibular apparatus; used loosely to mean dizziness or lightheadedness

vessel (VES-el) Tube or duct to transport fluid (roots: angi/o, vas/o, vascul/o)

vestibular apparatus (ves-TIB-u-lar) The portion of the inner ear that is concerned with the sense of equilibrium; it consists of the vestibule and the semicircular canals (root: vestibul/o)

vestibule (VES-tih-bule) The chamber in the inner ear that holds some of the receptors for equilibrium

vestibulocochlear nerve (ves-tib-u-lo-KOK-le-ar) The nerve that transmits impulses for hearing and equilibrium from the ear to the brain; eighth cranial nerve; auditory or acoustic nerve

villi (VIL-i) Tiny projections in the lining of the small intestine that absorb digested foods into the circulation (singular: villus)

visceral nervous system (VIS-er-al) The autonomic nervous system

vision (VIZH-un) The sense by which the shape, size, and color of objects are perceived by means of the light they give off

visual acuity (ah-KU-ih-te) Sharpness of vision

vital signs (VI-tal) Measurements that reflect basic functions necessary to maintain life

vitreous body (VIT-re-us) The transparent jelly-like mass that fills the eyeball's main cavity; also called vitreous humor

vocal folds (VO-kal) Membranous folds on either side of the larynx that are important in speech production; also called vocal cords

extern.ir

volvulus (VOL-vu-lus) Twisting of the intestine resulting in obstruction; usually involves the sigmoid colon and occurs most often in children and in the elderly; may be caused by congenital malformation, a foreign body, or adhesion; failure to treat immediately may result in death

vulva (VUL-va) The external female genital organs (roots: vulv/o, episi/o)

W

white matter Myelinated tissue of the nervous system

withdrawal A condition that results from abrupt cessation or reduction of a drug that has been used regularly

Z

zygote (ZI-gote) The fertilized ovum

extern.ir

Figure Credits

Chapter 1

Figure 1-3. Cohen B, Hull K. *Memmler's The Human Body in Health and Disease*. 14th ed. Baltimore, MD: Wolters Kluwer Health; 2019.

Figure 1-4. Cohen B, Hull K. *Memmler's The Human Body in Health and Disease*. 14th ed. Baltimore, MD: Wolters Kluwer Health; 2019.

Figure 1-5. Smeltzer SC, et al. *Medical-Surgical Nursing*. 12th ed. Philadelphia, PA: Wolters Kluwer Health; 2010.

Figure 1-6. Taylor C, et al. *Fundamentals of Nursing*. 7th ed. Philadelphia, PA: Lippincott Williams & Wilkins; 2011.

Figure 1-7. Taylor C, et al. *Fundamentals of Nursing*. 7th ed. Philadelphia, PA: Lippincott Williams & Wilkins; 2011.

Figure 1-8. Cohen B, Hull K. *Memmler's The Human Body in Health and Disease*. 14th ed. Baltimore, MD: Lippincott Williams & Wilkins; 2019.

Figure 1-9. Cormack DH. *Essential Histology*. 2nd ed. Philadelphia, PA: Lippincott Williams & Wilkins; 2001.

Figure 1-10. Cohen B, Hull K. *Memmler's The Human Body in Health and Disease*. 14th ed. Baltimore, MD: Lippincott Williams & Wilkins; 2019.

Figure 1-11. Cohen B, Hull K. *Memmler's The Human Body in Health and Disease*. 14th ed. Baltimore, MD: Lippincott Williams & Wilkins; 2019.

Figure 1-12. Cormack DH. *Essential Histology*. 2nd ed. Philadelphia, PA: Lippincott Williams & Wilkins; 2001.

Figure 1-13. Cohen B, Hull K. *Memmler's The Human Body in Health and Disease*. 14th ed. Baltimore, MD: Lippincott Williams & Wilkins; 2019.

Figure 1-14. Cohen B, Hull K. *Memmler's The Human Body in Health and Disease*. 14th ed. Baltimore, MD: Lippincott Williams & Wilkins; 2019.

Figure 1-15. Cohen B, Hull K. *Memmler's The Human Body in Health and Disease*. 14th ed. Baltimore, MD: Lippincott Williams & Wilkins; 2019.

Figure 1-16. Koneman EW, et al. *Diagnostic Microbiology*. 6th ed. Philadelphia, PA: Lippincott Williams & Wilkins; 2005.

Figure 1-17. Bickley LS. *Bates' Guide to Physical Examination and History Taking*. 10th ed. Philadelphia, PA: Lippincott Williams & Wilkins; 2009.

Figure 1-18. Cohen B, Hull K. *Memmler's The Human Body in Health and Disease*. 14th ed. Baltimore, MD: Lippincott Williams & Wilkins; 2019.

Figure 1-19. Taylor C, et al. *Fundamentals of Nursing*. 7th ed. Philadelphia, PA: Lippincott Williams & Wilkins; 2011.

Figure 1-20. Cohen B, Hull K. *Memmler's The Human Body in Health and Disease*. 14th ed. Baltimore, MD: Lippincott Williams & Wilkins; 2019.

Figure 1-21. Cohen B, Hull K. *Memmler's The Human Body in Health and Disease*. 14th ed. Baltimore, MD: Lippincott Williams & Wilkins; 2019.

Chapter 2

Figure 2-1. Cohen B, Hull K. *Memmler's The Human Body in Health and Disease*. 14th ed. Baltimore, MD: Lippincott Williams & Wilkins; 2019.

Figure 2-2. Cohen B, Hull K. *Memmler's The Human Body in Health and Disease*. 14th ed. Baltimore, MD: Lippincott Williams & Wilkins; 2019.

Figure 2-3. Courtesy Wenda S. Long, Thomas Jefferson University, Philadelphia, PA.

Figure 2-4. Cohen B, Hull K. *Memmler's The Human Body in Health and Disease*. 14th ed. Baltimore, MD: Lippincott Williams & Wilkins; 2019.

Figure 2-5. Cormack DH. *Essential Histology*. 2nd ed. Baltimore, MD: Lippincott Williams & Wilkins; 2001.

Figure 2-6. Parts A and B: Mills SE. *Histology for Pathologists*. 3rd ed. Philadelphia, PA: Lippincott Williams & Wilkins; 2006. **Part C:** Gartner LP, Hiatt JL. *Color Atlas of Histology*. 5th ed. Baltimore, MD: Lippincott Williams & Wilkins; 2009.

Figure 2-7. Part A: Cormack DH. *Essential Histology*. 2nd ed. Baltimore, MD: Lippincott Williams & Wilkins; 2001. **Part B:** Gartner LP, Hiatt JL. *Color Atlas of Histology*. 5th ed. Baltimore, MD: Lippincott Williams & Wilkins; 2009.

Figure 2-8. Cormack DH. *Essential Histology*. 2nd ed. Baltimore, MD: Lippincott Williams & Wilkins; 2001.

Figure 2-9. McConnell T, Hull K. *Human Form, Human Function*. Philadelphia, PA: Lippincott Williams & Wilkins; 2011.

Figure 2-10. Courtesy Wenda S. Long, Thomas Jefferson University, Philadelphia, PA.

Figure 2-11. Cohen B, Hull K. *Memmler's The Human Body in Health and Disease*. 14th ed. Baltimore, MD: Lippincott Williams & Wilkins; 2019.

Figure 2-12. Cohen B, Hull K. *Memmler's The Human Body in Health and Disease*. 14th ed. Baltimore, MD: Lippincott Williams & Wilkins; 2019.

Figure 2-13. Cohen B, Hull K. *Memmler's The Human Body in Health and Disease*. 14th ed. Baltimore, MD: Lippincott Williams & Wilkins; 2019.

Figure 2-14. Cohen B, Hull K. *Memmler's The Human Body in Health and Disease*. 14th ed. Baltimore, MD: Lippincott Williams & Wilkins; 2019.

Figure 2-15. McConnell T, Hull K. *Human Form, Human Function*. Philadelphia, PA: Lippincott Williams & Wilkins; 2011.

Figure 2-16. McConnell T, Hull K. *Human Foundations*. Philadelphia, PA: Lippincott Williams & Wilkins; 2011.

Figure 2-17. Cohen B, Hull K. *Memmler's The Human Body in Health and Disease*. 14th ed. Baltimore, MD: Lippincott Williams & Wilkins; 2019.

extern.ir

Chapter 3

Figure 3-1. A: Koneman EW, et al. *Color Atlas and Textbook of Diagnostic Microbiology.* 6th ed. Philadelphia, PA: Lippincott Williams & Wilkins; 2008. **B:** Harvey RA, Comelissen CN. *Lippincott Illustrated Reviews, Microbiology*. Philadelphia, PA: Lippincott Williams & Wilkins; 2012. **C:** Koneman EW, et al. *Color Atlas and Textbook of Diagnostic Microbiology*. 6th ed. Philadelphia, PA: Lippincott Williams & Wilkins; 2008. **D:** Image courtesy of the Centers for Disease Control (CDC). **E:** Volk WA, et al. *Essentials of Medical Microbiology*. 5th ed. Philadelphia, PA: Lippincott-Raven; 1996.

Figure 3-2. Bickley LS. *Bates' Guide to Physical Examination and History Taking*. 10th ed. Philadelphia, PA: Lippincott Williams & Wilkins; 2009.

Figure 3-3. A: Cohen B, Hull K. *Memmler's The Human Body in Health and Disease*. 14th ed. Baltimore, MD: Lippincott Williams & Wilkins; 2019. **B:** McConnell T, Hull K. *Human Form, Human Function*. Philadelphia, PA: Lippincott Williams & Wilkins; 2011.

Figure 3-4. A: McConnell T, Hull K. *Human Form, Human Function*. Philadelphia, PA: Lippincott Williams & Wilkins; 2011. **B:** Anatomical Chart Company Atlas of Pathophysicology. 3rd ed. Philadelphia, PA: Lippincott Williams & Wilkins; 2011.

Figure 3-6. Taylor C, et al. *Fundamentals of Nursing*. 7th ed. Philadelphia, PA: Lippincott Williams & Wilkins; 2011.

Figure 3-7. Taylor C, et al. *Fundamentals of Nursing*. 6th ed. Philadelphia, PA: Lippincott Williams & Wilkins; 2006.

Figure 3-8. Taylor C, et al. *Fundamentals of Nursing*. 7th ed. Philadelphia, PA: Lippincott Williams & Wilkins; 2006.

Figure 3-9. Taylor C, et al. *Fundamentals of Nursing*. 7th ed. Philadelphia, PA: Lippincott Williams & Wilkins; 2011.

Figure 3-10. Taylor C, et al. *Fundamentals of Nursing*. 6th ed. Philadelphia, PA: Lippincott Williams & Wilkins; 2006.

Figure 3-11. Taylor C, et al. *Fundamentals of Nursing*. 7th ed. Philadelphia, PA: Lippincott Williams & Wilkins; 2011.

Figure 3-13. Erkonen WE, Smith WL. *Radiology 101*. 3rd ed. Philadelphia, PA: Lippincott Williams & Wilkins; 2010.

Figure 3-14. Erkonen WE, Smith WL. *Radiology 101*. 3rd ed. Philadelphia, PA: Lippincott Williams & Wilkins; 2010.

Figure 3-15. A: Pilletteri A. *Maternal and Child Health Nursing*. 6th ed. Philadelphia, PA: Lippincott Williams & Wilkins; 2009. **B:** Bushberg JT, et al. *Essential Physics of Medical Imaging*. 3rd ed. Philadelphia, PA: Lippincott Williams & Wilkins; 2011.

Figure 3-17. Taylor C, et al. *Fundamentals of Nursing*. 7th ed. Philadelphia, PA: Lippincott Williams & Wilkins; 2011.

Figure 3-18. Smeltzer SC, et al. *Medical-Surgical Nursing*. 12th ed. Philadelphia, PA: Lippincott Williams & Wilkins; 2010.

Figure 3-19. Taylor C, et al. *Fundamentals of Nursing*. 6th ed. Philadelphia, PA: Lippincott Williams & Wilkins; 2006.

Figure 3-20. Taylor C, et al. *Fundamentals of Nursing*. 7th ed. Philadelphia, PA: Lippincott Williams & Wilkins; 2011.

Figure 3-21. Rosdahl CB, Kowalski MT. *Textbook of Basic Nursing*. 9th ed. Philadelphia, PA: Lippincott Williams & Wilkins; 2007.

Figure 3-23. A: Taylor C, et al. *Fundamentals of Nursing*. 6th ed. Philadelphia, PA: Lippincott Williams & Wilkins; 2006.

Chapter 4

Figure 4-1. Cohen B, Hull K. *Memmler's The Human Body in Health and Disease*. 14th ed. Baltimore, MD: Lippincott Williams & Wilkins; 2019.

Figure 4-2. A: Bickley LS. *Bates' Guide to Physical Examination and History Taking*. 10th ed. Philadelphia, PA: Lippincott Williams & Wilkins; 2009.

Figure 4-2. B: Cohen B, Hull K. *Memmler's The Human Body in Health and Disease*. 14th ed. Baltimore, MD: Lippincott Williams & Wilkins; 2019.

Figure 4-3. Rubin R, Strayer DS. *Rubin's Pathology.* 6th ed. Baltimore, MD: Lippincott Williams & Wilkins; 2012.

Figure 4-4. Cohen B, Hull K. *Memmler's The Human Body in Health and Disease*. 13th ed. Baltimore, MD: Lippincott Williams & Wilkins; 2015.

Figure 4-5. Hall JC. *Sauer's Manual of Skin Diseases*. 9th ed. Philadelphia, PA: Lippincott Williams & Wilkins; 2006.

Figure 4-6. Bickley LS. *Bates' Guide to Physical Examination and History Taking*. 10th ed. Philadelphia, PA: Lippincott Williams & Wilkins; 2009.

Figure 4-7. Nettina SM. *Lippincott Manual of Nursing Practice*. 9th ed. Philadelphia, PA: Lippincott Williams & Wilkins; 2009.

Figure 4-8. Hall JC. *Sauer's Manual of Skin Diseases*. 9th ed. Baltimore, MD: Lippincott Williams & Wilkins; 2006.

Figure 4-9. Bickley LS. *Bates' Guide to Physical Examination and History Taking*. 10th ed. Philadelphia, PA: Lippincott Williams & Wilkins; 2009.

Figure 4-10. Bickley LS. *Bates' Guide to Physical Examination and History Taking*. 10th ed. Philadelphia, PA: Lippincott Williams & Wilkins; 2009.

Figure 4-11. The American Cancer Society, American Academy of Dermatology.

Figure 4-12. Bickley LS. *Bates' Guide to Physical Examination and History Taking*. 10th ed. Philadelphia, PA: Lippincott Williams & Wilkins; 2009.

Figure 4-13. Smeltzer SC, Bare B. *Medical-Surgical Nursing*. 11th ed. Philadelphia, PA: Wolters Kluwer Health; 2009.

Figure 4-14. Goodheart HP. *Photoguide of Common Skin Disorders*. 2nd ed. Philadelphia, PA: Lippincott Williams & Wilkins; 2003.

Figure 4-15. Bickley LS. *Bates' Guide to Physical Examination and History Taking*. 10th ed. Philadelphia, PA: Lippincott Williams & Wilkins; 2009.

Figure 4-16. Hall JC. *Sauer's Manual of Skin Diseases*. 8th ed. Philadelphia, PA: Lippincott Williams & Wilkins; 1999.

Figure 4-17. Bickley LS. *Bates' Guide to Physical Examination and History Taking*. 10th ed. Philadelphia, PA: Lippincott Williams & Wilkins; 2009.

Figure 4-18. Smeltzer SC, Bare B. *Medical-Surgical Nursing*. 11th ed. Philadelphia, PA: Wolters Kluwer Health; 2009.

Figure 4-19. Bickley LS. *Bates' Guide to Physical Examination and History Taking*. 10th ed. Philadelphia, PA: Lippincott Williams & Wilkins; 2009.

extern.ir

Chapter 5

Figure 5-1. Cohen B, Hull K. *Memmler's The Human Body in Health and Disease*. 14th ed. Baltimore, MD: Lippincott Williams & Wilkins; 2019.

Figure 5-2. Cohen B, Hull K. *Memmler's The Human Body in Health and Disease*. 14th ed. Baltimore, MD: Lippincott Williams & Wilkins; 2019.

Figure 5-3. Cohen B, Hull K. *Memmler's The Human Body in Health and Disease*. 14th ed. Baltimore, MD: Lippincott Williams & Wilkins; 2019.

Figure 5-4. Cohen B, Hull K. *Memmler's The Human Body in Health and Disease*. 14th ed. Baltimore, MD: Lippincott Williams & Wilkins; 2019.

Figure 5-5. Cohen B, Hull K. *Memmler's The Human Body in Health and Disease*. 14th ed. Baltimore, MD: Lippincott Williams & Wilkins; 2019.

Figure 5-6. Rubin R, Strayer DS. *Rubin's Pathology*. 6th ed. Baltimore, MD: Lippincott Williams & Wilkins; 2012.

Figure 5-7. Cohen B, Hull K. *Memmler's The Human Body in Health and Disease*. 14th ed. Baltimore, MD: Lippincott Williams & Wilkins; 2019.

Figure 5-8. Erkonen WE, Smith WL. *Radiology 101*. 3rd ed. Philadelphia, PA: Wolters Kluwer Health; 2010.

Figure 5-10. Rubin R, Strayer DS. *Rubin's Pathology*. 6th ed. Baltimore, MD: Lippincott Williams & Wilkins; 2012.

Figure 5-11. A: Erkonen WE, Smith WL. *Radiology 101*. 3rd ed. Philadelphia, PA: Lippincott Williams & Wilkins; 2010. **B:** Becker KL, et al. *Principles and Practice of Endocrinology and Metabolism*. 3rd ed. Philadelphia, PA: Wolters Kluwer Health; 2001.

Figure 5-12. Rubin R, Strayer DS. *Rubin's Pathology*. 6th ed. Baltimore, MD: Lippincott Williams & Wilkins; 2012.

Figure 5-13. Cohen B, Hull K. *Memmler's The Human Body in Health and Disease*. 14th ed. Baltimore, MD: Lippincott Williams & Wilkins; 2019.

Figure 5-14. Rubin R, Strayer DS. *Rubin's Pathology*. 6th ed. Baltimore, MD: Lippincott Williams & Wilkins; 2012.

Figure 5-16. Daffner RH. *Clinical Radiology the Essentials*. 3rd ed. Philadelphia, PA: Lippincott Williams & Wilkins; 2007.

Figure 5-17. Erkonen WE, Smith WL. *Radiology 101*. 3rd ed. Philadelphia, PA: Lippincott Williams & Wilkins; 2010.

Figure 5-18. B: Erkonen WE. *Radiology 101*. 2nd ed. Philadelphia, PA: Lippincott Williams & Wilkins; 2004.

Figure 5-20. McConnell T, Hull K. *Human Form, Human Function*. Philadelphia, PA: Lippincott Williams & Wilkins; 2011.

Case Study 5-2. Rubin R, Strayer DS. *Rubin's Pathology*. 6th ed. Philadelphia, PA: Wolters Kluwer Health; 2012.

Chapter 6

Figure 6-1. McConnell T, Hull K. *Human Form, Human Function*. Philadelphia, PA: Wolters Kluwer Health; 2011.

Figure 6-2. Cohen B, Hull K. *Memmler's The Human Body in Health and Disease*. 14th ed. Baltimore, MD: Lippincott Williams & Wilkins; 2019.

Figure 6-3. Cohen B, Hull K. *Memmler's The Human Body in Health and Disease*. 14th ed. Baltimore, MD: Lippincott Williams & Wilkins; 2019.

Figure 6-4. Bucci C. *Condition-Specific Massage Therapy*. Baltimore, MD: Wolters Kluwer Health; 2012.

Figure 6-5. Cohen B, Hull K. *Memmler's The Human Body in Health and Disease*. 14th ed. Baltimore, MD: Lippincott Williams & Wilkins; 2019.

Figure 6-6. Cohen B, Hull K. *Memmler's The Human Body in Health and Disease*. 14th ed. Baltimore, MD: Lippincott Williams & Wilkins; 2019.

Figure 6-7. Cohen B, Hull K. *Memmler's The Human Body in Health and Disease*. 14th ed. Baltimore, MD: Lippincott Williams & Wilkins; 2019.

Figure 6-8. Adapted from Frontera WR, Silver JS. *Essentials of Physical Medicine and Rehabilitation*. 2nd ed. Philadelphia, PA: Hanley and Belfus; 2008.

Figure 6-9. *Stedman's Medical Dictionary*. 28th ed. Baltimore, MD: Lippincott Williams & Wilkins; 2006.

Chapter 7

Figure 7-1. Cohen B, Hull K. *Memmler's The Human Body in Health and Disease*. 14th ed. Baltimore, MD: Lippincott Williams & Wilkins; 2019.

Figure 7-2. Cohen B, Hull K. *Memmler's The Human Body in Health and Disease*. 14th ed. Baltimore, MD: Lippincott Williams & Wilkins; 2019.

Figure 7-3. Cohen B, Hull K. *Memmler's The Human Body in Health and Disease*. 14th ed. Baltimore, MD: Lippincott Williams & Wilkins; 2019.

Figure 7-4. Cohen B, Hull K. *Memmler's The Human Body in Health and Disease*. 14th ed. Baltimore, MD: Lippincott Williams & Wilkins; 2019.

Figure 7-5. McConnell T, Hull K. *Human Form, Human Function*. Philadelphia, PA: Wolters Kluwer Health; 2011.

Figure 7-6. McConnell T, Hull K. *Human Form, Human Function*. Philadelphia, PA: Wolters Kluwer Health; 2011.

Figure 7-7. Cohen B. *Memmler's The Human Body in Health and Disease*. 12th ed. Baltimore, MD: Wolters Kluwer Health; 2013.

Figure 7-8. A: McConnell T, Hull K. *Human Form, Human Function*. Philadelphia, PA: Wolters Kluwer Health, 2011. **B:** Mills SE. *Histology for Pathologists*. 3rd ed. Philadelphia, PA: Lippincott Williams & Wilkins; 2006.

Figure 7-9. Cohen B. *Memmler's The Human Body in Health and Disease*. 12th ed. Baltimore, MD: Wolters Kluwer Health; 2013.

Figure 7-10. Cohen B, Hull K. *Memmler's The Human Body in Health and Disease*. 14th ed. Baltimore, MD: Lippincott Williams & Wilkins; 2019.

Figure 7-11. Rubin E, Farber JL. *Pathology*. 4th ed. Philadelphia, PA: Lippincott Williams & Wilkins; 2005.

Figure 7-13. A: Wallover J. *Lippincott Procedures*. Baltimore, MD: Wolters Kluwer Health; 2014. **B:** Smeltzer SC, et al. *Medical-Surgical Nursing*. 12th ed. Philadelphia, PA: Lippincott Williams & Wilkins; 2010.

Figure 7-14. Erkonen WE, Smith WL. *Radiology 101*. 3rd ed. Philadelphia, PA: Lippincott Williams & Wilkins; 2010.

Figure 7-15. Rubin E, Farber JL. *Pathology*. 5th ed. Philadelphia, PA: Lippincott Williams & Wilkins; 2007.

Figure 7-16. Rubin R, Strayer DS. *Rubin's Pathology*. 6th ed. Baltimore, MD: Wolters Kluwer Health; 2012.

extern.ir

Figure 7-17. Bickley LS. *Bates' Guide to Physical Examination and History Taking*. 10th ed. Philadelphia, PA: Lippincott Williams & Wilkins; 2009.

Figure 7-18. Erkonen WE, Smith WL. *Radiology 101*. 3rd ed. Philadelphia, PA: *Rubin's* Pathology; 2010.

Chapter 8

Figure 8-1. Cohen B, Hull K. *Memmler's The Human Body in Health and Disease*. 13th ed. Baltimore, MD: Lippincott Williams & Wilkins; 2015.

Figure 8-2. Cohen B, Hull K. *Memmler's The Human Body in Health and Disease*. 14th ed. Baltimore, MD: Lippincott Williams & Wilkins; 2019.

Figure 8-3. Cohen B. *Memmler's The Human Body in Health and Disease*. 12th ed. Baltimore, MD: Lippincott Williams & Wilkins; 2013.

Figure 8-4. Smeltzer SC, Bare B. *Medical-Surgical Nursing*. 11th ed. Philadelphia, PA: Lippincott Williams & Wilkins; 2009.

Figure 8-5. Smeltzer SC, Bare B. *Medical-Surgical Nursing*. 11th ed. Philadelphia, PA: Lippincott Williams & Wilkins; 2009.

Figure 8-6. McConnell T, Hull K. *Human Form, Human Function*. Philadelphia, PA: Lippincott Williams & Wilkins; 2011.

Figure 8-7. Cohen B, Hull K. *Memmler's The Human Body in Health and Disease*. 13th ed. Baltimore, MD: Lippincott Williams & Wilkins; 2015.

Figure 8-8. Cohen B. *Memmler's The Human Body in Health and Disease*. 14th ed. Baltimore, MD: Lippincott Williams & Wilkins; 2019.

Figure 8-9. Cohen B. *Memmler's The Human Body in Health and Disease*. 12th ed. Baltimore, MD: Lippincott Williams & Wilkins; 2013.

Figure 8-10. Moore KL, Dalley AF. *Clinically Oriented Anatomy*. 6th ed. Philadelphia, PA: Lippincott Williams & Wilkins; 2009.

Figure 8-11. Cohen B, Hull K. *Memmler's The Human Body in Health and Disease*. 13th ed. Baltimore, MD: Lippincott Williams & Wilkins; 2015.

Figure 8-12. Smeltzer SC, Bare B. *Medical-Surgical Nursing*. 11th ed. Philadelphia, PA: Lippincott Williams & Wilkins; 2009.

Figure 8-13. National Eye Institute, Bethesda, MD.

Chapter 9

Figure 9-1. Cohen B, Hull K. *Memmler's The Human Body in Health and Disease*. 14th ed. Baltimore, MD: Lippincott Williams & Wilkins; 2019.

Figure 9-2. McConnell T, Hull K. *Human Form, Human Function*, Philadelphia, PA: Lippincott Williams & Wilkins; 2010.

Figure 9-3. Cohen B, Hull K. *Memmler's The Human Body in Health and Disease*. 14th ed. Baltimore, MD: Lippincott Williams & Wilkins; 2019.

Figure 9-4. Courtesy of Dana Morse Bittus and B. J. Cohen.

Figure 9-5. Courtesy of Sandoz Pharmaceutical Corporation, Princeton.

Figure 9-6. Rubin R, Strayer DS. *Rubin's Pathology*. 6th ed. Baltimore, MD: Lippincott Williams & Wilkins; 2012.

Chapter 10

Figure 10-2. McConnell T, Hull K. *Human Form, Human Function*. Philadelphia, PA: Lippincott Williams & Wilkins; 2011.

Figure 10-3. Cohen B, Hull K. *Memmler's The Human Body in Health and Disease*. 14th ed. Baltimore, MD: Lippincott Williams & Wilkins; 2019.

Figure 10-5. Smeltzer SC, et al. *Medical-Surgical Nursing*. 12th ed. Philadelphia, PA: Lippincott Williams & Wilkins; 2010.

Figure 10-6. McConnell T, Hull K. *Human Form, Human Function*. Philadelphia, PA: Lippincott Williams & Wilkins; 2011.

Figure 10-7. McConnell T, Hull K. *Human Form, Human Function*. Philadelphia, PA: Lippincott Williams & Wilkins; 2011.

Figure 10-8. McConnell T, Hull K. *Human Foundations*. Philadelphia, PA: Lippincott Williams & Wilkins; 2011.

Figure 10-9. Wingerd B. *Human Body*. 3rd ed. Philadelphia, PA: Wolters Kluwer Health; 2013.

Figure 10-11. Baim DS. *Grossman's Cardiac Catheterization, Angiography and Intervention*. 7th ed. Philadelphia, PA: Lippincott Williams & Wilkins; 2006.

Figure 10-12. McArdle WD, et al. *Exercise Physiology*. 8th ed. Philadelphia, PA: Wolters Kluwer Health; 2013.

Figure 10-14. Smeltzer SC, et al. *Brunner and Suddarth's Textbook of Medical Surgical Nursing*. 12th ed. Philadelphia, PA: Lippincott Williams & Wilkins; 2009.

Figure 10-17. Porth CM, Matfin G. *Pathophysiology*. 8th ed. Philadelphia, PA: Lippincott Williams & Wilkins; 2009.

Figure 10-18. Bickley LS. *Bates' Guide to Physical Examination and History Taking*. 10th ed. Philadelphia, PA: Lippincott Williams & Wilkins; 2009.

Figure 10-19. McConnell T, Hull K. *Human Form, Human Function*. Philadelphia, PA: Lippincott Williams & Wilkins; 2011.

Figure 10-21. McConnell T, Hull K. *Human Form, Human Function*. Philadelphia, PA: Lippincott Williams & Wilkins; 2011.

Figure 10-22. A: Matz Paul S. In: Chung EK, et al. *Visual Diagnosis and Treatment in Pediatrics*. 2nd ed. Philadelphia, PA: Lippincott Williams & Wilkins; 2010. **B:** Rajagopalan S, et al. *Manual of Vascular Diseases*. Philadelphia, PA: Wolters Kluwer Health; 2012.

Figure 10-23. Bickley LS. *Bates' Guide to Physical Examination and History Taking*. 10th ed. Philadelphia, PA: Lippincott Williams & Wilkins; 2009.

Chapter 11

Figure 11-1. Cohen B. *Memmler's The Human Body in Health and Disease*. 114th ed. Baltimore, MD: Lippincott Williams & Wilkins; 2019.

Figure 11-2. Cohen B. *Memmler's The Human Body in Health and Disease*. 14th ed. Baltimore, MD: Lippincott Williams & Wilkins; 2019.

Figure 11-3. Cohen B. *Memmler's The Human Body in Health and Disease*. 14th ed. Baltimore, MD: Lippincott Williams & Wilkins; 2019.

Figure 11-4. Gartner LP, Hiatt JL. *Color Atlas of Histology*. 5th ed. Philadelphia, PA: Lippincott Williams & Wilkins; 2009.

Figure 11-5. Gartner LP, Hiatt JL. *Color Atlas of Histology*. 5th ed. Philadelphia, PA: Lippincott Williams & Wilkins; 2009.

extern.ir

Figure 11-6. A and **C:** McConnell TH, Hull KH. *Human Form, Human Function*. Philadelphia, PA: Lippincott Williams & Wilkins; 2011.

Figure 11-7. Cohen B. *Memmler's The Human Body in Health and Disease*. 14th ed. Baltimore, MD: Lippincott Williams & Wilkins; 2019.

Figure 11-10. McConnell T, Hull K. *Human Form, Human Function*. Philadelphia, PA: Lippincott Williams & Wilkins; 2011.

Figure 11-11. Rubin R, Strayer DS. *Rubin's Pathology*. 6th ed. Philadelphia, PA: Lippincott Williams & Wilkins; 2012.

Figure 11-12. Rubin R, Strayer DS. *Rubin's Pathology: Clinicopathologic Foundations of Medicine*. 5th ed. Baltimore, MD: Lippincott Williams & Wilkins; 2007.

Figure 11-13. A: McClatchey KD. *Clinical Laboratory Medicine*. 2nd ed. Philadelphia, PA: Lippincott Williams & Wilkins; 2002. **B:** Rubin R, Strayer DS. *Rubin's Pathology*. 5th ed. Philadelphia, PA: Lippincott Williams & Wilkins; 2008.

Figure 11-14. Rubin E, Farber JL. *Pathology*. 5th ed. Philadelphia, PA: Lippincott Williams & Wilkins; 2007.

Figure 11-15. Rubin R, Strayer DS. *Rubin's Pathology*. 6th ed. Philadelphia, PA: Lippincott Williams & Wilkins; 2012.

Chapter 12

Figure 12-1. Cohen B, Hull K. *Memmler's The Human Body in Health and Disease*. 14th ed. Baltimore, MD: Lippincott Williams & Wilkins; 2019.

Figure 12-2. A, B: McConnell T, Hull K. *Human Form, Human Function*. Philadelphia, PA: Lippincott Williams & Wilkins; 2011.

Figure 12-3. Archer P, Nelson LA. *Applied Anatomy and Physiology for Manual Therapists*. Philadelphia, PA: Lippincott Williams & Wilkins; 2012.

Figure 12-4. Cohen B, Hull K. *Memmler's The Human Body in Health and Disease*. 14th ed. Baltimore, MD: Lippincott Williams & Wilkins; 2019.

Figure 12-5. Cohen B, Hull K. *Memmler's The Human Body in Health and Disease*. 14th ed. Baltimore, MD: Lippincott Williams & Wilkins; 2019.

Figure 12-6. Cohen B, Hull K. *Memmler's The Human Body in Health and Disease*. 14th ed. Baltimore, MD: Lippincott Williams & Wilkins; 2019.

Figure 12-7. Cohen B, Hull K. *Memmler's The Human Body in Health and Disease*. 14th ed. Baltimore, MD: Lippincott Williams & Wilkins; 2019.

Figure 12-8. *Lippincott's Visual Nursing*. 2nd ed. Philadelphia, PA: Lippincott Williams & Wilkins; 2011.

Figure 12-9. Rubin R, Strayer DS. *Rubin's Pathology*. 6th ed. Philadelphia, PA: Lippincott Williams & Wilkins; 2012.

Figure 12-10. Anatomical Chart Company. *Diseases and Disorders*. Philadelphia, PA: Lippincott Williams & Wilkins; 2008.

Figure 12-11. Paul P, et al. *Brunner and Suddarth's Canadian Textbook of Medical Surgical Nursing*. 3rd ed. Philadelphia, PA: Wolters Kluwer Health; 2015.

Figure 12-12. Labus D, Cohen A, Lippincott Advisor, Lippincott Williams & Wilkins; 2016.

Figure 12-13. Moore KL, et al. *Clinically Oriented Anatomy*. 7th ed. Philadelphia, PA: Wolters Kluwer Health; 2014.

Figure 12-14. Taylor C, et al. *Fundamentals of Nursing*. 5th ed. Philadelphia, PA: Lippincott Williams & Wilkins; 2005.

Figure 12-15. Cohen B, Hull K. *Memmler's The Human Body in Health and Disease*. 14th ed. Baltimore, MD: Lippincott Williams & Wilkins; 2019.

Figure 12-16. B: Reprinted courtesy of E.D. Andersen.

Figure 12-17. Carter PJ. *Lippincott Textbook for Nursing Assistants*. 3rd ed. Baltimore, MD: Lippincott Williams & Wilkins; 2011.

Figure 12-19. Rosdahl CB, Kowalski MT. *Textbook of Basic Nursing*. 11th ed. Philadelphia, PA: Wolters Kluwer Health; 2016.

Chapter 13

Figure 13-1. McConnell T, Hull K. *Human Form, Human Function*. Philadelphia, PA: Lippincott Williams & Wilkins; 2011.

Figure 13-2. McConnell T, Hull K. *Human Form, Human Function*. Philadelphia, PA: Lippincott Williams & Wilkins; 2011.

Figure 13-3. McConnell T, Hull K. *Human Form, Human Function*. Philadelphia, PA: Lippincott Williams & Wilkins; 2011.

Figure 13-4. Cohen B, Hull K. *Memmler's The Human Body in Health and Disease*. 14th ed. Baltimore, MD: Lippincott Williams & Wilkins; 2019.

Figure 13-5. McConnell T, Hull K. *Human Form, Human Function*. Philadelphia, PA: Lippincott Williams & Wilkins; 2011.

Figure 13-6. *Memmler's The Human Body in Health and Disease*. 13th ed. Baltimore, MD: Lippincott Williams & Wilkins; 2015.

Figure 13-8. C: Mulholland MW, et al. *Greenfields Surgery Scientific Principles and Practice*. 4th ed. Philadelphia, PA: Lippincott Williams & Wilkins; 2006.

Figure 13-11. Anatomical Chart Company. *Atlas of Pathophysiology*. 3rd ed. Baltimore, MD: *Rubin's Pathology*; 2010.

Figure 13-12. Rubin R, Strayer DS. *Rubin's Pathology*. 6th ed. Philadelphia, PA: Wolters Kluwer Health; 2012.

Figure 13-13. Erkonen WE. *Radiology 101*. 2nd ed. Philadelphia, PA: Lippincott Williams & Wilkins; 2004.

Figure 13-14. Bickley LS. *Bates' Guide to Physical Examination and History Taking*. 10th ed. Philadelphia, PA: Lippincott Williams & Wilkins; 2009.

Figure 13-15. A: McConnell TH. *The Nature of Disease*. 2nd ed. Baltimore, MD: Lippincott Williams & Wilkins; 2013. **B:** Erkonen WE, Smith WS. *Radiology 101*. 3rd ed. Philadelphia, PA: Lippincott Williams & Wilkins; 2010.

Figure 13-18. *Stedman's Medical Dictionary for the Health Professions and Nursing*. 6th ed. Baltimore, MD: Lippincott Williams & Wilkins; 2008.

Figure 13-19. B: Erkonen WE. *Radiology 101*. 2nd ed. Philadelphia, PA: Lippincott Williams & Wilkins; 2004.

Chapter 14

Figure 14-1. McConnell T, Hull K. *Human Form, Human Function*. Philadelphia, PA: Lippincott Williams & Wilkins; 2010.

Figure 14-2. Cohen B, Hull K. *Memmler's The Human Body in Health and Disease*. 14th ed. Baltimore, MD: Lippincott Williams & Wilkins; 2019.

Figure 14-3. Cohen B, Hull K. *Memmler's The Human Body in Health and Disease*. 14th ed. Baltimore, MD: Lippincott Williams & Wilkins; 2019.

extern.ir

Figure 14-4. McConnell T, Hull K. *Human Form, Human Function*. Philadelphia, PA: Lippincott Williams & Wilkins; 2010.

Figure 14-6. A and B: Premkumar K. *The Massage Connection*. 2nd ed. Baltimore, MD: Lippincott Williams & Wilkins; 2004. **C:** Porth C. *Essentials of Pathophysiology*. 2nd ed. Philadelphia, PA: Lippincott Williams & Wilkins; 2006.

Figure 14-7. Nath JL. *Using Medical Terminology*. Philadelphia, PA: Lippincott Williams & Wilkins; 2006.

Figure 14-8. B: Dunnick R, et al. *Textbook of Uroradiology*. 5th ed. Philadelphia, PA: Wolters Kluwer Health; 2012.

Figure 14-10. Erkonen WE. *Radiology 101*. 2nd ed. Philadelphia, PA: Lippincott Williams & Wilkins; 2004.

Figure 14-11. Rubin R, Strayer DS. *Rubin's Pathology*. 6th ed. Baltimore, MD: Lippincott Williams & Wilkins; 2012.

Figure 14-12. B: Schaaf CP, et al. *Human Genetics*. Philadelphia, PA: Lippincott Williams & Wilkins; 2011.

Figure 14-13. Rubin R, Strayer DS. *Rubin's Pathology*. 6th ed. Baltimore, MD: Lippincott Williams & Wilkins; 2012.

Figure 14-14. Rubin R, Strayer DS. *Rubin's Pathology*. 6th ed. Baltimore, MD: Lippincott Williams & Wilkins; 2012.

Chapter 15

Figure 15-1. McConnell T, Hull K. *Human Form, Human Function*. Philadelphia, PA: Lippincott Williams & Wilkins; 2011.

Figure 15-3. A: McConnell T, Hull K. *Human Form, Human Function*. Philadelphia, PA: Lippincott Williams & Wilkins; 2010.

Figure 15-4. Cohen B, Hull K. *Memmler's The Human Body in Health and Disease*. 14th ed. Baltimore, MD: Lippincott Williams & Wilkins; 2019.

Figure 15-6. Rubin R, Strayer DS. *Rubin's Pathology*. 6th ed. Baltimore, MD: Lippincott Williams & Wilkins; 2012.

Figure 15-7. C: Kyle T, Carman S. *Essentials of Pediatric Nursing*. 2nd ed. Philadelphia, PA: Lippincott Williams & Wilkins; 2012.

Chapter 16

Un-Figure 16-1. Taylor C, et al. *Fundamentals of Nursing*. 7th ed. Philadelphia, PA: Lippincott Williams & Wilkins; 2006.

Figure 16-1. McConnell T, Hull K. *Human Form, Human Function*. Philadelphia, PA: Lippincott Williams & Wilkins; 2011.

Figure 16-2. McConnell T, Hull K. *Human Form, Human Function*. Philadelphia, PA: Lippincott Williams & Wilkins; 2011.

Figure 16-3. McConnell TH. *The Nature of Disease*. Philadelphia, PA: Lippincott Williams & Wilkins; 2011.

Figure 16-4. McConnell T, Hull K. *Human Form, Human Function*. Philadelphia, PA: Lippincott Williams & Wilkins; 2011.

Figure 16-7. Rubin R, Strayer DS. *Rubin's Pathology*. 6th ed. Baltimore, MD: Lippincott Williams & Wilkins; 2012.

Figure 16-8. Anatomical Chart Company. *Infertility Anatomical Chart*. Baltimore, MD: Lippincott Williams & Wilkins; 2008.

Figure 16-9. Erkonen WE, Smith WL. *Radiology 101*. 3rd ed. Philadelphia, PA: Lippincott Williams & Wilkins; 2010.

Figure 16-11. Cohen B. *Memmler's The Human Body in Health and Disease*. 14th ed. Baltimore, MD: Lippincott Williams & Wilkins; 2019.

Figure 16-12. Pilletteri A. *Maternal and Child Health Nursing*. 6th ed. Philadelphia, PA: Lippincott Williams & Wilkins; 2009.

Figure 16-13. Cohen B. *Memmler's The Human Body in Health and Disease*. 14th ed. Baltimore, MD: Lippincott Williams & Wilkins; 2019.

Figure 16-14. McConnell TH. *The Nature of Disease*. Philadelphia, PA: Wolters Kluwer Health; 2011.

Figure 16-15. Anatomical Chart Company. *OB/GYN Disorders*. Philadelphia, PA: Lippincott Williams & Wilkins; 2008.

Figure 16-17. Anatomical Chart Company. *OB/GYN Disorders*. Philadelphia, PA: Lippincott Williams & Wilkins; 2008.

Figure 16-18. Pilletteri A. *Maternal and Child Health Nursing*. 6th ed. Philadelphia, PA: Lippincott Williams & Wilkins; 2009.

Figure 16-19. Pilletteri A. *Maternal and Child Health Nursing*. 6th ed. Philadelphia, PA: Lippincott Williams & Wilkins; 2009.

Figure 16-20. Pilletteri A. *Maternal and Child Health Nursing*. 6th ed. Philadelphia, PA: Lippincott Williams & Wilkins; 2009.

Figure 16-21. Erkonen WE, Smith WL. *Radiology 101*. 3rd ed. Philadelphia, PA: Lippincott Williams & Wilkins; 2010.

Figure 16-22. McConnell TH. *The Nature of Disease*. 2nd ed. Philadelphia, PA: Lippincott Williams & Wilkins; 2013.

extern.ir

Index of Boxes

Clinical Perspectives

Laboratory Study of Tissues 45
Medical Imaging 91
Medication Patches: No Bitter Pill to Swallow 126
Arthroplasty: Bionic Parts for a Better Life 166
Anabolic Steroids: Winning at All Costs? 191
Psychoactive Drugs: Adjusting Neurotransmitters to Alter Mood 236
Eye Surgery: A Glimpse of the Cutting Edge 277
Growth Hormone: Its Clinical Use Is Growing 296
Seasonal Affective Disorder: Some Light on the Subject 306
Hemodynamic Monitoring: Measuring Blood Pressure from Within 323
Lymphedema: When Lymph Stops Flowing 341
Use of Reticulocytes in Diagnosis 372
Tonsillectomy: A Procedure Reconsidered 394
Endoscopy 437
Sodium and Potassium: Causes and Consequences of Imbalance 470
Treating Erectile Dysfunction 498
Assisted Reproductive Technology: The "Art" of Conception 535

For Your Reference

Silent Letters and Unusual Pronunciations 7
Cell Structures 41
Anatomic Directions 53
Body Positions 55
Common Infectious Organisms 77
Imaging Techniques 92
Surgical Instruments 94
Routes of Drug Administration 108
Drug Preparations 110
Terms Pertaining to Injectable Drugs 111
Types of Skin Lesions 130
Bones of the Skeleton 154
Types of Fractures 162
Bone Markings 173
Types of Movement 192
The Cranial Nerves 222
Endocrine Glands and Their Hormones 295
Disorders Associated with Endocrine Dysfunction 300
Blood Cells 359
Leukocytes (White Blood Cells) 360
Common Blood Tests 370
Coagulation Tests 373
Organisms That Infect the Respiratory System 401
Volumes and Capacities (Sums of Volumes) Used in Pulmonary Function Tests 407
Organs of the Digestive Tract 427
The Accessory Organs 430
Sexually Transmitted Infections 496
Main Methods of Birth Control Currently in Use 516
Genetic Disorders 537

Focus on Words

Meaningful Suffixes 9
Name That Disease 77
The French Connection 132
Names That Are Like Pictures 161
Some Colorful Musculoskeletal Terms 199
Phobias and Manias 235
The Greek Influence 271
Are You in a Good Humor? 294
Name That Structure 320
Acronyms 359
Don't Breathe a Word 404
Homonyms 428
Words That Serve Double Duty 463
Which Is It? 492
Crazy Ideas 518

Health Professions

Health Information Technicians 4
Radiologic Technologist 51
Emergency Medical Technicians 77
Nurse Practitioners 131
Careers in Physical Therapy 161
Careers in Exercise and Fitness 193
Careers in Occupational Therapy 235
Audiologists 266
Dietitians and Nutritionists 303
Vascular Technologists 334
Careers in Hematology 371
Careers in Respiratory Therapy 407
Dental Hygienist 428
Hemodialysis Technician 472
Physician Assistant 499
Nurse-Midwives and Doulas 532

extern.ir

Index

Note: Page numbers followed by f indicate figures, t indicate tables, and b indicate boxes, respectively.

A

Abbreviations
  blood, 380–381
  cardiovascular system, 346–347
  digestive system, 449
  for drugs, 113–114
  ear, 269
  eye and vision, 282
  for immunity, 380–381
  integumentary system, 141
  male reproductive system, 502
  nervous system, 245
  phrase abbreviations, 8
  skeleton system, 174
  symbols, 8
  urinary system, 479
ABCDE factors, 135
Abdomen
  nine regions, 54f
  quadrants of, 56f
Abdominal cavity, 54, 56
Abdominal regions, 54–55
Abdominopelvic cavity, 56
ABGs. *See* arterial blood gases
Ablation, 332, 336
Abortifacient, 542
Abortion, 540
Abscess, 88
Accessory organs, 429–430, 429f, 430b, 430f, 435t, 440–442
Accommodation, 270, 270f, 272
ACE inhibitors (angiotensin-converting enzyme inhibitors), 462
Acetabulum, 153, 156
Acetylcholine (ACh), 190, 196, 240
ACh. *See* acetylcholine
Achalasia, 445
Achilles tendinitis, 201
Achlorhydria, 445
Achondroplasia, 171
Acid-fast stain, 87
Acidosis, 401, 408, 470, 474
Acne, 137
Acoustic neuroma, 233, 238, 266, 267
Acquired immunodeficiency syndrome (AIDS), 374–375
Acromegaly, 300, 303
Acronym, 8
Acronyms, 359
Acrophobia, 235b
ACTH. *See* adrenocorticotropic hormone
Actin, 190, 196
Actinic, 137
Acupuncture, 95, 97
Acute disease, 76, 80
Acute lymphoblastic leukemia (ALL), 373
Acute myeloblastic leukemia (AML), 373
Acute renal failure (ARF), 470
Acute respiratory distress syndrome (ARDS), 405, 408
Acute rhinitis, 404, 408
Acute tubular necrosis (ATN), 470
AD. *See* Alzheimer disease
Adaptive immunity, 80, 364–365, 364f, 368
  artificial, 365
  natural, 365
Addison disease, 301, 303
Adenocarcinoma, 80
Adenoidectomy, 413
Adenoids, 393, 393f, 397
Adenoma, 300, 303
Adenosine triphosphate (ATP), 46
ADH. *See* antidiuretic hormone
ADHD. *See* attention deficit hyperactivity disorder
Adhesion, 88
Adjective suffixes, 12, 13t
Adnexa, 526
Adrenal cortex, 295b
Adrenal glands, 294, 295b, 297, 297f, 298, 301–302
Adrenaline, 377
Adrenal medulla, 295b
Adrenocorticotropic hormone (ACTH), 295b
Adrenogenital syndrome, 305
Adult hypothyroidism, 301, 304
Advil, 106
AEDs. *See* automated external defibrillators
Aerosol therapy, 412
Afferent neuron. *See* sensory neuron
AFP. *See* alpha-fetoprotein
Afterbirth, 541
Age-related macular degeneration (AMD), 277–278, 278f, 279
Agglutination, 377
Agonist, 196
Agoraphobia, 235b
Agranulocytes, 360b, 361, 365
Agranulocytosis, 378
AI. *See* aromatase inhibitor; artificial insemination
AIDS. *See* acquired immunodeficiency syndrome
Albinism, 137
Albumin, 358, 365
Aldosterone, 295b, 297, 300b, 476
Alkaline phosphatase, 160, 169
Alkalosis, 401, 408
ALL. *See* acute lymphoblastic leukemia
Allergens, 374, 375
Allergy, 373, 374, 375
Allograft, 172
Aloe, 141
Alopecia, 137
Alpha-fetoprotein (AFP), 102, 542
ALS. *See* amyotrophic lateral sclerosis
Alternative medicine, 95, 97–98
Alveoli, 395, 397
Alzheimer disease (AD), 233–234, 234f, 237
Amblyopia, 259, 280, 282
AMD. *See* age-related macular degeneration
American Society of Health System Pharmacists (ASHP), 106
Amino acids, 51
AML. *See* acute myeloblastic leukemia
Amnesia, 241
Amniocentesis, 541
Amyloid, 234, 237
Amyotrophic lateral sclerosis (ALS), 199, 201, 241
Anabolic steroids, 191b
Anabolism, 51t
Anaphylactic reaction, 374, 375
Anaphylactic shock, 332
Anaphylaxis, 106, 107
Anaplasia, 88
Anastomosis, 438–439, 444
Anatomic directions, 53b
Anatomic position, 56
Androgens, 490, 493
Anemia, 370–372, 375, 470
  aplastic, 371
  Cooley anemia, 372
  hemorrhagic, 372
  to loss/destruction of red cells, 372, 372f
  nutritional, 371–372, 372f
  pernicious, 372
  and red cells, 371–372, 371f
  sickle cell anemia, 372, 372f
  sideroblastic, 372
Anencephaly, 540
Anesthesia, 95, 96
Aneurysm, 231, 231f, 237, 329, 329f, 334
Angina pectoris, 330, 334
Angioedema, 374, 375
Angioplasty, 330, 330f, 336
Angiotensin, 462, 465
Angiotensin-converting, 345
Angiotensin receptor blocker (ARB), 345
Anion gap, 477
Anisocoria, 280
Ankylosing spondylitis, 166, 166f, 168
Ankylosis, 165, 166f, 168
Annulus fibrosus, 170
Anorexia, 445
Anoxia, 411

extern.ir

ANS. *See* autonomic nervous system
Antacid, 447
Antagonists, 106, 107, 191, 196
Antepartum, 541
Anterior pituitary, 295b
Antianxiety agent, 244
Antiarrhythmic agent, 345
Antibodies, 364, 365
Anticoagulants, 380
Antidepressants, 244
Antidiarrheal, 447
Antidiuretic hormone (ADH), 295b, 296, 300b, 464, 465
Antiemetic, 447
Antiflatulent, 447
Antigen, 364, 365
Antigen presenting cells (APCs), 364, 365
Antihistamine, 380, 414
Anti-inflammatory agents, 165, 170, 204
Antipruritic, 141
Antispasmodic, 447
Antitussive, 414
Anuresis, 476
Anuria, 476
Anus, 426, 426f, 430
Anxiety disorders, 235–236, 235b, 239
Aorta, 317, 318f, 324
Aortic valve, 318, 324
APCs. *See* antigen presenting cells
Apex, 324
Aphagia, 445
Aphasia, 231, 237
Apheresis, 380
Aphthous ulcer, 445
Apical pulse, 342
Aplastic anemia, 371, 375
Appendectomy, 446
Appendicitis, 436, 442
Appendix, 339, 429, 430
Apraxia, 241
Aqueous humor, 271, 272
Arachnoid mater, 220, 221f, 225
ARB. *See* angiotensin receptor blocker
ARDS. *See* acute respiratory distress syndrome
Areola, 526
ARF. *See* acute renal failure
Aromatase inhibitor (AI), 527
Arrhythmia, 315, 331–332, 332f, 334, 347
Arterial blood gases (ABGs), 406, 409
Arteries, 321, 321f, 324
Arterioles, 321, 321f, 324
Arteriosclerosis, 328, 334
Arthritis, 164–165, 165f, 168
Arthrocentesis, 165, 169
Arthroclasia, 172
Arthrodesis, 166, 169
Arthroplasty, 166b, 169
Arthroscopy, 165–166, 166f, 169
Articulation, 156
Artificial insemination (AI), 542
Artificial pacemaker, 332, 332f
Ascites, 88, 440, 442
ASD. *See* autism spectrum disorder
Aseptic meningitis, 233
ASHP. *See* American Society of Health System Pharmacists
Asphyxia, 271b, 411
Aspiration, 172, 401, 408
Asterixis, 202
Asthenia, 202
Asthenia, 271b
Asthma, 405, 408
  case study, 121
  maintenance drug, 414
Astigmatism, 276, 277f, 279
Astrocytoma, 233, 237
Ataxia, 202, 241
Atelectasis, 405, 408
Atherectomy, 345
Atherosclerosis, 328, 329f, 334
Athetosis, 202, 241
Athletic trainers, 193b
Atlas, 153f, 156
ATN. *See* acute tubular necrosis
ATP. *See* adenosine triphosphate
Atopic dermatitis, 133, 133f, 135
Atresia, 540
Atria, 317, 324
Atrioventricular (AV) bundle, 319, 319f, 324
Atrioventricular (AV) node, 319, 319f, 324
Atrioventricular (AV) valves, 317, 318f, 324
Atrophy, 203
Attention deficit hyperactivity disorder (ADHD), 236–237, 239
Audiologists, 266b
Audiometry, 268
Auditory tube, 263
Aural, 267
Auscultation, 89, 89f, 96
Autism spectrum disorder (ASD), 237, 239
Autograft, 172
Autoimmune diseases, 134, 375
Autologous blood, 380
Automated external defibrillators (AEDs), 332
Autonomic nervous system (ANS), 218, 224, 224f, 225
AV bundle. *See* atrioventricular bundle
AV node. *See* atrioventricular node
Avulsion, 203
AV valves. *See* atrioventricular valves
Axial skeleton, 153, 154b
Axis, 153f
Axons, 218, 225
Azotemia, 476
Azoturia, 476

B

Babinski reflex, 243, 244f
Bacilli, 77b
Bacillus Calmette–Guérin vaccine, 403
Bacteria, 77b, 78, 78f
Bacteriuria, 469, 474
Baker cyst, 171
Balanitis, 500
Band cell, 361, 361f, 365
Bariatrics, 447
Bariatric surgery, 447
Barium study, 437, 444
Barium sulfate, 91b
Barrett syndrome, 439, 442
Bartholin glands, 512
Basal cell carcinoma, 134, 134f, 135, 148
Basal ganglia, 240
Basophils, 360, 360b, 365
B cells (B lymphocytes), 364–365, 365f
Beau lines, 137, 137f
Bedsore, 133
Behavioral disorders, 235
  anxiety disorders, 235–236, 235b
  attention deficit hyperactivity disorder, 236–237
  autism spectrum disorder, 237
  mood disorders, 236
  treatment, drugs used in, 237
Bell palsy, 241
Bence Jones protein, 379
Benign, 80
Benign neoplasm, 80
Benign prostatic hyperplasia (BPH), 489, 497, 497f, 499, 502
Berry aneurysm, 241
Beta-adrenergic blocking, 345
Bile, 430
Biliary colic, 441, 442
Bilirubin, 377, 440, 442
Billroth operations, 447
Biofeedback, 95, 97
Biopsy, 91, 96
Biot respirations, 411
Bipolar disorder, 236, 240
Bisphosphonates, 162–163, 170, 527
Bladder neck obstruction (BNO), 501
Blepharoptosis, 85t, 86f, 280
Blood, 358, 365
  abbreviations for, 380–381
  case studies
    blood replacement, 388
    latex allergy, 357, 381
    myelofibrosis, 389
  cells, 358, 358f, 359b
    erythrocytes, 358, 359, 359b, 359f
    leukocytes, 358, 359–361, 359b, 360b
  clinical aspects of
    anemia, 370–372
    coagulation disorders, 373
    neoplasms, 373–374
  clotting (coagulation), 362f, 365
  composition of, 358f
  formed elements, 358, 358f, 366
  plasma, 358, 358f
  roots for, 368t, 369t
  suffixes for, 367t
  tests, 370b
  types, 362–363, 363f
Blood–brain barrier, 240
Blood pressure (BP), 90, 90f, 321–323, 323b, 323f, 324
Blood replacement, 388
Blood urea nitrogen (BUN), 477
BNO. *See* bladder neck obstruction
Body structure
  abdominal regions, 54–55, 54f
  body cavities, 54, 54f
    abdominal cavity, 54
    abdominopelvic cavity, 54, 56
    pelvic cavity, 54
    spinal cavity, 54

extern.ir

directional terms, 52, 52f
frontal plane, 53, 53f
positions, 55b–56b
sagittal plane, 53, 53f
transverse plan, 53f
roots
enrichment terms, 60t
extremities, 58t
head and trunk, 57t
position and direction, 55, 59t
Body surface area (BSA), 132, 132f
Bolus, 445
Bone marrow, 156
Bones, 156
in human adult, 152
long, 155, 155f
markings, 173
metabolic diseases, 162–164, 163f, 164f
pelvic, 153f
roots for, 158t
of skeleton, 154b
Bougie, 94b
Bowleg, 161b
BP. *See* blood pressure
BPH. *See* benign prostatic hyperplasia
Brachytherapy, 501
Bradycardia, 331, 334
Bradypnea, 411
Brain, 218, 218f, 219–221, 225, 245f
external surface of, 220f
meninges, 220, 221f, 226
protection, 220, 221f
roots for, 228t
sagittal section, 219f
tumor, 233f
ventricles, 220, 221f
Brainstem, 219, 219f, 220, 225
Brand name, drugs, 106, 107
Braxton Hicks contractions, 541
Breast cancer, 523
Breathing, 395–396
expiration, 395, 396
inspiration, 395, 396, 396f
roots for, 400t
Broca area, 240
Bromhidrosis, 137
Bronchial system, 395
Bronchiectasis, 408
Bronchioles, 395, 397
Bronchitis, 408
Bronchodilator, 414
Bronchopneumonia, 402
Bronchoscope, 405, 409, 410f
Bronchospasm, 411
Bronchus, 395, 397
Bruit, 102, 343
Bruxism, 446
BSA. *See* body surface area
Bubonic plague, 77b
Bulbourethral glands, 492, 493
Bulimia, 446
BUN. *See* blood urea nitrogen
Bundle branches, 324
Bunion, 171, 199b
Burns, 132, 132f
Bursa, 156, 156f
Bursitis, 161b, 171
Byssinosis, 411

C

CABG. *See* coronary artery bypass graft
Cachexia, 446
CAD. *See* coronary artery disease
Calcium, 160
Calcium-channel blocker, 345
Cali-, 271b
Calisthenics, 271b
Calvaria, 170
Calyx, 463, 465
Cancer, 80, 95–96
digestive tract, 437–439, 438f
grading, 95, 96
lung, 405
methods for treatment, 96
of prostate, 497
skin, 134–135
staging, 95–96, 97
of testis, 497
of urinary system, 472–473, 473f
Candida albicans, 375
Candidiasis, 525
Cannula, 94b
Canthotomy, 281
Canthus, 280
Capillaries, 321, 321f, 324
Carbohydrates, 46
Carbon dioxide, 392, 397
Carbonic acid, 396, 397
Carbuncle, 137
Carcinoma, 80
Carcinoma in situ (CIS), 87
Cardia, 445
Cardiac catheterization, 344
Cardiac muscle, 190, 190f, 196
Cardiac output, 342
Cardiac tamponade, 343
Cardiogenic shock, 332
Cardiopulmonary resuscitation (CPR), 332, 337
Cardiovascular system, 316, 316f, 324
abbreviations, 346–347
case studies
arrhythmia, 315, 347
echocardiogram, 354
mitral valve replacement, 354
percutaneous transluminal coronary angioplasty, 354
clinical aspects of
aneurysm, 329, 329f
arrhythmia, 331–332, 332f
atherosclerosis, 328, 329f
congenital heart disease, 332–333, 333f
coronary artery disease, 330–331, 330f
embolism, 328–329, 329f
hypertension, 329–330
myocardial infarction, 331
rheumatic heart disease, 333
thrombosis, 328–329, 329f
veins, disorders of, 333–334, 333f
heart, 317–320, 317f
blood flow, 317–318, 318f
chambers of, 317
disease, 330–333
electrical conduction system, 319f
electrocardiography, 319, 320f
failure, 332
heartbeat, 318–319
layers, 317, 317f
myocardium, blood supply to, 318, 318f
rate, 319
roots for, 326t
sounds, 318
vascular system, 321–323
blood pressure, 321–323, 323f
disorders of, 333–334, 333f
roots for, 327t
Cardioversion, 332, 337
Caries, 436, 442
Carina, 410
Carotid endarterectomy, 231, 239
Carpal tunnel syndrome (CTS), 171, 200–201, 200f
Carrier, 540
Cartilage, 156
Cast, 474
Castration, 501
Casts, 469
Cataract, 278, 278f, 279, 279f
Cataract extraction surgeries, 279f
Catarrh, 404b
Catatonia, 241
Catheter, 102, 103f, 111f
Catheterization, 469, 469f, 475
Cautery/cauterization, 94, 96, 141
CD4+ T lymphocyte counts, 375, 377
Cecum, 429, 430
Celiac disease, 440, 442
Cell, 46
Cells, 41
division, 43
human karyotype, 48t
roots for, 47t–48t
structures, 41–42
types of tissues, 43
Cellulitis, 88
Central nervous system (CNS), 218, 218f, 225
Central venous pressure (CVP), 344
Cephalopelvic disproportion, 542
Cerebellum, 219, 219f, 220, 225
Cerebral angiography, 231, 239
Cerebral arterial circle, 240
Cerebral concussion, 231, 238
Cerebral contusion, 231, 237
Cerebral cortex, 219, 219f, 225
Cerebral palsy, 241
Cerebrospinal fluid (CSF), 220, 225
Cerebrovascular accident (CVA), 231, 238, 256, 329, 334
Cerebrum, 219–220, 219f, 220f
Cerumen, 262, 263
Cesarean section, 542
CF. *See* cystic fibrosis
CFS. *See* chronic fatigue syndrome
Chalazion, 280
Cheilosis, 446
Chemotherapy, 96
Cheyne–Stokes respiration, 411
CHF. *See* congestive heart failure
Childbirth, 531–532

extern.ir

Chiropractic, 95, 97
Chlamydia, 78, 78b
Chlamydia trachomatis, 276, 496
Chloasma, 541
Cholecystectomy, 441, 444, 456
Cholecystitis, 441, 442
Cholelithiasis (gallstones), 441, 441f, 442
Cholestasis, 446
Cholesteatoma, 267
Chondroitin, 172
Chondroma, 171
Chondrosarcoma, 164, 168
Chorea, 241
Choriocarcinoma, 542
Chorionic villus sampling (CVS), 539, 541
Choroid, 269, 270f, 272
Chromosome, 46
Chronic diseases, 76, 80
Chronic fatigue syndrome (CFS), 199, 201
Chronic lymphocytic leukemia (CLL), 373
Chronic myelogenous leukemia, 373, 374f
Chronic obstructive pulmonary disease (COPD), 404–405, 404f, 408
Chronic renal failure, 470, 471f
Chvostek sign, 203
Chyme, 445
Cicatrization, 131, 135
Cigarette smoking, 405
Cilia, 392
Ciliary body, 270, 270f, 272
Cineangiocardiography, 344
Cineradiography, 92b
Circumcision, 492, 493
Cirrhosis, 440–441, 442
CIS. *See* carcinoma in situ
CK. *See* creatine kinase
CK-MB. *See* creatine kinase MB
Clamp, 94b
Claustrophobia, 242
Clavus, 199b
Clean-catch specimen, 477
Clearance, 476
Cleft palate, 540
CLL. *See* chronic lymphocytic leukemia
Clonus, 203
Closed fractures, 162b, 163f
Clubbing, 101, 103f, 333, 335
Clysis, 102
CNS. *See* central nervous system
Coagulation
  blood, 362f, 365
  disorders, 373
  tests, 373b
Coarctation of aorta, 333, 333f, 335
Cocci, 77b
Cochlea, 263
Coitus, 492, 493
Colic, 101
Collagen, 51t
Colles, 162b, 163f
Colon, 429, 430
Colonoscopy, 438, 438f
  with biopsy, 457
Colposcope, 525
Coma, 232, 238
Combining forms, 5–6
Comedo, 137
Comminuted fractures, 162b, 163f
Commissurotomy, 345
Common bile duct, 430
Common cold, 404
Communicable diseases, 87
Complement, 377
Complementary medicine, 95, 97–98
Compliance, 342, 396
Compression fractures, 162b, 163f
Compulsion, 242
Computed tomography (CT), 91b, 92b, 92f
Conductive hearing loss, 266, 267
Condyle, 173
Cone biopsy, 525
Cones, 270, 270f, 272
Confusion, 232, 238
Congenital disorder, 537–539, 540
Congenital heart disease, 332–333, 333f
Congenital hypothyroidism, 301, 304
Congestive heart failure (CHF), 332
Conjunctiva, 269, 272
Conjunctivitis, 276, 279
Conn syndrome, 305
Constipation, 446
Continuous bladder irrigation, 103f
Continuous positive airway pressure (CPAP), 412
Continuous subcutaneous insulin infusion (CSII), 302
Contraception, 515–516
Contracture, 203
Contraindication, 106, 107
Contralateral, 240
Contrecoup, 132b
Contrecoup injury, 231, 238
Convergence, 271, 272
Convulsion, 234, 238
Cooley anemia, 77b, 372, 375
Coombs test, 379
COPD. *See* chronic obstructive pulmonary disease
Cornea, 269, 272
Coronary angiography, 330, 330f, 337
Coronary artery bypass graft (CABG), 331, 331f, 337
Coronary artery disease (CAD), 330–331, 330f
Coronary calcium scan, 330, 337
Coronary circulation, 318, 324
Cor pulmonale, 411
Corpus callosum, 241
Corpuscle, 377
Cortex, 51t
Corticosteroids, 165, 414
Cortisol (hydrocortisone), 295b, 297, 300b
Coryza, 411
Coumadin, 345
Coxa, 170
COX-2 inhibitor, 204
CPR. *See* cardiopulmonary resuscitation
Cranial cavity, 56
Cranial nerves, 220, 221f, 222b, 225
Craniopharyngioma, 305
Cranium, 154b
C-reactive protein (CRP), 330, 335
Creatine, 202
Creatine kinase (CK), 198, 202, 331
Creatine kinase MB (CK-MB), 331, 337
Creatinine, 476
Crest, 173
Creutzfeldt–Jakob disease (CJD), 242
Crib death. *See* sudden infant death syndrome (SIDS)
Crohn disease, 77b, 439, 442
Cross-matching, blood, 363, 365
Croup, 403–404, 408
CRP. *See* C-reactive protein
Cruciate ligaments, 170
Cryoprecipitate, 380
Cryptorchidism, 498, 498f, 499
Cryptosporidium, 375
CSF. *See* cerebrospinal fluid
CSII. *See* continuous subcutaneous insulin infusion
CT. *See* computed tomography
CTA. *See* CT angiography
CT angiography (CTA), 330, 337
CTS. *See* carpal tunnel syndrome
Culdocentesis, 526
Curet (curette), 94b, 95f
Curvatures of spine, 167–168, 168f
Cushing disease, 302, 304
Cushing syndrome, 301–302, 302f, 304
Cutaneous, 126, 128
Cutaneous lymphoma, case study, 149
CVA. *See* cerebrovascular accident
CVP. *See* central venous pressure
CVS. *See* chorionic villus sampling
Cyanosis, 101, 332, 335, 405, 408
Cycl/o, 271b
Cystectomy, 472, 473f, 475
Cystic fibrosis (CF), 405, 408
Cystitis, 469, 474
Cystocele, 526, 476
Cystometrography, 477
Cystoscope, 472, 473f, 475
Cystotome, 281
Cysts, 80
Cytology, 46
Cytoplasm, 46

D

D&E. *See* dilatation and evacuation
Debridement, 131, 136
Decibel (dB), 267
Decongestant, 414
Decubitus ulcer, 133
Deep touch, 260
Deep vein thrombosis (DVT), 334, 335
Defecation, 445
Defibrillation, 332, 337
Degenerative diseases, 76, 233–234, 234f
Degenerative joint disease (DJD), 165, 165f, 168
Deglutition, 445
Dehiscence, 131, 136
Dehydration, 470, 476
Delayed hypersensitivity reaction, 374, 375
Delirium, 242
Delusions, 236, 240
Dementia, 238
Dendrite, 218, 225
Dental hygienists, 428b
Deoxyribonucleic acid (DNA), 46

extern.ir

Depolarization, 319, 324
Depression, 236, 240
Derma, 126, 128
Dermabrasion, 141
Dermatitis, 133, 133f, 136
Dermatology, 130, 136
Dermatome, 136, 241
Dermatomyositis, 199, 201
Dermatophytosis, 137
Dermatoplasty, 141
Dermis, 126, 128
Desensitization, 380
Detrusor muscle, 476
Deviated septum, 411
Diabetes insipidus, 300, 304, 476
Diabetes mellitus (DM), 300–301, 302–303, 304, 313
  diagnosis, 302
  T1DM, 302
  T2DM, 302
  treatment, 302–303
  types of, 302
Diabetic retinopathy, 278, 278f, 279
Diagnosis, medical, 89–91, 96
  abbreviations, 105
  auscultation, 89, 89f, 96
  biopsy, 91, 96
  blood pressure, 90, 90f
  imaging techniques for, 91–93, 91b, 92b–93b
  inspection, 89, 89f, 96
  palpation, 89, 89f, 97
  percussion, 89, 89f, 97
  pulse rate, 90, 90f
  roots, physical forces, 98t
  suffixes for, 99t
  vital signs, 90, 97
Dialysis, 470, 471f, 475
Diaphoresis, 101, 137, 335
Diaphragm, 57
Diaphragm, 396, 397
Diaphysis, 157
Diarrhea, 436, 443
Diarthrosis, 156
Diascopy, 141
Diastole, 318, 324
DIC. *See* disseminated intravascular coagulation
Diencephalon, 219, 219f, 225
Dietitians, 303b
Diffuse toxic goiter. *See* Graves disease
Digestion, 426, 426f
Digestive system, 426, 426f
  abbreviations, 449
  accessory organs, 429–430, 429f, 430b, 430f, 435t
  case studies
    cholecystectomy, 456
    colonoscopy with biopsy, 457
    erosive esophagitis, 425, 429
    gastroesophageal reflux disease, 425, 429
  clinical aspects of
    accessory organs, 440–442
    digestive tract, 436–440
  digestion, 426, 426f
  digestive tract, 426–429, 426f
    large intestine, 429
    mouth to stomach, 427–428, 427f
    organs of, 427b
    roots for, 433t–434t
    small intestine, 428–429
  roots for, 432t, 433t–434t, 435t
  supplementary terms for, 445–447
Digestive tract, 426–429, 426f, 436–440
  cancer, 437–439, 438f
  gastroesophageal reflux disease, 439, 439f
  infection, 436
  inflammatory intestinal disease, 439–440
  large intestine, 429
  mouth to stomach, 427–428, 427f
  obstructions, 439, 439f
  organs of, 427b
  roots for, 433t–434t
  small intestine, 428–429
  ulcers, 436–437
Digit, 60
Digitalis, 345
Dilatation and evacuation (D&E), 541
Diopter, 280
Diphtheria, 401, 408
Discoid lupus erythematosus (DLE), 134, 134f
Diseases, 76
  abbreviations, 89
  acute, 76, 80
  alternative and complementary medicine for, 95
  benign, 80
  case studies, 114
    asthma, 121
    endocarditis, 120
  cause, 76
  chronic, 76, 80
  degenerative, 76
  diagnosis, 89–93, 105
  etiology, 76, 80
  hormonal disorders, 76
  immune disorders, 76
  infectious, 76–78
  mental and emotional disorders, 76
  metabolic disorders, 76
  names, 77b
  neoplasia, 76, 80
  prefixes for, 83t
  responses to
    immunity, 79–80
    inflammation, 79, 79f
    phagocytosis, 79, 79f
  roots for, 82t
  suffixes, 84t, 85t
  supplementary, 87–90
  surgery for, 93–95, 94b, 97
  symptoms, 89
  treatment, 93–95, 105
  types of, 76
Diskectomy, 167, 170
Dissecting aneurysm, 335
Disseminated intravascular coagulation (DIC), 373, 375
Diuresis, 464, 465
Diuretic, 345, 464, 465
Diuretic drugs, 330
Diverticulitis, 440, 443
Diverticulosis, 440, 443
DJD. *See* degenerative joint disease
DLE. *See* discoid lupus erythematosus
DM. *See* diabetes mellitus
DNA. *See* deoxyribonucleic acid
Doppler echocardiography, 344
Drain, 103
Drugs, 106, 107
  abbreviations for, 113–114
  administration, 107
    roots of, 108
  adverse effects, 106
  information, 106
  inhalation of, 108, 109f
  injectable, terms pertaining to, 111
  instillation of, 108, 109f
  names, 106
  prefixes for, 112
  preparations, 110
  roots for, 112
  suffixes for, 112
Drusen, 280
Duchenne muscular dystrophy, 198
Ductless glands. *See* endocrine glands
Ductus (vas) deferens, 492, 493
Dukes classification, 437, 444
Duodenal bulb, 445
Duodenal papilla, 445
Duodenum, 428, 431
Dura mater, 220, 221f, 225
DVT. *See* deep vein thrombosis
Dynamometer, 203
Dysarthria, 242
Dyskeratosis, 137
Dyslipidemia, 328, 335
Dysmenorrhea, 525
Dysmetria, 242
Dyspareunia, 526
Dyspepsia, 446
Dysphagia, 439, 443
Dyspnea, 330, 335, 405, 408
Dysthymia, 236, 240
Dysuria, 469, 474

E

Ear, 262–263, 262f–263f
  abbreviations, 269
  disorders, 267
  roots, 264t–265t
  treatment, 267
Eardrum. *See* tympanic membrane
Ebola, 77b
Ecchymoses, 137, 373, 375
ECG. *See* electrocardiography
Echocardiogram, 354
Echocardiography, 330, 337
Eclampsia, 540
ECMO. *See* extracorporeal membrane oxygenation
Ectopic beat, 343
Ectopic pregnancy, 540
Eczema, 133, 133f, 136
ED. *See* erectile dysfunction
Edema, 79, 79f, 80, 332, 335, 470
Eectopic pregnancy, 535–536
EEG. *See* electroencephalography

extern.ir

Efferent neuron. *See* sensory neuron
Efficacy, 107
Effusion, 88
Ejaculation, 492, 493
Ejaculatory duct, 492, 493
Electrocardiography (ECG), 319, 320f, 324, 330
Electroencephalography (EEG), 232, 239
Electrolyte imbalance, 470, 470b
Electrolytes, 358, 366
Electromyography (EMG), 198, 202
Electronystagmography (ENG), 268
Electrophoresis, 379
Electroretinography (ERG), 281
Elevator, 94b
ELISA, 379
Embolectomy, 345
Embolism, 231, 238, 328–329, 329f, 335
Embolus, 328–329, 335
Emergency medical technicians (EMTs), 77b
Emesis, 436, 443
Emetic, 447
EMG. *See* electromyography
Emission, 500
Emmetropia, 280
Emphysema, 404–405, 404f, 408
Empyema, 406, 408
EMTs. *See* emergency medical technicians
Encephalitis, 233, 238
Endemic diseases, 87
Endocarditis, 120
Endocardium, 317, 324
Endocrine glands, 294–297, 294f, 295b, 298
Endocrine system, 294, 298
  abbreviations, 307
  case studies
    diabetes, 313
    Graves disease, 293, 307
    hyperparathyroidism, 312
  clinical aspects of, 300–303
    adrenals, 301–302
    diabetes, 302–303
    pancreas, 302–303
    parathyroids, 301
    pituitary, 300–301
    thyroid, 301
  endocrine glands, 294–297, 294f, 295b
    adrenal glands, 295b, 297, 297f, 298, 301–302
    pancreas, 297, 297f
    parathyroid glands, 295b, 296f, 297, 301
    pituitary gland, 295b, 296
    thyroid gland, 295b, 296–297, 296f
  endocrine tissues, 297–298
  hormones, 294, 295b, 298
  roots for, 299t
  supplementary terms for, 305–306
Endocrine tissues, 297–298
Endometrial ablation, 542
Endometriosis, 525
Endoscope, 90, 90f, 96
Endoscopic retrograde cholangiopancreatography (ERCP), 441, 442f, 444
Endoscopy, 437, 437b, 437f, 444
Endotracheal intubation, 413f
End-stage renal disease, 487
ENG. *See* electronystagmography
Enucleation, 281
Enuresis, 476
Enzyme, 46
Enzymes, 426, 431
Eosinophils, 360, 360b, 366
Epicardium, 317, 324
Epicondyle, 173
Epicondylitis, 199–200
Epidermis, 126, 127f, 128
Epididymis, 492, 493
Epididymitis, 496, 499
Epidural hematoma, 231, 232f, 238
Epigastrium, 60
Epiglottis, 394, 397
Epiglottitis, 411
Epilepsy, 232, 234, 238
Epinephrine (adrenaline), 374, 377
Epiphyseal plate, 157
Epiphysis, 157
Episiorrhaphy, 526
Episiotomy, 512
Epispadias, 476
Epistaxis, 411
EPO. *See* erythropoietin
Eponym, 320b
Equilibrium receptors, 261
ERCP. *See* endoscopic retrograde cholangiopancreatography
Erectile dysfunction (ED), 498, 498b, 499, 509
Erection, 492, 493
ERG. *See* electroretinography
Erosive esophagitis, 425, 429
Eructation, 446
Erysipelas, 137
Erythema, 133, 136
Erythema nodosum, 138
Erythrocytes, 358, 359, 359b, 359f, 366
Erythrocytosis, 378
Erythropoietin (EPO), 359, 366, 462, 465
Escharotomy, 131, 136
Escherichia coli, 232, 469
Esophagus, 428, 431
Esthesi/o, 271b
Estrogen, 295b
Euphoria, 242
Eustachian tube. *See* auditory tube
Evisceration, 131, 136
Evoked potentials, 243
Ewing tumor, 171
Exacerbation, 87
Exanthema, 138
Excision, 94, 96
Excoriation, 138
Exercise and fitness, careers in, 193b
Exercise physiologists, 193b
Exophthalmos, 301, 304
Exostosis, 171
Expectorant, 414
Expectoration, 395, 397
Expiration (exhalation), 395, 396, 397
External auditory canal (meatus), 262, 263
Extracorporeal membrane oxygenation (ECMO), 542
Extrasystole, 343
Extubation, 412
Exudate, 88, 131
Eye and vision
  abbreviations for, 282
  clinical aspects of, 276–279
    cataract, 278, 278f, 279f
    glaucoma, 278
    infection, 276
    refraction, errors of, 276, 277f
    retina, disorders of, 276–278, 277f, 278f
  roots for, 273t, 274t
  suffixes for, 276t
  supplementary terms for, 280–281
  surgery, 277b
Eyebrows, 269, 269f
Eyelashes, 269, 269f

F

Facet, 173
Facial bones, 154b
Facies, 102
Fallopian tube, 512
Familial adenomatous polyposis (FAP), 446
Fanconi syndrome, 378
FAP. *See* familial adenomatous polyposis
Farsightedness. *See* hyperopia
Fascia, 190, 190f, 196
Fascicles, 190, 190f, 196
Fasciculation, 203
Fasting plasma glucose (FPG), 306
FDA. *See* Food and Drug Administration
Febrile, 102
Feces, 429, 431
Female reproductive system
  abbreviations, 528
  case study, 544
  clinical aspects
    cancer (*see* Female reproductive tract)
    endometriosis, 522–523
    fibroids, 522
    polycystic ovarian syndrome, 523
  enrichment terms, 541–543
  menopause, 515
  menstrual cycle, 514–515
  ovaries, 512
Fetal circulation, 530
Fibrillation, 332, 335
Fibrin, 361, 366
Fibrinogen, 361, 366
Fibrocystic disease of breast, 526
Fibroid, 514, 525
Fibromyalgia syndrome (FMS), 199, 201, 375
Fibromyositis, 203
Fibrositis, 203
Fimbriae, 512
Fissure, 88
Fistula, 88, 439, 443
Fitness workers, 193b
Fixation, 96
Flatulence, 446
Flatus, 446
Floater, 280
Fluoroscopy, 92b
Flutter, 343
FMS. *See* fibromyalgia syndrome

extern.ir

Follicle-stimulating hormone (FSH), 295b, 490, 493, 514
Folliculitis, 138
Fontanel, 541
Food and Drug Administration (FDA), 106
Foramen, 173
Forceps, 94b, 95f
Formed elements, blood, 358, 358f
Fossa, 173
Fovea, 271, 272
FPG. *See* fasting plasma glucose
Fractures, 162, 168
  reduction of, 162, 170
  types of, 162b, 163f
Free thyroxine index (FTI), 306
Fremitus, 411
FSH. *See* follicle-stimulating hormone
FTI. *See* free thyroxine index
FTSG. *See* full-thickness skin graft
Fulguration, 141
Full-thickness skin graft (FTSG), 132
Functional murmur, 318, 324
Fundus, 60
Fundus, 280, 463b
Fungi, 78b
Furuncle, 138

G

GAD. *See* generalized anxiety disorder
Galactorrhea, 542
Gallbladder, 430, 431
Gallstones, 441, 441f
Gametes, 490, 493
Gamma globulin, 365, 366
Ganglion, 219, 225
Gangrene, 88
Gas transport, 396
Gastric bypass, 448f
Gastroduodenostomy, 4, 4f
Gastroenteritis, 436, 443
Gastroesophageal reflux disease (GERD), 425, 429, 439, 439f, 443
Gastrojejunostomy, 448f
Gavage, 447
GDM. *See* gestational diabetes mellitus
Gene, 46
Generalized anxiety disorder (GAD), 235
Generic name, drugs, 106, 107
Genitalia, 500
Genitourinary (GU) tract, 490
Genu, 170
Genu varum, 161b
GERD. *See* gastroesophageal reflux disease
Gestational diabetes mellitus (GDM), 302
GFR. *See* glomerular filtration rate
GH. *See* growth hormone
Giant cell tumor, 171
Gigantism, 300, 304
Gigli saw, 94b
Glans penis, 492, 493
Glasgow Coma Scale, 243
Glaucoma, 278, 279
Gleason tumor grade, 501
Glenoid cavity, 170
Glioblastoma, 242
Gliomas, 233, 238
Glomerular capsule, 463, 465
Glomerular filtrate, 463–464, 465
Glomerular filtration rate (GFR), 476
Glomerulonephritis, 375, 469–470, 474
Glomerulus, 463, 465
Glottis, 394, 397
Glucagon, 295b
Glucosamine, 172
Glucose, 46
Glycated hemoglobin (HbA1c) test, 303, 304
Glycogen, 51t
Glycogen, 202
Glycosuria, 302, 304, 476
Goiter, 304
Golfer's elbow, 200
Gonads, 298, 490, 493
Goniometer, 172
Gonioscopy, 281
Gonorrhea, 276, 496
Gout, 165, 168
Graafian follicle, 526
Grading, cancer, 95, 96
Graft *versus* host reaction (GVHR), 378
Gram stain, 80
Granulocytes, 360, 360b, 366
Graves disease, 293, 301, 301f, 304, 307, 375
Gray matter, of nervous system, 218, 225
Greater omentum, 445
Greenstick fractures, 162b, 163f
Grippe, 404b
Growth hormone (GH), 295b, 296b, 300b
Guillain–Barré syndrome, 242
Gustation (taste), 260, 261
GVHR. *See* graft *versus* host reaction
Gyrus, 219, 220f, 225

H

Haemophilus influenzae, 232
Hair, 127, 127f, 128
Hair follicle, 127, 127f, 128
Hairy cell leukemia, 378
Hallucinations, 236, 240
Hallux, 170
Hallux valgus, 199b
Hammertoe, 171
Hamstring strain, 201
Hantavirus fever, 77b
Hashimoto disease, 305
HAV. *See* hepatitis A virus
HBV. *See* hepatitis B virus
HCL. *See* hydrochloric acid
HDN. *See* hemolytic disease of the newborn
Head injury, 231–232
Healing, wounds, 131–132
Hearing
  clinical aspects of
    acoustic neuroma, 266
    hearing loss, 266
    Ménière disease, 266
    otitis, 266
    otosclerosis, 266
  loss, 266
  receptors, 261
Heart, 317–320, 317f, 324
  blood flow, 317–318, 318f
  chambers of, 317
  disease, 330–333
  electrical conduction system, 319f
  electrocardiography, 319, 320f
  failure, 332, 335
  heartbeat, 318–319
  layers, 317, 317f
  myocardium, blood supply to, 318, 318f
  rate, 319, 325
  roots for, 326t
  sounds, 318, 325
Heartbeat, 318–319
Heart block, 331–332, 332f, 335
Heartburn, 439, 443
Heberden nodes, 171
Helicobacter pylori, 436
Helminths, 78b
Hemangioma, 138
Hemarthrosis, 171
Hematemesis, 446
Hematocrit, 370b, 371f
Hematologists, 371b
Hematoma, 378
Hematomyelia, 242
Hematuria, 469, 474
Hemiballism, 242
Hemiparesis, 231, 238
Hemiplegia, 231, 238
Hemodialysis, 470, 475
Hemodialysis technician, 472b
Hemoglobin, 359, 366, 396, 397
Hemolysis, 372, 376
Hemolytic disease of the newborn (HDN), 378, 540
Hemophilia, 373, 376
Hemopoietic stem cell, 377
Hemoptysis, 403, 408
Hemorrhagic anemia, 372, 376
Hemorrhoids, 334, 335, 439, 443
Hemosiderosis, 378
Hemostat, 94b, 95f, 366
Hemothorax, 406, 408
Heparin, 329, 345, 377
Hepatic flexure, 445
Hepatic portal system, 430, 431
Hepatitis, 440, 443
Hepatitis A virus (HAV), 440
Hepatitis B virus (HBV), 440
Hepatitis C, 440
Hepatitis D, 440
Hepatitis E, 440
Hepatomegaly, 440, 443
Herbal medicines, 106–107
HER2 inhibitor, 527
Hernia, 76, 80, 81f
Herniated disk, 166–167, 167f, 168
Herniorrhaphy, 498, 500, 508
Herpes simplex, 138
Herpes virus, 233
Hertz (Hz), 267
Hiatal hernia, 439, 443
High functioning autism, 237
Hilum, 410
Hirsutism, 138, 536
Histamine H_2 antagonist, 447
HIV. *See* human immunodeficiency virus
Hodgkin disease, 77b

extern.ir

Hodgkin lymphoma, 373–374, 374f, 376
Holistic health care, 95, 97
Holter monitor, 344
Homeopathy, 95, 97
Homeostasis, 46
Homocysteine, 344
Homologous blood, 380
Homonyms, 428b
Hordeolum, 280
Hormonal disorders, 76
Hormonal imbalances, 235
Hormone replacement therapy (HRT), 162
Hormones, 294, 295b, 298
Horseshoe kidney, 476, 478f
Housemaid's knee, 161b
HRT. *See* hormone replacement therapy
HTN. *See* hypertension
Human adult skeleton, 152
Human immunodeficiency virus (HIV), 233, 374–375, 376
Humoral immunity, 294b, 364–365, 364f
Humors, 294b
Hunchback, 168
Huntington disease, 242
Hydatidiform mole, 542
Hydramnios, 542
Hydrocele, 501
Hydrocephalus, 233, 233f, 238
Hydrochloric acid (HCl), 428
Hydronephrosis, 472, 474
Hydrophobia, 235b
Hydrothorax, 406, 408
Hydroureter, 476
Hymen, 526
Hyoid, 154b
Hyperglycemia, 302, 304
Hyperkalemia, 470b, 474
Hypernatremia, 470b, 474
Hyperopia, 276, 277f, 279
Hyperparathyroidism, 312
Hyperplasia, 88
Hyperpnea, 410
Hypersensitivity, 374, 376
Hypertension (HTN), 329–330, 335, 470
Hypertrophy, 88
Hyperventilation, 401, 409
Hypochondriasis, 242
Hypochondrium, 60
Hypoglycemia, 303, 304
Hypokalemia, 470b, 474
Hypolipidemic agent, 345
Hyponatremia, 470b, 474
Hypophysis. *See* pituitary gland
Hypopnea, 410
Hypoproteinemia, 470, 474
Hypospadias, 476, 478f
Hypotension, 343
Hypothalamus, 219f, 220, 225, 296, 298
Hypoventilation, 401, 409
Hypovolemia, 476
Hypovolemic shock, 332
Hysterectomy, 525
Hz. *See* hertz

I

IABP. *See* intraaortic balloon pump
Iatrogenic diseases, 87
IBD. *See* inflammatory bowel disease
Ibuprofen, 106
ICD. *See* implantable cardioverter defibrillator
Ichthyosis, 138
Icterus, 440, 441f, 443
Ictus, 242
Idiopathic adolescent scoliosis, 151
Idiopathic diseases, 87
Idiopathic thrombocytopenic purpura (ITP), 378
IF. *See* intrinsic factor
IGT. *See* impaired glucose tolerance
Ileal conduit, 472, 473f, 475
Ileocecal valve, 445
Ileum, 428, 431
Ileus, 439, 443
Ilium, 153, 153f, 157
Imaging techniques, 91–93, 91b, 92b–93b
Immune disorders, 76
Immune serum, 365
Immunity, 79–80, 364, 364f, 366
  abbreviations for, 380–381
  adaptive, 364–365, 364f, 368
  clinical aspects of
    autoimmune diseases, 375
    hypersensitivity, 374
    immunodeficiency, 374–375
  innate, 364
  roots for, 368t
Immunodeficiency, 374–375, 376
Immunoglobulins (Ig), 364, 364f, 366
Immunology, 365
Immunosuppression, 380
Immunotherapy, 96
Impacted fractures, 162b, 163f
Impaired glucose tolerance (IGT), 305
Impetigo, 138, 138f
Implantable cardioverter defibrillator (ICD), 332
Impotence, 498, 500
Incision, 96
Incus (anvil), 262, 262f, 264
Induration, 88
Indwelling Foley catheter, 477
Infarct, 331, 335
Infectious diseases, 76, 77b–78b, 78
  prefixes, 86t
  roots, 86t
Infectious mononucleosis, 378
Infectious organisms, 77b–78b, 401b–402b
Inferior vena cava, 317, 318f, 325
Infertility, 535
Infertility, 497f, 498, 500
Inflammation, 79, 79f, 80
Inflammatory bowel disease (IBD), 77b, 439–440
Inflammatory intestinal disease, 439–440
Influenza, 403, 409
Inguinal canal, 490, 491f, 493
Inguinal hernia, 498, 499f, 500
INH. *See* isoniazid
Injectable drugs
  materials, 111f
  terms pertaining to, 111
Injection, 108, 109f
Innate immunity, 364
Insemination, 500
Insertion, 192, 196
Insomnia, 234, 238
Inspection, 89, 89f, 96
Inspiration (inhalation), 395, 396, 396f, 397
Insulin, 295b, 300b
Insulin shock, 303, 304
Integumentary system, 126, 128
  abbreviations, 141
  case studies
    basal cell carcinoma, 148
    cutaneous lymphoma, 149
  clinical aspects of, 130–131
    autoimmune disorders, 134, 134f
    dermatitis, 133, 133f
    nurse practitioners, 131b
    psoriasis, 133, 133f
    skin cancer, 134–135
    types, 130b
    wounds, 131–133
  enrichment terms, 137–140
  key terms, 135–136
  medication patches, 126b
  pressure ulcer, 125
  roots, 129
Intermittent claudication, 343
Intermittent positive pressure breathing (IPPB), 412
Intermittent positive pressure ventilation (IPPV), 412
Interneurons, 218, 225
Interstitial, 51t
Interstitial cells, 490, 493
Intestinal obstructions, 439, 439f
Intestine, 428, 431
Intraaortic balloon pump (IABP), 345
Intraocular lens (IOL), 278
Intraocular lens implant, phacoemulsification with, 291
Intrapartum, 541
Intravenous pyelography (IVP), 473, 473f, 475
Intravenous urography (IVU), 473, 473f, 475
Intrinsic factor (IF), 372, 376
Intubation, 413
Intussusception, 439, 439f, 443
In vitro fertilization (IVF), 542
IOL. *See* intraocular lens
Iontophoresis, 172
IPPB. *See* intermittent positive pressure breathing
IPPV. *See* intermittent positive pressure ventilation
Ipsilateral, 241
Iris, 270, 270f, 272
Irrigation, 102
Irritable bowel syndrome (IBS), 446
Ischemia, 328, 335
Ischium, 153, 153f
Isometric, 202
Isoniazid (INH), 414
Isotonic, 202
ITP. *See* idiopathic thrombocytopenic purpura
IVF. *See* in vitro fertilization

extern.ir

IVP. *See* intravenous pyelography
IVU. *See* intravenous urography

J

Jaundice, 440, 441f, 443
JCAHO. *See* Joint Commission on Accreditation of Healthcare Organizations
Jejunum, 428, 431
Joint Commission on Accreditation of Healthcare Organizations (JCAHO), 8
Joints, 152, 156, 156f, 157
  disorders, 164–166
  repair, 165–166
  roots for, 158t

K

Kaposi sarcoma, 135, 136, 375, 376
Karyotype, 541
Keloids, 131, 131f, 136
Keratin, 126, 128
Keratoconus, 280
Keratometer, 281
Keratosis, 138
Ketoacidosis, 302, 304
Ketosis, 305
Kidneys, 462–463, 463f, 465
  blood supply to, 463
  location and structure, 462–463, 463f
  nephrons, 463, 464f
  roots for, 465t
Kinesthesia, 202
Klebsiella pneumoniae, 402
Kleptomania, 235b
Knee joint, 156, 156f
Knock-knee, 161b
Korotkoff sounds, 342
Kussmaul respiration, 411
Kyphosis, 168

L

Labyrinth, 263, 263f, 264
Labyrinthitis, 268
Lacrimal (tear) glands, 269, 272
Lactate, 202
Lactation, 532
Lacteals, 429, 431
Laminectomy, 173
Laparoscopy, 526
Large intestine, 429, 431
Laryngopharynx, 393
Larynx, 393, 394, 394f, 397
Laser, 96
Laser in situ keratomileusis. *See* LASIK
Laser trabeculoplasty, 277b
LASIK (laser in situ keratomileusis), 277b
Latex allergy, 357, 381
Lavage, 102, 132b, 447
Laxative, 447
LCA. *See* left coronary artery
L-dopa (levodopa), 233, 239
LE. *See* lupus erythematosus
Left anterior descending (LAD) artery, 318
Left AV valve, 318, 318f, 325
Left bundle branch, 319, 319f
Left coronary artery (LCA), 318
Legg–Calvé–Perthes disease, 171
Leiomyoma, 525
Lens, 270, 270f, 272
Leptomeninges, 241
LES. *See* lower esophageal sphincter
Lesions, 76, 77, 80
Lethargy, 242
Leukemias, 373, 376
Leukocytes, 358, 359–361, 359b, 360b, 366
Leukoplakia, 437, 443
Leukorrhea, 526
Leukotriene antagonist, 414
LH. *See* luteinizing hormone
Lichenification, 138, 138f
Lidocaine, 345
Ligaments, 156, 157
Ligature, 103
Linea nigra, 541
Lingual tonsils, 393, 393f, 397
Lipid, 46
Lipoproteins, 328, 337
Liquid biopsy, 91
Lithotomy, 472, 475
Lithotripsy, 472, 472f, 475
Lithotrite, 477
Liver, 430, 431
Lobar pneumonia, 402
Lobectomy, 413
Lochia, 541
Long bone, 155, 155f
Loop diuretic, 345
Lordosis, 168, 169
Lower esophageal sphincter (LES), 428, 431
Lower extremity bones, 153, 154b
Lumbar puncture, 232–233, 232f, 239
Lumen, 60
Lungs, 392, 395, 395f, 397
  cancer, 405
  giant cell sarcoma, case study, 422
  roots for, 400t
  scans, 406, 409
Lupus erythematosus (LE), 77b, 134, 136
Luteinizing hormone (LH), 295b, 490, 493
Lyme disease, 77b
Lymph, 337, 339
Lymphadenitis, 341, 342
Lymphadenopathy, 373, 376
Lymphangitis, 341, 342
Lymphatic system, 337, 338f, 339, 339f
  clinical aspects of, 341
  roots for, 340t
Lymphedema, 341b, 342, 342f
Lymph nodes, 339, 339f
Lymphocytes, 360b, 361, 366
Lymphocytic leukemia, 373
Lymphocytosis, 378
Lymphoma, 341, 342

M

Macula, 271, 271f, 272, 463b
Magnetic resonance imaging (MRI), 91b, 92b, 92f
Malaise, 102
Male reproductive system, 490, 490f
  abbreviations, 502
  case studies
    benign prostatic hyperplasia, 489, 502
    erectile dysfunction, 509
    herniorrhaphy, 508
    transurethral resection of prostate, 489, 502
    vasectomy, 508
  clinical aspects of, 496–499
    benign prostatic hyperplasia, 497, 497f
    cryptorchidism, 498, 498f
    erectile dysfunction, 498, 498b
    infection, 496, 496b
    infertility, 497f, 498
    inguinal hernia, 498, 499f
    prostatic cancer, 497
    testicular cancer, 497
  penis, 492, 492f
  roots for, 494t
  semen, 492
  spermatozoa, transport of, 491f, 492
  supplementary terms for, 500–501
  testes, 490, 491f, 492
Malignant neoplasm, 80, 81
Malleolus, 170
Malleus (hammer), 262, 262f, 264
Malnutrition, 76
Mammary glands, 512–513
Mammography, 523, 525
Manias, 235b, 236, 240
Manometry, 447
MAOI. *See* monoamine oxidase inhibitor
Massage, 95, 98
Mastectomy, 525
Mastication, 427, 431
Mastitis, 536–537, 540
Mastoiditis, 268
Mastoid process, 267
Maximal transport capacity (Tm), 476
Meatus, 173
Meconium, 541
Mediastinoscopy, 412
Mediastinum, 395, 397
Medical technologists, 371b
Medical terminology
  abbreviations, 8
  combining forms, 5–6
  medical dictionaries, 8–9
  prefixes, 18–26
  pronunciation, 6–7
  suffix, 9–10
  unusual pronunciations, 7, 7b
  word derivations, 6, 6f
    suffixes beginning with *rh,* 6
    words ending in *x,* 6
  word parts, 4–6
Meditation, 95, 98
Medulla, 51t
Medulla, 463b
Medulla oblongata, 219f, 220, 226
Megacolon, 446
Megakaryocytes, 361, 366
Meibomian gland, 280

extern.ir

Meiosis, 428b, 490, 493
Melanoma, 80, 135, 135f, 136
Melatonin, 295b
Melena, 446
Membrane, 46
Membranes, 45
MEN. *See* multiple endocrine neoplasia
Ménière disease, 266, 267
Meninges, brain, 220, 221f, 226
Meningioma, 233, 238
Meningitis, 232–233, 238
Meningococcus *(Neisseria meningitidis)*, 232
Meniscectomy, 173
Meniscus, 170
Menopause, 515
Menstrual bleeding abnormalities, 523
Menstrual cycle, 514–515
Mental and emotional disorders, 76
Mesentery, 445
Mesocolon, 445
Metabolic bone diseases, 162–164, 163f, 164f
Metabolic disorders, 76
Metabolic syndrome, 302, 304
Metabolism, 46
Metaphysis, 157
Metaplasia, 88
Metastasis, 80, 81
Metrorrhagia, 525
MG. *See* myasthenia gravis
MI. *See* myocardial infarction
Microcalcification, 526
Microorganism, 81
Micturition, 465
MID. *See* multi-infarct dementia
Midbrain, 219f, 220, 226
Migraine, 242
Mild traumatic brain injury (MTBI), 231
Miliary tuberculosis, 403, 403f
Miosis, 280, 428b
Mitosis, 46
Mitral valve, 318, 318f, 325
Mitral valve prolapse, 343
Mitral valve replacement (MVR), 354
Mixed nerves, 219
Molar tooth, 427, 427f
Monoamine oxidase inhibitor (MAOI), 244
Monoclonal antibody, 379
Monocytes, 360b, 361, 366
Mons pubis, 526
Mood disorders, 236
Motor neuron, 218, 219f, 226
Motor unit, 202
Motrin, 106
Mouth, 426, 426f, 427, 427f, 431, 432t
MRI. *See* magnetic resonance imaging
MS. *See* multiple sclerosis
MTB. *See* mycobacterium tuberculosis
MTBI. *See* mild traumatic brain injury
Mucolytic, 414
Mucus, 46
Multi-infarct dementia (MID), 234, 238
Multiple endocrine neoplasia (MEN), 305
Multiple myeloma, 171, 374, 376
Multiple sclerosis (MS), 233, 238
Murmur, 333, 335
Murphy sign, 447
Muscle
  relaxant, 204
  strain, 199, 201
  tone, 190
Muscular dystrophy, 198, 201
Muscular system, 190, 196
  abbreviations, 204
  action, 190–191, 191f, 192f
  case studies
    brachial plexus injury, 189, 205
    rotator cuff tear, 212
    "wake-up" test during spinal fusion surgery, 214
  clinical aspects of, 198–201
    multiple-system disorders, 198–199
    muscular dystrophy, 198
    stress injuries, 199–201
  movement, types of, 192b, 193f
  naming, 194, 194f, 195f
  roots, 197t
  structure, 190, 190f
  supplementary terms, 202–204
  types of
    cardiac, 190, 190f
    skeletal, 190, 190f
    smooth, 190, 190f
Mutation, 540
MVR. *See* mitral valve replacement
Myasthenia gravis (MG), 199, 201, 375
Mycobacterium tuberculosis (MTB), 403
Mycosis fungoides, 139
Mydriasis, 280
Mydriatic, 281
Myelin, 218, 226
Myelinated axons, 218
Myelodysplastic syndrome, 378
Myelofibrosis, 378, 389
Myelogenous leukemia, 373
Myelogram, 173
Myocardial infarction (MI), 331, 332, 335
Myocardium, 317
  blood supply to, 318, 318f
Myoglobin, 202
Myomectomy, 527
Myopia, 276, 277f, 279
Myosin, 190, 196
Myringotomy, 266, 267

N

Nails, 127, 127f, 128
Narcolepsy, 234, 238
Nares, 410
Nasal cannula, 412, 412f
Nasal septum, 410
Nasogastric (NG) tube, 447, 448f
Nasopharynx, 393
National Center for Complementary and Alternative Medicine (NCCAM), 95
National Institutes of Health (NIH), 95
Naturopathy, 95, 98
Nausea, 436, 443
NCCAM. *See* National Center for Complementary and Alternative Medicine
Nearsightedness. *See* myopia
Necrosis (death of tissue), 76, 81
Negative prefixes, 21t
Neisseria gonorrhoeae, 496
Neoplasia, 76, 80, 81
Neoplasms, 80, 81, 233, 233f, 373–374
Nephrology technician, 472b
Nephrons, 463, 464f, 465
Nephrotic syndrome, 470, 474
Nerves, 219, 226
Nervous system, 218
  abbreviations, 245
  autonomic, 224, 224f
  behavioral disorders, 235
    anxiety disorders, 235–236, 235b
    attention deficit hyperactivity disorder, 236–237
    autism spectrum disorder, 237
    mood disorders, 236
    treatment, drugs used in, 237
  brain, 219–221
    external surface of, 220f
    protection, 220, 221f
    roots for, 228t
    sagittal section, 219f
  case studies
    cerebrovascular accident, 256
    diving accident, 217, 246
    neuroleptic malignant syndrome, 257
    spinal cord injury, 217, 246
  clinical aspects of
    coma, 232
    confusion, 232
    degenerative diseases, 233–234, 234f
    epilepsy, 234
    head injury, 231–232
    hormonal imbalances, 235
    infection, 232–233
    neoplasms, 233, 233f
    sleep disturbances, 234
    vascular disorders, 231
  gray matter, 218
  organization of, 218–219, 218f
    nerves, 219
    neuron, 218–219, 219f
  roots for, 227t
  spinal cord, 222, 223f
    reflexes, 222, 223f
    roots for, 227t
    spinal nerves, 222, 223f
  suffixes for, 230t
  supplementary terms, 240–244
  white matter of, 218
Neurasthenia, 271b
Neurilemmoma. *See* acoustic neuroma
Neurofibromatosis, 242
Neurogenic arthropathy, 171
Neurogenic bladder
Neuroglia, 218, 226
Neuroleptic malignant syndrome, 257
Neuroleptics, 237, 244
Neuromuscular junction (NMJ), 190, 191f, 196
Neuron, 218–219, 219f, 226
Neurosis, 242
Neurotransmitters, 219, 226

extern.ir

Neutropenia, 378
Neutrophils, 360, 360b, 366
Nevus, 139
NHL. *See* Non-Hodgkin lymphoma
NIH. *See* National Institutes of Health
Nitroglycerin, 346
NMJ. *See* neuromuscular junction
Nocturia, 477
Nocturnal, 102
Nodes, 218
Non-Hodgkin lymphoma (NHL), 374, 376
Nonrapid eye movement (NREM) sleep, 234
Nonsteroidal anti-inflammatory drugs (NSAIDs), 165, 170, 204
Norepinephrine, 241
Normal saline (NS), 102
Nose, 392–393, 393f, 397
Nosocomial, 87
Noun suffixes, 9–10
NP. *See* nurse practitioner
NS. *See* normal saline
NSAIDs. *See* nonsteroidal anti-inflammatory drugs
Nuclear medicine, 102
Nucleus, 47
Nucleus, 241
Nucleus pulposus, 171
Nurse practitioner (NP), 131b
Nutritional anemia, 371–372, 372f, 376
Nutritionists, 303b
Nyctalopia, 280
Nystagmus, 280

O

OA. *See* osteoarthritis
Oblique fractures, 162b, 163f
Obsessive–compulsive disorder (OCD), 236, 240
Obstetrics, 543
Obstipation, 446
Occlusion, 331, 336
Occlusive vascular disease, 343
Occult blood, 437, 443
Occupational therapy (OT), 203
  careers in, 235b
OCD. *See* obsessive–compulsive disorder
ODS. *See* Office of Dietary Supplements
Office of Dietary Supplements (ODS), 106
OGTT. *See* oral glucose tolerance test
OI. *See* osteogenesis imperfecta
Olecranon, 171
Olfaction (smell), 260, 261
Oligohydramnios, 542
Oliguria, 469, 474
OMeatus, 60
Oncologists, 95
One-way valves, heart, 317, 318f
Oocyte, 526
Oophorectomy, 523
Open fractures, 162b, 163f
Ophthalmia neonatorum, 276, 279
Ophthalmoscope, 90, 90f, 96
Opportunistic diseases, 87
Optic disk, 272
Oral glucose tolerance test (OGTT), 306
Orbit, 269, 269f, 272
Orchitis, 496, 500
Organ, 47
Organelle, 47
Organs and organ systems
  digestive system, 45–46, 45f
Orgasm, 500
Orifice, 60
Origin, 192, 196
ORL. *See* otorhinolaryngology
Oropharynx, 393
Orthopedics, 160, 170
Orthopneic position, 412
Os, 171
Osgood–Schlatter disease, 172
Osseous, 171
Ossicles, 154b, 262, 262f, 264
Ossification, 157
Osteoarthritis (OA), 165, 165f, 169
Osteoblast, 157
Osteochondroma, 172
Osteochondrosis, 172
Osteoclast, 157
Osteocyte, 157
Osteodystrophy, 172
Osteogenesis imperfecta (OI), 172, 186
Osteogenic sarcoma, 164, 169
Osteoma, 172
Osteomalacia, 163–164, 169
Osteomyelitis, 162, 169
Osteopathy, 95, 98
Osteopenia, 163, 169
Osteoplasty, 173
Osteoporosis, 162–163, 163f, 169
Ostomy surgery, 438, 438f, 444
Otitis, 266
  externa, 266, 267
  media, 266, 267
Otorhinolaryngology (ORL), 268
Otosclerosis, 266, 267
Otoscope, 90, 90f, 96, 268
Ovaries, 512, 513f
Ovaries, 295b, 298
Over-the-counter (OTC) drugs, 106
Oxygen (O_2), 393f, 395, 397
Oxytocin, 295b, 296

P

Pacemaker, 319, 336
Paclitaxel, 527
Paget disease, 164, 164f, 169
Pain, 260
Palate, 427, 431
Palatine tonsils, 393, 393f, 397
Palliative therapy, 93, 96
Pallor, 102
Palpation, 89, 89f, 97
Palpebrae, 269, 269f, 272
Palpitation, 343
Pancreas, 297, 297f, 302–303, 430, 431
Pancreatic islets, 297, 297f, 298
Pancreatitis, 441, 443
Pancytopenia, 378
Pandemic diseases, 87
Panhypopituitarism, 300, 304
Panic disorder, 235, 240
Papilla of Vater rugae, 445
Papilledema, 280
Paracentesis, 102
Paralysis, 231, 239
Paranoia, 236, 240
Paraplegia, 242
Parasite, 81
Parasomnia, 242
Parasympathetic nervous system, 224, 226
Parathyroid glands, 295b, 296f, 297, 301
Parathyroid hormone (PTH), 295b, 297, 300b
Parathyroids, 301
Parenchyma, 51t
Parenteral hyperalimentation, 447
Parietal, 51t
Parkinsonism, 233, 239
Paronychia, 139, 139f
PAs. *See* physician assistants
Patent ductus arteriosus, 333, 333f, 336
Patent ductus arteriosus (PDA), 542
Pathogen, 81
PCOS. *See* polycystic ovarian syndrome
PCP. *See Pneumocystis* pneumonia
PCWP. *See* pulmonary capillary wedge pressure
PDA. *See* patent ductus arteriosus
PDR. *See physicians' Desk Reference*
Pediatrics, 543
Pediculosis, 139
PEEP. *See* positive end-expiratory pressure
Pelvic bones, 153, 153f, 154b
Pelvic cavity, 57
Pelvic inflammatory disease (PID), 522, 525
Pelvimetry, 543
Pelvis, 153, 153f, 157
Pemphigus, 134, 134f, 136
Penis, 492, 492f, 493
PEP. *See* protein electrophoresis
Pepsin, 428
Peptic ulcers, 436, 444
Percussion, 89, 89f, 97
Percutaneous endoscopic gastrostomy (PEG) tube, 447, 448f
Percutaneous transluminal coronary angioplasty (PTCA), 330, 330f, 337, 354
Perfusion, 342
Pericardium, 317, 325
Perimenopause, 526
Periosteum, 157
Peripartum, 541
Peripherally inserted central catheter (PICC), 111f
Peripheral nervous system (PNS), 218, 226
Peristalsis, 426, 426f, 431
Peritoneal dialysis, 470, 475
Peritoneum, 57
Peritoneum, 431
Peritonitis, 436, 444
Pernicious anemia, 372, 376, 446
Pertussis, 401, 409
PET. *See* positron emission tomography
Petechiae, 139, 373, 376
Peyer patches, 339
PH, 379
Phacoemulsification, 277b, 278, 279, 279f
Phagocytosis, 79, 79f, 81, 361, 366

extern.ir

Phallus, 500
Pharynx (throat), 392, 393–394, 393f, 398, 428, 431
Pheochromocytoma, 305
Philadelphia chromosome (Ph), 373, 376
Phimosis, 501
Phlebitis, 334, 336
Phlebotomist, 344, 371b
Phlyctenule, 280
Phobia, 235, 235b, 240
Phonocardiography, 344
Phorometer, 281
Photosensitization, 139
Phrase abbreviations, 8
Phrenic nerve, 396, 398
Physical examination, 89, 104
Physical therapists (PTs), 161b
Physical therapy (PT), 161b, 204
Physician assistants (PAs), 499b
Physicians' Desk Reference (PDR), 106
Phytomedicine, 106, 107
Pia mater, 220, 221f
PICC. *See* peripherally inserted central catheter
PID. *See* pelvic inflammatory disease
PIH. *See* pregnancy-induced hypertension
Pilonidal cyst, 446
Pineal gland, 294f, 295b, 297, 298
Pinna (auricle), 262, 264
Pitocin, 543
Pitting edema, 343, 343f
Pituitary apoplexy, 305
Pituitary gland, 219f, 220, 295b, 296, 298, 300–301, 493
Placental abnormalities, 536
Placental abruption, 540
Placenta previa, 540
Plaque, 328, 336
Plasma
  blood, 358, 358f, 366
  cells, 364, 366
Plasmin, 378
Platelets, 358, 359, 361, 361f, 366
Plethysmography, 344, 412
Pleura, 395, 395f, 398
Pleural disorders, 405–406, 405f, 406f
Pleural effusion, 406, 406f, 409
Pleural friction rub, 411
Pleural space, 395, 395f, 398
Pleurisy, 405, 409
Plexus, 241
Plural formation, 15, 15t
PMNs. *See* poly morphonuclear leukocytes
Pneumoconiosis, 405, 409
Pneumocystis jirovecii, 375
Pneumocystis pneumonia (PCP), 403
Pneumonia, 402–403, 402f, 409
Pneumonitis, 403, 409
Pneumoplasty, 413
Pneumotachometer, 412
Pneumothorax, 405, 406f, 409
PNS. *See* peripheral nervous system
Poisons. *See* toxins
Poliovirus, 233
Polyarteritis nodosa, 344
Polycystic kidney disease, 477, 478f
Polycystic ovarian syndrome (PCOS), 523
Polycythemia, 378
Polycythemia vera, 378
Polydipsia, 477
Poly morphonuclear leukocytes (PMNs), 361, 361f
Polymorphs, 361
Polymyositis, 198–199, 201
Polyps, 88, 437, 444
Polysomnography, 234, 239
Polyuria, 477
Pons, 219f, 220, 226
Popeye's shoulder, 161b
Portal hypertension, 441, 444
Positive end-expiratory pressure (PEEP), 413
Positron emission tomography (PET), 93b, 243
Postconcussion syndrome, 231
Posterior pituitary gland, 295b
Posttraumatic stress disorder (PTSD), 236, 240
Postural drainage, 413
Potassium, in body fluids, 470b
Potentiation, 106, 107
Pott disease, 162, 162b, 163f, 169
PPI. *See* proton pump inhibitor
Precordium, 342
Preeclampsia, 536, 540
Prefixes, 18–19
  for colors, 20t
  for degree, 23t
  for direction, 22t
  negative, 21t
  for numbers, 18t
  position, 25t, 26t
  for size and comparison, 24t
  for time, 25t
Prefixes
  for disease, 83t
  for drugs, 112
Pregnancy and birth
  childbirth, 531–532
  clinical aspects
    abortion, 540
    ectopic pregnancy, 535–536
    mastitis, 536–537
    placental abnormalities, 536, 537f
    preeclampsia, 536
    Rh incompatibility, 536
  enrichment terms, 541–543
  fertilization and early development, 528, 529f
  lactation, 532–533
  placenta, 528, 530f
  roots for, 534t–535t
Pregnancy-induced hypertension (PIH), 540
Prehypertension, 329
Prepuce, 492, 493
Presby, 271b
Presbyacusis, 268
Presbycusis, 271b
Presbyopia, 271b, 276, 279
Prescription (Rx) drugs, 106, 107
Pressure ulcers, 125, 133, 136
Priapism, 501
Prime mover, 191, 196
Process, 173
Prodrome, 102
Progesterone, 295b
Prognosis, 93, 97
Progressive systemic sclerosis (PSS), 134
Prolactin, 295b
Prolapse, 81, 95
Pronunciation, 6–7
Prophylaxis, 103
Proprioception, 260, 261
Prostaglandins, 298
Prostatectomy, 497, 500
Prostate gland, 492, 493
Prostatic cancer, 497
Prostatitis, 496, 500
Prosthesis, 173
Protease inhibitor, 380
Protein, 47
Protein electrophoresis (PEP), 477
Proteinuria, 469, 470, 474
Proton pump inhibitor (PPI), 447
Protozoa, 78b
Prozac, 106, 236b
Pruritus, 133, 136
Pseudophakia, 281
Psoriasis, 133, 133f, 136
PSS. *See* progressive systemic sclerosis
Psychoactive drugs, 236b
Psychosis, 240
PTCA. *See* percutaneous transluminal coronary angioplasty
PTH. *See* parathyroid hormone
PTs. *See* physical therapists
PTSD. *See* posttraumatic stress disorder
Puberty, 490, 493
Pubis, 153, 153f
Puerperium, 542
Pulmonary artery, 317, 318f, 325
Pulmonary capillary wedge pressure (PCWP), 323b, 344
Pulmonary circuit, 317, 317f, 325
Pulmonary function tests, 406, 407b, 409
Pulmonary valve, 318, 325
Pulmonary veins, 317, 318f, 325
Pulmonary ventilation, 395, 396f, 398
Pulse, 319, 325
  pressure, 343
  rate, 90, 90f, 325
Pulse oximetry, 406, 406f, 409
Pupil, 270, 270f, 272
Purkinje fibers, 319, 319f, 325
Purpura, 139, 373, 376
Purulent, 88
Pus, 79, 81
Pyelonephritis, 469, 474
Pyloric stenosis, 439, 444
Pylorus, 428, 431
Pyothorax, 406, 409
Pyramidal tracts, 241
Pyuria, 469, 474

Q

Quadriplegia, 242
Quinsy, 404b

extern.ir

R

RA. *See* rheumatoid arthritis
Rabies virus, 233
Radiation therapy, 96
Radioactive iodine uptake test (RAIU), 306
Radiography, 91, 91b, 91f, 93b, 97
Radioimmunoassay (RIA), 306
Radiology, 102
Radionuclide, 102
Radionuclide heart scan, 344
RAIU. *See* radioactive iodine uptake test
Rales, 411
Rapid eye movement (REM) sleep, 234
RAS. *See* reticular activating system
Rasp, 94b
Raynaud disease, 134, 344
RBCs. *See* red blood cells
RDS. *See* respiratory distress syndrome
Receptors, 294, 298
Rectocele, 526
Rectum, 429, 431
Red blood cells (RBCs), 358, 359, 359b, 359f
Reed–Sternberg cells, 374, 374f, 377
Reflexes, 222, 223f, 226
Refraction, 270f, 271, 272
  errors of, 276, 277f
Regurgitation, 344, 439, 444
Reiter syndrome, 172
Remission, 97
Remission of diseases, 88
Renal calculi, 486
Renal colic, 472, 474
Renal corpuscle, 476
Renal cortex, 463, 465
Renal failure, 474
Renal insufficiency, 470
Renal medulla, 463, 465
Renal pelvis, 463, 465
Renal pyramids, 463, 465
Renal technician, 472b
Renal transplantation, 470, 475
Renin, 462, 466
Repetitive strain injury (RSI), 199, 201
Repolarization, 319, 325
Resection, 103
Resectoscope, 501
Resorption, 157
Respiration, 392, 392f
Respiratory distress syndrome (RDS), 405, 409
Respiratory syncytial virus (RSV), 403
Respiratory system, 392, 392f, 393f
  abbreviations, 414–415
  breathing, 395–396
    expiration, 395, 396
    inspiration, 395, 396, 396f
    roots for, 400t
  case studies
    giant cell sarcoma of the lung, 422
    preoperative respiratory testing for asthma, 391, 415
    terminal dyspnea, 423
  clinical aspects of, 401–407
    asthma, 405
    cystic fibrosis, 405
    emphysema, 404–405, 404f
    infections, 401–404
    lung cancer, 405
    pleural disorders, 405–406, 405f, 406f
    pneumoconiosis, 405
    respiratory disorders, diagnosis of, 406, 406f, 407f
    respiratory distress syndrome, 405
    sudden infant death syndrome, 405
  gas transport, 396
  infectious organisms for, 401b–402b
  lower respiratory passageways, 394
    bronchial system, 395
    larynx, 394, 394f
    trachea, 394–395
  lungs, 395, 395f
    roots for, 400t
  roots for, 399t
  suffixes for, 398t
  upper respiratory passageways, 392
    nose, 392–393, 393f
    pharynx (throat), 392, 393–394, 393f
Respiratory therapy, careers in, 407f
Restless legs syndrome (RLS), 203
Retention of urine, 477
Reticular activating system (RAS), 241
Reticulocyte counts, 372, 377
Reticulocytes, 372b
Retina, 270, 270f, 272
Retina, disorders of, 276–278, 277f, 278f
Retinal detachment, 276–278, 277f, 279
Retinitis, 281
Retinitis pigmentosa, 281
Retinoblastoma, 281
Retinoscope, 281
Retractor, 94b, 95f
Retrograde pyelography, 473, 473f, 475
Reye syndrome, 243
Rhabdomyolysis, 203
Rhabdomyoma, 203
Rhabdomyosarcoma, 203
Rheumatic heart disease, 333, 336, 375
Rheumatism, 203
Rheumatoid arthritis (RA), 165, 165f, 169
Rheumatoid factor, 165, 169
Rheumatology, 204
Rh incompatibility, 536
RhoGAM, 543
Rhonchi, 411
RIA. *See* radioimmunoassay
Ribonucleic acid (RNA), 47
Rickets, 163–164, 164f, 169
Rickettsia, 78, 78b
Rifampin (rifampicin), 414
Rift Valley fever, 77b
Right AV valve, 318, 318f, 325
Right bundle branch, 319, 319f
Right coronary artery (RCA), 318
Right lymphatic duct, 337, 339
Rinne test, 268, 268f
Rods, 270, 270f, 272
Romberg sign, 243
Rongeur, 94b
Roots, 222, 223f, 226
  for accessory organs, 435t
  for blood, 368t, 369t
  for bones, 158t
  for brain, 228t
  for breathing, 400t
  for digestive system, 432t, 433t–434t, 435t
  for digestive tract, 433t–434t
  for disease, 82t
  of drug administration, 108
  for drugs, 112
  ear, 264t–265t
  for endocrine system, 299t
  for eye and vision, 273t, 274t
  for heart, 326t
  for immunity, 368t
  for infectious disease, 86t
  for integumentary system, 129
  for joints, 158t
  for lungs, 400t
  for lymphatic system, 340t
  for male reproductive system, 494t
  for mouth, 432t
  for muscular system, 197t
  for nervous system, 227t
  for physical forces, 98t
  for respiratory system, 399t
  for skeleton system, 159t
  for spinal cord, 227t
  for urinary system, 465t, 467t
  for urinary tract, 467t
  for vascular system, 327t
Rosacea, 139
Rotator cuff (RTC) injury, 199, 200f
Rotator cuff tear, 212
RSI. *See* repetitive strain injury
RSV. *See* respiratory syncytial virus
Rubella, 77b
Rule of nines, 132f, 136

S

SAD. *See* seasonal affective disorder
Sagittal plane, 57
Saliva, 427, 432
Salivary glands, 429–430, 429f
Salpingectomy, 523, 525
Salpingitis, 525
Sarcoma, 80, 81
Scabies, 139
Scalpel, 94b, 95f
Scarlet fever, 77b
Schilling test, 379
Schizophrenia, 236, 240
Schwann cells, 241
Schwannoma. *See* acoustic neuroma
Sciatica, 243
Scintigraphy, 93b
Scissors, 94b
Sclera, 269, 273
Scleroderma, 126, 134, 136
Scoliosis, 168, 169
Scotoma, 281
Scrotal abnormalities, 501f
Scrotum, 490, 490f, 494
Seasonal affective disorder (SAD), 305, 306b

extern.ir

Sebaceous glands, 126, 128
Sebum, 126, 128
Seizures, 233, 239
Selective estrogen receptor modulators (SERMs), 162, 170
Selective serotonin reuptake inhibitor (SSRI), 244
Sella turcica, 305
Semen, 492, 494
Semicircular canals, 263, 264
Semilunar valves, 318
Seminal vesicles, 492, 494
Seminoma, 501
Senile lentigines, 139
Senses, 260–261
Sensorineural hearing loss, 266, 267
Sensory neuron, 218, 226
Sensory receptors, 260, 261
Sensory system, 260–261
  case studies
    amblyopia, 259, 282
    audiology report, 290
    intraocular lens implant, phacoemulsification with, 291
  ear, 262–263, 262f–263f
    abbreviations, 269
    disorders, 267
    roots, 264t–265t
    treatment, 267
  eye and vision, 269–271
    abbreviations for, 282
    clinical aspects of, 276–279
    roots for, 273t, 274t
    suffixes for, 276t
    supplementary terms for, 280–281
  hearing, clinical aspects of
    acoustic neuroma, 266
    hearing loss, 266
    Ménière disease, 266
    otitis, 266
    otosclerosis, 266
  suffixes for, 261t
Sentinel node biopsy, 525
Sepsis, 78, 82
Septal defect, 332–333, 333f, 336
Septicemia, 88, 379
Septic shock, 332
Septum, 60
Septum, 317, 325
Sequela, 102
SERMs. *See* selective estrogen receptor modulators
Seroconversion, 379
Sertoli cells, 490, 494
Serum, 361, 367
Sex hormones, 295b, 297
Sexually transmitted infections (STIs), 496, 496b, 500
SG. *See* specific gravity
Shingles, 139, 233, 239
Shin-splint, 201
Shock, 332, 336
Shoulder girdle, 154b
Sickle cell anemia, 372, 372f, 376
Side effects, drugs, 106, 107
Sideroblastic anemia, 372, 376
SIDS. *See* sudden infant death syndrome
Sigmoid colon, 429, 432
Sign, 97
Simmonds disease, 305
Single-photon emission computed tomography (SPECT), 93b
Sinoatrial (SA) node, 319, 319f, 325
Sinuses, 60, 173, 174f, 392, 398
Sinus rhythm, 319, 325
Sjögren syndrome, 375, 376
SK. *See* streptokinase
Skeletal muscle, 190, 190f, 196
Skeleton, 157
Skeleton system
  abbreviations, 174
  bones, 154b
    formation, 155
    long, 155, 155f
  case studies
    arthroplasty of right TMJ, 184
    idiopathic adolescent scoliosis, 151, 175
    osteogenesis imperfecta, 186
  clinical aspects of, 160–168
    fractures, 162, 162b, 163f
    infection, 162
    joint disorders, 164–166
    metabolic bone diseases, 162–164, 163f, 164f
    neoplasms, 164
    spine, disorders of, 166–168
  divisions of, 152–153, 152f, 153f
  human, 152
  joints, 156, 156f
  roots for, 159t
  structure and function, terms for, 156–157
  supplementary terms, 170–173
Skin, 126, 128
  anatomy of, 126, 127f
  burns, 132
  cancer, 134–135
  case studies, 148–149
  clinical aspects of, 130–131
    autoimmune disorders, 134, 134f
    dermatitis, 133, 133f
    psoriasis, 133, 133f
    wounds, 131–133
  cross-section of, 127f
  lesions, types of, 130b
  medication patches, 126b
  receptors for general senses in, 260, 260f
  structures, 126–128
Skin turgor, 141
Skull, 152, 152f
SLE. *See* systemic lupus erythematosus
Sleep apnea, 234, 239, 412
Sleep disturbances, 234
Slit-lamp biomicroscope, 281
Small cell carcinoma, 412
Small intestine, 428–429, 432
Smooth (visceral) muscle, 190, 190f, 196
Snellen chart, 281
Sodium, in body fluids, 470b
Somatic nervous system, 218, 226
Somatoform disorders, 243
Somatotropin, 295b, 492b
Somnambulism, 243
Sound, 94b, 95f
Spasm, 203
Spasticity, 203
Specific gravity (SG), 473, 475
SPECT. *See* single-photon emission computed tomography
Speculum, 102, 103f, 527
Spermatic cord, 492, 494
Spermatocele, 501
Spermatozoa, transport of, 490, 491f, 492
Spermatozoon, 494
Sphenoid bone, 305
Spherocytic anemia, 379
Sphincter, 60
Sphincter of Oddi, 445
Sphygm/o, 271b
Sphygmomanometer, 90, 97, 271b, 322, 323f, 325
Spina bifida, 540
Spinal cavity, 57
Spinal cord, 218, 218f, 222, 223f, 226
  reflexes, 222, 223f
  spinal nerves, 222, 223f
Spinal nerves, 222, 223f, 226
Spine, 173
  curvatures of, 167–168, 168f
  disorders of, 166–168
Spiral fractures, 162b, 163f
Spiral organ (organ of Corti), 263, 264
Spirochetes, 77b
Spirogram, 407f
Spirometer, 406, 410
Spleen, 339
Splenic flexure, 445
Splenomegaly, 373, 377, 441, 444
Split-thickness skin graft (STSG), 132
Spondee, 268
Spondylolisthesis, 166, 167f, 169
Spondylolysis, 166, 169
Spondylosis, 172
Sprain, 201
Sputum, 392, 398
Squamous cell carcinoma, 134, 135f, 136
SSRI. *See* selective serotonin reuptake inhibitor
Staghorn calculus, 477, 478f
Staging, cancer, 95–96, 97
Stapedectomy, 266, 267
Stapedius, 267
Stapes (stirrup), 262, 262f
Stapling, 103
Stasis, 344
Statins, 346
Stem cell, 51t
Stenosis, 333, 336
Stents, 330, 331f, 337
Stereotactic biopsy, 525
Sterility, 496, 500
Steroid hormones, 294, 298
Steroids, 165, 191b
Steth/o, 271b
Stethoscope, 90, 97
-sthen/o, 271b
Stimulants, 244
STIs. *See* sexually transmitted infections
Stoma, 438, 444

extern.ir

Stomach, 428, 432
Strabismus, 281
Streptococcus pneumoniae, 232, 402
Streptokinase (SK), 346
Stress incontinence, 461, 479
Stress injuries, 199–201
Stress tests, 330, 337
Striae atrophicae, 542
Stridor, 411
Stroke, 231, 239, 329, 336
Stroke volume, 343
STSG. *See* split-thickness skin graft
Student's elbow, 161b
Stupor, 243
Subacute bacterial endocarditis (SBE), 344
Subcutaneous layer, skin, 126, 128
Subdural hematoma, 231, 232f, 239
Subluxation, 172
Substance dependence, 106, 107
Substance withdrawal, 106, 107
Sudden infant death syndrome (SIDS), 405, 409
Suffixes
  adjective, 13t
  for blood, 367t
  condition of, 10t
  for diagnosis, medical, 99t
  for disease, 84t
  for drugs, 112
  for eye and vision, 276t
  for nervous system, 230t
  noun, 9–10
  for respiratory system, 398t
  for sensory system, 261t
  for surgery, 100t
Sulcus, 219, 220f, 226
Superior vena cava, 317, 318f, 325
Suppuration, 88
Surfactant, 396, 398
Surgeon, 103
Surgery, 93–95, 94b, 97
  instruments for, 94b
  purposes of, 94–95
  suffixes for, 100t
Surgical fixation, 94
Surgical instruments, 94b
Suture, 97, 156, 157
Swan–Ganz catheter, 323b, 344
Swayback, 168
Sweat (sudoriferous) glands, 126, 128
Symbols, 104
Symbols, medical terminology, 8
Sympathectomy, 243
Sympathetic nervous system, 224, 226
Symphysis, 156, 157
Symphysis pubis, 171
Symptoms, 89, 97
Synapse, 219, 226
Syncope (fainting), 102, 332, 336
Syndrome, 102
Synechia, 281
Synergist, 192, 196
Synergy, 106, 107
Synovial fluid, 156, 157
Synovial joint, 156, 157
Syringomyelia, 243
Systemic circuit, 317, 317f
Systemic diseases, 88
Systemic lupus erythematosus (SLE), 134, 375, 377
Systemic sclerosis, 375, 377
Systole, 318, 325

T

Tabes dorsalis, 243
Tachycardia, 331, 336
Tachypnea, 410
Tactile sense, 260, 261
Tailor's bottom, 161b
Talipes, 172
Target tissue, 294, 298
Tarsorrhaphy, 281
Tarsus, 280
TB. *See* tuberculosis
TBG. *See* thyroxine-binding globulin
TCA. *See* tricyclic antidepressant
T cells (T lymphocytes), 364, 367
Teletherapy, 527
Temperature, 260
Tendinitis, 199, 201
Tendons, 156, 157, 190, 190f, 196
Tennis elbow, 161b, 200
Tenosynovitis, 199, 202
Teratogen, 540
Testes, 295b, 298, 490, 491f, 492
Testicular cancer, 497
Testis, 494
Testosterone, 494
Testosterone, 295b, 490
Tetanus, 203
Tetany, 203, 301, 304
Tetralogy of Fallot, 344
TGV. *See* thoracic gas volume
Thalamus, 219f, 220, 227
Thalassemia, 372, 377
Therapy, 93, 97
Thoracentesis, 406, 406f, 410
Thoracic cavity, 57
Thoracic duct, 337, 340
Thoracic gas volume (TGV), 413
Thoracoscopy, 412
Thorax, 153, 154b, 157
Thrombin, 378
Thromboangiitis obliterans, 344
Thrombocytes, 358, 359b, 361, 361f, 367
Thrombocytopenia, 373, 377
Thrombophlebitis, 334, 336
Thrombosis, 231, 239, 328–329, 329f, 336
Thrombotic thrombocytopenic purpura (TTP), 379
Thrombus, 328–329, 336
Thrush, 446
Thymus, 297–298, 339, 340
Thyroid, 301
  gland, 295b, 296–297, 296f, 298
  scan, 306
Thyroid-stimulating hormone (TSH), 295b, 300b
Thyroid storm, 305
Thyrotoxicosis, 305
Thyroxine, 295b
Thyroxine-binding globulin (TBG) test, 297, 306
TIA. *See* transient ischemic attack
Tic, 243
Tic douloureux, 243
Tick- and mosquito-borne viruses, 233
Tinea, 139, 139f
Tinea versicolor, 139
Tinnitus (ringing in ears), 266, 267
Tissue plasminogen, 346
Tn. *See* troponin
TNM system, 96
Tolerance, 106, 107
Tomosynthesis, 525
Tonometer, 281
Tonsillectomy, 394b
Tonsillitis, 394b
Tonsils, 339, 340, 393, 393f
Tonus, 190, 196
Torticollis, 203
Tourette syndrome, 243
Toxins, 78, 82
Trachea, 394–395, 398
Tracheostomy, 413
Tracheostomy tube, 413f
Tracheotomy, 413
Trachoma, 276, 279
Traction, 162, 170
Tracts, 222, 227
Transdermal (TD) patches, 126b
Transesophageal, 345
Transient ischemic attack (TIA), 243
Transsphenoidal adenomectomy, 306
Transurethral incision of prostate (TUIP), 497, 497f
Transurethral resection of prostate (TURP), 489, 497, 497f, 502
Transverse fractures, 162b, 163f
Transverse plane, 57
Trauma, 76, 82
Tremor, 233, 239
Trephination, 243
Trichotillomania, 235b
Tricuspid valve. *See* right AV valve
Tricyclic antidepressant (TCA), 244
Triglyceride, 345
Trigone, 464f, 465, 466
Triiodothyronine, 295b
Trocar, 94b
Trochanter, 173
Troponin (Tn), 331, 337
Trousseau sign, 204
TSH. *See* thyroid-stimulating hormone
TTP. *See* thrombotic thrombocytopenic purpura
Tubercles, 77b, 173
Tuberculin test, 403, 410
Tuberculosis (TB), 77b, 162, 403, 403f, 409
Tuberosity, 173
Tubular reabsorption, 464, 466
TUIP. *See* transurethral incision of prostate
Tumors, of nervous tissue, 233
Turbinate bones, 392, 398
TURP. *See* transurethral resection of prostate
Tussis, 411
Tylenol, 106
Tympanic membrane, 262, 264

extern.ir

Type 1 diabetes mellitus (T1DM), 302
Type 2 diabetes mellitus (T2DM), 302

U

UA. *See* urinalysis
UFE. *See* uterine fibroid embolization
Ulcerative colitis, 439–440, 440f, 444
Ulcers, 436–437
Ultrasonography, 539, 539f, 541
Ultrasonography, 93b, 93f
Umbilicus, 542
United States Pharmacopeia (USP), 106
Urea, 464, 466
Uremia, 470, 475
Ureter, 463, 466
Ureterocele, 477, 478f
Urethra, 464f, 465, 466, 490, 492b, 494
Urethritis, 469, 475, 496, 500
Urinalysis (UA), 473, 475
Urinary bladder, 464–465, 464f, 466
Urinary frequency, 477
Urinary incontinence, 465, 477
Urinary lithiasis, 472
Urinary stasis, 469, 475
Urinary system, 462, 462f
  abbreviations, 479
  case studies
    end-stage renal disease, 487
    renal calculi, 486
    stress incontinence, 461, 479
  clinical aspects of, 469–473
    cancer, 472–473, 473f
    chronic renal failure, 470, 471f
    glomerulonephritis, 469–470
    infections, 469
    nephrotic syndrome, 470
    urinalysis, 473
    urinary lithiasis, 472
  kidneys, 462–463, 463f
    blood supply to, 463
    location and structure, 462–463, 463f
    nephrons, 463, 464f
    roots for, 465t
  roots for, 465t, 467t
  supplementary terms for, 476–477
  urine formation, 463–464
    transport and removal of, 464–465, 464f
Urinary tract infections (UTIs), 469
Urinary urgency, 477
Urination, 465, 466
Urine, 466
  formation, 463–464
  transport and removal of, 464–465, 464f
Urinometer, 477
Urogenital (UG) tract, 490
Urticaria, 140, 140f, 374, 377
USP. *See* United States Pharmacopeia
Uterine fibroid embolization (UFE), 522
Uterine tube, 492b
UTIs. *See* urinary tract infections
Uvea, 269–270, 270f, 273
Uvula, 427, 432

V

VAC. *See* vacuum-assisted closure
Vacuum-assisted closure (VAC), 131
VAD. *See* ventricular assist device
Vaginal speculum, 103f
Vaginitis, 525
Vagotomy, 447
Valgus, 172
Valsalva maneuver, 343
Valves, 325
Varicella-zoster virus, 233
Varicocele, 501
Varicose veins, 333–334, 333f, 336
Varus, 172
Vascular disorders, 231
Vascular system, 321–323
  blood pressure, 321–323, 323f
  roots for, 327t
Vascular technologists, 334b
Vas deferens, 492b, 494
Vasectomy, 492b, 498, 500, 508
Vasodilator, 346
Vegetation, 344
Veins, 321, 322f, 325
  disorders of, 333–334, 333f
  varicose, 333–334, 333f
Venous stasis ulcer, 140, 140f
Ventricles, 220, 221f, 227, 317, 326, 463b
Ventricular assist device (VAD), 345
Ventriculography, 345
Venules, 321, 321f, 326
Vernix caseosa, 542
Verruca, 140
Vertebral column, 152, 153f, 154b
Vertigo (dizziness), 266, 267
Vessel, 326
Vestibular apparatus, 263, 264
Vestibule, 263, 264, 526
Vestibulocochlear nerve, 263, 264
Vibrios, 77b
Villi, 429, 429f, 432
Vincent disease, 446
Viruses, 78b
Visceral, 51t
Visceral nervous system. *See* autonomic nervous system (ANS)
Vision receptors, 261
Visual acuity, 270, 270f, 273
Vital signs (VS), 90, 97
Vitiligo, 140, 140f
Vitreous body, 270f, 271, 273
Vocal folds, 394, 398
Voice box, 394
Volvulus, 439, 439f, 444
Von Recklinghausen disease, 172, 305
Von Willebrand disease, 379
VS. *See* vital signs

W

Waiter's tip position, 161b
"Wake-up" test during spinal fusion surgery, 214
Wallerian degeneration, 243
Warfarin, 329
Water intoxication, 477
WBCs. *See* white blood cells
Weber test, 268, 268f
Wernicke area, 241
Western blot assay, 379
West Nile disease, 77b
West Nile virus, 233
Wheeze, 411
Whiplash, 243
White blood cells (WBCs), 358, 359–361, 359b
White matter, of nervous system, 218, 227
White of eye. *See* sclera
Whitmore–Jewett staging, 501
WHO. *See* World Health Organization
Wilms tumor, 477
Windpipe, 394
Withdrawal, substance, 106, 107
Wolff–Parkinson–White, 344
Wood lamp, 141
Word components
  prefix, 5
  root, 4
  suffix, 4
Word derivations, 6, 6f
World Health Organization (WHO), 77b
Wounds, 131–133
  healing, 131–132
  skin, 131–133
Wright stain, 379

X

Xanthoma, 281
Xenophobia, 235b
Xeroderma, 126
Xeroderma pigmentosum, 140

Y

Yellow fever, 77b

Z

Zonule, 280

extern.ir